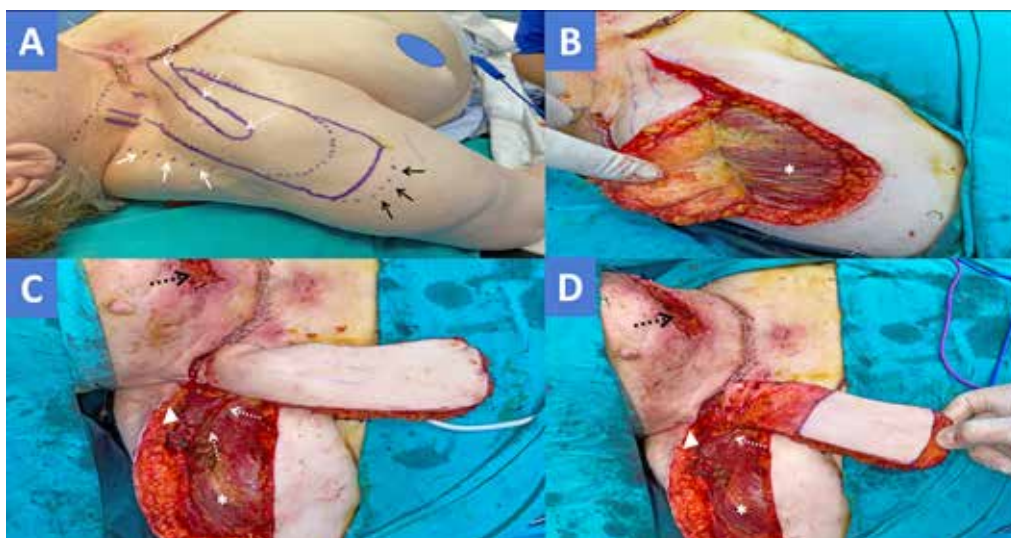


ACTA CHIRURGIAE PLASTICAE



Sahin et al., p. 53

Contents:

Long-term donor-site morbidity after thumb reconstruction with twisted-toe technique
Kempný T. et al.

Supraclavicular artery island flap for head and neck reconstruction Şahin B. et al.

Free tensor fascia lata flap – a reliable and easy to harvest flap for reconstruction
Manjunath K. N. et al.

Presence of circulating tumor cells in a patient with multiple invasive basal cell carcinoma – a case report Kiss K. et al.

Pyoderma gangrenosum: a rare complication of reduction mammoplasty – a case report
Šíroková M. et al.

Negative pressure therapy in the orofacial region in oncological patients – two case reports Štembířek J. et al.




Volume 63 | July 2021 | Issue 2

THE COMPANY ADYTON LTD, AN EXCLUSIVE SUPPLIER OF MOTIVA IMPLANTS AND MEDICAL DEVICES IS A GENERAL PARTNER OF THE JOURNAL ACTA CHIRURGIAE PLASTICAE FOR THE YEAR 2021.

Published by the Czech Medical Association of J. E. Purkyně. ISSN (print) 0001-5423, ISSN (online) 1805-4404, Reg. No. E4844
ABSTRACTED/INDEXED BY: ADIS INTERNATIONAL LTD., EBSCOHOST, ELSEVIER BV (EMBASE, SCOPUS), INTERNATIONAL ATOMIC ENERGY AGENCY, PUBMED, MEDLINE, BIBLIOGRAPHIA MEDICA CZECHOSLOVACA

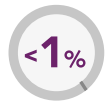Motiva® 6th Generation Breast Implants¹

The most comprehensive advanced smooth² portfolio with the only smooth ergonomic and smooth anatomical implants globally³

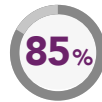

SmoothSilk®/ SilkSurface®

- Advanced **360° smooth surface** nanotechnology, bioengineered to be **cell friendly/biocompatible**^{1,4}
- **Less bacteria and biofilm formation** compared to macro/microtextured surfaces^{6,7}
- **Less inflammation and healthier capsule formation** compared to traditional smooth surfaces⁸



<1% Less than 1% overall complication rate (capsular contracture, rupture, late seroma & double capsule)^{9,10,11}



85% Of surgeons stated Motiva Implants[®] reduce overall complications¹

FIRST-OF-ITS-KIND SAFETY FEATURES



TrueMonobloc®

Harmonious **shell-gel-patch** interaction designed to reduce rippling⁵



BluSeal®

100% visual confirmation of the gel barrier layer designed to minimize gel bleed⁹



Q Inside® Safety Technology

Optional **digital passport for implant traceability** (passive radiofrequency identification)¹²

ERGONOMIC GEL ProgressiveGel™ Ultima®

- Dynamic 'anatomical' implant designed to **mimic natural breast tissue** and **maximize patient comfort**¹
- **100%** absolute consensus that the **Ergonomix® produces softer breasts** and **85% more natural look** compared to Motiva® Round implants¹

STATE-OF-THE-ART MANUFACTURING

- **Energy-efficient and sustainable** Gold LEED^{*} certified facility
- **MDSAP^{*} certified** Quality System satisfying the strictest requirements of global regulatory jurisdictions including US FDA

EVOLUTION: Top 3 Reasons Surgeons Transitioned to Motiva Implants^{®1}

92%

Technology

77%

Implant softness

62%

Safety

1. Sforza M, Hammond DC, Botti G et al. Expert Consensus on the Use of a New Bioengineered, Cell-Friendly, Smooth Surface Breast Implant. Aesth Surg. J. 2019 May; 39(S3):S95-S102. doi: 10.1093/asj/sjz054 2. ISO-14607:2018 Non-active surgical implants - Mammary implants - Particular requirements. 3. Atlan M. Lecture presented at: Audition publique ANSM.; March 26, 2019; Paris, France. 4. Cappellano G, Ploner C, Lobenwein S et al. Immunophenotypic characterization of human T cells after in vitro exposure to different silicone breast implant surfaces. PLoS ONE 2018;13(2):e0192108. 5. Chacón M, Chacón M, Fassero J. Six-Year Prospective Outcomes of Primary Breast Augmentation with Nano-Surface Implants. Aesthet Surg J. 2018; doi: 10.1093/asj/sjy196. 6. James G, Boegli L, Hancock J et al. Bacterial Adhesion and Biofilm Formation on Textured Breast Implant Shell Materials. Aesth Plast Surg. 2019 Apr; 43:490-497. 7. Jones P, Mempin M, Hu H, et al. The functional influence of breast implant outer shell morphology on bacterial attachment and growth. Plast Reconstr Surg. 2018;142(4):837-849. 8. Doloff J. Overcoming host rejection response to improve breast implant biocompatibility. Oral presentation at: 3rd World Symposium on Ergonomic Implants; Sep 2017; Lago di Garda, Italy. 9. Sforza M, Zacccheddu R, Alleruzzo A et al. Preliminary 3-year evaluation of experience with SilkSurface and VelvetSurface Motiva silicone breast implants: a single-center experience with 5813 consecutive breast augmentation cases. Aesthet Surg J. 2018; 38(Suppl 2):S62-S73. 10. Huemer GM, Wenny R, Aitzetmüller MM, Duscher D. Motiva Ergonomix Round SilkSurface Silicone Breast Implants: Outcome Analysis of 100 Primary Breast Augmentations over 3 Years and Technical Considerations. Plast Reconstr Surg. 2018; 141(6):831e-842e. 11. Sim HB. Revisiting Prepectoral Breast Augmentation: Indications and Refinements, Aesthet Surg J. sjy294, https://doi.org/10.1093/asj/sjy294. 12. Nelson MT, Brattain KA, Williams JM. Does Electronic Identification Enablement for Silicone Gel Implants Impact Patient Safety? J Surg Open Access. 2018;4(1). doi: 10.16966/2470-0991.162.

Product availability may differ by country, please check regulations for locally approved products.

*LEED = Leadership in Energy and Environmental Design, MDSAP = Medical Device Single Audit Program

ACTA CHIRURGIAE PLASTICAE

INTERNATIONAL JOURNAL OF PLASTIC SURGERY, MAXILLOFACIAL
SURGERY, HAND SURGERY AND BURNS

Volume 63, No. 2, 2021

EDITORIAL BOARD

Chairman

Zdeněk Dvořák, MD, PhD,
Brno, Czech Republic

Vicechairman

Aleš Fibír, MD, PhD,
Hradec Králové, Czech Republic

MEMBERS

Assoc. Prof. Luboš Dražan, MD, PhD,
Brno, Czech Republic

Prof. René Foltán, MD et DMD, PhD,
Prague, Czech Republic

Assoc. Prof. Nguyen Hong Ha, MD,
Hanoi, Vietnam

Amin Kalaaji, MD, PhD,
Oslo, Norway

Assoc. Prof. Leo Klein, MD, CSc,
Hradec Králové, Czech Republic

Assoc. Prof. Břetislav Lipový, MD, PhD, MBA,
Brno, Czech Republic

Vladimír Mařík, MD,
České Budějovice, Czech Republic

Assoc. Prof. Ondřej Měšťák, MD, PhD,
Prague, Czech Republic

Martin Molitor, MD, PhD,
Prague, Czech Republic

Assoc. Prof. Aleš Nejedlý, MD,
Prague, Czech Republic

Martin Paciorek, MD, MBA,
Ostrava, Czech Republic

Drahomír Palenčár, MD, PhD,
Bratislava, Slovak Republic

Assoc. Prof. Richard Pink, MD, DMD, PhD,
Olomouc, Czech Republic

Alena Schmoranzová, MD,
Vysoké nad Jizerou, Czech Republic

Prof. Peter Stanko, MD, PhD,
Bratislava, Slovak Republic

Assoc. Prof. Libor Streit, MD, PhD,
Brno, Czech Republic

Prof. Andrej Sukop, MD, PhD,
Prague, Czech Republic

Jan Štebánek, MD, DMD, PhD,
Ostrava, Czech Republic

Inka Třešková, MD, PhD,
Plzeň, Czech Republic

Assoc. Prof. Peter Tvrdý, MD, DMD, PhD,
Olomouc, Czech Republic

Robert Zajíček, MD, PhD,
Prague, Czech Republic

Bohumil Zálešák, MD, PhD,
Olomouc, Czech Republic

Contens

| | |
|---|----|
| D. Palenčár Editorial | 45 |
| T. Kempný, O. Košková, K. Urbášek, M. Zvonař, K. Kolářová, B. Lipový, M. Knoz, J. Holoubek Long-term donor-site morbidity after thumb reconstruction with twisted-toe technique | 46 |
| B. Şahin, M. Ulasan, B. Başaran, S. Güneş, E. Oymak, S. Genç Supraclavicular artery island flap for head and neck reconstruction | 52 |
| R. Sathyamurthy, K. N. Manjunath, V. P. Waiker, S. Shanthakumar, M. Kumaraswamy Free tensor fascia lata flap – a reliable and easy to harvest flap for reconstruction | 57 |
| K. Kiss, I. Kiss, K. Kolostová, E. Pospíšilová, M. Šíroká, A. Fibír Presence of circulating tumor cells in a patient with multiple invasive basal cell carcinoma – a case report | 64 |
| M. Šíroká, K. Kiss, A. Fibír Pyoderma gangrenosum: a rare complication of reduction mammoplasty – a case report | 69 |
| J. Belobradová, O. Res, J. Stránský, Z. Čermáková, T. Blažek, P. Hurník, J. Štembírek Negative pressure therapy in the orofacial region in oncological patients – two case reports | 73 |
| L. Klein Thirty-five years of the Department of Plastic Surgery and Burns Treatment at the University Hospital in Hradec Králové | 78 |
| Czech summaries | 84 |

Editorial

Dear Colleagues,

You are receiving the second issue of *Acta Chirurgiae Plasticae* this year. I hope it caught you in a good mood. The last twelve months of our lives have been very atypical and turbulent. It must be said that the period we are currently living does not favor the development of science in our workplaces. Most of us have prosaic worries in our daily working lives. There is no time left to develop scientific activities alongside normal and covid work.

I don't know what the situation at your departments or clinics is like but at our Plastic Surgery Department in Bratislava, we have only been able to operate acute conditions, injuries and urgent oncological cases recently. This period did

not favor the introduction of the latest scientific trends into routine medical practice. Patients could not come for regular check-ups. The results of previous operations were difficult to trace retrospectively. Our young doctors had to work at covid wards, vaccination clinics or sampling points for testing covid patients. Therefore, it did not increase their time to expand their scientific skills.

Fortunately, we managed to compile the issue of *Acta Chirurgiae Plasticae*, which you are holding in your hands. In this issue, articles from reconstructive plastic surgery are presented to you. You will be able to read very interesting case reports or a paper about a retrospective study of microsurgical reconstructions of the thumb, and you may also



be inspired by new flaps suitable for the reconstruction of defects in the head and neck region or defects of various etiologies.

I hope that the content of this issue of *Acta Chirurgiae Plasticae* will motivate you for your further work in the field of reconstructive plastic surgery.

Drahomír Palenčár, MD, PhD
Head of Plastic Surgery Department
School of Medicine
Comenius University,
Bratislava, Slovakia

Long-term donor-site morbidity after thumb reconstruction with twisted-toe technique

T. Kempný¹, O. Košková^{2,3}, K. Urbášek^{2,3}, M. Zvonař⁴, K. Kolářová⁴, B. Lipový^{1,3}, M. Knoz^{1,3,5}, J. Holoubek^{1,3}

¹ Department of Burns and Plastic Surgery, University Hospital Brno, Czech Republic

² Department of Pediatric Plastic Surgery – Department of Pediatric Surgery, Orthopedics and Traumatology, University Hospital Brno, Czech Republic

³ Faculty of Medicine, Masaryk University, Brno, Czech Republic

⁴ Department of Kinesiology, Faculty of Sport Studies, Masaryk University, Brno, Czech Republic

⁵ Department of Plastic and Aesthetic Surgery, St. Anne's University Hospital, Brno, Czech Republic

Summary

Background: Traumatic thumb loss is a serious injury affecting patient's ability to work and participate in activities of daily life. The main goal for a plastic surgeon is to restore hand grip, often by microsurgical methods. However, patients should be informed of all effects associated with tissue harvesting. The aim of the study was to assess the impact on donor foot and gait cycle in patients who have undergone thumb reconstruction using twisted-toe technique modified by Kempný. **Material and methods:** Twelve patients participated in the study: all suffered a thumb loss between the years 2003 and 2011 and the twisted-toe technique for thumb reconstruction was utilized. The changes in foot pressure distribution and lower extremity joint loading were evaluated. **Results:** The differences in total maximal plantar pressure, pressure time integral, contact area, and maximum force between the affected and non-affected foot were statistically significant ($P \leq 0.1$). No significant differences of temporal gait parameters between the affected and non-affected extremity were observed; however, statistically significant differences in kinetics parameters, frontal ankle and knee moments were detected. **Conclusion:** Donor limb functionality and anatomical disability were assessed using pedobarography systems and 3D-gait analysis. The recorded differences in plantar pressure distribution (increased pressure in I., IV. and V. metatarsal areas) and overload of the medial compartment of the knee joint were the most significant findings. Therefore, wearing individually adapted shoe insoles as prevention of osteoarthritis might be beneficial for patients after thumb reconstruction by a twisted-toe technique.

Key words

thumb reconstruction – twisted-toe method – 3D-gait analysis – pedobarography – donor site morbidity

Kempný T, Košková O, Urbášek K et al. Long-term donor-site morbidity after thumb reconstruction with twisted-toe technique. *Acta Chir Plast.* 2021, 63(2): 46–51.

Introduction

Traumatic thumb loss is a serious injury with an enormous health impact and effect on patient's daily life. An effort to restore the handgrip is the goal during post-traumatic recovery, allowing the patient to return to a near normal hand functionality. There are many thumb reconstruction methods ranging from lengthening the first metacarpal or index finger pollicization to toe transplantation [1]. Plastic surgeons attempt to find the delicate balance between restoring handgrip while minimizing damage to donor areas. From many published studies, there are only a few that concern the inevitable health impact on the donor site after thumb recon-

struction. Patients should be informed about all benefits and limitations of this surgery.

The aim of the study was to determine the effects on patient's gait after thumb reconstruction by the twisted-toe technique modified by Kempný et al. [2]. According to this method, a neothumb is constructed with a partial onychocutaneous flap from the great toe and an osteotendinous flap from the second toe. Subsequently, a neo-great toe is created by combining the onychocutaneous part of the second toe and the remaining parts of the great toe (Fig. 1, 2). Foot pressure distribution in static and dynamic conditions during barefoot walking, walking with a standard type of shoes,

and 3D-gait analysis were evaluated in patients with thumb reconstruction by twisted-toe technique. Combining results of all pedobarography measurements and gait analysis enabled us to describe changes in plantar pressure and lower limb joint loading postoperatively.

Material and methods

Study design

This study was approved by the Ethics Committee of the University Hospital Brno. Patients who suffered a traumatic thumb loss and were treated by the same plastic surgeon (Kempný, MD) were included in the study. All patients underwent a thumb reconstruction using the twisted-toe technique mo-

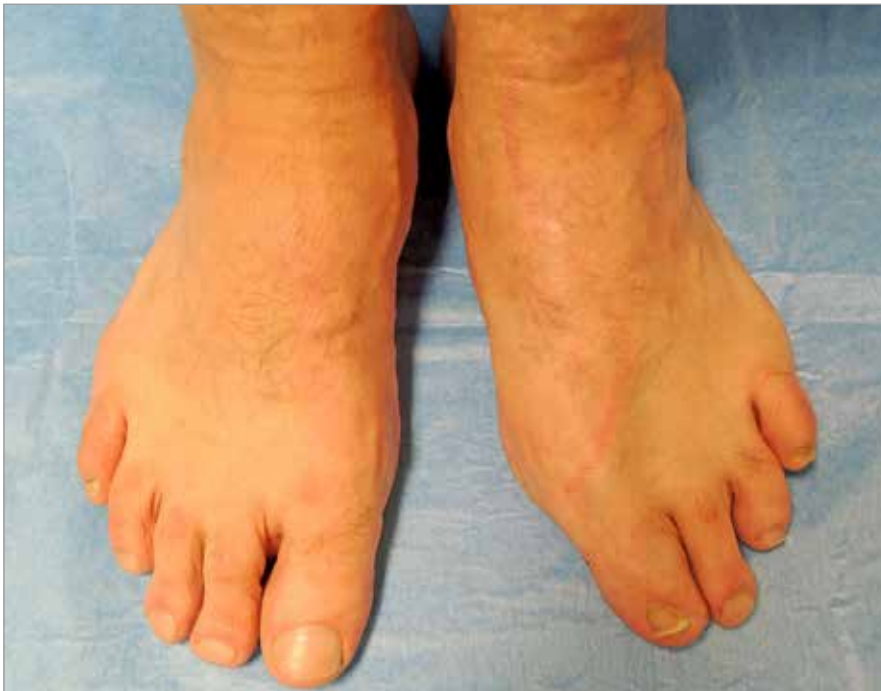

Fig. 1. Aesthetic result in one case, 11 years postoperatively.

dified by Kempný. The patients included in the study fulfilled the following criteria: age 15–65 years, no comorbidities (diabetes mellitus, rheumatoid arthritis, prior stroke, oncological diseases of musculoskeletal or nervous system), no trauma of lower limbs or spine in the

past, no congenital malformation or degenerative diseases of the musculoskeletal system, and BMI < 30. The study included only patients whose post-surgery period had exceeded two years.

All patients in the study underwent the following tests: the Emed® Novel

pedobarography system for evaluating foot pressure distribution in static and dynamic conditions, the Pedar® Novel system for step timing analysis during walking in shoes equipped with sensor insoles, and 3D-gait analysis for monitoring of lower extremity joints loading.

Principles of pedobarography tests and gait analysis

The Emed® Novel pedobarography system is one of the methods for measuring plantar pressure distribution in static and dynamic conditions. The limitation of this system is that the patient is required to walk barefoot maintaining natural gait and at the same time step in the center of the sensor platform in order to obtain accurate readings [3].

This system provides data about the foot contact area on the pressure sensor pad, maximum force, peak pressure (the highest value in each region) and pressure time integral (including both the pressure affecting the pad during the whole gait phase contact and its time). A customized mask comprised of 10 foot regions (M1–M10) was fitted to each pedobarographic image (Fig. 3). The re-

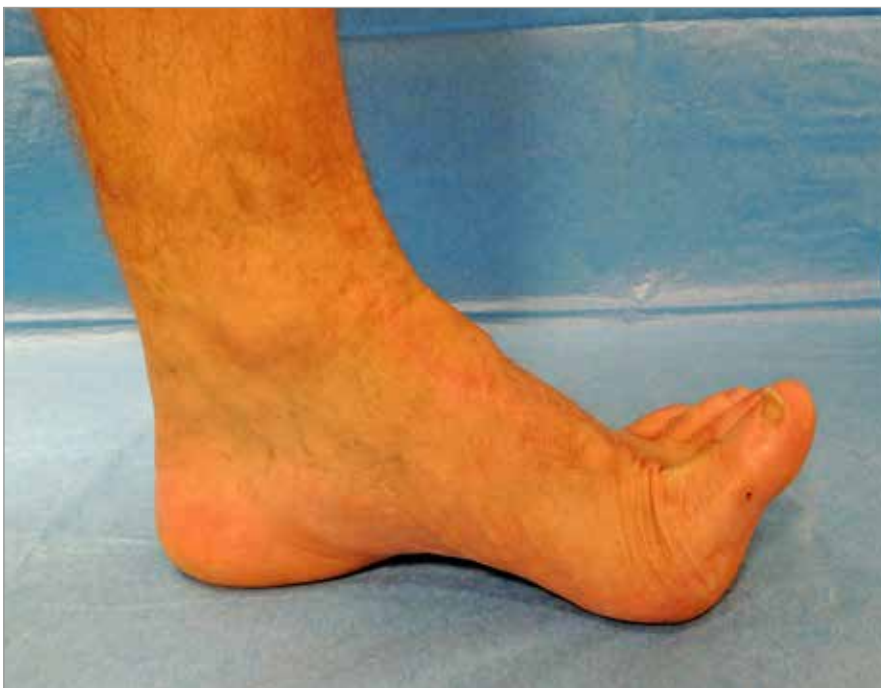

Fig. 2. Functional result in one case, 11 years postoperatively.

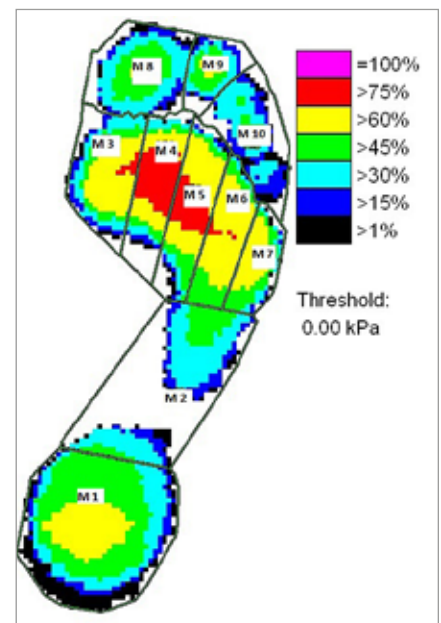


Fig. 3. Ten regions of foot made by automask program Emed® Novel pedobarography systems.

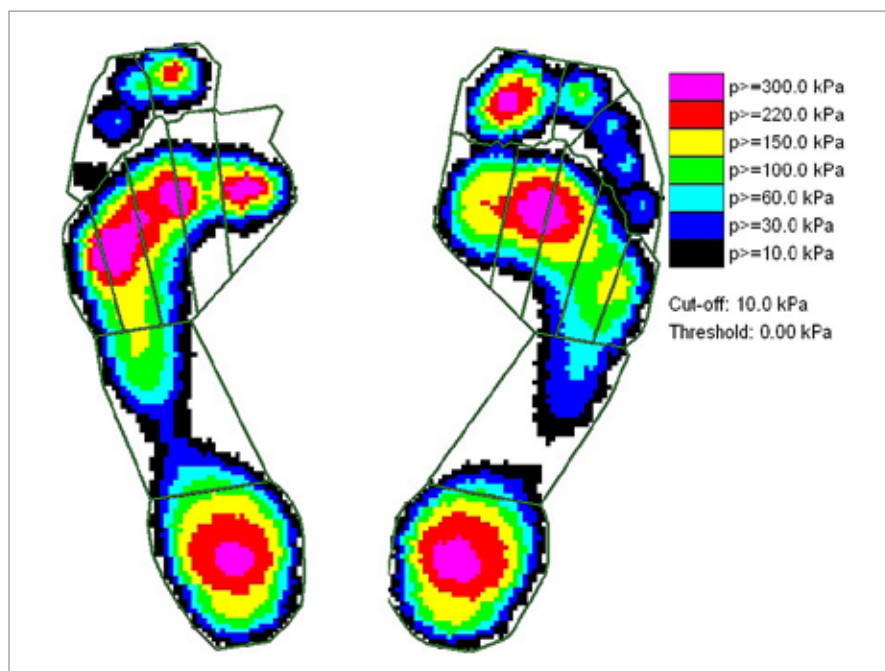


Fig. 4. Distribution of plantar pressure on the left foot (affected limb with a neo-toe) and on the right foot (non-affected foot).

sults for the entire foot surface and each region are available separately. Standardized partitioning of each foot image allowed for a comparison of the left and the right foot for all patients (Fig. 4).

The Pedar® Novel system is an in-shoe dynamic pressure measuring system. Its advantages include better monitoring of natural gait, making it ideal for standardized step timing analysis. The time value of stride (from right-heel contact to the subsequent right-heel contact), step (from right-heel contact to left-heel contact), stance (one foot contact time with pad), swing (time when the foot is not in contact with pad), and others were assessed.

The 3D-gait analysis was performed by the Vicon motion capture system (8 infrared cameras T020) and 2 force plates (AMTI OR6-7-2000). Six parameters were chosen to describe gait changes: sagittal ankle kinematics and 5 kinetic parameters (ankle sagittal and frontal moment, ankle sagittal power, knee frontal moment in the first and second part of stance phase). These parameters were selected mainly because they are ideal for reflecting gait cycle

alternations for this specific pathological condition. The first ray (hallux) is loaded particularly in the second half of the stance phase, the reason being is to divide frontal knee kinetics into the 1st and 2nd half of stance phase. The hallux is important for transmitting muscle propulsion power generated by the triceps surae muscle and other plantar flexors in the pre-swing phase. Sagittal ankle joint loading and propulsion energy are predominantly represented by ankle sagittal moment and ankle sagittal power. Another presumption was there would be obvious gait changes of ankle and knee frontal balance parameters represented by frontal knee moments in patients undergoing twisted-toe thumb reconstruction.

Statistical analysis

The gait characteristics obtained by all three methods were compared between the affected and non-affected extremity in all patients. The third step method was applied in Emed® Novel pedobarography system: the first two steps represent acceleration gait phase and then the actual monitoring is per-

formed starting with the third step, as the gait is stabilized. To avoid variations in the gait cycle, the patient continued to walk even after the foot made contact with the sensor platform [4]. The resulting values of maximum force, peak pressure, pressure time integral, and contact area were determined as an average value of five measurements. Step timing analysis by the Pedar® Novel system and gait characteristics by 3D-gait analysis were also established as a mean value of at least three measured trials of each patient. The analysis was carried out using the statistical package STATISTICA Ver. 12, and the Wilcoxon matched pairs test was used while assessing statistically a significant level at $P \leq 0.1$.

Results

Twelve patients were included in the study: 11 males and 1 female (Tab. 1). The mean age of the patients during this study was 41.8 years (22–65 years). The mean age of the patients at the time of thumb reconstruction was 34.5 years (16–59 years). The left foot was used as a donor site in 8 cases (66.7%). The mean interval between pedobarography measurement and surgery was 7.2 years (2–11 years).

The differences of maximal plantar pressure between the affected and non-affected extremity were statistically significant in the following areas: I, IV, and V. metatarsal region, neo-great toe and total peak pressure of the whole foot (Tab. 2). Pressure time integral, which indicates the time of maximal pressure action in a defined area, was significantly higher by 27% in I. metatarsal region. The mean peak pressure of the affected foot was significantly higher by 39%; conversely, the maximal force was lower by 1% in total, and up to 28% in the area of II. metatarsal region. In comparison to the non-affected limb, the contact area of the affected foot was statistically significantly reduced by 7%, with the difference averaging 13 cm². The significant part of the reduction was registered at

Tab. 1. Characteristics of all patients treated with the twisted-toe technique.

| Patient | Sex | Age at thumb reconstruction (years) | Age at gait tests (years) | Period from surgery to gait evaluating (years) | BMI | Donor site foot |
|---------|-----|-------------------------------------|---------------------------|--|------|-----------------|
| 1 | M | 49 | 58 | 9 | 25.6 | left |
| 2 | M | 26 | 34 | 8 | 25.3 | right |
| 3 | M | 24 | 33 | 7 | 27.3 | right |
| 4 | M | 16 | 22 | 6 | 28.8 | left |
| 5 | F | 59 | 61 | 2 | 25.0 | left |
| 6 | M | 17 | 23 | 6 | 18.2 | left |
| 7 | M | 36 | 39 | 3 | 24.2 | left |
| 8 | M | 27 | 38 | 11 | 30.4 | left |
| 9 | M | 36 | 44 | 8 | 23.5 | right |
| 10 | M | 17 | 27 | 10 | 20.6 | left |
| 11 | M | 49 | 58 | 9 | 17.7 | left |
| 12 | M | 58 | 65 | 7 | 28.7 | right |

BMI – body mass index, F – female, M – male

The 3D-gait analysis was only completed by 11 patients. One patient was excluded from the study due to non-compliance during examination resulting in invalid test values. The difference between the affected and non-affected limb was statistically significant in parameters representing ankle loading in the sagittal plane (maximal sagittal ankle moment and maximal ankle sagittal power) and knee loading (maximal frontal knee moment in the first and second half of the stance phase). There were no statistically significant differences in maximal frontal ankle moment and sagittal ankle kinematics (representing ankle loading in frontal plane and ankle range of movement (Tab. 3).

Discussion

Traumatic thumb loss is a serious injury affecting patient’s ability to work and function in daily life activities. Microsurgical or non-microsurgical methods of thumb reconstruction are available and they are based on the post-traumatic condition of the affected hand, sufficient blood supply of the affected hand

the neo-toe as well as at the heel and the I. metatarsal region.

Median values of temporal gait characteristics were equal for both affected

and non-affected extremities. The stride was measured at 1.12 sec, the step at 0.56 sec, the stance at 0.69 sec, and the swing at 0.44 sec.

Tab. 2. The differences of maximal plantar pressure, pressure time integral, contact area and maximum force between the affected and non-affected feet. The minus sign and the decrease under 100% mean reduction of the parameter in the affected limb. The significance levels were set at P ≤ 0.1 (in bold).

| | Peak pressure (kPa) | | | Contact area (cm ²) | | | Maximum force (N) | | | PTI (kPa*s) | | |
|-----------------|-----------------------|------------|-------------|------------------------------------|-----------|------------------|---------------------|-----------|-------------|-------------------------|------------|------------------|
| | mean difference (kPa) | % | P-value | mean difference (cm ²) | % | P-value | mean difference (N) | % | P-value | mean difference (kPa)*s | % | P-value |
| Total | 140 | 139 | 0.01 | -13 | 93 | < 0.01 | -12 | 99 | 0.01 | 57 | 127 | < 0.01 |
| heel | 15 | 104 | 0.26 | -2 | 96 | 0.04 | -42 | 92 | 0.31 | -1 | 99 | 0.48 |
| middle part | 8 | 108 | 0.13 | -2 | 96 | 0.58 | 8 | 104 | 0.21 | 4 | 111 | 0.06 |
| metatarsal I | 125 | 155 | 0.02 | -1 | 96 | 0.04 | 45 | 130 | 0.24 | 33 | 150 | 0.03 |
| metatarsal II | -15 | 95 | 0.88 | -1 | 95 | 0.07 | -68 | 72 | 0.01 | -8 | 94 | 0.94 |
| metatarsal III | 28 | 106 | 0.53 | 0 | 99 | 0.39 | -37 | 83 | 0.02 | 1 | 103 | 0.64 |
| metatarsal IV | 65 | 122 | 0.05 | 0 | 101 | 0.39 | 19 | 111 | 0.16 | 37 | 129 | 0.06 |
| metatarsal V | 48 | 132 | 0.04 | 0 | 104 | 0.27 | 0 | 101 | 0.75 | 21 | 137 | 0.06 |
| big toe/neo-toe | 118 | 138 | 0.01 | -4 | 70 | < 0.01 | -14 | 93 | 0.58 | 30 | 159 | 0.07 |
| other fingers | 10 | 125 | 0.53 | -1 | 64 | 0.21 | -3 | 70 | 0.43 | 1 | 117 | 0.88 |

Tab. 3. Parameters of 3D-gait analysis. The minus sign means reduction of the parameter in the affected limb. The significance levels were set at $P \leq 0.1$ (in bold).

| | No. of patients | Difference | | P-value |
|---|-----------------|-------------|----------------------|------------------|
| | | median | (0.1 to 0.9) | |
| maximum ankle sagittal power (W/kg) | 11 | -0.4 | (-1 to 0.1) | 0.09 |
| maximum ankle dorsiflexion sagittal moment (Nmm/kg) | 11 | -141 | (-290 to -5) | < 0.01 |
| maximum ankle dorsiflexion in mid stance (°) | 11 | -0.5 | (-3.1 to 2.3) | 0.66 |
| maximum ankle valgus frontal moment (Nmm/kg) | 11 | -29 | (-230 to 47) | 0.18 |
| maximum frontal knee moment first part (Nmm/kg) | 11 | 108 | (-20 to 242) | 0.03 |
| Max frontal knee moment second part (Nmm/kg) | 11 | 162 | (-78 to 254) | 0.09 |

and donor site, patient's comorbidities, and reasonable goals for post-operative hand functioning.

The twisted-toe technique was first described by Foucher in 1980 and subsequently developed and modified by Tsai, Aziz and Iglesias [5–7]. The twisted-toe technique allows a reconstructive surgeon to create a very natural-appearing neothumb with good stability and grip force [2]. Many published studies focus on the long-term results of hand functioning [8,9], but fewer on the impact at the donor site. Studies analyzing foot conditions – specifically after toe-to-hand transfer [10] or thumb reconstruction by modified wraparound flap [11] – are based more on subjective observations of patients [12] than on objective assessment. Pedobarography and the 3D-gait analysis are used for objective evaluation of gait, pressure distribution, and joint loading [12]. Currently these two methods are commonly used in studies of gait in obese [13,14] and diabetic [15–17] patients, or in studies evaluating post-traumatic conditions [18,19]. In patients with less common diagnoses, such as Down syndrome [20], Ehlers-Danlos syndrome [21] or ankylosing spondylitis [22], these two methods

might be utilized as well. Pan et al. [23] published outcomes of 20 patients who underwent thumb reconstruction applying the modified wraparound flap method. No significant differences in 5 biomechanical parameters (timing, trajectory, symmetry, average peak force, and peak pressure between donor foot and contralateral foot) were found in gait analysis or in dynamic pedodographic measurements.

This study reveals that patients who underwent the thumb reconstruction by twisted-toe technique do not bear any visible signs of lower extremity disability during gait. Patients do not limp, and there were no significant differences in temporal gait parameters between the affected and non-affected extremity. However, the thumb reconstruction had some effects: plantar pressure distribution is changed in terms of higher plantar pressure of neo-toe and the I. metatarsal area, reduction of total contact area (not only of the neo-toe, but also of the heel region) and lower maximal force of the affected foot. The result is forefoot overloading.

The donor foot condition is comparable with a more common foot deformity, hallux valgus (HV). There are

a few studies discussing gait parameters associated with HV [24]. Many describe greater hallux peak pressure, peak pressure under the first metatarsal head [25], and greater mean pressure [26] in HV subjects compared to controls. HV has been linked to foot pain, poor balance and increased falls in older adults [27,28]. Similar changes in foot pressure distribution in patients with hallux valgus are seen in patients from this study, suggesting the development of a foot disability after thumb reconstruction.

According to the 3D-gait analysis, tissue harvesting at the donor site leads to uneven loading of the ipsilateral knee joint, especially increased loading of its medial compartment – the area of the knee most commonly affected by osteoarthritis (OA) [29,30]. In their MOST study, Sharma et al. [31] found that varus alignment is a risk factor for incident cartilage damage which leads to OA of the knee. A similar pathology is presented in this study, wherein patients undergoing thumb reconstruction by twisted-toe technique are at risk of knee joint OA. Insoles, especially lateral wedge insoles, are commonly recommended for patients with medial knee OA [32].

Based on these findings, and considering other foot pathologies, individually adapted shoe insoles might be appropriate for the prevention of medial compartment cartilage damage and foot pain.

Conclusion

The twisted-toe technique is a thumb reconstruction method associated with a very natural-appearing neo-thumb with good stability and grip force [2]. The degree of functional disability of the donor limb was observed using pedobarography systems and 3D-gait analysis. There were no changes in temporal gait parameters recorded. The plantar pressure distribution differed in the donor: increased plantar pressure in neo-toe and I. metatarsal areas were measured. The forefoot overloading

and overloading of medial knee joint compartment were also observed. Post-operative anatomic and functional changes of the affected limb might cause earlier development of knee joint osteoarthritis.

Roles of authors: All authors contributed equally to this work.

Financial disclosures: None of the authors has a financial interest in any of the products, devices, or drugs mentioned in this manuscript.

Disclosure: Authors have no conflicts of interest to disclose. The project was approved by the Ethics Committee of University Hospital Brno and proceeded according to the general principles of good clinical practice. All procedures performed in this study involving human participants were in accordance with the Helsinki declaration and its later amendments or comparable ethical standards.

References

- Kempný T., Lipový B., Brychta P. Historie a současnost rekonstrukce palce ruky. *Rozhl v Chir.* 2015, 94: 145–152.
- Kempný T., Paroulek J., Marik V., et al. Further developments in the twisted-toe technique for isolated thumb reconstruction: our method of choice. *Plast Reconstr Surg.* 2013, 131: 871–879.
- Abdul Razak AH., Zayegh A., Begg RK., et al. Foot plantar pressure measurement system: a review. *Sensors.* 2012, 12: 9884–9912.
- Bus SA., Lange AD. A comparison of the 1-step, 2-step, and 3-step protocols for obtaining barefoot plantar pressure data in the diabetic neuropathic foot. *Clin Biomech.* 2005, 20: 892–899.
- Foucher G., Chabaud M. The bipolar lengthening technique: a modified partial toe transfer for thumb reconstruction. *Plast Reconstr Surg.* 1998, 102: 1981–1987.
- Tsai T-M., Aziz W. Toe-to-thumb transfer: a new technique. *Plast Reconstr Surg.* 1991, 88: 149–153.
- Iglesias M., Butron P., Serrano A. Thumb reconstruction with extended twisted toe flap. *J Hand Surg Am.* 1995, 20: 731–736.
- Kotkansalo T., Vilkki S., Elo P. Long-term results of finger reconstruction with microvascular toe transfers after trauma. *J Plast Reconstr Aesthetic Surg.* 2011, 64: 1291–1299.
- Lin PY., Sebastin SJ., Ono S., et al. A systematic review of outcomes of toe-to-thumb transfers for isolated traumatic thumb amputation. *Hand.* 2011, 6: 235–243.
- Stupka I., Veselý J., Dražan L., et al. Foot morbidity following toe to hand transfers. *Eur J Plast Surg.* 2004, 27: 283–287.
- Kotkansalo T., Elo P., Luukkaala T., et al. Long-term effects of toe transfers on the donor feet. *J Hand Surg Eur.* 2014, 39: 966–976.
- Wafai L., Zayegh A., Woulfe J., et al. Identification of foot pathologies based on plantar pressure asymmetry. *Sensors (Basel).* 2015, 15: 20392–20408.
- Periyasamy R., Mishra A., Anand S., et al. Foot pressure distribution variation in pre-obese and non-obese adult subject while standing. *Foot.* 2012, 22: 276–282.
- Butterworth PA., Urquhart DM., Landorf KB., et al. Foot posture, range of motion and plantar pressure characteristics in obese and non-obese individuals. *Gait Posture.* 2015, 41: 465–469.
- Bennetts CJ., Owings TM., Erdemir A., et al. Clustering and classification of regional peak plantar pressures of diabetic feet. *J Biomech.* 2013, 46: 19–25.
- Lobmann R., Kayser R., Kasten G., et al. Effects of preventive footwear on foot pressure as determined by pedobarography in diabetic patients: a prospective study. *Diabet Med.* 2001, 18: 314–319.
- Fernando M., Crowther RG., Cunningham M., et al. The reproducibility of acquiring three dimensional gait and plantar pressure data using established protocols in participants with and without type 2 diabetes and foot ulcers. *J Foot Ankle Res.* 2016, 9: 4.
- Jansen H., Frey SP., Ziegler C., et al. Results of dynamic pedobarography following surgically treated intra-articular calcaneal fractures. *Arch Orthop Trauma Surg.* 2013, 133: 259–265.
- Schepers T., Kieboom BC., Kieboom B., et al. Pedobarographic analysis and quality of life after Lisfranc fracture dislocation. *Foot ankle Int.* 2010, 31: 857–864.
- Pau M., Galli M., Crivellini M., et al. Relationship between obesity and plantar pressure distribution in youths with Down syndrome. *Am J Phys Med Rehabil.* 2013, 92: 889–897.
- Pau M., Galli M., Celletti C., et al. Plantar pressure patterns in women affected by Ehlers-Danlos syndrome while standing and walking. *Res Dev Disabil.* 2013, 34: 3720–3726.
- Aydin E., Turan Y., Tastaban E., et al. Plantar pressure distribution in patients with ankylosing spondylitis. *Clin Biomech.* 2015, 30: 238–242.
- Pan Y., Zhang L., Tian W., et al. Donor foot morbidity following modified wraparound flap for thumb reconstruction: a follow-up of 69 cases. *J Hand Surg Am.* 2011, 36: 493–501.
- Nix SE., Vicenzino BT., Collins NJ., et al. Gait parameters associated with hallux valgus: a systematic review. *J Foot Ankle Res.* 2013, 6: 1–12.
- Bryant A., Tinley P., Singer K. Radiographic measurements and plantar pressure distribution in normal, hallux valgus and hallux limitus feet. *Foot.* 2000, 10: 18–22.
- Martínez-Nova A., Sánchez-Rodríguez R., Pedrera-Zamorano JD., et al. Plantar pressures determinants in mild hallux valgus. *Gait Posture.* 2010, 32: 425–427.
- Chaiwanichsiri D., Janchai S., Tantisiriwat N. Foot disorders and falls in older persons. *Gerontology.* 2009, 55: 296–302.
- Nix S., Smith M., Vicenzino B. Prevalence of hallux valgus in the general population: a systematic review and meta-analysis. *J Foot Ankle Res.* 2010, 3: 21.
- Massardo L., Watt I., Cushnaghan J., et al. Osteoarthritis of the knee joint: an eight year prospective study. *Ann Rheum Dis.* 1989, 48: 893–897.
- Johnson F., Leitzl S., Waugh W. The distribution of load across the knee. A comparison of static and dynamic measurements. *J Bone Jt Surg Br.* 1980, 62: 346–349.
- Sharma L., Chmiel JS., Almagor O., et al. The role of varus and valgus alignment in the initial development of knee cartilage damage by MRI: the MOST study. *Ann Rheum Dis.* 2013, 72: 235–240.
- Jordan KM., Arden NK., Doherty M., et al. EULAR Recommendations 2003: an evidence based approach to the management of knee osteoarthritis: Report of a Task Force of the Standing Committee for International Clinical Studies Including Therapeutic Trials (ESCISIT). *Ann Rheum Dis.* 2003, 62: 1145–1155.

Olga Košková MD, PhD

Department of Pediatric Plastic Surgery –
Department of Pediatric Surgery,
Orthopedics and Traumatology
University Hospital Brno
Černopolská 9
613 00 Brno
Czech Republic
e-mail: koskova.olga@fnbrno.cz

Submitted: 28. 02. 2021

Accepted: 02. 05. 2021

Supraclavicular artery island flap for head and neck reconstruction

B. Şahin¹, M. Ulusan², B. Başaran², S. Güneş³, E. Oymak¹, S. Genç¹

¹ Department of Otorhinolaryngology & Head and Neck Surgery, Kocaeli Health Sciences University Derince Training and Research Hospital, Kocaeli, Turkey

² Department of Otorhinolaryngology & Head and Neck Surgery, Istanbul Medical Faculty, University of Istanbul, Istanbul, Turkey

³ Department of Otorhinolaryngology & Head and Neck Surgery, Memorial Hizmet Hospital, Istanbul, Turkey

Summary

Background: The ablative surgical resection has a critical importance for achieving better oncological outcomes for patients with head and neck cancer. However, radical surgical resections reveal the reconstruction requirement of complex anatomical structures. Microvascular free flaps have been recommended as a gold standard treatment choice for head and neck reconstruction following definitive oncological surgery. The supraclavicular artery island flap (SCAIF) is a thin and reliable fasciocutaneous pedicled flap that is simple and quick to harvest. **Material and methods:** A total of 19 patients who underwent head and neck reconstruction with SCAIF were included in this study. The SCAIF was used for the reconstruction of oncological defects in 17 patients while it was used for the reconstruction of a skin defect on the lower face following radiotherapy in 1 patient and for cervical open wound (blast injury) closure in 1 patient. **Results:** There were neither intraoperative nor postoperative major complications in any patient. The SCAIF has been used successfully in 18 of 19 patients for head and neck reconstructive surgery. Partial necrosis of the skin was detected in 1 patient (5.3%) only, while a total flap failure has not occurred in any patient. The partial skin necrosis was seen in an area of 1.5 cm of the distal end of the flap and was managed conservatively with local wound care. Wound dehiscence has not appeared in the flap donor area in any patient. **Conclusion:** The SCAIF constitutes a good alternative to free flaps, providing almost equivalent functional results and requiring less operative time and surgical effort.

Key words

head and neck cancer – supraclavicular artery island flap – pedicled flap – fasciocutaneous flap – head and neck reconstruction

Şahin B., Ulusan M., Başaran B., et al. Supraclavicular artery island flap for head and neck reconstruction. *Acta Chir Plast.* 2021, 63(2): 52–56.

Introduction

The objectives of the reconstruction of head and neck defects should include provision of vascularized tissue support for complex defects, and functional and cosmetic restoration of three-dimensional anatomical structures. Microvascular free flaps are the first treatment option to achieve these goals according to current medical guidelines [1,2]. However, free tissue transfers require proper vascular structure and neck anatomy, microvascular anastomosis expertise, prolonged surgery times and intensive care unit monitoring following surgery. For these reasons, the usage of free tissue flaps may not be possible in every patient. Local flaps are usually not suitable for the repair of large surgical defects while pedicled regional flaps are bulky and have

some disadvantages, such as significant donor-site morbidity, functional problems and aesthetic incompatibility.

The supraclavicular artery island flap (SCAIF) is a fasciocutaneous pedicled flap based on the supraclavicular artery, a branch of the transverse cervical artery, first described by Lamberty and Cormack [3] in 1983. In the 1990s, Pallua et al. [4] popularized this flap for the reconstruction of postburn mentosternal contractures. Subsequently, Chiu et al. [5] reported for the first time that the supraclavicular flap can be used for head and neck reconstruction following an oncologic surgery. The use of SCAIF in the reconstruction of head and neck defects has become popular in recent years, especially being utilized in defects of the lower third of the face and neck [6].

The aim of this study was to investigate the indications, both functional and cosmetic outcomes and complications of the SCAIF as well as its reliability as an alternative to free tissue transfer for moderate to large defects of the head and neck area.

Material and methods

Patients selection

This retrospective clinical study was carried out at two different tertiary referral hospitals (Department of Otorhinolaryngology – Head and Neck Surgery) through the utilization of patient records taken between January 2017 and December 2020. The study protocol was approved by the local ethics committee. All phases of the study were conducted in line with the principles of the Helsinki Declaration.

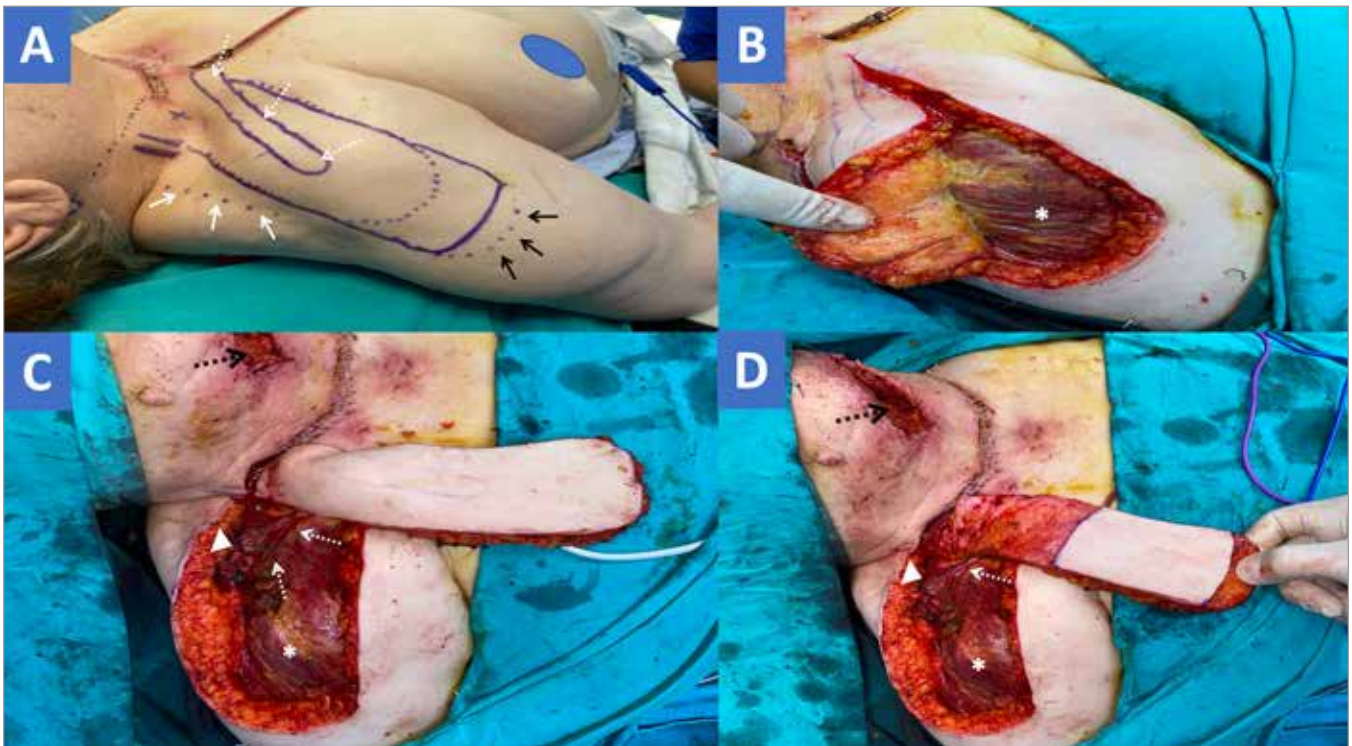


Fig. 1. (A) Determination of the possible origin of the supraclavicular artery via anatomical landmarks. (B) Elevation of the flap from the distal to the proximal over the deltoid muscle. (C) Completion of the flap elevation up to its most proximal portion, where the supraclavicular artery originates from the transverse cervical artery. (D) Performance of skin de-epithelization of the flap after completion of flap harvesting (*straight white arrows* – anterior border of the trapezius muscle; *dashed white arrows* – clavicle; *straight black arrows* – inferior border of the deltoid muscle; *dashed black arrow* – surgical defect area; *asterisk* – deltoid muscle; *arrow heads* – trapezius muscle).

A total of 19 patients who underwent head and neck reconstruction with SCAIF were included in this study. All surgical procedures were performed by head and neck surgeons. The demographic features of the patients, regions of the surgical defects, flap harvesting times, histopathological subtypes and localization of the cancer, postoperative complications and wound problems of all patients were obtained from the patients' medical records. The SCAIF was used for the reconstruction of oncological defects in 17 patients, for the reconstruction of a skin defect on the lower face following radiotherapy in 1 patient and for cervical open wound (blast injury) closure in 1 patient.

Surgical technique

The patient was placed in a supine position and a pillow was put under the patient's shoulder. The patient's neck was

brought into an extension position and the head was rotated to the opposite side of the flap donor site. The possible origin point of the supraclavicular artery was marked in a triangular region, which was delimited by sternocleidomastoid muscle anteriorly, by clavicle inferiorly and by the external jugular vein posteriorly (Fig. 1A). The flap was designed according to the size, shape and localization of the surgical defect in an area defined by the anterior border of the trapezius muscle posteriorly and by the line parallel to the deltoid muscle fibers anteriorly (Fig. 1A).

After the completion of the skin, subcutaneous tissue and fascial incisions, the fascia was sutured to the skin by a 4-0 polyglactin suture (Vicryl®, Ethicon© Inc, Johnson & Johnson, Somerville, NJ). The flap was raised from the distal to the proximal (Fig. 1B). The flap elevation was performed in a subfascial

plane just superficial to the deltoid muscle up to the clavicle and subperiosteal dissection was carried out on the clavicle. The flap was raised to its most proximal portion, where the supraclavicular artery originated from the transverse cervical artery (Fig. 1C). During these surgical maneuvers, the supraclavicular artery and vein were kept in mind but they were not dissected in the supraclavicular fossa. After completion of the flap harvesting, skin de-epithelization was performed on the proximal part of the flap in most patients and the flap was tunneled under the skin of the neck (Fig. 1D). Then, the flap was simply rotated or transposed to the surgical defect area for cervical and facial skin or pharyngeal reconstruction (Fig. 2A). The flap donor sites were closed primarily (Fig. 2B) following undermining of the skin edges and drainage tube placement in all patients.

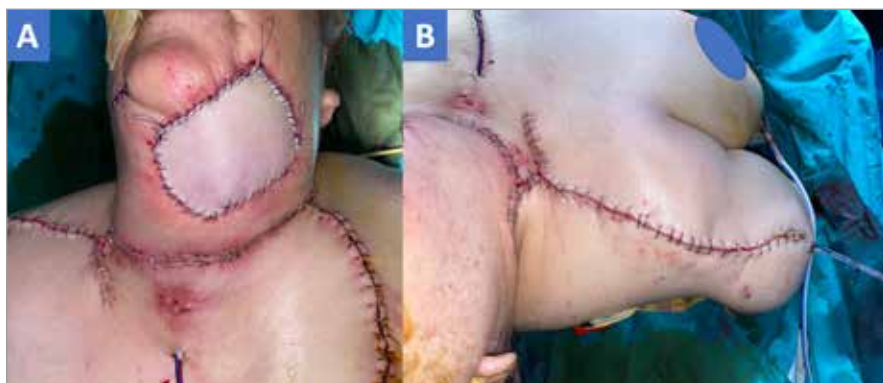

Fig. 2. (A) Intraoperative view of the reconstructed surgical defect area, which includes skin and soft tissue defects of the anterior neck. (B) Postoperative view of the flap donor area, which was successfully closed primarily without any tension.

Results

There were 15 male (79%) and 4 female (21%) patients of the average age 58.94 ± 12.89 (median: 63; range: 24–72) years. The mean follow-up time was 22.68 ± 6.18 (median: 23; range: 12–36) months. Patients' characteristics such as demographics, comorbid diseases, smoking status, alcohol consumption, surgical indication and defect area as well as other details were summarized in Tab. 1.

The SCAIF has been utilized successfully in 18 of 19 patients for head and neck reconstructive surgery. There were neither intraoperative nor postoperative major complications in any patient. Partial necrosis of the skin was detected in 1 patient (5.3%) only, while a total flap failure has not occurred in any patient. In this patient, the flap has been used for the reconstruction of the auricle and skin of the temporal region. The partial skin necrosis was seen in an area of 1.5 cm of the distal end of the flap and was managed conservatively with local wound care.

Wound dehiscence has not appeared in the flap donor area in any patient. However, partial dehiscence has occurred between the flap recipient area and flap skin in 1 patient (5.3%) with oral cavity reconstruction. Wound edges were sutured by horizontal mattress sutures under local anesthesia. However, neck exploration and re-suturing was

performed in 1 patient (5.3%) due to pharyngocutaneous fistula recurrence.

The mean flap harvesting time was 42.8 ± 6.5 minutes and the intraoperative blood loss was less than 50 mL. A closed suction drain was placed in the flap donor area and it was removed when drainage dropped to 30 mL or less. In 3 patients who underwent tongue and mouth floor reconstruction, the tracheostomy tube was placed for airway safety. The tracheostomy tube was removed 72 hours after the surgery in these patients.

Discussion

We have successfully applied the SCAIF to different surgical defects and found that this flap is reliable and easy to harvest, and is associated with low morbidity. It has also appropriate color and texture distribution with head and neck skin. This study supports a suggestion that the SCAIF may provide similar functional and cosmetic outcomes compared to free tissue transfers but requires less operative time, surgical effort and perioperative care.

The SCAIF has numerous favorable characteristics for the head and neck reconstructive surgeons. First, the SCAIF is a thin and hairless flap and has optimal aesthetic concordance with the skin of the head and neck region. Second, it is close to the head and neck region compared to pedicled flaps, such as pectora-

lis major and latissimus dorsi flaps, providing a better rotation arc. Third, being a flap of axial pattern, its blood supply is sufficient and reliable. Additionally, the flap can be used for oral cavity, oropharynx, hypopharynx, larynx, and cervical and facial skin reconstruction with good functional and cosmetic outcomes due to its high versatility [5,7–15]. These features make the SCAIF one of the optimal treatment choices of reconstructive surgery of the head and neck.

The main disadvantage of the SCAIF is partial skin necrosis, which may develop on the most distal portion of the flap. Kokot et al. [11] reported that a flap length longer than 22 cm is significantly associated with distal tip necrosis. However, in this study, the relationship between the flap length and flap necrosis was not significant. For neopharyngeal or pharyngoesophageal reconstruction, the most distal part of the flap has a critical importance and is responsible for repairing the surgical defect. During flap harvesting, the elevation of the flap until a point 5 cm away from the last place where doppler flow was detected, which is usually located over the inferior border of the deltoid muscle, may prevent distal flap necrosis [6]. Nthumba [16] declared the rate of partial and total flap necrosis to be 6.9% and 1.4%, respectively, in his series of 349 patients. The partial flap necrosis ratio has been found to be 14.9% in another study, which includes 47 patients with advanced head and neck cancer [9]. Wang et al. [15] used the SCAIF and sternohyoid muscle combination for the reconstruction of laryngeal or hypopharyngeal defects. They did not observe partial or total flap necrosis in any patient. Teixeira et al. [6] reported a 100% rate of flap survival in 6 patients undergoing pharyngocutaneous or tracheoesophageal fistula closure. Pabiszczak et al. [17] and Li et al. [18] notified this ratio for pharyngocutaneous fistula repair as 84% and 100%, respectively. In our series, partial flap necrosis was detected in 1 patient

Tab. 1. Patients' characteristics

| Variable | Value |
|--------------------------------------|----------------------------------|
| Age ± SD (median and range) | |
| male | 58.1 ± 12.6 (61 and 24–70 years) |
| female | 61.2 ± 14.9 (71 and 38–72 years) |
| Gender | |
| male | 15 (79%) |
| female | 4 (21%) |
| Comorbid Disease | |
| hypertension | 10 (52.6%) |
| diabetes mellitus | 8 (42.1%) |
| coronary artery disease | 3 (15.8%) |
| hyperlipidemia | 2 (10.5%) |
| atrial fibrillation | 1 (5.3%) |
| Smoking | |
| yes | 14 (73.7%) |
| no | 5 (26.3%) |
| Alcohol Consumption | |
| yes | 3 (15.8%) |
| no | 16 (84.2%) |
| History of Prior Radiation | |
| yes | 6 (31.6%) |
| no | 13 (68.4%) |
| Concomitant Neck Dissection | |
| Present | 17 |
| ipsilateral | 6 |
| contralateral | 11 |
| Absent | 2 |
| Surgical Defect Area | |
| skin defect | 9 (47.3%) |
| – neck | 5 (26.3%) |
| – lower face | 2 (10.5%) |
| – retroauricular region | 2 (10.5%) |
| pharyngeal wall | 4 (21%) |
| pharyngocutaneous fistula | 2 (10.5%) |
| tongue | 2 (10.5%) |
| tracheoesophageal fistula | 1 (5.3%) |
| floor of the mouth | 1 (5.3%) |
| Head and Neck Malignancy | |
| Present | 17 (89.5%) |
| larynx | 4 (21%) |
| hypopharynx | 4 (21%) |
| skin | 3 (15.8%) |
| tongue | 2 (10.5%) |
| unknown primary with neck metastasis | 2 (10.5%) |
| auricle | 1 (5.3%) |
| floor of the mouth | 1 (5.3%) |
| Absent | 2 (10.5%) |
| skin defect following radiotherapy | 1 (5.3%) |
| blast injury in the neck | 1 (5.3%) |

SD – standard deviation

(1/19, 5.3%) only, while total flap necrosis was not seen in any patient.

Donor site complications of the SCAIF are minimal and most of them tolerable for many patients. Seroma formation or wound dehiscence frequency has been described as 0–15% during the perioperative period [5,19]. Pallua and Magnus Noah [20] reported that the primary closure of the donor site can be performed for flaps up to 16 cm wide. On the other hand, Alves et al. [9] stated that all donor sites were primarily closed without any complications, although some of them were 12 cm wide. However, Martins de Carvalho et al. [21] suggested that the flaps wider than 7 cm require skin grafting. A closure under tension is strongly related to a high risk of wound dehiscence and unexpected scar formation development. Therefore, split thickness skin grafts or local flaps should be used for the closure of a larger donor site. Limitation of shoulder movements can be seen in some patients but this has no significant impact on daily life for them [19]. In our study, the biggest flap was 10 cm wide, and the flap donor area was closed without any problems in all subjects while wound dehiscence was not detected in any patient.

The supraclavicular artery may be identified with a hand-held Doppler or computed tomography angiography of the neck preoperatively. Some authors have utilized a hand-held Doppler to identify the origin of the supraclavicular artery before the surgical procedure [6,11,12,18,22,23]. The concomitant ipsilateral neck dissection or history of previous neck dissection is a relative contraindication for the SCAIF due to the risk of injury of the supraclavicular vessels. In spite of this, this flap was applied in our study successfully in 6 patients who underwent ipsilateral neck dissection without any complication. In our experience, if transverse cervical vessels are preserved in level 4 during neck dissection and surgical maneuvers are performed carefully in both level 4 and

5, the SCAIF can be used safely. We believe that the intraoperative doppler ultrasonography is not routinely necessary except for patients with previously ipsilaterally neck dissection history.

There are some limitations of this study such as retrospective design, lack of control group and relatively small sample size. Further prospective and multicenter studies comparing the SCAIF and both pedicled and microvascular free flaps are needed.

Conclusions

The supraclavicular artery island flap is a thin, reliable and technically simple fasciocutaneous flap that has low complication rate and provides single-stage reconstruction of the numerous surgical defects of the head and neck. The SCAIF constitutes a good alternative to free flaps, while providing almost equivalent functional results and requiring less operative time and surgical effort.

Roles of authors: All authors have been actively involved in the planning, preparation, analysis and interpretation of the findings, enactment and processing of the article with the same contribution.

Conflict of Interest: The authors declare that they have no conflict of interest.

Funding Information: No financial supporter of this study.

References

- Sukato DC., Timashpolsky A., Ferzli G., et al. Systematic review of supraclavicular artery island flap vs free flap in head and neck reconstruction. *Otolaryngol Head Neck Surg.* 2019, 160: 215–222.
- Gurtner GC., Evans GRD. Advances in head and neck reconstruction. *Plast Reconstr Surg.* 2000, 106: 672–683.
- Lamberty BG., Cormack GC. Misconceptions regarding the cervico-humeral flap. *Br J Plast Surg.* 1983, 36: 60–63.
- Pallua N., Machens HG., Rennekampff O., et al. The fasciocutaneous supraclavicular artery island flap for releasing postburn mento-ternal contractures. *Plast Reconstr Surg.* 1997, 99: 1878–1884.
- Chiu ES., Liu PH., Friedlander PL. Supraclavicular artery island flap for head and neck oncologic reconstruction: indications, complications, and outcomes. *Plast Reconstr Surg.* 2009, 124: 115–123.
- Teixeira S., Costa J., Monteiro D., et al. Pharyngocutaneous and tracheoesophageal fistula closure using supraclavicular artery island flap. *Eur Arch Otorhinolaryngol.* 2018, 275: 1921–1926.
- Kim RJT., Izzard ME., Patel RS. Supraclavicular artery island flap for reconstructing defects in head and neck region. *Curr Opin Otolaryngol Head Neck Surg.* 2011, 19: 248–2450.
- Sandu K., Monnier P., Pasche P. Supraclavicular flap in head and neck reconstruction: experience in 50 consecutive patients. *Eur Arch Otorhinolaryngol.* 2012, 269: 1261–1267.
- Alves HR., Ishida LC., Ishida LH., et al. A clinical experience of the supraclavicular flap used to reconstruct head and neck defects in late-stage cancer patients. *J Plast Reconstr Aesthet Surg.* 2012, 65: 1350–1356.
- Granzow JW., Suliman A., Roostaeian J., et al. The supraclavicular artery island flap (SCAIF) for head and neck reconstruction: surgical technique and refinements. *Otolaryngol Head Neck Surg.* 2013, 148: 933–940.
- Kokot N., Mazhar K., Reder LS., et al. The supraclavicular artery island flap in head and neck reconstruction. Applications and limitations. *JAMA Otolaryngol Head Neck Surg.* 2013, 139: 1247–1255.
- Giordano L., Bondi S., Toma S., et al. Versatility of the supraclavicular pedicle flap in head and neck reconstruction. *Acta Otorhinolaryngol Ital.* 2014, 34: 394–398.
- Anand AG., Tran EJ., Hasney CP., et al. Oropharyngeal reconstruction using the supraclavicular artery island flap: a new flap alternative. *Plast Reconstr Surg.* 2012, 129: 438–441.
- Welz C., Canis M., Schwenk-Zieger S., et al. Oral cancer reconstruction using the supraclavicular artery island flap: comparison to free radial forearm flap. *J Oral Maxillofac Surg.* 2017, 75: 2261–2269.
- Wang Q., Chen R., Zhou S. Successful management of the supraclavicular artery island flap combined with a sternohyoid muscle flap for hypopharyngeal and laryngeal reconstruction. *Medicine (Baltimore).* 2019, 98: 17499.
- Nthumba PM. The supraclavicular artery flap: a versatile flap for neck and orofacial reconstruction. *J Oral Maxillofac Surg.* 2012, 70: 1997–2004.
- Pabiszczak M., Banaszewski J., Pastusiak T., et al. Supraclavicular artery pedicled flap in reconstruction of pharyngocutaneous fistulas after total laryngectomy. *Otolaryngol Pol.* 2015, 69: 9–13.
- Li C., Chen W., Lin X., et al. Application of the supraclavicular artery island flap for fistulas in patients with laryngopharyngeal cancer with prior radiotherapy. *Ear Nose Throat J.* 2020 Aug 25: 145561320951678.
- Herr MW., Bonanno A., Montalbano LA., et al. Shoulder function following reconstruction with the supraclavicular artery island flap. *Laryngoscope.* 2014, 124: 2478–2483.
- Pallua N., Magnus Noah E. The tunneled supraclavicular island flap: an optimized technique for head and neck reconstruction. *Plast Reconstr Surg.* 2000, 105: 842–851; discussion 852–854.
- de Carvalho FM., Correia B., Silva Á., et al. Versatility of the supraclavicular flap in head and neck reconstruction. *Eplasty.* 2020, 20: 45–52.
- Karabulut B. Supraclavicular flap reconstruction in head and neck oncologic surgery. *J Craniofac Surg.* 2020, 31: 372–375.
- Thompson A., Khan Z., Patterson A., et al. Potential benefits from the use of the supraclavicular artery island flap for immediate soft-tissue reconstruction during the COVID-19 pandemic. *J Maxillofac Oral Surg.* 2020, 19: 1–6.

Bayram Şahin, MD

Department of Otorhinolaryngology &
Head and Neck Surgery
Kocaeli Health Sciences University Derince
Training and Research Hospital
İbni Sina Mah. Lojman Sok. Derince/
Kocaeli, Turkey, 41090
e-mail: drbayramsahin@gmail.com

Submitted 29. 03. 2021

Accepted 09. 05. 2021

Free tensor fascia lata flap – a reliable and easy to harvest flap for reconstruction

R. Sathyamurthy, K. N. Manjunath, V. P. Waiker, S. Shanthakumar, M. Kumaraswamy

Department of Plastic and Reconstructive Surgery, Ramaiah Medical College, Bangalore, India

Summary

Background: Flaps are the essence of reconstructive surgery. The ability to successfully design, execute and manage the flaps makes plastic surgery an outstanding speciality. The choice of flap is mainly guided by the type of the defect. However, certain factors like technique feasibility, duration of the surgery and patient factors do have a role in decision making. The primary type of free flap (whether a muscle or a fasciocutaneous flap) is dictated by the defect or the wound characteristics. However, the choice of flap depends on various factors like the component of flap, pedicle length required, the ease of harvest and donor site morbidity. Tensor fascia lata (TFL) is one myocutaneous flap, which has well developed components other than a muscle. **Materials and methods:** The patients admitted to a tertiary care hospital with the diagnosis of composite tissue defect in any region of the body were enrolled for this study from November 2016 to November 2018. Patients undergoing free TFL flap reconstruction are studied. The duration of flap harvest, the anatomical site of pedicle, flap outcome and the need of secondary surgery were analysed. **Results:** Totally 14 patients were reconstructed with a free TFL flap. The anatomic location of the defect was more frequent on lower limbs – 8 cases (58%), followed by the upper limb and the head and neck area (3 cases, each 21%). The mean flap harvest time was 62.07 (45–80) min. The mean size of pedicle entry was 8.7 cm from the anterior superior iliac spine. Out of the 14 flaps, there were 10 (71%) flaps successful completely and 4 (29%) of them had partial loss. **Conclusion:** A free TFL flap harvest time is very short compared to any other flaps and hence makes it the flap of choice in patients who are critical and cannot withstand long operating time.

Key words

tensor fascia lata – free flap – reconstructive surgery

Sathyamurthy R., Manjunath K.N., Waiker P., et al. Free tensor fascia lata flap – a reliable and easy to harvest flap for reconstruction. *Acta Chir Plast.* 2021, 63(2): 57–63.

Introduction

Flaps are the essence of reconstructive surgery. The type of the defect is a main guide for the choice of a flap. However, certain factors like technique feasibility, duration of the surgery and patient factors do have a role in decision [1]. The advances of microsurgery and better understanding of vascular anatomy has made it possible to reconstruct the defect nearly to the normal. The primary type of a free flap (whether muscle/fasciocutaneous flap) is dictated by the defect or the wound characteristics. However, the choice of a flap (tensor fascia lata – TFL, anterolateral thigh flap – ALT, thoracodorsal artery perforator – TAP) depends on various factors like the component of the flap, pedicle length required, the ease of harvest and donor site morbidity [2]. Tensor fascia lata (TFL) is one of the myocutaneous flaps which has very constant pedicle anatomy

and well-developed components other than a muscle [3]. Hence, harvesting the flap is less time-consuming compared to other flaps. When used as a free flap, it has many advantages, too. This study was undertaken to assess the success outcome of free TFL flaps.

The aim of the presented study was to ascertain success rate of reconstruction of various defects with tensor fascia lata free flap. The objectives were to determine the ease of harvest of the flap in terms of time to harvest the exact location of the pedicle and to determine the outcome of the free TFL flap in terms of flap loss.

Materials and methods

Group of patients

The hospital based prospective study was carried out at the Department of Plastic and Reconstructive Surgery, over

a period of 24 months between November 2016 and November 2018. The subjects were enrolled according to the inclusion and exclusion criteria after obtaining an informed consent (Tab. 1).

The inclusion criteria included a composite defect in different regions of the body, age group 12–70 years, and a good Doppler flow in the recipient vessels.

The exclusion criteria included patients unfit for the free flap surgery with cardiopulmonary disease, renal failure, blood coagulation disorders and peripheral vascular diseases. A TFL free flap was planned in the defects which warranted a fasciocutaneous flap and in whom an ALT fasciocutaneous perforator was absent in the Doppler study, too.

Flap elevation technique

The musculocutaneous flap includes the entire muscle and an island of over-

Tab. 1. Demographic profile of the patients.

| SI. No | Defect site | Size | Sex | Loss | Pedicle entering site (cm from ASIS) | Age | Harvest time |
|--------|--------------------------|----------------------------|--------|----------|--------------------------------------|-----|--------------|
| 1 | head & neck | 15 × 10 cm (mucosa + skin) | male | NIL | 8 | 50 | 45 min |
| 2 | head & neck | 7 × 6 cm (mucosa) | female | partial | 8 | 60 | 60 min |
| 3 | head & neck | 18 × 6 cm (mucosa + skin) | male | complete | 9 | 60 | 50 min |
| 4 | lower 1/3 of leg | 18 × 8 cm | male | complete | 8 | 52 | 60 min |
| 5 | lower 1/3 of leg | 15 × 7 cm | male | NIL | 8 | 48 | 60 min |
| 6 | dorsal ankle contracture | 28 × 7 cm | male | partial | 9 | 20 | 45 min |
| 7 | dorsum of foot | 15 × 6 cm | female | NIL | 8 | 15 | 45 min |
| 8 | dorsum of foot | 20 × 10 cm | female | NIL | 9 | 48 | 75 min |
| 9 | dorsum of foot | 30 × 8 cm | male | NIL | 10 | 60 | 60 min |
| 10 | right heel | 18 × 10 cm | male | complete | 9 | 20 | 50 min |
| 11 | left heel | 20 × 10 cm | male | partial | 10 | 46 | 65 min |
| 12 | left forearm | 20 × 8 cm | female | complete | 10 | 15 | 80 min |
| 13 | right forearm | 30 × 8 cm | male | NIL | 10 | 65 | 80 min |
| 14 | right hand | 28 × 10 cm | male | NIL | 8 | 27 | 80 min |

ASIS – anterior superior iliac spine, NIL – no loss of flap

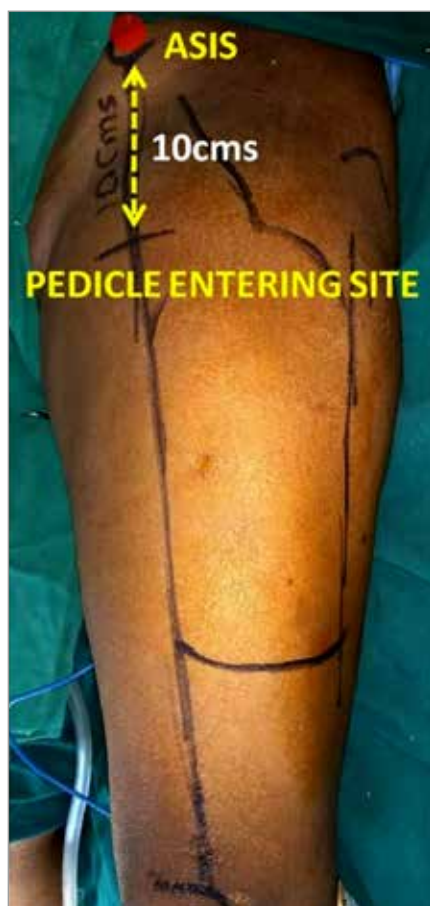

Fig. 1. Pedicle surface marking.

lying skin of the size 10 × 20 cm, larger than the muscle itself. The incision is made along the distal border of the flap and is continued through the fascia lata. Then the anterior and posterior incisions are made, extending from below upwards and toward the anterior superior iliac spine and the border of iliac crest. The dissection is continued deep to the fascia lata overlying the vastus lateralis rapidly in a relatively bloodless field. At a level of 8–10 cm below the anterior superior iliac spine (Fig. 1), the terminal branches of the lateral circumflex femoral artery are easily identified. The descending branch courses distally either between the vastus lateralis and the tensor fascia lata or within the vastus lateralis itself. The transverse branch enters the tensor fascia lata on its deep medial surface and is identified easily. The dissection is carried out proximally and separated from gluteal muscles. The follow up was done daily till the wound healed and later at 2- and 6-month intervals after the discharge of the patient.

Donor site management

Since the flaps harvested were large in size, the majority of flaps required skin grafts for donor site coverage. In cases where primary closure was possible, the donor site was closed primarily.

Results

There were totally 14 patients reconstructed with free TFL flaps. Out of the 14 patients, 10 (71%) and 4 (29%) were below and above 60 years of age, respectively. Ten were male patients and 4 were female patients. Eight patients (58%) had haemoglobin levels above 12% before reconstruction. In our study, we used free tensor fascia lata myocutaneous flaps for the coverage of composite defects following excision of buccal mucosal carcinoma in 3 patients, leg defects in 2 patients, dorsum of foot defects in 4 patients, heel defects in 2 patients, and upper limb defects in 3 patients. The anatomic location of the defect was more often on the lower limbs – 8 cases (58%), followed by the upper limb and the head and neck area

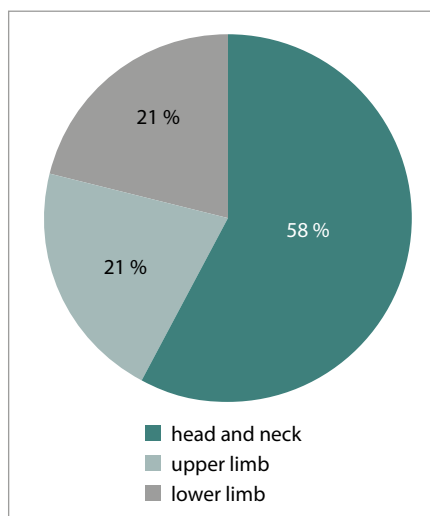


Fig. 2. Recipient site distribution.

(3 cases each 21%) (Fig. 2). The mean flap harvest time was 62.07 (45–80) min. The mean size of the pedicle entry was 8.7 cm (8–10) cm from the anterior superior iliac spine. The minimum and maximum lengths of the flap harvest were 14 and 30 cm, respectively. Type 2 diabetes mellitus was a comorbidity in 7 (50%) of our patients; 1 patient had thrombocytosis. Out of the 14 flaps, 10 (71%) of them were successful completely and 4 (29%) of them had partial loss. Out of the 4 patients who had partial flap loss, 3 had diabetes mellitus and 1 had preoperative thrombocytosis. On re-exploration, one patient had arterial thrombosis, which was re-anastomosed and, eventually, the patient had only minimal loss of the flap. The defect was covered by a skin graft. All the donor sites healed well and the patients had no deficit in hip extension or during walking.

Discussion

Tensor fascia lata is a flat muscle which acts as an accessory flexor and medial rotator of the thigh. Its arterial supply is from the transverse branch of the lateral femoral circumflex iliac artery and venous drainage from the pair of venae comitantes [4]. In the study on a hundred of cadavers, it is inferred that the muscle is supplied by a single dominant transverse branch in 67% and by anterior

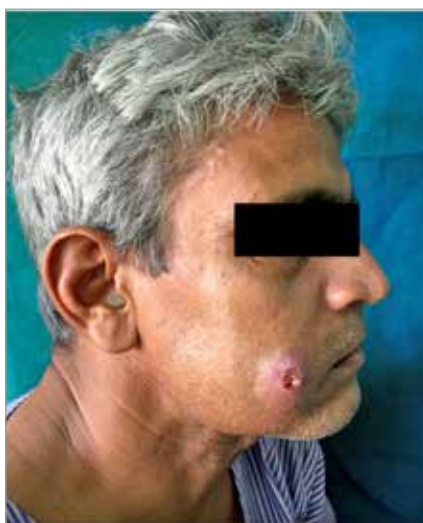

Fig. 3A. Preoperative photo of the patient with carcinoma of buccal mucosa.

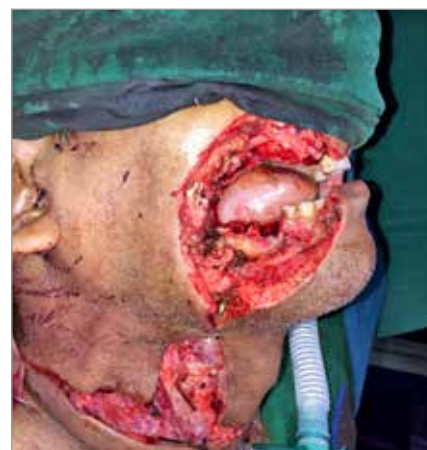

Fig. 3B. Composite defect after excision of the tumour.

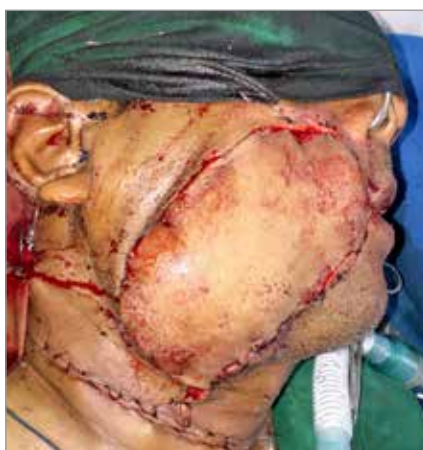

Fig. 3C. Status after the inset of free TFL flap.

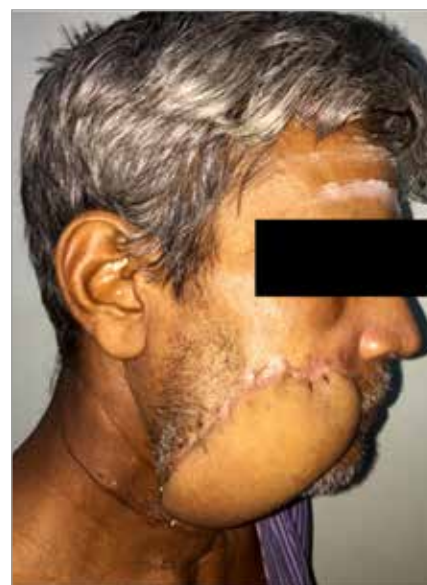

Fig. 3D. Late postoperative result.

branch in 13%; in 20% of cases, it has additional supply from the common femoral or medial circumflex femoral vessels. The vascular pedicle enters the muscle approximately 8 cm distal to the anterior iliac spine [5]. In our cadaver study, there were 10 TFL flaps studied and the pedicles were identified at the average 9.15 (8–10.5) cm. Cadaver studies show that the blood supply to the skin is provided by numerous perforators from the underlying muscular arteries; the artery after piercing the muscle pierces the fascia and divides superiorly and inferiorly to supply the skin. Sometimes it is supplemented by the branches of the de-

scending branch of lateral circumflex femoral vessels. The vascular pedicle is very consistent in position. It enters the muscle at 8 cm from the anterior superior iliac spine (ASIS) [6]. The diameter of the pedicle of TFL flap was measured to be 1.5–2 mm. The calibre of the vessels is compatible for microvascular anastomosis. This makes the flap ideal for microvascular surgery. The vascular pedicle in this flap can be dissected to 4–5 cm in length, which is considered relatively short by some surgeons. However, the length of the pedicle can be increased up to 10 cm, if the descending branch of lateral circumflex femoral and rectus

femoris branch are divided [6]. The dissection up to the lateral circumflex and ligating ascending branch and descending branch adds additional 4–5 cm to the pedicle length and also increases the diameter to 2–3 mm. Although this myocutaneous flap has skin, subcutaneous tissue, fascia and muscle, it is a thinner and more pliable flap compared with an ALT free flap [7]. In our study, 3 patients with composite defects of the head and neck were reconstructed using tensor fascia lata flap. In all these patients, the muscle was debulked completely, to make the flap thinner. Since the flap was completely thin, the flap contoured well to the defect. Out of 3 patients, 1 patient had partial loss of the flap (inner lining). The patient had perioperative hypotension and was put on noradrenaline support perioperatively. This led to a perioperative fluctuation of blood pressure. During revision surgery, the patient had huge external clot pressing on the anas-

tomosis leading to venous thrombosis. The clot was evacuated and venous reanastomosis was performed. Eventually the inner lining of the flap necrosed. The outer skin paddle was healthy and inner lining left for secondary healing. The majority of the studies conclude that an ALT flap is considered as an ideal soft tissue donor for head and neck reconstruction [8–10] but the dissection of the musculocutaneous perforator is a challenge [11–13]. Moreover, the inconsistent anatomy of perforators make it difficult to harvest sometimes. In patients with large amounts of subcutaneous fat, the flap harvested is too bulky for head and neck reconstruction.

In all 3 of our cases, preoperative Doppler studies could not identify the perforator for an ALT flap. In all 3 cases, a TFL was harvested within 60 minutes, which is its greatest advantage (Fig. 3A–D). The flap harvested was thin and contoured the buccal mucosa. In one of the pa-

tients, we chose the free tensor fascia lata flap for buccal mucosa reconstruction, mainly because the flap territory was thin and non-hairy compared with other flap sites. In the study conducted by Subramania Iyer et al., the flap was also harvested along with the iliac crest for maxillary and orbital reconstruction with a good outcome [14]. For head and neck reconstruction, a TFL provides an alternative to an ALT.

In 8 of our cases, leg and foot reconstruction was performed with a TFL flap. In these cases, the defects were large. An ALT provides a wide territory to harvest large flaps. In all these cases, perforators were not located in preoperative Doppler studies. Studies by Contendin [7] showed that in the absence of an ALT perforator, a TFL perforator flap can be harvested. They also suggested that the skin in a TFL perforator flap can be of large dimensions [15–17]. Kardbeg et al. [18] harvested a TFL

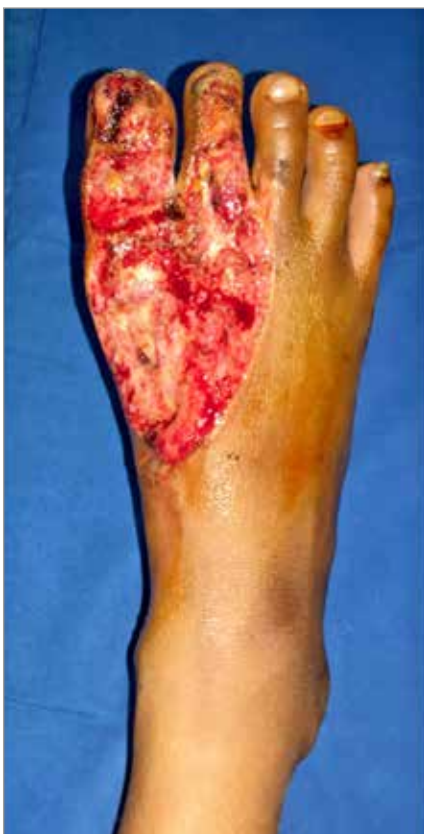

Fig. 4A. Posttraumatic foot defect with exposed metatarsal bone.

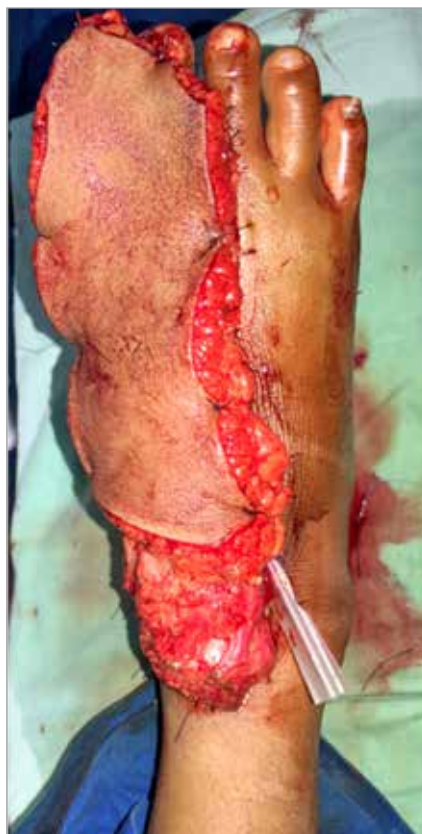

Fig. 4B. Immediate result after the inset of the flap.

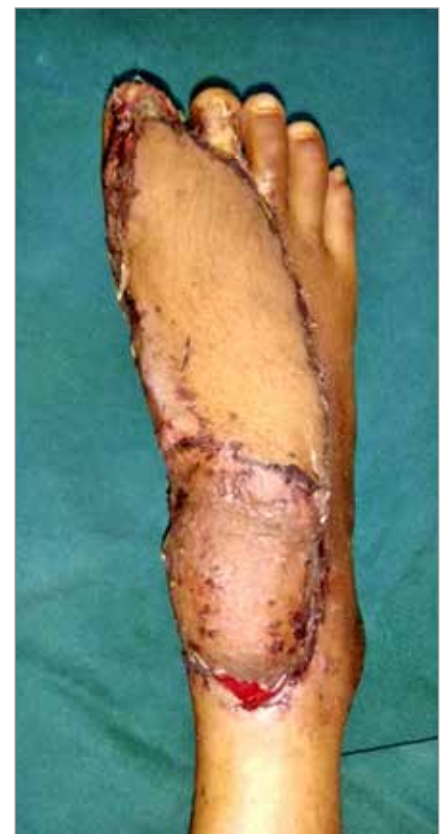

Fig. 4C. Late result after reconstruction.

flap up to 30 × 15 cm as a pedicled flap. However, no studies have defined the exact boundaries of the skin territory in these flaps [4]. In our study, we used a free tensor fascia lata flap to resurface two composite heel defects. In these cases, fascia lata adhered well to the calcaneum, providing a durable cover for the heel defect. Two leg and four foot dorsum defects were resurfaced with a free TFL flap as well (Fig. 4A–C). In 3 of our patients, there was a minimal flap necrosis. One patient was a diabetic and developed arterial thrombosis within 12 hours of the anastomosis. The patient had atherosclerotic vessels; he had a good flow immediately after the anastomosis but later developed arterial thrombosis. The other patient was a young male. The muscle component of the flap was bulky, the cut ends exerted profuse bleeding postoperatively, leading to pressure effects on the anastomosis and venous thrombosis. In both cases, timely re-exploration salvaged the flap; however, there was a flap necrosis of a minimal extent. This minimal necrosis of the flap required regular dressing and the wound healed by secondary intention.

In 3 of our cases, a TFL was used for hand and forearm reconstruction. During the flap harvest, we found that the flap anatomy was constant and the pedicle was found at 8–10 cm from the ASIS in all 3 cases. In 2 cases, the different components of the flaps were used for different purposes. In one case, the fascia lata was used for bridging the gaps of the excised tendons and the flap provided an easy gliding surface. In another case, the patient had necrosis of the flexor group of the muscles exposing the bone. In this case, the TFL muscle was used to cover the defect and the fascia was used to bridge the tendon gaps. Same patient had a circumferential loss of the soft tissue over the metacarpals and phalanges. To cover this defect, a large skin paddle was harvested and used for resurfacing the defect. All fingers except the thumb were resurfaced on both ventral and dorsal side. The fingers moved as one unit (Fig. 5A–C). In these cases, the defect size was smaller but required a thin pliable flap, which also allowed easy gliding of the tendons underneath. By doing so, we could reconstruct tendons and cover the defect in a single stage. In each site of the re-

construction, the distinctive advantage of a TFL flap was utilised.

Free flap and microvascular surgery have their own limitations like a long operating time and a high anaesthetic risk [19]. They represent indirect implications on the hospitalisation costs. The majority of a microvascular surgery time is spent on flap harvest. In our study, all flaps are harvested along with the muscle and hence were harvested within 1 hour, compared to ALT, which was harvested in 1½ hour, where the time is spent more on dissecting an intramuscular pedicle. This is a major advantage as it reduces the total operating hours. Akthar et al. [20] also concluded in their study that a TFL is best suited for critical patients who cannot tolerate a long operating time. Besides this, the flap has a reliable, highly consistent vascular pedicle, which can support a large dimension flap [21]. In our study, flap was harvested with the muscle. Retrospectively, we think this was the cause of flap loss in 2 cases. As per the literature, isolation of a perforator through the muscle was also possible in a short time. Reducing the muscle bulk can improve a success rate. An ALT is proved beyond

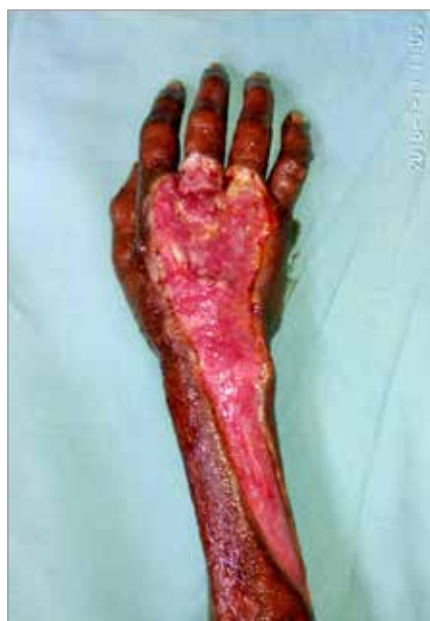

Fig. 5A. Preoperative photo of hand and forearm defect.

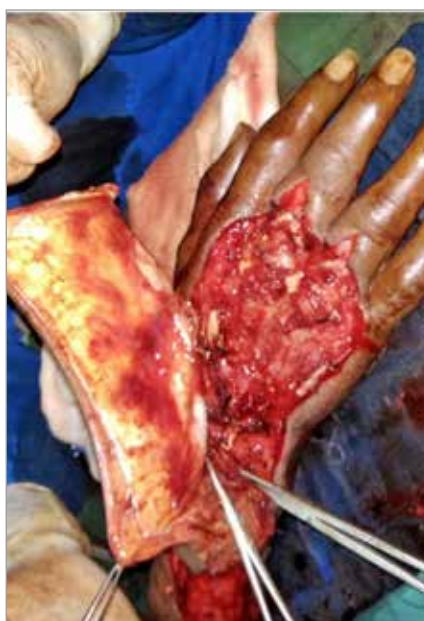

Fig. 5B. Free TFL flap used for bridging the tendon gap.

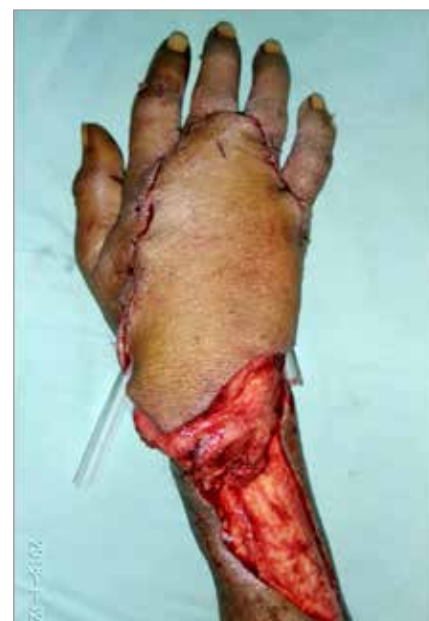

Fig. 5C. Status after the inset of free TFL flap.

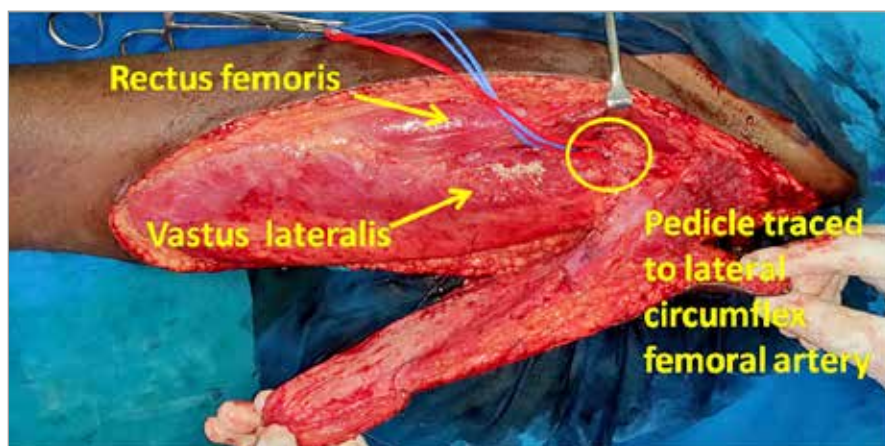


Fig. 6. Dissection of the pedicle up to the lateral circumflex femoral branch.

doubt as a first choice for soft tissue reconstruction. Nevertheless, anatomical inconsistency of the vascular pedicle is a major hurdle while harvesting the flap. Compared with an ALT, a tensor fascia lata free flap has a certain disadvantage like a short pedicle length [16,22] but certain manoeuvres like dissecting proximally up to lateral circumflex femoral artery (Fig. 6) can increase the pedicle length. Studies also show that the calibre of a TFL pedicle is good for survival of a large flap and for its metabolic demands [23]. Hence, a free TFL can be used either as a first choice or as an alternative to an ALT flap whenever a musculocutaneous ALT perforator is inconsistent.

Conclusion

Tensor fascia lata is a thin, pliable, myocutaneous flap, which can be used either as a first choice or as an alternative to an ALT fasciocutaneous flap. The consistent anatomy of a vascular pedicle is advantageous in a free TFL, compared to an ALT flap. Although the pedicle length is short, it can be increased when dissection is continued up to the lateral circumflex femoral artery. An excess muscle bulk proves hazardous in some situations. Reducing the muscle bulk around the vascular pedicle prevents undue pressure on the anastomosis, and thus improves a success rate. The non-hair bearing skin in the TFL flap territory

makes it a choice for buccal mucosa reconstruction. Similarly, the use of a fascial component for tendon reconstruction can avoid the second stage surgery in hand and forearm reconstruction. The harvest time is very short compared to any other flaps and hence makes it the flap of choice in patients who are critical and cannot withstand a long operating time.

Roles of authors: All authors have been actively involved in planning, preparation, analysis and interpretation of the findings as well as in enactment and processing of the article with the same contribution.

Declaration: All procedures followed were in accordance with the ethical standards of the responsible committee on human experimentation (institutional and national) and with the Helsinki Declaration of 1975, as revised in 2008. An informed consent for being included in the study was obtained from all patients.

Conflict of interest: There is no conflict of interest to disclose.

Funding: This research received no specific grant from any funding agency in the public, commercial, or not-for profit sectors.

References

1. Aladimi MT., Han B., Li C., et al. Factors to consider when deciding on the type of free-flap reconstruction of head and neck soft tissue defects. *J Otorhinolaryngol Relat Spec.* 2017, 79: 230–238.
2. Broome Martin M., Juilland N., Litzstorf Y., et al. Factors influencing the incidence of severe complications in head and neck free flap reconstructions. *Plast Reconstr Surg – Global Open.* 2016, 4: 1013

3. Shestak KC., Edington HJD., Johnson RR. The separation of anatomic components technique for the reconstruction of massive midline abdominal wall defects: Anatomy, surgical technique, applications, and limitations revisited. *Plast Reconstr Surg.* 2000, 105: 731–739.
4. Rifaat MA., Gawad WSA. The use of tensor fascia lata pedicled flap in reconstructing full thickness abdominal wall defects and groin defects following tumor ablation. *J Egypt Natl Canc Inst.* 2005, 17: 139–148.
5. Saadeh FA., Haikal FA., Abdel-Hamid FA. Blood supply of the tensor fasciae latae muscle. *Clin Anat.* 1998, 11: 236–238.
6. Williams JK., Carlson GV., DeChalain T., et al. Role of tensor fasciae latae in abdominal wall reconstruction. *Plastic and Reconstructive Surgery.* 1998, 101: 713–718.
7. Contedini F., Negosanti L., Pinto V., et al. Tensor fascia latae perforator flap: An alternative reconstructive choice for anterolateral thigh flap when no sizable skin perforator is available. *Indian J Plast Surg.* 2013, 46: 55–58.
8. Coskunfirat OK., Ozkan O. Free tensor fascia lata perforator flap as a backup procedure for head and neck reconstruction. *Ann Plast Surg.* 2006, 57: 159–163.
9. Chen HC., Tang YB. Anterolateral thigh flap: An ideal soft tissue flap. *Clin Plast Surg.* 2003, 30: 383–401.
10. Chana JS., Wei FC. A review of the advantages of the anterolateral thigh flap in head and neck reconstruction. *Br J Plast Surg.* 2004, 57: 603–609.
11. Engel H., Gazyakan E., Cheng MH., et al. Customized reconstruction with the free anterolateral thigh perforator flap. *Microsurgery.* 2008, 28: 489–494.
12. Wei FC., Jain V., Celik N., et al. Have we found an ideal soft tissue flap? An experience with 672 anterolateral thigh flaps. *Plast Reconstr Surg.* 2002, 109: 2219–2226.
13. Wei FC., Celik N., Jeng SF. Application of “simplified nomenclature for compound flaps” to the anterolateral thigh flap. *Plast Reconstr Surg.* 2005, 115: 1051–1055.
14. Iyer S., Kuriakose MA. Tensor Fascia Lata-iliac crest osteocutaneous flap for orbitomaxillary reconstruction: A preliminary report. *Indian J Plast Surg.* 2010, 43: 8–13.
15. Deiler S., Pfadenhauer A., Widmann J., et al. Tensor fasciae latae perforator flap for reconstruction of composite Achilles tendon defects with skin and vascularized fascia. *Plast Reconstr Surg.* 2000, 106: 342–349.
16. Koshima I., Urushibara K., Inagawa K., et al. Free tensor fasciae latae perforator flap for the reconstruction of defects in the extremities. *Plast Reconstr Surg.* 2001, 107: 1759–1765.
17. Coskunfirat OK., Ozkan O. Free tensor fascia lata perforator flap as a backup procedure for head and neck reconstruction. *Ann Plast Surg.* 2006, 57: 159–163.

18. Karabeg R., Dujso V., Jakirlic M. Application of tensor fascia lata pedicled flap in reconstructing trochanteric pressure sore defects. *Medicinski arhiv*. 2008, 62: 300–302.
19. Krishnan KG., Winkler PA., Müller A., et al. Closure of recurrent frontal skull base defects with vascularized flaps – a technical case report. *Acta Neurochirurgica*. 2000, 142: 1353–1358.
20. Akhtar MS., Khurram MF., Khan AH. Versatility of pedicled tensor fascia lata flap: a useful and reliable technique for reconstruction of different anatomical districts. *Plast Surg Int*. 2014. 2014: 846082.
21. Hubmer MG., Schwaiger N., Windisch G., et al. The vascular anatomy of the tensor fasciae latae perforator flap. *Plastic and Reconstructive Surgery*. 2009, 124: 181–189.
22. Kimura N., Satoh K., Hosaka Y. Tensor fasciae latae perforator flap. *Clin Plast Surg*. 2003, 30: 439–446.
23. Tursun R., Marwan H., Marshall Green J., Alotaibi F., LeDoux A. Combined anterolateral thigh and tensor fasciae latae flaps: an option for reconstruction of large head and neck defects. *Oral Maxillofac Surg*. 2017, 75: 1743–1751.

K. N. Manjunath, MS, Mch
Department of Plastic and Reconstructive
Surgery
Ramaiah Medical College
M S Ramaiah Nagar, MSRIT Post
Bangalore 560 054, India
e-mail: drknmanjunath@gmail.com

Submitted: 25. 02. 2021
Accepted: 09. 05. 2021

Presence of circulating tumor cells in a patient with multiple invasive basal cell carcinoma – a case report

K. Kiss¹⁻³, I. Kiss^{4,5}, K. Kološtová⁵, E. Pospíšilová⁵, M. Široká^{1,2}, A. Fibír^{1,2}

¹ Department of Plastic Surgery, University Hospital in Hradec Králové, Czech Republic

² Faculty of Medicine in Hradec Králové, Charles University, Hradec Králové, Czech Republic

³ Department of Plastic Surgery, Third Faculty of Medicine and University Hospital Královské Vinohrady, Charles University, Prague, Czech Republic

⁴ First Faculty of Medicine, Charles University, Prague, Czech Republic

⁵ Laboratory of Genetics, Department of Laboratory Diagnostics, Third Faculty of Medicine and University Hospital Královské Vinohrady, Charles University, Prague, Czech Republic

Summary

Background: Basal cell carcinoma (BCC) is the most frequent skin cancer worldwide, however, its metastatic spreading is extremely rare.

Case: We present a case of advanced BCC with rapid growth of new tumor lesions in a patient who was later diagnosed with Gorlin syndrome. Due to the advanced disease stage, the patient was examined for circulating tumor cells (CTCs), which are used as a prognostic marker in some metastatic malignancies. To date, no studies have been found that could assess the BCC tumor and the presence of CTCs in peripheral blood. CTCs were obtained after each surgical excision and during systemic oncological therapy from the peripheral venous blood by size-based isolation method (Metacell®) and cultured *in vitro* for 7 days. CTCs were enriched by size-based separation and examined using vital fluorescence microscopy. Cytomorphological comparison of CTCs with cells from the tumor lesions was provided. In the course of the treatment, the CTCs count in the blood decreased after surgical removal of the tumorous mass, but finally, the sustained and persisting decrease in CTCs was achieved with a hedgehog pathway inhibitor treatment. **Conclusion:** The detection of CTCs points a systematic disease behavior in this case.

Key words

basal cell carcinoma – BCC – circulating tumor cells – CTCs – hedgehog pathway inhibitor

Kiss K., Kiss I., Kološtová K., et al. Presence of circulating tumor cells in a patient with multiple invasive basal cell carcinoma – a case report. *Acta Chir Plast.* 2021, 63(2): 64–68.

Introduction

Basal cell carcinoma (BCC) belongs to the group of non-melanoma skin cancer and it is the most common cutaneous malignancy at all [1]. Examples of other non-melanoma tumors include squamous cell carcinoma, Merkel cell carcinoma or sebaceous carcinoma; however, BCC accounts for 80–85% of this category [1,2]. The worldwide incidence of skin malignancies (melanoma along with non-melanoma skin cancer) is epidemically increasing [2,3].

Even though BCC is known to be a slowly growing and very rarely metastatic skin cancer (with an estimated incidence of 0.003–0.550%), the tumor may be destructive to surrounding tissues, and even to a cartilage or a bone [4].

BCC can be easily misdiagnosed for various similar benign skin conditions, and most of them might be underestimated.

Despite the increasing incidence of skin cancer, which may be due to better diagnostic methods, research of literature on skin cancer confirmed the rising trends of its prevalence [5]. Circulating tumor cells (CTCs) shed as entire cells and cell clusters from the primary and/or secondary tumors are able to migrate into the bloodstream while often having the potential of creating distant metastatic lesions [6].

CTCs are a promising biomarker of malignancy and tumor dissemination. Studies declared potential use of CTCs in the detection, disease staging and management of metastatic melanoma

[7]. A therapy response could be monitored in melanoma patients receiving interferon therapy or other immunotherapies, such as immune checkpoint inhibition [8]. As metastatic BCC is exceedingly uncommon, very poor understating of its incidence, risk factors, dissemination and treatment options are known [9]. In accordance with the advanced clinical stage of the reported patient, CTCs isolation has been tested in this case.

Case report

A 67-year-old Caucasian woman was admitted to a Czech district hospital in December 2017 for anemia-induced fatigue and collapse. Anemia, with admission hemoglobin level 4.7 g/dL was

caused by chronic bleeding from extensive skin tumors.

In the year 2012, she had already undergone excision of small BCC on the trunk and scalp regions. After the appearance of new lesions, she was afraid of undergoing another surgical procedure. She was bandaging the growing multiple ulcerated skin lesions and hiding them from her relatives.

The patient was thoroughly examined by medical imaging; X-ray of the chest, ultrasound of the abdomen, CT scans of the head and trunk, gastroscopy and colonoscopy. None of the examinations showed any other cause of bleeding or metastatic involvement. After all of the examinations and treatment with blood transfusions, she was recommended to undergo the surgical treatment of skin tumors at the department of plastic and reconstructive surgery.

This patient was presented to our department at the beginning of January 2018 with extensive bleeding skin neoplasm with a past medical history of atrial fibrillation, diabetes mellitus, hypertension, and hyperlipidemia; her surgical history included total abdominal hysterectomy with bilateral salpingo-oophorectomy. Clinical examination showed multiple (at least 10) ulcerated skin lesions. Two of them, which were the biggest ones, both on the back, were actively bleeding. The diameter of both bleeding masses was 8–9 cm and around 2 cm above the skin surface (Fig. 1). There were other ulcerated lesions on the neck and parietal region of the head. Other parts of the body, mainly the back, were covered by lesions with the appearance typically described for superficial basal cell carcinoma; mostly scaly, erythematous patches or thin papules [10].

A multiphase surgery was planned with the primary goal of removing bleeding lesions. The patient underwent the first surgery under general anesthesia, in which wide excisions of the two biggest masses on the back and local flaps for coverage of the defects were per-

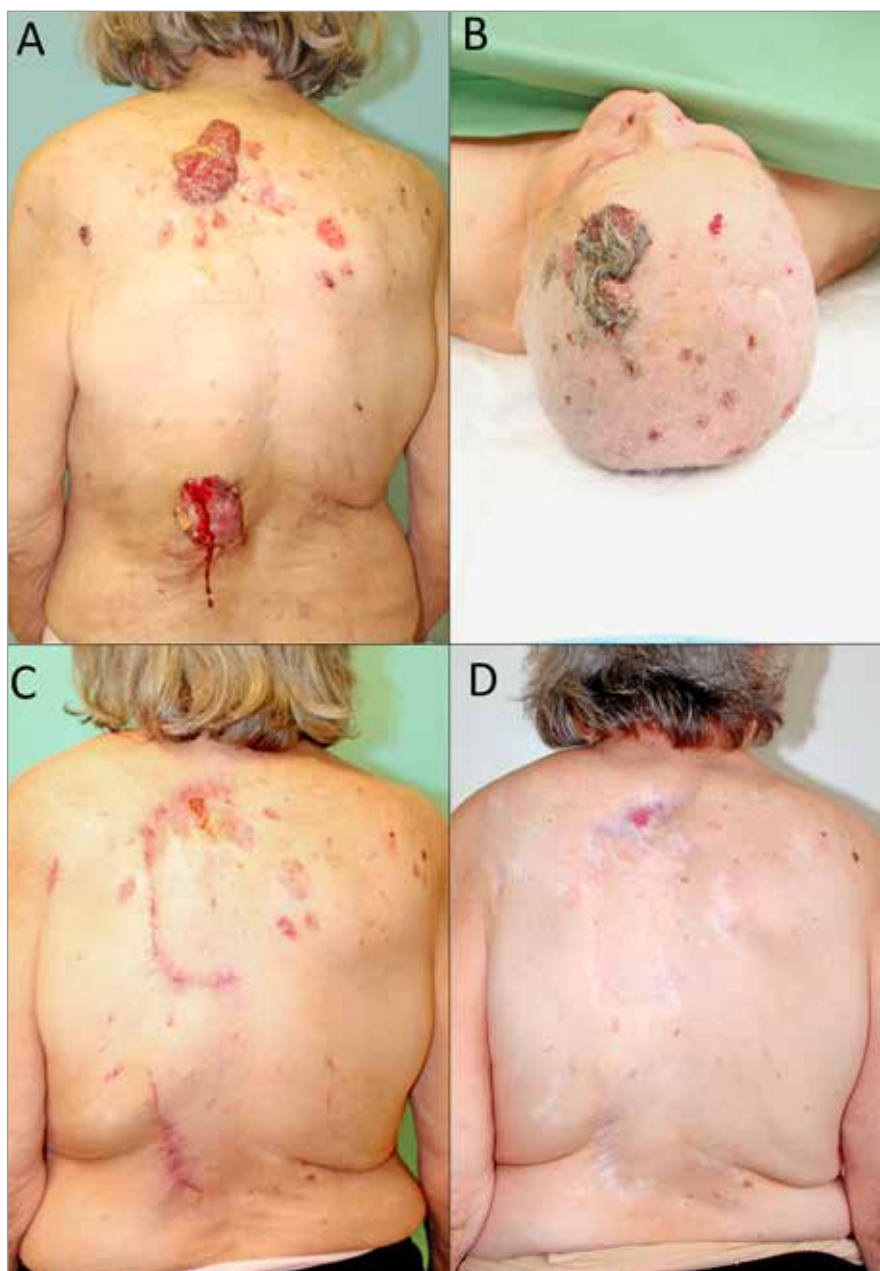

Fig. 1. The patient during the treatment. (A) Patient's back on the first day of admission. (B) Patient's head before the second stage of surgeries. (C) Patient's back after the second stage of surgeries. (D) Patient's back after 10 months of Erivedge treatment. Previously unremoved lesions are already in regression.

formed. We excised three other smaller lesions. Three days later, we continued in surgical removal of other suspicious lesions under local anesthesia. Three months later, after the patient's recovery, we proceeded into the next phase of the removal of larger lesions under general anesthesia. The BCC of the scalp expanded virtually 1% of the total body surface area. A wide excision of the ul-

cerated scalp mass was performed, and the defect was covered by a split-thickness skin graft. During this operation, smaller presumed skin tumors were removed by excision. The patient healed very well without any complications.

All 14 excised lesions were sent for histopathological examination, which showed a combination of invasive, nodular and superficial BCC with clear

margins except for one area of the left temporal region. Despite our efforts of surgical elimination of multiple BCCs, we observed rapid growth of previous lesions and the occurrence of new lesions predominantly localized on the back and the head. In agreement with the oncologist and the dermatologist, we came to the conclusion that the patient could no longer be offered further surgical therapy or local dermatological therapy.

The patient was referred to oncologists for further treatment and monitoring. Radiotherapy had not been indicated due to the extensive affected skin areas. Genetic examination verified Gorlin syndrome (nevroid basal cell carcinoma syndrome). Targeted therapy with a hedgehog pathway inhibitor had been initiated. From the beginning, the treatment was without any complications and a reduction of some lesions was observed. Later on, complete regression of several BCCs was confirmed. The patient had been treated with Erivedge (Erivedge®, Vismodegib, Genentech, USA) 150 mg once a day for almost a year with mild side effects only (occasional diarrhea and hair thinning). This therapy will continue until drug toxicity.

Circulating tumor cell investigation

As previously mentioned, BCC is known for its individual invasive local growth. The patient described in the study presented multiple and rapidly growing skin lesions with an intention of systematic spreading. Isolation of CTC was indicated to prove the possible systemic disease character following a thorough examination which excluded other malignancies that could affect the results.

After the patient signed the informed consent, she was examined for CTCs throughout the entire period of her treatment. The patient underwent regular blood sampling, approximately 8 mL of venous blood was drawn from the cubital veins and placed into S-Monovette tubes (Sarstedt AG & Co., Numbrecht,

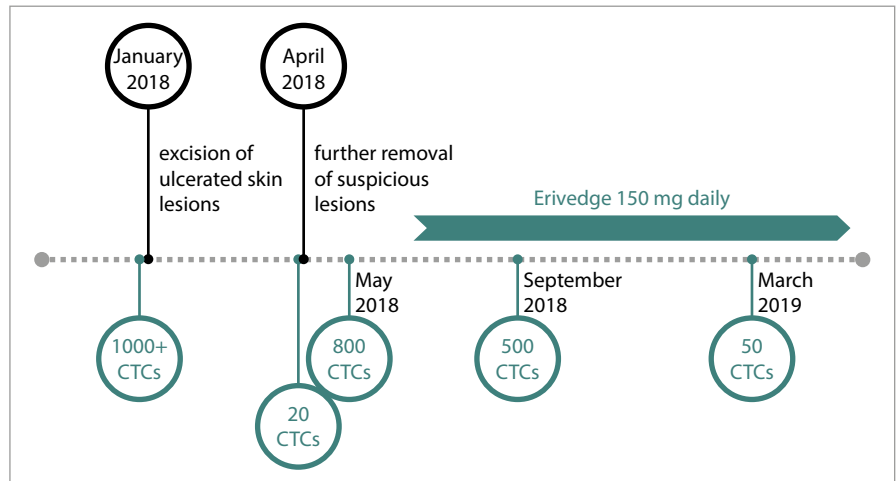


Fig. 2. Sequence of patient treatment and blood samplings reporting numbers of circulating tumor cells in time.

Germany) containing 1.6 mg EDTA (ethylenediaminetetraacetic acid) /mL blood as an anticoagulant. The samples were processed at room temperature using an isolation procedure completed within 24 hours after blood draw.

CTCs enrichment and culture: A size-based separation method for viable CTC-enrichment from peripheral blood was used (MetaCell®, MetaCell s.r.o., Ostrava, Czech Republic) [11]. The size-based enrichment process is based on the filtration of peripheral blood through a porous polycarbonate membrane with pores of 8 µm in diameter. The standard 8 mL of peripheral blood were transferred to the filtration tube. The peripheral blood flow is supported by the capillary action of the absorbent touching the membrane filter. The membrane filter, which is kept in a plastic ring, was transferred directly into a 6-well culture plate and 4 mL RPMI (Roswell Park Memorial Institute) medium containing 10% FBS (fetal bovine serum) was added to the membrane top and CTCs were cultured on the membrane *in vitro* under standard cell culture conditions (37°C, 5% CO₂ atmosphere) for a minimal period of 7 days on the membrane. Vital fluorescence stains (NucBlue® Live ReadyProbes® Reagent, CellTracker™ Green CMFDA, MitoTracker Red CMXRos, all by ThermoFisher Scientific, USA) were

applied on the cultured cells to visualize cell nucleolus, cytoplasm, and mitochondria. The membrane with the captured cells was transferred to a microscopic slide and examined using fluorescence microscopy at magnification 20× to get an overall view of cells on the membrane and further at magnification 40× and 60× for detailed cytomorphological analysis. Isolated cells and/or clusters of cells of interest were selected, digitized and examined by an experienced researcher.

Blood sampling was initiated in the morning before the first of the surgeries in January 2018 (Fig. 2). The collection of blood specimens was obtained from cubital veins under aseptic conditions. The first samples showed the presence of CTCs in an uncountable amount, more than a thousand cells on the filtration membrane were detected. The cytomorphological analysis showed cells with epithelial character of regular shape, smooth nucleus structure and regular nuclear contour (Fig. 3).

An additional blood test was performed before the second stage of skin cancer removal, about 3 months after the primary surgery in April 2018. In this phase of lesions elimination, a small section of tumorous tissue was sampled and sent along with blood for comparative cellular examination. The results sur-

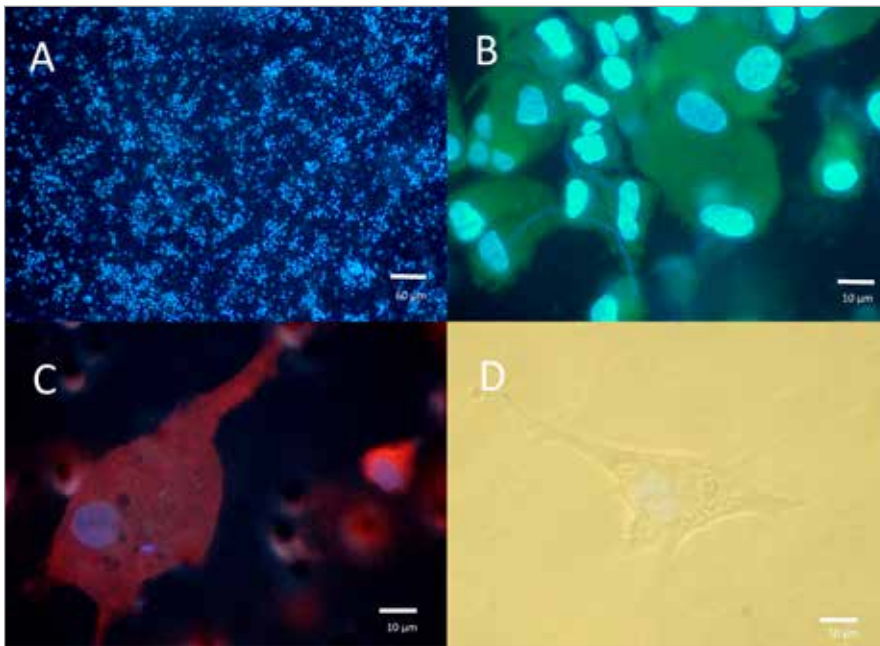


Fig. 3. Viable circulating tumor cells from peripheral blood and basal cell carcinoma cells obtained from cancer tissue. (A) Isolated circulating tumor cells from the patient’s peripheral blood before the first surgery (magnification 10×). (B) Circulating tumor cell clusters, (CellTracker™, NucBlue™) (magnification 60×). (C) Isolated circulating tumor cells, (NucBlue™, Mitotracker™) (magnification 60×). (D) Tumor cells from the basal cell carcinoma lesion (magnification 60×).

prisingly presented a significant reduction in the number of CTCs to a level that was the lowest throughout the whole measurement. There were only 20 cells on the membrane. The cells from the primary tumor cultivated during the same period, stained as examined CTCs from the peripheral blood, showed the same morphological characteristics, thus explaining their origin in the circulation. During this period, when the largest ulcerated bleeding tumors were surgically removed, our patient was in a stable stage regarding the constant number of tumor lesions, which once again corresponds to the lowest rate of the measured CTCs.

Two weeks later, in May 2018, the third blood examination was done when the wounds were nearly healed. The number of CTCs steeply rose to about 800. We observed that new BCC lesions began to appear, and previous lesions had grown in size. Shortly afterward, Erivedge treatment in the oncology department had

been initiated. Other blood samplings were completed 5 months after the previous collection in September 2018. The wounds after the excisions were completely healed at that time and improvement such as decreased tumor growth due to oncologic treatment was already observed. The presence of CTCs decreased slightly, approximately 500 cells were detected. The last blood sample was taken 9 months after therapy initiation, in March 2019, when the patient had no more complaints and her quality of life improved significantly. The number of CTCs reached almost the lowest previous value, 50 cells on the membrane were identified.

Discussion

In the past two decades, big efforts and expectations were put into the discovery of new non-invasive tools for diagnosis of cancer. Further improvement of these markers could help in more precise diagnosis, specific prognosis, per-

sonalized therapy and early recurrence alert. Examination of CTCs, known also as liquid biopsy, is easily collected from the patient and allows to examine molecular architecture and behavior of tumor cells in real time. Thus, it helps to understand disease pathophysiology and gives a chance to promptly react to treatment effectiveness [12]. CTCs are cells which are shed from the primary tumor, enter the bloodstream of the patient and have the potential to develop distant metastasis [13]. Positive isolation and detection of CTCs has been validated as a prognostic factor in metastatic breast cancer and several other solid tumors such as prostate, colorectal and lung cancer [14].

This case report shows the presence of CTCs in a patient with BCC, a malignant cancer known for its local invasive growth instead of systemic spread. No study evaluating a BCC tumor and the presence of CTCs in peripheral blood has been found so far.

Before the first therapeutic surgery, the number of CTCs was extremely high. This is very interesting due to the fact, that the general presence of CTCs in patients with malignancy is rather low and these high numbers could be matched with blood samples from heavily disseminated metastatic diseases.

Our case shows that tumor removal itself influenced the reduction of the CTCs number. The question is whether the removal of all skin malignancies would lead to complete elimination of CTCs. In our patient, a significant re-growth of CTCs was recorded even after the removal of most of the BCCs, up to the treatment with a hedgehog pathway inhibitor causing CTCs rate decline. These findings suggest that we should keep in mind the possibility of early progress of BCC into a systemic disease. Although BCC is commonly referred as a local disease, in advanced cases systematic therapy with hedgehog inhibitors is used with a positive outcome, which is also in correlation with the presented case.

With the appearance of new BCC lesions, an increase of CTCs in peripheral blood was observed. The growth of these new lesions has ceased only through permanent reduction of CTC cells in the blood.

Conclusion

We report a case of successful isolation of CTCs in multiple invasive BCC with dynamic change of cell quantity reflecting the surgical and oncological treatment. While surgical excisions were followed by an immediate, although temporary drop in cell count, a final persistent decrease was achieved with hedgehog pathway inhibitor treatment. This continual decline of CTCs was eventually associated with termination of developing new lesions and regressing the existing ones. The detection of CTCs in this case points to a possible systematic behavior. Surely, there is a requirement for further studies and approval of the presence of CTCs in other patients who are treated for BCC.

Acknowledgements: This work was funded by the Charles University Grant Agency, Progres Q40/04.

Ethical approval: All procedures performed in the case study involving human participant were in accordance with the ethical standards of the institutional

research committee (Ethics Committee, University Hospital Hradec Kralové, Sokolská 581, 500 05 Hradec Kralové, Czech Republic, reference number 201805 S09P) and with the Helsinki declaration from 1975 (revised in 2000) and its later amendments or comparable ethical standards.

Roles of authors: All authors contributed equally to preparing the manuscript.

Conflict of interest: The authors state that there are no conflicts of interest regarding the publication of this article.

References

1. Simões MCF, Sousa JJS, Pais AACC. Skin cancer and new treatment perspectives: a review. *Cancer Lett.* 2015, 357: 8–42.
2. Apalla Z, Nashan D, Weller RB, et al. Skin cancer: epidemiology, disease burden, pathophysiology, diagnosis, and therapeutic approaches. *Dermatol Ther (Heidelb).* 2017, 7: 5–19.
3. Ferlay J, Colombet M, Soerjomataram I, et al. Estimating the global cancer incidence and mortality in 2018: GLOBOCAN sources and methods. *Int J Cancer.* 2019, 144: 1941–1953.
4. Berking C, Hauschild A, Kölbl O, et al. Basal cell carcinoma-treatments for the commonest skin cancer. *Dtsch Arztebl Int.* 2014, 111: 389–395.
5. Keeney S, Mckenna H, Fleming P, et al. Attitudes, knowledge and behaviours with regard to skin cancer: a literature review. *Eur J Oncol Nurs.* 2009, 13: 29–35.
6. Sundling KE, Lowe AC. Circulating tumor cells: overview and opportunities in cytology. *Adv Anat Pathol.* 2019, 26: 56–63.
7. De Souza LM, Robertson BM, Robertson GP. Future of circulating tumor cells in the mela-

noma clinical and research laboratory settings. *Cancer Lett.* 2017, 392: 60–70.

8. Pachmann K, Willecke-Hochmuth R, Schneider K, et al. Circulating epithelial tumor cells as a prognostic tool for malignant melanoma. *Melanoma Res.* 2018, 28: 37–43.

9. Tang S, Thompson S, Smee R. Metastatic basal cell carcinoma: case series and review of the literature. *Australas J Dermatol.* 2017, 58: 40–43.

10. Marzuka AG, Book SE. Basal cell carcinoma: pathogenesis, epidemiology, clinical features, diagnosis, histopathology, and management. *Yale J Biol Med.* 2015, 88: 167–179.

11. Kolostova K, Spicka J, Matkowski R, et al. Isolation, primary culture, morphological and molecular characterization of circulating tumor cells in gynecological cancers. *Am J Transl Res.* 2015, 7: 1203–1213.

12. Siravegna G, Marsoni S, Siena S, et al. Integrating liquid biopsies into the management of cancer. *Nat Rev Clin Oncol.* 2017, 14: 531–548.

13. Paoletti C, Hayes DF. Circulating Tumor Cells. *Adv Exp Med Biol.* 2016, 882: 235–258.

14. Brouwer A, De Laere B, Peeters D, et al. Evaluation and consequences of heterogeneity in the circulating tumor cell compartment. *Oncotarget.* 2016, 7: 48625–48643.

Katerina Kiss, MD
 Průběžná 1826/63, 100 00 Prague 10
 Czech Republic
 e-mail: kiss.katerrina@gmail.com

Submitted: 04. 10. 2020
 Accepted: 27. 02. 2021

Pyoderma gangrenosum: a rare complication of reduction mammoplasty – a case report

M. Šíroká^{1,2}, K. Kiss^{2,3}, A. Fibír^{1,2}

¹Department of Plastic and Aesthetic Surgery and Burn Treatment, University Hospital Hradec Králové, Czech Republic

²Department of Surgery, Faculty of Medicine in Hradec Králové, Charles University, Prague, Czech Republic

³Department of Plastic Surgery, Third Faculty of Medicine, Charles University, Prague, Czech Republic

Summary

Background: Pyoderma gangrenosum (PG) is a rare non-infectious inflammatory disease of unknown etiology that affects the skin and mucous membranes. The occurrence of pyoderma gangrenosum after a reduction mammoplasty is a very rare complication, which at first glance may seem like an infectious complication; in reality, however, it is an inflammatory disease. **Case:** This case report describes a rare postoperative complication – pyoderma gangrenosum and its appropriate treatment in our patient who underwent reduction mammoplasty. **Conclusion:** Early detection of this complication is essential for the patient's recovery because the primary surgical treatment can lead to worsening of the condition and is therefore contraindicated in such a case. Pyoderma gangrenosum must be treated conservatively with corticosteroids.

Key words

pyoderma gangrenosum – pyoderma – reduction mammoplasty – complications

Šíroká M., Kiss K., Fibír A. Pyoderma gangrenosum: a rare complication of reduction mammoplasty – a case report. *Acta Chir Plast.* 2021, 63(2): 69–72.

Introduction

Pyoderma gangrenosum (PG) is a very rare inflammatory disease of unknown etiology that affects the skin and mucous membranes. Disruption of the function of polymorphonuclear cells, which accumulate in tissues after an infectious or traumatic stimulus and release proteolytic enzymes that damage the tissue, is considered [1]. Typically, pustules and red nodules, which disintegrate necrotically and turn into widespread and painful ulcerations, form on the lower limbs. The diagnosis of this disease is clinical (ulcerations, fever, pain); the patients have increased inflammatory markers – especially leukocytes and C-reactive protein and histological examination may show neutrophil infiltration. Bacterial wound infection is not found. A proper and timely diagnosis of this disease is essential for the success of the treatment. The treatment is predominantly conservative; in addition to symptomatic treatment, immunosuppressive treatment is indicated, especially

with corticosteroids and cyclosporine A, while azathioprine, sulfasalazine or biological treatment (infliximab) may also be used [2]. A person's medical history often mentions minor injuries, insect bites, etc., before the development of the sites. The occurrence of the disease at the site of the surgical wound early after the operation is described in even fewer cases. It is difficult to distinguish PG from postoperative infectious complications; however, this is absolutely essential for further treatment. It can be considered a mistake to start thinking about this disease only after several unsuccessful attempts to do necrectomy and resuture of the wound.

Case report

A 39-year-old woman underwent a reduction mammoplasty at our department in June 2019; the surgery was performed without complications, she was discharged on 2nd postoperative day with a problem-free local finding, i.e. surgical wounds healing *per primam*, with

out signs of inflammation, afebrile. From 5th postoperative day, the patient developed fever (up to 38.5 °C) and rapidly progressing ulcerations began to appear under the breast and in vertical suture line with purulent discharge without the areola being affected. During the first examination, purulent discharge was evacuated and broad-spectrum penicillin antibiotic amoxicillin + clavulanic acid (Amoksiklav®, Lek Pharmaceuticals d.d., Ljubljana, Slovenia) was administered empirically and a culture smear was collected with a repeatedly negative result. The patient was hospitalized again with a persistent febrile condition and deteriorating local finding; intravenous penicillin antibiotic piperacillin and beta-lactamase inhibitor (Piperacillin/Tazobactam®, Sandoz, Switzerland) were administered. PG was suspected for the atypical appearance of the defects, bilateral affection and a negative finding during culture (Fig. 1). Therefore, a tissue sample was taken from the edge of the defect for histology, which

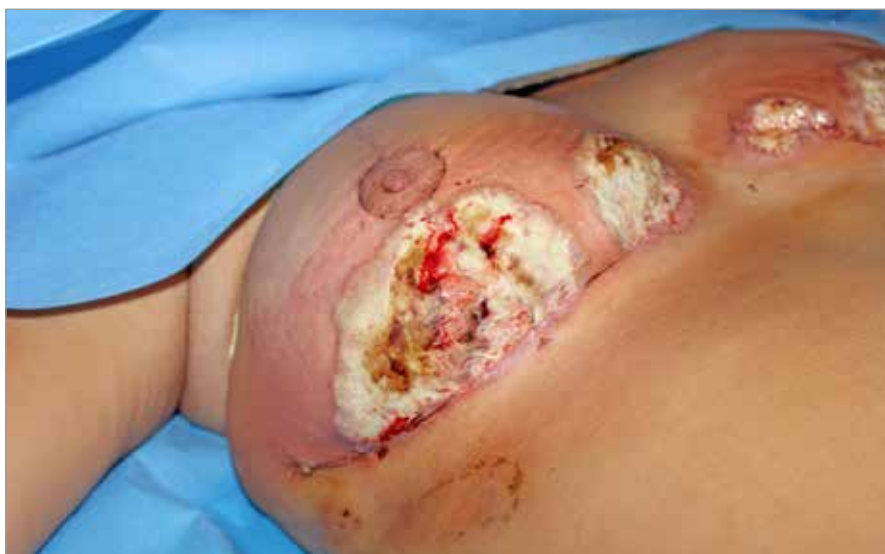

Fig. 1. Development of pyoderma gangrenosum on 10th postoperative day.

described numerous neutrophil infiltrations (Fig. 2).

After consultation with a dermatologist, methylprednisolone (Solu-Medrol®, Pfizer Manufacturing, Belgium) was administered intravenously at a dose of 120 mg/day for 6 days, followed by prednisone (Prednison®, Zentiva, Czech Republic) at a dose of 50 mg/day. The effect of corticosteroid therapy was obvious both clinically and from laboratory tests, with gradual reduction of inflammatory markers from the initial value of CRP 311 mg/L and leucocytes $35 \times 10^9/L$. Gradually, the necroses were demar-

cated and spontaneously separated (Fig. 3).

Antibiotics were used for 7 days only; prednisone was used as part of the corticosteroid therapy (Prednison®, Zentiva, Czech Republic) at a dose of 50 mg/day and continued for a total of 3 months with gradual reduction of the corticosteroid dose. At the same time, regular dressings of small defects of both breasts with antiseptic non-adhesive dressing made of tulle fabric and impregnated with white soft paraffin with an active broad-spectrum antiseptic component (Bactigras®, Smith & Nephew, Great Bri-

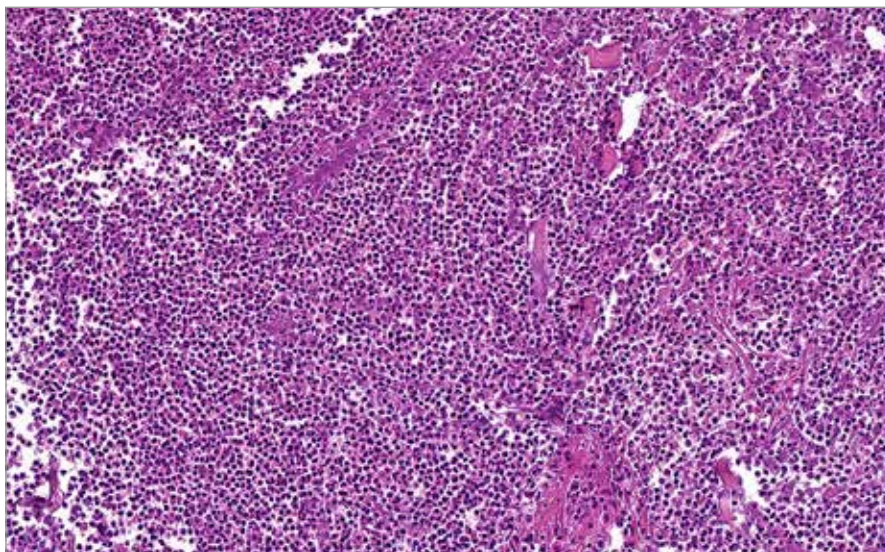


Fig. 2. Histological finding of numerous neutrophil infiltrations.

tain) were applied with following visible improvement of the defects (Fig. 4).

The patient fully healed approximately after 6 months; flat hypertrophic scars remained in the lower quadrants of the breasts (Fig. 5). During the treatment, the patient also underwent a professional immunological examination which ruled out the presence of a systemic disease that may be associated with the occurrence of PG [1].

Discussion

PG was first described by Brunsting et al. in 1930 as a rare skin disease of unknown etiology, which belongs to neutrophilic dermatoses [3]. PG is very rare as a complication following a surgery.

It mainly affects adults, most often between the ages of 25 and 54 years. It is more common in women [4]. The disease is rare in children under 15 years of age, in whom it accounts for only 4% of cases [5,6].

This condition is associated with a systemic disease in 50–70% of cases (rheumatoid arthritis, ulcerative colitis, Crohn's disease, hematological malignancies, endocrine disorders – e.g. with an underactive thyroid gland [7], autoimmune diseases, and pregnancy in 28% of cases) [8]. Rarely, the association of PG with immunoglobulin A or M monoclonal gammopathy, hepatitis C, Wegener's granulomatosis, systemic lupus erythematosus and also with human immunodeficiency virus (HIV) [9] has been reported. In about half of the cases, however, no such associated disease was detected in patients [2], which was the case of our patient as well. We verified this by retrospectively performed immunological examination of most commonly associated diseases. Postoperative PG has a lower association with systemic disease than other forms of PG.

The etiology of PG is unknown. Brunsting et al. hypothesized that skin ulcerations are associated with a systemic disease that reduces resistance of the immune system. The disorder is in both

humoral and cell-mediated immune responses [5,6]. In any case, PG is often associated with iatrogenic injury, which can be a vaccination, an injection, debridement or a surgery [6].

The average time from a surgery to the onset of the first symptoms of PG (febricity, pain, ulceration in the wound area) is reported to be approx. 6 days. Fever and leukocytosis occur in 55% and 43% patients with PG, respectively. In case of paired organ surgery, disease propagation is bilateral in 88% [10]. An interesting thing is that neither the nipple-areola complex (NAC) nor the deeper breast parenchyma is affected if breasts are affected [4,7,8]. In our patient, only the lower quadrants of the breasts without NAC were affected. The most frequently affected parts of the body in postoperative PG are the breasts and the abdomen [4], with the lower limbs and the torso affected by other forms of PG [5]. Powell and Collins described 4 different variants of PG – ulcerative, bullous, pustular and vegetative [3].

The diagnosis of PG is tricky, the disease is often initially confused and treated as a postoperative infectious complication. Therefore, the diagnosis is indirect and based on a clinical finding, a typical histological finding and a positive response to corticosteroids. Culture smears tend to be negative until the pustules ulcerate, when secondary infectious contamination of the wound may occur [5].

The treatment of the disease should be conservative while avoiding any early surgical intervention. The general therapy mainly includes corticosteroid treatment. Other immunosuppressive drugs such as cyclophosphamide, azathioprine or cyclosporine have been used in patients with a steroid-resistant form of PG [5]. Specific targeted treatment of PG with a recombinant human interleukin-1 receptor antagonist anakinra has been used in case of PAPA syndrome (pyogenic arthritis, pyoderma gangrenosum, acne) [11]. Anti-staphy-

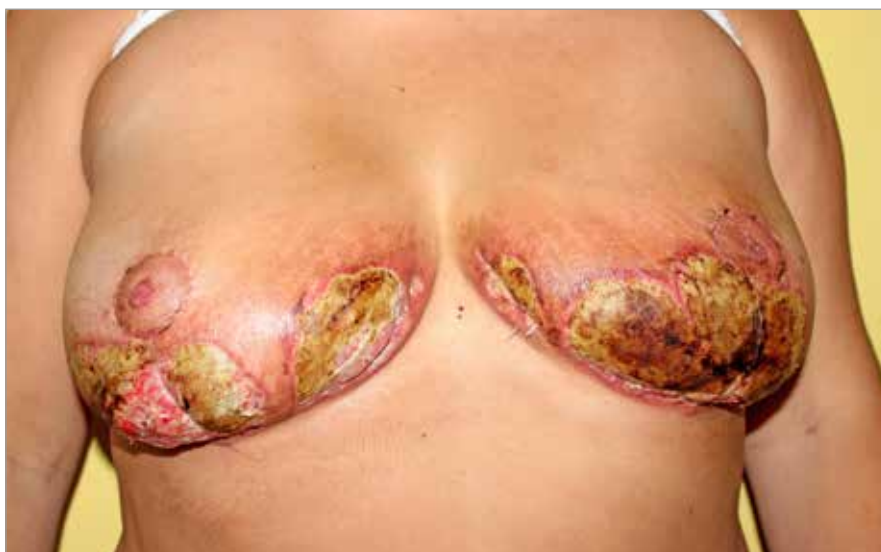

Fig. 3. Gradual demarcation of necrosis on 20th postoperative day.

lococcal antibiotics can only be added to the treatment to prevent superinfection [7]. Local therapy consists of regular dressings of the defects with their change; antibacterial ointments can be used. Furthermore, intravenous steroid injections have been described in patients where systemic corticosteroids have been contraindicated [5]. The use of vacuum therapy on the defects had a positive effect on tissue perfusion and reduced secretion [12]. Hyperbaric oxygen therapy also improved local findings and accelerated healing [5]. It has

been used, for example, to stabilize defects before skin autotransplantation [13]. As stated above, no surgery (debridement, skin grafts, flap plastic surgery) should be used in the active phase of PG disease. Covering the defects with a skin graft can be successful after several weeks of the treatment with corticosteroids at the earliest, when the disease is in a latent phase [5].

In our patient, it was favorable for us to proceed conservatively, avoiding any surgery, and after consultation with

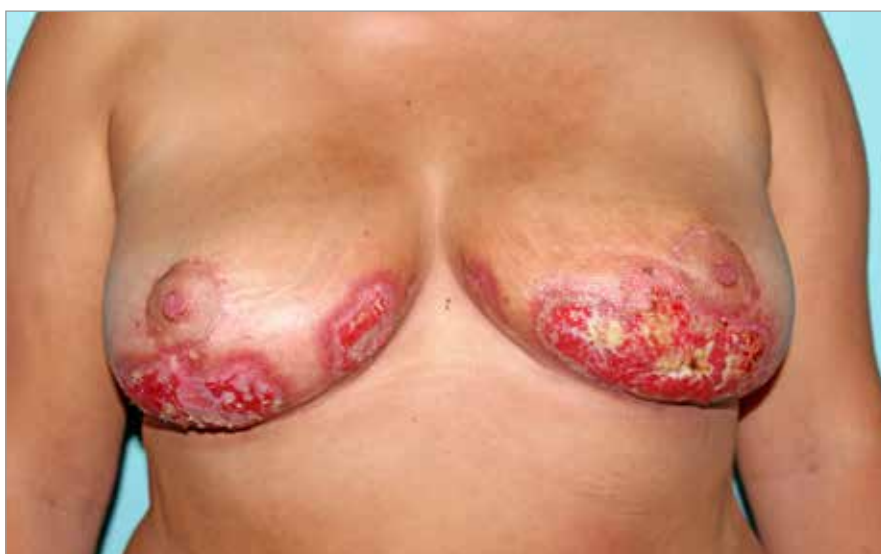

Fig. 4. Condition after separation of necrosis during conservative therapy (42nd postoperative day).

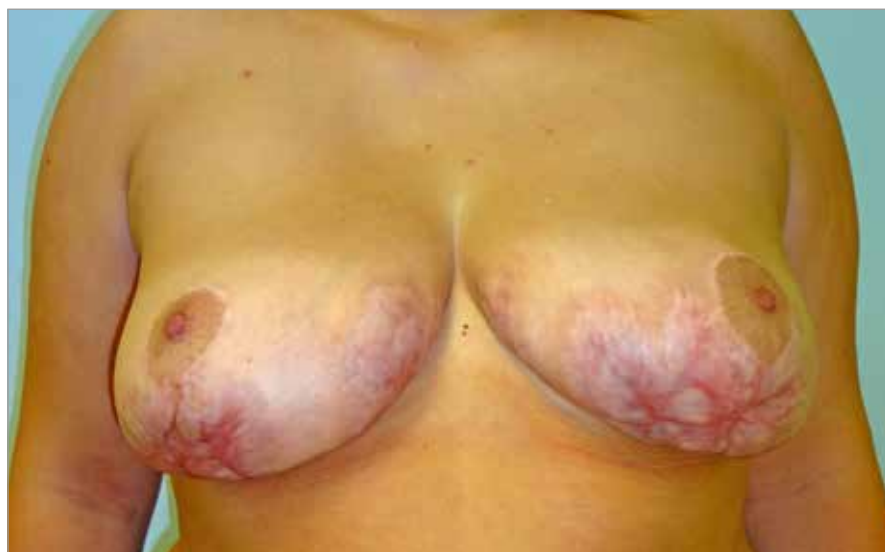

Fig. 5. Condition following full healing after 6 months from the operation.

a dermatologist, to start the treatment with corticosteroids.

Conclusion

In addition to bleeding, early complications of reduction mammoplasty include wound healing disorders or the necrosis of flaps or breast tissue. The treatment is usually surgical (necrectomy, resuture, etc.). However, surgical treatment is contraindicated in case of PG, as it may worsen further course of the disease. Although it is a rare complication after surgery, it is necessary to be aware of it and include it in a broader differential diagnosis. The diagnosis is indirectly based on clinical appearance, a positive response to corticosteroid therapy and also on any histological findings. In addition to early immunosuppressive treatment, it is crucial to avoid early surgical intervention in the area of the defect, which can significantly worsen the course and extent of the disease, inclu-

ding the formation of difficult to reconstruct permanent consequences.

Ethical approval: All procedures performed in the case study involving human participant were in accordance with the ethical standards of the institutional research committee and with the Helsinki declaration from 1975 and its later amendments or comparable ethical standards.

Roles of authors: All authors contributed equally to preparing the manuscript.

Conflict of interests: The authors state that they have no potential conflicts of interest regarding the drugs, products or services mentioned in the case report.

References

1. Petrášová D. Pyoderma gangrenosum. *Dermatologie pro praxi*. 2013, 7:134–135.
2. Krajčová H., Machovcová A. Sekundární pyoderma gangrenosum v kazuistikách. *Dermatologie pro praxi*. 2013, 7: 29–32.
3. Momeni A., Satterwhite T., Eggleston M. Post-surgical pyoderma gangrenosum after autologous breast reconstruction. *Ann Plast Surg*. 2015, 74: 284–288.
4. Tolkachjov SN., Fahy AS., Cerci FB., et al. Post-operative pyoderma gangrenosum: a clinical re-

view of published cases. *Mayo Clinic Proc*. 2016, 91: 1267–1279.

5. Huish SB., de la Paz EM., Ellis PR., et al. Pyoderma gangrenosum of the hand: a case series and review of the literature. *J Hand Surg Am*. 2001, 26: 679–685.

6. Keskin M., Tosun Z., Ucar C., et al. Pyoderma gangrenosum in a battered child. *Ann Plast Surg*. 2006, 57: 228–230.

7. Lifchez SD., Larson DL. Pyoderma gangrenosum after reduction mammoplasty in an otherwise healthy patient. *Ann Plast Surg*. 2002, 49: 410–413.

8. Larcher L., Schwaiger K., Eisendle K., et al. Aesthetic breast augmentation mastopexy followed by postsurgical pyoderma gangrenosum (PSPG): clinic, treatment, and review of the literature. *Aesthetic Plast Surg*. 2015, 39: 506–513.

9. Kaddoura IL., Amm Ch. A rationale for adjuvant surgical intervention in pyoderma gangrenosum. *Ann Plast Surg*. 2001, 46: 23–28.

10. Tuffaha SH., Sarhane KA., Mundinger GS., et al. Pyoderma gangrenosum after breast surgery. *Ann Plast Surg*. 2016, 77: 39–44.

11. Brenner M., et al. Targeted treatment of pyoderma gangrenosum in PAPA (pyogenic arthritis, pyoderma gangrenosum and acne) syndrome with the recombinant human interleukin-1 receptor antagonist anakinra. *Br J Dermatol*. 2009, 161: 1199–1201.

12. Soncini JA., Salles AG., Neto JA., et al. Successful treatment of pyoderma gangrenosum after augmentation mastopexy using vacuum therapy. *Plast Reconstructive Surg Glob Open*. 2016, 4: 1–6.

13. Zakhireh M., Rockwell B., Fryer RH. Stabilization of pyoderma gangrenosum ulcer with oral cyclosporine prior to skin grafting. *Plast Reconstr Surg*. 2004, 113: 1417–1420.

Michaela Široká, MD

Department of Plastic and Aesthetic Surgery and Burn Treatment

University Hospital Hradec Králové

Sokolská 581, 500 05 Hradec Králové,

Czech Republic

e-mail: michaela.siroka@fnhk.cz

Submitted: 06. 02. 2021

Accepted: 03. 04. 2021

Negative pressure therapy in the orofacial region in oncological patients – two case reports

J. Belobradová¹, O. Res¹, J. Stránský¹, Z. Čermáková², T. Blažek², P. Hurník^{3,4}, J. Štembírek^{1,5}

¹ Department of Oral and Maxillofacial Surgery, University Hospital Ostrava

² Department of Oncology, University Hospital Ostrava

³ Department of Pathology, University Hospital Ostrava

⁴ Department of Pathology, Faculty of Medicine, University of Ostrava

⁵ Laboratory of Molecular Morphogenesis, Institute of Animal Physiology and Genetics, Czech Academy of Sciences

Summary

Background: Chronic wounds and their problematic healing is a widely discussed topic in all branches of medicine. In recent years, vacuum therapy appears to be a very successful non-invasive method supporting the healing of these wounds. The aim of this paper is to demonstrate the possibility of utilizing a vacuum system in the orofacial area where other conservative and surgical procedures have failed. **Cases:** The case reports demonstrate the use of vacuum therapy in non-healing postoperative wounds in cancer patients. **Conclusion:** Vacuum therapy has limited use in the orofacial area, but based on our experience, we can conclude that it has a very positive effect on the healing of chronic wounds. Thanks to this treatment, it was possible to reduce the frequency of dressings and significantly shorten the length of hospital stay. Despite these advantages, however, it is necessary to adhere to the conditions for the application of vacuum treatment.

Key words

negative pressure therapy – chronic wound – orofacial region – squamous cell carcinoma

Belobradová J., Res O., Stránský J., et al. Negative pressure therapy in the orofacial region in oncological patients – two case reports. *Acta Chir Plast.* 2021, 63(2): 73–77.

Introduction

Negative pressure therapy (also known as vacuum therapy) is a non-invasive method used for the treatment of non-healing wounds through the application of subatmospheric pressure combined with the removal of excessive exudate [1]. The negative pressure causes macro- and microdeformations of the wound and facilitates the removal of excess fluids, which, in combination, causes the change of the wound environment. *Macrodeformation* is a term used to describe the reduction of the wound surface arising as a result of the forces acting on the wound surface through the foam (or other suitable material) which shrinks due to the applied suction [2]. *Macrodeformation* is influenced by the size of the wound and the type of the contact material, especially its specific

density or texture. The ideal value supporting the formation of the granulation tissue is 125 mmHg [3]. The term *microdeformation* describes the reaction of the tissues on the microscopic level where the mechanical cell deformation triggers signalling cascades initiating cell migration and proliferation, which contributes towards wound healing [4]. The tension induced by the vacuum affects the cell cytoskeleton and the differentiation of fibroblasts (preferentially to myofibroblasts) and, in effect, production of collagen and other components of the extracellular matrix [3]. Removal of the liquids from the wound leads to the reduction of swelling and of capillary compression, thus improving tissue perfusion. At the same time, drainage of the exudate removes inflammatory cytokines, leukocytes and, possibly, bac-

teria (although there has been no clear evidence on reducing the bacterial contamination of the wound so far) [2]. Increased infiltration of the wound floor by neutrophils when applying negative pressure therapy has been reported [3].

The negative pressure system consists of a vacuum pump, fluid receptacle, drainage tubing, occlusive dressing responsible for maintaining the vacuum, and the contact dressing itself, usually made of a polyurethane or polyvinyl alcohol foam, sometimes antiseptic gauze. The dressing is applied under aseptic condition, the wound must be thoroughly cleaned and its vicinity must be prepared in a way ensuring that the occlusive dressing does not fail. From the foam or another contact material, a suitable shape is cut out; the size must be sufficient to cover the entire wound

floor. Then, the occlusive dressing is applied (at least 5 cm around the wound), containing a hole in the middle through which a suction tube is inserted and the joint is sealed. The tubing is connected to the vacuum pump through the receptacle; after turning on the pump, the foam contracts [5].

The most common applications for vacuum therapy include treatment of dehisced wounds, skin-loss injuries, burns, ulceration, or, sometimes, covering dermo-epidermal grafts. Contraindications of the application of vacuum therapy can be divided into absolute and relative. Absolute contraindications include the presence of a tumour or necrotic tissue on the wound floor and active bleeding. Relative contraindications include untreated osteomyelitis, the presence of the neurovascular bundle or a parenchymatic/hollow organ on the wound floor, conditions with a high risk of bleeding and patient's non-compliance [3].

Although negative pressure therapy has been used in the treatment of wounds in the orofacial region relatively rarely so far, it can be used in certain conditions, such as in the treatment of inflammations in the vicinity of the jaws. It could also significantly contribute towards healing acceleration and towards the improvement of the quality of life of patients with extensive defects of the soft tissues in the orofacial region [6].

In this paper, we would like to present two cases of oncological patients in whom negative pressure therapy was successfully used.

Case reports

Patient 1

A 65-year-old male with spinocellular carcinoma T3N2bM0 (T – primary tumor, N – regional lymph nodes, M – metastasis) in the retromolar region of the right lower jaw was admitted to our department for planned surgery in October 2019. His comorbidities included lower extremity arterial disease, hypertension,

the homozygous form of the Leiden mutation and history of gastroduodenal ulceration. The patient smokes approx. 15 cigarettes a day, alcohol consumption is occasional only.

After admission, percutaneous endoscopic gastrostomy (PEG) was performed. The following day, he underwent a radical neck dissection of lymph nodes from level I–IV, tooth extraction from both the upper and lower jaws and tumour excision with mandibular resection with the interruption of mandibular continuity. Histological examination revealed intact resection margins without marks of angioinvasion or perineural spread. The surgery itself was without complications, with blood loss < 750 mL, under an antibiotic cover. After the surgery, the patient was observed at an Intensive Care Unit (ICU) and the following day transferred to our Department of Oral and Maxillofacial Surgery in a stabilized condition. The wounds were treated with Betadine solution and sterile dressing was changed daily; in the mouth, 3% hydrogen peroxide was used. Antibiotic therapy continued. The patient rinsed the mouth 3-times a day with 0.12% chlorhexidine and was advised to perform meticulous dental hygiene. The nutrition was originally administered only via PEG, later also orally; everything was consulted with a nutritional therapist.

On Day 7 after the surgery, a small dehiscence developed in the mouth and serous liquid started to leak submandibularly between stitches. On the next day, the dehiscence was intraorally re-sutured and a compression dressing was applied externally. However, as the wound dehiscence reappeared again and the exudation continued, swabs were taken for bacteriological examination. Based on the results of cultivation and consultation with the antibiotic centre, Augmentin was replaced with a combination of metronidazole and ciprofloxacin. Despite this change in antibiotic therapy, the wound dehiscence continued,

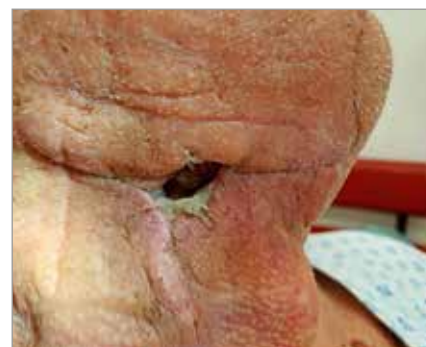

Fig. 1. Non-healing wound in right submandibular region of 1st patient before starting vacuum therapy.

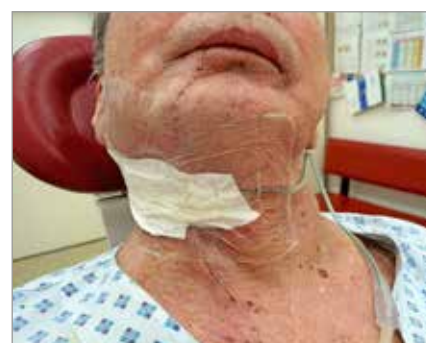

Fig. 2. Demonstration of functional vacuum therapy in 1st patient.

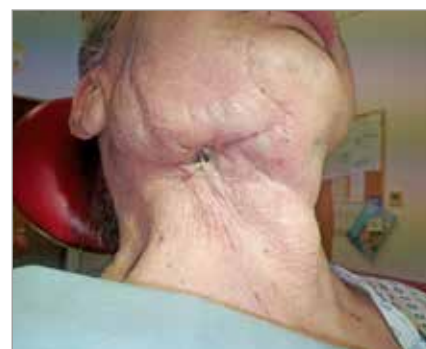

Fig. 3. Significant size reduction of the wound in 1st patient after 10 days of vacuum therapy.

which resulted in the development of an orostoma. Hence, on Day 24 after the surgery, a wound revision under general anesthesia from the original cutaneous side was performed. The margins of the orostoma were excised and the mesial mandibular stump protruding into the wound was resected. The defect was then covered with a flap from the anterior belly of the digastric and sterno-

cleidomastoid muscles and soft tissues were sutured in layers. The tissue samples for both bacteriological and histological examinations were taken.

On Day 3 after the second surgery, the wound began to disintegrate again, forming a dehiscence of approx. 3.5 cm with a mucous exudate; the wound, however, did not communicate to the oral cavity any more (Fig. 1). Following another consultation with the antibiotic centre, another medication change was made. The wound was externally bathed with Actimaris solution followed by the application of Actimaris gel; 3% hydrogen peroxide and 0.12% chlorhexidine were used for rinsing and bathing the wound from the side of the oral cavity. The wound floor began slowly to granulate. At that time, we decided to apply vacuum therapy with a 2-day interval of dressing change. As our department does not possess a suitable vacuum pump, a Redon drain was used for achieving negative pressure (Fig. 2).

After 10 days of negative pressure therapy, the wound was significantly smaller and the patient was discharged from the hospital with instructions to continue local treatment with Actimaris solution and gel (Fig. 3). Within one month, the wound fully healed. After this healing, the patient underwent adjuvant cancer therapy. The follow-up in November 2020 (i.e., approx. 1 year after the primary surgery) did not reveal any clinical signs of recurrence of the tumour.

Patient 2

A 57-year-old male patient was treated at the ENT Department with a quadruple malignancy in the region of the oral cavity and oropharynx. In October 2017, he underwent excision of the spinocellular carcinoma from the oral floor and tonsillogingual sulcus (left-sided) with a radical neck dissection on the same side followed by adjuvant radiotherapy that was completed in February 2018. The personal history included hypertension,

post-radiation hypothyreosis, chronic obstructive pulmonary disease and neuropathy of lower extremities. The patient does not drink alcohol and smokes 3 cigarettes a day. He was admitted to the Department of Maxillofacial Surgery due to a left-sided osteoradionecrosis of the lower jaw for elective necrectomy and lower jaw resection with interruption of mandibular continuity.

Under general anaesthesia and antibiotic cover, the excision of the left-sided submandibular extraoral fistula, extraction of teeth 21–12 and, subsequently, left-sided mandibular resection with continuity interruption in the extent of –34567. The bone stumps were cleaned to the macroscopically healthy bone and fixed to the surrounding tissue. The soft tissues were hermetically sutured in layers. Samples for histopathological and bacteriological examinations were collected during the surgery. The surgery was without complications. A nasogastric tube was introduced after the surgery and the patient was (repeatedly over the next few weeks) examined by a nutritional therapist.

Since Day 1 after the surgery, the patient kept rinsing his mouth with 0.12% solution of chlorhexidine 3-times a day, the wounds were locally disinfected during everyday dressing changes and ATB treatment (Augmentin) continued. Despite this, an intraoral dehiscence appeared on Day 3, followed by a leak of serosanguinolent fluid. After consulting the antibiotics centre, ciprofloxacin was added into the medication on Day 4. On Day 5, however, even extraoral wound disintegration occurred; 2 days later, the dehiscence size was 4 × 2 cm and communicated to the oral cavity. A swab for further bacteriological examination was taken, the frequency of dressing changes with debridement was increased to twice a day.

Following another consultation with the ATB centre, vancomycin was added into the therapy; 5 days later, however, it had to be discontinued due to increas-

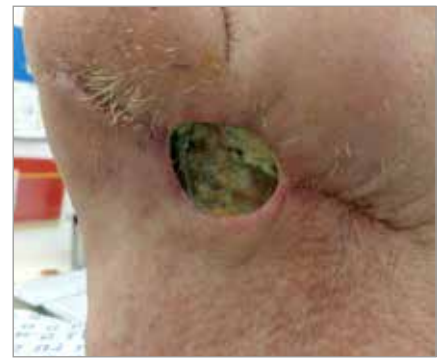

Fig. 4. Wound in the left submandibular region of 1st patient before starting vacuum therapy; relatively extensive dehiscence is visible.

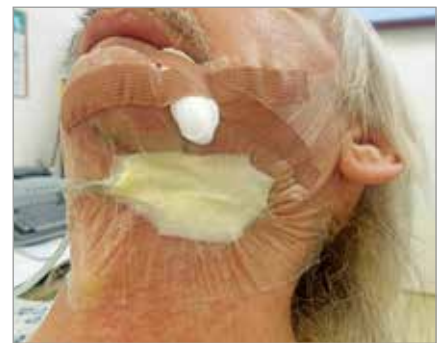

Fig. 5. Demonstration of vacuum therapy in 2nd patient.

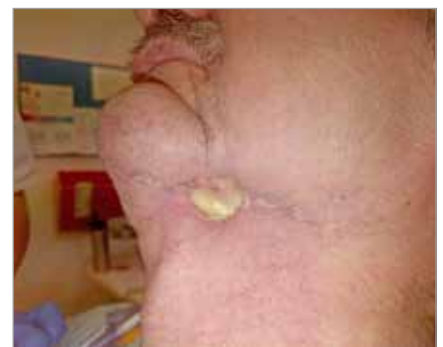

Fig. 6. Significant size reduction of the wound in 2nd patient after 8 days of vacuum therapy.

ing creatinine levels. On Day 20, the patient was transferred to the ICU as a result of acute renal failure; at about the same time, the wound in the oral cavity began to close. During his stay at ICU, the external application of Iodine gel was combined with intraoral Actimaris gel application.

After overall stabilization of the patient, he was transferred back to the standard ward. At that point, the dehiscence of approx. 4×2 cm persisted but it did not communicate with the oral cavity any more (Fig. 4). This facilitated the application of the vacuum system, again in a modification with a Redon drain (Fig. 5). The dressings were changed every 2 days for a period of 8 days, after which the wound length decreased to approx. 2 cm only (Fig. 6). The patient was subsequently transferred to a hospital nearer to his place of living (his lab results were still not normal enough for his discharge to a home care). The vacuum therapy was discontinued at the local hospital; the wound was, however, treated with standard means. After his discharge from the hospital, the patient was followed-up on an outpatient basis. The insufficient home wound care resulted in prolonged healing but eventually, the wound healed with a scar. Approx. 5 months later, another spinocellular carcinoma developed on the lateral and ventral side of the tongue (T1-2N0M0), which was surgically removed with histologically confirmed carcinoma-free resection margins. At present, the patient is in a home care.

Discussion

Wound healing is a complicated process consisting of a complex interaction of various inflammatory cells, chemokines, cytokines, molecules, and nutrients. These processes comprise four stages of wound healing, namely hemostasis, inflammation, proliferation and remodeling. Disruption of this cascade leads to the development of chronic non-healing wounds [7].

Such wounds are often infected, a permanent inflammatory infiltrate is present, re-epithelization is disrupted and the wound fills with granulation tissue. This tissue is of poor quality, with low fibroblast infiltration and increased levels of matrix metalloproteinases (MMP) and cytokines [8]. MMPs are en-

zymes involved in the degradation of the extracellular matrix during wound healing. The presence of pro-inflammatory cytokines, such as interleukin-1-alfa (IL-1 α), epidermal growth factor (EGF), platelet derived growth factor (PDGF) and tumor necrosis factor- α (TNF- α) increases the MMP production. TNF- α (cachectin), predominantly produced by macrophages, plays an important role in wound healing. Excessive synthesis of TNF- α (and, therefore, of MMP) can cause healing disturbances leading to the development of a chronic wound or other inflammatory diseases [9].

Many factors, both internal and external, play a role in wound healing. Among others, this includes factors affecting blood supply, immune functions, metabolic diseases, drug use or previous tissue damage (e.g. by radiotherapy). Stable pressure, temperature and humidity are also important factors [7].

As wound healing is an energetically demanding process, the role of nutrition must not be underestimated. In malnourished patients, increased nutrition supply or use of food supplements with high energy and protein values are needed [10].

As already mentioned, vacuum therapy reduces the wound size and can also positively influence the amount and the quality of granulation tissue. It is instrumental in reducing the extent of edema and amount of pro-inflammatory mediators (including MMP) through draining the exudate, which is another mechanism of how this technique can positively affect the wound environment and, in effect, contribute to better healing.

In the field of maxillofacial surgery, negative pressure therapy is relatively rarely used, in particular, because of the difficulty of achieving sufficient sealing of the wound caused by the complex anatomy of the head and neck, as well as by the fact that wounds usually heal relatively well in this area [11].

Conclusion

The options for the use of negative pressure therapy in the orofacial region are limited and, moreover, debatable in oncological patients. Our experience, however, indicates a very positive influence of such therapy on the healing of chronic wounds, despite the fact that our experience is based on the use of an improvised vacuum therapy solution (in the Czech Republic, negative pressure therapy systems Vivano[®]Tec, PICO[®] or AVELLE[®] are available on the market).

A complex approach towards the patients with chronic wounds in the area of head and neck is necessary and suitable nutrition should not be underestimated as such patients often suffer from malignant tumours or extensive inflammatory processes and their organisms are often exhausted by both the disease itself and its therapy. Healing is often problematic in such patients, often negatively influenced by radiotherapy and hence, even a notable reduction of the wound can be considered as success in these cases.

Grant support: This paper was supported by the grant AZV/009830/2019 of the Ministry of Health of the Czech Republic and the Institutional Support RVO-FNOs/2018 and SGS14/LF OU/2017-2018.

Disclosure: This manuscript has not been published and is not under consideration for publication elsewhere. We have no conflicts of interest to disclose. All procedures performed in this study involving human participants were in accordance with ethical standards of the institutional and/or national research committee and with the Helsinki declaration and its later amendments or comparable ethical standards.

Roles of authors: Julia Belobradová: review of literature, patient treatment, manuscript writing. Oldřich Res: final manuscript approval, patient treatment. Jiří Stránský: final manuscript approval, patient treatment. Zuzana Čermáková Zdeňková: final manuscript approval, patient treatment. Tomáš Blažek: final manuscript approval, patient treatment. Pavel Hurník: final manuscript approval, patient treatment. Jan Štembárek: manuscript writing, final manuscript approval, patient treatment.

References

1. Šimonová D. Kontrolovaný podtlak při komplikovaném hojení operační rány – kazuistika. *Onkologie*. 2016, 10: 238–242.
2. Huang C., Leavitt T., Bayer LR., et al. Effect of negative pressure wound therapy on wound healing. *Curr Probl Surg*. 2014, 51: 301–31.

3. Šimek M., Bém R., et al. *Podtlaková léčba ran*. Praha: Maxdorf 2013, 10–24.
4. Wiegand C., White R. Microdeformation in wound healing. *Wound Rep. and Regen.* 2013, 21: 793–799.
5. Hanousková J. Převoz rány za použití V. A. C. systému. *Urolog. pro Praxi.* 2009, 10: 247–248.
6. Pink R., Šimek M., Michl P., et al. Využití negativního tlaku v léčbě zánětů orofaciální oblasti. *Čes. stomatol. / Prakt. zubní lék.* 2013, 113: 74–79.
7. Han G., Ceilley R. Chronic wound healing: a review of current management and treatments. *Adv Ther.* 2017, 34: 599–610.
8. Martin P., Nunan R. Cellular and molecular mechanisms of repair in acute and chronic wound healing. *Br J Dermatol.* 2015, 173: 370–378.
9. Franková J., Pivodová V., Ulrichová J. Porovnání vlivu Traumacelu Biodressu, vlhké terapie a klasické terapie na produkci matrixových metaloproteináz a TNF- α (pilotní studie). *Hojení ran.* 2011, 1: 6–9.
10. Dryden SV., Shoemaker WG., Kim JH. Wound management and nutrition for optimal wound healing. *Atlas Oral Maxillofac Surg Clin North Am.* 2013, 21: 37–47.
11. Mellott AJ., Zamierowski DS., Andrews BT. Negative pressure wound therapy in maxillofacial applications. *Dent J.* 2016, 4: 30.

Jan Štembírek, MD et MD, PhD
Department of Oral and Maxillofacial
Surgery
University Hospital Ostrava
17. listopadu 1790/5, 708 52 Ostrava
Czech Republic
e-mail: jan.stembirek@fno.cz

Submitted: 20. 11. 2020

Accepted: 06. 02. 2021

Thirty-five years of the Department of Plastic Surgery and Burns Treatment at the University Hospital in Hradec Králové

L. Klein

Department of Plastic Surgery and Burns Treatment, Medical Faculty and University Hospital, Charles University, Hradec Králové, Czech Republic

Summary

Background: The Department of Plastic Surgery and Burns Treatment was established as a part of the newly created 2nd Department of Surgery of Charles University, Medical Faculty and the University Hospital in Hradec Králové in 1985. Through modest beginnings, activities of the Department expanded up to full coverage of specialized care in plastic surgery within the region with almost one million inhabitants.

Aim: In this article, the most important events of several historical phases related to almost four decades are described. The aspects of medical personnel, technological and space equipment are especially emphasized. The Department has always been working on the principles of interdisciplinary cooperation within the department itself and other departments within the hospital as well. Over the past 35 years, the Department of Plastic Surgery and Burns Treatment has been firmly entrenched in the spectrum of specialized activities of the University Hospital in Hradec Králové.

Key words

plastic surgery – burns treatment – establishment of the department – historical phases – complex specialized care – Hradec Králové

Klein L. Thirty-five years of the Department of Plastic Surgery and Burns Treatment at the University Hospital in Hradec Králové. *Acta Chir Plast.* 2021, 63(2): 78–82.

Introduction

The development of plastic surgery and burns treatment is relatively well documented in the Czech Republic; however, predominantly in close connection with the two most significant and leading units – the Departments of Plastic Surgery in Prague [1–5] and Brno [6–9]. Activities of other institutions are only rarely mentioned [10–14], even though they undoubtedly belong to the mosaic of specialized care in plastic surgery. Together, they create a network ensuring medical and preventive care in the field of plastic surgery in our country. We would like to contribute to the mosaic with this article written on the occasion of the 35th anniversary of our Department's establishment.

Plastic surgery at the University Hospital Hradec Králové before 1985

Specialized medical-preventive care in the field of plastic surgery at the Depart-

ment of Surgery of the then Regional Institute of National Health and the University Hospital of the Medical Faculty of Charles University was provided by Dr Karel Dlabal, originally a member of the Department of Military Surgery (KVCH) of the Purkinje Military Medical Academy (VLA JEP). He was trained at the Department of Plastic surgery by the academician Burian in Prague in the years 1964–1967. From 1967, he served as a clinical ordinary and a regional ordinary for plastic surgery of the East Bohemian region. Plastic surgery patients were hospitalized mainly at the ward in Nechanice hospital, where everyone commuted daily by a special hospital line. Dr Dlabal often performed surgeries in almost all district hospitals in the region as well. Over 13 years, he performed several thousands of operations. Professionally, he was predominantly interested in hand surgery, and he became a top expert in this field. In 1980, Dr Dlabal was appointed the chief phy-

sician in the specialized Institute of Plastic and Reconstructive Hand Surgery in Vysoké nad Jizerou on the recommendation of Prof. Karfik. His successor in providing care in the field of plastic surgery at the Department of Surgery became Maj. Dr Ľudovít Pintér, also a member of KVCH VLA JEP. He became a clinical ordinary for plastic surgery in 1982.

The historical context of the establishment of the Department of Plastic Surgery and Burns Treatment

During the 1970s and early 1980s, the dynamic development of individual surgical specialties and the related construction of a new surgical pavilion contributed to the preparations for the division of the existing Department of General Surgery. The three new units were intended to provide medical-preventive care, teaching, and research in individual fields according to their specializations. A modern pavilion was

opened on 1 June 1985, and three newly established departments began their operations. The 2nd Department of Surgery (head: Col. Prof. Dr B. Konečný, CSc.) focused on general surgery, trauma and plastic surgery and treatment of burns. The department also became the clinical basis of KVCH VLA JEP. The Department of Plastic Surgery and Burns Treatment was opened on 1 September 1985.

The 1985–1994 phase

The ward consisted of nine triple and three single rooms, all with their own bathroom. The Department could use 18 beds, burn patients usually occupied single rooms. The operating-and-dressing tract with two operating rooms and a dressing room formed an integral part of the Department. There was also a spacious room intended for rehabilitation exercises. Three physicians in pre-certification training in plastic surgery worked at the Department at that time: Dr Jiří Vosmík, Maj. Dr Leo Klein and Dr Zdeňka Talábová. The Senior Assistant and Ordinary for Plastic Surgery – Dr L. Pintér – joined the Department on 1 January 1986 (Tab. 1). The beginnings of our activities were really challenging because we did not have any unique instrumentation and material equipment, except for two Humby skin grafting knives. The so-called skin graft meshing procedure used for skin transplantation was performed manually; the skin grafts were perforated with a scalpel while lying on cellophane or plastic foils. Thus, when

we obtained the first roller dermatome, we really celebrated the occasion. Over time, however, we managed to supplement the operating instruments and expand the instrumentation with an electrodermatome, Watson's knives, etc. For training purposes, we were able to obtain an operating microscope used in the vivarium of the VLA JEP. Since 1993, we had an opportunity to use a special air-fluidized bed for the treatment of burns. We had blocked two surgical days for operations under general anaesthesia during the week, operations under local anaesthesia took place in the remaining days, and outpatient activities were concentrated to one day (Friday). The "as we go" general schooling of nurses and their training in the specialized treatment and nursing care of especially burn patients, patients after transplantations, flap surgeries etc., formed an integral part of building the ward. It should be noted that all nurses and other medical personnel of the ward welcomed such activities with interest and actively embraced the possibility of deepening their knowledge and skills. Since the beginning, the Department has provided medical and preventive care in a wide range of its specialization – surgical treatment of skin tumours, hand and face traumas, some congenital deformities, and reconstruction of defects provided for other surgical departments within the UH, especially in co-operation with trauma surgeons. We started to conduct operations using various types

of the so-called flap surgeries. We also performed corrections of cosmetic defects to some extent. The principles of comprehensive continuous care of burn patients were implemented in the field of burns treatment. The application of the early necrectomy method and temporary biological skin covers was introduced. Moreover, a permanent anesthesiologist joined our Department. We have closely co-operated with the Tissue Bank, Department of Metabolic Care and Gerontology, Institute of Microbiology and some others; thus, a functional interdisciplinary burns team has been established. The spectrum and numbers of patients gradually expanded. In the late 1980s and early 1990s, our Department served as a regional burns unit of the then East Bohemian Region. The department physicians were also involved in teaching, publishing activities and scientific research. Two physicians defended their dissertation theses (Dr Pintér in 1991, Dr Klein in 1994). During this phase, Dr Vosmík left our Department and joined the Department of Plastic Surgery in Prague – Vinohrady on 1 September 1988. Dr Martin Šorma became a member of our Department on 1 January 1990.

The 1995–1998 phase

It was by far the most difficult and challenging phase in the history of the Department. After the November Revolution in 1989, fundamental political, economic, and societal changes took

Tab. 1. Chief physicians of the Department of Plastic Surgery and Burns Treatment.

| | Name | From | To | Note |
|------------------|----------------------------------|------------|-------------|-----------------------------|
| senior assistant | Ľudovít Pintér, MD, CSc. | 1 Jan 1986 | 28 Feb 1995 | |
| senior assistant | Assoc. Prof. Leo Klein, MD, CSc. | 1 Mar 1995 | 31 Dec 1998 | |
| | Zdeňka Talábová, MD | 1 Jan 1999 | 31 Aug 2004 | appointed by the management |
| | Robert Čáp, MD, PhD | 1 Sep 2004 | 31 Mar 2008 | appointed by the management |
| head | Assoc. Prof. Leo Klein, MD, CSc. | 1 Apr 2008 | 31 Aug 2014 | |
| head | Aleš Fibír, MD, PhD | 1 Sep 2014 | until now | |

place in the country, which, of course, affected the health care, too. Since 1990, there was, once again, only one Department of Surgery under the leadership of Assoc. Prof. Dr J. Bedrna, CSc. The Department was created by merging the two previous units. The general enthusiasm and pursuit of free enterprise, which manifested in many spheres in the early 1990s, along with a change in societal values, encouraged physicians and other professionals, who had worked until then in a unified centrally managed healthcare system, to start providing their services in a way based on other principles. The field of plastic surgery was particularly affected by these changes significantly, and the changes also influenced our Department. On 1 March 1995, Dr Pintér, Dr Talábová and Dr Šorma left the Department for the private sphere and joined the newly established facility of the First Private Surgical Centre (SANUS) in Hradec Králové. Along with them, several experienced nurses left the ward and the operating theatre part of the Department. Thus, only one certified plastic surgeon, Lt. Col. Dr Klein remained at the Department. Nevertheless, surgeries, outpatient activities, teaching and scientific work continued to a certain level. The Department's daily operation was enabled only thanks to a maximal effort and personal commitment, regardless of the time and energy spent. For example, non-acute medical counselling at other departments were carried out on the weekends. The outpatient clinic operated even after official working hours, after the student lectures, etc. In 1995, young physicians Maj. Dr František Hošek (1 January) and Dr Vladimír Janeček (1 May) joined the team. The operation team stabilized, and the Department fully provided specialized care in the region covered by the UH. We also found the time for additional professional activities, as we organized scientific conferences of burns medicine with international participation in 1995 and 1997. Scientific re-

search also continued, and its results formed the basis of successful habilitation (Dr Klein 1998). Moreover, after getting real experience with activities in the private sector, Dr Talábová asked the UH management if she could return and join the team, once again, on 1 June 1996. Therefore, the Department employed four physicians (two certified and two physicians preparing for their certifications). The Department, thus, successfully overcame a critical period of a year and a half, despite the initially expressed fears (even on the part of the management) that the Department would probably cease to exist.

The 1999–2007 phase

Brig. Gen. Assoc. Prof. Klein has temporarily left the Department, on 1 January 1999, and was sent on a mission abroad. In 1999–2002, he served as Medical Advisor to the Supreme Commander, and Chief of the Medical Department of NATO Supreme Headquarters Allied Powers in Europe (SHAPE). When the foreign mission was concluded, he held the position of Surgeon General of the Czech Armed Forces. After leaving for the reserve, in 2004–2008, he was appointed the Head of the Department of Burns Medicine of the 3rd Medical Faculty, Charles University and the UH Královské Vinohrady in Prague.

The management of the Department was entrusted to Dr Talábová, who continued to ensure its smooth running. In co-operation with pediatric surgeons, the range of operations in treating specific congenital deformities were expanded. The attention also focused on cosmetic surgeries. Lt. Dr Robert Čáp joined the team, and Dr Talábová created conditions for his training and launching microsurgeries by him. Microsurgical instruments and a new operating microscope were purchased. The team began to perform surgeries and research in the sentinel node in malignant melanoma. Dr Janeček left for private practice on 30 April, 2005. Further-

more, Dr Pavel Horyna joined the team on 1 September 2005.

On 1 September 2004, Lt. Col. Dr Čáp, PhD was appointed the chief by the management of the Department. The team launched the first clinical microsurgeries. Dr Čáp also performed the first successful replantation of a thumb. Together with trauma surgeons and other specialists, the team co-operated in the reconstruction phases of the trauma or cancer treatment using free flap transfers by the microsurgery techniques.

The 2008–2014 phase

On 1 April 2008, Assoc. Prof. Klein returned to his alma mater (Fig. 1). The Department continued to perform all its tasks in medical care, teaching and scientific activities. The co-operation with the 3rd Internal Department of Metabolic Care and Gerontology in treating non-healing wounds and chronic defects continued. We expanded the application of the vacuum assisted therapy method and broadened the interdisciplinary co-operation within the UH. We managed to increase the number of physicians and even recruited one nurse for the operating theatre section. In co-operation with the UH management, an operating system focused on cosmetic surgery of self-paying patients was created. Assoc. Prof. Klein was appointed the supervisor of the theses of three successful PhD graduates (Dr Čáp, Dr Kłosová, Dr Fibír). Furthermore, in 2012, we organized the 17th Annual Czech-Slovak Conference on Burns Medicine.

The personnel aspect of the Department continued to be subjected to a continuous generational change. On 30 April 2009, after passing his attestation exam, Dr Horyna left for the Department of Plastic Surgery in Prague-Vinohrady. On the contrary, Dr Lucie Hasenöhrlová and Dr Igor Slaninka started to work at the Department on 1 September 2009. On 1 October 2013, Capt. Dr Adam Bajus, a member of the Central Military Hospital in Prague, started his long-term training (until



Fig. 1. Surgeons of the Department – January 2009 (from the right to the left): L. Klein, Z. Talábová, R. Čáp, F. Hošek.

28 February 2017) at our Department prior to his attestation exam. On 1 December 2013, Dr Ondřej Šedivý entered our employment.

On 1 September 2014, Assoc. Prof. Klein handed over the position of the head of the Department to Dr Aleš Fibír, PhD after a successful selection procedure. On 31 December 2014, Dr Čáp terminated his activities at the Department and left to be the head of the plastic surgery department in the private sector.

The 2015–2020 phase

Dr Fibír came as an experienced plastic surgeon with many years of experience in the private sector. He got quickly oriented and has continued to develop the Department purposefully. As a member of the younger generation, he extensively uses digitalization to manage and co-ordinate the operation of the Department, to plan outpatient and operational activities, as well as teaching activities. As a prominent expert in hand surgery, he has expanded the range of surgical procedures in this area. After purchasing the necessary instruments, he put into

practice endoscopic surgeries of entrapment syndromes on upper extremities. In co-operation with trauma surgeons, microsurgeries using free flap transfers have developed, especially in reconstructive operations. Prophylactic surgeries were introduced, and reconstructive surgeries have developed as part of the comprehensive treatment of breast cancer. We managed to gain additional room for our outpatient care and increase the number of physicians and nurses in the operating and outpatient section of the Department. Dr Talábová terminated her activities at the Department on 1 September 2016 and left for a private outpatient practice. In 2017, we admitted two new physicians – Dr Michaela Široká on 1 July, and Dr Kateřina Kubíčková on 1 September. Dr Kubíčková, however, left after less than three years and moved to the Department of Plastic Surgery in Prague-Vinohrady on 1 July 2020. Dr Slaninka defended his PhD thesis in May 2018. On 28 February 2020, shortly after passing the attestation exam, Dr Šedivý left for the Department of Plastic Surgery in Brno-Královo Pole. With

the arrival of the youngest physician Dr Jan Jaroš on 1 June 2020, this natural and permanent cycle has, within this phase, concluded.

Conclusion

Over the past 35 years, the Department of Plastic Surgery and Burns Treatment of the Department of Surgery in Hradec Králové has been firmly entrenched in the spectrum of specialized activities of the UH. It provides full-scale medical care in the given field. Since its beginning, the Department has relied on the principles of interdisciplinary and interdepartmental co-operation because physicians – members of three ministries, namely the Ministry of Health (UH), the Ministry of Youth, Education and Sports (LFUK), and the Ministry of Defence (Faculty of Military Health Sciences of the University of Defence, formerly VLA JEP) – have been working at our Department (and at the Department of Surgery as well). Incorporating a specialized department into the framework of a multidisciplinary clinic of surgery provides opportunities for mutual contacts and professional progress as well as for the development of direct and immediately accessible co-operation. This fact undoubtedly represents a significant benefit for patients, teaching, and research. Moreover, this aspect is also of great importance for the education of young physicians in the conditions of the current super-specialized medicine.

Disclosure: There is no conflict of interest to declare.

References

1. Měšťák J., Hrivnáková J., Čakrtová M., et al. Reduction mammoplasty at the Department of Plastic Surgery in Prague. *Acta Chir Plast.* 1993, 35: 147–153.
2. Königová R. František Burian a péče o popálené v Evropě. *Rozhl Chir.* 1998, 77: 426–428.
3. Tvrdek M., Fára M. The history of cleft lip operations at the Department of Plastic Surgery in Prague. *Acta Chir Plast.* 2009, 51: 85–86.
4. Tvrdek M., Fára M. The history of cleft palate operations at the Department of Plastic Surgery in Prague. *Acta Chir Plast.* 2009, 51: 87–88.

5. Smrčka V., Mádlová V. *Válečný chirurg František Burian a zrození české plastické chirurgie*. 1st ed. Praha: Karolinum, Univerzita Karlova v Praze; 2015.
6. Karfík V. Profesor MUDr. Kubáček, DrSc., 60 let. *Rozhl Chir*. 1977, 56: 158–159.
7. Veselý J., Válka J. Prof. MUDr. Kubáček, DrSc. – osmdesátiletý. *Rozhl Chir*. 1977, 76: 167.
8. Brychta P., Staněk J. *Historický vývoj české (československé) plastické a estetické chirurgie*. In: *Estetická plastická chirurgie a korektivní dermatologie*, 1st ed. Praha: Grada Publishing; 2014, 10–12.
9. Dražan L. Professor Ladislav Bařinka, MD, DSc (July 1, 1927–July 28, 2020). *Acta Chir Plast*. 2020, 62: 115.
10. Karfík V. K 25. výročí popáleninového oddělení v Ostravě. *Rozhl Chir*. 1980, 59: 291–292.
11. Měřička P., Hošek F. The importance of stored supplies of biological skin covers in territorial management of mass burn casualties. *Acta Chir Plast*. 2002, 44: 90–96.
12. Rezková H. *Vysocká nemocnice aneb od císaře pána k chirurgii ruky*. 1. vyd. Vlkov: Helena Rezková; 2015.
13. Třešková I. Jubilant primář Vlastimil Bursa. *Rozhl Chir*. 2019, 98: 349.
14. Klein L. Tři a půl desetiletí oddělení plastické chirurgie a léčby popálenin ve FN Hradec Králové (1985-2020). *Scan*. 2021, 31: 6–10.

Assoc. Prof. Leo Klein, MD, CSc.
Department of Plastic Surgery and
Burns Treatment
University Hospital
Sokolská 581, 500 05 Hradec Králové
Czech Republic
e-mail: leo.klein@fnhk.cz

Submitted: 09. 04. 2021

Accepted: 09. 05. 2021

ACTA CHIRURGIAE PLASTICAE

INTERNATIONAL JOURNAL OF PLASTIC
SURGERY, MAXILLOFACIAL SURGERY,
HAND SURGERY AND BURNS



- ▶ Founded 1959
- ▶ Published four times a year
- ▶ Peer-reviewed
- ▶ Original scientific papers
- ▶ Latest news and important information from the specialty
- ▶ Printed and online versions

Follow Acta chirurgiae plasticae online:
www.prolekare.cz/en/journals/acta-chirurgiae-plasticae



Care Comm
we care...



ČESKÉ SOUHRNY

Dlouhodobé výsledky morbidit donorského místa po rekonstrukci palce twisted-toe technikou

T. Kempný, O. Košková, K. Urbášek, M. Zvonař, K. Kolářová, B. Lipový, M. Knoz, J. Holoubek

Úvod: Traumatická ztráta palce ruky je vážné zranění ovlivňující schopnost pacienta pracovat a účastnit se každodenních činností. Hlavním cílem plastického chirurga je obnovit úchop ruky, často mikrochirurgickými metodami. Pacienti by však měli být informováni o všech následcích odběru tkáně. Cílem studie bylo posoudit dopad na došlap donorské nohy a na chůzi u pacientů, kteří podstoupili rekonstrukci palce ruky technikou twisted-toe modifikovanou Kempným. **Materiál a metody:** Studie se zúčastnilo 12 pacientů: všichni utrpěli ztrátu palce ruky mezi lety 2003 a 2011 a pro rekonstrukci byla použita technika twisted-toe. Byly hodnoceny změny v rozložení tlaku na chodidla a zatížení kloubů dolních končetin. **Výsledky:** Rozdíly mezi celkovým maximálním plantárním tlakem, integrálem tlakového času, kontaktní plochou a maximální silou mezi postiženou a neovlivněnou nohou byly statisticky významné ($p \leq 0,1$). Nebyly pozorovány žádné významné rozdíly parametrů časové chůze mezi postiženou a nepostiženou končetinou; byly však zjištěny statisticky významné rozdíly v kinetických parametrech a momentech předního kotníku a kolene. **Závěr:** Funkčnost donorské končetiny a anatomické postižení byly hodnoceny pomocí pedobarografických systémů a 3D analýzy chůze. Nejvýznamnější nálezy byly zaznamenány v rozdílné distribuci plantárního tlaku (zvýšený tlak v I., IV. a V. metatarzální oblasti) a přetížení mediálního kompartmentu kolenního kloubu. Proto by pro pacienty po rekonstrukci palce technikou twisted-toe mohlo být jako prevence osteoartrózy prospěšné nošení individuálně přizpůsobených vložek do bot.

Supraklavikulární ostrůvkový lalok v rekonstrukci hlavy a krku

B. Şahin, M. Ulsan, B. Başaran, S. Güneş, E. Oymak, S. Genç

Úvod: Ablativní chirurgická resekce má zásadní význam pro dosažení lepších onkologických výsledků u pacientů s karcinomem hlavy a krku. Radikální chirurgická resekce však vytváří požadavek na komplexní rekonstrukci jednotlivých anatomických struktur. Mikrovaskulární volné laloky byly doporučeny jako zlatý léčebný standard pro rekonstrukci hlavy a krku po definitivní onkologické operaci. Supraklavikulární ostrůvkový lalok (SCAIF) je tenký a spolehlivý fasciokutánní stopkovaný lalok, který se snadno a rychle preparuje. **Materiál a metody:** Do této studie bylo zahrnuto celkem 19 pacientů, kteří podstoupili rekonstrukci hlavy a krku pomocí SCAIF. SCAIF byl použit k rekonstrukci onkologického defektu u 17 pacientů, u 1 pacienta k rekonstrukci kožního defektu dolní poloviny obličeje po radioterapii a u 1 pacienta k uzávěru otevřené rány (poranění výbuchem). **Výsledky:** U žádného pacienta nedošlo k závažné komplikaci při ani po operaci. SCAIF byl úspěšně použit u 18 z 19 pacientů pro rekonstrukční chirurgii hlavy a krku. Částečná nekróza kůže byla detekována pouze u 1 pacienta (5,3 %), zatímco k úplnému selhání laloku nedošlo v žádném případě. Částečná nekróza kůže byla pozorována v rozsahu 1,5 cm od distálního okraje laloku a byla ošetřena konzervativně lokální péčí o ránu. Dehiscence rány v donorské oblasti laloku se neobjevila u žádného pacienta. **Závěr:** SCAIF představuje dobrou alternativu k volným lalokům, přičemž poskytuje téměř ekvivalentní funkční výsledky a vyžaduje méně operačního času a chirurgického úsilí.

Volný lalok tensor fasciae latae

R. Sathyamurthy, K. N. Manjunath, V. P. Waiker, S. Shanthakumar, M. Kumaraswamy

Úvod: Laloky jsou podstatou rekonstrukční chirurgie. Schopnost tyto laloky úspěšně navrhnout, provést a zahojit je specialitou plastické chirurgie. Volba laloku se řídí hlavně typem vady. Při rozhodování však hrají roli určité faktory, jako je proveditelnost, doba trvání operace a stav pacienta. Primární typ volného laloku (svalového nebo fasciokutánního) je určen defektem nebo charakterem rány. Volba laloku také závisí na různých faktorech, jako je požadovaná délka stopky laloku, snadnost odběru a morbidita donorského místa. Tensor fascia lata flap (TFL) je myokutánní lalok, který obsahuje kromě svalu další komponenty. **Materiál a metody:** Do studie byli zahrnuti pacienti přijatí do terciární nemocniční péče s diagnostikovaným kompozitním tkáňovým defektem v kterékoli oblasti lidského těla v intervalu od listopadu 2016 do listopadu 2018. Pacienti ve studii podstoupili rekonstrukci volným TFL lalokem. Byla analyzována délka trvání odběru laloku, anatomická lokalizace stopky, hojení laloku a potřeba sekundárních chirurgických výkonů. **Výsledky:** Celkem 14 pacientů podstoupilo rekonstrukci pomocí volného TFL laloku. Anatomická pozice defektů byla nejčastěji na dolních končetinách – 8 případů (58 %), následovaly horní končetiny a hlava a krk (3 případy po 21 %). Průměrná doba odběru laloku byla 62,07 min (rozmezí 45–80 min). Pozice vstupu stopky do laloku byla průměrně 8,7 cm od spina iliaca anterior superior. Ze 14 laloků bylo 10 (71 %) laloků zcela úspěšných a u 4 (29 %) laloků se vyskytla parciální ztráta. **Závěr:** Doba odběru volného TFL laloku je ve srovnání s jinými laloky velmi krátká, a proto je lalokem volby u pacientů, kteří jsou v kritickém stavu a netolerují dlouhodobou celkovou anestézií.

Přítomnost cirkulujících nádorových buněk u pacientky s mnohočetnými invazivními bazocelulárními karcinomy – kazuistika

K. Kiss, I. Kiss, K. Kolostová, E. Pospíšilová, M. Šíroká, A. Fibír

Úvod: Bazocelulární karcinom (BCC) je celosvětově nejčastějším karcinomem kůže, jeho metastatické šíření je však extrémně vzácné. **Případ:** Prezentujeme případ pokročilého BCC s rychlým růstem nových nádorových lézí u pacienta, u kterého byl později diagnostikován Gorlinův syndrom. Vzhledem k pokročilému stadiu onemocnění byl pacient vyšetřován na cirkulující nádorové buňky (CTC), které se používají jako prognostický marker u některých metastatických malignit. Doposud nebyly nalezeny žádné studie, které by mohly posoudit BCC a přítomnost CTC v periferní krvi. CTC byly získány po každé chirurgické excizi a během systémové onkologické terapie z periferní žilní krve metodou izolace podle velikosti (Metacell®) a kultivovány *in vitro* po dobu 7 dnů. CTC byly zmnoženy separací podle velikosti a zkoumány pomocí vitální fluorescenční mikroskopie. Bylo poskytnuto cytomorfologické srovnání CTC s buňkami z nádorových lézí. V průběhu léčby se počet CTC v krvi snížil po chirurgickém odstranění nádorové hmoty, ale nakonec bylo dosaženo trvalého a přetrvávajícího snížení CTC při léčbě inhibitorem dráhy hedgehog. **Závěr:** Detekce CTC v tomto případě ukazuje na systémové chování nemoci.

Pyoderma gangrenosum – vzácná komplikace redukční mammoplastiky – kazuistika

M. Šíroká, K. Kiss, A. Fibír

Úvod: Pyoderma gangrenosum (PG) je vzácné neinfekční zánětlivé onemocnění neznámé etiologie, které postihuje kůži i sliznice. Výskyt pyoderma gangrenosum po redukční mammoplastice je velmi vzácná komplikace, která na první pohled vypadá jako infekční komplikace, ve skutečnosti se ale jedná o zánětlivé onemocnění. **Případ:** V této kazuistice popisujeme vzácnou pooperační komplikaci – pyoderma gangrenosum a její léčbu u naší pacientky, která podstoupila redukční mammoplastiku. **Závěr:** Včasně rozpoznání této komplikace je pro vyléčení pacienta zcela zásadní, protože primární chirurgická léčba vede ke zhoršení průběhu a je zde tedy kontraindikována. Pyoderma gangrenosum musí být primárně léčeno konzervativně kortikoidy.

Podtlaková léčba a její využití v orofaciální oblasti u onkologických pacientů – dvě kazuistiky

J. Belobradová, O. Res, J. Stránský, Z. Čermáková, T. Blažek, P. Hurník, J. Štembírek

Úvod: Chronické rány a jejich problematické hojení jsou široce diskutovaným tématem ve všech odvětvích medicíny. V posledních letech se terapie podtlakem jeví jako velice úspěšná neinvazivní metoda podporující hojení těchto ran. Cílem práce je ukázat možnosti využití podtlakového systému v orofaciální oblasti, kdy ostatní konzervativní i chirurgické postupy selhaly. **Případy:** Kazuistiky ukazují využití podtlakové terapie na nehojících se pooperačních ranách u onkologických pacientů. **Závěr:** Možnosti využití podtlakové léčby v orofaciální oblasti jsou jen omezené, nicméně naše zkušenosti svědčí o velmi pozitivním vlivu na hojení chronických ran. Díky této léčbě bylo možno omezit četnost převazů a značně zkrátit dobu hospitalizace. I tak je ovšem nutno dodržovat podmínky aplikace podtlaku.

Třicet pět let Oddělení plastické chirurgie a léčby popálenin FN Hradec Králové

L. Klein

Oddělení plastické chirurgie a léčby popálenin bylo založeno jako součást nově vytvořené II. chirurgické kliniky LF UK a FN Hradec Králové v roce 1985. Přes skromné začátky postupně rozvíjelo činnost v daném oboru a plně pokrývalo potřeby svého regionu s téměř 1 mil. obyvatel. V článku jsou zaznamenány nejdůležitější momenty v jednotlivých etapách vývoje zasahujícího do čtyř dekad. Důraz je položen na personální aspekty, technické a prostorové vybavení pracoviště. Oddělení vždy pracovalo na principu mezioborové spolupráce v rámci kliniky i dalších oborů FN. Za 35 let se oddělení pevně etablovalo do spektra specializovaných činností a plně pokrývá potřeby odborné péče poskytované ve FN Hradec Králové.

ACTA CHIRURGIAE PLASTICAE

© Czech Medical Association of J. E. Purkyně, Prague 2021

Ministry of Culture of the Czech Republic Reg. No. MK ČR E4844. ISSN (print) 0001-5423, ISSN (online) 1805-4404.

Published by CareCom s.r.o., Klicperova 604/8, 150 00 Prague 5, Czech Republic.

Editing: Petra Polsen, e-mail: petra.polsen@carecomm.cz

Graphic design: Miroslav Chudík, e-mail: mirek.chudik@carecomm.cz

Issued: 4 times per year. Annual subscription: 870 CZK. Information on subscription: predplatne@carecomm.cz

Advertisement: Nikola Janková, phone: +420608848496, e-mail: niki.jankova@carecomm.cz

The manuscript and a cover letter may be sent in an electronic form to the following address: zdenek.dvorak@fnusa.cz. Printed papers are not paid; the authors receive one copy of the journal for free.

The publisher obtains full copyright for usage of the article by publishing the manuscript.

The publisher and the editorial board inform that the content and the language of the advertisement is a sole responsibility of the advertiser.

No part of this journal may be copied for further distribution in any form or by any means, mechanically or electronically, including photocopies, recordings, and information databases on mechanical media, without written consent of the copyright owner and their authorization for publishing.

This issue is published on 15. 7. 2021

New antibacterial nanotechnological solution for wound care management



The **StopBac STERILE** range is a modern, antibacterial dressing designed for wound care. StopBac is produced by **Grade Medical**, a leading Czech manufacturer of innovative medical devices for wound treatment, and was invented in collaboration with Czech well-known plastic surgeons.

Thanks to unique manufacturing process and the use of nanotechnology based on silver cations, it provides an exceptionally powerful antimicrobial effect preventing wound contamination and reducing infection-related complications. This technology means that StopBac forms an ideal preventive barrier-type protection for surgical wounds against complications during the healing process. Therefore, StopBac is a great solution for covering wounds after plastic surgeries.

The bearer of the antibacterial effect are silver cations, which cause the cell death of bacteria, which is synergistically supported by the sol itself. As a result, StopBac helps shorten the period of hospitalisation, reducing the amount of antibiotics and analgesics used, and reduces the number of times the wound needs to be redressed. It is thus a cost-effective way of healing postoperative wounds, which prevents a manifold increase in treatment costs and the devastating impact of infection on the patient's health, contributes to the faster and more effective healing of wounds and saves time for medical staff. All this at better prices than expensive foreign materials.

The exceptional effectiveness of StopBac dressings has been proven based on painstaking development and testing in Czech university hospitals. The excellent results of StopBac in wound care management were subsequently published in many magazines including EWMA.

Excellent price-performance ratio and effectiveness of StopBac has been proved multiple times in high-ranking studies, e. g. StopBac – a new silver dressing in surgical wounds led by Ass. Prof. Martin Oliverius, MD, PhD (University Hospital Kralovske Vinohrady) published at International Wound Journal or **Silver-based antimicrobial dressing in the prevention of surgical site infection** led by Jan Stryja, MD (Salvatella, Hospital Podlesi).

StopBac dressings are recommended by leading clinics at university hospitals that use these products on a daily basis.

