ACTA CHIRURGIAE PLASTICAE

INTERNATIONAL JOURNAL OF PLASTIC SURGERY, MAXILLOFACIAL SURGERY, HAND SURGERY AND BURNS

No. 1, 2018

Vol. 60 / 2018 / No. 1

CONTENTS

http://www.cls.cz

ACTA CHIRURGIAE PLASTICAE

Editor-in-chief:
Aleš Fibír, M.D., PhD.

Editing:
Michaela Malinová
e-mail: malinova@levyn.cz

Published by: Czech Medical Association J. E. Purkyně, Sokolská 31, 120 26 Prague 2, Czech Republic

For Czech Medical Association JEP prepared by Mladá fronta a. s.

mladá fronta

General manager: Ing. Jan Mašek
Director of Medical Services division:
Karel Novotný, MBA
Coordinator of technical journals of the Czech Medical Association JEP:
Michaela Lízlerová, M.D.
Graphical layout, typography:
Jan Borovka
Marketing:
Marketing director: Jaroslav Aujezdský
Brand manager: Petra Trojanová

Print: TRIANGL, a. s.

Distribution in the Czech Republic:
Postservis Prague
Olšanská 38/9, 225 99 Prague 3

In the Slovak Republic: Mediaprint Kapa – Pressegrosso, a. s.,
Vajnorská 137, P.O. BOX 183
831 04 Bratislava

Distribution abroad: (with the exception of Slovak Republic): Myris Trade Ltd., P. O. Box 2, V Stihlach 1311, 142 01 Prague 4, Czech Republic.
Phone +420 234 035 200,
Fax +420 234 035 207, E-mail: myris@myris.cz

Issued: 4 times per year
Single issue CZK 124,-
Slovak Republic EUR 6,60

Information about subscription is provided and subscription order is accepted by:
Czech Medical Associaton JEP,
Sokolská 31, 120 26 Prague 2,
tel.: +420 296 181 805 – J. Spalová,
e-mail: spalova@cls.cz

Advertisement: Ing. Kristína Kupcová,
kupcova@mf.cz; +420 225 276 355

Sending the manuscripts:
The manuscript and a cover letter may be sent in a written printed form and also in an electronic form on CD, DVD or flash disc to the following address: MUDr. Aleš Fibír, Oddělení plastické chirurgie a léčby popálenin, Fakultní nemocnice Hradec Králové, Sokolská 581, Hradec Králové, PSČ 500 05, Czech Republic. If the electronic form of the manuscript is smaller than 8 Mb, it is possible to send it as an attachment to an email to the following address: fibir@seznam.cz.
Manuscript was submitted to production on xx. xx. xxxx.
Submited papers are not returned.
Printed manuscripts of the authors are not paid; the authors receive one copy of the journal for free.

ISSN (Print) 0001-5423, ISSN (Online) 1805-4404,
Ministry of Culture Czech Republic MK ČR E4844.

ACTA CHIRURGIAE PLASTICAE, 60, 1, 2018, pp. 3

Dear readers,

You hold yet another issue of our journal in your hands. I had been thinking for a long time about the topic of this editorial. This time, the topic will not be about journal content, which you will read in a few moments of course, and it will not be about what we have achieved in the past either or about what we could achieve in the future. I think that a very interesting current topic for all of us, plastic surgeons, is the educational system in our country and the changes taking place now.

In the past, plastic surgery was a specialization, in which it was possible to specialize only after the basic experience and first-grade examination in general surgery. From a retrospective point of view, it can be said, that this system had made sense. Those of us who have gone through this educational system still appreciate the need to acquire basic expertise in general surgery that we often use in our practice, so we are also able to tackle the problems and complications that are not related only with plastic surgery.

Then there was a change from a two-stage to a one-stage educational system, when plastic surgery became a basic specialization. The goal of this specialization was to provide sufficient training to doctors after graduation from medical school up to the plastic surgery attestation. It was not a simple task, but the plastic surgery society and its representatives tried to set up rules that would make sense and on the other hand, which would not complicate access to specialization to all who have the interest and ability to be good plastic surgeons. It was not an easy task to accomplish this within the one-stage educational system.

However, it would not be a serious problem if such system remained stable even in the long run. Unfortunately, this did not happen. For a variety of more or less justified or unjustified reasons, there have been repeated changes to the plastic surgery training program rules where plastic surgeons have been educated and certified at one moment according to several different educational programs with different requirements for obligatory practice, internships, courses, and practical skills. There were totally five changes in the plastic surgery curriculum within the last 13 years, so we have versions of the training program of 2005, 2009, 2011, 2015 and 2017! These frequent changes sometimes fundamentally altered the requirements for the extent of the obligatory education without fulfilment of which no one could be accepted for the final attestation exam.

These changes did not reduce the requirements for professional knowledge or practical skills, but there was, in particular, a continuous pressure to shorten the total required educational time before the attestation exam. But this effort must have a reasonable limit. In the historical two-stage education system, three years of general surgery and five years of plastic surgery training were mandatory, totally it meant eight years of training. According to the latest requirements from 2017, education should last for 30 months in general surgery, followed by 30 months of training in plastic surgery including obligatory internships and courses. The situation that it would be possible to acquire sufficient professional ability and especially practical skills in plastic surgery during such an extremely short period of time is not considered by the representatives of our professional society to be realistic and therefore it demands prolongation for at least one more year.

In the year 2017, the representatives of the society updated the training program to meet the legal requirements and, at the same time, to enable training of sufficiently educated specialists in plastic surgery. The extent of obligatory internships and courses was modified, the extent of theoretical training was updated with new topics, and the requirements for practical skills were adjusted by modification of the spectrum and number of required operations and assistances, etc.

Unfortunately, it is sad and frustrating that even at the end of year 2018 we still do not know the final rules of education that were adopted in the middle of 2017. Other specialities that are related to the scientific focus of our journal, e.g. burn surgery, maxillo-facial surgery, stomato-surgery or hand surgery face similar problems.

Uncertainty in education subsequently influences the situation in our specialization, so in the future, it may be a barrier for possible candidates to enter to plastic surgery, it may complicate the situation of doctors already in specialized training, and cause a shortage of plastic surgeons and disintegration of established teams of super-specialized plastic surgery care.

It is therefore my great wish, and also a great wish of other representatives of plastic surgery society, to stop this uncertainty as soon as possible, so that the extent of training enabled preparation of well-educated plastic surgery generation and mainly to keep it stable for a significantly longer period of time than the recent educational programs. So we will see.

Inspirational reading wishes

Aleš Fibír, M.D., PhD.
Acta Chirurgiae Plasticae

USE OF LICAP AND LTAP FLAPS FOR BREAST RECONSTRUCTION

Martellani, L., Manara, M., Renzi, N., Papa, G., Ramella, V., Arnež, Z.

ASUITS Trieste, Italy

ACTA CHIRURGIAE PLASTICAE, 60, 1, 2018, pp. 4-8

ABSTRACT

Breast conserving surgery has been reserved for patients with favorable proportion between tumor dimensions and breast size. Introduction of local flaps from the lateral thoracic region has widened the indications for breast conserving surgery, by allowing surgeons to perform wider excisions, thus yet be able to ensure tumor-free surgical margins and a good aesthetic result.
We have used lateral intercostal perforator flaps and flaps harvested on the lateral thoracic artery and lateral thoracic artery axial flap in patients with small breasts and an unfavorable tumor to breast size proportion.
From May 2015 to October 2016, 19 patients with breast tumors have been treated with BCS and immediate volume replacement reconstruction by pedicle perforator flaps from the lateral thoracic region. In 15 patients lateral intercostal artery perforator flaps or lateral thoracic artery perforator flaps were used after quadrantectomy or wide local excision, in 3 patients as volume replacement after mastectomy and in 1 patient after mastectomy following previous augmentation mammoplasty. In all patients, good breast symmetry was achieved, with no major complications. Fibrosis of the flap and residual breast parenchyma, with volume reduction were noticed after postoperative radiotherapy in thin patients or flaps with little subcutaneous fat.
Perforator flaps from the lateral thoracic region should become the gold standard for reconstructions after breast conserving surgery involving less than 20% of the breast volume or after mastectomy in patients with small breasts. The operating procedure is safe, quick and allows sparing of the latissimus dorsi muscle and thus minimal donor site morbidity, as well as an excellent aesthetic result.

KEYWORDS

LICAP, LTAP, breast reconstruction, perforator flaps

INTRODUCTION

Breast conserving surgery (BCS) followed by radiotherapy is considered the gold standard treatment for early breast cancer. Survival rates after BCS are similar to those of mastectomy. Associated to those are considerable aesthetic and psychological benefits for the patient.[1]

The main issue in BCS is accurate selection of patients as, this surgical technique is addressed to patients with a positive ratio between breast size and tumor volume. Residual breast parenchyma is redistributed according to breast reduction patterns or rotation/advancement flaps (volume displacement) and usually a contralateral breast reduction or mastopexy is required to achieve symmetry and a pleasant aesthetic result.[2,3,4]

The introduction of local flaps from the lateral thoracic region for volume replacement reconstruction has widened the indications for BCS by allowing surgeons to perform wider excision (even more than 20% of breast parenchyma) to ensure tumor-free margins and an immediate good aesthetic result with no need for contralateral surgery.[5,6]

As described by Hamdi et al., the costal segment of the intercostal vessels provides several perforators to the skin by means of the intercostal, serratus anterior and latissimus dorsi muscles. The lateral intercostal artery perforator (LICAP) flap can be harvested based on these perforators.[7,8]

Intercostal perforators can be found predominantly between the fifth and eighth intercostal spaces. They emerge deep to the intercostal muscles, from the subcostal groove, run into the intercostal space deep to the internal and external intercostal muscles and then obliquely under a slip of the origin of the serratus anterior muscle.

Moreover, vascular connections link the intercostal perforators to the serratus anterior branch, enabling a safer harvesting of the flap.

Flaps based on the lateral thoracic artery are another valuable option. They can be raised as perforator flaps, as described by McMillan et al.[9], or as an axial flap based on the principal (lateral thoracic) vessel allowing the reconstruction of more medial defects or a total breast reconstruction as the vascular pedicle and consequently the arc of rotation are longer.

MATERIALS AND METHODS

Perforator flaps from the lateral thoracic region have been described for reconstruction of partial thoracic defects, axillary contractures[6,10] and defects after BCS.[11-15] In our case series we used LICAP and flaps harvested on the lateral thoracic artery perforator (LTAP) and lateral thoracic artery axial flap.

From May 2015 to October 2016, 19 patients were treated, with a total of 20 flaps harvested. In 15 patients the perforator flaps from the lateral thoracic region were used after quadrantectomy or wide local excision (in one patient also the contralateral breast was shaped for better symmetry after a previous quadrantectomy without reconstruction by the same technique), in 3 patients as volume replacement after mastectomy and in 1 patient the flap was used to reinforce the lower breast pole instead of an acellular dermal matrix (ADM), after mastectomy following a previous breast augmentation. All patients who

underwent reconstruction by this technique had medium to small breasts, adequate subcutaneous tissue and skin laxity in the lateral thoracic region as well as an unfavorable tumor/breast size ratio. The average patient age was 54 years (range 43-64years).

In 17 patients lateral intercostal artery perforator (LICAP) flaps were harvested. In 8 patients we took advantage of the vascular connections between the intercostal perforators and the lateral thoracic system for a more reliable vascular supply, and in 2 patients the flap was raised solely on the perforators of the lateral thoracic artery (LTAP flap).

In the OR the patients were positioned on the back with an inflatable bag placed behind the shoulder. After that quadrantectomy, wide tumor excision or mastectomy and axillary clearance were performed. Following tumor excision, the specimen was weighted and then sent for histology. After completing the oncologic part of the procedure, the inflatable device was inflated, which exposed the lateral thoracic region for a comfortable harvesting of the flap. The size of the flap was determined preoperatively taking in consideration the location of the defect (lateral quadrants of the breast) and the estimated volume to be replaced by the flap. Flap harvesting and breast reconstruction were thus performed without the need to reposition the patient. All our flaps were harvested on several perforators. The perforator that offered the best swing of the flap with minimal rotation of the perforator was finally selected; all the others were clipped. The flap was then de-epithelialized, folded, when necessary, and positioned into the defect. Two suction drains were positioned (one drained the breast and one the donor site). (Fig. 1–4.)

RESULTS

All our flaps survived. We encountered no flap loss (neither partial nor total). The total number of complications was 8: three seromas on the back and four small superficial wound dehiscences. One patient required return to the operating theatre on the first postoperative day for evacuation of a hematoma.

In all cases a good aesthetic result, with good symmetry, was achieved.

14 patients underwent radiotherapy 6 to 8 weeks after surgery. The average duration of the reconstruction was 63 minutes (range 50-80min). The average weight of anatomical specimens after quadrantectomy or wide local excision was 81.89 g (range 29-200g) (Table 1.)

DISCUSSION

The pedicle perforator flaps from the lateral thoracic region for reconstruction of partial breast defects after BCS are more and more popular as they allow breast reconstruction with minimal donor site morbidity. Even after wide resections, an adequate volume replacement can be achieved with no need to sacrifice latissimus dorsi muscle and major vessels (e.g. thoracodorsal artery) since even big flaps can be

NAME	AGE	SURGERY	SPECIMEN WEIGHT	TYPE OF FLAP	OPERATING TIME (min)
BR	55	RIGHT UOQ, SNB	110	LICAP *	70
CI	59	LEFT OOQQ, SNB + CONTRALATERAL SIMMETRIZATION	65	LICAP	125
CC	61	LEFT LOQ, SNB	140	LICAP *	75
CM	55	RIGHT UOQ, SNB	85	LICAP *	58
CLM	51	RIGHT UOQ, AD	120	LICAP	62
DM	64	RIGHT MASTECTOMY, SNB	60	LICAP	70
DC	46	RIGHT UOQ, AD	77	LICAP	65
MM	46	RIGHT UOQ, SNB	60	LICAP*	70
MM	63	LEFT UUQQ, SNB	95	LICAP *	55
PF	52	RIGHT MASTECTOMY, SNB	200	LICAP	80
PP	51	RIGHT LOQ, SNB	55	LICAP	65
RV	60	RIGHT LOQ, SNB	62	LTAP	55
SP	59	LEFT MASTECTOMY, SNB	68	LICAP	65
SN	43	LEFT MASTECTOMY, AD	100	LTAP	70
SG	51	RIGHT UOQ, SNB	70	LICAP *	55
VF	56	RIGHT UOQ, SNB	29	LICAP	50
GP	52	LEFT OOQQ, SNB	45	LICAP *	60
AC	50	LEFT UOQ, SNB	70	LICAP	60
GM	52	LEFT UOQ, SNB	45	LICAP *	55

Table 1. The table shows patients' age, type of surgery and location of the defect, specimen weight, type of flap harvested and operating time. (*) In these cases the connections between lateral intercostal artery perforator and the lateral thoracic perforator have been preserved

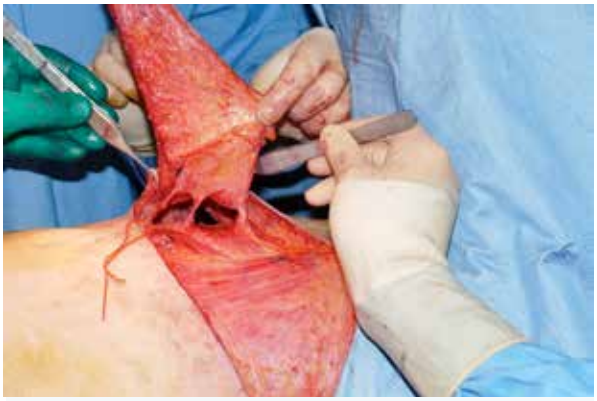

Fig 1. Flap harvested on three perforators of the lateral intercostal artery

Fig 2. Flap harvested on one lateral intercostal artery perforator and one lateral thoracic artery perforator. The distal one (LICAP) was later clipped

Fig 3. Patient with lower outer quadrant cancer of the right breast. Quadrantectomy, sentinel lymph node biopsy and reconstruction with LICAP flap were performed.
A: Preoperative view. B: One moth postoperative view.
C: Result after radiotherapy (loss of volume, shrinkage of the flap and radiodermatitis)

reliably raised on minor vessels, or a single perforator.[8,9,14,15] Moreover in case of local relapse of the tumor, the reconstruction after mastectomy is still feasible as all major vascular pedicles have been preserved by previous surgery.

LICAP flap has also been used as an ADM in a patient who underwent dual plane breast augmentation first and then a mastectomy for breast cancer. Wishing to preserve the implant, we harvested the flap and used it to protect and support the lower pole of the prosthesis, while in the upper pole it was already covered by the pectoralis major muscle. Such reconstruction proved to be strong and stable, with no ptosis or mal-positioning of the implant with time.

The vascular anatomy of the region is constant, the dominant perforators of the intercostal artery are typically located in the fourth to eighth intercostal spaces, with a higher concentration in the sixth and seventh intercostal spaces, 3.5 cm medial from the anterior border of the latissimus

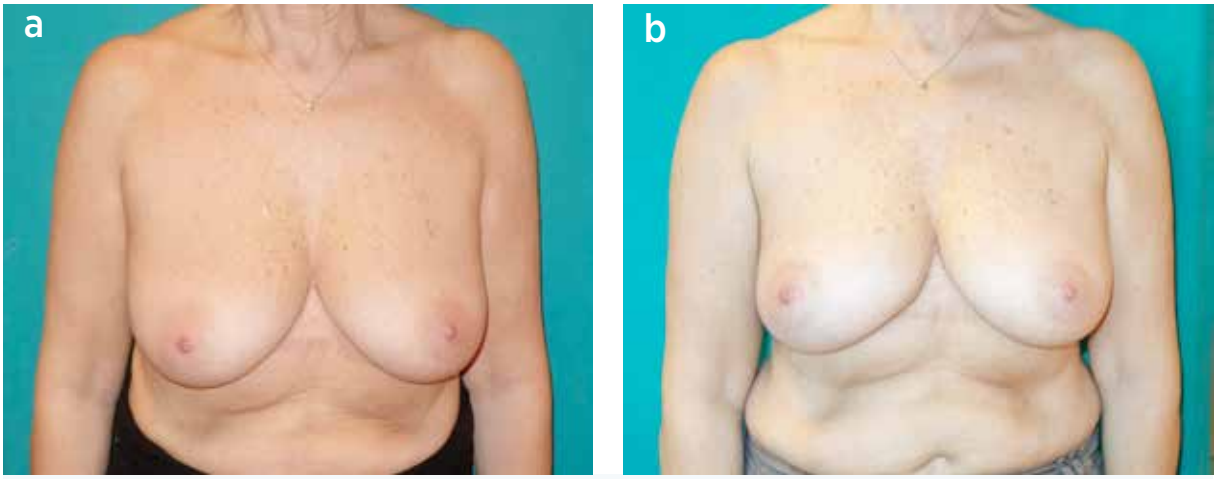

Fig 4. Patient with upper outer quadrant cancer of the right breast. Quadrantectomy, sentinel lymph node biopsy and reconstruction with LICAP flap were performed. A: Preoperative view. B: One month postoperative views

dorsi.[8] Pedicle length was always adequate, also in cases of total breast reconstruction (dissection of the main pedicle was performed to the costal groove if a longer arch of rotation was required) and we did not face problems of venous stasis even after a rotation of 180°. In our practice, while searching for the intercostal perforators, we noticed that the course of the lateral thoracic permitted harvesting of the flap on a perforator vessel from it (LTAP flap) or on the main vessel itself, as an axial flap, enhancing the arc of rotation.

Harvesting of local pedicle perforator flaps from the lateral thoracic region, if compared to the TDAP, does not prolong operating time due to the more constant anatomy, the less tedious harvesting technique and because the repositioning of the patient is not necessary. Moreover, the learning curve for the surgeons is significantly shorter when compared to other reconstructive techniques.

The main problem that we outlined in this case series has been the changes that the flaps underwent after radiotherapy in terms of pliability and volume.[16] The early postoperative results were all excellent (see Fig. 4) but in almost all cases we could appreciate a variable degree of stiffness and loss of volume of the flap after radiotherapy if compared to the immediate postoperative results (see Fig. 3). We partially attributed this effect to the ratio between dermis and subcutaneous tissue of the flaps harvested. In majority of patients the BMI was normal to slightly underweight, so that scarce subcutaneous fat could have made flaps, mainly consisting of dermis, more sensitive to radiation damage.

We did not use any secondary lipostructure to improve tissue pliability and correct volume deficiencies due to lack of adequate studies about its oncologic safety.

CONCLUSIONS

Perforator flaps of the lateral thoracic region should become the gold standard for reconstructions after BCS involving 20% of the breast volume. It is a safe procedure, that allows good aesthetic results, it spares the LD muscle and minimizes donor site morbidity. It does not prolong the operating time significantly due to constant anatomy, an easy harvesting without repositioning of the patient.

In skinnier patients the aesthetic result is less pleasant, particularly after radiotherapy because of fibrosis and shrinkage of the flap, but this reconstructive technique has still to be preferred to prosthetic reconstruction.

Further studies and longer outcome measurements are necessary to evaluate the stability of the aesthetic results with time and to improve our knowledge about the feasibility of axial pattern flaps based on the lateral thoracic artery.

Conflict of interest statement: The authors do not have any potential conflicting interests to declare.

REFERENCES

1. Veronesi U, Cascinelli N, Mariani L et al. Twenty-year follow-up of a randomized study comparing breast-conserving surgery with radical mastectomy for early breast cancer. *N Engl J Med*. 2002 Oct 17;347(16):1227-32.
2. Doridot V, Nos C, Aucouturier JS, Sigal-Zafrani B, Fourquet A, Clough KB. Breast-conserving therapy of breast cancer. *Cancer Radiother*. 2004 Feb;8(1):21-8.
3. Clough KB, Lewis JS, Couturaud B, Fitoussi A, Nos C, Falcou MC. Oncoplastic techniques allow extensive resections for breast-conserving therapy of breast carcinomas. *Ann Surg*. 2003 Jan;237(1):26-34.
4. Hamdi M. Oncoplastic and reconstructive surgery of the breast. *Breast*. 2013 Aug;22 Suppl 2:S100-5.
5. Dixon JM, Venizelos B, Chan P. Latissimus dorsi mini-flap: a technique for extending breast conservation. *Breast*. 2002 Feb;11(1):58-65.
6. Stillaert FB, Casaer B, Roche N et al. The inframammary extending lateral intercostal artery perforator flap for reconstruction of axillary contractures: a case report. *J Plast Reconstr Aesthet Surg*. 2008 Dec;61(12):e7-11.
7. Taylor GI, Daniel RK. The anatomy of several free flap donor sites. *Plast Reconstr Surg*. 1975 Sep;56(3):243-53.
8. Hamdi M, Spano A, Van Landuyt K, D'Herde K, Blondeel P, Monstrey S. The lateral intercostal artery perforators: anatomical study and clinical application in breast surgery. *Plast Reconstr Surg*. 2008 Feb;121(2):389-96.
9. McCulley SJ, Schaverien MV, Tan VK, Macmillan RD. Lateral thoracic artery perforator (LTAP) flap in partial breast reconstruction. *J Plast Reconstr Aesthet Surg*. 2015 May;68(5):686-91.
10. Schwabegger AH, Herczeg E, Piza H. The lateral thoracic fasciocutaneous island flap for treatment of recurrent hidradenitis axillaris suppurati-

va and other axillary skin defects. *Br J Plast Surg*. 2000 Dec;53(8):676-8.
11. Holmström H, Lossing C. The lateral thoracodorsal flap in breast reconstruction. *Plast Reconstr Surg*. 1986 Jun;77(6):933-43.
12. Hamdi M, Wolfli J, Van Landuyt K. Partial mastectomy reconstruction. *Clin Plast Surg*. 2007 Jan;34(1):51-62
13. Losken A, Hamdi M. Partial breast reconstruction: current perspectives. *Plast Reconstr Surg*. 2009 Sep;124(3):722-36.
14. Hamdi M, Van Landuyt K, Monstrey S, Blondeel P. Pedicled perforator flaps in breast reconstruction: a new concept. *Br J Plast Surg*. 2004 Sep;57(6):531-9.
15. Hamdi M, Van Landuyt K, de Frene B, Roche N, Blondeel P, Monstrey S. The versatility of the inter-costal artery perforator (ICAP) flaps. *J Plast Reconstr Aesthet Surg*. 2006;59(6):644-52.
16. Albino FP, Koltz PF, Ling MN, Langstein HN. Irradiated autologous breast reconstructions: effects of patient factors and treatment variables. *Plast Reconstr Surg*. 2010 Jul;126(1):12-6.

Corresponding author:

Zoran Marij Arnež, M.D.

ASUITS Trieste
strada di Fiume 447 34137 Trieste, Italy
E-mail: zoran.arnez@asuits.sanita.fvg.it

IMAGING POSSIBILITIES OF THE PERIPHERAL NERVE TUMOR USING MAGNETIC RESONANCE IMAGING – CASE REPORT

Humhej I.[1], Ibrahim I.[2], Lodin J.[1], Sameš M.[1], Čižmář I.[3]

[1] Department of Neurosurgery, J. E. Purkyně University, Masaryk Hospital, Ústí nad Labem, Czech Republic
[2] MR Unit, Department of Radiodiagnostic and Interventional Radiology, Institute for Clinical and Experimental Medicine (IKEM), Prague, Czech Republic
[3] Department of Traumatology, Faculty of Medicine, Palacky University, Faculty Hospital Olomouc, Czech Republic

ACTA CHIRURGIAE PLASTICAE, 60, 1, 2018, pp. 9–13

ABSTRACT

Magnetic resonance imaging (MRI) plays a crucial role in the diagnosis and morphological analysis of peripheral nerve tumours (PNTs). In recent years, a number of novel MRI sequences such as MR neurography (MRN), diffusion tensor imaging (DTI) or MR tractography (MRT) have emerged extending the range of conventional MRI techniques. These advanced sequences are able to provide detailed information concerning PNTs structure, including the course and function of individual neural fascicles. This data can then be utilized in tailoring a suitable surgical procedure, reducing the risks of postoperative neurological deficit. The following case report of a median nerve tumour demonstrates the range and practicality of current MRI techniques. With continuing advancement and perfection of these MRI techniques, we can expect their integration into standard diagnostic protocols of PNTs.

KEYWORDS

Peripheral nerve tumour, magnetic resonance imaging, MR neurography, diffusion tensor imaging (DTI), MR tractography

INTRODUCTION

Peripheral nerve tumours (PNTs) are relatively rare diseases, comprising less than 5% of all soft tissue tumours [1]. They are predominantly benign affections, with schwannomas (neurinomas, neurilemmomas) and neurofibromas being the most common [2]. PNTs are usually solitary lesions, however can present in multiples, such as in cases of neurofibromatosis type I. or schwannomatosis. Correct diagnosis performed using the patient's history, physical examination and especially imaging techniques, is paramount in cases where PNTs are suspected. Electromyography (EMG) studies are less useful, as they commonly show normal nerve conduction [3]. Imaging modalities include ultrasonography, most notably high-resolution techniques, and magnetic resonance imaging (MRI), a method with excellent soft tissue differentiation. Detailed anatomical analysis is key in preoperative planning, as the main surgical objective for most symptomatic growing PNTs is radical resection, with maximal preservation of neurological function [4-6]. Continuing technological advancement has led to the development of novel MRI techniques and sequences, allowing complex 3D reconstructions of peripheral nerves (PNs). The following case report describes the use of these so-called advanced MRI techniques, in the diagnostic algorithm of a median nerve tumour.

CASE REPORT

The following case is a 64-year-old male, who presented with a growing mass distally on the medial border of the left arm. Palpation of the mass led to paraesthesia and spasms of the IIIrd and IVth finger. Upon clinical evaluation, the patient showed no signs of hypaesthesia or dysaesthesia in any neural dermatomes on the affected limb. Furthermore, there was no loss of muscle strength including fine motor skills when compared to the normal limb. The mass itself was a ball-like resistance of 3 cm in diameter, approximately 10 cm proximal to the medial epicondyle of the humerus. On palpation, it was tough and mobile perpendicularly to the humerus. Percussion of the tumour showed a positive Tinel's sign, resulting in paraesthesias and shock-like sensations in the distribution of the median nerve (MN). Conduction studies as well as needle EMG of the affected nerve resulted in normal values. Bed-side ultrasonography

was performed and showed a solid, well circumscribed, hypoechogenic mass, measuring 20 x 20 x 24 mm, in close proximity to the brachial vessels. MRI using T1, T2-STIR and T1 with gadolinium contrast sequences was performed and showed a contrast enhancing PNT. 3D T2-STIR (short tau inversion recovery) SPACE (sampling perfection with application optimized contrast using varying flip angle evaluation) sequences of the tumour are shown in Fig. 1a. Consequently, we performed a series of advanced MRI sequences, specifically MR neurography (MRN), diffusion tensor imaging (DTI) and MR tractography (MRT). Due to these novel techniques, we obtained a detailed anatomical image of the tumour originating from the MN – Fig. 1b (3D T2-STIR SPACE MIP), showing the MN course throughout the arm, including the tumour, using fraction anisotropy (FA) – Fig. 1c (FA-MIP) and visualization of neural fascicles adjacent to the tumour (MRT) – Fig. 1d, Fig. 2a and 2b.

Following the diagnosis, a surgical procedure was planned and later performed, under regional anaesthesia using an axillary block at the outpatient clinic. Radical resection of the tumour, resembling a schwannoma, was performed using microsurgical techniques with the aid of peroperative electrostimulation and neurography – Fig. 3a-c. The procedure was accomplished without surgical complications; the originating fascicle of the tumour did not show an action potential or peripheral response under stimulation, which allowed its safe transection without the need of reconstruction. The tumour was then resected en bloc and preserved for histological examination. The patient was then shortly observed and later discharged with a follow-up plan, consisting of dates for changes of wound dressing, suture removal and a plan for rehabilitation. The postoperative period was without any complications, with the patient's painful IIIrd and IVth finger, spasms and paraesthesias subsiding shortly following the surgery. For a short period, the patient experienced hypoesthesia as well as flexion weakness of the IInd and IIIrd fingers (4+/5 based on the British Medical Research Council grading system), however these deficits resolved completely within three months after the surgery. The patient's wound on the medial aspect of the arm healed in a painless fashion per primam intentionem, with only minor signs of hypertrophy and no sensory deficits. Histological examination of the tumour verified the presence of a well-circumscribed, non-invasive neurinoma derived from Schwann cells (Antoni A type). Postoperative EMG has shown a minor lesion of the MN in the distal arm, with reinnervation activity in the abductor pollicis brevis muscle.

DISCUSSION

In general, PNT resections are accompanied with the risks of persisting neurological deficits. Successful surgeries, completely preserving PN function, make up 90% of schwannoma, 80% of solitary neurofibroma and 66% of neurofibromatosis type I. associated neurofibroma cases [7,8]. In order to decrease the risk of surgical morbidity, it is crucial that PNT patients are referred to the centres experienced in microsurgery, equipped with tools for peroperative electrophysiological monitoring and adequately prepared for unpredictable surgical complications (for example reconstruction of damaged neural structures).

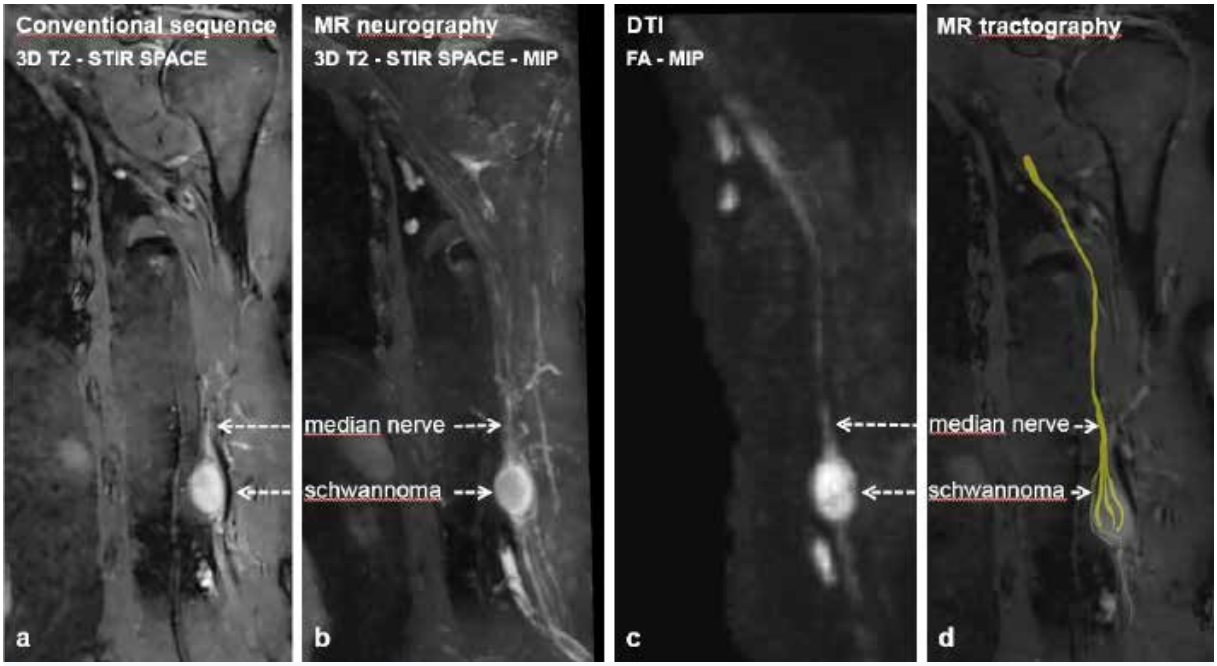

Fig. 1. Median nerve schwannoma showed using (a) conventional MRI sequence – 3D T2–STIR SPACE, (b) MRN–3D T2–STIR SPACE–MIP reconstruction, (c) DTI–FA–MIP reconstruction and (d) MRT
DTI= diffusion tensor imaging; FA= fraction anisotropy; MIP= maximum intensity projection; MRN= MR neurography; MRT= MR tractography; SPACE= sampling perfection with application optimized contrast using varying flip angle evaluation; STIR= short tau inversion recovery; T2= T2 weighted images

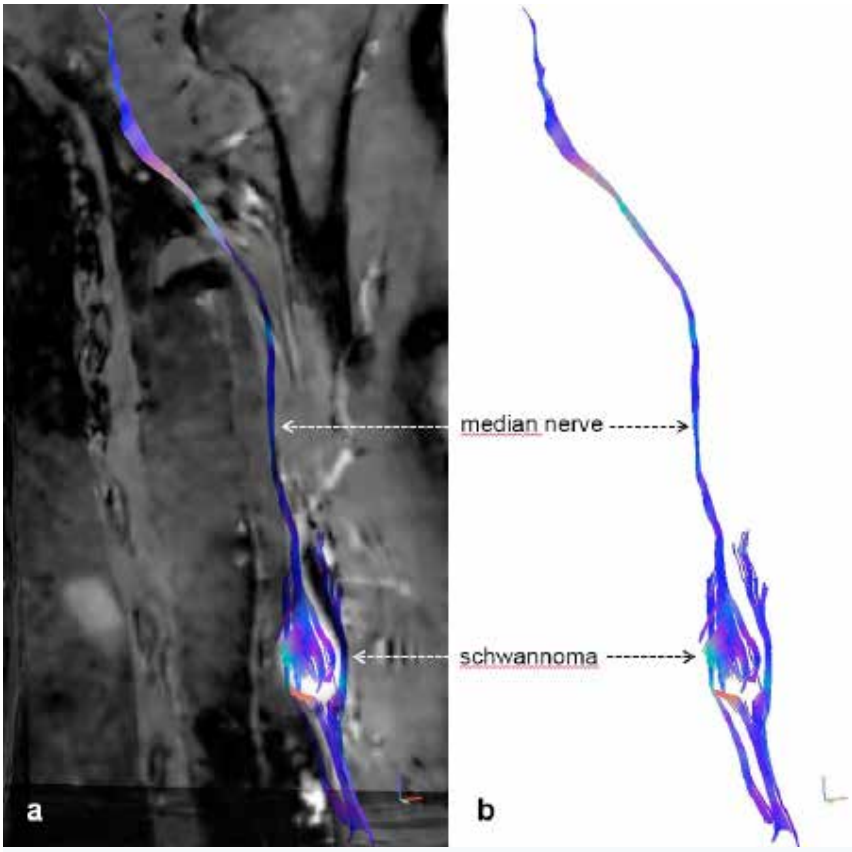

Fig. 2. 3D MR tractography (MRT) of schwannoma of the median nerve – (a) neural fascicle projection into basic structural images of conventional MRI and (b) isolated MRT reconstruction

Electrophysiological monitoring plays an important role in identifying the course of neural fascicles, which are often hidden within the tumour capsule and at risk of damage when initially entering the tumour [9]. In order to gain better understanding of PNT anatomy, as well as their relationship to neural fascicles, advanced MRI techniques can be performed. These techniques allow detailed analysis of anatomical structures as well as identifying possible surgical risks preceding the actual procedure. Possible applications of these techniques are illustrated in the presented clinical case.

Advanced MRI techniques, especially DTI and MRT, are not used routinely in diagnostic algorithms of PNT; they are mostly considered experimental tools. However, increasing technological advancements and availability of these methods, has led to their gradual integration into clinical practice, which will most likely result in their routine use within MRI diagnostic protocols in the near future. Our department has adopted the use of advanced MRI techniques in selected patients in 2013, when we designed and technically modified our own diagnostic sequences. These were tested on a control group of healthy patients as well as patients with PN disorders, after signing informed consent. All scans are performed via a 3T MRI (Siemens Magnetom Trio, Erlangen, Germany). Advanced MRI techniques differ from conventional MRI techniques in that they do not only allow detailed depiction of the affected PN as well as its disorder (MRN), but also show and quantify the functional integrity of neural fibres on a microscopic level (DTI and MRT). Due to these features, advanced MRI techniques are well-established diagnostic tools of white matter tract lesions of the brain. They have only been used for PN examination since the early 21st century.

The MRN method is a specialized MRI technique used to demonstrate PN. It allows high resolution 3D demonstration of PN course, as well as detailed visualization of PN morphology and lesions [10]. A 3T MRI is advantageous compared to 1,5T MRI, as it allows depiction of fine intraneural fascicles, which is useful for exact localization of PN pathologies [11]. Other sequences, such as 3D T2-STIR SPACE with a spatial resolution of 1 mm^3, can further complement MRN in order to visualize extremely fine neural structures. Data acquisition is followed by software processing, maximum intensity projection (MIP) reconstruction and 3D reconstruction. Individual sequences used to complement MRN as well as their setting vary, based on MRI manufacturers and strength of the magnetic field. It is necessary to tailor each diagnostic protocol based on the examined area [12].

Diffusion tensor imaging (DTI) is unique, compared to qualitative structural methods of MRN or conventional MRI, in that it provides quantitative microstructural information, which reflects functional integrity of neural fibres [13]. This technique is based on principles similar to diffusion weighted imaging (DWI), which are based on visualization of water molecule diffusion (hydrogen proton bound in water molecules) in the examined tissue. Neural axons are a type of tissue, in which this process is heavily influenced by fibre microstructure. Water molecules diffuse most efficiently in a direction parallel to the long axis of neurons. Diffusion perpendicular to the neuron axis is limited due to the presence of myelin sheaths and neuronal membranes, which inhibit this process (anisotropic diffusion) [14]. Damage or degradation of neuronal membranes or myelin sheaths, which can be caused by a variety of pathological processes, leads to a decrease in fraction anisotropy (FA), an increase of the apparent diffusion coefficient (ADC) and can be detected using DTI [15]. FA and ADC are the most widely used scalar maps of the diffusion tensor. Consequent software processing of the obtained data allows 3D reconstruction of neural tracts – MR tractography (MRT). In order to obtain better anatomical context of the nerve, MRT allows projection of these reconstructed images into images of conventional

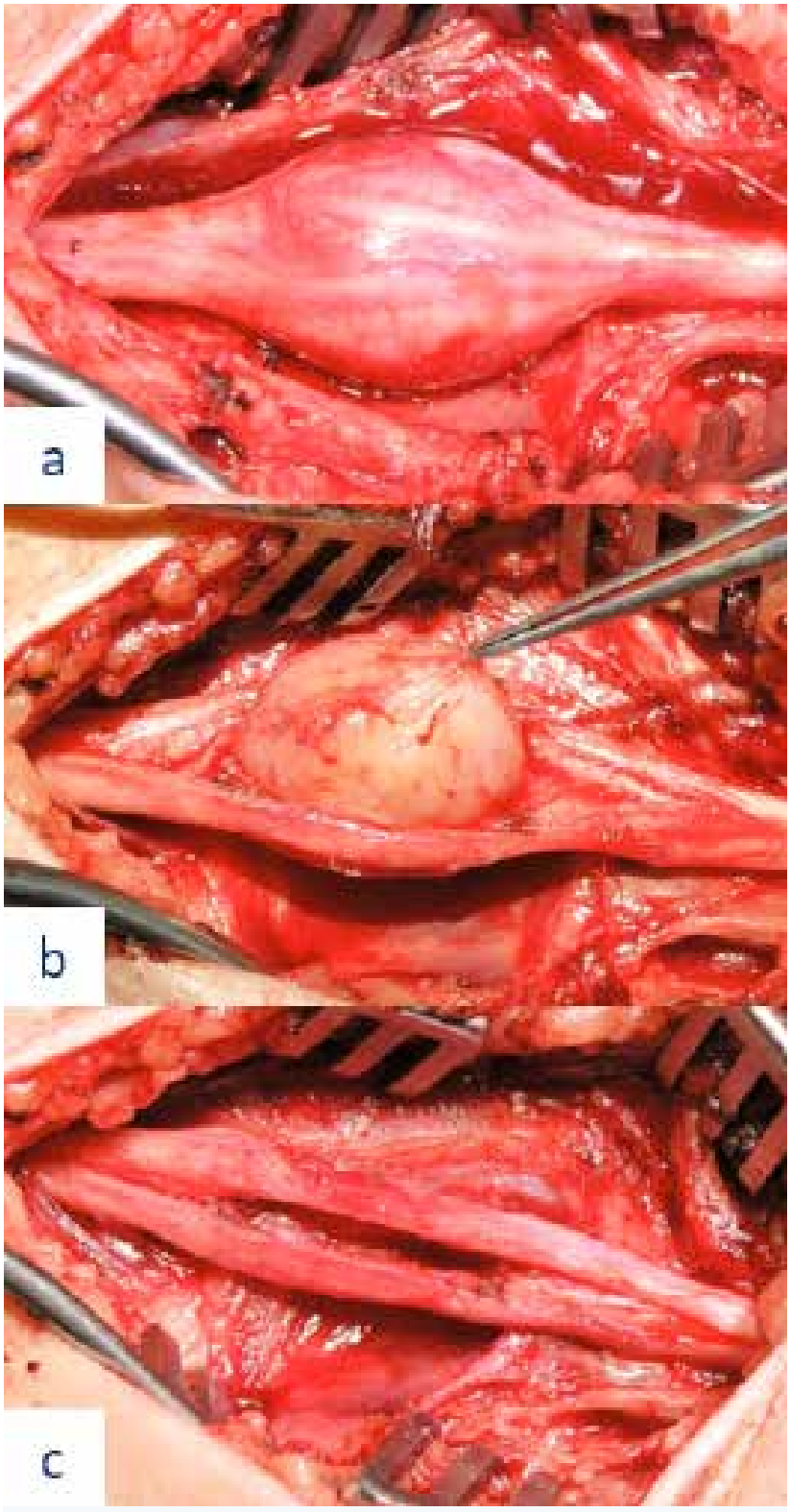

Fig. 3. Peroperative image of the median nerve schwannoma resection – (a) fascicle course on the surface of the tumour preceding tumour resection, (b) microsurgical tumour resection, and (c) preserved neural structures following radical tumour resection.

MRI sequences [13]. The disadvantage of DTI include, motion artefacts, which prevent the acquisition of usable images, or differentiation between neural and muscle fibres. These technical issues can be partially reduced with the use of adequate MR array coils, optimization of imaging protocols reducing their length or post-processing.

CONCLUSION

Advanced MRI techniques allow us to obtain detailed structural and microstructural information concerning PN disorders including PNTs. They expand the range of diagnostic tools available for the diagnosis of PNTs and allow optimal surgical planning, potentially decreasing the risks of patient morbidity. Technological advancements will most likely result in further improvement of these methods and their gradual integration into MRI diagnostic protocols used in clinical practice.

REFERENCES

1. Midha R, Zager EL. *Surgery of peripheral nerves: a case-based approach.* 1st ed. New York: Thieme Medical Publishers, Inc; 2008. Chapter 49, Schwannoma; p. 231-235.
2. Kim DH, Murovic JA, Tiel RL, Moes G, Kline DG. A series of 397 peripheral neural sheath tumors: 30-year experience at Louisiana State University Health Sciences Center. *J Neurosurg.* 2005 Feb;102(2):246-55.
3. Russell SM. Preserve the nerve: microsurgical resection of peripheral nerve sheath tumors. *Neurosurgery.* 2007 Sep;61(3 Suppl):113-7.
4. Levi AD, Ross AL, Cuartas E, Qadir R, Temple HT. The surgical management of symptomatic peripheral nerve sheath tumors. *Neurosurgery.* 2010 Apr;66(4): 833-40.
5. Matejcík V, Benetín J, Danis D. Our experience with surgical treatment of the tumours of peripheral nerves in extremities and brachial plexus. *Acta Chir Plast.* 2003;45(2):40-5.
6. Ball JR, Biggs MT. Operative steps in management of benign nerve sheath tumors. *Neurosurg Focus.* 2007 Jun 15;22(6):E7.
7. Mackinnon SE. *Nerve Surgery.* 1st ed. New York: Thieme Medical Publishers, Inc; 2015. Chapter 18, Tumours of the peripheral nervous system: p. 530-571.

8. Kim DH, Midha R, Murovic JA, Spinner RJ, Teil R. *Kline and Hudson's Nerve Injuries: Operative Results for Major Nerve Injuries, Entrapments and Tumours.* 2nd ed. Philadelphia: Saunders Elsevier; 2008. Chapter 23, Tumours involving nerve: p. 433-472.
9. Sova M, Neuman E, Vybíhal V, Fadrus P, Šprláková A, Křen L. Naše zkušenosti s chirurgickou léčbou tumorů periferních nervů. *Cesk Slov Neurol N.* 2015; 78/111(6): 694-698.
10. Chhabra A, Flammang A, Padua A Jr, Carrino JA, Andreisek G. Magnetic resonance neurography: technical considerations. *Neuroimaging Clin N Am.* 2014 Feb;24(1):67-78. doi: 10.1016/j.nic.2013.03.032.
11. Chhabra A, Madhuranthakam AJ, Andreisek G. Magnetic resonance neurography: current perspectives and literature review. *Eur Radiol.* 2018 Feb;28(2):698-707. doi: 10.1007/s00330-017-4976-8.
12. Ibrahim I, Tintěra J, Škoch A, Jírů F. MR traktografie mozku a MR neurografie periferních nervů. *Ces Radiol.* 2017;71(4): 345-352.
13. Jeon T, Fung MM, Koch KM, Tan ET, Sneag DB. Peripheral nerve diffusion tensor imaging: Overview, pitfalls, and future directions. *J Magn Reson Imaging*. 2018;47(5):1171-89.
14. Keřkovský M, Šprláková-Puková A, Kašpárek T, Fadrus P, Mechl M, Válek V. Diffusion tensor imaging – současné možnosti MR zobrazení bílé hmoty mozku. *Cesk Slov Neurol N.,* 2010;73/106(2):136–42.
15. brahim I, Tintěra J. Teoretické základy pokročilých metod magnetické rezonance na poli neurověd. *Ces Radiol.* 2013;67(1):9-19.

This study was supported by a grant of AZV MZ CR No. 17-28587A.

Corresponding author:

Ivan Humhej, M. D.

Department of Neurosurgery, J. E. Purkyně University, Masaryk Hospital
Sociální péče 12A
401 13 Ústí nad Labem
Czech Republic
E-mail: ivan.humhej@kzcr.eu

PEDICLED PECTORALIS MAJOR FLAP IN HEAD AND NECK RECONSTRUCTION – TECHNIQUE AND OVERVIEW

Dvořák, Z.[a,b,c], Pink, R.[a,d], Michl, P.[a,d], Heinz, P.[a,d], Tvrdý, P.[a,d]

[a] Department of Oral and Maxillofacial Surgery, University Hospital Olomouc, Czech Republic
[b] Department of Plastic and Aesthetic Surgery, St. Anne`s University Hospital, Brno, Czech Republic
[c] Faculty of Medicine, Masaryk University, Brno, Czech Republic
[d] Faculty of Medicine, Palacky University, Olomouc, Czech Republic

ACTA CHIRURGIAE PLASTICAE, 60, 1, 1018, pp. 14-21

SUMMARY

The pedicled pectoralis major flap was the original workhorse flap for head and neck reconstruction. Over time, it became the secondary choice for oropharyngeal reconstruction with the implementation of free-soft tissue transfers. Nowadays, a polymorbid patient is primarily indicated for pedicled pectoralis major flap reconstruction, other indications include combinations of pedicled pectoralis major flap with free microvascular flap, salvage reconstruction due to complications, salvage reconstruction due to free flap failure and salvage reconstruction due to recurrent or extended primary disease. Pedicled pectoralis major flap can be successfully used for specific oropharyngeal defects, even primary resections, especially for less cooperative patients and patients after extensive neck dissection. Improving the flap harvesting techniques can reduce undesired complications in specific cases of oropharyngeal reconstruction. Flap morbidity in these cases remains comparable to morbidity of patients who had undergone free flap reconstruction. Pedicled pectoralis major flap remains valid reconstruction tool that should be included in the armamentarium of each surgeon dealing with reconstruction of the head and neck.

KEYWORDS

Oral cancer, pedicled pectoralis major flap, pectoralis muscle flap, head and neck reconstruction

INTRODUCTION

For over 30 years, since the description by Ariyan [1,2], the pedicled pectoralis major (PPM) flap was the "workhorse" flap for head and neck cancer reconstruction [3]. It was gradually replaced by versatile free-flaps with success rates of 94%–98%, fewer complications, better overall functional outcome [4–11] and minimal morbidity [12,13]. Current trends in free-style perforator flaps have further improved cosmetic and functional results and decreased donor site morbidity [14–16]. One disadvantage of this technique is however longer surgical procedure with higher risk of complications due to prolonged anesthesia [12,17]. In developing countries, PPM flap is the flap of first choice [18,19] with large numbers of patients referred and with a success rate of 98%–100% [20–22]. In developed countries, the PPM flap is not often the flap of first choice [23–25].

ADVANTAGES AND DISADVANTAGES

PPM flap technique advantages include relatively quick and easy elevation of the flap, reliability and versatility in terms of sufficient mass, span of transposed tissue and a relatively good reach to oropharynx [24,25,20,21,23]. Compared to free flaps, the operation time using PPM flap is reduced because there is no need for microvascular anastomosis. A team of two surgeons can perform the procedure (as well as for free flap technique). The flap elevation itself is faster and the only prolongation may be construction of a cervical tunnel. It can be concluded, that for the team of surgeons trained in microsurgery, the overall reconstruction time using PPM flap will be shorter than the time of the same trained team using free flap technique [11,26–28]. Shortening the procedure reduces the incidence of medical and surgical complications [29], and the absence of microvascular anastomosis decreases the risk of flap failure due to vascular problems. These factors should be taken into account especially for immunocompromised patients [30].

Based on empirical findings, the inpatient stay duration after PPM flap surgery is usually 14 days [31], which is the same as for free flap technique [28,32], though longer [26,33] and shorter [9,25] times are reported. Assuming an experienced microsurgical team and possibility of rapid surgical revision, the reliability of pedicled flaps and free flaps is comparable and ranges between 93% and 98%.

The greatest cos ts of free flap reconstruction technique are related to the creation of a microsurgical team and implementation of the new technique. The costs go beyond

instruments and material costs such as purchase of surgical microscope, micro instrumentation, suturing material, clips and other equipment needed for intensive care units [28,34–38]. They also include high initial microsurgery team training costs.

The disadvantages of the PPM flap technique results from the general characteristics of pedicled flaps: limited arc of flap rotation precluding use in reconstruction of soft palate and maxilla defects; the reach of the flap is externally to the level of the zygomatic arch and inside to the superior tonsillar field [9].

Other drawbacks of PPM flap include formation of a contacting band and tissue excess at the reconstruction site [39]. This can be successfully mitigated (even after radiotherapy), however, by cutting the vascular pedicle without compromising flap viability [40] and muscle twitching can be eliminated using botulinum toxin [41].

Another drawback can be considered the greater mass of the PPM flap that cannot be compared to thin and pliable free flaps [26]. For this reason, the PPM flap is unsuitable for reconstruction of superficial intraoral defects. It is suitable, however, for cases that require a large volume of tissue, e.g. major resection of tongue and floor of the oral cavity. In case of superficial defects, the use of PPM flap reduces the quality of speech and swallowing, compared to the thin and pliable free flap [8,42]. Moreover, secondary thinning of the PPM flap is complicated by fibrotic changes and impaired tissue viability after radiotherapy, which frequently follows the surgical procedure.

Most PPM flap comparison studies published to date have been based on the Chinese flap [9]. This is relatively hairless and the abundance of hair was often cited as one of the disadvantages of the PPM flap. Currently, the anterolateral thigh flap (ALTF) is considered the "workhorse" flap for oropharyngeal defects, especially in Asian publications [4,7,13]. Measured by its "hairiness", it is comparable to the PPM flap and the hairiness of the flap in the mouth diminishes after radiotherapy and can be further reduced using laser depilation.

PPM flap achieves similar results compared to the use of free tissue transfer of gracilis muscle [39]. The extended vertical lower trapezius island myocutaneous flap (TIMF) in comparison to PPM flap has greater arc of rotation, larger skin island and fewer small defects but it is necessary to rotate the patient and it is also more bulky [43]. Different texture and color of the skin is also considered a disadvantage of PPM flap, but these characteristics are similar for all types of flaps that are harvested from the body below the clavicle (including free flaps).

The most significant morbidity after the harvesting of PPM flap occurs at the donor site. In some cases the following complications may occur:
– disfigurement of the front of the chest with the disruption of typical contour of anterior axillary fold
– depression at the muscle harvesting site
– asymmetrical shift of nipple-areola complex
– extensive scars (endoscopically assisted elevation is used to reduce the incidence of scars of PPM flap) [44].

Limited range of neck motion may occur after radical neck dissection. "Frozen shoulder" and debilitating shoulder dysfunction may occur if the accesorius nerve was interrupted [45,46]. These symptoms do not occur in cases of selective neck dissection where the PPM flap elevation increases the morbidity and dysfunction of the shoulder [47] – paradoxically, patients who undergo radical or modified radical neck dissection suffer less shoulder dysfunction, if PPM flap procedure has been used [48]. Elevation of the PPM flap reduces shoulder and neck function in all cases [49]. The shoulder movement restriction or reduced functional capability can be assessed only by prospective studies using indices such as shoulder

Advantages	Disadvantages
Quick and easy elevation	Limited arc of rotation
Short time of surgery	Limited length of flap pedicle
Stable and reliable anatomy	Significant abundance
Universal design	Limited pliability (questionable)
Contains muscle and skin island	Supravicular bulge or neck string (questionable)
Microsurgical instrumentation is not necessary	Different texture and color of skin island
Without the risk and necessity of microsurgical anastomosis	Hair growth
Rare flap failure	Chest donor site deformity
Large secondary intervention rarely necessary	Frequent small early complications
Most complications can be handled conservatively or using minor surgical interventions.	Neck movement restriction (questionable)
Indications	**Contraindications**
- Large defects of tongue and oral cavity	- Small or superficial intraoral defects
- Lateral part of the mandible	- Anterior segment of the mandible
- Oropharynx, lateral wall in particular	- Soft palate reconstruction
- Neck defects, vessel depletion	- Maxilla reconstruction
- Closure of neck and mandible fistulas	

Table 1. Advantages, disadvantages, indications and contraindications of PPM flap

strength and range of motion (ROM), neck ROM and subjective quality of life assessment using the shoulder pain and disability index (SPAD) and neck disability index (NDI) [50]. PPM flap reconstruction has a small but significant negative effect on upper extremity dysfunction and also neck ROM limitations [48–50]. In general, we can say that patients, who undergo primary reconstruction using PPM flap, often have significantly reduced working capacity, mainly due to preoperative polymorbidity.

Patients with oropharyngeal cancer who underwent radical surgical procedure followed by the reconstruction using PPM flap technique displayed comparable overall morbidity to patients using a free flap technique. However, patients who undergo free flap reconstruction show better results for speech and shoulder function. They also experience better "mood" than patients who undergo PPM flap reconstruction [51].

Advantages and disadvantages of PPM are summarized in Table 1.

COMPLICATIONS

The number of complications depends primarily on:
- the type of procedure (primary or salvage procedure)
- location of reconstruction
- patient morbidity
- nutritional status
- previous radiotherapy
- duration of surgery
- experience of the surgeon

The rate of complications increases significantly if the flap is raised with a rib [52] or if two skin islands are harvested [22,34]. From this point of view, these procedures can be considered obsolete and it is better to replace them with a combination of PPM flap and free flap, which is associated with lower complication rate.

According to the literature, the incidence of total flap failure ranges from 0% to 8% [34,37,38,51]. In reports after 2009, flap losses are reported from 0% to 2.5% [18,19,24,53–56]. The major partial skin flap loss varies from 1% to 7%, minor losses range from 13% to 29%, the incidence of orocutaneous fistulae ranges from 7%–29% and the incidence of infections is about 8% –39% [9,21,24,33,34,57–60]. The overall incidence of any complication is fairly high and ranges from 16% to 68% [20–23,34,37,53,56–59,61,62]. This is higher than for free flaps. However, most of the complications are minor [33] and handled using a conservative wound management technique. The need for a secondary surgical correction is 2%–12% [9,33,55,57], however, there are also studies reporting higher rates of major complications [53,61].

Complications at the donor sites are reported in approximately 5% to 8% [9,23,55,63–65]. Because most patients are polymorbid, there is a higher risk of hematoma [23,34] that can be exacerbated by concomitant hepatic dysfunction.

CURRENT INDICATIONS FOR PPM

Avery [66] reported the frequency of PPM flap use for primary reconstruction in the range of 5%–62%. In the US, the frequency was reported at around 5% [25]. However, a review of the US Academic Otolaryngology program revealed that the PPM flap was used two to three times more often than free flaps [67]. PPM flap is always considered only as a second choice after free flaps and the reasons for their primary use varies. The most common indications for primary use of PPM are financial, associated comorbities, extended radical neck dissection, vessel depletion in the neck and previous different malignancies [9,17,32,36,37].

The other reasons for PPM flap are the area for reconstruction (lateral part of the mandible, parotidectomy) in order to reduce the donor site morbidity after bone harvesting and also the greater success in reconstructions in polymorbid patients [66,68].

Another preferred choice is the use of PPM in combination with a free flap [23,25,34], rather than using the combination of two free flaps that increases the risk of reconstruction failure. This is suitable only for lateral mandible defects and in patients after extensive neck dissection, especially if radiotherapy is planned.

More frequent use of PPM flap is reported in salvage reconstruction following complications [25], but in these scenarios it is necessary to take into account the increased risk of complications (compared to primary reconstruction). In this case, the main indications include pharyngeal fistula [69,70] and exposure of great vessels [71]. Other indications may be orocutaneous fistula, obliteration of dead space in the neck [38], osteoradionecrosis, exposure of hardware or wound breakdown.

PPM flap is also employed as a salvage reconstruction following free flap failure [24], especially for large composite defects, in comorbidities, in malnutrition, wound breakdown, infection, lack of blood vessels in the neck and in psychological causes. On the other hand, Wei and other

Primary reconstruction	Associated comorbidities
	Extended radical neck dissection
	Depletion of blood vessels in the neck
	Previous malignant disease
In combination with free flap	Lateral mandible
	Extended radical neck dissection
Salvage reconstruction following complication	Pharyngeal fistula
	Exposure of large vessels
Salvage reconstruction following free flap failure	
Salvage reconstruction due to recurrence or primary disease resumption	

Table 2. Summary of PPM flap indications for head and neck reconstructions

authors recommend another free flap for its similar risk of failure as PPM flap for salvage reconstruction after free flap failure [8,10,72]. This procedure is performed at some centers in developed countries but in some cases the success of secondary free flap reconstruction has been reported as only 73% [73]. Very high success rates of reconstruction using PPM flap is confirmed in other studies although partial skin flap loss may occur more frequently [4,34,59].

Last but not least, salvage reconstruction in prevailing or recurrent primary disease is also a typical indication for PPM flap [74]. In these patients, the PPM remains twice as frequently used as free flap reconstruction [66]. An overview of indications is summarised in Table 2.

FLAP ELEVATION TECHNIQUES

The flap can be elevated as muscular, musculocutaneous or osteomyocutaneous (including the fifth rib into the flap) [52]. Planning of the position and size of the flap is best done on a standing patient before surgery. The position of the lower border of the pectoralis major muscle can be marked when the patient is standing with hands on hips and muscles clenched. It is also advisable to mark the direction of the dominant vascular pedicle. The line from the shoulder tip to the xiphoid determines the direction of the lower part of the flap and position of the thoracoacromial artery [2]. The upper part of the flap and start of the pedicle can be marked by plotting the perpendicular from the middle of the clavicle to xiphoid acromial-line [75]. The lateral thoracic artery can be found using Doppler along a line extending from the apex of the axilla to the iliac crest [76].

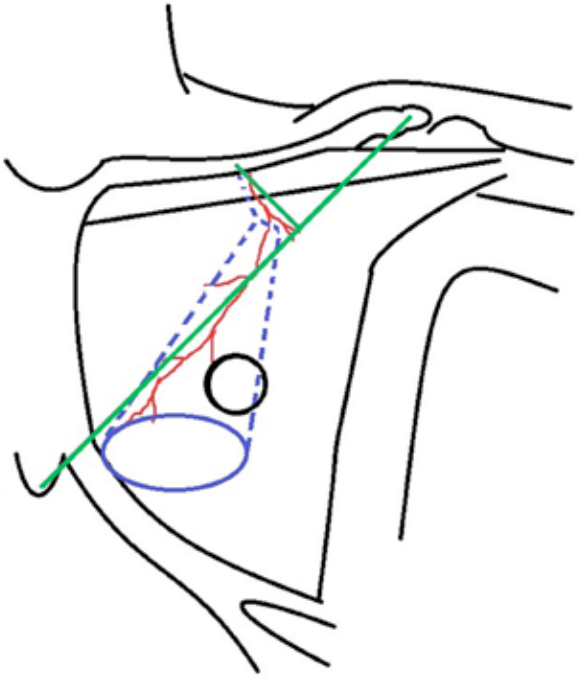

Fig. 1. Preoperative planning: green color - the line from the shoulder tip to xiphoid and its perpendicular from middle of the clavicle showing expected position of pectoral branches of thoracoacromial artery; blue color – skin island design; dashed blue line – muscle dissection design

The best way to design the skin island of the PPM flap for oropharyngeal localisation of defects is medially below the nipple-areola complex and above the pectoralis major muscle [22]. Extension of the skin island over the rectus sheath should be avoided – especially in the case of female patients with ptotic breast and the skin island placed submammary [55]. When only a small skin island is needed, it is better to harvest a large one and de-epithelise redundant areas [77]. Preoperative planning is shown in Figure 1.

Raising the flap begins with incision of the lower portion of the skin paddle. The incision continues towards the projection of the beginning of the vascular bundle or towards the axilla (if it is planned to spare the deltopectoral flap) [78]. After exposing the lateral part of the sternocostal portion of the major pectoral muscle, in a lateromedial direction, the lower portion of the major pectoral muscle is dissected from the chest wall. After the exposure of the medial portion of the muscle, we proceed with the elevation of a muscle strip with the skin island. Dissection from the thorax is done bluntly using fingers in the direction towards the clavicle. Underlying nutritional vessels may be visible on the upper half of the muscle. In case the lateral thoracic artery is visible, it is better to include it together with the pectoral minor muscle into the flap or dissect this muscle in the proximity of the acromion to enable release and transposition of the

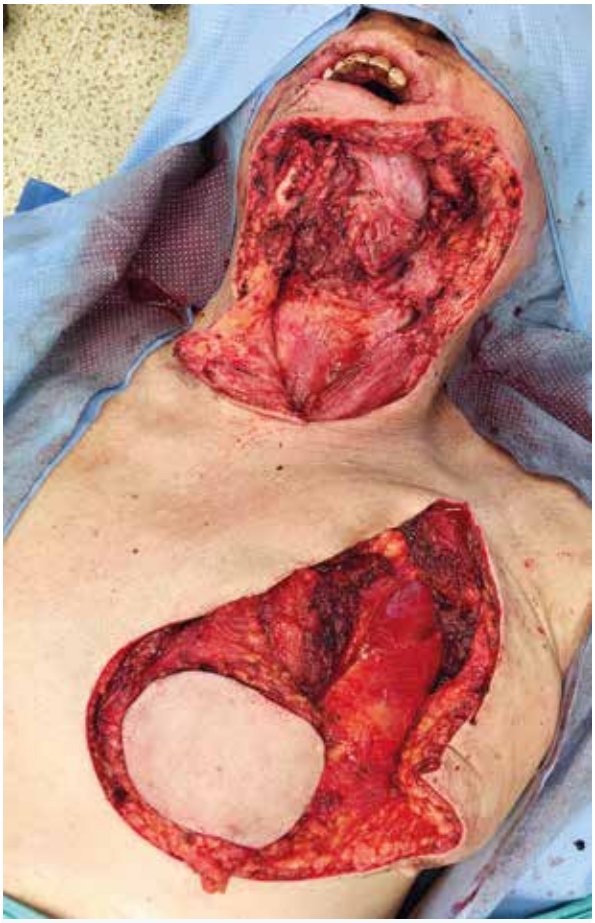

Fig. 2. Raising of the PPM flap

Fig. 3. Elevated PPM flap with the pedicle reduced only to the vessels

blood vessel [79,80], not to restrict the arc of flap rotation and disrupt the dominant nutrition of the laterocaudal part of the flap [81]. When the pedicle is visible and with thoracoacromial vessels at the base of pectoral major muscle, we continue with the reduction of muscle tissue around the vascular pedicle until a thin muscle strip ending at the border of the clavicular and sternocostal portion of the muscle is left. In this part, the vascular pedicle is safely under the muscle tissue and clavicular portion of the muscle does not have to be included in the flap (Fig. 2, Fig. 3), [2,82]. It is simply severed (34), not to limit the arc of the rotation of the pedicle around the clavicle. Afterwards, the pedicle is dissected, branches of lateral pectoral nerve are identified and tested through neurostimulation and cut off to a length of 3–4 cm to achieve denervation of the muscle. These two maneuvers (cut through the portion of the muscle and denervation) mitigate the occurrence of muscle abundance above the clavicle and contracture band on the lateral side of the neck. Following creation of a subcutaneous tunnel, blunt dissection above the clavicle towards the site of neck dissection, prepares the route for flap transportation to the site of the defect. Smaller flaps can be transposed subclaviculary without damaging the subclavian vessel [21,83]. Flap donor site on the chest is closed directly (Fig. 4) or with a lateral thoracic flap. [76,84].

DENERVATION AND FLAP TRANSPOSITION

A number of surgeons perform transection of the lateral pectoral nerve, which has a similar course to the pectoral branches of the thoracoacromial trunk and contributes to the innervation of the pectoral muscle [20]. The bulges or contracting folds in place of the vascular pedicle are often reported in the literature (based on assumptions that are best described for cases of transposition of the latissimus dorsi muscle for breast reconstruction). Flap volume changes have been observed in this field of surgery interventions thanks to complete trans-sectioning of the muscle tendon from its insertions and release of both ends of the muscle regardless of the denervation of the muscle (85). This finding is supported by Kääriäinen et al. and Szychta et al. who found no difference in volume regardless whether the thoracodorsal nerve was transected or not [86,87]. Furthermore, in one prospective study, Szychta et al. showed that patients with latissimus dorsi muscle denervation achieved lower scores for pain, animation of reconstructed breast and also scored higher on overall satisfaction with their reconstructed breasts [87]. Nerve resection is performed in a length of 3–4 cm based on a study by Schroegendorfer et al., who observed twitching in a sample of 74 patients undergoing latissimus dorsi breast reconstruction. At 12 and 24-month follow-up, all patients with an intact thoracodorsal nerve showed twitching of the muscle. However, only 50% (67.9% after 24 months) of the denervated patients showed twitching. No patient had twitching at

Fig. 4. The immediate postoperative result

12 or 24 months postoperatively if more than 4 cm of the nerve was excised and the length of nerve resection was predictive of twitching. [88]. Another factor that is fundamentally involved in any supraclavicular bulge is strict disconnection of the transferred muscle flap and rotation around the clavicle only on the vascular bundle [2,82].

Kanno et al. reported [79] that preservation of the lateral thoracic artery and use of the subclavian route are alternatives to ensure sufficient blood supply and an increased rotation arc of PPM flap. This approach enables harvesting of the flap that can reach the entire oral cavity, including the infraorbital region, palate, middle pterygopalatine fossa and nasopharynx, with no risk of vascular insufficiency, to the distal skin island. Greater reach of the flap has not been confirmed by anatomical studies [89]. According to literature resources, most authors did not use the subclavian route.

CONCLUSION

PPM flap cannot be considered obsolete or a secondary choice for reconstruction of the head and neck in developed countries. Currently the "renaissance" of pedicled flaps with improvement in flap elevation techniques means that PPM flap may be optimal for: specific oropharyngeal defects, even primary resections, especially for less cooperative patients and patients with extensive neck dissection, extensive resection of cervical lymph nodes, free flap failure, depleted blood vessels in the neck, combined with free flap and in case of disease recurrence or progression. PPM flap remains a valid reconstruction tool that should be included in the armamentarium of surgeons involved in reconstruction of the head and neck, especially in the elderly and thus polymorbid population.

Acknowledgements: This research received no funding from public agencies, commercial, or non-profit sectors.

Conflict of interest statement: The authors state that there are no conflicts of interest regarding the publication of this article.

REFERENCES

1. Ariyan S. The pectoralis major myocutaneous flap. A versatile flap for reconstruction in the head and neck. *Plast Reconstr Surg*. 1979 Jan;63(1):73-81.
2. Ariyan S. Further experiences with the pectoralis major myocutaneous flap for the immediate repair of defects from excisions of head and neck cancers. *Plast Reconstr Surg.* 1979 Nov;64(5):605-12.
3. Ariyan S. The functional pectoralis major musculocutaneous island flap for head and neck reconstruction. *Plast Reconstr Surg*. 1990 Oct;86(4):807-8.
4. Kucur C, Durmus K, Uysal I, et al. Management of complications and compromised free flaps following major head and neck surgery. *Eur Arch Otorhinolaryngol*. 2016 Jan;273(1):209-13.
5. Costa H, Zenha H, Sequeira H, et al. Microsurgical reconstruction of the maxilla: Algorithm and concepts. *J Plast Reconstr Aesthet Surg*. 2015 May;68(5):e89-e104.
6. Nouraei SA, Middleton SE, Hudovsky A, et al. Role of reconstructive surgery in the management of head and neck cancer: a national outcomes analysis of 11,841 reconstructions. *J Plast Reconstr Aesthet Surg*. 2015 Apr;68(4):469-78.
7. Thiele OC, Seeberger R, Engel M, Freier K, Hoffmann J. Development of the clinical use of distant flaps for head and neck reconstruction. *J Craniomaxillofac Surg*. 2014 Jan;42(1):79-83.
8. Corbitt C, Skoracki RJ, Yu P, Hanasono MM. Free flap failure in head and neck reconstruction. *Head Neck.* 2014 Oct;36(10):1440–5.
9. O'Neill JP, Shine N, Eadie PA, Beausang E, Timon C. Free tissue transfer versus pedicled flap reconstruction of head and neck malignancy defects. *Ir J Med Sci.* 2010 Sep;179(3):337–43.
10. Germain MA, Hartl DM, Marandas P, Juliéron M, Demers G. Free flap reconstruction in the treatment of tumors involving the hard palate. *Eur J Surg Oncol.* 2006 Apr;32(3):335-9.
11. McCrory AL, Magnuson JS. Free tissue transfer versus pedicled flap in head and neck reconstruction. *Laryngoscope*. 2002 Dec;112(12):2161-5.
12. Eckardt A, Fokas K. Microsurgical reconstruction in the head and neck region: an 18-year experience with 500 consecutive cases. *J Craniomaxillofac Surg*. 2003 Aug;31(4):197-201.
13. Zhang C, Sun J, Zhu H, et al. Microsurgical free flap reconstructions of the head and neck region: Shanghai experience of 34 years and 4640 flaps. *Int J Oral Maxillofac Surg.* 2015 Jun;44(6):675-84.
14. Cho A, Hall FT. Review of perforator flaps in head and neck cancer surgery. *Curr Opin Otolaryngol Head Neck Surg*. 2016 Oct;24(5):440-6.
15. Lyons AJ. Perforator flaps in head and neck surgery. *Int J Oral Maxillofac Surg.* 2006 Mar;35(3):199-207.
16. Bravo FG, Schwarze HP. Free-style local perforator flaps: concept and classification system. *J Plast Reconstr Aesthet Surg*. 2009 May;62(5):602-8; discussion 609.
17. Singh B, Cordeiro PG, Santamaria E, Shaha AR, Pfister DG, Shah JP. Factors associated with complications in microvascular reconstruction of head and neck defects. *Plast Reconstr Surg.* 1999 Feb;103(2):403-11.
18. Gadre KS, Gadre P, Sane VD, Halli R, Doshi P, Modi S. Pectoralis major myocutaneous flap--still a workhorse for maxillofacial reconstruction in developing countries. *J Oral Maxillofac Surg*. 2013 Nov;71(11):2005.e1-2005.e10.
19. Metgudmath RB, Metgudmath AR, Metgudmath VV, Roy B, Das AT. Versatility of pectoralis major myocutaneous flap in oncosurgery and its role in developing countries. *Indian J Otolaryngol Head Neck Surg*. 2013 Jul;65(Suppl 1):80-4.
20. Milenović A, Virag M, Uglesić V, Aljinović-Ratković N. The pectoralis major flap in head and neck reconstruction: first 500 patients. *J Craniomaxillofac Surg*. 2006 Sep;34(6):340-3.
21. Vartanian JG, Carvalho AL, Carvalho SM, Mizobe L, Magrin J, Kowalski LP. Pectoralis major and other myofascial/myocutaneous flaps in head and neck cancer reconstruction: experience with 437 cases at a single institution. *Head Neck*. 2004 Dec;26(12):1018-23.
22. Bhola N, Jadhav A, Borle R, Khemka G, Kumar S, Shrivastava H. Is there still a role for bilobed/bipaddled pectoralis major myocutaneous flap for single-stage immediate reconstruction of post ablative oncologic full-thickness defects of the cheek? *Oral Maxillofac Surg.* 2015 Jun;19(2): 125-31.
23. Liu R, Gullane P, Brown D, Irish J. Pectoralis major myocutaneous pedicled flap in head and neck reconstruction: retrospective review of indications and results in 244 consecutive cases at the Toronto General Hospital. *J Otolaryngol.* 2001 Feb;30(1):34-40.
24. Avery CM, Gandhi N, Peel D, Neal CP. Indications and outcomes for 100 patients managed with a pectoralis major flap within a UK maxillofacial unit. Int J Oral *Maxillofac Surg.* 2014 May;43(5):546-54.
25. Schneider DS, Wu V, Wax MK. Indications for pedicled pectoralis major flap in a free tissue transfer practice. *Head Neck.* 2012 Aug;34(8): 1106-10.
26. Mallet Y, El Bedoui S, Penel N, Ton Van J, Fournier C, Lefebvre JL. The free vascularized flap and the pectoralis major pedicled flap options: comparative results of reconstruction of the tongue. *Oral Oncol*. 2009 Dec;45(12):1028-31.

27. Smeele LE, Goldstein D, Tsai V, et al. Morbidity and cost differences between free flap reconstruction and pedicled flap reconstruction in oral and oropharyngeal cancer: Matched control study. *J Otolaryngol.* 2006 Apr;35(2):102-7.
28. Tsue TT, Desyatnikova SS, Deleyiannis FW, et al. Comparison of cost and function in reconstruction of the posterior oral cavity and oropharynx. Free vs pedicled soft tissue transfer. *Arch Otolaryngol Head Neck Surg*. 1997 Jul;123(7):731-7.
29. Ferrier MB, Spuesens EB, Le Cessie S, Baatenburg de Jong RJ. Comorbidity as a major risk factor for mortality and complications in head and neck surgery. *Arch Otolaryngol Head Neck Surg*. 2005 Jan;131(1):27–32.
30. Gerude MF, Dias FL, de Farias TP, Albuquerque Sousa B, Thuler LC. Predictors of postoperative complications, prolonged length of hospital stay, and short-term mortality in elderly patients with malignant head and neck neoplasm. *ORL J Otorhinolaryngol Relat Spec.* 2014;76(3): 153-64.
31. Kekatpure VD, Trivedi NP, Manjula BV, Mathan Mohan A, Shetkar G, Kuriakose MA. Pectoralis major flap for head and neck reconstruction in era of free flaps. *Int J Oral Maxillofac Surg.* 2012 Apr;41(4):453-7.
32. Schusterman MA, Horndeski G. Analysis of the morbidity associated with immediate microvascular reconstruction in head and neck cancer patients. *Head Neck.* 1991 Jan-Feb;13(1):51-5.
33. Chepeha DB, Annich G, Pynnonen MA, et al. Pectoralis major myocutaneous flap vs revascularized free tissue transfer: complications, gastrostomy tube dependence, and hospitalization. Arch Otolaryngol *Head Neck Surg*. 2004 Feb;130(2):181-6.
34. Mehta S, Sarkar S, Kavarana N, Bhathena H, Mehta A. Complications of the pectoralis major myocutaneous flap in the oral cavity: a prospective evaluation of 220 cases. *Plast Reconstr Surg.* 1996 Jul;98(1):31–7.
35. Ord RA. The pectoralis major myocutaneous flap in oral and maxillofacial reconstruction: a retrospective analysis of 50 cases. *J Oral Maxillofac Surg*. 1996 Nov;54(11):1292-5; discussion 1295-6.
36. Talesnik A, Markowitz B, Calcaterra T, Ahn C, Shaw W. Cost and outcome of osteocutaneous free-tissue transfer versus pedicled soft-tissue reconstruction for composite mandibular defects. *Plast Reconstr Surg*. 1996 May;97(6):1167-78.
37. Kroll SS, Evans GR, Goldberg D, et al. A comparison of resource costs for head and neck reconstruction with free and pectoralis major flaps. *Plast Reconstr Surg.* 1997 Apr;99(5):1282–6.
38. Shektman A, Silver C, Strauch B. A re-evaluation of hypopharyngeal reconstruction: pedicled flaps versus microvascular free flaps. *Plast Reconstr Surg.* 1997 Dec;100(7):1691–6.
39. Jing SS, O'Neill T, Clibbon JJ. A comparison between free gracilis muscle flap and pedicled pectoralis major flap reconstructions following salvage laryngectomy. *J Plast Reconstr Aesthet Surg*. 2014 Jan;67(1):17-22.
40. van Rossen ME, Verduijn PV, Mureau MA. Survival of pedicled pectoralis major flap after secondary myectomy of muscle pedicle including transection of thoracoacromial vessels: does the flap remain dependent on its dominant pedicle? *J Plast Reconstr Aesthet Surg*. 2011 Mar;64(3):323-8.
41. Trignano E, Dessy LA, Fallico N, et al. Treatment of pectoralis major flap myospasms with botulinum toxin type A in head and neck reconstruction. *J Plast Reconstr Aesthet Surg.* 2012 Feb;65(2):e23-8.
42. Su WF, Hsia YJ, Chang YC, Chen SG, Sheng H. Functional comparison after reconstruction with a radial forearm free flap or a pectoralis major flap for cancer of the tongue. *Otolaryngol Head Neck Surg.* 2003 Mar;128(3):412-8.
43. Chen WL, Wang YY, Zhang DM, Fan S, Lin ZY. Extended vertical lower trapezius island myocutaneous flap versus pectoralis major myocutaneous flap for reconstruction in recurrent oral and oropharyngeal cancer. *Head Neck*. 2016 Apr;38 Suppl 1:E159-64.
44. Turkmen A, Perks AG. Endoscopic assisted harvest of the pedicled pectoralis major muscle flap. *Br J Plast Surg*. 2005 Mar;58(2):170–4.
45. Kuntz AL, Weymuller EA Jr. Impact of neck dissection on quality of life. *Laryngoscope*. 1999 Aug;109(8):1334-8.
46. Rogers SN, Ferlito A, Pellitteri PK, Shaha AR, Rinaldo A. Quality of life following neck dissections. *Acta Otolaryngol*. 2004 Apr;124(3):231-6.
47. Cappiello J, Piazza C, Giudice M, De Maria G, Nicolai P. Shoulder disability after different selective neck dissections (levels II-IV versus levels II-V): a comparative study. *Laryngoscope.* 2005 Feb;115(2):259-63.
48. Refos JW, Witte BI, de Goede CJ, de Bree R. Shoulder morbidity after pectoralis major flap reconstruction. *Head Neck*. 2016 Aug;38(8):1221-8.
49. Sun Q, Guo S, Wang D, Xu N, Jin SF, Wang CC. Does pectoralis major flap harvesting induce upper extremity dysfunction? *J Int Med Res.* 2015 Aug;43(4):555-9.
50. Moukarbel RV, Fung K, Franklin JH, et al. Neck and shoulder disability following reconstruction with the pectoralis major pedicled flap. *Laryngoscope*. 2010 Jun;120(6):1129-34.
51. Hsing CY, Wong YK, Wang CP, et al. Comparison between free flap and pectoralis major pedicled flap for reconstruction in oral cavity cancer patients--a quality of life analysis. *Oral Oncol.* 2011 Jun;47(6):522-7.
52. Shunyu NB, Medhi J, Laskar HA, Lyngdoh N, Syiemlieh J, Goyal A. 5th Rib Osteo-pectoralis Major Myocutaneous Flap-Still a Viable Option for Mandibular Defect Reconstruction. *Indian J Otolaryngol Head Neck Surg*. 2014 Dec;66(4):414-7.
53. Ribeiro Salles Vanni CM, de Matos LL, Faro Junior MP, et al. Enhanced morbidity of pectoralis major myocutaneous flap used for salvage after previously failed oncological treatment and unsuccessful reconstructive head and neck surgery. *ScientificWorld Journal.* 2012;2012:384179.
54. McLean JN, Carlson GW, Losken A. The pectoralis major myocutaneous flap revisited: a reliable technique for head and neck reconstruction. *Ann Plast Surg*. 2010 May;64(5):570–3.
55. Ramakrishnan VR, Yao W, Campana JP. Improved skin paddle survival in pectoralis major myocutaneous flap reconstruction of head and neck defects. *Arch Facial Plast Surg*. 2009 Sep-Oct;11(5):306–10.
56. Pinto FR, Malena CR, Vanni CM, Capelli Fde A, Matos LL, Kanda JL. Pectoralis major myocutaneous flaps for head and neck reconstruction: factors influencing occurrences of complications and the final outcome. *Sao Paulo Med J*. 2010 Dec;128(6):336-41.
57. IJsselstein CB, Hovius SE, ten Have BL, Wijthoff SJ, Sonneveld GJ, Meeuwis CA, et al. Is the pectoralis myocutaneous flap in intraoral and oropharyngeal reconstruction outdated? *Am J Surg.* 1996 Sep;172(3):259–62.
58. Wilson JS, Yiacoumettis AM, O'Neill T. Some observations on 112 pectoralis major myocutaneous flaps. *Am J Surg.* 1984 Feb;147(2):273–9.
59. Shah JP, Haribhakti V, Loree TR, Sutaria P. Complications of the pectoralis major myocutaneous flap in head and neck reconstruction. *Am J Surg.* 1990 Oct;160(4):352–5.
60. Wang CH, Wong YK, Wang CP, et al. Risk factors of recipient site infection in head and neck cancer patients undergoing pectoralis major myocutaneous flap reconstruction. *Eur Arch Otorhinolaryngol.* 2015 Nov;272(11):3475-82.
61. Khan F, Hameed H, Khan NU, Shah SA. Head and neck reconstruction; our experience of pectoralis major myocutaneous pedicled flap. *Professional Med J.* 2011 Jun;18(2):310-316.
62. Rudes M, Bilić M, Jurlina M, Prgomet D. Pectoralis major myocutaneous flap in the reconstructive surgery of the head and neck--our experience. *Coll Antropol.* 2012 Nov;36 Suppl 2:137-42.
63. Biller HF, Baek SM, Lawson W, Krespi YP, Blaugrund SM. Pectoralis major myocutaneous island flap in head and neck surgery: Analysis of complications in 42 cases. *Arch Otolaryngol.* 1981 Jan;107(1):23-6.
64. Baek SM, Lawson W, Biller HF. An analysis of 133 pectoralis major myocutaneous flaps. *Plast Reconstr Surg.* 1982 Mar;69(3):460–9.
65. Ossoff RH, Wurster CF, Berktold RE, Krespi YP, Sisson GA. Complications after pectoralis major myocutaneous flap reconstruction of head and neck defects. *Arch Otolaryngol.* 1983 Dec;109(12):812-4.

66. Avery C. A perspective on the role of the pectoralis major flap in oral and maxillofacial oncology surgery. *Oral Surg.* 2014;7(3):130–142.
67. Bhaya MH, Har-el G. Resident training in head and neck flap reconstruction in U.S. academic otolaryngology programmes. *J Laryngol Otol.* 2001 Feb;115(2):119–21.
68. Avery CM, Crank ST, Neal CP, Hayter JP, Elton C. The use of the pectoralis major flap for advanced and recurrent head and neck malignancy in the medically compromised patient. *Oral Oncol.* 2010 Nov;46(11): 829-33.
69. Kroll SS, Goepfert H, Jones M, Guillamondegui O, Schusterman M. Analysis of complications in 168 pectoralis major myocutaneous flaps used for head and neck reconstruction. *Ann Plast Surg.* 1990 Aug;25(2):93–7.
70. Virós Porcuna D1, León Vintró X, López Vilas M, Pujol Olmo A, Masià Ayala J, Quer Agustí M. Pectoralis major flaps. Evolution of their use in the age of microvascularized flaps. *Acta Otorrinolaringol Esp.* 2008 Jun-Jul;59(6):263-8.
71. Zbar RI, Funk GF, McCulloch TM, Graham SM, Hoffman HT. Pectoralis major myofascial flap: a valuable tool in contemporary head and neck reconstruction. *Head Neck.* 1997 Aug;19(5):412–8.
72. Wei FC, Celik N, Yang WG, Chen IH, Chang YM, Chen HC. Complications after reconstruction by plate and soft-tissue free flap in composite mandibular defects and secondary salvage reconstruction with osteocutaneous flap. *Plast Reconstr Surg.* 2003 Jul;112(1):37-42.
73. Ross G, Yla-Kotola TM, Goldstein D, et al. Second free flaps in head and neck reconstruction. *J Plast Reconstr Aesthet Surg*. 2012 Sep;65(9): 1165-8.
74. Liu HL, Chan JY, Wei WI. The changing role of pectoralis major flap in head and neck reconstruction. *Eur Arch Otorhinolaryngol.* 2010 Nov;267(11):1759-63.
75. Serafin, D. The gracilis muscle-musculocutaneous flap. In: *Atlas of Microsurgical Composite Tissue Transplantation.* Philadelphia: WB Saunders Company; c1996.p.293-299.
76. Chan YW, Ng RW, Yuen AP. Lateral thoracic flap for donor site repair of pectoralis major myocutaneous flap. *J Plast Reconstr Aesthet Surg*. 2009 Aug;62(8):1004-7.
77. Kim EK, Yang SJ, Choi SH. Method to help ensure survival of a very small skin paddle of pectoralis major musculocutaneous flap in head and neck reconstruction. *Head Neck.* 2013 Aug;35(8):E237-9.
78. Nayak BB, Nilamani M. Single stage reconstructions in head and neck surgery using deltopectoral and pectoralis major myocutaneous flaps. *Indian J Plast Surg.* 2012 Jan;45(1):151-3.
79. Kanno T, Nariai Y, Tatsumi H, Karino M, Yoshino A, Sekine J. A modified pectoralis major myocutaneous flap technique with improved vascular supply and an extended rotation arc for oral defects: A case report. *Oncol Lett.* 2015 Nov;10(5):2739-2742.
80. Po-Wing Yuen A. Preservation of lateral thoracic artery to improve vascular supply of distal skin without compromising pedicle length in harvesting pectoralis major myocutaneous flap. *J Plast Reconstr Aesthet Surg*. 2006;59(12):1433-5.
81. Kim DM, Jeon A, Kim KY, et al. Neurovascular distribution within the abdominal head of the pectoralis major muscle: Application to breast and flap surgery. *Clin Anat.* 2015 May;28(4):520-6.
82. Temiz G, Şirinoğlu H, Yeşiloğlu N, et al. A salvage maneuver for the caudal part of the pectoralis major muscle in the reconstruction of superior thoracic wall defects: The pectoralis kite flap. *J Plast Reconstr Aesthet Surg.* 2015 May;68(5):698-704.
83. de Azevedo JF. Modified pectoralis major myocutaneous flap with partial preservation of the muscle: a study of 55 cases. *Head Neck Surg*. 1986 May-Jun;8(5):327–31.
84. Tashiro K, Harima M, Mito D, et al. Preoperative color Doppler ultrasound assessment of the lateral thoracic artery perforator flap and its branching pattern. *J Plast Reconstr Aesthet Surg.* 2015 Jun;68(6):e120-5.
85. Bonomi S, Salval A, Sorbi F, Settembrini F. To sever or not the thoracodorsal nerve in latissimus dorsi flap breast reconstruction. *Plast Reconstr Surg.* 2012 Aug;130(2):367e-368e; author reply 368e-369e.
86. Kääriäinen M, Giordano S, Kauhanen S, Helminen M, Kuokkanen H. No need to cut the nerve in LD reconstruction to avoid jumping of the breast: a prospective randomized study. *J Plast Reconstr Aesthet Surg*. 2014 Aug;67(8):1106-10.
87. Szychta P, Butterworth M, Dixon M, Kulkarni D, Stewart K, Raine C. Breast reconstruction with the denervated latissimus dorsi musculocutaneous flap. Breast. 2013 Oct;22(5):667-72.
88. Schroegendorfer KF, Hacker S, Nickl S, Vierhapper M, Nedomansky J, Haslik W. Latissimus dorsi breast reconstruction: how much nerve resection is necessary to prevent postoperative muscle twitching? *Plast Reconstr Surg.* 2014 Dec;134(6):1125–9.
89. Vanni CM, Pinto FR, de Matos LL, de Matos MG, Kanda JL. The subclavicular versus the supraclavicular route for pectoralis major myocutaneous flap: a cadaveric anatomic study. *Eur Arch Otorhinolaryngol.* 2010 Jul;267(7):1141-6.

Corresponding author:

Zdeněk Dvořák, M.D., Ph.D.

Department of Plastic and Aesthetic Surgery,
St. Anne's University Hospital,
Berkova 34, 612 00 Brno, Czech Republic
E-mail: zdenek.dvorak@fnusa.cz

SECURING INTRAORAL SKIN GRAFTS TO THE FLOOR OF THE MOUTH: CASE REPORT AND TECHNIQUE DESCRIPTION

Kenny, E. M.[1], Egro, F. M. [1], Solari, M. G.[1,2]

[1]Department of Plastic Surgery, University of Pittsburgh Medical Center, Pittsburgh, PA, USA
[2]Department of Otolaryngology, University of Pittsburgh Medical Center, Pittsburgh, PA, USA

ACTA CHIRURGIAE PLASTICAE, 60, 1, 2018, 22-25

SUMMARY

In this report, we describe an innovative bolstering technique that resulted in successful skin graft take to the floor of the mouth when the teeth and alveolus were unavailable for anchorage.

KEYWORDS

Skin grafting, graft fixation, graft securing, intraoral cavity; floor of mouth

INTRODUCTION

Due to the minimal bulk, ease of harvest, acceptable functional and aesthetic results, and low complication rates, skin grafts are commonly used in reconstruction of small to moderate-sized defects in the oral cavity [1]. Graft survival is largely dependent on two requirements: sufficient vascularity of the recipient bed and immobilization of the graft for subsequent adherence to the defect [2]. Stabilizing an intraoral skin graft poses unique challenges – an uneven wound bed, high mobility of the region, and accumulation of salivary secretions, which can all lead to skin graft failure [3]. To overcome these challenges, the skin graft is usually immobilized by means of a bolster. Multiple case reports have previously described techniques to immobilize the graft to the cheek using a bolster dressing for 5–7 days while the graft is most susceptible to shearing forces [3–5]. Less commonly than the cheek, intraoral skin grafts can be required in reconstruction of the floor of the mouth. In these occurrences, bolsters may be secured to the teeth or the alveolus. However, the difficulty arises in patients who have undergone an anterior marginal or composite mandibulectomy. To our knowledge, no reports have been presented in the literature on how best to bolster a skin graft to the floor of the mouth for adequate immobilization and adherence to the defect. In this report, we describe a bolstering technique that resulted in successful skin graft take to the floor of the mouth.

CASE REPORT

A 47-year-old man sustained a gunshot wound to the face resulting in significant bone and soft tissue loss. After multiple debridements, fixation of facial fractures, left-sided osteocutaneous free fibula flap for mandible reconstruction (defect spanning from angle to angle), and right-sided osteocutaneous free fibula flap for midface reconstruction, the patient desired dental restoration. To facilitate dental implants, the free fibula skin paddle used to reconstruct the floor of mouth was excised, the anterior sulcus recreated, and a U-shaped 7x4 cm split-thickness skin graft (STSG) was placed. This procedure was performed approximately 28 months following mandible reconstruction and 14 months following midface reconstruction. The STSG was harvested from the lateral aspect of the left thigh. The donor area was prepped with mineral oil and the STSG was harvested using a Zimmer® dermatome (Zimmer, Inc., Warsaw, IN) at a thickness of 0.4 millimeters. The STSG was then pie crusted by creating slits of approximately 5 mm in length, spread throughout the graft using a No.10 blade scalpel. The graft was trimmed to fit the defect, which covered the floor of the mouth and neo-gingivobuccal sulcus. The fenestrated graft was secured with a running 4-0 chromic suture along the defect perimeter and several interrupted sutures securing the graft to the wound base. The donor site was covered with OPSITE (Smith & Nephew, Hull, UK) dressing for three days. The OPSITE dressing was then exchanged with Xeroform (Kendall Brands of Covidien, Mansfield, MA) and left in place until it peeled off on its own.

TECHNIQUE

The graft was then immobilized to the floor of mouth using the bolstering technique described below:

– The bolster is created by mixing cotton balls with bacitracin and rolling them into four sheets of Xeroform (Kendall Brands of Covidien, Mansfield, MA).

– The bolster is then conformed to the shape of the skin graft that needs to be immobilized (Fig. 1A).

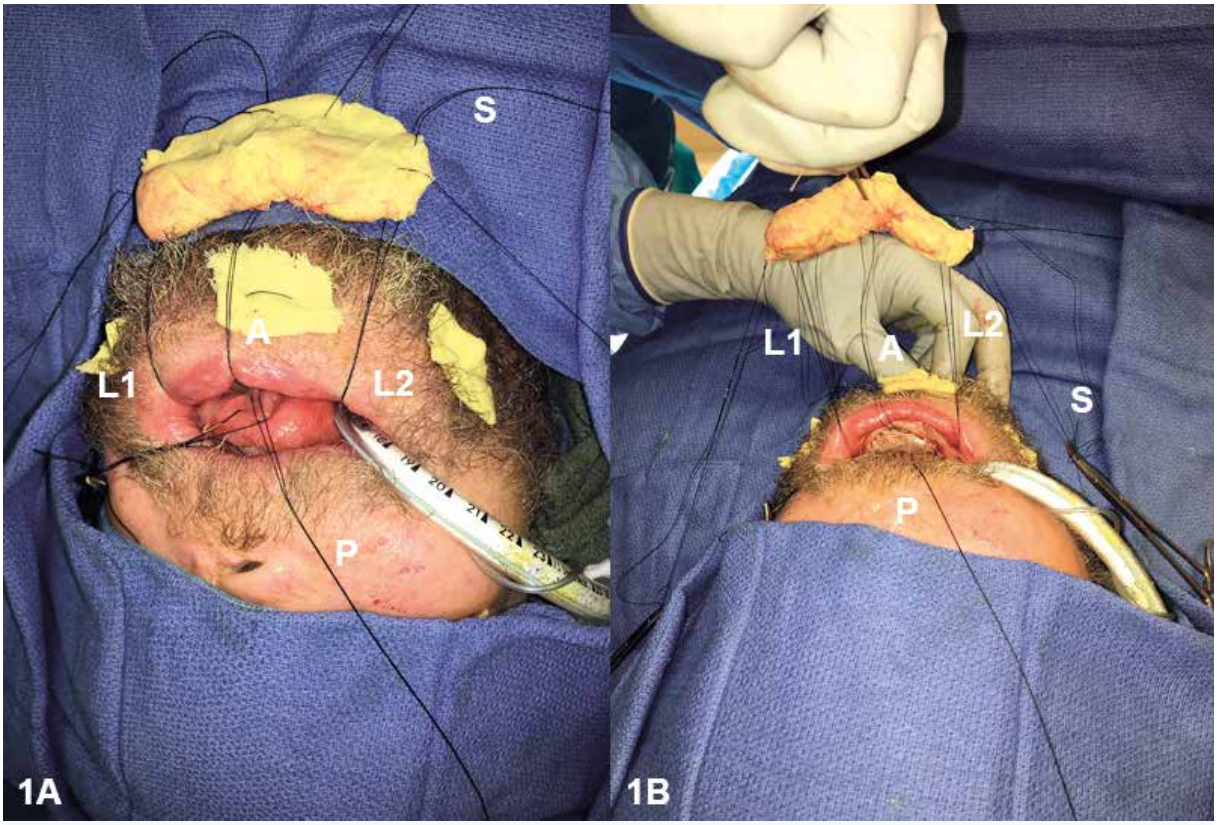

Fig. 1 (A, B) Application of the intraoral bolster. The bolster was secured using 2-0 silk-tie-over sutures at the anterior (A), posterior (P), and lateral (L1, L2) poles. A safety suture (S) was passed through the bolster

– The four poles of the bolster are secured using 2-0 silk tie-over sutures. The anterior suture is passed through the bolster, lower lip, and external Xeroform layer, then mattressed back through the Xeroform, lower lip, and bolster (Fig. 1B). The lateral sutures are passed through the inferior part of the cheek in a similar fashion. The posterior suture is passed through the frenulum. Care should be taken to avoid devascularizing the tissue with the bolster suture. In this case, both facial arteries were sacrificed for the free flap, and flow to the lower lip was retrograde. The cheek sutures were placed to avoid compromising flow to the lip.

– The ends of the 2-0 silk ties are knotted in the middle of the bolster (Fig. 2A, 2B).

– A safety suture can also be passed through the bolster and delivered out of the oral cavity and secured to the cheek with Steri-Strips (3M Health Care, St. Paul, MN) or Tegaderm (3M Health Care, St. Paul, MN). In the case of bolster dislodgement, the bolster can be pulled out by the extra-oral tie to avoid airway compromise.

– The schematic view in Figure 3 illustrates how the sutures were placed in order to secure the bolster.

– The bolster was removed on day 5 following STSG placement.

DISCUSSION

Due to the inherent mobility of the region, bolsters are commonly required to stabilize intraoral skin grafts. Proper bolster placement requires application of constant and evenly distributed pressure in order to provide maximal contact between the graft and the recipient bed, reduction in shearing forces, and prevention of the accumulation of salivary secretions, hematoma, or seroma under the graft [6,7]. An ideal bolster should apply a force that exceeds interstitial pressure (15 to 20 mmHg) while not exceeding capillary perfusion pressure (25 to 30 mmHg) [8]; this balance is key to adequately immobilize the graft and close dead space while not limiting perfusion and risking graft breakdown. Although pressure was not quantitatively assessed in this patient, adequate bolster pressure can be determined based on the appearance of the sutures compressing the Xeroform bolster and the complete immobilization of the bolster over the floor of the mouth. Care should be taken to avoid excessive tension over the facial skin to prevent ulceration.

Bolster dressings aid in the distribution of pressure over a skin graft, and a number of techniques have been described to secure the bolster to the wound bed. These techniques include traditional tie-over [1,9], tie-over modifications [10–12], and externally secured [13,14] bolster methods. Despite the rich literature describing techniques for securing a bolster for skin graft adherence, to our knowledge a description of how best to secure a bolster to the floor of the mouth, especially after resection of the mandible, has never been described. In this article, the authors present a bolstering technique to secure a skin graft to the floor of the mouth when the alveolus and teeth are unavailable.

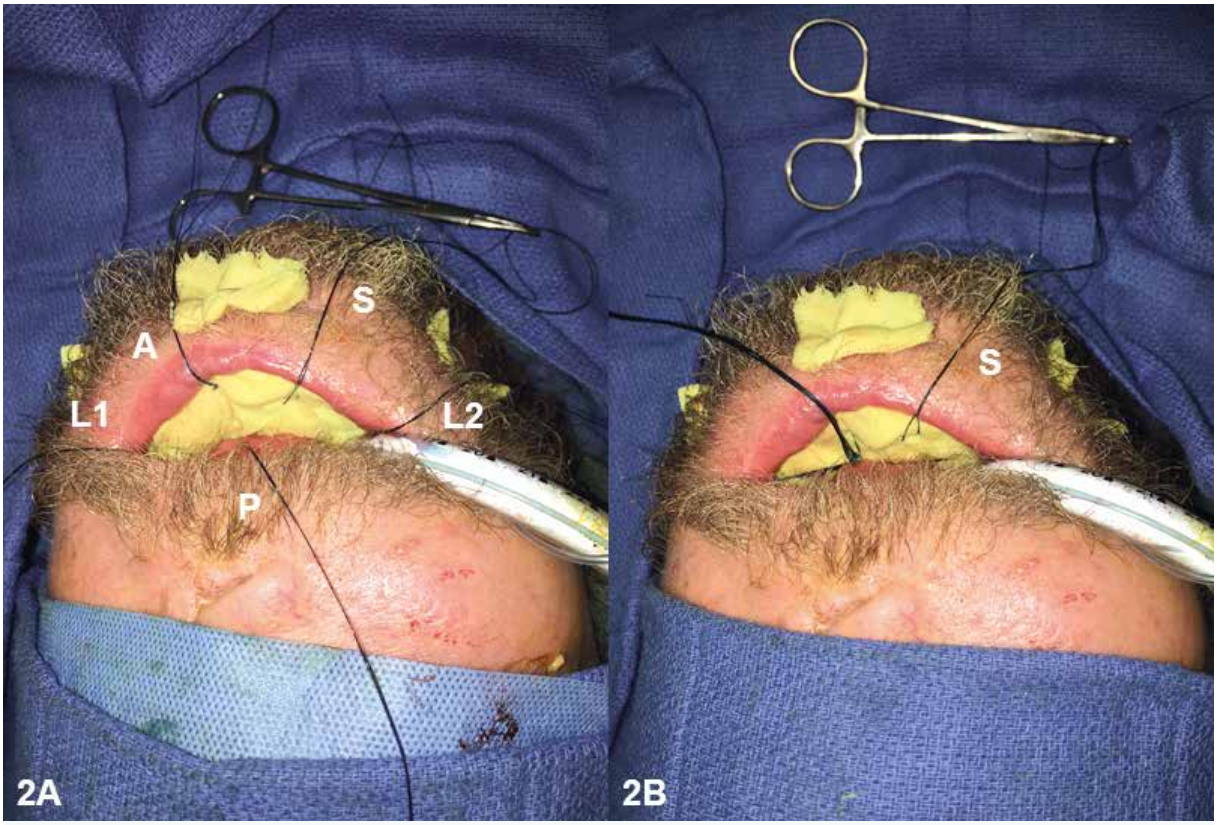

Fig 2. (A, B) Securing of the intraoral bolster. The bolster was placed over the graft, and the ends of the 2-0 silk ties were tied in the middle of the bolster. A safety suture (S) remained outside of the oral cavity for ease of removal in the case of bolster dislodgement and airway compromise

Alternative methods of skin graft fixation or surgical reconstructive options warrant mention. Other materials to construct a bolster could be considered, which should work equally as well as the Xeroform bolster described in this case report. Bolster materials most commonly described in the literature include foam, cotton, gauze, and silicone sheets. Any of these materials would likely be effective, as the innovative transoral bolstering suture technique rather than bolster material is largely responsible for the even distribution of pressure across the skin graft. Sealant options such as fibrin glue are likely unsuitable in the oral cavity due the high level of secretions and proximity to the gastrointestinal tract. For smaller defects, alternatives to a skin graft could be considered, such as buccal mucosa grafts or local flaps; however, given the extent (7x4 cm), unusual location (floor of mouth), and reconstructed anatomy (prior midface and mandible reconstructions) in this patient, these options were not available at the time of surgery.

CONCLUSION

This technique for securing a skin graft to the floor of the mouth was well-tolerated by the patient resulting in oral competence with no complications or visible scarring. A 100% skin graft take was obtained using this technique, which is simple and effective. No significant odor, patient discomfort, or change in care related to the oral cavity were noted in this case. While we did not experience spontaneous release of the bolster or suture failure, the inclusion of a safety suture allows for prompt bolster removal should unintended bolster dislodgement occur. Vascular supply of the facial soft tissues must be considered when placing transfacial sutures to secure a skin graft bolster.

In conclusion, we describe an innovative technique to secure a skin graft in the floor of the mouth – a challenging location, for which no bolstering technique is described. This technique provided even pressure distribution and secured the bolster to allow successful skin graft take with minimal patient discomfort and no complications. While transbuccal or transcutaneous approaches are typically adequate for securing a bolster in the oral cavity, the technique described in this case report is indicated in the rare cases where skin grafting to the floor of the mouth is required.

Conflict of Interest: The authors of this study certify that they have NO affiliations with or involvement in any organization or entity with any financial interest or non-financial interest in the subject matter or materials discussed in this manuscript.

REFERENCES

1. Schramm VL Jr, Myers EN. Skin grafts in oral cavity reconstruction. *Arch Otolaryngol.* 1980 Sep;106(9):528-32.

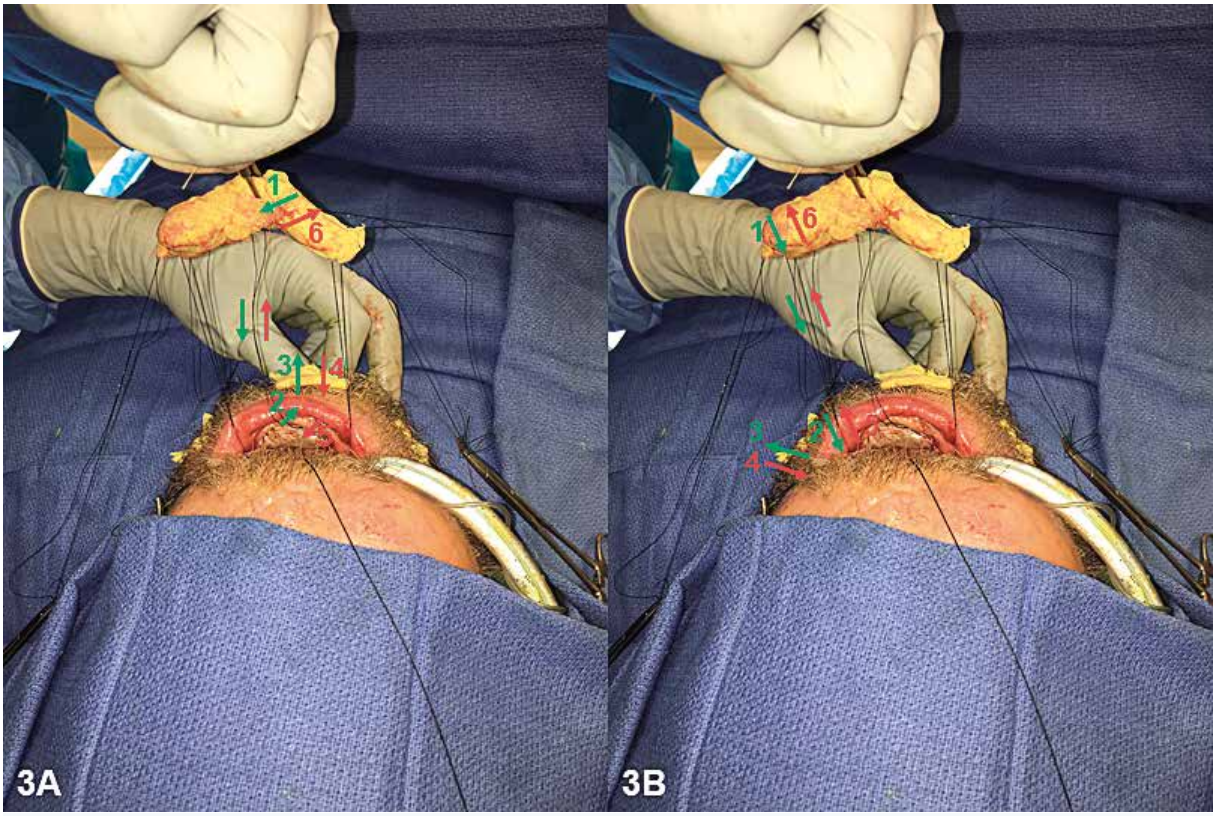

Fig 3. Scheme of the sequence of suture placement to secure the intraoral bolster. Schematic view of suture placement to secure the intraoral bolster. Green text/arrows depict the entry route of the sutures, and red text/arrows depict the exit route of the sutures. (A) The anterior sutures were run (1) through the Xeroform bolster, (2) through the graft in the anterior floor of the mouth, and (3) through the mentolabial sulcus (superior to the reconstructed osseous mandible) and an external piece of Xeroform. The suture was then run in the reverse direction: (4) through the external Xeroform and mentolabial sulcus, (5) through the graft in the anterior floor of the mouth, and (6) through the Xeroform bolster. (B) Similarly, the lateral sutures were run (1) through the Xeroform bolster, (2) through the graft in the lateral floor of the mouth, and (3) through the lateral cheek (superior to the reconstructed osseous mandible) and an external piece of Xeroform. The suture was then run in the reverse direction: (4) through the external Xeroform and lateral cheek, (5) through the graft in the lateral floor of the mouth, and (6) through the Xeroform bolster

2. Zender CA, Petruzzelli GJ. Skin grafting in oral cavity reconstruction. *Oper Tech Otolaryngol-Head Neck Surg*. 2005 Mar.16(1):24-27.
3. Qureshi SS, Chaukar D, Dcruz AK. Simple technique of securing intraoral skin grafts. *J Surg Oncol*. 2005 Feb 1;89(2):102-3.
4. Friedlander AH, Miller J. Stabilization of intraoral skin grafts to the cheek. *J Oral Surg*. 1981 Jan;39(1):63.
5. Robiony M, Forte M, Toro C, Costa F, Politi M. Silicone sandwich technique for securing intraoral skin grafts to the cheek. *Br J Oral Maxillofac Surg*. 2007 Mar;45(2):166-7.
6. Wetton L, Kwei J, Kippen J, Nicklin S, Gillies M, Walsh WR. A model of pressure distribution under peripherally secured foam dressings on a convex surface: does this contribute to skin graft loss? *Eplasty*. 2010;10:e19.
7. Blair VP, Brown JB. The use and uses of large split skin grafts of intermediate thickness. *Plast Reconstr Surg*. 1968 Jul;42(1):65-75.
8. Weiner LJ, Moberg AW. An ideal stent for reliable and efficient skin graft application. *Ann Plast Surg*. 1984 Jul;13(1):24-8.
9. Wolf Y, Kalish E, Badani E, Friedman N, Hauben DJ. Rubber foam and staples: do they secure skin grafts? A model analysis and proposal of pressure enhancement techniques. *Ann Plast Surg*. 1998 Feb;40(2):149-55.
10. Pelissier P, Martin D, Baudet J. The running tie-over dressing. *Plast Reconstr Surg*. 2000 Nov;106(6):1436-7.
11. Joyce CW, Joyce KM, Mahon N, et al. A novel barbed suture tie-over dressing for skin grafts: a comparison with traditional techniques. *J Plast Reconstr Aesthet Surg*. 2014 Sep;67(9):1237-41.
12. Westerband A, Fratianne RB. Stapled tie-over stent: a simplified technique for pressure dressings on newly applied split-thickness skin grafts. *J Burn Care Rehabil*. 1993 Jul-Aug;14(4):463-5.
13. Chaturvedi P, Pai PS, Decruz AK, et al. Extra-oral knotting of tie-over sutures: a novel technique to bolster the split thickness skin graft for a buccal mucosal defect. *J Surg Oncol*. 2003 Oct;84(2):103-4.
14. Garvey CM, Panje WR, Hoffman HT. The'parachute' bolster technique for securing intraoral skin grafts. *Ear Nose Throat J*. 2001 Oct;80(10): 720, 723.

Corresponding author:

Francesco M. Egro, MBChB MSc MRCS

Department of Plastic Surgery, University of Pittsburgh Medical Center, 3550 Terrace Street, 6B Scaife Hall, Pittsburgh, PA 15261, United States
E-mail: francescoegro@gmail.com

INTRAOSSEOUS HAEMANGIOMA OF THE ZYGOMA. CASE REPORT AND LITERATURE REVIEW

Němec, I.

Department of Otorhinolaryngology and Maxillofacial Surgery, 3rd Faculty of Medicine of Charles University and the Military University Hospital, Prague, Czech Republic

ACTA CHIRURGIAE PLASTICAE, 60, 1, 2018, pp. 26–29

SUMMARY

Intraosseous haemangioma is a benign lesion that accounts for less than 1% of all bone tumours. It is found in the zygoma only rarely. This type of tumour is more common in women than in men. The paper presents the case of a female patient with intraosseous cavernous haemangioma in the zygoma. The tumour caused a deformation of the zygoma on the left. The lesion was visible in computed tomography (CT) scans, and also in magnetic resonance imaging (MRI) scans obtained previously due to problems unrelated to the lesion. We performed complete removal of the tumour including edges of healthy bone. The defect was bridge using a titanium miniplate. A good cosmetic effect was seen after 5 months from the surgery. Follow up CT and MRI evaluation showed no recurrence or residue of the tumour. The paper also includes a review of available literature.

KEYWORDS

Haemangioma, intraosseous, zygoma

INTRODUCTION

Intraosseous haemangioma accounts for less than 1% of all bone tumours [1–6]. It is found most commonly in the spine and in the skull [2, 3, 7–9, 10]. In facial bones, a haemangioma may occur in the maxilla, mandible and in nasal bones [3, 5, 6, 8, 10]. The finding of haemangioma in the zygoma is rare [1, 3, 6, 10, 11]. This paper presents a patient with intraosseous cavernous haemangioma of the zygoma.

CASE REPORT

A 40-year-old female patient has observed a solid mass in the zygoma on the left (Fig. 1 a, b) for 8 years. In the most recent 3 months, the patient began feeling pain at the site of the mass and the mass slightly increased. The patient also observed swelling of the cheek area on the left. No injury to the cheek area was reported. Clinical assessment showed deformation of the cheek area on the left; no swelling was present and appearance of the skin was normal. Computed tomography (CT) assessment showed a clear expansion in the zygoma sized 23 x 19 x 14 mm, which was pushing the bone structure apart. The expansion showed a honeycomb structure without perifocal sclerosis. The tumour reached into the frontal and maxillary process of the zygoma. External and internal corticalis of the zygoma was thinned. No alterations were visible in soft tissues in the area of the expansion (Fig. 2 a, b). The lesion was visible already in magnetic resonance imaging (MRI) scans taken in the patient 2 years before the CT assessment. The MRI assessment was performed due to problems of the patient unrelated to the lesion. The axial T2-weighted image showed a solid expansive lesion sized 15 x 10 mm in the lower edge of the left orbit without any perifocal oedema. The left maxillary sinus was filled with air (Fig. 2 c).

Under general anaesthesia, from subciliary incision we reached the lower edge of the orbit, at the place of the mass. The tumour was completely resected. The resected tissue included a border of healthy bone. Bleeding during the surgery was minimal. The resulting defect was bridged using a titanium miniplate. No complications occurred during the postoperative period. Cavernous haemangioma was demonstrated based on histology. A good cosmetic effect was seen after 5 months from the surgery (Fig. 3 a, b). Follow up CT and MRI assessments showed no recurrence or residue of the tumour. Three-dimensional CT scan showed a postoperative defect bridged with the titanium miniplate (Fig. 4).

DISCUSSION

Intraosseous haemangioma is a benign vasoformative neoplasm or developmental condition of endothelial origin according to the World Health Organization [12]. The first haemangioma in the skull was described by Toynbee in 1845. Two tumours were present in parietal bones [13]. In 1950, Schofield was the first to describe haemangioma in the zygoma [14].

Intraosseous haemangioma most commonly develops in the 4th to 5th decade of life [4, 8, 15–17]. It is more common in women than in men [1–3, 6, 8, 9]. Various haemangioma variants are recognized [12]. Many facial haemangiomas are cavernous [15, 18]. As regards to aetiology of haemangiomas, a congenital

Fig. 1a, b. Patient with visible bulging of the cheek region on the left (arrow).

cause has been reported. In addition, a possible association with a prior trauma has been mentioned [8, 9, 19, 20].

Intraosseous haemangioma may cause swelling [2, 19] and deformity of the zygomatic region (2, 8) and of the orbit (2). Protrusion of the eye bulb and diplopia may develop [2, 9, 15, 18, 19, 20]. Strabismus may also appear [20]. Patients may suffer from pain [2, 8, 15, 18], and bleeding may occur [15, 18].

Preoperative assessments include CT and MRI [1, 9]. As reported by some authors, routine preoperative angiography is not necessary given that it may not provide evidence of blood supply in many patients [2, 3, 18, 20]. Although biopsy usually makes it possible to determine the diagnosis, it poses a risk of bleeding, which may be difficult to manage [19]. A circumscribed lesion of the zygoma was clearly visible in the CT scans. The assessment confirmed a finding of an MRI assessment performed 2 years ago. Given the extent of the finding and its localisation, angiography and biopsy were not indicated before the surgery.

Bucy and Capp in 1930 were the first to describe haemangiomas in various parts of the skeleton including the skull based

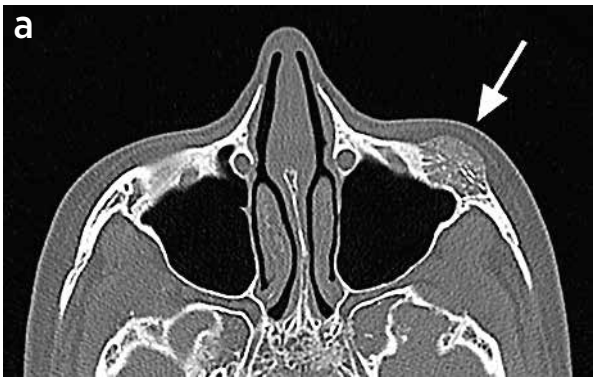

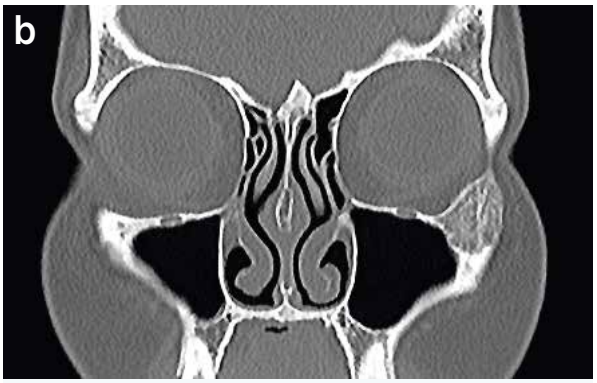

Fig. 2a, b. The CT scan shows a lesion in the left zygoma sized 23 x 19 x 14 mm. The corticalis is thinned; the surrounding soft tissues are unaltered (arrow)

Fig. 2c. MRI completed 2 years before the CT assessment. The axial T2-weighted image indicates a solid expansive lesion sized 15 x 10 mm in the lower edge of the left orbit without perifocal oedema. The left maxillary sinus is filled with air (arrow)

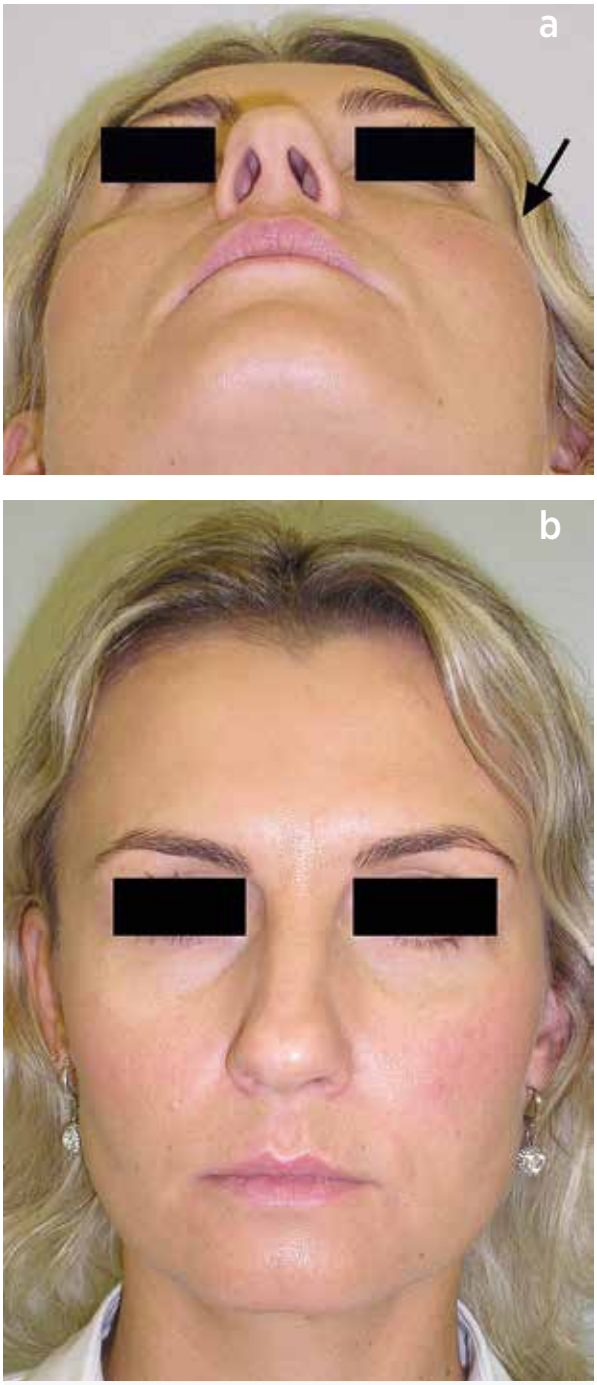

Fig. 3a, b. Condition after 5 months from the surgery (arrow)

on classic x-ray imaging [21]. In 1949, Wyke published a paper where he described haemangiomas in an x-ray image found in the skull [22]. Basic x-ray assessment of the skull indicates an intradiploic, well circumscribed expansion – rarefaction with a honeycomb configuration on axial views and a classic sunray pattern of trabeculation in tangential views [23], usually without any reactive sclerosis of the edges [17, 23]. This classic feature may be absent in many cases and instead, it may be presented only as lytic or dense bone expansive masses [23].

The trabeculae of bone and the corticalis are well visible in the CT scans. Appearance in the CT scans is variable, and the calvaria most commonly shows a characteristic sharply circumscribed expansive lesion with intact inner and outer tables and a sunburst pattern of the radiating trabeculae. "Soap bubble" and "honeycomb" configuration may also occur [1].

The surrounding soft tissues are well shown on MRI scans [1]. Some authors have advocated magnetic resonance imaging as superior for evaluation of highly vascularized lesions such as intraosseous haemangiomas [18]. As described by Moore et al., in cases where a round, potentially benign bone lesion is initially detected on MRI, the lesion may be confused with other disease processes, including malignancy [1].

Malignant transformation of the haemangioma has been described in association with radiotherapy [1, 2, 18]. In particular, fibrous dysplasia, multiple myeloma, osteoma, numerous sarcomas, metastatic tumours and osteomyelitis should be considered in the differential diagnosis [15].

In many cases, haemangioma can only be observed [15, 18]. Indications for therapy include correction of a mass effect, control of haemorrhage and cosmetic deformities [10, 15, 18]. Removal of the tumour including an edge of healthy bone usually provides a definitive cure; recurrences are rare [1]. Complete resection of the tumour is preferred also by other authors [3, 9, 11, 23]. Partial resection of the tumour can also be considered [15, 18]. Curettage of the tumour mentioned by some authors entails the risk of uncontrolled bleeding [1, 6].

Some authors recommend preoperative angiography and embolization to reduce the risk of bleeding [1, 16]. According to other publications, bleeding prevention is not necessary provided that the edge of healthy bone is also resected with the tumour [2, 3].

The zygoma is of crucial importance for aesthetics of the face and its symmetry [2]. After excision of the haemangioma, the defect should therefore be reconstructed using some implant type [3, 6, 11, 18, 20]. Primary reconstruction prevents the soft tissues from contracting [15].

Fig. 4. Three-dimensional CT scan after 5 months from the surgery. The postoperative defect of the zygoma bridged with the titanium miniplate is visible in the scan

In our patient, it was possible to resect the tumour with an edge of healthy bone. Bleeding during the surgery was minimal. The resulting bone defect was primarily bridged using a titanium miniplate, which was sufficient to prevent postoperative deformation of the cheek region, and particularly, any potential deformation of the lower eyelid (Fig. 3, 4).

CONCLUSION

Intraosseous haemangioma is a benign lesion, which is found only rarely in the zygoma. Preoperative assessments include CT and MRI. Complete resection of the tumour with an edge of healthy bone prevents any major bleeding during the surgery and any later recurrence of the tumour. Primary reconstruction of the defect should be undertaken to prevent any major cosmetic deformation of the cheek region.

REFERENCES

1. Moore SL, Chun JK, Mitre SA, Som PM. Intraosseous hemangioma of the zygoma: CT and MR findings. *AJNR Am J Neuroradiol*. 2001 Aug;22(7):1383-5.
2. Ramchandani PL, Sabesan T, Mellor TK. Intraosseous vascular anomaly (haemangioma) of the zygoma. *Br J Oral Maxillofac Surg*. 2004 Dec;42(6):583-6.
3. Konior RJ, Kelley TF, Hemmer D. Intraosseous zygomatic hemangioma. *Otolaryngol Head Neck Surg*. 1999 Jul;121(1):122-5.
4. Madge SN, Simon S, Abidin Z et al. Primary orbital intraosseous hemangioma. *Ophthalmic Plast Reconstr Surg*. 2009 Jan-Feb;25(1):37-41.
5. Dhupar V, Yadav S, Dhupar A, Akkara F. Cavernous hemangioma - uncommon presentation in zygomatic bone. *J Craniofac Surg*. 2012 Mar;23(2):607-9.
6. Savastano G, Russo A, Dell'Aquila A. Osseous hemangioma of the zygoma: a case report. *J Oral Maxillofac Surg*. 1997 Nov;55(11):1352-6.
7. Gupta T, Rose GE, Manisali M, Minhas P, Uddin JM, Verity DH. Cranio-orbital primary intraosseous haemangioma. Eye (Lond). 2013 Nov;27(11):1320-3.
8. Marshak G. Hemangioma of the zygomatic bone. *Arch Otolaryngol*. 1980 Sep;106(9):581-2.
9. Sweet C, Silbergleit R, Mehta B. Primary intraosseous hemangioma of the orbit: CT and MR appearance. *AJNR Am J Neuroradiol*. 1997 Feb;18(2):379-81.
10. Pinna V, Clauser L, Marchi M, Castellan L. Haemangioma of the zygoma: case report. *Neuroradiology*. 1997 Mar;39(3):216-8.
11. Zins JE, Türegün MC, Hosn W, Bauer TW. Reconstruction of intraosseous hemangiomas of the midface using split calvarial bone grafts. *Plast Reconstr Surg*. 2006 Mar;117(3):948-53; discussion 954.
12. Adler CP, Wold L. Haemangioma and related lesions. In: Fletcher CDM, Unni KK, Mertens F, eds. *Pathology and genetics of tumours of soft tissue and bone.* World Health Organization Classification of Tumours. Lyon: IARC Press, 2002.
13. Toynbee J. An account of two vascular tumours developed in the substance of bone. *Lancet*, 1845; 2:676.
14. Schofield AL. Primary hemangioma of the malar bone. *Br J Plast Surg*. 1950 Jul;3(2):136-40.
15. Marcinow AM, Provenzano MJ, Gurgel RK, Chang KE. Primary intraosseous cavernous hemangioma of the zygoma: a case report and literature. *Ear Nose Throat J*. 2012 May;91(5):210, 212, 214-5.
16. Colombo F, Cursiefen C, Hofmann-Rummelt C, Holbach LM. Primary intraosseous cavernous hemangioma of the orbit. *Am J Ophthalmol*. 2001 Jan;131(1):151-2.
17. Slaba SG, Karam RH, Nehme JI, Nohra GK, Hachem KS, Salloum JW. Intraosseous orbitosphenoidal cavernous angioma. Case report. *J Neurosurg*. 1999 Dec;91(6):1034-6.
18. Cheng NC, Lai DM, Hsie MH, Liao SL, Chen YB. Intraosseous hemangiomas of the facial bone. *Plast Reconstr Surg*. 2006 Jun;117(7):2366-72.
19. Riveros LG, Simpson ER, DeAngelis DD, Howarth D, McGowan H, Kassel E. Primary intraosseous hemangioma of the orbit: an unusual presentation of an uncommon tumor. *Can J Ophthalmol*. 2006 Oct;41(5):630-2.
20. Valentini V, Nicolai G, Lorè B, Aboh IV. Intraosseous hemangiomas. *J Craniofac Surg*. 2008 Nov;19(6):1459-64.
21. Bucy PC, Capp CS. Primary hemangioma of bone with special reference to the roentgenological diagnosis. *Am J Roentgenol* 1930;23:1-33.
22. Wyke BD. Primary hemangioma of the skull: a rare cranial tumor: review of the literature and report of a case, with special reference to the roentgenographic appearances. *Am J Roentgenol Radium Ther*. 1949;61:302-16.
23. Banerji D, Inao S, Sugita K, Kaur A, Chhabra DK. Primary intraosseous orbital hemangioma: a case report and review of the literature. *Neurosurgery*. 1994 Dec;35(6):1131-4.

Corresponding author:

Ivo Němec, M.D.

Department of Otorhinolaryngology and Maxillofacial Surgery,
3rd Faculty of Medicine of Charles University and the Military University Hospital Prague
U Vojenské nemocnice 1200
169 02 Prague 6, Czech Republic
E-mail: Ivo.Nemec@uvn.cz

PEDICLED PECTORALIS MAJOR FLAP IN HEAD AND NECK RECONSTRUCTION – OUR EXPERIENCE

Dvořák, Z. [a,b,c], Pink, R. [a,d], Michl, P. [a,d], Heinz, P. [a,d], Tvrdý, P. [a,d]

[a] Department of Oral and Maxillofacial Surgery, University Hospital Olomouc, Czech Republic
[b] Department of Plastic and Aesthetic Surgery, St. Anne`s University Hospital, Brno, Czech Republic
[c] Faculty of Medicine, Masaryk University, Brno, Czech Republic
[d] Faculty of Medicine, Palacky University, Olomouc, Czech Republic

ACTA CHIRURGIAE PLASTICAE, 60, 1, 2018, pp. 30–34

ABSTRACT

Introduction. The pedicled pectoralis major flaps are still harvested and mainly indicated for reconstruction in the polymorbid patient. Other indications are combinations of pedicled pectoralis major flaps with free microvascular flap, salvage reconstruction following complications, free flap failure and recurrent or extended primary disease.
Materials and Methods. We describe the pedicled pectoralis major flap in 18 patients operated on at the Department of Oral and Maxillofacial Surgery, Olomouc from 1st January 2014 to 1st December 2016.
Results. Fifteen oropharyngeal defect reconstructions were performed using pedicled pectoralis major flap (including 1 submandibular defect of the neck). Indications were primary resection in polymorbid patients in 10 cases and recurrent diseases after previous neck dissection and radiotherapy in 5 cases. Pedicled pectoralis major flap was used for secondary reconstruction in 3 cases. Complications occurred in 50 % of patients, 28 % were major and 22 % minor. Major complications included a total flap failure (defect was successfully treated with free tissue transfer of latissimus dorsi myocutaneous flap) in 1 case, plate exposure in 2 cases, large dehiscence and large hemorrhage 1 case each. Minor complications included only small dehiscences (22 %). One was associated with fluidothorax after rib harvesting (6%). There were no cases of neck contracture or supraclavicular bulge.
Conclusion. Even today, usage the pedicled pectoralis major flap in head and neck reconstruction surgery cannot be considered as an obsolete reconstructive procedure that has been completely replaced by a free microvascular flap. Innovations of flap harvesting techniques and high rate of flap survival are the main reasons why pedicled pectoralis major flap can still be primarily indicated for high-risk patients, non-cooperative patients and also for patients with extensive neck dissection. The pedicled pectoralis major flap has been the first choice in salvage surgery, in cases of a complication or free flap failure or a recurrence of a primary disease.

KEYWORDS

Oral cancer, pedicled pectoralis major flap, pectoralis muscle flap, head and neck reconstruction

INTRODUCTION

The pedicled pectoralis major flap (PPM) is usually considered as a second choice flap after free flaps and the reasons for their primary use varies. The most common indications for primary use of PPM are associated comorbities, extended radical neck dissection, neck vessel depletion for microvascular anastomosis and previous various malignancies [1–5]. Another preferred choice is the use of PPM in combination with a free flap [6–8]. Other indications for use of PPM are a salvage reconstruction following complications [8], a salvage reconstruction following free flap failure [9] and a salvage reconstruction in prevailing or recurrent primary disease [10]. The PPM used for our cases includes all these indications.

MATERIALS AND METHODS

This was a retrospective study of 18 patients operated at the Department of Oral and Maxillofacial Surgery between 1st January 2014 and 1st December 2016. 18 patients underwent reconstruction using 18 PPM flaps. All procedures were performed by two surgeons in one stage reconstruction. Patient demographic data, indications for the procedure, site and extent of primary tumor, defect itself, clinical stage of malignant disease, postoperative complications and management of these postoperative complications related to the flap were recorded and analysed.

Complications were divided into major and minor complications according to the Chepeha classification [11]. Flap failures that required surgical intervention were classified as major complications. Failures, which did not require surgical intervention and were resolved conservatively by regular bandaging, incisions, excochleations, drainages, changes of compression and antibiotic therapy, were classified as minor complications. These included: partial flap necrosis, salivary gland fistula, partial flap dehiscence, wound infec-

ID	Age	p TNM	Localisation	Operation	Flap type (M, MC, OMC)	Duration of hospitalization (days)	Minor complication	Major complication	Death*	Chemotherapy and / or radiotherapy before operation	Comment
1	61	pT3N0Mx - gr. III	Bottom of oral cavity	Primary	MC	14			NED	0	Metastasis in the neck - supraclavicular flap secondary
2	69	pT2N1Mx - gr. III	Alveoli	Primary	MC	15			DOD, 5 month	0	
3	56	pT3pN2bMx - gr. IV	Face	Primary	MC	25		large dehiscence	DOD, 4 month	0	
4	64	pT3N1Mx - gr. IV	Tongue	Primary	MC	15			NED	0	
5	54	pT2N2Mx - gr. IV	Bottom of oral cavity, tongue, alveoli	Salvage	MC	7			NED	CH, R	
6	29	pT4apN1pMX - gr.IV	Alveoli	Primary	MC	10			NED	0	
7	69	pT2N0Mx - gr. II	Tongue	Salvage	MC	6		total flap failure (necrosis)	DOD, 17 month	0	Secondary reconstruction using free latissimus dorsi flap
8	54	pT2N1Mx - gr. III	Bottom of oral cavity	Primary	MC	16			NED	0	
9	60		Mandible osteomyelitis	Secondary	M	6		dehiscence with plate exposure	DOC, 15 month	R	Osteonecrosis recurrence, another resection, supraclavicular flap
10	64	ypR2, ypN0	Submandibular region	Salvage	MC	16		dehiscence with plate exposure	DOD. 13 month	R	Plate exposure – supraclavicular flap
11	71		Bottom of oral cavity	Secondary	OMC	13	small dehiscence, fluidothorax		NED	R	Secondary correction of flap abundance – removing of skin island
12	66	pT2N0Mx - gr. II	Bottom of oral cavity, alveoli	Primary	M	14				0	
13	43	pT4N2bMx - gr. IV	Bottom of oral cavity	Primary	MC	20			DOD, 9 month	0	PPM including nipple-areolar complex, pathological fracture of the femur
14	45	pT2N0Mx - gr. II.	Bottom of oral cavity, tongue	Salvage	MC	19	small dehiscence		NED	0	
15	66	pT2N0Mx - gr. II	Tonsil oropharynx	Primary	MC	11	small dehiscence		NED	0	
16	56	pT2N0Mx - gr. II	Bottom of oral cavity	Primary	MC	28		Hemorrhage to Hb 60 g/l – revision and blood transfusion	NED	0	
17	68	pT4N1Mx - gr. IV	Bottom of oral cavity, alveoli	Secondary	M	18	small dehiscence		NED	R	
18	58	pT2N0Mx - gr. II	Bottom of oral cavity, alveoli	Salvage	MC	18			NED	0	

Abbreviations: M - muscular, MC - musculocutaneous, OMC - osteomyocutaneous, CH - chemotherapy, R - radiotherapy
* Legend to „Death" values NED (no evidence of disease), DOD (died of disease), DOC (died of other of causes)

Table 1. Patients characteristics and results

tion, plate exposure, hematoma, seroma and other similar complications at the donor sites.

The pathological stage of the disease was based on preoperative evaluation of USG, CT and MRI results, according to current TMN classification.

Elevation of the flap was done using complete dissection of clavicular portion of pectoralis muscle from the flap and with denervation of the muscle. Photo documentation of patients (before, during and after the procedure) was taken.

RESULTS

All patients were males, average age 58.5 years (minimum 29 years, maximum 71 years and median 60.5 years). In terms of tumor type, all patients suffered from spinocellular carcinoma. In the case of patient no. 2, it was combined with chronic lymphacytic leukemia (Table 1). In terms of disease stage, there were 6 patients in stage II, 3 in stage III and 6 patients in stage IV of cancer. 15 reconstructions of oropharyngeal defects and 1 reconstruction of submandibular defect of the neck were performed using PPM. Indications for the procedure were:

– 10 cases of primary resection of polymorbid patient (all these patients were long-term smokers with a history of alcohol abuse and hepatic dysfunction).

– 5 cases in which the indication was disease recurrence after previous neck dissection and radiotherapy.

– 3 cases of secondary reconstruction due to osteonecrosis or absence of the mandible in irradiated area

Denervated PPM in all cases, 14 PPM with skin island, 3 PPM without skin island and 1 PPM with skin island and rib bone (osteomyocutaneous flap).

Surgeries were used for the reconstruction of the floor of the oral cavity, oropharynx, lateral side of the neck and in one case was PPM used for the treatment of osteomyelitis after complete radionecrosis of the mandible (see Table 1).

Complications occurred in 9 out of 18 patients (50.0 %). There were 5 major (27.8 %) and 4 minor complications (22.2 %).

Major complications included:

– 1 case of total flap failure (necrosis) due to technical error (5.5 %). This submandibular defect was successfully treated afterwards using the LDM flap transfer - free tissue transfer of latissimus dorsi myocutaneous flap).

– 2 cases of large dehiscence with plate exposure. These two cases were treated by secondary surgery with plate coverage using an ipsilateral supraclavicular flap (11.1 %).

– 1 case of large dehiscence was treated with secondary surgery (5.5 %).

– 1 case of large hemorrhage mainly to donor area in the thorax, accompanied by blood loss of about 600 ml with drop of hemoglobin level to 60 g/l. This case was a polymorbid patient with systemic morbidities and impaired coagulation cascade due to previous toxonutritive hepatopathy. During the successful surgical revision was diffuse bleeding stopped with QuikClot® devices impregnated with kaolin that were removed the next day after compensation of the blood loss.

Minor complications were only small dehiscences. These occurred in 4 cases (22,2 %), one of them was associated with fluidothorax after the rib harvesting (5,5 %). Repeated needle aspiration of pleural effusion was used to resolve this complication.

No case of muscle abundance on the neck or supraclavicular bulge was observed; the overall morbidity of donor site was very low and no orocutaneous fistula occurred.

The median duration of hospitalization was 15 days (minimum 6 days, maximum 28 days).

The rate of complications on the sample of 5 patients, who underwent radiotherapy before the surgery, was 80 %. There were 2 cases of small dehiscences and 2 cases of large dehiscence that required secondary surgical intervention as a transposition of a supraclavicular flap.

Postoperative folow up was 5 to 36 months. There were 6 deaths observed during the postoperative period (38%), none of them related to the surgery. Five were caused by recurrence and overall progression of the cancer and one pacient died due to heart failure.

In one case, metastasis was found after a period from the surgery, which was resolved by excision and coverage of the defect using a supraclavicular flap.

DISCUSSION

The overall incidence of complications in our small sample of patients was 50%, which can be considered as the mid-range of values referred from other groups of patients - Wilson et al. 16% [12], Milenovic et al. 33% [13], Liu et al. 35% [6], Vartanian 36.1% [14], Pinto et al 43.1% [15], Ijsselstein et al. 53% [16], Rudes et al. 59.3% [17], Kroll et al. 63% [18], and Shah et al. 63% [19]. Total flap necrosis occurred in 6% of cases although the literature reports a flap failure from 2% to 3% [13,18,19]. This fact may be due to the small sample. The microvascular free tissue transfer (free flap reconstruction) was used as a salvage operation as Tang et al. 2012 [20].

The rate of minor and major complications contrasts with the literature [5,6,9,13,19,21,22] but like Vanni Salles Ribeiro et al., [23] and Pinto et al. [15] probably due to the small sample size. Previous radiotherapy increased the incidence of postoperative complications as observed in other studies [24,25] and also deterioration in perception of quality of life [26].

All patients were males. The supraclavicular flap is the preferred option for women patients due to a higher risk of skin paddlefailure and subsequent deformity of the breast [27]. The mean duration of hospitalisation time was 14.7 as in other authors [4,21,28]. During the elevation of the flap, we did not use surgical sparing of the field of elevation of deltopectoral flap. However, this can be used after harvesting of pedicled pectoral major flap [13,17,29]. We used the supraclavicular flap instead, to achieve a better aesthetic result for the contours of the soft tissues on the head and neck [30–32].

Our team has always performed nerve transection [13] and we have never observed development of bulges or contracting folds in place of the vascular pedicle as it is often reported in the literature. Another factor that is fundamentally involved in any supraclavicular bulge is strict disconnection of the transferred muscle flap and rotation around the clavicle only on the vascular bundle [33,34]. There was no neck deformity in our patients probably owing to the above.

In our sample, we did not use the dominance of the lateral thoracic artery. Kanno et al. reported [35] that preservation of the lateral thoracic artery and use of the subclavian route are alternatives to ensure sufficient blood supply and an increased rotation arc of PPM. In our sample, we did not use the subclavian route.

There was no complaint of ipsilateral shoulder movement restriction or reduced functional capability. PPM flap reconstruction has a small but significant negative effect on upper extremity dysfunction and also neck ROM limitations [36–38]. In general, we can say that patients who undergo primary reconstruction using PPM, often have significantly reduced working capacity, mainly due to preoperative polymorbidity.

Due to poor quality of rib bone, we refrain from mandible reconstruction using osteomyocutaneous PPM flap [39]. Another aspect that needs to be considered is the necessity of donor site closure using mesh, need for chest tube drainage due to distortion of pleural cavity and long term patient recovery [40]. Given these facts, we refrain from bone reconstruction and rarely use a reconstructive plate in the case of severely polymorbid patients [3]. If possible, we prefer the reconstruction using fibular free flap even for "borderline" indicated patients whenever the condition of blood vessels that supply lower limb permits [2].

CONCLUSION

Even today, usage the PPM in head and neck reconstruction surgery cannot be considered as a historical reconstructive procedure that has been completely replaced by a free microvascular flap. Innovations of flap harvesting techniques and high rate of flap survival are the main reasons why PPM can still be primarily indicated for high-risk patients, non-cooperative patients and also for patients with extensive neck dissection. A combination of PPM and free flap can be advantageous for reconstruction of large complex defects. PPM has been the first choice in salvage surgery, in cases of a complication or free flap failure or a recurrence of a primary disease. In these cases, PPM morbidity remains comparable to morbidity in patients undergoing reconstruction using a free flap.

Acknowledgements: This research received no funding from public agencies, commercial, or not-for-profit sectors.

Conflict of interest statement: The authors state that there are no conflicts of interest regarding the publication of this article.

REFERENCES

1. Kroll SS, Evans GR, Goldberg D, et al. A comparison of resource costs for head and neck reconstruction with free and pectoralis major flaps. *Plast Reconstr Surg*. 1997 Apr;99(5):1282–6.
2. Talesnik A, Markowitz B, Calcaterra T, Ahn C, Shaw W. Cost and outcome of osteocutaneous free-tissue transfer versus pedicled soft-tissue reconstruction for composite mandibular defects. *Plast Reconstr Surg*. 1996 May;97(6):1167-78.
3. Singh B, Cordeiro PG, Santamaria E, Shaha AR, Pfister DG, Shah JP. Factors associated with complications in microvascular reconstruction of head and neck defects. *Plast Reconstr Surg*. 1999 Feb;103(2):403-11.
4. Schusterman MA, Horndeski G. Analysis of the morbidity associated with immediate microvascular reconstruction in head and neck cancer patients. *Head Neck*. 1991 Jan-Feb;13(1):51-5.
5. O'Neill JP, Shine N, Eadie PA, Beausang E, Timon C. Free tissue transfer versus pedicled flap reconstruction of head and neck malignancy defects. *Ir J Med Sci*. 2010 Sep;179(3):337–43.
6. Liu R, Gullane P, Brown D, Irish J. Pectoralis major myocutaneous pedicled flap in head and neck reconstruction: retrospective review of indications and results in 244 consecutive cases at the Toronto General Hospital. *J Otolaryngol*. 2001 Feb;30(1):34-40.
7. Mehta S, Sarkar S, Kavarana N, Bhathena H, Mehta A. Complications of the pectoralis major myocutaneous flap in the oral cavity: a prospective evaluation of 220 cases. *Plast Reconstr Surg*. 1996 Jul;98(1):31–7.
8. Schneider DS, Wu V, Wax MK. Indications for pedicled pectoralis major flap in a free tissue transfer practice. *Head Neck*. 2012 Aug;34(8):1106-10.
9. Avery CM, Gandhi N, Peel D, Neal CP. Indications and outcomes for 100 patients managed with a pectoralis major flap within a UK maxillofacial unit. *Int J Oral Maxillofac Surg*. 2014 May;43(5):546-54.
10. Liu HL, Chan JY, Wei WI. The changing role of pectoralis major flap in head and neck reconstruction. *Eur Arch Otorhinolaryngol*. 2010 Nov;267(11):1759-63.
11. Chepeha DB, Annich G, Pynnonen MA, et al. Pectoralis major myocutaneous flap vs revascularized free tissue transfer: complications, gastrostomy tube dependence, and hospitalization. *Arch Otolaryngol Head Neck Surg*. 2004 Feb;130(2):181-6.
12. Wilson JS, Yiacoumettis AM, O'Neill T. Some observations on 112 pectoralis major myocutaneous flaps. *Am J Surg*. 1984 Feb;147(2):273–9.
13. Milenović A, Virag M, Uglesić V, Aljinović-Ratković N. The pectoralis major flap in head and neck reconstruction: first 500 patients. *J Craniomaxillofac Surg*. 2006 Sep;34(6):340-3.
14. Vartanian JG, Carvalho AL, Carvalho SM, Mizobe L, Magrin J, Kowalski LP. Pectoralis major and other myofascial/myocutaneous flaps in head and neck cancer reconstruction: experience with 437 cases at a single institution. *Head Neck*. 2004 Dec;26(12):1018-23.
15. Pinto FR, Malena CR, Vanni CM, Capelli Fde A, Matos LL, Kanda JL. Pectoralis major myocutaneous flaps for head and neck reconstruction: factors influencing occurrences of complications and the final outcome. *Sao Paulo Med J*. 2010 Dec;128(6):336-41.
16. IJsselstein CB, Hovius SE, ten Have BL, Wijthoff SJ, Sonneveld GJ, Meeuwis CA, et al. Is the pectoralis myocutaneous flap in intraoral and oropharyngeal reconstruction outdated? *Am J Surg*. 1996 Sep;172(3):259–62.
17. Rudes M, Bilić M, Jurlina M, Prgomet D. Pectoralis major myocutaneous flap in the reconstructive surgery of the head and neck--our experience. *Coll Antropol*. 2012 Nov;36 Suppl 2:137-42.
18. Kroll SS, Goepfert H, Jones M, Guillamondegui O, Schusterman M. Analysis of complications in 168 pectoralis major myocutaneous flaps used for head and neck reconstruction. *Ann Plast Surg*. 1990 Aug;25(2):93–7.
19. Shah JP, Haribhakti V, Loree TR, Sutaria P. Complications of the pectoralis major myocutaneous flap in head and neck reconstruction. *Am J Surg*. 1990 Oct;160(4):352–5.
20. Tang CL, Wu YC, Lai CH, et al. Salvage for pectoralis major myocutaneous flap failure in head and neck reconstruction by microvascular flap. *J Plast Surg Hand Surg*. 2012 Oct;46(5):335–8.
21. Kekatpure VD, Trivedi NP, Manjula BV, Mathan Mohan A, Shetkar G, Kuriakose MA. Pectoralis major flap for head and neck reconstruction in era of free flaps. *Int J Oral Maxillofac Surg*. 2012 Apr;41(4):453-7.
22. McLean JN, Carlson GW, Losken A. The pectoralis major myocutaneous flap revisited: a reliable technique for head and neck reconstruction. *Ann Plast Surg*. 2010 May;64(5):570–3.
23. Ribeiro Salles Vanni CM, de Matos LL, Faro Junior MP, et al. Enhanced morbidity of pectoralis major myocutaneous flap used for salvage after previously failed oncological treatment and unsuccessful reconstructive head and neck surgery. *ScientificWorld Journal*. 2012;2012:384179.
24. Tabah RJ, Flynn MB, Acland RD, Banis JC. Microvascular free tissue transfer in head and neck and esophageal surgery. *Am J Surg*. 1984 Oct;148(4):498–504.
25. Zhang C, Sun J, Zhu H, et al. Microsurgical free flap reconstructions of the head and neck region: Shanghai experience of 34 years and 4640 flaps. *Int J Oral Maxillofac* Surg. 2015 Jun;44(6):675-84.

26. Herce-Lopez J, Rollon-Mayordomo A, Lozano-Rosado R, Infante-Cossio P, Salazar-Fernandez CI. Assessment of quality of life of oral cancer survivors compared with Spanish population norms. *Int J Oral Maxillofac Surg*. 2013 Apr;42(4):446–52.
27. Ou KL, Chen TM, Dai NT, et al. Treatment of breast deformity with free deep inferior epigastric perforator flap secondary to pectoralis major flap harvesting. *Formos J Surg*. 2014;47(1):32-35.
28. Tsue TT, Desyatnikova SS, Deleyiannis FW, et al. Comparison of cost and function in reconstruction of the posterior oral cavity and oropharynx. Free vs pedicled soft tissue transfer. *Arch Otolaryngol Head Neck Surg*. 1997 Jul;123(7):731-7.
29. Nayak BB, Nilamani M. Single stage reconstructions in head and neck surgery using deltopectoral and pectoralis major myocutaneous flaps. *Indian J Plast Surg.* 2012 Jan;45(1):151-3.
30. Granzow JW, Suliman A, Roostaeian J, Perry A, Boyd JB. Supraclavicular artery island flap (SCAIF) vs free fasciocutaneous flaps for head and neck reconstruction. *Otolaryngol Head Neck Surg*. 2013 Jun;148(6): 941-8.
31. Pallua N, Wolter TP. Moving forwards: the anterior supraclavicular artery perforator (a-SAP) flap: a new pedicled or free perforator flap based on the anterior supraclavicular vessels. *J Plast Reconstr Aesthet Surg*. 2013 Apr;66(4):489-96.
32. Pallua N, Machens HG, Rennekampff O, Becker M, Berger A. The fasciocutaneous supraclavicular artery island flap for releasing postburn mentosternal contractures. *Plast Reconstr Surg.* 1997 Jun;99(7):1878-84; discussion 1885-6.
33. Ariyan S. Further experiences with the pectoralis major myocutaneous flap for the immediate repair of defects from excisions of head and neck cancers. *Plast Reconstr Surg.* 1979 Nov;64(5):605-12.
34. Temiz G, Şirinoğlu H, Yeşiloğlu N, et al. A salvage maneuver for the caudal part of the pectoralis major muscle in the reconstruction of superior thoracic wall defects: The pectoralis kite flap. *J Plast Reconstr Aesthet Surg*. 2015 May;68(5):698-704.
35. Kanno T, Nariai Y, Tatsumi H, Karino M, Yoshino A, Sekine J. A modified pectoralis major myocutaneous flap technique with improved vascular supply and an extended rotation arc for oral defects: A case report. *Oncol Lett.* 2015 Nov;10(5):2739–42.
36. Sun Q, Guo S, Wang D, Xu N, Jin SF, Wang CC. Does pectoralis major flap harvesting induce upper extremity dysfunction? *J Int Med Res*. 2015 Aug;43(4):555-9.
37. Moukarbel RV, Fung K, Franklin JH, et al. Neck and shoulder disability following reconstruction with the pectoralis major pedicled flap. *Laryngoscope*. 2010 Jun;120(6):1129-34.
38. Refos JW, Witte BI, de Goede CJ, de Bree R. Shoulder morbidity after pectoralis major flap reconstruction. *Head Neck*. 2016 Aug;38(8):1221-8.
39. Shunyu NB, Medhi J, Laskar HA, Lyngdoh N, Syiemlieh J, Goyal A. 5th Rib Osteo-pectoralis Major Myocutaneous Flap-Still a Viable Option for Mandibular Defect Reconstruction. *Indian J Otolaryngol Head Neck Surg*. 2014 Dec;66(4):414-7.
40. Ord RA. The pectoralis major myocutaneous flap in oral and maxillofacial reconstruction: a retrospective analysis of 50 cases. *J Oral Maxillofac Surg*. 1996 Nov;54(11):1292-5; discussion 1295-6.

Corresponding author:

Richard Pink M.D., Ph.D.

Department of Oral and Maxillofacial Surgery, University Hospital
I. P. Pavlova 6, 779 00, Olomouc, Czech Republic
E-mail: richard.pink@seznam.cz

IN MEMORIAM: PROFESSOR RAJKO DOLEČEK

With great sadness, the Czech Society of Burns Medicine received sad news that Professor Rajko Doleček, M.D, DrSc., passed away on December 20, 2017, aged 92.

He was a prominent figure and a well-respected medical authority in the Czech Republic as well as internationally by medical, endocrinological and burns societies.

Rajko Doleček was born on June 1, 1925 in Prague. His father was Czech while his mother was Serbian from the eastern part of Bosnia-Hercegovina. He graduated from the Faculty of Medicine at Charles University in Prague in 1950. In 1951, Dr. Doleček started working in Ostrava Regional Hospital, in one of the most industrialized regions of the country, with many burn injuries at that time. Since the very beginning, he oriented himself for endocrinology which was then at its early stage of development. He became the pioneer in the field of metabolism, diabetes, stress and particularly in metabolic/endocrine aspects of burns injuries. His studies of metabolic and endocrinological problems in burn patients were published in Czechoslovakia/Czech Republic repeatedly, but also in the USA (1969, 1990), Spain (1993), etc. In his last book "Endocrinology of Trauma" (2016), he summarized the laboratory results obtained during 60 years of endocrine and metabolic studies in burn and trauma patients. Altogether, over 50 laboratory parameters have been studied including 33 hormones. At the Ostrava University Hospital, Prof. Doleček worked all his medical career, until recently, when he had his last out-patient clinic on October 5, 2017. In May of 2016, he was awarded the Prof. Radana Königová Burns Prize for his life-long contribution to burns medicine.

Besides medicine, being a half-Serbian, Prof. Doleček wrote several books dedicated to Serbian history and culture in addition to relations between a variety of Balkan nations. He tried to describe and explain the complicated national, ethnic and religious problems in that region which, among others, led to the war in Yugoslavia between 1991–1995.

Professor Rajko Doleček passed away in the hospital where he has worked relentlessly for more than 66 years. Our esteemed, highly respected colleague, a very beloved open-minded and jovial friend as well as a man of distinguished character, left this world with honour, having accomplished a tremendous career that contributed immensely to Czech medicine, endocrinology, and burns treatment in particular.

Assoc. Prof. Leo Klein, MD, CSc.
Division of Plastic Surgery and Burns Treatment
Teaching Hospital, Hradec Králové

NOVÁ MONOGRAFIE ESTETICKÉ RINOPLASTIKY

Nos neschováš aneb vše o nosu

Jan Válka a kolektiv. ISBN: 978-80-271-0304-1

Formát 167×240, 280 stran. Vydala Grada Publishing a. s., 2017

Monografie o nosu „Nos neschováš aneb vše o nosu“ autorů Jan Válka a kolektiv, kterou vydala Grada Publishing a.s., navazuje na knihu stejného autora „Korektivní operace nosu“. Jan Válka tuto úspěšnou publikaci důmyslně rozšířil, ve spolupráci s odborníky z řady lékařských a jiných oborů, o velmi zajímavé a poučné kapitoly s cílem vytvořit komplexní pohled na estetickou rinoplastiku. A právě v tom spatřuji jedinečnost protagonisty tohoto díla, který svoji myšlenku dokázal ztvárnit a příkladně realizovat.

Kniha je bezesporu dalším významným obohacením našich současných vědomostí a zkušeností v jedné z nejtěžších problematik estetické chirurgie, kterou představuje estetická rinoplastika.

Jan Měšťák

COMMEMORATION OF PROFESSOR MIROSLAV FÁRA, M.D., DSC.

This year we commemorate 95 years of the birth and 5 years of the death of Professor Miroslav Fára, M.D., DSc.

Profesor Miroslav Fára was an important representative of Czech plastic surgery, who, as a student and follower of Prof. František Burian, contributed to the maintenance and spread of a good name of Czech plastic surgery in the world.

He was born in Pelhřimov in a family of a general practitioner. There he attended basic school and later also a high school. He completed the Medical Faculty of Charles University successfully in 1949. After graduation, he started working in Jindřichův Hradec Hospital, where he gradually worked in the Medical Department, Surgical Department and Gynaecological Department. He evaluated this period of his practice as very important because he learned independent decision making and complex view of the patient; these characteristics he utilized later in his further clinical practice.

In 1955, he was admitted to the Department of Plastic Surgery in Prague as a secondary physician and he had the possibility to work under the lead of Prof. Burian and later under the lead of his followers, Prof. Karlík and Prof. Pešková. In 1964, he was appointed Assistant and later he obtained the title CSc. and in the same year he successfully passed the habilitation procedure and was appointed Assistant Professor. In 1970, he obtained the title DSc. and in 1976 was appointed professor of plastic surgery.

He has deepened his experience during long-term fellowships in Sweden and USA. He has visited several important units of plastic surgery in the USA, Canada, Japan, Australia, Singapore, Thailand, Mexico, Peru, India and other countries, where he was an invited lecturer.

In 1975, he was appointed Head of the Department of Plastic Surgery in Prague, which he led until 1992. At that time, he also led the 2nd Department of the Institute of Experimental Medicine of the Czechoslovak Academy of Sciences.

Professor Fára published over 200 papers in plastic surgery and he is a co-author of 11 monographs. He participated and was a chair of several domestic and foreign congresses and symposia, where he presented over 300 lectures. Special attention should be paid to his papers which dealt with facial clefts. His anatomical studies of these disorders are unique worldwide. He is also the first author who described a new syndrome "Dysmorphia otofaciocervicalis".

Professor Fára was a honorary member of the Czech Society of Plastic Surgery CzMA and of many foreign medical societies. He was also a member of the executive committee of IPRAS (International Confederation for Plastic, Reconstructive and Aesthetic Surgery) in the period 1975–1983 as the only representative of former Eastern Europe. His contribution to plastic surgery was in 1992 awarded by the invitation of ASPRS (American Society of Plastic and Reconstructive Surgeons) where he presented prestigious annual Maliniac lecture as the only European. He was also a holder of various other domestic and foreign awards.

With respect, we commemorate this jubilee of an important personality of Czechoslovak medicine, an internationally recognized expert and last but not least also a kind teacher, who has trained several important plastic surgeons.

Assoc. Prof. Miroslav Tvrdek, M.D.

ČESKÉ SOUHRNY

ACTA CHIRURGIAE PLASTICAE, 60, 1, 2018, pp. 00-00

POUŽITÍ LICAP A LTAP LALOKŮ PRO REKONSTRUKCI PRSU

Martellani L., Manara M., Renzi N., Papa G., Ramella V., Arnež Z.

Záchovné operace prsu jsou vyhrazeny pro pacienty s příznivým poměrem mezi velikostí nádoru a velikostí prsu. Vložení místního laloku z laterální oblasti hrudníku rozšířilo indikace pro záchovné operace prsu tím, že umožnilo chirurgovi provést širší excizi a zajistit tak čisté okraje excize a dobrý kosmetický výsledek.

My používáme laterální interkostální perforátorové laloky a axiální laloky na arteria thoracica lateralis u pacientek s malými prsy a příznivým poměrem velikosti prsu a nádoru.

Od května 2015 do října 2016 bylo 19 pacientek s nádory prsu léčeno s využitím záchovné operace a okamžité náhrady objemu pomocí stopkovaných perforátorových laloků z laterální oblasti hrudníku. U 15 pacientek byly použity laterální interkostální arteriální perforátorové laloky nebo perforátorové laloky na arteria thoracica lateralis po kvadrantektomii nebo široké lokální excizi, u tří pacientek jako náhrada objemu po mastektomii, u jedné pacientky po mastektotomii po předchozí augmentační mamaplastice. U všech pacientek byla dosažena dobrá symetrie prsu, bez žádných velkých komplikací. Po pooperační radioterapii byla u hubených pacientek nebo u laloků s malým množstvím podkožního tuku pozorována fibróza laloku a reziduálního prsního parenchymu s redukcí objemu.

Perforátorové laloky z laterální oblasti hrudníku by se měly stát zlatým standardem pro rekonstrukci po záchovných operacích prsu zahrnujících méně než 20 % objemu prsu nebo po mastektomii u pacientek s malými prsy. Operační výkon je bezpečný, rychlý a umožňuje zachování musculus latissimus dorsi a tím minimalizuje morbiditu donorského místa a má také excelentní estetický výsledek.

MOŽNOSTI ZOBRAZENÍ TUMORU PERIFERNÍHO NERVU POMOCÍ MAGNETICKÉ REZONANCE – KAZUISTIKA

Humhej I., Ibrahim I., Lodin J., Sameš M., Čižmář I.

Pro stanovení diagnózy tumoru periferního nervu (PNT) a jeho morfologický popis sehrává zásadní roli magnetická rezonance (MR). Kromě tradičních konvenčních sekvencí MR se v posledních letech začínají rozvíjet pokročilé zobrazovací techniky, mezi které patří MR neurografie (MRN), diffusion tensor imaging (DTI) a MR traktografie (MRT). Tyto techniky umožní získat nejen detailní strukturální informace o PNT, ale i údaje o průběhu a funkci jednotlivých fasciklů periferního nervu. Získaná data mohou přispět ke stanovení adekvátního operačního postupu s redukcí rizika vzniku pooperačního neurologického deficitu. Na uvedené kazuistice tumoru nervus medianus demonstrujeme současné možnosti pokročilých technik magnetické rezonance. S dalším technologickým pokrokem a zdokonalením těchto metod se dá v budoucnu očekávat rozšíření a začlenění pokročilých technik do standardních vyšetřovacích protokolů MR.

STOPKOVANÝ PEKTORÁLNÍ LALOK V REKONSTRUKCI HLAVY A KRKU – TECHNIKA A PŘEHLED

Dvořák Z., Pink R., Michl P., Heinz P., Tvrdý P.

Stopkovaný pektorální lalok byl původně hlavní lalok pro rekonstrukci hlavy a krku. U orofaryngeálních rekonstrukcí se s příchodem volných laloků časem stal druhou volbou. V současné době je polymorbidní pacient stále primárně indikován k rekonstrukci pektorálního laloku, dalšími indikacemi jsou kombinace pektorálního laloku s volným lalokem, jako záchranná operace po komplikacích, po selhání volného laloku a při rekurenci nebo pokračování primárního onemocnění. Pektorální lalok lze tedy úspěšně použít pro specifické orofaryngeální defekty i při primárních resekcích, zejména u méně spolupracujících pacientů a u pacientů po rozsáhlé krční disekci. U orofaryngeálních rekonstrukcí ve specifických případech může zlepšení techniky odběru laloku snížit nežádoucí komplikace. Morbidita při užití pektorálního laloku v těchto případech zůstává srovnatelná s morbiditou pacientů, kteří podstoupili rekonstrukci volnými laloky. Pektorální lalok zůstává platným nástrojem rekonstrukce, který by měl být součástí „profesní výbavy“ každého chirurga, který se zabývá rekonstrukcí hlavy a krku.

ZAJIŠTĚNÍ INTRAORÁLNÍCH KOŽNÍCH ŠTĚPŮ KE SPODINĚ DUTINY ÚSTNÍ: KAZUISTIKA A POPIS TECHNIKY

Kenny M., Egro F. M., Solari M. G.

V tomto článku popisujeme inovační bolusovou techniku, která umožnila úspěšné přihojení kožního štěpu ke spodině dutiny ústní v případě, kdy nebyly k dispozici zuby a alveolus pro ukotvení.

INTRAOSEÁLNÍ HEMANGIOM LÍCNÍ KOSTI. KAZUISTIKA A PŘEHLED LITERATURY

Němec, I.

Intraoseální hemangiom je benigní léze, která představuje méně než 1 % vše kostních nádorů. V oblasti lícní kosti se vyskytuje vzácně. Častější je výskyt u žen než u mužů. V článku prezentujeme případ pacientky s intraoseálním kavernózním hemagiomem lícní kosti. Tumor byl příčinou deformace lícní kosti vlevo. Léze byla patrná na výpočetní tomografii (CT) a na již dříve provedené magnetické rezonanci (MRI) pro obtíže nesouvisející s vyšetřovanou lézí. Provedli jsme kompletní odstranění tumoru včetně okraje zdravé kosti. Defekt jsme překlenuli titanovou minidlahou. Stav pět měsíců po operaci ukázal dobrý kosmetický efekt. Kontrolní CT a MRI vyšetření neprokázaly recidivu ani reziduum tumoru. Zároveň uvádíme přehled dostupné literatury.

STOPKOVANÝ VELKÝ PEKTORÁLNÍ LALOK V REKONSTRUKCI HLAVY A KRKU – NAŠE ZKUŠENOSTI

Dvořák Z., Pink R., Michl P., Heinz P., Tvrdý P.

Východiska. Stopkovaný velký pektorální lalok je stále používán a indikován pro rekonstrukce u polymorbidních pacientů. Dalšími indikacemi jsou kombinace stopkovaného velkého pektorálního laloku s volným mikrovaskulárním lalokem, jako záchranná rekonstrukce při komplikacích, selhání volného laloku a při rekurenci nebo pokračování primárního onemocnění.

Metodika. Je zkoumáno užití stopkovaného velkého pektorálního laloku u 18 pacientů operovaných na Klinice ústní, čelistní a obličejové chirurgie ve FN Olomouc od 1. ledna 2014 do 1. prosince 2016.

Výsledky. Bylo provedeno 15 rekonstrukcí orofaryngeálních defektů pomocí stopkovaného velkého pektorálního laloku (včetně jednoho submandibulárního defektu krku). Indikacemi byly primární resekce u polymorbidních pacientů v 10 případech a rekurence onemocnění po předchozí disekci krku a radioterapii v pěti případech. Stopkovaný velký pektorální lalok byl také použit pro sekundární rekonstrukci ve třech případech. Komplikace se vyskytly u 50 % pacientů, 28 % bylo závažných a 22 % bylo méně závažných. Hlavními komplikacemi byla v jednom případě kompletní ztráta laloku (defekt byl úspěšně vyřešen pomocí volného přenosu latissimus dorsi svalového laloku), obnažení dlahy ve dvou případech a po jednom případě větší dehiscence a krvácení. Drobnými komplikacemi byly jen menší dehiscence (22 %). Jeden případ byl spojen s fluidothoraxem po odběru laloku s žebrem (6 %). Nebyl zaznamenán případ kontraktury krku nebo nadklíčkové abundance.

Závěr. Ani v dnešní době nelze stopkovaný pektorální lalok považovat za historický výkon v rekonstrukci hlavy a krku, který byl plně nahrazen volnými mikrovaskulárními laloky. Díky inovacím v technice elevace laloku a vysoké úspěšnosti přežití laloku může být stále primárně indikován u rizikových a nespolupracujících pacientů a u pacientů po rozsáhlé disekci krku. Stopkovaný pektorální lalok stále zůstává první volbou v případech, kdy došlo k selhání nebo komplikaci volného laloku nebo při rekurenci základního onemocnění.

INSTRUCTIONS TO THE AUTHORS

ACTA CHIRURGIAE PLASTICAE, 60, 1, 2018, pp. xx–xx

The journal *Acta Chirurgiae Plasticae* is an international journal of plastic surgery. It is published in English with Czech/Slovak structured abstracts four times a year. There are articles dealing with problems of plastic, reconstructive and aesthetic surgery, craniofacial surgery, hand surgery, microsurgery, burns and allied and cooperating fields of medicine. The journal accepts the following types of articles for publication: original scientific papers including experimental studies, case reports, review articles, discussions, reviews of domestic and foreign publications, news (invitations to specialized meetings, reports from congresses and meetings, letters to the editors, etc.) and other important information from the specialty. All articles are subject to a peer review procedure, whereas bilateral anonymity is maintained. The editorial board accepts articles in English, or possibly after a previous agreement also in Czech and Slovak languages. Only articles that have not been previously published elsewhere can be accepted.

REQUIREMENTS FOR FORMAL STRUCTURE OF THE MANUSCRIPT

The whole manuscript including the attachments must be made available in electronic form. The article should be written in one of commonly used text editors (best is MS Word), recommended font size is 12, Times New Roman, spacing 1.5, width of text 15 cm, no underlying, with switched off automatic functions. The text file must be named so that it could not be mistaken (name of the file without diacritic marks, e.g. surname of main author, key word of the paper and the word text, for example: "Smith_reconstruction_text.docx"). Recommended extent is maximally 10 normalized pages (counted without title page, abstract and literature, 1 normalized page = 1800 characters without spaces). Each section should be started on a new page. In the manuscript text, please observe the following order: title page, summary, key words, actual text of the paper and summary of used literature.

Tables, charts and images to the articles should be marked in the actual text (for better orientation) and attached in a separate file. Tables and charts must be sent in a form of individual files (or individual excel sheets), which can be edited (best is MS Excel, MS Word). Tables and charts should be prepared appropriately simple and comprehensive, numbered according to the order of occurrence within the text. There should be a brief description to each table and chart. You should also explain all abbreviations, which were used. You should also verify, whether all tables and texts are really referenced in the text. Name the file should be made the same way as in the text (e.g. "*Smith_reconstruction_text.xlsx*"). Imaging documents should be sent in an electronic form as JPG, BMP, TIFF with resolution at least 300 dpi. If the image is printed in the size of one third of a page, it must have a minimal width of 700 pixels, in the size of two thirds of a page it must have a minimal width of 1500 pixels and in the size of the whole page it must have a minimal width of 2200 pixels. If there is imaging documentation reprinted from another source, it is necessary to provide the original source and a written consent of the copyright holder. Imaging documents cannot be received in MS PowerPoint form. Imaging attachments are numbered according to the occurrence in the text and stored individually as separated files, named analogically as the other files (e.g. „*Smith_reconstruction_pict1.jpg*"). The legend to the imaging documentation should be submitted as a separate file in MS Word named analogically as the other files (e.g. „*Smith_reconstruction_legends.docx*") and possible symbols and abbreviations should be explained.

TITLE PAGE

Title page must contain brief and clear name of the article (maximum 10 words), in the case reports this should be included in the name.

It must also contain full name and surname of all authors, in the order reflecting their participation on the manuscript, name of workplaces of all authors (in case of more workplaces, name the first where the manuscript was created mostly), address of the main author, telephone and email address, where should be sent the correspondence related to the manuscript.

In case there was financial support or non-financial support used during the preparation of the article (grants, equipment, medication, etc.), it is necessary to provide in sufficient extent the source of this support. Possible acknowledgement may be located before the literature section.

STRUCTURE OF ORIGINAL PAPER

In the original paper the author works with his/her own file and provides his/her own ideas related to the particular problem based on the analysis of his/her own results and using appropriate statistical methods. The text must be written at appropriate scientific level and comprehensively. The conclusions must be formed clearly and so that any different interpretation was ruled out. The text of the original article must follow a prescribed structure.

Abstract – structured abstract represents summary of article content into a brief form. Characteristic information is required from the article. Structure of the abstract of the original paper copies the structure of the whole paper, i.e. it contains the following chapters "Introduction, Material and methods, Results, Discussion and Conclusion". The abstract should have an extent of a maximum of one normalized page (maximum of 1800 characters).

Key words – 3-8 words or short phrases that enable characterizing the paper with regards to its content. It is recommended to use terms that originate from the recommended terms of the National Library of Medicine: Medical Subject Headings (MeSH).

Introduction – brief and clear description of the problem including reference to the basic literature and formulation of the goal of the patient or working hypothesis, brief introduction about the origin of the article.

Material and methods – a basic description of the file, summary of used methods, description of the hypothesis and methods within the study, including the method of evaluation and used statistical method.

Results – obtained data and their evaluation.

Discussion – brief confrontation with similar studies and papers from the last two or more years. Evaluation of achieved study goals.

Conclusion – brief and clear summary with clearly formulated outputs for practice.

Literature – citation according to the instructions for authors, organized according to the occurrence in the text, only relevant citations.

STRUCTURE OF REVIEW ARTICLE

Review article should summarize the current knowledge about aetiology, pathogenesis, diagnostics and therapy of a disease or group of diseases, or complex review of the issues related with the topic of the journal. After reading the article the reader should obtain a sufficient and current idea about the particular topic. The article should be written with a maximum emphasis on its practical use. Instructive imaging documentation is welcome.

The contribution of the author to the particular problem should be based on extensive study of literature, provided in the list of used literature but also on the own work of the author. In case of processing a more extensive topic, it is possible to divide the article into several parts after an agreement with the editorial board.

Summary – brief summary of the content of the article in the extent of a maximum of 1000 characters.

Key words – 3-8 words or short phrases enabling documentation of the content of the paper with regards to its content; it is recommended to use the terms from the recommended terms of the National Library of Medicine: Medical Subject Headings (MeSH).

Introduction – brief explanation of the origin of the article, proposal of the theme and its limitations.

Evaluation of the topic – brief basic thoughts of the paper, own approach of the author, review of current knowledge.

Conclusion – brief message of the paper.

Literature – citation according to the instructions for the authors, organized according to the occurrence in the text.

STRUCTURE OF CASE REPORT

Case report is a description of one or several similar cases and their solution. The case reports should be in some extent unique and their solution should be innovative, or possibly it should supplement or confirm current knowledge.

Summary – brief summary of the content of the article in the extent of a maximum of 200 characters.

Key words – 3-8 words or short phrases enabling documentation of the content of the paper with regards to its content; it is recommended to use the terms from the recommended terms of the National Library of Medicine: Medical Subject Headings (MeSH).

Introduction – brief explanation of the origin of the article, description of the topics.

Description of the case – there are all important data related to the described case including history, clinical picture, possibly results of laboratory examination, description of the finding of imaging techniques, therapeutic procedure and result.

Discussion – it should be brief and it discusses the actual case report with regards to similar case reports or papers of other authors, which are cited.

Conclusion – brief summary of the most important aspects of the paper.

Literature – citation according to the instructions for the authors, organized according to the occurrence in the text. Only relevant citations.

Use metric units and SI units. Use only established abbreviations, do not use any abbreviations in the header and summary, in case of the first use of the abbreviation in the text, provide expanded version in brackets. List of abbreviations in alphabet order with explanation may be provided before the list of used literature. In case of medication it is necessary to provide a generic name and producer in the product name.

LITERATURE

The manuscript may contain only the actual sources, i.e. publication referenced by the authors in the text or papers that are really important (no papers may be provided only from formal reasons). Literature may be arranged according to the occurrence in the text, not in alphabet order, it is marked with a number of appropriate reference number written as upper index and it is cited according to Uniform Requirements for Manuscripts Submitted to Biomedical Journals“ according to “Vancouver citation format”.

In case of references to the papers that were not published yet, however already accepted for publication, please provide the name of the journal with the note “in print”. References within the text, tables or descriptions of images should be marked with Arabic numbers in hard brackets. Several sources should separated by a comma, without spaces.

EXAMPLES OF CORRECT FORMS OF CITATIONS:

Article in a journal:

Provide full surname of the authors, initials of the name without a full stop, put comma between the authors, after the last name is a full stop. If the number of authors is more than 6, put first three authors and an abbreviation “et al.”. Name of the article should be terminated with a full stop. Then is written the official abbreviation of the article (name of the journals is abbreviated according to a style used in Index Medicus) and year (possibly even month) of issue, do not separate with a comma, after the year put a semicolon. Year of the journal and possibly number of issue in parenthesis, colon, pages completed with a full stop.

Examples:

Petitti DB, Crooks VC, Buckwalter JG, Chiu V. Blood pressure levels before dementia. *Arch Neurol.* 2005 Jan;62(1):112-6.

Chapter in a book:

In the authors write their full surname, initials of the name without a full stop, between the authors put comma, after the last name put full stop. The name of the book is separated with a comma, number of issue is terminated with a full stop. City of issue and in round bracket country of issue and colon, publisher, semi-colon, year of issue, full stop, name of chapter, semi-colon and pages terminated with a full stop.

Examples:

Riffenburgh RH. *Statistics in medicine*. 2nd ed. Amsterdam (Netherlands): Elsevier Academic Press; c2006. Chapter 24, Regression and correlation methods; p. 447-86.

Book, monograph:

In the authors put full surname, initials of the name without a full stop, between authors put comma, after the last name put full stop. Name of the book is terminated with a full stop and number of issue is terminated with a full stop. City, colon, publisher, semi-colon, year of issue, full stop and total number of pages terminated with a full stop.

Examples:

Eyre HJ, Lange DP, Morris LB. *Informed decisions: the complete book of cancer diagnosis, treatment, and recovery*. 2nd ed. Atlanta: American Cancer Society; c2002. 768 p.

EXAMPLES OF OTHER CITATIONS:

Article in electronic serial publication:

Polgreen PM, Diekema DJ, Vandeberg J, Wiblin RT, Chen YY, David S, Rasmus D, Gerdts N, Ross A, Katz L, Herwaldt LA. Risk factors for groin wound infection after femoral artery catheterization: a case-control study. Infect Control Hosp Epidemiol [Internet]. 2006 Jan [cited 2007 Jan 5];27(1):34-7. Available from: http://www.journals.uchicago.edu/ICHE/journal/issues/v27n1/2004069/2004069.web.pdf

Electronic publication:

Richardson ML. Approaches to differential diagnosis in musculoskeletal imaging [Internet]. Version 2.0. Seattle (WA): University of Washington School of Medicine; c2000 [revised 2001 Oct 1; cited 2006 Nov 1]. Available from: http://www.rad.washington.edu/mskbook/index.html

Article from web pages:

Complementary/Integrative Medicine [Internet]. Houston: University of Texas, M. D. Anderson Cancer Center; c2007 [cited 2007 Feb 21]. Available from: http://www.mdanderson.org/departments/CIMER/.

Article from online database:

MeSH Browser (2011 MeSH) [Internet]. Bethesda (MD): National Library of Medicine (US), Medical Subject Headings Section; [1999] – [updated 2010 Aug 28; cited 2011 Jul 8]. Available from: http://www.nlm.nih.gov/mesh/MBrowser.html Files are updated every week on Sunday.

Complete instructions for citation and rules for citations other than above examples of the sources according to "Vancouver citation format" is available at:

http://www.ncbi.nlm.nih.gov/books/NBK7256/

ETHICAL ASPECTS

The condition to publish clinical research is that the used procedures corresponded to the ethical principles of Helsinki declaration from 1975 (revised in 2000) and they were approved by appropriate ethics committee. In case of animal studies, it is necessary to document that valid regulations and directives for breeding and experimental use of animals were observed. The authors must declare compliance with such conditions in written in a cover letter. All information about patients must respect the rules set forth by relevant law on protection of personal data. No names of patients, their initials or hospital (treatment, reference) numbers are provided, especially in any imaging material. The clinical photographs of the patients must be adjusted so that the patient could not be identified. If such adjustments are not possible with regards to the nature of the paper, it is possible to provide written informed consent of the patient (possibly family or guardian) with publishing such photographs.

STATISTICS

Used statistical methods should be sufficiently described so that the reader with access to the original data could verify the results. The editors recommend that the author before completing the paper discusses all used statistical methods with a professional statistician who deals with biomedicine.

AUTHORSHIP AND COPYRIGHTS

Only a manuscript that was not published in another journal, not even partially, will be accepted for publication. The cover letter must contain a statement that the article or its part was not sent to another journal. As co-authors may be mentioned only those who significantly contributed to the preparation or overall performance of the study, to analysis and interpretation of the findings or to processing, editing and adjustment of the text. All co-authors must consent with the final version of the manuscript. The order of authors must correspond to their effort during the performance of the study and writing of the manuscript. Published articles are property of the journal – copy of the articles or of their part may be published only with the consent of the editorial board with provision of the source.

REVIEW OF THE ARTICLE

Review of the article is bilaterally anonymous. The editors perform anonymization of the text, i.e. removal of data that could help identify the authors before the text proceeds to the review process. Each text submitted for publication in the journal *Acta chirurgiae plasticae* is (apart from reviews, reports, medallions and some other information) provided to two peers for review. The chief editor chooses specialists for the review in the field, which corresponds to the content of the text. He/she also considers that the reviewers were not closely related to the author, by common institution or personally. Reviewers fill out a standardized form whether the they recommend the text for acceptance, rewriting or refusal. Their decision is explained in the opinion into which they can also include recommendation for adjustment of the text. The editors have a right to propose the author shortening of the manuscript, adjustments (language of the manuscript), and possibly after the review they can return the manuscript to the author to rewrite. Confirmation that the article was accepted for printing in the journal *Acta chirurgiae plasticae* is provided to the author only after both reviewers accepted the article for publishing. Proofreading must be

sent to the editors within three days; the text is confirmed for publication only by the chief editor.

PAYMENTS

Manuscripts of articles, information and reports sent for publication to the journal *Acta Chirurgiae Plasticae* are not subject to a payment of the authors. They are published on the expense of the publisher.

Advertisements and other commercial information from companies are subject to payment according to the valid pricelist of the publisher.

CONFLICT OF INTEREST

Authors are obliged to send a statement together with the manuscript that in relation with the theme, creating and publication of this manuscript they are not in conflict of interest. It means that the creation of the manuscript and its publication was not financially supported by any pharmaceutical or other company or other subject and none of the authors was influenced during the creation of the paper in any way.

Otherwise the main authors is obliged to report whether and how was the main author or any of the co-authors in relation to the writing and to the theme of the manuscript within the last 24 months contractually bound, whether and from what subject was obtained any financial support for the work and publication, whether and who supported his/her/their participation in a specialized meeting or conference related to the theme of the manuscript, etc.

SENDING THE MANUSCRIPTS

The manuscript and the cover letter corresponding to the aforementioned requirement may be sent in a written printed form and also in an electronic form on CD, DVD or flash disc to the following address: **MUDr. Aleš Fibír, Oddělení plastické chirurgie a léčby popálenin, Fakultní nemocnice Hradec Králové, Sokolská 581, Hradec Králové, PSČ 500 05, Czech Republic**. If the electronic form of the manuscript is smaller than 8 Mb, it is possible to send it as an attachment to an email to the following address: fibir@seznam.cz. When sending larger files, it is possible, after a previous agreement, to use also commercial provider for delivering of data.

COVER LETTER

The manuscript must be accompanied with a cover letter that contains the following information: name of the paper, format of the paper, name and surname of the authors, statement of the authors regarding approval of the ethics committee (experimental or clinical studies) or in case of an animal study a statement of compliance with the procedures during manipulation with experimental animals, statement about possible conflict of interests, statement that all materials (schemas, images, charts, tables, etc.) obtained from other sources or publications were used with the consent of the person or publisher, which have appropriate copyright or publishing rights to that reproduced material, furthermore statement that the manuscript is approved for publication by all authors, name and address of the main author, his/her telephone and email address where all correspondence related to proofreading and publication should be sent. The cover letter must be signed by all authors.

Updated on 1. 9. 2015