Clinic of Plastic Surgery, Charles University, Prague (Czechoslovakia)
Director: Academician F. Burian

MEDIAN CLEFTS OF THE NOSE

F. BURIAN

Congenital defects occur frequently in the central part of the face, the bridge of the nose and the adjoining parts. These regions are the seat of great embryonic activity. The involution of the neurocranial tube is completed at this site in the third week by the closure of the anterior neuropore. This process is easily influenced by external factors which can disturb normal development. Sometime after the closure of the neuropore, the cranial tube protrudes at this site to the ectoderm. This junction is situated on the external aspect of the cartilaginous nasal shell. The nasal bones are formed externally and are connected to the frontal bone only by a membrane (the fonticulus nasofrontalis); later, this is replaced by bone (nasal process of the frontal bone). At the same time the newly formed bone constricts the dural projection. In the newborn, a filiform canal persists (foramen coecum).

This process can be disturbed by the persistence of a wide canal into which brain substance may protrude like a hernia. This can persist or be cut off by bone which subsequently closes the cranial opening. The part of the brain which is cut off in the prenasal space undergoes regressive changes which lead to its complete disintegration or to the persistence of a tumour of a gliomatous character. This tumour may still be connected with the dura by a hollow thread. Cerebral hernias and their derivatives, secondary gliomas, can develop in other parts of the frontal lobes when there are disturbances in the formation of the frontal bone. Apertures can persist like that of the fonticulus.

Disturbances can develop at any site in the prenasal connecting canal. Remnants can persist in the form of a dermoid cyst with or without a fistula. These dermoids occur quite frequently. They are mainly situated in the nasal septum but they can also occur externally on the bridge of the nose in some relation to the former fonticulus. Disturbances in the closure of the neuropore do not necessarily lead to the formation of a hernia, glioma or dermoid but may cause distortion in the development of the central part of the face. These abnormalities take various forms, such as simply hypertelorism, broadening and flattening of the bridge of the nose and epicanthus across the inner corner of the eye.

The infant H, aged four months, had this type of abnormality (Fig. 1).

The young girl Sz. F. (No. 1241), aged 19 years, had hypertelorism and a completely flat nose with a medial scar descending to the line of the upper lip. She had been operated on previously, evidently for a median cleft. At operation in 1934 the entire scar was extirpated. Beneath, the nasal bones were gaping and the nasal septum, both the bony and cartilaginous, was found to be duplicated.

Fig. 1. Girl H., aged four months.

In the cleft there was a dermoid cyst. The left septal lamella together with the dermoid was resected, and an osteotomy was performed of the frontal process of the maxilla and their junction with the nasal bones.

Another case, that of a girl T. R., aged 15 years (No. 477), who was born with a tumour on the bridge of the nose which had been removed at the age of three weeks. We were not able to obtain the operation notes. On examination there was hypertelorism and a wide, flat bridge of the nose, flanked by folds which reached to the forehead. On the right this fold ended in a protrusion. From here an ugly operation scar ran down to the tip of the nose. The X-ray showed a median fissure of the frontal bone and behind that a small bony lamella. The sella turcica was very broad, the nasal cavity low and quadrangular and the septum broad and obviously duplicated.

At operation on June 11, 1926 the scar was removed. A deep cleft was found between the nasal bones which was prolonged downwards bordered by a split lamina perpendicularis and filled with dermoid substance. The cartilaginous part of the septum was also split. We resected the left lamella, removed the cyst and reduced the width of the nose by bilateral osteotomy. The hypertelorism, of course, remained (Fig. 2, 3).

Fig. 2.

Fig. 3.

Fig. 2. Girl T. R., aged 15 years—flat broad nose with scar resulting from an operation, probably extirpation of dermoid. — Fig. 3. Girl T. R., after operation. High degree of hypertelorism.

Fig. 4. Six-month-old girl T. M. with median cleft of upper lip and nose.

A six-month-old infant T. M. (No. 2447), the first child of healthy parents, had an incomplete cleft of the upper lip in the form of a groove. From here to the columella there was no muscle in the lip so that the skin lay directly on the mucous membrane. The tip of the nose was cleft and the halves splayed. Above that the rudimentary nasal skeleton protruded. The nostril was transverse

Fig. 5. The girl T. M., aged 17 years.

(Fig. 4). The harelip was operated on at the age of three months. The abnormal medial strip of lip was resected, the edges of the muscles isolated and sutured and the vermillion border modelled. At the age of four (1943) a columella was formed from the medial part of the lip by a V-Y plastic. There were two septal lamellae with the space in between filled by fibrolipomatous tissue. This was removed, the septal lamellae were drawn together and sutured and the alar cartilage was treated similarly. In this way the tip of the nose was modelled and lifted. Thirteen years later a compound lamella, taken from a rib, was grafted so that its bony part was fixed to the nasal bones. Fig. 5 shows the present appearance of the patient.

A two-month-old boy (No. 27021), the first child of healthy parents, was born with a broad short nose, cleft at the tip. The columella was only 2 mm. long and more than 1 cm. broad. The nostrils were placed almost horizontally. There were two skin tags infront of the lobe of the left ear (Fig. 6). There was obvious hypertelorism. The X-ray disclosed a medial cleft in the maxilla and a wide vertical bony lamella in the skull. The child had a cervical rib and a dislocation of the spinal column.

Operation was performed at the age of three (1954). A columella was formed from the upper lip and the spongy substance situated between the lateral cartilages was removed and both cartilages sutured. Two years later the nose was still broad. It was interesting that the distance between the eyes did not increase. Treatment has not yet been completed (Fig. 7).

The patient P. A. (No. 20713), a woman aged 32, had an unusual type of

Fig. 6. Two-month-old boy V. L. with median cleft of the tip of nose and cartilaginous appendices in front of the left ear.

deformity. Its relation to the group of deformities under consideration was manifested by marked hypertelorism, at the same time the right orbit was further from the mid-line than the left. The bridge of the nose was flattened and inclined to the right where there was a sharp epicanthus. The right side of the nose was obviously shorter than the left, giving the impression of a coloboma. Another peculiarity was the underdevelopment of the right eyebrow where there were only sparse tufts of hair, some extending to the epicanthus.

A series of operations was performed. The eyebrow was shifted symmetrically to the left, the epicanthus corrected by a Z-plastic, and the right wing of the nose was reconstructed (Fig. 8, 9).

The most severe forms of medial cleft cause grotesque deformity of the face. Such was the case with F. V. (No. 1499), a 30-year-old man. He face was flat with eyes and eyebrows wide apart (6.5 cm.). The nostrils were narrow vertical slits 4 cm. apart. The medial side of each nostril was flanked by a ridge which descended to the upper lip getting broader and flatter.

The forehead was low and the hairline serrated with wedges of hair of varying length and width. Folds of skin ran up from the nostrils to the forehead where they disappeared (Fig. 10, 11).

Breathing was very limited and only possible through the right nostril, whose walls touched each other so that rhinoscopic examination was impossible. The left nostril was completely obstructed forming a blind canal 4 to 5 cm. deep.

Fig. 7. The boy V. L. two years after operation. The nose still very broad, will be corrected at a later date, when formation of the head is more advanced.

There was a prominent torus on the palate from which several folds of mucosa extended posteriorly. The soft palate was cleft and there was a submucosal cleft in the hard palate. Posterior rhinoscopy showed that there was atresia of the left choana. The X-rays showed a fine bony lamella in the median plane of the skull cavity reaching to half its height. On both sides there were fissures in the frontal bones. Only the right side of the nose could be filled with contrast material. The lateral projection showed a wide connection between the sphenoid and the maxilla and hard palate. The base of the skull and the lower part of the frontal bone were 1 cm. thick. At the site of the foramen coecum there was a 1 cm. wide duct leading under the short nasal lamella to the frontal bone.

During the year 1935—1936 several operations were performed. Part of the skin of the forehead was used to construct a nose. The nasal septum was duplicated and in the space between the lamellae was an homogenous shining substance which was removed. Both parts of the septum were fractured, brought together and sutured. The cleft palate was repaired. In place of the vomer there was a mass of compact bone which was connected to the base of the skull. Fine

Fig. 8. Fig. 9.

Fig. 8. P. A. 32-year-old woman showing a queer deformity of face, asymmetrical hypertelorism, coloboma of the right ala. — Fig. 9. Patient P. A. after the corrective operations.

Fig. 10. Fig. 11.

Fig. 10. Patient F. V. 30 years old. Severe form of median cleft complicated by other cranial and naso-oral anomalies. — Note the extreme degrees of hypertelorism. — Fig. 11. Profile aspect of patient F. V. shows flat nasofacial plane.

exostoses covered with mucous membrane were hanging from this into the oral cavity. The mucosa was removed from the exostoses and used to reconstruct the cleft palate.

A lamella of cartilage taken from the seventh rib was implanted in the nose to form the bridge. The patient did not complete treatment because he was killed in 1937 in a motor car accident (Fig. 12).

Fig. 12. Patient F. V. after a series of operations by which the nasal ducts were opened, the nose reconstructed, not yet modelled

According to experimental teratology and embryology this deformation can be traced to the third to eighth week. Foetuses younger than three weeks do not have a face. The anterior part of the cranial tube forms a centre lying on either side of which are the tubercles of the maxilla. The cranial protuberance covers the primary mouth cavity.

The anterior part of the brain increases rapidly by the rapid growth of the paraxial mesoderm, which invades the visceral mesoderm in company with the cranial nerves. Disturbances in the development of the paraxial mesoderm lead to some parts developing incompletely or not at all. The primary cause is a disturbance in the development of the anterior part of the cranial tube. Hypertelorism and a wide sella are evidence that there was a certain degree of hydrocephalus and that a certain part of the brain, especially the rhinencephalic part, did not develop normally. These disturbances induce irregular growth of the mesoderm. The centre of the face develops around the olfactory grooves. Their borders are raised and the forebrain protrudes over them. Between the two nasal grooves

is a depression (area triangularis) where the bridge of the nose is raised. Caudally, there is the area infranasalis, the future centre of the upper lip. At this stage the nose is devided by a deep groove between the primitive nostrils. Disturbances in the development of the mesoderm lead to this part remaining at a primitive stage. In this way deformities originate which bear the character of a median cleft.

The disturbance in the development of the brain is either primary or provoked by some external factor, such as local pressure or a local disease. A disturbance of the amnion could produce such an effect, if cords or folds exerted pressure on the face. It is not possible, of course, to arrive at a definite conclusion despite the great advances in experimental teratology. With these defects it is more probable that the fault lies with external factors than with heredity. There are, of course, exceptions since Esser published a whole series of cases from the Sanvenero-Rosselli Clinic in Milan among which was a family afflicted through several generations. External noxa primarily affect parts of the embryonic mass which are phylogenetically young, which is a sign of the higher development of the species. Malformations which call to mind states in the lower vertebrates thus originate in this way.

Recently, great attention has been paid to toxoplasma as a cause of congenital malformations. It has been shown that the parasite penetrates the placenta and becomes established in the organs of the embryo, producing developmental disturbances. In successive generations such parasitic infections can form heredity. Even the familial incidence, as reported by Esser, can be accounted for in this way.

Intense research work is necessary to throw light on the origin of congenital defects. Afflicted families should be studied in detail, including their geneological tables and their living conditions. Scientists should work collectively on such a task as this. Research carried out on an international scale could lead to the establishing of certain preventive measures. It might be possible to warn against unfavourable factors and even to eradicate the predisposition in affected families.

Congenital anomalies are an ever increasing burden on mankind both because the absolute number is increasing and also because the number that survive is increasing. They are not only a material burden to the community but are also a source of great moral suffering for the afflicted and their families.

SUMMARY

A number of abnormalities of the nose and the central part of the face belonging to the category of arhinencephalic displasia which are characterised by anomalies of the region of the anterior neuropore, are desribed. These changes in the structure of the face, their possible origin and the methods of plastic repair are dealt with in detail.

ВЫВОДЫ

Медиальные расщепления носа

Ф. Буриан

Описывается целый ряд аномалий носа и средней части лица, которые принадлежат к ариненцефалическим порокам развития и которые характеризуются повреждениями в области переднего neuroporus'a. Рассматриваются изменения структуры лица, возможности их возникновения и способы пластической коррекции.

RÉSUMÉ

Les Fentes Médiales du Nez

F. Burian

La déscription est faite des différentes anomalies du nez et de l'étage médial de la face, qui s'attachent à la série des anomalies arrhinencephaliques, dont le signe principal réprésentent les lésions de la partie du neuroporus antérieur. L'auteur discute les malformations dans la structure de la face et les possibilités de leur origine de même que les méthodes du traitement esthétique.

ZUSAMMENFASSUNG

Mediale Nasenspalten

F. Burian

Der Verfasser beschreibt eine Reihe von Anomalien der Nase und des mittleren Gesichtsteils, die zu den arhinenzephalischen Missbildungen gehören; diese letzteren sind durch Störungen im Gebiet des vorderen Neuroporus gekennzeichnet. Der Verfasser erörtert die Veränderungen, die in der Gesichtsstruktur vorgefunden werden, die Möglichkeiten ihrer Entstehung sowie die Arten der plastischen Korrektion.

(Akademik F. Burian): Škrétova 8, Praha 12, Czechoslovakia

Department of Plastic Surgery, Faculty Hospital, Košice (Czechoslovakia)
Director: R. Erdélyi, M.D., C.Sc.

THE SURGICAL TREATMENT OF SADDLE NOSE

R. ERDÉLYI

Saddle nose is due to partial or complete destruction of the nasal skeleton, mainly as a result of damage to the cartilaginous septum, the perpendicular plate, the nasal bones and sometimes the vomer. The commonest causes are trauma, syphilis and faulty submucous resection of the septum. If not reduced in time, frontal and laterofrontal fracture of the nose and septum often leave a depression. In tertiary syphilis the nose is a common site for gummas, including the nasal bones and the cartilaginous and bony septum, in which ulceration and sequestration occur. In submucous resection of the septum, unless an adequate strip of cartilage is left at the lower end of the nose and below the bridge, the inadequate support collapses after some months or years. Tuberculosis, caries of the bones and cartilage, leprosy and rhinoscleroma may also produce this deformity. In syphilitic children and infants saddle nose results from the development of syphilitic coryza with a chronic course, followed by ulceration and sequestration of the bones and cartilage. Not every saddle nose has a history of trauma or disease, however, since the nose is one of the organs whose form is inherited; no nose is symmetrical and individual familial and racial variations are so manifold that hardly two noses are alike. This also applies to congenital saddle nose, which occurs in a manifold variety of forms.

Depression of the bridge of the nose always causes considerable respiratory difficulties and even complete atresia of the nasal passages. Sometimes the whole or the cutaneous part of the septum (the columella) is absent and the apex of the nose has no support.

For the treatment of saddle nose Burian elaborated the method described below, which is used for the treatment of this deformity in the author's clinic. In general, the treatment consists in the following processes:

1. osteotomy of the nasal bones,
2. implantation of a corium-fat graft or acrylate,
3. implantation of a cortico-cancellous autograft or autogenic cartilage.

Before commencing the treatment of saddle nose, any loss of part of the mucous membrane or skin of the nose must first be replaced. In mild depression of the nose, fourfold osteotomy of the nasal bones and the frontal process of the maxilla is often sufficient (particularly after trauma) to narrow a broad nose

and at the same time raise the bridge. The nose is anaesthetized by one injection fanning out from the glabella to the apex.

If the depression is deep and the skin of the nose is immobile and tightly stretched, the soft coverings are loosened by inserting a corium-fat graft below the coverings of the nose through an incision in the columella. The graft is obtained by preparing a strip of skin in the hypogastrium and removing the epithelium. The exposed corium is then removed, together with a large or small layer of fat. The site of the graft is selected so that later, when removing a cartilage or bone graft, it is not necessary to make a fresh wound and scar elsewhere. The later bone graft is taken from above the iliac crest.

About three to four months later, after possible repeated implantation of corium-fat grafts, when the soft parts are dilated, the bridge of the nose is raised or the septum is replaced. In the case of a small depression, perichondral cartilage is sufficient; for a deep depression an osteochondral graft (¼ bone, ¾ cartilage) from a rib is used. The graft is fixed transcutaneously by pinning it to the nasal bone. Where a large part of the septum requires replacing and a support has to be formed for the apex of the nose, the most satisfactory is a cortico-cancellous graft from the ilium. A graft of the required size, which on section has the form of a right-angled triangle, is removed. The graft is modelled in approximately the form of the letter L, the short arm being intended for support of the apex and the long arm for the bridge of the nose. Access is obtained to the site of the absent septum via a vertical incision in the columella, below the skin of the nose, and the whole area is freed. The technique of inserting the graft via an intranasal incision has been abandoned because of the danger of infection, which even antibiotics fail to prevent. Over the bones of the nose the subperiosteal route is used. After the alar cartilages have been completely mobilized, the graft is inserted in the nose by introducing the long arm, consisting of cortical bone only, subperiosteally along the nasal bone, but only far enough to preserve the fronto-glabellar angle. Fixation is superfluous, since the graft is inserted below the periosteum and is firmly supported on the other side by the nasal spine. Cartilage is implanted in the nose in the same way. In this, and in subperiosteal insertion of the proximal part of the graft, Burian's method plays an important part. It is the most natural form of fixation of the graft and ensures perfect attachment of the cartilage to the bones of the nose. In saddle nose with a defect of the skin of the nose or of the columella, the defect must be treated before replacing the septum.

In addition to autoplastic material, alloplastic material has been, and still is used for repairing saddle nose. Celluloid, gold, silver, platinum, aluminium, vaseline and paraffin have now, in the main, been discarded, their place being taken by ticonium, tantalum, vitallium, plexiglas, acrylates and ivory. The main disadvantage of an alloplastic implant is that it can never take, in the biological sense, or become attached to the surrounding tissues. The dead implant is merely surrounded and encapsulated with granulation and fibrous tissue; the body is always trying to dispose of it and waits only for a convenient moment to expel it. Small episodes, such as slight trauma, near and metastatic inflammation, etc.,

hasten its expulsion. An alloplastic graft is always a non-biological enclave. Its harmonious, normal connection with the surrounding tissues is incompatible with biological laws.

The author has often had the opportunity of verifying these biological processes in practice. He has seen more than one patient with a temporary acrylate implant in the nose, which could easily and freely be twisted round its own axis by the fingers, through the skin, without any reaction in the surrounding tissue. This shows that the implant is tolerated well by the organism, but that it always remains a foreign body. Non-absorbable alloplastic materials have the advantage that their shape does not alter. They can be dangerous, however. Paraffin, for example, can, in the course of time, give rise to paraffinomata (pseudotumours with a chronic inflammatory course). Paraffin can also be a carcinogenic agent. In recent years reports on permanent acrylate inplants in the face have been published. They only cover periods of two to three years after the operation, however — too short a time for a definite conclusion. In the meantime reports on the carcinogenic effect of acrylates have appeared. In animal experiments, the formation of a carcinoma was observed eight to ten years after permanent implantation. Although the results of animal experiments cannot be applied absolutely to human medicine, the permanent implantation of acrylates in the human body should be avoided.

Probably the only circumstances under which the temporary use of non-absorbable alloplastic material is justified is to free and stretch the soft coverings of the nose, particularly in children, in whom saddle nose cannot finally be corrected until puberty, or in cases of repeated absorption of corium-fat grafts. In the author's experience, the best substances (or temporary implants for the purpose of preparation and dilatation are acrylate and ivory. The latter is refined material very similar to bone and because of its hardness is relatively easy to deal with both before and after the operation. The early implantation of ivory was found to have a good effect not only on the state of the skin, but also on the development of the whole area, where there is a broad basis (usually the whole of the middle section of the face).

The fate and manner of healing of living material is quite different. In this case conditions for a true take are present. The graft itself, as well as the tissue to which it is transplanted, takes full part in vital processes and in time becomes part of the organism as a whole. This is the whole purpose of transplantation of living matter. Corium-fat grafts are nourished at first by imbibition. Although this type of graft shrinks in a short time through wrinkling, in rhinoplasty, if correctly fixed, with reference to its changeable form, it fulfils its purpose, i. e. to extend the cutaneous covering of the nose so as to reduce pressure on a solid implant. Cartilage is not vascularized and receives its nutrition by means of osmosis. The greater part of the cartilage becomes organically attached to the surrounding granulation tissue and years after — if the cartilage is not damaged during implantation — only signs of aging can be detected. Cartilage solidifies by calcification and asbestos transformation (Burian). Osseous connections are not formed, but the graft becomes firmly attached to the connective tissue. Deteriora-

tion and resorption are very rare and occur only if the graft is damaged during manipulation at operation. The chief advantage of cartilage is that it keeps its resilience. Sometimes, however, distortion may occur, especially in the case of large grafts, as a result of traction by scar tissue. This can often be prevented by using an osteochondral graft, i. e. an autograft composed of bone and cartilage. The bone becomes firmly attached to the nasal bones and the graft maintains its direction.

With cortico-cancellous grafts the process is somewhat different. The physical-biological advantage of these grafts is that the cortical bone makes the graft firm and the spongy bone acts mainly as an osteogenic medium. Vascularization is rapidly renewed after transplantation, since the loose structure of the spongy bone permits invasion of the trabeculae by small blood vessels from the surrounding tissues. It is known that almost all the mature elements of the cortical and spongy bone die, but that the production of new bone soon begins from the cells of the endosteal and periosteal layers. Part of the cortical bone dies and part produces new bone. The spongy bone remains intact without rarefaction and the peripheral part is converted into cortical bone, forming a firm base for the bridge of the nose. Although the osteogenic activity of the periosteum is not very great, it also forms bone, with the result that the graft presents a complex, very slightly diminished in size, with an almost complete covering of cortical bone, firmly attached to the surrounding parts. Insertion of the part of the graft containing no spongy bone below the periosteum at the root of the nose results in firm connection with the bones of the nose (os novum). For the above reasons the transplantation of cortical bone without spongy bone is not suitable. The ideal site for obtaining a corticocancellous graft is the iliac crest. The tibia is no longer used because of the lack of spongy bone and the danger of fracture.

Preserved homoplastic material has been used in very few cases; in the majority it was either eliminated or absorbed. It is known that the cells of homogenous bone, whatever the method by which the bone is preserved, do not survive after implantation, but are replaced by bone from the bed. Peptic leucocyte ferments dissolve the dead protein-containing mass, so that if the implant is not completely absorbed, it merely acts as a skeleton for the newly formed bone. Homoplastic material is therefore employed only in selected cases in which its use is justified. Heteroplastic material is not used, as it is still in the experimental stage.

When the author worked at Professor Burian's Clinic of Plastic Surgery in Prague, he examined all cases of bone and cartilage transplantation in the nose (up to 1949). Of 309 autografts transplanted by different surgeons, 9% were rejected. The main failures were cases of saddle nose of syphilitic origin or after lupus. In the same clinic, Karfík (1943) reported on 108 cases of transplantation of ivory in the nose, with 36% failures. The results in the author's present department (though in a considerably smaller number of cases) not only confirm these results, but actually show some improvement as a result of the larger selection of antibiotics now available. Tolerance of artificial substances was much lower than the take of autoplastic material.

In conclusion it can be stated that in the surgical treatment of saddle nose autoplasty takes precedence over alloplasty. The transplantation of autoplastic, living material may not be the simplest method, but it is the most natural. Only living material can be incorporated into the new environment. It is possible — and probable — that suitable alloplastic material can be found, but even this is comparable only with a dead implant. The results of treatment of saddle nose by alloplasty are often better than an autograft as far as form is concerned, but it is impossible to say whether an alloplastic implant will not be expelled after some years. Homoplastic grafts are very often absorbed or replaced by fibrous tissue. When autoplastic grafts have once taken, they are never eliminated, unless infection occurs immediately after transplantation. The ideal graft should be able to be used rapidly and should be sufficiently large. Its consistency should be such as to allow it to be modelled as required and it should be resistant to absorption. It should not change form after implantation, but should become a firm part of the given site and should be tolerated by the surrounding tissues. Cartilage and bone obviously fulfil most of these conditions and it is therefore safe to claim that bone occupies first place in reconstructive surgery of the nose. Its biological and physical properties are indispensable in reparative rhinoplasty. In corrective surgery of the nose free cartilage grafts are the most satisfactory.

SUMMARY

A brief description is given of the aetiology, pathogenesis and clinical aspects of saddle nose and of the principles of Burian's method of treatment.

The method consists in the implantation of a corium-fat graft or acrylate and in implantation of a cortico-cancellous bone autograft or of autogenic cartilage.

In a large proportion of cases homoplastic grafts are absorbed or replaced by fibrous tissue and are therefore unsuitable material for repairing saddle nose. Heterogenous grafts are not used, since this question is still in the experimental stage.

The author draws attention to the possibility of using alloplastic material for the purpose of correcting saddle nose, but also points out the danger of the carcinogenic effect of some alloplastic materials. This danger is not excluded even in the case of acrylate, if permanent acrylate implants are used. Acrylate can therefore be used as a temporary implant only, for the purpose of dilatation.

No alloplastic implant "takes" in the biological sense and it never becomes attached to the surrounding tissues. It may still be expelled after many years. When once it has taken, autoplastic material is never rejected. Experience shows that bone grafts are the most satisfactory in reconstructive surgery of the nose and that free cartilage grafts are the best in corrective surgery.

ВЫВОДЫ

Хирургическое лечение седловидного носа

Р. Эрдельи

После короткого описания этиологии, патогенеза и клиники седловидного носа разобраны принципы его лечения, разработанные академиком Бурианом в клинике пластической хирургии в Праге. Лечение состоит в общем из следующих частей: из остеотомии носовых костей, из пересадки кожно-жирового трансплантата или акрилата и из пересадки корково-губчатого аутотрансплантата или аутогенного хряща. Гомопластический имплантат, в большинстве случаев, резорбируется или заменяется фиброзной тканью, поэтому он не представляет собой пригодный материал для выравнивания седловидного носа. Гетерогенный трансплантат мы не применяем, так как применение его находится еще в экспериментальной стадии.

Указано на возможность применения аллопластического материала с целью выравнивания седловидного носа и вместе с тем обращено внимание на возможность канцерогенного действия некоторых аллопластов. Также и у акрилатов нельзя сегодня исключить канцерогенное действие, если они имплантированы навсегда. Однако, акрилат можно применять в качестве временного, подготовительного расширяющего вкладыша.

На один аллопласт в биологическом смысле никогда не приживет и не соединится с окружающей его тканью и может даже через несколько десятков лет выделиться. Аутопластический материал, если он уже прижил, то не выделяется. Опыт показал, что костный трансплантат занимает ведущее место в восстановительной хирургии носа, а в корригирующей хирургии — свободно пересаженный хрящ.

RÉSUMÉ

Le Traitement Chirurgical du Nez en Selle

R. Erdélyi

Une déscription de l'étiologie, de la pathogénèse et de la clinique du nez en selle, du même que les règles du traitement, élaborées par académicien Burian à la clinique de la chirurgie plastique à Prague, vient d'être décrite.

La thérapie se compose de l'implantation du transplant dermo-souscutané, d'acrylat et de l'implantation d'autogreffes de l'os compact et spongieux ou d'autogreffe du cartillage.

Le transplant homoplastique se résorbe en bien grand nombre des cas, soit il se remplace par le tissu fibreux et devient de cette raison un matériel peu convenable quand à l'accomplissement du nez en selle.

L'on ne se sert point d'hétérotransplant car la sollution de ce problème ne se trouve qu'en stade des recherches expérimentalles.

La littérature signale la possibilité de l'emploie du matériel alloplastique en correction du nez en selle, mais, en même temps, elle indique la possibilité de l'effet carcinogène de certes alloplastes. Cet effet carcinogène n'est point négligeable chez certes acrylats, du moment qu'ils sont implantés à demeure. C'est pour cela qu'on ne se sert de l'acrylat qu'en forme de l'enjeu dilatateur.

Quiconque matériel alloplastique ne guérrit jamais au sens biologique et ne se réunit jamais au tissu des environs. Il peut être rejeté des dizaines d'années même après l'implantation. Le matériel autoplastique, au contraire, une fois guérrit, n'est guerre rejetté par l'organisme. Les expériences ont montré que la greffe osseuse occupe la place supérieure en chirurgie réconstructive tandis que le cartillage l'occupe en chirurgie réparatrice.

ZUSAMMENFASSUNG

Die chirurgische Behandlung der Sattelnase

R. Erdélyi

Es wird eine kurze Beschreibung der Äthiologie, Pathogenese und Klinik der Sattelnase unter gleichzeitiger Anführung der Behandlungsprinzipien gegeben, die and der Klinik für plastische Chirurgie in Prag von Akademiker Burian ausgearbeitet wurden.

Der Behandlungsvorgang beruht in der Implantation eines Corio-Fettgewebetransplantates oder Akrylates und Implantation eines cortico-spongiosen Knochens oder eines autogenen Knorpels.

Das homoplastische Implantat wird in einem ziemlich hohen Prozentsatz resorbiert oder durch fibröses Gewebe ersetzt und ist aus diesem Grunde ein unverlässliches Füllmaterial für die Sattelnase.

Heterogene Transplantate wurden nicht verwendet, da sich die Lösung dieser Frage noch im experimentellen Stadium befindet.

Es wird auf die Verwendungsmöglichkeit von alloplastischem Material zwecks Sattelausgleich hingewiesen, wobei gleichzeitig auf die Möglichkeit einer cancerogenen Wirkung einiger Alloplasten aufmerksam gemacht wird. Selbst bei Akrylaten ist heute eine cancerogene Wirkung nicht auszuschliessen, soweit es sich um eine Dauerimplantation von Akrylaten handelt. Akrylate können jedoch als zeitweilige vorbereitende Dilatationseinlagen verwendet werden.

Jedwedes alloplastische Material heilt niemals in biologischem Sinn ein und verbindet sich nicht mit dem benachbarten Gewebe. Es kann auch nach Jahrzenten eliminiert werden. Soweit das autoplastische Material einmal eingeheilt ist, wird es nicht mehr ausgeschieden. Die Erfahrungen haben gezeigt, daß das Knochentransplantat eine führende Stellung in der rekonstruktiven Nasenchirurgie und der frei übertragene Knorpel in der Korrektionschirurgie einnimmt.

REFERENCES

1. **Berndorfer, A.**: Orv. Lapja 3, 143, 1947.
2. **Blegvad, G.**: Pract. oto-rhino-laryng. (Basel) 10, 162, 1948.
3. **Burian, F.**: Rev. Chir. struct. 4, 132, 1937.
4. **Converse, A.**: Plast. reconstr. Surg. 5, 247, 1950.
5. **Ersner, A.**: Eye, Ear, Nose Thr. Monthly 26, 23, 1947.
6. **Karfík, V.**: Čas. Lék. čes. 27, 756, 1943.
7. **Kartashev, K.**: Chirurgiya (Mosk.) 4, 6, 1950.
8. **Kramarenko, I.**: Chirurgiya (Mosk.) 3, 29, 1950.
9. **Mohr, R.**: Dtsch. zahnärztl. Z. 3, 792, 1948.
10. **Malbec, E.**: Rev. Asoc. méd. argent. 60, 761, 1946.
11. **Malbec, E.**: Dia méd. urug. 19, 2405, 1947.
12. **Penn, O.**: S. Afr. med. J. 20, 666, 1946.
13. **Rapin, M.**: Pract. oto-rhino-laryngol. (Basel) 12, 405, 1950.
14. **Surnney, L. et al.**: Lancet 2, 389, 1947.
15. **Vainio, S.**: Duodecim (Helsinki) Suppl. 27, 1, 102.
16. **Šula, J.**: Čs. Stomatol. 3, 85, 1957.

(Dr. R. Erdélyi): Zimná 16, Košice, Czechoslovakia

Department of Plastic Surgery, Peking Medical College, 2nd Hospital, Peking (China)
Director: prof. Chu Hung-yin

RECONSTRUCTION OF THE THUMB

CHU HUNG-YIN, WANG TA-MEI, KUNG FAN-HU, HOU CHU-JEN

The main cause of defects of the thumb is trauma and since the defects vary in degree, methods of repair also vary. This article deals with the treatment of complete loss of both segments of the thumb.

When both digital segments of the thumb are damaged, the adjacent structures are also likely to be damaged; for example, the first metacarpal bone may sustain partial or complete destruction and soft tissues such as the thenar muscle, tendons of the thumb and the adjacent skin may be injured. These are among the factors which influence the selection of methods of repair and functional recovery.

Ideally, reconstruction of the thumb should fulfil two purposes: (1) The reconstructed thumb should have the function of extension, flexion and opposition and should also have strength. (2) It should have stereognosis.

The many methods of thumb reconstruction fall into two main categories: The first involves the use of a tube pedicle and bone grafting and the second utilizes a finger or toe for transplantation.

The first kind is relatively simple but has many shortcomings. The thumb reconstructed in this way, itself has no power of extension and flexion and depends on the first metacarpal for any movement. Therefore, integrity of the first metacarpal and the thenar eminence are decisive factors in the result of such operations. If the first metacarpal is completely missing, then it is only possible by this method, to make an immobile stump standing out of the palm, and the pinch function can only be obtained by bringing the other fingers to it. The presence of the reconstructed immobile thumb standing out of the palm may handicap the patient a great deal in such tasks as laundering or holding large objects. Even when the first metacarpal is intact and is able to import a certain mobility to the thumb, the slackness and softness of the flap, its liability to abrasion and burns and its grossly deficient sensation all cause great inconvenience.

The second kind of thumb reconstruction is to transplant a finger or toe in place of the missing thumb. If the opposite hand or a foot is used for this purpose, it is not only necessary to perform several operations thereby inconveniencing the patient a great deal, but more important, since the nerves and vessels must be severed, the transplanted digit must rely on regenerated nerves and vessels which often prove inadequate and result in nutritional disorders of

the bone and soft tissues and in blunt sensation. The final result, therefore, of such operations is not any better than the results of thumb reconstruction using a tube pedicle.

There are many ways of transplanting a finger from the same hand to replace the missing thumb. One is to maintain the attachment of a temporary pedicle to

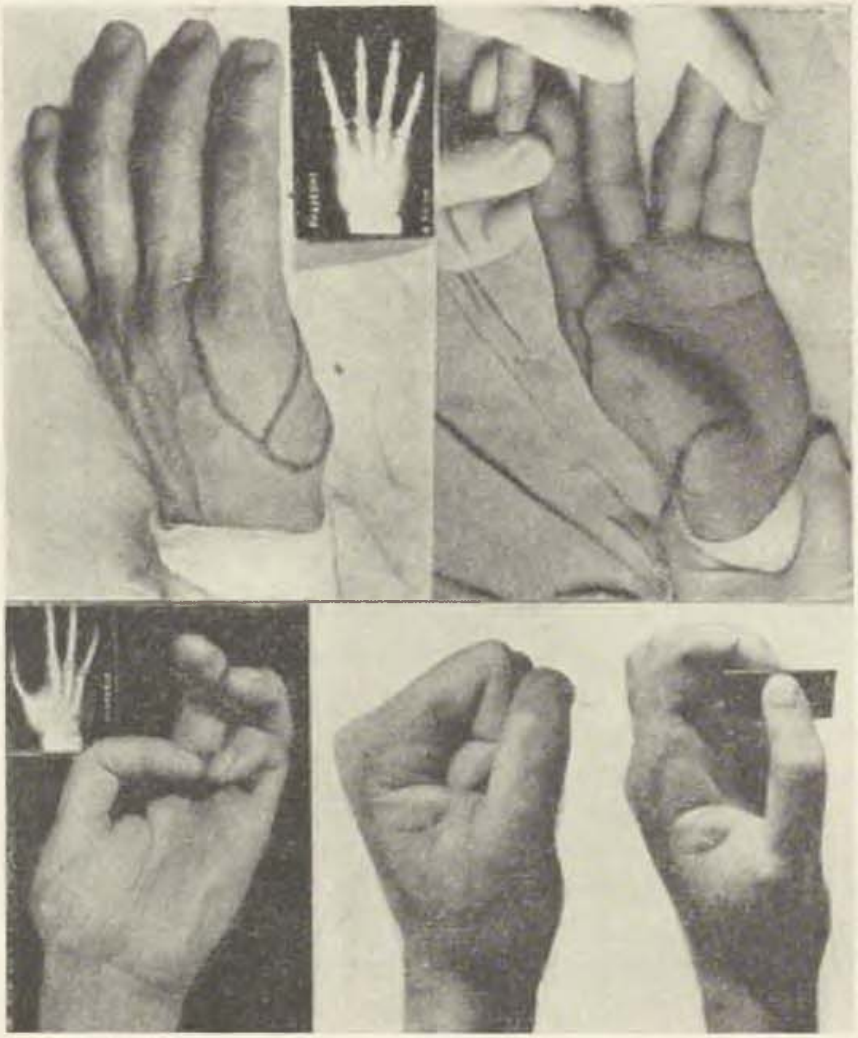

Case 1. Wang Yung, 5463544, male, age 26, electric welding worker. Left thumb caught in pneumatic drill in 1951. Soft tissues distal to the base of thumb all torn away. First metacarpal excised and wound sutured. — Admitted December 26th, 1954. Left thumb and metacarpal absent. Pollicization of index finger performed December 30th, 1954.

the finger during transplantation and to divide it after the finger has acquired a new blood supply. The results of this method are similar to those of the above mentioned method of finger transplantation since the vessels and nerves of the finger are also divided. Another method is to transfer the index finger step by step to the position of the thumb — to divide the operation into stages. During this process the main nerves and vessels remain intact. Although the results of this kind of operation are relatively better since the main nerves and vessels are

preserved, accurate placing of the index finger is rendered difficult by the necessity of inserting a skin flap. The fact that the operation has to be performed in stages is also a disadvantage.

A relatively ideal method — the method recommended in this article — is to transfer the index finger to the position of the thumb in one operation on the

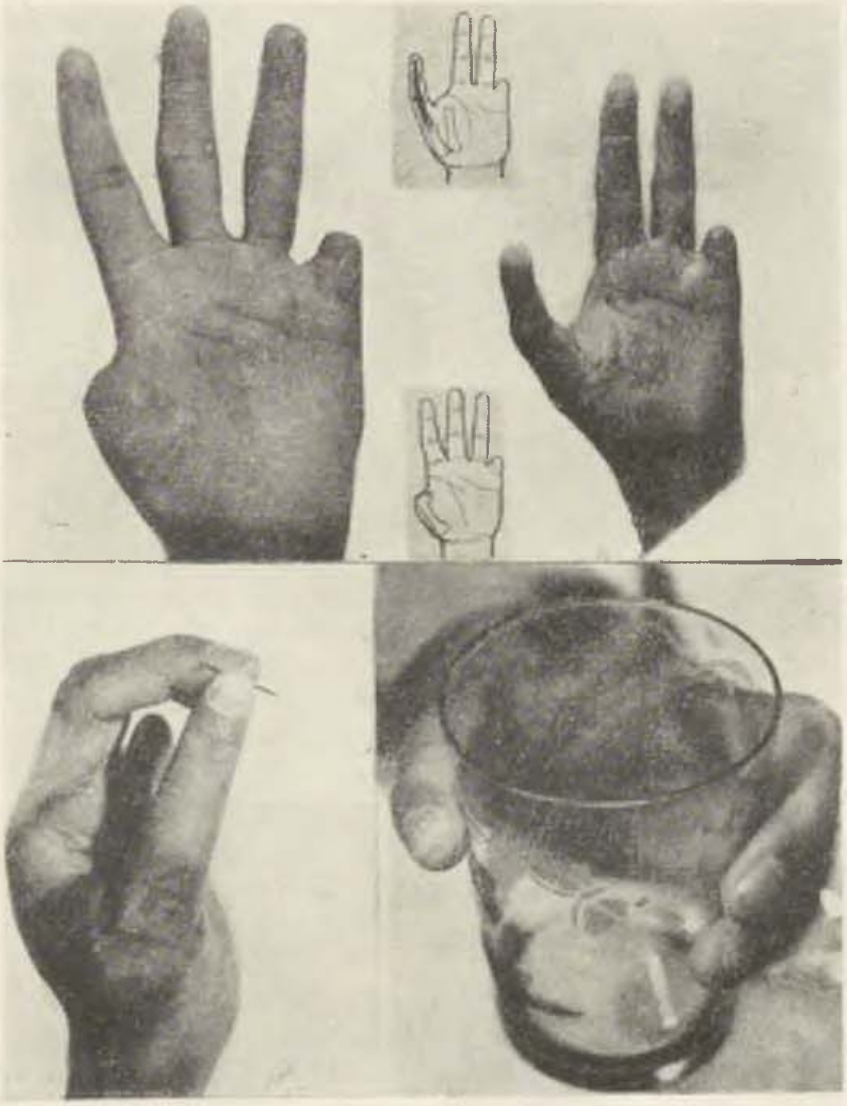

Case 2. Wang Chen-chia, 5634240, male, age 39, paper factory worker. Crushing injury of left thumb and little finger by 5-ten-machine in 1954. Little finger and thumb amputated. Later the little finger was amputated because of necrosis. — Admitted July 25th, 1956. Left thumb from metacarpo-phalangeal joint and all 3 digital segments of little finger missing. Pollicization of index finger performed August 13th, 1956.

basis of the principle of the "artery flap". This method was first used by S. Bunnell (1952) and J. W. Littler (1953).

The steps of the operation as performed by us are illustrated in the following sketches:

Flap I is made surrounding the base of the index finger. Flap II is made surrounding the stump of the thumb (Figure I. a).

A superficial vein leading to the index finger is dissected out but left in continuity with the flap, the extensor tendon to the index finger is divided at a suitable level (Figure I. b).

Case 3. Chang Teh-chung, 5633939, male, age, 19 machine worker. Left thumb amputated by machine March 1956. Wound excision and skin suture performed. Wound infection developed. Skin grafting carried out and wound healed 20 days later. — Admitted August 16th, 1956. Left thumb and part of first metacarpal missing. Pollicization of index finger performed August 23rd, 1956.

Case 3. Chang Teh-chung, 563939, male, age 19, machine worker. Left thumb amputated where in December 1956 because of tuberculosis of 5 years duration. — Admitted December 15th, 1956. Left thumb missing from metacarpo-phalangeal joint. Pollicization of index finger performed December 29th, 1956.

The space between the index finger and the middle digit is dissected. The superficial transverse ligament is severed and the branch of the common digital artery leading to the middle digit and the sub-branches leading to the palmar

and dorsal skin are severed and ligated. The deep transverse ligament is divided. The neurovascular bundle of the ulnar aspect of the index finger is separated. The muscles attached to the second metacarpal are displaced (Figure I. c).

The neurovascular bundle of the radial aspect of the index finger is separated. The attachment of the first dorsal interosseus muscle to the proximal phalanx of

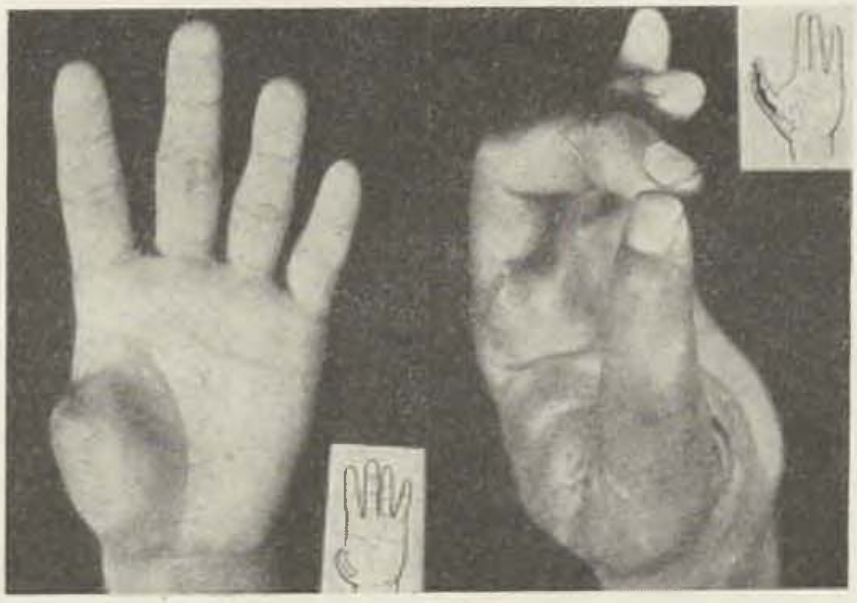

Case 5. Juan Ch'eng-ping, 5728782, male, age 34, worker. Left thumb destroyed from middle of proximal phalanx by shotgun explosion December 1956. Wound excision and a suture carried out. — Admitted May 31st, 1957. Left thumb absent with partial loss of metacarpal on admission. Pollicization of index finger performed June 8th, 1957.

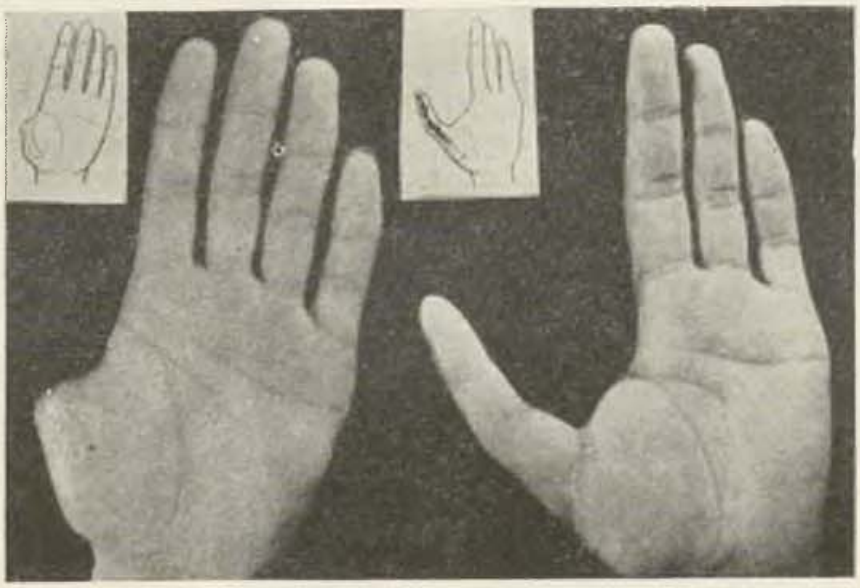

Case 6. Wu Lung-chung, 5733690, male, age 22, enamel worker. Left thumb injured by machine 1953. Two operations of unknown kind in another hospital. — Admitted October 11th, 1957. Absence of left thumb and partial loss of head of first metacarpal. Pollicization of index finger performed October 24th, 1957.

the index finger is divided. The second metacarpal is sectioned (Figure I. d, e), and the index finger is transferred to the position of the thumb. If there is complete loss of the first metacarpal, the second metacarpal stump is spiked into a socket made in the trapezium and fixed with Kirschner wire. If there is still a remnant of the first metacarpal, it is joined to the stump of the second meta-

Case 7. Yang Hsiao-suo, 5741050, male, age 19, printing worker. Crushing injury of left thumb by paper cutting machine August 1956. Wound sutured. — Admitted November 20th, 1957. Absence of left thumb metacarpo-phalangeal joint and partial loss of head of first metacarpal on admission. Pollicization of index finger performed November 25th, 1957. — In 1958 and 1959 the authors performed another 3 such operations in other hospitals. Altogether 10 cases were done.

carpal, but since a thumb thus reconstructed may be longer than necessary, it is better to join the proximal phalanx of the index finger to the first metacarpal stump. Intramedullary fixation is done with a bone graft obtained from the second metacarpal stump. The extensors of the index finger are sutured to the extensors of the thumb (Figure I. f). The skin is sutured.

DISCUSSION

1. The pre-operative plan should be carefully made so as to ensure that all wound surfaces can be covered up after exchanging positions between flap I and II. It is inevitable that scars will be found at the base of flap II as a result of previous trauma, but slight scarring does not affect the viability of the flap. If circulatory insufficiency at the distal end of the flap becomes apparent during transference, that part of the flap should be excised and used as a free graft in order to obviate the risk of subsequent necrosis.

2. In dissecting flap I, a superficial vein draining it should be preserved and transferred together with the index finger. This will constitute the main venous return for the index finger after it is separated from its base.

3. In a normal hand, with the fingers extended, the tip of the thumb is slightly below the level of the proximal interphalangeal joint of the index finger. A re-

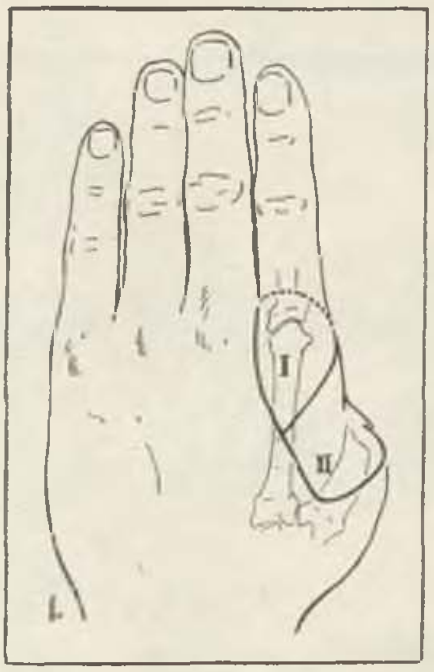

Fig. 1a.

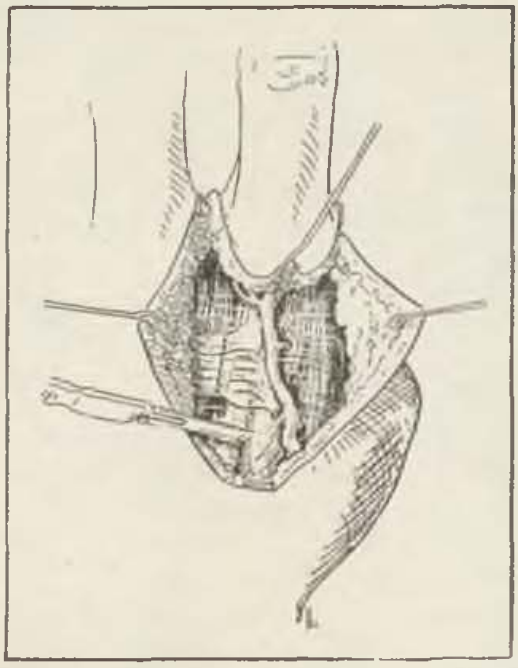

Fig. 1b.

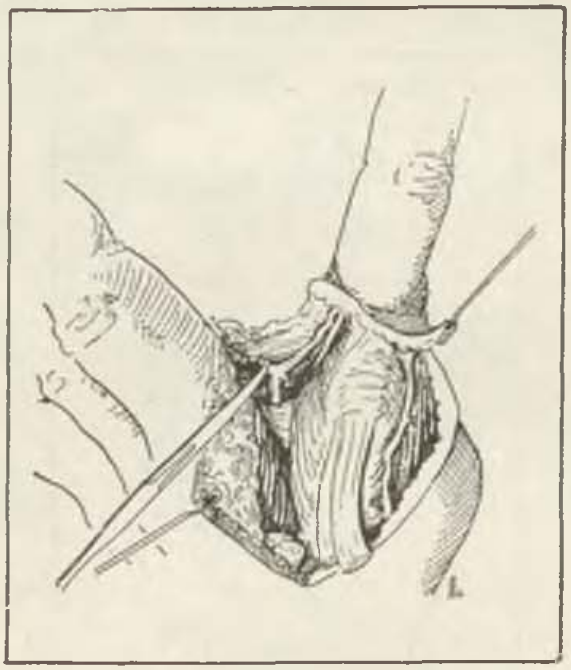

Fig. 1c.

constructed thumb should aim at this length. When the first metacarpal is intact or has only a partial defect, if the proximal phalanx of the index finger is transplanted to the first metacarpal, the length of the "thumb" so reconstructed is right.

If there is a complete or major loss of the first metacarpal, the index finger together with a part of the second metacarpal should be transplanted to the trapezium or to the stump of the first metacarpal.

Fig. 1d.

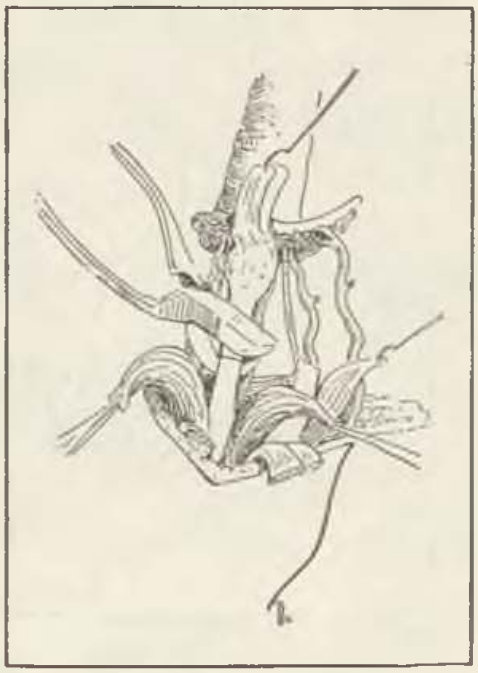

Fig. 1e.

Fig. 1f.

4. After the index finger is transferred to the position of the thumb, the tendons may become slack. Since the extensors are sutured to the extensors of the

thumb, they should be shortened to maintain normal tone. The flexors are transferred intact together with the index finger. In Littler's opinion, shortening of the flexor tendon is necessary a few months after operation. But according to our experience, this step is in fact unnecessary. Flexion returned in all our cases within a few weeks of post-operative functional exercises and with reasonable strength and therefore we did not carry out tendon shortening. This was probably be due to the fact that the tendon sheaths were transferred together with the flexors, so that adhesion between the strong tendon sheath and surrounding tissues constructed a pulley which increased the range of sliding movement of the tendon and therefore eliminated slackness.

5. After loss of the thumb, functional activity of the injured hand is reduced and the muscles become weaker. Therefore, pre-operative functional exercises are important in obtaining a good post-operative result.

SUMMARY

Since 1954, 9 cases of transposition of the index finger were done in the Peking Medical College Hospital. The index finger with its neurovascular bundles and flexor and extensor tendons are transposed to the position of the thumb. In case both the thumb and the first metacarpal bone are lost, the index finger and part of the second metacarpal bone are transposed, and the stump of the second metacarpal bone is inserted into the multiangular bone. If part of the first metacarpal bone is preserved, it is united to the proximal phalangeal bone of the index finger. Extensors of the index finger are united to those of the thumb. The flexors of the index finger are kept intact when the latter is transposed. Results of the 9 cases were uniformly satisfactory both in sensation and motion.

ВЫВОДЫ

Реконструкция большого пальца

Чу Хунг-ин, Ванг Та-мей, Кунг Фан-ху, Хао Чу-джен

Начиная с 1954 года, в факультетской больнице в Пекине в девяти случаях была произведена транспозиция указательного пальца (137). При этом методе указательный палец вместе с нервно-мышечными пучками и сухожилиями разгибателей и сгибателей переставляется в положение большого пальца. В тех случаях, когда отсутствует палец и его пястная кость, переставляется указательный палец вместе с его пястной костью и последняя вставляется в большую многогранную кость. Если часть первой пястной кости сохранена, то на нее насадивается фаланга указательного пальца. Сухожилие разгибателей указательного пальца присоединяется к сухожилиям разгибателей большого пальца. Сухожилия сгибателей указательного пальца остаются при транспозиции ненарушенными. Результаты, полученные в девяти случаях, оказались большей частью удовлетворительными. как в отношении чувствительности, так и в отношении движения.

RÉSUMÉ

Chu Hung-yin, Wang Ta-mei, Kung Fan-hu, Hou Chu-jen

La Réconstruction du pouce

Dès l'année 1954, la transposition du pouce a été pratiquée neuf fois en Hôtel-Dieu de la Faculté de Médicine de Peking. L'index — ces nerfs, ces vaisseaux, ces tendons

des fléchisseurs et des extenseurs y compris — devient transposé en place du pouce. Là, ou il y a à la fois manque du métacarpien, l'index devient transposé avec même une partie de son métacarpien, laquelle se fixe en os multangulum majeur. Au cas de survie d'une partie même du premier métacarpien, la phalange basale de l'index se fixe là-dessus. Les tendons des extenseurs de l'index se fixent aux tendons des extenseurs du pouce, et doivent rester indemnes durant la transposition. Les résultats des neufs cas cités étaient favorables en somme quand à la sensation de même qu'au mouvement.

ZUSAMMENFASSUNG

Daumenrekonstruktion

Chu Hung-yin, Wang Ta-mei, Kung Fan-hu, Hou Chu-jen

Seit dem Jahre 1954 wurde im Fakultätskrankenhaus in Peking neunmahl eine Transposition des Zeigefingers durchgeführt (137). Der Zeigefinger wurde zusammen mit seinen neurovaskulären Bündeln, sowie Extensoren- und Flexorensehnen in Daumenstellung übergeführt. Dort wo der Daumen und sein Metacarpus fehlt, wurde der Zeigefinger und ein Teil seines Metacarpus transponiert und dieser hernach in den os multangulum majus eingepflanzt. Bleibt ein Teil des ersten Metacarpus erhalten, wird auf diesen das Grundglied eingepflanzt. Die Extensorensehnen des Zeigefingers werden den Extensorensehnen des Daumens angegliedert. Die Flexorensehnen des Zeigefingers bleiben bei der Transposition unversehrt. Die Ergebnisse waren in allen 9 Fällen durchwegs befriedigend u. zw. hinsichtlich Empfinden und Beweglichkeit.

REFERENCES

1. **Bunnel, S.**: Surgery of the Hand. 3rd edition.
2. **Littler, J. W.**: Plast. Reconstr. Surg. 12 : 303, 1953.

(Dr. Chu Hung-yin): Peking Medical College, 2nd Hospital, Peking, China

Clinic of Plastic Surgery, Medical Faculty, Comenius University, Bratislava
(Czechoslovakia)
Director: Doc. Š. Demjén, M. D.

FREE TENDON GRAFTS IN PRIMARY REPAIR OF INJURY TO THE FLEXOR TENDONS OF THE HAND IN THE AREA OF THE FIBROUS SHEATH

A. TÖRÖKOVÁ

Today it is generally acknowledged that secondary reconstruction of injured tendons of the flexors of the hand in the area from the proximal finger joint to the distal joint, i. e. in the area of the relatively rigid osteofibrous sheath, using free tendon grafts, gives better results than primary suture, even if the tendon of the flexor profundus only is sutured and the tendon of the flexor sublimis is resected.

Since January 1956, in an attempt to shorten the time of disability and improve the functional result, the author has used free tendon grafts in the primary repair of injury to the flexor tendons in the area of the osteofibrous sheath.

Since the functional results after reconstruction of the flexors are directly related to the extent to which firm adhesions are formed between the sutured part of the tendon and the surrounding tissues, it was necessary to avoid every known cause of such adhesions.

On principle this method was used for sharp, clean injuries only, since in lacerated and contused wounds and complicated injuries involving damage to the bone, etc., the formation of firm adhesions is more than likely.

The formation of firm adhesions was avoided as far as possible by observing principles of atraumatic operative technique.

The method and operative technique were as follows: Using general anaesthesia the operation was performed in a bloodless operation field by applying the cuff of a manometer for not more than 70 minutes. Antibiotics were given before the operation and for seven days after to avoid the danger of adhesions being formed as a result of infection.

The operation field was exposed by extending the wound mediolaterally and raising a skin flap. In the palm, the physiological creases were used as far as possible.

In two cases the tendon of the palmaris longus was used as the graft and in two cases the tendon of the flexor sublimis was used. The surface of the grafts was smooth, glossy and uninjured. The proximal stump of the tendon of the flexor profundus was resected close to the site of origin of the lumbrical muscle

and 0.5 cm. of the distal stump was left at the insertion on the distal phalanx. The tendon of the flexor sublimis was resected at the transition to the belly of the muscle on the forearm and was drawn out of the palm. The distal stump of this tendon was resected near the insertion on the middle phalanx, leaving a 1 cm. stump on both sides.

Fig. 1. Knife injury severing tendons of flexors of fourth and fifth finger. Patient E. Č.

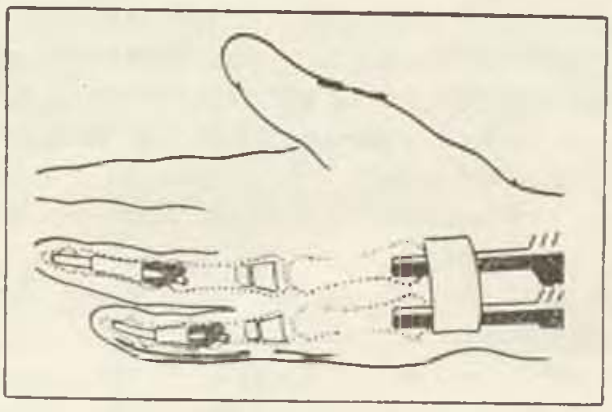

Fig. 2. Diagram of severed tendons of flexors of fourth and fifth finger. Patient E. Č.

The fibrous sheath was resected leaving a band of the annular ligaments on the basal and middle phalanx. The graft was drawn through the bands of annular ligaments and fixed to the distal stump of the tendon of the flexor profundus by a crossed suture. After suture of the skin of the finger, a proximal anastomosis was performed between the graft and the proximal stump of the tendon of the flexor profundus, using a crossed buried suture, or, if the graft was very much thinner than the tendon of the flexor profundus, the anastomosis was made by drawning the graft through a slit in the tendon, burying the free end. The free end of the tendon of the flexor profundus was split, thinned out and sutured to the graft so as not to leave an exposed raw surface. Before suturing, the paratendon was dissected away from the tendon in a proximal direction for a distance

of about 1.5 cm. and was afterwards used to cover the sutured part. When suturing the tendon to the graft, care was taken not to leave loose tendon fibres and if necessary, auxiliary sutures were used for apposition. The tendon was sutured with monofilamentous fibre, using an atraumatic needle.

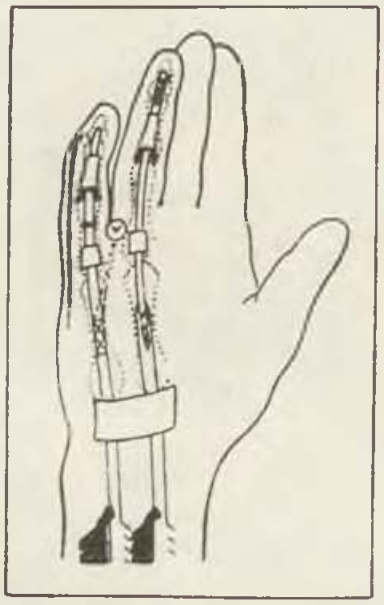

Fig. 3.

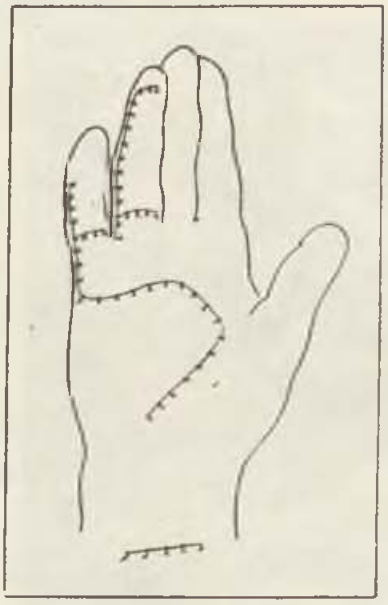

Fig. 4.

Fig. 3. Diagram of sutured tendon graft in fourth finger and suture of tendon of flexor profundus in fifth finger. The resected tendon of the flexor sublimis is sutured to the tendon of the deep flexor in the forearm. Patient E. Č. — Fig. 4. Skin incisions exposing operation field. Patient E. Č.

Fig. 5. Position of fingers after reconstruction of tendons on fourth and fifth finger. Patient E. Č.

The length of the graft was estimated according to Rank by performing the proximal suture with the finger flexed in the interphalangeal joints, with no tension in the proximal stump of the tendon.

The patient spent seven days in hospital. The skin sutures were removed after 10 to 14 days in the out-patients' department.

All the fingers were immobilized by a dorsal plaster, which was applied from the tips of the fingers as far as the elbow and was removed three weeks after the

Fig. 6.

Fig. 7.

Fig. 6. Degree of active flexion 14 months after injury, after primary tendon graft in fourth finger and primary suture in fifth finger. Patient E. Č. — Fig. 7. Degree of extension 14 months after primary tendon graft in fourth finger and primary suture in fifth. Patient E. Č.

injury. Rehabilitation therapy, which was carried out at the outpatients, consisted in baths and exercises. Four patients have so far been treated in this way.

The functional results in the first two are very good. Both patients can bend the finger to the palm and the strength of the finger is normal. In one case extension is normal, in the other the distal joint is 14 degrees short of full extension. In the other two patients the functional result can be classified as satisfactory. One year after the injury, active flexion of the finger is 2 cm. short of the palm. Except for one patient, in whom simultaneous injury to the tendons of the middle finger required operation, the patients were away from work for 6—8 weeks.

The range of movement in the interphalangeal joints in individual patients after one to 1½ years was as follows:

Patient No. 1: The middle joint could be moved for 180—83 degrees. i. e. a difference of 97 degrees. In the distal joint movement was 166—104, a difference of 62 degrees. The normal range of movement is individual and varies according to occupation. In subjects performing heavy manual labour it is smaller. Average

movement of the middle joint is usually estimated at 110 degrees and of the distal joint at 80 degrees. In this patient, after primary tendon transplantation and removal of the tendon of the superficial flexor, movement of the middle joint was 13 degrees short of normal and in the distal joint 18 degrees short of normal.

Fig. 8. Injury by glass to third and fourth fingers of right hand. Patient J. Č.

Patient No. 2: Movement in the middle joint was 180—85 degrees (difference 95 degrees, 15 degrees short of normal) and in the distal joint 180—105 degrees (difference 75 degrees, five degrees short of normal).

Patient No. 3: Movement in the middle joint was 150—90 degrees (difference 60 degrees) and in the distal joint 150—115 degrees (difference 35 degrees).

Patient No. 4: Movement in the middle joint was 150—100 degrees and in the distal joint 180—135 degrees.

The difference between the functional results in the first two patients and in the other two is due to the fact that in the first two the injury was not complicated by injury to other structures. In the third patient a digital nerve was also injured and the dorsal wall of the tendon sheath and the periosteum was damaged. In the fourth patient some bruising was caused in the wound by a rough piece of glass measuring 1×0.5×0.2 cm., which was found in the finger.

Another possible cause of the greater adhesions in the last two patients may be that they were given penicillin only, while the first two received penicillin and streptomycin.

Another important factor in favour of the first two patients were their own efforts to recover the function of the finger. They cooperated well and actively in rehabilitation and occupation therapy. The other two patients were young

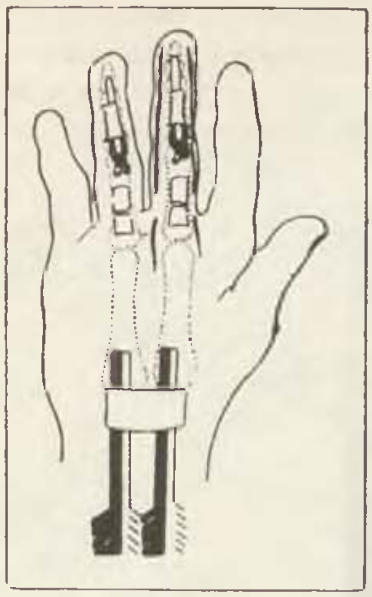

Fig. 9.

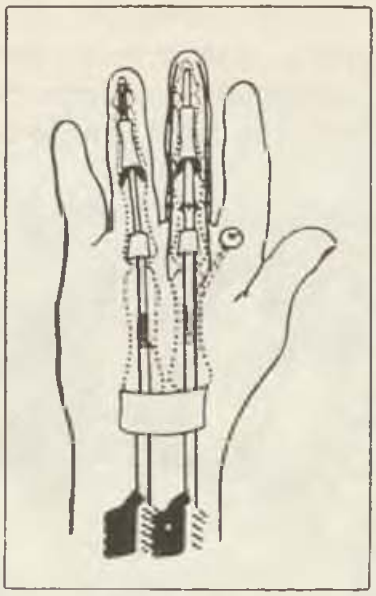

Fig. 10.

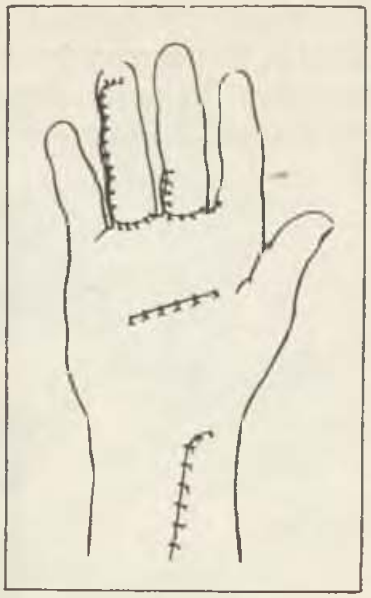

Fig. 11.

Fig. 9. Diagram of severed tendons of third and fourth finger and severed nerve in third finger. Patient J. Č. — Fig. 10. Diagram of suture of primary tendon graft in fourth finger and suture of tendon of flexor profundus and nerves of third finger. Patient J. Č. — Fig. 11. Skin incisions exposing operation field. Patient J. Č.

girls, who did not attend rehabilitation therapy regularly and did not make every effort to regain the use of their fingers.

Cases 1 and 2:

The first was a male patient aged 41, a private furrier by occupation. On February 15, 1956, he cut the fourth and fifth finger of the right hand in the region of the proximal phalanx with a knife (Fig. 1).

Both flexor tendons were severed on both fingers and on the fifth finger the digital nerve was severed on the ulnar side (Fig. 2).

For seven years before the injury the patient had had an ankylosed metacarpophalangeal joint on the third finger following suppurative arthritis.

Three hours after injury he was given penicillin. The operation was performed 6 ¼ hours after injury under general anaesthesia. Since the tendon injury on the fifth finger was complicated by injury to the nerve, primary tendon transplantation was carried out in the fourth finger, despite the adjoining ankylosed metacarpophalangeal joint. The resected tendon of the flexor sublimis of the fifth finger was used as the graft. On the fifth finger primary suture of the tendon of the flexor profundus was carried out by a tension suture on the proximal stump and by apposition sutures at the site of junction (Bunnell). The severed nerve was sutured at the same time (Fig. 3).

The direction of the skin incision is shown in Fig. 4. The position of the fingers after reconstruction of the tendons is shown in Fig. 5.

Movement was recovered more rapidly in the fifth finger, movement of the fourth finger being restricted by the adjoining ankylosed metacarpophalangeal joint. Six weeks after injury the patient returned to work of his own accord

(cutting furs with heavy scissors), at the same time continuing rehabilitation therapy.

Three months after injury, the fifth finger, in which primary suture had been carried out, could be bent to touch the palm. Active flexion of the fourth finger, in which primary tendon grafting had been carried out, was still 2 cm. short of the palm.

Fig. 12.

Fig. 13.

Fig. 12. Degree of flexion 10 months after primary transplantation in fourth finger and seven months after secondary graft in third finger. Patient J. Č. — Fig. 13. Degree of extension 10 months after primary tendon graft in fourth finger and seven months after secondary graft in third finger. Patient J. Č.

Eight months after injury, both fingers touched the palm on active flexion. The range of movement in the fourth finger was 180—83 degrees in the middle joint and 170—120 degrees in the distal joint. In the fifth finger it was 180—95 degrees in the middle joint and 180—105 degrees in the distal joint.

Fourteen months after injury the patient himself stated that the strength of his fingers was normal. Flexion had improved, but extension had deteriorated — in the patient's opinion because he had been working intensively for several months with the fingers continuously flexed.

The range of movement in the interphalangeal joints was as follows: in the middle joint of the fourth finger it was 180—83 degrees, in the distal joint 166—104 degrees. In the fifth finger it was 170—80 degrees in the middle joint and 170—90 degrees in the distal joint. The patient did not attend for further follow-up examination.

The second patient was a 19-year-old chemist. On May 29, 1956, he cut himself on glass while at work, injuring the third and fourth finger of the right hand in the region of the proximal crease (Fig. 8).

Both tendons were severed on both fingers and on the third finger both neurovascular bundles were severed (Fig. 9).

Three hours after injury the patient was given penicillin and the operation was performed. In the fourth finger a primary free tendon graft was made, using the palmaris longus, as the tendons of the sublimis were too thick. In the third finger primary suture of the flexor profundus was carried out, together with resection of the tendon of the flexor sublimis and suture of both nerves (Fig. 10 and 11).

Movement was recovered in the fourth finger, but the third finger remained in semiflexion and there was no movement in the interphalangeal joints.

When the third finger failed to improve after three months, surgical inspection was carried out. This showed rupture at the site of suture, due to the fibre of the tension suture having snapped. The problem was resolved by a secondary free tendon graft from the tendon of the long extensor of the second toe on the right foot.

Two months after the second operation the patient returned to his original occupation.

Six and a half months after the injury the patient could touch the palm with both fingers on active flexion. The range of movement in the fourth finger after primary tendon graft was 180—90 degrees in the middle joint and 180—115 degrees in the distal joint. In the third finger, 2 ½ months after secondary grafting, the range of movement in the middle joint was 150—75 degrees and in the distal joint 180—125 degrees.

Eleven months after injury the patient stated that movement of the fingers had improved and that their strength was almost normal. The range of movement in the middle joint of the fourth finger was 180—85 degrees and in the distal joint 180—105 degrees. In the third finger it was 160—80 degrees in the middle joint and 185—110 degrees in the distal joint (Fig. 12 and 13).

SUMMARY

The use of primary free tendon grafts in sharp, clean injuries to the tendons of the flexors of the fingers in the area of the fibrous sheath, using an atraumatic technique and antibiotics, followed by rehabilitation therapy with the active participation of the patient, gave very good functional results in two of four patients in whom it was tested. In two patients who did not cooperate actively in rehabilitation therapy and in whom injury to the tendons was complicated by nerve injuries or contusions, the functional results were satisfactory.

The period for which the patients were unfit for work was one to two months less than with secondary transplantation.

The method of primary tendon transplantation cannot be evaluated from four cases only and further trials will therefore be carried out.

ВЫВОДЫ

Свободная пересадка сухожилия во время первичной обработки травмированных сухожилий сгибателей кисти руки в области фиброзной сумки

А. Тёрёкова

У четырех больных была произведена первичная свободная пересадка сухожилий при чистых ранениях сухожилий острым предметом, связанных с угрозой нарушения функции пальцев; лечение производилось при соблюдении нетравмирующей техники, при помощи антибиотиков, восстановительной терапии и при активном участии больного; у двух больных из четырех были получены весьма хорошие результаты. У двух дальнейших больных, не содействовавших активно восстановительной терапии, у которых ранение сухожилий осложнялось травмированием или повреждением нерва, были получены удовлетворительные функциональные результаты.

Срок неспособности к труду был, по сравнению с вторичной пересадкой, сокращен на 1—2 месяца.

Произвести оценку метода первичной пересадки сухожилия на основании данных, полученных у четырех больных, не представляется возможным, поэтому исследование в этом отношении будет необходимо продолжать дальше.

RÉSUMÉ

Le Rôle de la Greffe Tendineuse Libre au Cours du Traitement Précoce des Fléchisseurs de la Main à la Blessure aux Environs de la Capsule fibreuse

A. Tőrőková

Les résultats favorables de la greffe tendineuse libre en face des blessures tranchées, à l'infection exclue, des fléchisseurs de la région en menace des doigts viennent d'être discutés par l'auteur. Ils ont été obtenus à l'aide de la technique atraumatique, des antibiotiques, de la réhabilitation et de la coopération active chez deux cas sur quatre des malades. Les deux malades à l'échec de la réhabilitation active, chez lesquelles la blessure du tendon été accompagnée de la blessure du nerf ou de la contusion, montraient de résultats satisfaisants quand à la fonction.

La durée de l'inaptibilité devint de l'un à deux mois plus courte vis-à-vis de celle de la transplantation tardive.

Faute d'impossibilité du jugement de cette méthode à transplantation tendineuse libre précoce rien que de quatre cas démonstrés, l'auteur continue a suivre son exploration.

ZUSAMMENFASSUNG

Freie Sehnentransplantation bei primärer Behandlung von verletzten Sehnen der Handflexoren im Gebiete der fibrosen Kapsel

A. Tőrőková

Bei primärer freien Sehnentransplantation bei scharfen nicht verunreinigten Verletzungen der Sehnenflexoren im gefährdeten Fingergebiet waren die Funktionergebnisse unter Beibehaltung einer atraumatischen Technik mit Beihilfe von Antibiotika, Rehabilitationsbehandlung und aktiven Anteilnahme des Patienten — bei 2 Patienten von 4 Fällen — sehr gut. Bei 2 Patientinen, die sich um eine Rehabilitation aktiv nicht bemühten und bei denen die verletzten Sehnen durch Nervenverletzungen oder Quetschungen kompliziert waren, waren die Funktionsergebnisse zufriedenstellend.

Im Vergleich zur sekundären Transplantation war die Dauer der Arbeitsunfähigkeit um 1—2 Monate verkürzt.

Eine Auswertung der Methode der primären Sehnentransplantation auf Grund von 4 Fällen ist unmöglich, wir setzen daher unsere Forschung fort.

(Dr. A. Töröková): Partyzánská 1, Bratislava, Czechoslovakia

Orthopädische Universitätsklinik, Rostock (DDR)
Direktor: Prof. Dr. Harro Seyfarth

DIE BEUGESEHNENTRANSPLANTATION AN DER HAND

H. SEYFARTH

Von den verschiedensten Seiten ist in den letzten Jahren immer wieder darauf hingewiesen worden, dass die „Chirurgie der Hand" sich im Rahmen der Wiederherstellungschirurgie einen ganz besonderen Platz gesichert hat. Man hat heute erkannt, dass die Versorgung von frischen Handverletzungen keineswegs ohne Bedenken dem praktischen Arzt überlassen bleiben sollte, sondern dass jede mittlere oder grössere Handverletzung nur von einem in der Handchirurgie erfahrenen Chirurgen versorgt werden muss; hängt doch das funktionelle Spätergebnis einer jeden Verletzung weitestgehend von der exakten Ausführung der Erstversorgung ab. Auch ein noch so ausgeklügelter und mit aller technischer Raffinesse ausgeübter Sekundäreingriff zur Wiederherstellung der verlorengegangenen Funktion kann dann nur mittelmässige Ergebnisse aufweisen, wenn nach einer mangelhaft durchgeführten Erstversorgung ungünstige Narbenverhältnisse zurückgeblieben sind.

Es ist dieserhalb wichtig, dass jeder Arzt, der eine frische Handverletzung zugewiesen bekommt, in der Lage ist, eine exakte Diagnose über Umfang, Ausdehnung, Lokalisation und Schwere der Verletzung zu stellen. Leider täuscht das Ausmass der äußerlich sichtbaren Hautverletzung über die Schwere der Verletzung in der Tiefe oft hinweg, so dass die einfache Inspektion völlig unzureichend ist. Frakturen und Luxationen sind meist leicht, besonders auch mit Hilfe der Röntgenstrahlen, zu diagnostizieren; anders verhält es sich dagegen mit den Verletzungen der Nerven oder der Sehnen. Hier ist vor allen Dingen eine subtile Funktionsdiagnostik durchzuführen, die es erst ermöglicht, je nach Art des Befundes unterschiedliche therapeutische Konsequenzen zu ziehen. Auf Einzelheiten der Diagnostik der Sehnenverletzungen kann im Rahmen dieser Ausführungen nicht eingegangen werden. Wir verweisen auf die einschlägigen Arbeiten von Bunnell, Moberg, Dick u. a.

Für die chirurgische Versorgung von Handverletzungen konnten in letzter Zeit bestimmte Grundsätze erarbeitet werden. So hat sich unter anderem herausgestellt, dass bisweilen eine primäre Naht einer durchtrennten Beugesehne sehr unzweckmässig sein kann, weil unter gewissen Voraussetzungen dabei die funktionellen Spätergebnisse sehr schlecht sein könen. Dies trifft besonders für alle Sehnenverletzungen im Bereich des sog. „Niemandslandes" zu, in dem die Beugesehnen in engen Sehnenkanälen bzw. Sehnenscheidenkanälen verlaufen. Das

B. Boytchev

UNE NOUVELLE TECHNIQUE OPERATOIRE DANS LE TRAITEMENT DE LA MAIN BOTTE EN VARUS ET VALGUS

Fig. 1.

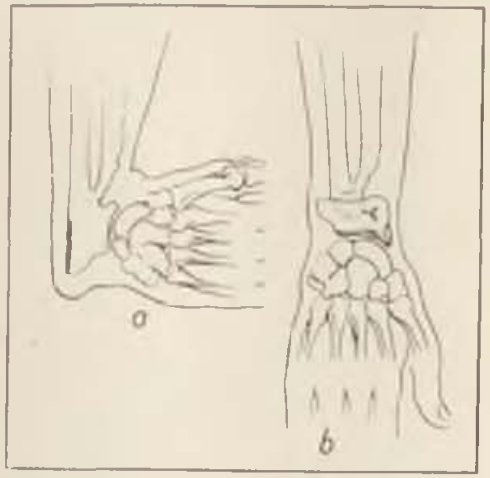

Fig. 2.

Fig. 3.

V. Karfík

CARTILAGE AS A SUBSTITUTE FOR CONGENITAL DEFECT OF THE FINGER SKELETON

Fig. 6.

Niemandsland erstreckt sich von der distalen queren Hohlhandfalte bis etwa in die Mitte der Fingermittelglieder an der Beugeseite.

Die Begründung dafür liegt in der Tatsache, dass in einem Sehnenkanal die Heilungsbedingungen für eine Sehne immer sehr ungünstig sind, weil die Heilung einer Sehne nämlich nicht vom spezifischen Sehnengewebe selbst seinen Ausgang nimmt, sondern weil die Sehnenheilung in der Hauptsache durch proliferative Vorgänge vom paratendinösen Bindegewebe her erfolgt. (In einem geringen Grade geht allerdings auch zusätzlich eine gewisse Proliferation von dem zwischen den einzelnen Sehnenbündeln liegenden mesenchymalen Bindegewebe aus; dieser Vorgang tritt aber an Bedeutung zurück). Da nun in den Sehnenkanälen praktisch keinerlei paratendinöses Bindegewebe vorhanden ist, heilen die Sehnenverletzungen in diesem Bereich grundsätzlich sehr schlecht.

Es kommen aber zwei weitere Gründe für die mangelhafte Heilungstendenz der Sehnen im Niemandsland in Betracht. Es treten nämlich nach jeder Traumatisierung (und dazu gehören auch die Manipulationen bei einer Sehnennaht) an den Sehnen gesetzmässig gewisse Veränderungen auf, die kurz besprochen werden müssen. Zunächst ist hier die posttraumatische Schwellung zu nennen. Diese Schwellung beansprucht immer einen gewissen Raum. Ein starrer, fibröser Sehnenkanal ist aber nicht nachgiebig, so dass durch die starke Schwellung der Sehne an derselben erhebliche Druckwirkungen auftreten, die zu ischämischen Ernährungsstörungen mit einer nachfolgenden Nekrose führen. Das Endergebnis ist dann eine starre, mit der Umgebung verbackene Narbe, die die Funktion der Sehne praktisch vollständig aufhebt und dazu meist noch zu einer Beugekontraktur des bzw. der Finger führt.

Des weiteren tritt bei jeder Sehnenverletzung (auch bei völlig aseptischer Heilung) eine posttraumatische Entzündung auf, die eine Verklebung der Sehnenoberfläche mit dem Gleitlager ihrer Umgebung nach sich zieht. Solche Verluste des Gleitvermögens einer Sehne haben ausserhalb des Bereiches eines Sehnenkanals nur eine geringe Bedeutung, weil das locker um die Sehne angeordnete peritendinöse Gleitbindegewebe an den Verschiebungen der Sehne teilnehmen kann. Anders verhält es sich aber bei den Sehnenkanälen. Diese sind ja praktisch am Knochen fixiert, weshalb sie die Bewegungen der in ihnen liegenden Sehnen nicht mitmachen können. Treten also in einem Sehnenkanal solche posttraumatischen Verklebungen auf, dann bedeutet dies immer eine erhebliche Funktionseinbusse für die betreffende Sehne.

Die Wiederherstellung der Funktion nach einer Beugesehnendurchtrennung im Niemandsland erfolgt also niemals durch eine primäre oder sekundäre Sehnennaht, sondern hier muss eine Sehnentransplantation durchgeführt werden, so dass innerhalb des Sehnenkanals nur gesundes Sehnengewebe zu liegen kommt. Diese freie Sehnenverpflanzung erfolgt grundsätzlich sekundär, weil dazu absolut sicher eine Primärheilung erforderlich ist, was bei einer Primärversorgung nicht immer gewährleistet ist.

Der günstigste Zeitpunkt für eine Sehnentransplantation liegt 4—6 Wochen nach Abschluss der Wundheilung. Danach sind sicher alle Entzündungen und Schwellungen von der primären Verletzung abgeklungen.

Eine weitere unabdingbare Voraussetzung ist die intakte Sensibilität des Fingers. Nötigenfalls soll erst noch vorher eine Fingernervennaht durchgeführt werden, und danach müssen die trophischen und Sensibilitätsfunktionen des Fingers wiederhergestellt sein. Bei Nervenverletzungen im Grundgliedbereich ist dies oft etwa 8 Wochen nach der Nervennaht der Fall. Mit Recht hat Moberg

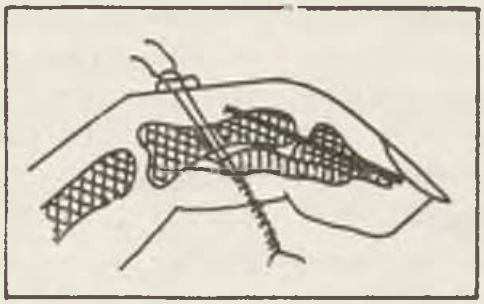

Abb. 1. Kombinierte Endgelenksarthrodese und -Tenodese (nach Moberg).

immer wieder darauf hingewiesen, dass ein zwar beweglicher aber gefühlloser Finger praktisch nicht benutzt werden kann. Die „taktile Gnosis" muss vor der Sehnentransplantation in Ordnung sein.

Eine weitere Bedingung, die vor der Ausführung einer Sehnentransplantation erfüllt sein muss, ist die freie (passive) Beweglichkeit und die Stabilität der Gelenke des betreffenden Fingers. Auch diese müssen nötigenfalls vor dem geplanten Sehneneingriff wiederhergestellt sein. Eine Sehnenverpflanzung an einem unstabilen oder an einem kontrakten Finger ist völlig zwecklos.

Erst wenn all diese Voraussetzungen erfüllt sind, kann man an die Transplantation einer Beugesehne an der Hand herangehen.

Die Indikation zu einer Beugesehnentransplantation ergibt sich aus den anatomischen und funktionellen Besonderheiten der Fingerbeugesehnen. Der tiefe Beuger beugt in erster Linie das Endgelenk, wirkt aber unterstützend auf die Beugung im Fingermittelgelenk mit ein, das vorwiegend vom oberflächlichen Beuger gebeugt wird. Die Beugung im Grundgelenk besorgen die Interossei und die Lumbricales. Daraus ergibt sich, dass ein alleiniger Ausfall eines oberflächlichen Beugers eine Sehnentransplantation nicht erforderlich macht. Fällt nur die tiefe Beugesehne aus, dann ist es zweckmässig, ebenfalls von einer Beugesehnentransplantation abzusehen und besser eine Tenodese bzw. eine Arthrodese im Endgelenk in einer Winkelstellung von 150 Grad durchzuführen (Abb. 1). Diese ermöglicht auf eine einfache Weise einen vollwertigen Flexionsgriff bei einem nur geringen, funktionell bedeutungslosen Streckdefekt. Nur bei einem Ausfall beider Beugesehnen (Sublimis und Profundus) ist eine Beugesehnentransplantation indiziert. Dabei wird grundsätzlich nur die tiefe Beugesehne ersetzt, während die oberflächliche weitestgehend entfernt wird.

Das prinzipielle Vorgehen bei einer Beugesehnentransplantation an den dreigliedrigen Fingern ist folgendes: Zunächst wird der zentrale tiefe Beugesehnenstumpf bis in die Hohlhand gekürzt. Der zentrale oberflächliche Beugesehnen stumpf wird ebenfalls bis in die Hohlhand gekürzt und dort eventuell zur Kraft-

vermehrung in den zentralen Stumpf der tiefen Beugesehne eingepflanzt, oder aber freigelassen. Die beiden peripheren Sehnenstümpfe (Sublimis und Profundussehne) werden vollständig excidiert. Dann wird das Transplantat einmal mit dem zentralen Stumpf der tiefen Beugesehne verbunden und durch die Hohlhand und den Fingersehnenkanal bis zum Endglied eingezogen und am Endglied befestigt. Auch am Daumen wird der Ersatz der tiefen Beugesehne auf diese Weise durchgeführt, allerdings wird hierbei der zentrale Stumpf meist bis oberhalb des Handgelenkes gekürzt, und von da aus wird dann das Transplantat bis zum Endglied des Daumens durchgezogen.

Die technische Ausführung einer Sehnentransplantation setzt die Beherrschung zahlreicher Technizismen der modernen Handchirurgie voraus, auf die hier nur kurz eingegangen werden kann, zumal sie im wesentlichen als bekannt vorausgesetzt werden müssen.

Jeder wiederherstellende Eingriff an der funktionsgestörten Hand erfordert „Ruhe und Zeit". Man darf nicht unter Zeitdruck stehen, und nur mit Geduld lässt sich der operative Eingriff erfolgreich beenden. Es muss mit schonendster Technik „atraumatisch" operiert werden. Jede brüske Bearbeitung der Gewebe muss auf alle Fälle vermieden werden. Moberg betont, dass Hakenpinzetten, Gefässklemmen und trockene Tupfer kleine Schädigungen und Traumatisierungen hinterlassen, welche eine Schwellung und sogar Nekrosen mit nachfolgender Narbenbildung und Verwachsungen verursachen. Daher muss jede operative Tätigkeit an der Hand mit möglichst hakenfreien Instrumenten und mit leichter behutsamer Hand ohne Reissen und Zerren ausgeführt werden. Jede Sehnennaht verlangt ein besonders schonendes Vorgehen, denn eine der Hauptgefahren ist hierbei die Verletzung der sehr empfindlichen Gleitflächen. Jede grobe Berührung oder Austrocknung des Sehnengewebes zieht einen Gleitverlust der Sehnenoberfläche oder ihres peritendinösen Gleitlagers nach sich. Das Berühren oder Fassen der Sehnen mit Pinzetten oder Klemmen ist nur am Sehnenende gestattet, das dann abgeschnitten werden muss.

Die Anwendung von Ligaturen soll möglichst beschränkt werden. Schlecht sind immer Catgutligaturen, weil diese lokale Reizerscheinungen hervorrufen, die sich in den empfindlichen Geweben der Hand sehr nachteilig auswirken können.

Die Instrumente müssen fein sein. Keinesfalls sind aber zahlreiche Spezialinstrumente notwending. Man kommt durchaus mit wenigen Instrumenten aus. Bewährt haben sich u. a. gerade Nähnadeln, von grossem Vorteil sind atraumatische Nadeln.

Es versteht sich von selbst, dass eine peinliche Asepsis und gute Lichtverhältnisse unerlässlich sind.

Die Eingriffe an der Hand werden grundsätzlich in Blutleere ausgeführt, und zwar erfolgt die Blutsperre nach Auswickelung des betreffenden Armes mit einer pneumatischen Manschette am Oberarm. Jede andere Abschnürung birgt die Gefahr einer Nervenläsion in sich. Die Abdeckung darf keinesfalls abschnüren. Von Zeit zu Zeit muss die Wunde mit körperwarmer, steriler, physiologischer Koch-

salzlösung ausgespritzt werden, um ein Austrocknen der Gewebe zu verhindern. Getupft wird möglichst überhaupt nicht (es blutet ja wegen der Blutleere auch nicht!). Wenn doch getupft werden muss, dann grundsätzlich nur mit Kochsalzlösung angefeuchteten Tupfern.

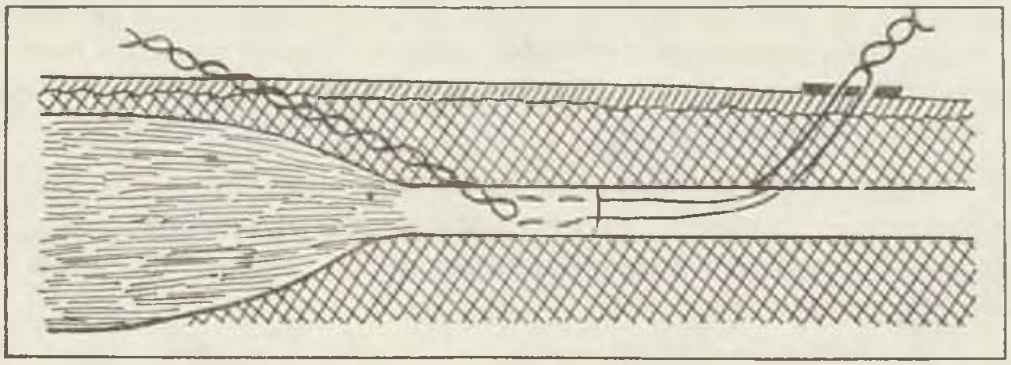

Abb. 2. Prinzip der Sehnennaht mit Ausziehdraht (Pull-out-wire) nach Bunnell.

Die Schnittführung hat einen wesentlichen Einfluss auf das funktionelle Spätergebnis. Ausgesprochen schlecht ist der mediane Längsschnitt an der Beugeseite eines Fingers oder der Längsschnitt in der Hohlhand. Einmal liegt dann bei einer Beugesehnenoperation die Hautnarbe direkt über der Sehne, so dass Verwachsungen zwischen Haut und Beugesehne auftreten können, zumal diese Schnittführung die wichtigen, unter einer ständigen Druckbelastung stehenden volaren Gleitflächen an den bedeutungsvollsten Punkten zerstört. Außerdem entstehen nach derartigen Schnitten oft erhabene, längsverlaufende Narbenstränge, die sich allmählich zunehmend kontrahieren, bis schließlich Beugekontrakturen der betreffenden Finger eintreten.

Der Schnitt erfolgt an den Fingern grundsätzlich streng lateral, in der Hohlhand werden die Schnitte nach Möglichkeit entsprechend den natürlichen Faltenlinien angebracht. Am Zeigefinger wird der Schnitt an der Radialseite, am Kleinfinger an der Ulnarseite gelegt. Am Mittelfinger und am Ringfinger bleibt es gleich, ob der Schnitt radial oder ulnar durchgeführt wird.

Bei der Ausübung einer Sehnentransplantation muß der Operateur die Technik der Sehnennaht vollkommen beherrschen, und zwar sowohl das Grundprinzip der End-zu-End-Naht als auch ihre verschiedenen Variationen. Eine entscheidende Verbesserung der Sehnennaht war die Einführung der „ausziehbaren" Sehnennaht durch Bunnell.

Für die Sehnennaht wird heute grundsätzlich feinster Stahldraht verwendet, der in verschiedenen Stärken entweder einfach oder gezwirnt geliefert wird. Uns hat sich der auch von Zahnärzten verwendete Remanit-Stahldraht bewährt, der auf Rollen in den Stärken 0,1—0,5 mm geliefert wird. Am gebräuchlichsten sind die Stärken 0,1 und 0,2 mm, eventuell gezwirnt als 0,1 × 2 oder 0,1 × 3. Nach Hainzl hat der Remanitstahldraht 0,1 × 2 eine Zugfestigkeit von 1600 g.

Der Zug an einer einfachen Sehnennaht erfolgt immer nur an demjenigen Sehnenstumpf, der vom Muskel her kommt (sogenannter aktiver Stumpf), wäh-

rend der andere Stumpf der Sehne passiv bleibt. Deshalb wird die Sehnendrahtnaht nur in den proximalen Stumpf eingeflochten, dann über die Durchtrennungsstelle durch den distalen Stumpf, schließlich bis durch die Haut herausgeführt, wo sie über einem Knopf oder einer Glaskugel fest verankert wird. Somit wird

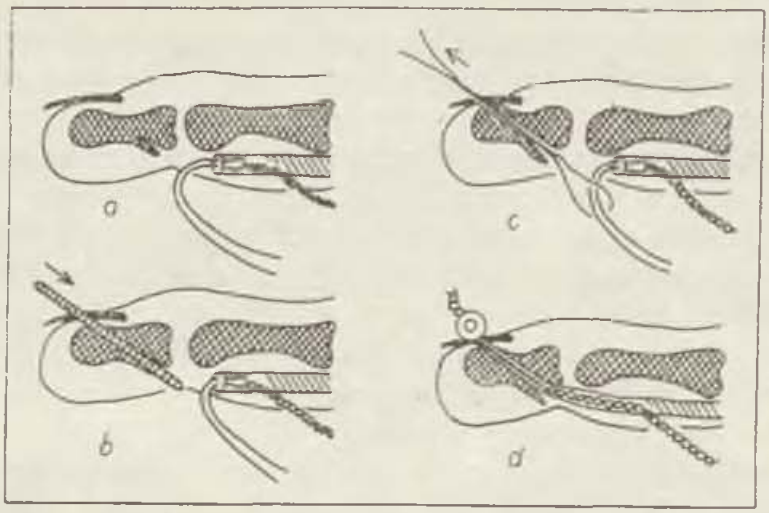

Abb. 3. Prinzip der Befestigung des Sehnentransplantates am Endgliedknochen des Fingers.

also das proximale (aktive) Sehnenende an das distale (passive) Ende herangezogen und fixiert. Die Entfernung des Drahtes nach Abschluß der Wundheilung erfolgt durch einen sog. „Ausziehdraht" (Pull-out-wire), der durch die proximale Schlinge der Sehnendrahtnaht im aktiven Sehnenstumpf gelegt wird. Die beiden Schenkel des Ausziehdrahtes werden umeinander verwendelt und dann mit einer Nadel durch die Haut proximal der Sehnennaht herausgeführt. (Abb. 2.) Wenn dann nach 3 Wochen die Sehnennaht fest verheilt ist, werden die distalen Nahtenden an ihrer Durchtrittsstelle durch die Haut mit Sepsotinktur bestrichen und anschließend abgeschnitten. Durch einen Zug am (proximal gelegenen) Ausziehdraht kann dann die ganze Sehnennaht nach proximal herausgezogen werden. Da der Ausziehdraht in sich verdreht (verwendelt) worden ist, ist es unmöglich, daß in seine beiden Schenkel Gewebe einwächst, was die Entfernung behindern würde.

Auch die Befestigung eines Sehnenendes am Endgliedknochen eines Fingers erfolgt mit Hilfe dieser Ausziehdrahtmethode. Diese Technik soll weiter unten noch besprochen werden.

Die Operation wird entweder in Plexusanaesthesie oder (besser) in Vollnarkose durchgeführt. Genau seitlich am Finger erfolgt von der Fingerkuppe bis an die Interdigitalfalte heran eine Längsincision. Dorsal des volaren Gefäßnervenbündels arbeitet man sich dann bis an die Sehnenscheide heran bei Schonung der Nerven und Gefässe. Unter teilweiser (keineswegs vollständiger) Eröffnung der Sehnenscheide werden die Sehnenstümpfe freigelegt. Die Ringbänder (Ligg. annularia) bleiben auf alle Fälle erhalten. Dann werden der periphere Stumpf der tiefen Beugesehne am Endglied und der periphere Stumpf des oberflächlichen Beugers knapp proximal des Mittelgelenkes abgetrennt.

Von einem weiteren Schnitt im Handteller aus, werden die beiden proximalen zurückgeschlüpften Sehnenstümpfe aufgesucht und aus ihren Verwachsungen ausgelöst. Das gesamte Narbengewebe wird sorgfältig excidiert. Danach werden die Sehnen bis zum Lumbricalisursprung dargestellt. Nun empfiehlt es sich, provisorisch einen langen Sehnenfaden mit Hilfe der Öhrsonde in das zukünftige Transplantatlager von der Hohlhand bis an das Endglied des Fingers einzuziehen.

Sodann wird das Transplantat entnommen. Wir verwenden dazu grundsätzlich die Sehne des langen Zehenstreckers der 3. oder 4. Zehe. (Die Strecksehnen der 1. oder 5. Zehe sollen nicht genommen werden.) Man kann auch die Sehne des M. palmaris longus nehmen, aber in ca. $^1/_5$ der Fälle fehlt diese. Zur Entnahme der Sehne werden über dem Sehnenverlauf in Abständen von 3 cm mehrere kleine quere Hauteinschnitte vorgenommen. Zunächst wird das periphere Ende der Sehne abgelöst, dann wird sie schrittweise nach proximal hin isoliert und schließlich proximal durchtrennt, wonach sie mühelos herausgenommen werden kann. Die Oberfläche der Sehne muß sorgfältigst geschont werden, sie darf nicht rauh, sondern sie muß glatt und spiegelnd sein.

Unterschiedlich wird nun die Befestigung des Transplantates gehandhabt. Man kann zunächst das Transplantat am proximalen Stumpf des Profundus annähen und dann erst die Verankerung am Endgliedknochen vornehmen; aber auch der umgekehrte Modus ist möglich. Wir bevorzugen den ersteren Weg. Die Verbindung des Transplantates mit dem Profundus-Stumpf in der Hohlhand erfolgt in der oben beschriebenen Weise nach Bunnell. Allerdings kann man auch diese Verbindungsnaht mit einer einfachen versenkten Sehnennaht durchführen. Dabei wird der zentrale Profundussehnenstumpf etwas längst eingekerbt, und das Transplantat wird zwischen die beiden Schenkel des Sehnenstumpfes zur Naht eingelagert. Abschließend wird die Sehnennaht noch mit dem zugehörigen Lumbricalismuskel gedeckt.

Für die Befestigung des Transplantates am Endglied sind nun gewisse Vorbereitungen (Abb. 3) notwendig. Mit einem kleinen geraden Meißel wird eine distal gestielte dünne Knochenlamelle an der Volarseite des Endgliedknochens knapp peripher der Endgelenkskapsel abgelöst. Unter dieser Lamelle wird somit ein Bett für die ossäre Verankerung des Transplantates geschaffen. Danach wird in die Mitte des Fingernagels dicht peripher der Lunula mit dem Messer ein kleines Loch geschnitten. Von diesem Loch aus wird mit einem geraden Zahnarztbohrer bis zu der volaren Kerbe ein Schrägkanal nach proximal durch den Endgliedknochen gebohrt. Von der Fingernagelseite her wird durch diesen Kanal zunächst eine dünne Drahtschlinge gezogen bis diese an der Volarseite des Endgliedes erscheint. Am peripheren Ende des Sehnentransplantates wird nunmehr eine typische Sehnennaht (mit nach proximal liegendem Ausziehdraht) angebracht. Die beiden freien (peripheren) Enden dieser Sehnenaht werden dann mit Hilfe der durch den Schrägkanal liegenden Drahtschlinge durch den Knochen gezogen, bis sie aus dem Loch im Fingernagel herausragen. Sodann wird die Sehnennaht entweder über einem Drahtring oder über den freien Nagelrand fest geknüpft. — Der rückwärtig liegende Ausziehdraht wird seitlich am Mittelglied nach außen geführt und dort provisorisch mit Hilfe einer Glasperle an der Haut fixiert.

Einige Erfahrung erfordert immer die Bestimmung der Transplantatlänge. Sie ist keineswegs einfach. Als allgemeine Grundregel kann gelten, daß bei dem narkotisierten Patienten sich bei einer leichten Dorsalflexion im Handgelenk der betreffende Finger in einer leichten Beugestellung befinden soll. Dabei sind der 4. und 5. Finger mehr gebeugt als der 2. und 3. Finger.

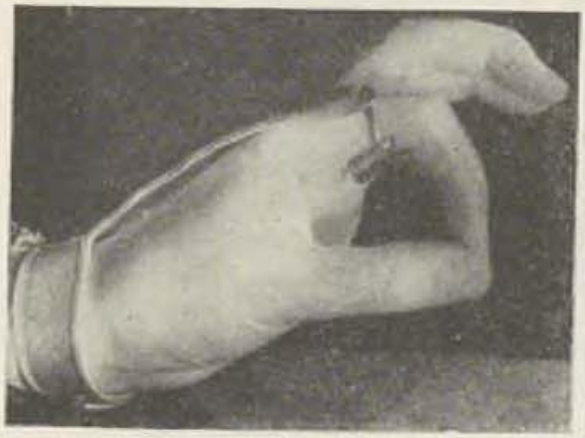

Abb. 4a.

Abb. 4b.

Abb. 4a, b. Fingerfederschiene.

Nach Beendigung der Sehnentransplantation erfolgt die Abnahme der Blutleere. Dazu wird zunächst die Hand hochgehalten. Die Wunde wird mit feuchten Tupfern komprimiert. Dann erst wird die pneumatische Manschette entfernt. Während der Phase der ersten reaktiven Hyperämie mit der vermehrten Kapillarblutung wird die Kompression der Wunden aufrecht erhalten. Erst nach einigen Minuten wird die Hand gesenkt und die Kompression von der Wunde entfernt. Dann noch spritzende Gefäße werden mit feinen Klemmen gefaßt und nötigenfalls mit feinstem Perlon unterbunden. Catgut darf dazu nicht verwendet werden.

Schließlich erfolgt der Verschluß der Wunde, wobei zur Hautnaht sich eine fortlaufende Drahtnaht sehr bewährt hat. Seide könnte infiziertes Material von der niemals ganz keimfreien Haut in den Stichkanal aufsaugen und Punktabszesse verursachen, die wiederum zum Ausgangspunkt einer Wundinfektion werden könnten.

Man muß bei der Verwendung von rostfreiem Draht sehr sorgfältig darauf achten, daß er nicht geknickt wird oder sog. Ösen wirft, weil er sonst leicht bricht. Beim Durchziehen einer Schlinge durch das Gewebe hält ein Assistent nach jedem Stich mit Hilfe einer zarten Klemme die Drahtschlinge gespannt, wodurch das Abknicken des Drahtes vermieden wird.

Sehr wichtig ist auch der Verband. Die Wunde wird steril abgedeckt, darüber kommt ein kugeliges Polster aus sterilisierter Stahlwolle, die eine genügende Kompression bei gleichzeitiger guter Luftdurchlässigkeit ermöglicht. Die Hand muss immer in „Funktionsstellung“ fixiert werden, wobei das Handgelenk leicht dorsalflektiert ist und der leicht gebeugte Zeige- und Mittelfinger mit ihren Spitzen die Kuppe des opponierten Daumens lose berühren. — Niemals darf in einer Streckstellung des Handgelenkes und der Finger fixiert werden, weil es

dabei rasch zu einer Schrumpfung der Kollateralligamente in den Metacarpophalangeal- und in den Interphalangealgelenken kommen kann. — Die Funktionsstellung der Hand wird durch das Anlegen einer dorsalen Gipslonguette von den Fingerendgliedern bis dicht an das Ellbogengelenk gesichert.

Die Hautnähte werden am. 10. Tage entfernt, man kann sie aber, zumal sie mit Draht gelegt wurden, auch länger belassen. Die ausziehbaren Sehnennähte werden nach 3—4 Wochen gezogen (spätestens dabei aber auch die Hautnähte). Danach beginnt eine systematische aktive Übungsbehandlung unter strenger täglicher Kontrolle des Arztes. Brüske passive Bewegungen haben auf alle Fälle zu unterbleiben. Von Vorteil sind auch aktive Bewegungsübungen unter (warmem) Wasser.

Uns hat sich in der Nachbehandlung ganz besonders noch (für ca 3 Monate) die Fingerfederschiene bewährt (Abb. 4 a, b). Dieses einfache Gerät, fixiert das Fingergrundgelenk federnd in einer leichten Beugestellung. So kann sich die anfänglich noch schwache Leistung des Transplantates voll auf das Mittelgelenk und auf das Endgelenk konzentrieren, zum anderen wird das Ligamentum annulare des Grundliedes in den ersten Monaten nach der Operation wirkungsvoll gestützt, so dass es sich trotz der aktiven Übungen auf das nötige Mass straffen kann. Nähere Einzelheiten über unsere Fingerfederschiene haben wir mehrfach erläutert (Seyfarth). Die Nachbehandlung erstreckt sich ungefähr auf ein Vierteljahr beim Erwachsenen, beim Kinde kann man sie meist schon eher beenden.

Wenn man diese, in aller Kürze gebrachten Gesichtspunkte bei der Ausführung einer Beugesehnentransplantation genau beachtet, dann wird auch der Erfolg nicht ausbleiben. Es muss allerdings abschliessend noch hervorgehoben werden, dass auch ein nicht unerheblicher Faktor für den Operationserfolg der Wille des Patienten zur Heilung ist. Die Operation selbst ist nur ein Teil der Behandlung, die Vor- und vor allen Dingen aber die Nachbehandlung sind mindestens ebenso wichtig. Die Operation schafft lediglich die Grundvoraussetzungen für einen guten Erfolg. Ob dieser eintritt, hängt weitgehend von der aktiven Mitarbeit des Patienten ab.

ZUSAMMENFASSUNG

Die freie Sehnentransplantation zum Ersatz der tiefen Beugesehne eines Finger ist ein dankbarer Eingriff, der allerdings eine strenge Indikation, eine entsprechende Vorbehandlung, eine subtile Operationstechnik und eine konsequente Nachbehandlung erfordert. Dem Operateur müssen die modernen Erkenntnisse der Handchirurgie geläufig sein, vor allen Dingen muss er auch Ruhe und Zeit haben, denn nur dann ist eine erfolgreiche Behandlung möglich.

ВЫВОДЫ

Пересадка сухожилий сгибателей на руке

Г. Сейфарт

Свободная пересадка сухожилия для возмещения сухожилия глубокого сгибателя пальца представляет собой весьма эффективное вмешательство, которое, однако, требует строгих показаний, соответствующего предварительного лечения, тонкой операционной

техники и последовательного восстановительного лечения. Хирург должен быть хорошо ознакомлен с современными сведениями в отношении хирургии руки, в частности он должен располагать соответствующим спокойствием и временем, так как только при таких условиях можно достигнуть благоприятного результата лечения.

SUMMARY

Transplantation of Flexor tendons in the Hand

H. Seyfarth

Free transplantation of a flexor tendon for the replacement of the profundus tendon of a finger is a gratifying operation which, however, requires a strict indication, suitable pre-operative treatment, fine surgical technique and consistent after-treatment. The surgeon must be well acquainted with up-to-date knowledge on the surgery of the hand, particularly, however, he must allow enough time to work calmly, since only in this way it is posible to attain a successful result.

RÉSUMÉ

Le greffage des tendons fléchisseurs de la main

H. Seyfarth

Le greffage libre des tendons pour remplacer le tendon fléchisseur profond des doigts présente une intervention efficace, mais demandant une indication formelle, une thérapie antérieure appropriée, une technique opératoire subtile et un traitement post-opératoire surveillé. Le chirurgien doit posséder à fond les notions modernes de la chirurgie de la main et surtout disposer de toute la tranquillité et du temps nécéssaires, conditions indispensables pour arriver à des résultats satisfaisants.

LITERATUR

1. **Bunnell, St.:** Surgery of the Hand. J. B. Lippincott Company. Third Edition, 1956.
2. **Bunnell, St., Böhler, J.:** Chir. Prax. 2, 185, 1958,
3. **Dick, W.:** Chir. Prax. 1, 79, 1957.
4. **Ender, J., Krotschek, H., Simon-Weidner, R.:** Die Chirurgie der Handverletzungen. Springer-Verlag, Wien 1956.
5. **Hainzl, H.:** Beitr. Orthop. 4, 133, 1957.
6. **Moberg, E.:** Akute Handchirurgie. C. W. K. Gleerup-Verlag, Lund 1953.
7. **Moberg, E.:** 74. Tg. Dtsch. Ges. Chir. 1957.
8. **Seyfarth, H.:** Chir. Prax. 3, 321, 1958.
9. **Seyfarth, H.:** Beitrag zur Beugesehnenplastik an der Hand. Vhdlg. Dtsch. Ges. Unfallhk. 22. Tagung, Kiel 1958.
10. **Seyfarth, H.:** Chirurg 29, 11, 527, 1958.
11. **Seyfarth, H.:** Zbl. Chir. 84, 41, 1679, 1959.

(Prof. Dr. Med. H. Seyfarth): Ulmenstrasse 44/45, Rostock,
Deutsche Demokratische Republik

Institut de specialisation et de perfectionnement des medicins, Sofia (Bulgarie)
Clinique d'orthopedie et traumatologie, Sofia
Directeur: Prof. B. Boytchev

UNE NOUVELLE TECHNIQUE OPERATOIRE DANS LE TRAITEMENT DE LA MAIN BOTTE EN VARUS ET VALGUS

B. BOYTCHEV

C'est à l'occasion d'un cas de main botte en varus et pronation, une déformation qui s'était instituée à la suite d'une fracture ouverte compliquée d'une ostéomyélite du tiers inférieur du radius et de l'ulna, qui dans le procès de stabilization se sont synostosé dans une position vicieuse et on déformé la main en position de varus et de pronation (Fig. 1) que nous avons appliqué une technique opératoire qui nous a donné de très bons résultats fonctionnels et éstéthiques.

Dans notre cas, quoique la main eut été dans une position de varus et de pronation très prononcée, elle avait une très bonne mobilité, les mouvements se faisant dans une néarthrose formée entre les os du carpe et le bout des deux os synostosés.

Nous avons décidé de préserver dans ce cas cette mobilité sans attaquer la nouvelle articulation, quoiqu'elle fut anormale, notre seul but étant de réparer la forme de la main, en conservant sa bonne mobilité et sa fonction. C'est ainsi que nous avons recouru à une technique que nous pensons peut être utilisée avec succès dans les cas d'agénésie congénitale du radius.

Notre technique est la suivante:

On fait une incision cutanée longitudinale, qui couvre le tiers distal de l'avant bras, le long du cubitus. Après avoir découvert l'os, on fait une fente longitudinale dans ce dérnier de telle facon, qu'un lambeau ostéo-périostique à charnière distale. Ce lambeau est forcé à l'extérieur de facon à ouvrir un éspace d'os rafraichi.

Puis, on fait une ostéotomie transversale de l'os dans un plan à 2—3 centimètres au dessus de l'extrémité distale de l'os et le fragment ainsi libéré est tourné à 90^0 de telle manière que le lambeau se pose le long du bord cubital du fragment proximal et la surface spongieuse découverte par le lambeau même s'appose contre la surface de l'ostéotomie du fragment proximal (Fig. 2 a b). La fixation des deux fragments est éfectuée avec un ou deux fils. La main reprend sa forme normale. Le plâtre est tenu pendant deux mois (Fig. 3 Radio).

Cette technique est facile à pratiquer, elle est atraumatique et présente une solution dans un grand nombre des cas avec position vicieuse de la main, mais l'indication doit être précisée strictement dans chaque cas individuel. La con-

tracture des tissus dans les agénésies congénitales du radius exige non seulement une ostéotomie avec rotation du fragment distal, mais aussi une abrévation économique de l'os même pour diminuer et surmonter la contracture des muscles et des tendons du côté du radius absent.

Nous nous bornons ici de présenter seulement la technique de l'opération.

RÉSUMÉ

Dans des cas de main botte en varus ou en valgus, quand la mobilité du poignet est bien préservée, la forme de la main peut être corrigée par une ostéotomie transversale du radius, le fragment proximal duquel s'appose contre la surface externe du fragment distal (en cas de varus) et contre la surface interne (en cas de valgus). De telle manière le fragment distal est roté par rapport au fragment proximal et aligne la main sur l'axe du membre.

ВЫВОДЫ

Новая операционная техника при лечении поврежденной руки в варусном и вальгозном положении

Б. Бойчев

В случае повреждения руки в вальгозном и варусном положении при сохранении хорошей подвижности в запястье коррекция формы руки может быть проведена путем поперечной остеотомии лучевой кости. Проксимальный отломок прикладывается к боковой поверхности нижнего отломка (в случае варусного положения) или к внутренней поверхности нижнего отломка (в случае вальгозного положения). Таким образом производится поворот нижнего отломка по отношению к верхнему отломку, вследствие чего рука выпрямляется по оси конечности.

SUMMARY

A new Surgical Procedure in the Treatment of Club Hand in the Varus or Valgus Position

B. Boytchev

In cases of club hand in the varus or valgus position, when the mobility of the hand is preserved, the form of the wrist may be corrected by a transverse osteotomy of the radius, the proximal fragment of which is apposed to the lateral surface of the distal fragment (in case of varus) or to its medial surface (in case of valgus). The distal fragment is thus rotated in relation to the proximal fragment and thus alines the hand along the axis of the extremity.

ZUSAMMENFASSUNG

Eine neue Operationstechnik für die Behandlung der Krummen Varus- und Valgushand

B. Boytchev

In Fällen mit einer krummen Valgus- oder Varushand, falls die Bewegung behalten ist, kann die Form des Handgelenks durch eine transversale Radiusosteotomie korrigiert werden, wobei das Proximalfragment gegenüber der Lateralfläche des Distalfragments

(in Fällen mit Varuszustand) oder gegenüber seiner Medialfläche (in Fällen mit Valguszustand) aufgestellt wird. Dadurch wird das Distalfragment in Bezug auf das Proximalfragment rotiert und aliniert die Hand der Extremitätachsenlänge nach.

REFERENCES

1. **Bogoraz, N. A.**: Surgery of Repair. 2, 2, Medgiz 1948.
2. **Iljin, G. A.**: Kosorukost i yeye lietchenye. Tashkent 1938.
3. **Ombrédanne, L., Mathieu, P.**: Traité de chirurgie orthopédique (H. L. Rocher-Main botes congenitale, p. 2471—2484). Vo. III, Paris 1937.
4. **Campbell**: Operative orthopaedics. Vol. I, II. S. Luis 1949.

(Prof. B. Boytchev): Vasil Kolarov 3, Sofia, Bulgarie

Clinic of Plastic Surgery, University Brno (Czechoslovakia)
Director: Prof. V. Karfík, MD

CARTILAGE AS A SUBSTITUTE FOR CONGENITAL DEFECT OF THE FINGER SKELETON

V. KARFÍK

The improvements and advances in skin neoplasty, and particularly the introduction of tubular pedicle flap methods, have given rise to a form of neoplasty, namely to the palliative replacement of fingers by means of skin flaps.

Experience has shown that sensation, even though it never reaches deeper stereognosis, is fairly soon restored and, thus, a finger repaired by means of a skin flap may become useful for the function of the hand. Trophic changes taking place in a pedicle graft are of a much slower and milder nature than those in a complicated transplant, such as a whole finger.

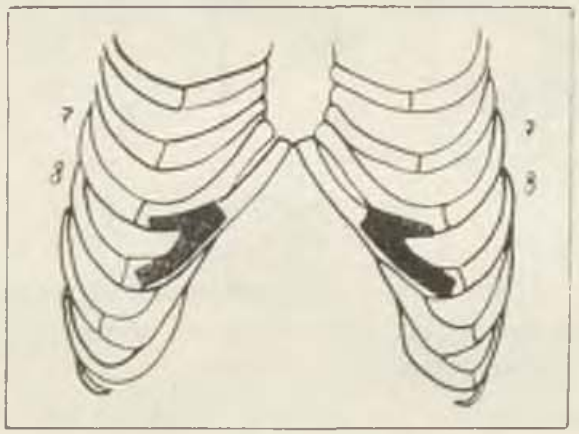

Fig. 1.

The improvement in the aesthetic appearance of these finger neoplasties, too, has been the objective of many plastic surgeons who are making great efforts in order to solve this problem, which will certainly soon be realized (Gillies, Dino, Gonzales).

In all finger neoplasties, the reconstruction and further destiny of the bony framework remains an unanswered question.

The most frequent method of replacing the bony framework of a lost finger has so far been the transfer of cancellous or compact bone secondarily inserted into a previously prepared skin flap.

In finger neoplasty, it is however, function that plays a decisive role in the final outcome of the transferred bone. It is a well-known fact that it is the portion of the bone transplant freely protruding into the soft parts which is subject to atrophy. The Soviet surgeons, Pokotilo and Kozdova, have made a series of experiments proving that the resulting form of the transplanted bone depends on function. Bone without function undergoes dissolution and atrophy.

Fig. 2.

In cases where full function cannot be restored, there is dissolution, bone resorption and stump shortening. Consequently, the stump does not correspond to an aesthetic but only to a functional finger stump.

It is function that settles the question of shape and appearance according to rules valid in plastic surgery.

Experience with progressive atrophy of the transferred bone, which cannot always be controlled, and which often destroys the good primary result, has led us to attempt to restore or reconstruct the bony framework of the finger by means of cartilage.

In using cartilage, we have proceeded from experience with its great elasticity, firmness and resistance to deformation. These properties have proved valuable in many other instances. At the same time, we have tried to solve the question of mobility of the reconstructed thumb in an extensive, almost complete defect of the thumb where replacement of the skeleton has up to the present been solved only by anchoring the bone graft in the immovable remnant of the metacarpal or even in the carpal bones.

Fig. 3.

Fig. 4.

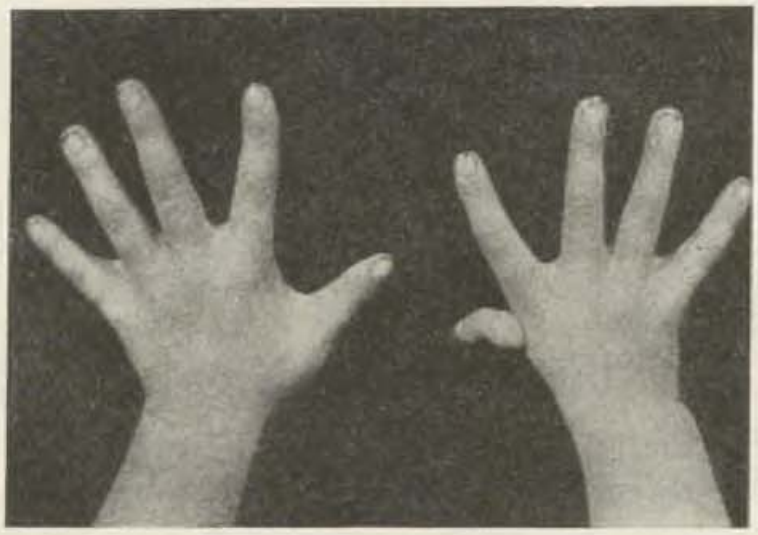

Fig. 5.

In this case we have used the method of anchoring of a V-shaped cartilage graft obtained from the junction of the 7th and 8th rib, from the right side for the right hand thumb and from the left side for the left hand thumb (Fig. 1, 2, 3, 4).

Four successful thumb neoplasties of this kind have been carried out. After these good results, we have also used cartilage for prolonging fingers after the loss of the terminal phalanges of the 3rd and 4th finger.

The above successful operations have led us to the treatment of congenital defects of the finger skeleton by means of the temporary transfer of cartilage (Fig. 5).

In congenital defects of the finger skeleton and its parts, it is age that decides the method of reconstruction. After the growth of the hand has been

Fig. 7.

completed, it is possible to repair the defect in the same way as in the case of an acquired loss, namely definitively, by bone transplantation. Congenital defects, on the other hand, must be repaired sooner, where possible in early childhood, since the finger skeleton means a very important growth impulse in late development. In congenital defects the finger gets stunted in growth and this results in a disorder in the equilibrium of the preserved muscles and in contractures of the affected fingers. These defects are usually accompanied by amniotic strictures which still further affect the trophicity of the constricted part.

The task, therefore, consists in more operations. First of all, the stricture of the finger must be repaired in order to improve the nutrition of the peripheral part and to render the connecting part large enough for the reconstruction of the finger skeleton. The bone graft for the congenital defect, if it is not to be subject to atrophy, must be joined to the epiphyseal ends or to the articular surfaces of the adjoining phalanges.

In order to prevent poor development of the finger in childhood, we have chosen rib cartilage for repairing the finger skeleton. We treated a girl patient, S., aged 6, case-sheet No. 14070, with partial hypoplasia of the right upper ex-

tremity. The child's humerus and forearm bones were shorter. Extensive hypoplasia of the thenar muscles were present together with a defect of the first metacarpal. The rudiment of the thumb was connected with the hand by a narrow pedicle containing the tendon of the long flexor hallucis. Extension was absent, the child only used her good hand (Fig. 6).

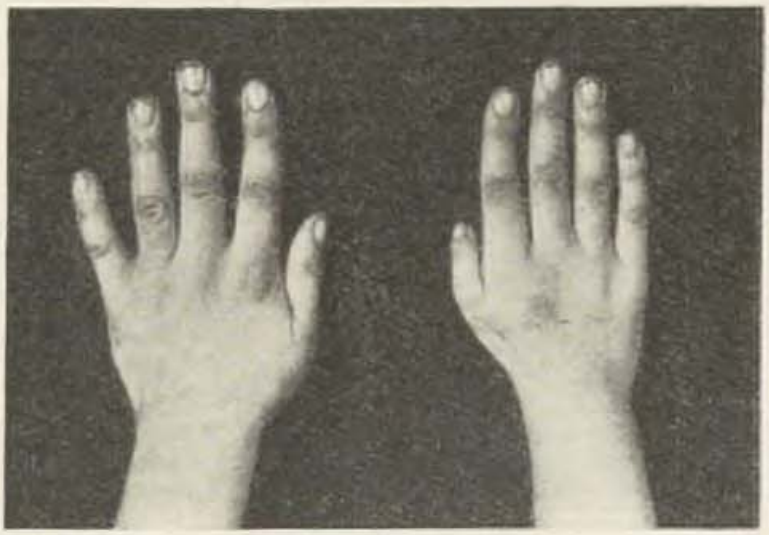

Fig. 8.

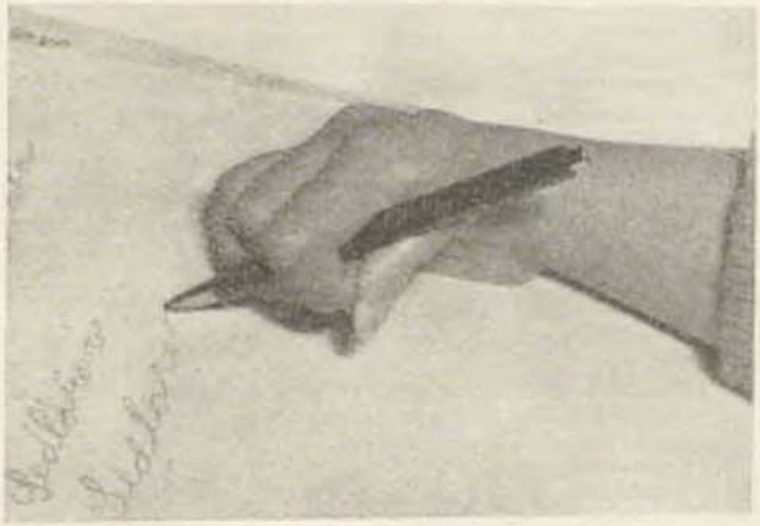

Fig. 9.

In our first operation we enlarged the narrow pedicle by means of an interchangeable skin flap from the back of the hand thus improving nutrition in the whole rudiment. In the second operation, we inserted a V-shaped cartilage from the junction of the 7th and 8th right rib into the thumb. One branch of this V-shaped cartilage was then firmly fixed to the side of the second metacarpal with catgut sutures (Fig. 7, 8). Half a year later active movements were recorded, i. e. flexion of the two phalanges. After entering school, the girl started to use her repaired

thumb when writing. A check-up after two years has shown good growth of this thumb, the length of which is approaching that of the good hand (Fig. 8, 9). Early cartilage transplant replacing the finger skeleton has made it possible to acquire working reflexes of the hand, thus encouraging good development of the part threatened by becoming stunted in growth.

SUMMARY

We recommend the use of cartilage as a temporary substitute for the skeleton in congenital defects. Early reinforcement activates the preserved muscles of the finger, working reflexes are acquired in childhood and, thus, the restored reinforcement of the finger becomes a physiological growth impulse for the hypoplastic finger.

ВЫВОДЫ

Применение хряща для замещения врожденного дефекта скелета пальца

В. Карфик

Автор применил хрящ в качестве временного замещения скелета при врожденном дефекте скелета большого пальца. При помощи своевременного подкрепления активируются сохранившиеся мышцы пальца, осваиваются в молодости рабочие рефлексы и восстановленное заполнение пальца становится физиологическим импульсом роста в большинстве случаев гипопластических частей пальца.

RÉSUMÉ

Le remplacement d'une défectuosité squelettique congénitale du doigt par du cartilage

V. Karfík

L'auteur s'est servi de cartilage pour remplacer temporairement certaines parties squelettiques, lors des défectuosités congénitales du squelette des doigts. Après la mise en place d'un support solide, pratiquée à temps, les muscles intactes du doigt reprennent leur activité, acquièrent de bonne heure des réflexes de travail et le support renouvellé du doigt confère une impulsion physiologique au développement des parties hypoplastiques du doigt.

ZUSAMMENFASSUNG

Knorpel als Ersatz bei einem kongenitalen Defekt des Fingerskelets

V. Karfík

Der Verfasser verwendete Knorpel als provisorischen Ersatz des Skelets bei einem angeborenen Defekt des Fingerskelets. Durch eine rechtzeitige Versteifung werden die erhalten gebliebenen Fingermuskel aktivisiert, Arbeitsreflexe schon in der Jugend erworben und die wiederhergestellte Stütze der Fingergestalt bildet einen physiologischen Reiz für das Wachstum der hypoplastischen Fingerabschnitte.

REFERENCES

1. **Bunnell, S.**: Surgery of the Hand. Lippincott, Philadelphia 1948.
2. **Lexer, E.**: Wiederherstellungs-Chirurgie. 1928.
3. Plastic Surgery of the Hand. Stát. zdrav. nakl. Praha 1956.
4. **Rank, K. B.**: Surgery of Repair as applied to Hand Injuries. Edinburgh 1953.

(Prof. V. Karfik): Berkova 34, Brno 12, Czechoslovakia

The Medicine and Pharmacy Institute, Bucarest (Roumania) F.P.S.M.F.
Clinic of Plastic and Reconstructive Surgery, Emergency Hospital
Director: Dr. Agrippa Ionescu, Cand. Sci. M.

TOTAL AVULSION OF THE SKIN OF THE PENIS AND SCROTUM

A. IONESCU, A. VASILIU

The traumatic avulsion of the teguments of both penis and scrotum occurs rarely in medical practice.

The case which we present, is more extensive than any we have found in the literature, as, in addition to the avulsion of the skin covering the penis and scrotum, in our case part of the tegument of the perineum were also torn off.

We publish this case not only on account of its rarity but also because when we got the case with such a great loss of teguments 20 hours after the accident, an interesting problem of surgical therapeutics was placed before us.

In cases of avulsion of the skin covering the penis and testicles, it is always recommended that grafting be carried out, because, when deprived of their cutaneous covering, the external male organs become covered by granulation tissue; this encircles the penis, testicles and spermatic chords, which are shortened, strangled and compressed in the course of the scarring process, their function thus being endangered. Such a case has been published by Campbell in 1957, in which he was obliged to excize all the scar tissue and then the skin graft the surface.

The treatment of cutaneous avulsion of the penis by free skin grafting, of full or split thickness, is a fact wholly established to-day in plastic surgery.

Free skin grafts take very well on the penis whose teguments have been avulsed, and the thicker the skin is, the better are the results.

The method of using, neighbouring pedicled flaps containing skin and fat tissue, for the covering of the penis, and the method of Quénu, of burying the penis in a bipedicled skin muff in the hypogastric region, are outdated as the results obtained are not very satisfactory.

With this method a very thick penis is obtained which has little functional flexibility, has the disadvantage of the presence of the pubic hairs, and in which sensitivity reappears very late.

This method is indicated only in cases in which the cavernous bodies of the penis have suffered major injury.

The operative problem of testicles denuded by avulsion of the scrotum sac has not been resolved.

When reconstructing a new covering for the testicles, the patient's mental attitude must be taken into consideration, and his desire to have a new scrotum which well resemble the old one as much as possible, and also the possibility of assuring the patient of normal spermatogenetic function.

The spermatogenetic function of the testicles can be preserved only by assuring these organs good irrigation conditions and a favourable temperature.

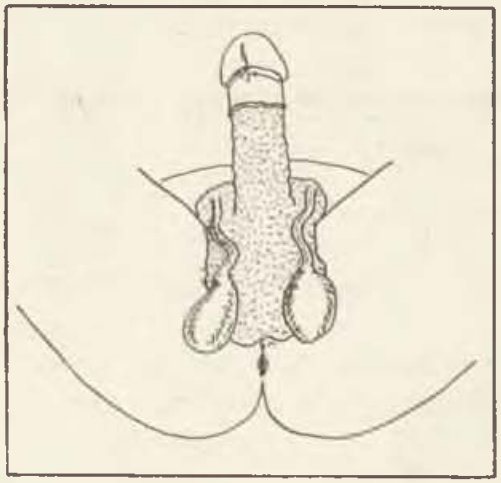

Fig. 1.

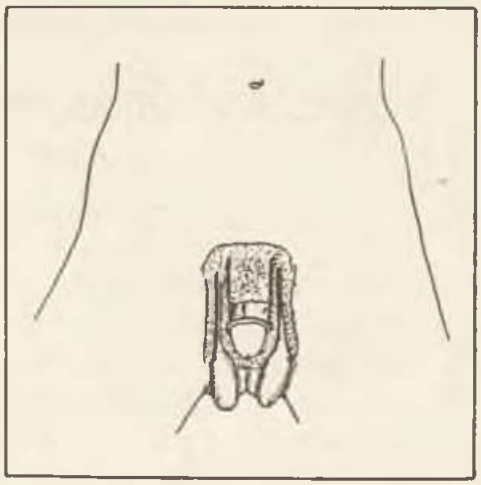

Fig. 2.

Fig. 1. Sketching of initial lesions showing the cutaneous defects created by traumatism with testicles hanging on the chords. — Fig. 2. Sketching of initial lesions showing the cutaneous defects created by traumatism, with testicles hanging on the chords.

Owens showed that for maintaining normal spermatogenesis, the new scrotal sac must ensure the testicles a temperature 1 degree below the normal body temperature.

The different methods of covering the testicles can be divided into three groups:

1. The method in which the testicles are buried beneath the teguments of the upper parts of the thighs.

2. The method by which the testicles are covered by pedicled flaps taken from the thighs.

3. The method in which the testicles are covered by free skin grafts.

The operative technique of the first group is rapid and convenient both for the patient and for the surgeon, but it does not bestow favourable conditions for preserving spermatogenetic function, as the testicles are maintained at body temperature, which, as we have seen, is not favourable and in the course of time the testicles become atrophied. Furthermore, there are strong repercussions on the patient's mental condition because his external genitals remain mutilated by the loss of the scrotum.

The operative technique of the two latter categories are to be preferred, as the patient is provided with a new scrotum, in which the testicles are preserved in conditions approaching more closely the normal.

Gibson and Conley think that the ideal solution is only obtained by grafting the testicles with free skin grafts, spermatogenesis being preserved only in these conditions.

Nevertheless, this technique also is not perfect, as spermatogenesis decreases after some time, as Balakrishnan showed, even if a new scrotum has been created by grafting with free skin flaps.

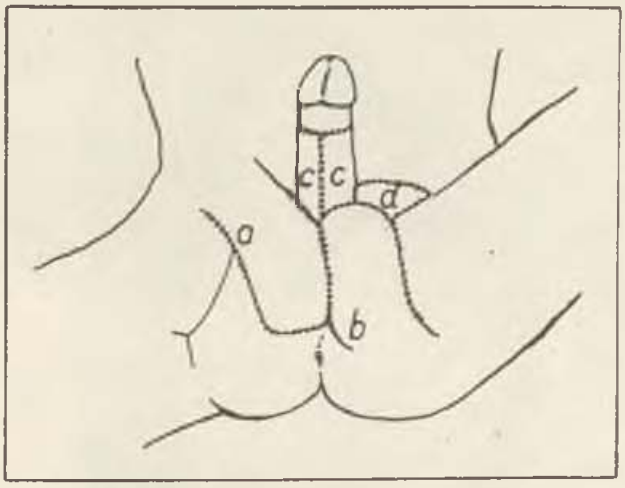

Fig. 3. Sketching of initial operation: a, b. — pedicled flaps; c, d. — free skin grafts of full thickness.

Fig. 4. Seven days after operation. One may notice the pedicled flaps that cover the testicles, and the free graft on the penis; also the delivering incisions on the thigh.

Malbec, in 1958 states that: "Spermatogenesis is possible only when the testicle is placed in its original sac, and placed under favourable conditions of temperature, circulation, etc., — things which are impossible to obtain by plastic surgery technique, however complex and perfect it may be".

Our case was an agricultural labourer, aged 28, a tractor driver, who in the afternoon of July 28, 1958, attempted a place a transmission strap on to a cutting straw machine. The strap caught his overall, twisted and avulsed it as well as

the skin covering the penis and scrotum which got twisted in the overall. Though wounded, the patient climbed on to his machine, which he drove alone 18 km. till he reached the medical centre, where the emergency ambulance was called, which took him to the local hospital. There, his wound was dressed and he was sent to Bucarest. The next day, the patient was admitted to our clinic, where, after examination, operation is decided upon.

Fig. 5. End result.

The patient showed avulsion of the skin of the external genitalia, including the penis and scrotum, with the exception of the glands and of a small tegumental ring at the level of the prepuce. The anterior denuded area reached the public insertion of the penis suspensor ligament and laterally it reached the upper part of the thighs at the inguinal fold and behind it included the perineum up to 5 cm. from the anal orifice. The wound was dirty, with numerous necrotic particles of denuded tissue and vascular thrombosis. The cavernous bodies did not show major injuries. The testicles, with the parietal vaginalis untouched, were suspended to the spermatic chords. An echymosis was visible on the glands. There were numerous excoriations on the antero-internal surface of the right thigh. In view of the extent of the injury and the fact that the wound was dirty and the patient 20 hours after the accident, it was decided to graft the penis with a free skin graft and to cover the scrotum and the rest of the denuded perineum by pedicled flaps from the thighs.

The patient was operated on the July 29, under ether-oxygen endotracheal anaesthesia.

In the first stage operation, two pedicled flaps were formed, sized 25 X 15 cm. from the antero-internal superior portion of the two thighs, one with an inferior

base, the other with a superior one, which were shifted inside and sutured on the median line, covering the two testicles. The denuded areas created were covered by the method of local plastics by the Limberg procedure, and the areas that could not be sutured on account of tension, where the flap had the inferior base, were grafted a few minutes later with a full thickness free skin graft.

In the second stage a full thickness free skin graft was taken from the left fossa iliaca and the left flank, sized 20×12 cm. with which the penis was grafted as well as the denuded area on the left thigh. The denuded area created on the abdominal wall was sutured. A urinary catheter was introduced into the bladder via the urethra to drain the urine and at the same time to serve as internal splinting for the penis, which at the end of the operation was fixed and immobilized by a plaster.

The operation was carried out under cover of local and parenteral antibiotics. Two days after the operation the patient developed orchiepididymitis, first on the right side, and after two days, on the left side, which disappeared after a few days of treatment.

The free skin graft on the penis took to the extent of 85 per cent, with necrotic areas at the insertion of the penis, which after elimination was grafted anew. The free grafts on the thighs took to the extent of 50 per cent.

The pedicled flaps maintained their viability and covered the testicles well with the exception of a few small areas of marginal necrosis at the level of the perineal sutures, which, after elimination, was freely grafted.

In view of forming a sac for the new scrotum, and to assure better preservation of the testicles, a Filatov flap was formed at the base of the right hemithorax (26. 11. 1958) with which later (10. 1. 1959) the skin surface of the new scrotum was enlarged.

Twelve days after the operation the patient had erections, and after 3 months sexual intercourse was possible.

To-day, 15 months after the operation, he continues sexual activity.

CONCLUSION

In conclusion, we would like to emphasize the following:

1. The patient was operated on 20 hours after the accident, the wound being very dirty.

2. The method applied for covering a surface exceeding 500 cm^2. and trying at the same time to assure a normal function, was a combined one: full thickness free skin graft for the penis and pedicled flaps for the scrotum.

3. To give the necessary shape to the new scrotum and to assure a certain mobility of the testicles, it was necessary to bring new skin by Filatov pedicled flaps.

4. The anatomical and functional result was good after 3 months, and is maintained now, after 15 months.

ВЫВОДЫ

Полное оскальпирование мужского полового члена и мошонки

А. Ионеску, А. Василиу

В заключение мы хотим подчеркнуть следующее:

1. Больной был оперирован спустя 20 часов после травмы при наличии сильно загрязненной раны.

2. Для покрытия дефекта, превышающего 500 кв см, и в целях обеспечения нормальных функций, был применен комбинированный метод: свободная пересадка кожи полной толщины для покрытия полового члена и использование лоскутов на ножке — для восстановления мошонки.

3. Для придания новой мошонке желательной формы и для обеспечения некоторой подвижности яичек, было необходимо произвести добавочную пересадку кожи при помощи филатовских лоскутов на ножке.

4. Спустя 3 месяца наблюдались хорошие анатомические и функциональные результаты, которые сохраняются уже в течение 15 месяцев.

2. La méthode employée pour couvrir une parte de la peau à la surface de plus gewinnen.

RÉSUMÉ

Décollement cutané total de la verge et du scrotum

A. Ionescu, A. Vasiliu

En conclusion, nous voulons souligner les faits suivants:

1. Le malade était opéré 20 hrs. après l'accident, la plaie étant très sale contaminé.

2. La méthode employée pour couvrir une parte de la peau à la surface de plus de 500 cm² cube qui en même temps tâchait de restaurer la fonction normale, était compliquée:

pour la verge, c'était l'autogreffe dermo-epidermal,
pour le scrotum, le lambeau pédiculé.

3. Voulant procurer la forme nécessaire au nouveau scrotum et faciliter les mouvements des testicules, on a été obligé de se servir du lambeau tubulé de Filatov.

4. Les résultats, quant à l'anatomie d'autant qu'à la fonction, ont été favorables après 3 mois, et le restent encore aujourd'hui, les 15 mois passés.

ZUSAMMENFASSUNG

Totale Penis- und Skrotumskalpierung

A. Ionescu, A. Vasiliu

Abschliessend möchten wir Folgendes bemerken:

1. Der Patient wurde 20h nach dem Unfall operiert, wobei die Wunde sehr verunreinigt war.

2. Sehr Deckung einer mehr als 500 ccm betragenden Oberfläche wurde eine kombinierte Methode zwecks Sicherung einer normalen Funktion verwendet: Ein Ganzhaut-Transplantat für den Penis und ein Stiellappen für das Skrotum.

3. Um eine entsprechende Form des neuen Skrotums und eine gewisse Beweglichkeit der Testikel zu sichern, war es notwendig einen neuen Filatov'schen Stiellappen zu gewinnen.

4. Das anatomische und funktionelle Ergebnis war nach 3 Monaten gut und dauert nach 15 Monaten noch an.

(Dr A. Ionescu): Str. Biserica Amzei 2, Bucarest, Roumania

Laboratory of Plastic Surgery, Czechoslovak Academy of Sciences, Prague (Czechoslovakia)
The Burns Unit of the Clinic of Plastic Surgery, Charles University, Prague
Director: Academician F. Burian

ELECTRIC CONDUCTIVITY OF TRANSPLANTED HUMAN SKIN IN THE COURSE OF HEALING

J. KRYŠPÍN, J. DOLEŽALOVÁ

When using electrophysiological methods in research on the transplantation of human skin, we find that a comparison between the well known facts of human skin electrophysiology and the pathophysiological changes of the skin during transplantation is almost completely lacking. The aim of this work was to establish basic criteria for the electrical findings in transplanted human skin.

MATERIAL AND METHODS

Nine patients (8 men, 1 woman), aged 18 to 47 years, were examined, all of whom had sustained burns of the second and third degree of varying extent. All had been grafted either with their own or with homologous skin. The investigations were usually made after the surgical healing of grafted areas. Several patients were under observation until two years after the operation. The ohmic resistance of the graft was measured by means of our method of transients with constant current (density of current about 1 microampere per sq. cm), in four cases the temperature of skin surface was also measured by means of thermistor thermometer. The healthy and clinically normal skin of the same subject were used as control.

THEORETICAL QUESTIONS OF SKIN ELECTROPHYSIOLOGY

The advantage of our method is the measurement of the ohmic resistance of the skin by means of direct constant current which excludes the distorsion of the values by the so-called polarisation counter-electromotoric force. This polarisation distorsion is observed in all cases measured without constant current and is rather complicated when the voltage is more than 2 volts. The exclusion of the polarisation counter — e. m. f. on the skin is the most important arrangement which secures the correct interpretation of results. The other important methodical requirement is a good non-polarisable electrode — in our experiments Ag-AgCl electrode was always used — and a well reproducible contact between the electrode and the skin, which is attained by means of a cellophane membrane of constant size on the bottom of the electrode vessel which is filled with physio-

logical saline. Good quality of electrodes and ohmic character of measured values are controlled by means of transient phenomena which are observed and/or photographied on the screen of a cathode-ray oscilloscope. In this arrangement it is possible to measure well reproducible values of ohmic resistance of normal and transplanted human skin, including their physiological variations for minutes and hours. An important criterion of the correctness of observed values is the linear relationship between current and voltage on the measured area of skin. This linear relationship is found in all types of skin but in a range of very small currents only — up to 10 microamperes; as soon as the voltage in the skin is over 2 volts, there are deviations from a linear relationship.

EVALUATION OF RESULTS

We first evaluate the average resting values of ohmic resistance, which are ascertained by repeated measurements of one or more areas in one experiment. The average value is calculated from about ten measurements. An important criterion of the electric properties of the graft is the index R_T/R_N, i. e. the ratio of resistance of the graft R_T to resistance of normal skin R_N. We next evaluate the relationship voltage-current for currents greater than 10 microamperes which should be non-linear for normal skin. The relationship between electric and thermal conductivity of graft and normal skin was tested by means of the thermal circulation index (Burton 1947).

RESULTS

The resting average values of normal skin are 220,000 ohms per 1 cm^2, in all our patients they varied between 25,000 ohms and 450,000 ohms. The resting values of the graft depend on several factors: the interval after transplantation, mode of management and dressing, vitality of the graft, epidermal regeneration, restitution of skin organs and innervation. The variance of values in our material is therefore considerable and in evaluating the resting values, the index R_T/R_N is of greatest importance, as is demonstrated by its changes during the healing of two of our patients.

Both patients were burnt by an explosion; the first case was a woman with rheumatoid arthritis and the extent of the burns was 32%. Healing was uneventful. The take of the grafts was very good, the newly formed skin was rather dry and scaly, with slight tendency to crack. The granulations were healthy, epithelization good. Bacteriologically *Staphylococcus pyogenes aureus* and *Streptococcus beta-haemolyticus* were present. The haemoglobin and blood albumin values were low during the whole time of hospitalization. The other patient, a man, with burns covering 27% body area, had a complicated course with bronchopneumonia and mental changes. The granulations were healthy and contaminated with *Staphylococcus pyogenes aureus* and *B. pyocyaneus*. Haematological and biochemical findings during hospitalization were normal.

The indices R_T/R_N had a similar character in all our patients; we have divided all calculated values of R_T/R_N into two groups, depending on the time elapsed from transplantation. The periods were: the first up to six months,

Patient	Interval after transplantation	Local findings	R_T/R_N
D. M., woman, 35 years	4 days	grafts without reaction, without desquamation	0,268
	9 days	good take of all grafts, beginning to grow from margins	0,595
	30 days	dry scaly scar	0,460
	18 months	dry scaly scar, in several places oedema of subcutis, dilated superficial skin veins	1,560
P. Z., man, 34 years	30 days	good take of grafts, epithelization from margins	0,608
	9 months	thickened grafts, varices of superficial skin veins, hypertrophy of margins	0,546
	12 months	marginal hypertrophy vanishes, varices still present	1,140
	15 months	no marginal hypertrophy, boundaries between grafts vanishing, varices of superficial veins vanishing	1,350
	2 years	no boundaries between grafts, soft pliable scar, cyanosis and itching in cold environment	1,000

the second over six months. In the first group, the index was 0.950, in the second it was 1.165; the difference has a great statistical significance ($P < 0.001$).

A linear relationship was observed between voltage and current in transplanted skin in 40% and in normal skin in 6.7%. This difference is striking and constant. No relationship between electrical and thermal conductivity was demonstrated either for normal or transplanted skin.

DISCUSSION AND CONCLUSION

The results of our measurements are well reproducible not only on single patients but in the whole series. The resistance of human skin is a value which reflects all changes in the internal and/or external environment of an organism. Therefore, a static measurement of resistance values is rather unreliable, but if it is possible to measure one area repeatedly, either for minutes or hours, or longer periods, we can get much useful information. To-day, it would be premature to explain pathophysiological changes in grafts on the basis of our results. We have tried only to demonstrate the significance of basic problems of skin electrophysiology in clinical research and the possibility of using simple criteria of the functional state of the human epidermis, such as non-linear dependence of the resistance when using greater currents, and the ratio of the resistance of transplanted to normal skin. For a detailed study of functional regeneration we have suggested electrophysiological epidermal stripping test (Kryš-

pín, Harantová, Koníčková 1959) and we assume that for skin electrophysiology, to be of value clinically several new functional tests are needed, with the possibility of quantitative evaluation and the reliable interpretation of results. From the point of view of biological interpretation of electrical measurements, the measurement of polarisation counter — e.m.f., or polarisation resistance respectively, is rather inexact and unreliable.

We stress the significance of ohmic resistance, as measured by means of transients with constant direct current, the interpretation of which is simple (geometrical factor, number, mobility and charge of particles). Our comparison of values of thermal and electrical conductivity shows a complete independence of these two values, which could be taken as an argument against identity of important structures (electrical and thermal barrier respectively) and indirectly could prove the independence of resistance and circulation.

SUMMARY

This communication presents first experiences with skin electrophysiology in research on transplanted skin. Methodical and theoretical questions of skin electrophysiology are first shortly elucidated, especially those that have been rather neglected in clinical research. For estimating the electrical properties of transplanted human skin, the factor R_T/R_N has been found the most reliable (the ratio between average graft resistance and average normal skin resistance of one patient in one series of measurements). This index is significantly dependent on the time after transplantation, in our series it was lower than 1.00 in the group under six months and higher than 1.00 after this period. We assume that it can be taken as an indicator of renewal of normal properties of transplanted epidermis. Another important indicator is the function voltage-current which in transplanted skin is linear in 40%, and in normal skin only in 6.7%.

In conclusion, we can state that with certain methodical precautions, skin-electrophysiology is a very useful and rather unexplored method of transplantation research, especially in its clinical aspects.

ВЫВОДЫ

Электрическая проводимость трансплантатов человеческой кожи в течение их приживления

Й. Кришпин, Й. Долежалова

В статье описывается первый опыт в отношении применения электрофизиологии кожи для изучения трансплантированной кожи. Прежде всего обращается внимание на необходимость соблюдения некоторых методических предпосылок, далее на теоретические вопросы электрофизиологии кожи, которым, особенно при клиническом исследовании, не уделялось внимания. Для оценки электрических свойств трансплантированной человеческой кожи наиболее пригодным оказался фактор R_T/R_N (соотношение сопротивления трансплантата и сопротивления нормальной кожи у того же больного в указанной последовательности измерения) и определение зависимости напряжения от тока. Фактор R_T/R_N показался значительно зависимым от времени, прошедшего с момента трансплантации; у наших больных он составлял до 6 месяцев после трансплантации менее 1,00, а после истечения этого

времени — он был выше 1,00, так что его можно расценивать в качестве определенного индикатора восстановления нормальных свойств трансплантируемого энидермиса. Прямолинейная зависимость между напряжением и током у нормальной кожи отмечается только в 6,7 %, в то время как у трансплантируемой кожи она была установлена в 40 % наших наблюдений. В заключение можно сказать, что при соблюдении определенных методических принципов электрофизиология кожи представляет собой весьма выгодный и до сих пор неиспользованный метод исследования трансплантации, особенно клинического.

RÉSUMÉ

Conductibilité électrique des greffons de la peau humaine

J. Kryšpín, J. Doležalová

L'étude présentée communique les premières expériences faites avec l'emploi de l'électrophysiologie cutanée pour des recherches sur la peau greffée. Après avoir souligné la nécéssité d'observer certains principes méthodiques, les auteurs passent en revue quelques questions théoriques de l'électrophysiologie cutanée qui ne sont que trop négligées, surtout dans les investigations cliniques. C'est le facteur R_T/R_N, c'est-à-dire le rapport entre la résistance du greffon (R_T) et celle de la peau normale (R_N) du même malade dans des conditions données, qui s'est montré le plus approprié pour l'évaluation des propriétés électriques de la peau greffée, puis la détermination de la fonction $E=f(i)$, c'est-ă-dire la corrélation entre la tension et le courant. Le facteur R_T/R_N était en corrélation significative avec le temps qui s'était écoulé depuis la greffe, chez nos malades, il était inférieur à 1,00 au cours des 6 premiers mois après le greffage et supérieur à 1,00 après cette période, ce qui permet de le considérer comme étant un certain indicateur de la rénovation des propriétés normales de l'épiderme greffée. Une corrélation linéaire entre la tension et le courant n'existe que dans 6,7 % seulement en ce qui concerne la peau normale, tandis que nous l'avons constatée dans 40 % de nos observations faites sur la peau greffée. Nous en concluons que, si certains principes méthodiques sont observés, l'électrophysiologie cutannée constitue une méthode très utile et, jusqu'à présent, insuffisamment exploîtée pour les recherches, surtout cliniques, dans la domaine des greffages.

ZUSAMMENFASSUNG

Elektrische Leitungsfähigkeit von Menschenhaut-Transplantaten im Verlaufe der Einheilung

J. Kryšpín, J. Doležalová

Die Arbeit enhält die ersten Erfahrungen mit der Elektrophysiologie bei der Erforschung der transplantierten Haut. Vor allem wird auf die Einhaltung einiger methodischen Voraussetzungen, ferner auf theoretische Fragen der Elektro-Hautphysiologie aufmerksam gemacht, die besonders bei der klinischen Forschung vernachlässigt wurden. Bei der Beurteilung der elektrischen Eigenschaften der transplantierten Menschenhaut hat sich der Faktor R_T/R_N am besten bewährt, der das Verhältnis des Transplantat-Widerstandes (R_T) zum Widerstand der Normalhaut (R_N) des gleichen Patienten in der gegebenen Messungs folge darstellt; weiter die Funktions-Feststellung $E = f(i)$ d. i. die Spannungsabhängigkeit vom Strom. Der Faktor R_T/R_N hing wesentlich vom Zeitraum nach der Transplantation ab und war bei unseren Patienten bis zu 6 Monaten nach der Hauttransplantation niedriger als 1,00 und von diesem Zeitraum ab höher als 1,00. Daher kann der Faktor R_T/R_N als bestimmter Erneuerungsindikator der normalen Eigenschaften der transplantierten Epidermis angesehen werden. Eine lineare Spannungsabhängigkeit vom Strom besteht bei

der Normalhaut bloss in 6,7 %, wogegen wir bei der transplantierten Haut eine solche in 40 % unserer Beobachtungen feststellen konnten. Wir schliessen daher, dass die Elektro-Hautphysiologie bei Einhaltung von bestimmten methodischen Grundsätzen eine sehr zweckmäßige und bisher unausgenützte Methode, besonders der klinischen Transplantationsforschung darstellt.

REFERENCES

1. **Burton, A. C.:** Amer. J. Physiol. 129, 326, 1947.
2. **Kryšpín, J., Harantová, Z., Koníčková, Z.:** Čs. Fysiol. 9, 31, 1960.

(Dr. J. Kryšpín): Legerova 63, Praha 2, Czechoslovakia

Clinic of Plastic Surgery, Charles University, Prague (Czechoslovakia)
Director: Academician F. Burian
First Stomatological Clinic, Charles University, Prague
Director: Prof. J. Křečan, M. D.

CONTRIBUTION ON FACILITATING IMPLANTATION OF CHIPPED CARTILAGE AND BONE INTO CAVITIES

M. FÁRA, V. HABERZETTEL

In plastic surgery, orthopaedics, stomatology, otorhino-laringology and other surgical branches it is often necessary to implant cartilage or bone transplants into cavities or under the skin and mucosa in order to fill a defect of hard tissue.

This may be performed by placing a suitable shaped cartilage or bone graft through an incision made, if possible, at an inconspicuous site (on the margin of the eyebrows, in the hairy part of the head, in a skin crease in the face or in an existing scar), by which a broad approach to the defect can be obtained.

In other cases chipped cartilage or bone, i. e. tissue cut into minute shavings or chips, suffices for filling the cavity. This material for implantation is then placed at the site of the defect through the smallest possible and most inconspicuous incision in the skin or the mucosa.

Hitherto, this was performed at the Clinic — and as far as the authors could ascertain, also elswhere — by way of a small incision through which it was possible to reach the cavity or depression under the skin (or the mucosa). A pocket of required shape and size was prepared by dissecting scissors or other suitable instrument passed through the incision, and the chipped transplant then laboriously inserted in small portions with tweezers and pusher by means of a grooved inserter. Syringes with broad necks proved unsuitable because the chipped material, massed and compressed by the piston, immediately blocked the outlet of the neck. The authors tried to introduce a short tube filled with the chipped material which they pushed out into place by means of an improvised stylet. This method too, however, proved unsatisfactory because of the time-consuming filling of the tube and its small capacity.

Therefore, the authors designed an apparatus which facilitates and accelerates the implantation of chipped cartillage or bone.

DESCRIPTION OF APPARATUS

The gadget consists of a tube (1) into which a stylet (10) fits exactly. The tube and the stylet are cut at one end obliquely at an angle of 45^0. At the other end of the tube two rings are fixed for the fingers (2), and one ring on the stylet for the thumb (9). All the three rings are in one plane. Where the ring is fixed to the

stylet there is a small wedge (8) which fits into a notch (7) of the tube (1) determining the correct position of the point of the stylet when completely inserted. Near the rings of the tube a container (6) the shape of a hollow prism is attached, the one broader side of which is about one third shorter than the others. The

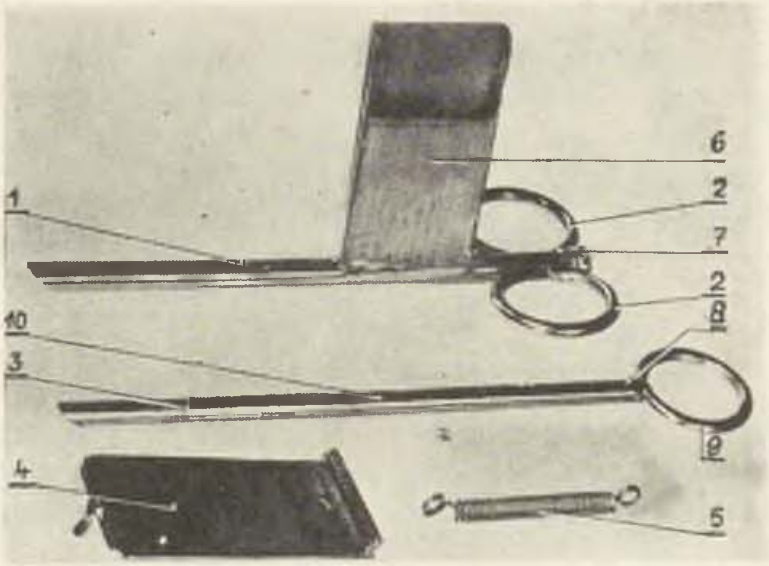

Fig. 1. Parts of apparatus for implantation of cartilage and bone into cavities. 1 — tube, 2 — rings of fingers, 3 — gauge-mark on the stylet, 4— pusher, 5 — spiral spring, 6 — container, 7 — notch in the tube, 8 — wedge on the stylet, 9 — ring for the thumb, 10 — stylet.

container has no bottom so that the space inside is continuous with that of the tube. A pusher exactly fitting into the container (4) is pushed inside by a spiral spring 5) (Fig. 1, 2, 3).

FUNCTION OF APPARATUS

The container (6) is filled with minute pieces of cartilage or bone and then the pusher (4) is placed into position. The stretched spiral spring (5) is then fixed to the pusher (4). The stylet (10) is withdrawn to the gauge mark (3) so that the space in the tube below the container is freed. The chipped cartilage (bone) squeezed out from the container (6) by the pusher (4) fills the space in the tube below the container (6). On inserting the stylet (10) the cartilage (bone) chips are pushed to the end of the tube and out. By repeated withdrawal and insertion of the stylet the transplant material is pushed from the container towards the free end of the tube, and from there out.

APPLICATION OF APPARATUS DURING OPERATION

Through a small incision a tunnel is made by which a pocket for the implantation of the cartilage (bone) chips is prepared.

The gadget can then be used in two ways:

1. The free end of the tube is inserted into the pocket to the site where the transplanted tissue is to be placed. The required amount of cartilage (bone) is deposited by the repeated withdrawal and insertion of the stylet.

2. It is also possible first to block the free end of the tube by a finger and to fill the whole tube with transplant material by repeated withdrawal and insertion of the stylet, and afterwards to introduce the tube into the wound. The procedure is then the same as in the first instance.



Fig. 2. View of apparatus from the left. 1 — tube, 2 — rings for fingers, 4 — pusher, 6 — container.

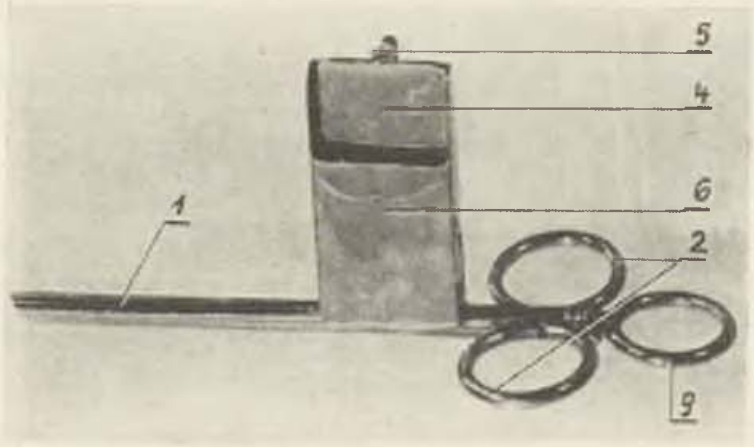

Fig. 3. View of apparatus from the right. 1 — tube, 2 — rings for fingers, 4 — pusher, 5 — spiral spring, 6 — container, 7 — notch in the tube, 9 — ring for thumb.

The advantages of the apparatus are as follows:

1. Easy and quick placing of the implanted tissue at the site of the defect through a minute incision.
2. Sufficiently large volume of the container and the simple way of filling it.
3. When squeezed out the material is slightly compressed so that it can easily be moulded from without by the fingers, and keeps its shape.

If working with cartilage considerable difficulty and time losses arise from the preparation of the material, i. e. the chopping of the coarse grafts into the required fine pieces. Hitherto, the practice at the Clinic was to cut the cartilage by hand with a scalpel into fine chips just as one cuts onions. The particles of cartilage, however, were of different size, work was protracted and the time needed for the operation thus prolonged.

For this reason the authors designed a gadget by which it is possible to cut cartilage quickly into equally thin shavings of required dimensions. The shavings thus obtained are very suitable for use in the above-described "apparatus for implantation", since by the pressure of the pusher in the container and the stylet



Fig. 4. Part of apparatus for cutting cartilage. 1 — basic slab of gadget, 2 — cutting blade, 3 — rider, 4 — container, 5 — pusher of container, 6 — spiral spring, 7 — rod connecting spiral springs above pusher of container, 8 — groove on top of pusher where the rod lies (7).

in the tube they are easily moulded into a compact mass with minimum free space in between. When designing the gadget the authors were concerned with making its operations as simple possible.

DESCRIPTION OF APPARATUS

The gadget consists of a small slab (1) of rectangular shape in the centre of which a blade (2) is obliquely fixed. (An ordinary blade for sharpening pencils was used which can be changed when blunt.) The blade is fixed to the slab by a handle and screws. A rider (3) with an opening (4) in the centre, forming the container for the cartilage, is attached to the slab. The long axis of the container is at right angles to the slab. The pusher (5) is pressed into this container by two spiral springs (6) fixed at one end to a connecting rod (7), at the other to the base of the container (Fig. 4, 5).

OPERATING OF APPARATUS

The rider is put into the slab (1), the cartilage placed into the container (4), the pusher applied (5), the rod (7) connecting the spiral springs (6) placed into the groove (8) of the pusher (5). The slab (1) with the blade (2) is then grasped by the left hand so that one end rests on the tip of the thumb, the other on the tips of the fingers. The right hand holds the rider at side notches at the level of the slab and is quickly shifted from one end of the slab to the other and back. Shavings of cartilage fall directly into the palm of the hand. If finer shavings

are required the pieces cut first are placed again into the container and cut for a second time. Thus very fine chips the shape of short noodles are obtained.

With the help of this gadget cartilage is cut more evenly and much quicker than by hand with a scalpel.



Fig. 5. View of assembled empty apparatus. 1 — basic slab of garget, 2 — cutting blade, 3 — rider, 5 — pusher of container, 6 — spiral spring, 7 — rod connecting both spiral springs.

SUMMARY

In the surgery of the face and in orthopaedics it is often necessary to implant chipped cartilage or bone into cavities or to even out depressions.

The authors designed a gadget with the aid of which this operation can be performed more quickly and more easily through a minute incision in the skin than previously by the laborious and time-consuming filling of the cavity by means of tweezers and pusher. By the described method the material sqeezed out is slightly compressed so that it can easily be moulded as required by finger pressure from without and preserves its shape.

In order to eliminate the time-consuming and inexact cutting of cartilage by hand with a scalpel the authors designed another gadget which is constructed like a grater and permits easy and quick slicing of cartilage into equally thin shavings of required dimensions which are very suitable for the use in the "apparatus for implantation".

ВЫВОДЫ

Пособие для облегчения работы при имплантации измельченного хряща и кости в полости

М. Фара, В. Габерцеттель

В хирургии лица и в ортопедии зачастую возникает необходимость имплантации измельченного хряща или кости в полости или для заполнения впадин.

Авторы сконструировали прибор, при помощи которого можно быстро и удобно производить это вмешательство из небольшого кожного разреза вместо прежнего трудоемкого

и длительного заполнения полостей при помощи пинцета и другого набивочного инструмента. При применении этого прибора выдавливаемый материал немного сдавливается и таким образом его можно легко формировать путем давления пальцев через кожу, причем он сохраняет придаваемую ему форму.

Для устранения длительного и неточного разрезания хряща при помощи скальпеля вручную авторы сконструировали второй прибор. Его конструкция напоминает терку и при его помощи можно быстро и удобно нарезать пластинки одинаковой толщины и необходимых размеров, которые весьма пригодны для применения в «приборе для имплантации».

RÉSUMÉ

Une contribution pour rendre plus aisée l'implantation de cartilage fragmenté et de matière osseuse dans les cavités

M. Fára, V. Haberzettel

En chirurgie faciale et en orthopédie nous nous trouvons souvent forcés d'implanter du cartilage fragmenté ou de la matière osseuse dans les cavités ou pour remplir des impressions.

Les auteurs ont construit un appareil à l'aide duquel cette intervention peut être pratiquée rapidement et aisément, en ne faisant qu'une petite inscision en comparaison à l'ancienne méthode où l'on remplissait les cavités à l'aide d'une pince et d'un remplisseur. En outre, le matériel est forcé dans la cavité sous pression légère ce qui permet un modelage aisé par pression transcutanée à l'aide des doigts et la forme obtenue reste inchangée.

De façon à éliminer le coupage manuel du cartilage à l'aide d'un scalpel, ce qui est une méthode lente et inexacte, les auteurs ont construit un autre appareil. C'est une sorte de râpe qui permet de couper aisément et rapidement des écailles de cartilage également minces et de la taile voulue ce qui les rend appropriées pour l'usage dans l'appareil d'implantation.

ZUSAMMENFASSUNG

Beitrag zur Arbeitserleichterung bei der Implantation von zerstückelter Knorpel und Knochen in die Höhlen

M. Fára, V. Haberzettel

In der Gesichtschirurgie und Orthopedie tritt oft das Bedürfnis ein, zerstückelte Knorpel oder Knochen in die Höhlen zwecks Ausfüllung von Impressionen zu implantieren.

Die Autoren haben einen Apparat angefertigt, mittels dessen man diesen Eingriff aus einer kleinen Haut-Inzission rasch und bequem durchführen kann, statt der früher geübten mühsamen und lanwierigen Ausfüllung der Höhlen mittels Pinzette und
Dabei ist das ausgepresste Material mässig zusammengedrückt, dass es sich je nach Gebrauch durch transcutanen Fingerdruck gut formen lässt und die gegebene Form beibehält.

Zwecks Beseitigung des langwierigen und ungenauen Scheidens der Knorpel mittels Skalpel wurde ein zweiter Apparat angefertigt. Der Apparat ist auf die Art eines Reibeisens konstruiert, mittels dessen man bequem und rasch gleich dünne Blättchen in den gewünschten Ausmassen schneiden kann, die sich sehr gut zur Verwendung im „Apparat zur Implantation" eignen.

(Dr. M. Fára): Šrobárova 50, Praha 12, Czechoslovakia

Central Institute of Traumatology and Orthopaedics, Moscow, U. S. S. R.

RECONSTRUCTION OF THE HAND AND FINGERS BY MEANS OF FILATOV'S TUBED FLAP WITH TRANSPLANTATION OF BONE, CARTILAGE OR PLASTIC MATERIAL

V. N. BLOKHIN

There are a large number of patients requiring reconstructive operations of the hand and fingers as a result of various types of injuries, frost-bite, burns, defects from tumour removal, congenital defects and amputation of part of the hand and fingers. This high incidence is due either to the severity of the original trauma, or to the lack of careful operative and therapeutic techniques on the part of the surgeon who carried out the primary treatment i. e. did not use techniques of primary plastic surgery. Such reconstructive operations are very difficult and are rarely performed by the few experts in the field. The task has been here taken on of working out simpler methods of reconstruction with the least risk to the patients and making these available to the widest possible surgical circles.

From existing methods it is known that for a given reconstruction of defects of the hands and fingers to be functional, the following are the most important: 1. the use of metacarpals to form phalanges, 2. transplantation of toes to the hand, 3. replacement of the thumb with the index finger, 4. replacement of the thumb by the third or fourth digit from the same hand, 5. transplantation of fingers from the other hand, 6. reconstruction of fingers by the method of skin-bone plasty.

The operation for the construction of a phalanx from the metacarpal (provided the latter is long enough) when all fingers are missing is simple, always effective, and markedly increases the function of the hand (Albrecht, Parin, Priorov, Shipachev, Yusevich).

Both we and other colleagues of the Central Institute of Traumatology and Orthopaedics have often performed this operation with excellent functional results, but only if the metacarpal is long enough. If there is scar formation, the operation must be supplemented by a skin plasty (free skin graft or tubed flap).

With a complete or partial defect of the first metacarpal, or if the second metacarpal is not long enough, this operation must be supplemented by a skin-bone plasty, which produces good results.

Transplantation of toes to the hand, according to Nicoladoni is more rarely performed, both from the point of view of frequent failure and due to the

inadequate cosmetic result. The most effective techniques for this operation were worked out by Sviatukhin, Kuslik, Parin and Klarksson. Replacement of the thumb by the index finger or by transplantation of the third of fourth digit from the same hand on nutrient pedicles (a neurovascular flap) are complex operations.

According to the Soviet literature, Parin has performed this operation six times, N. Blockhin five-times and Shushkov twice. In recent years, the technique of this operation has been described in detail by Parin (1944), Gosset (1949), Hilgenfeldt (1950) and Bunnell (1944, 1952) all of whom have introduced some rational modifications.

In 1956 in one patient we carried out replacement of one metacarpal by transplantation of another metacarpal for a defect of the first metacarpal after amputation of all fingers.

These complex plastic operations, involving the necessity of sacrificing a finger for transplantation, can be performed only by a specialist. If the operation fails, there remains an even greater defect and the patient is dismayed.

Transplantation of fingers from the opposite hand is difficult and not indicated. Among other defects, this operation seldom results in a return of sensation.

We consider the most effective method to be a skin-bone plasty of the fingers, which is a technique available to a large number of surgeons.

The type of reconstructive operation and its functional results are in direct relationship to the severity of the damage. Reconstruction is indicated in all cases where all fingers are missing, particularly when there has been damage to both hands. It is also indicated if the thumb is missing, since this digit is the most important for function of the hand. Of lesser significance are single defects of other fingers, with the exception of those patients where an individual finger has a special function for their occupation (musicians, some types of qualified workers, watch makers, etc.). It is necessary to state that in a number of cases a relatively small defect of a finger may cause inability to work due to its negative effect on the psychological state of the patient. A small plastic operation may lead to the complete return of working capacity in such individuals.

A thorough analysis of the defects of the hand and the working out of an individual plan of reconstructive surgery is of great significance for success for each patient in relation to his occupation.

The above relates also to the working out a plan for the primary surgery of open wounds of the hand. It must be remembered that fractions of a centimeter of the long bones of the fingers and hand can markedly simplify subsequent reconstructive surgery.

The method of skin-bone plasty is the most widely used. It can be applied with any combination of defects, if all the fingers are missing, or even in large defects of the metacarpals. The advantage of this method is the use of tissues which per se are of no functional significance (skin, bone transplants). If the operation fails, it can be repeated. The method suggested by Nicoladoni has been gradually perfected. The use of a tubed flap was a significant improvement.

Since 1940 we have carried out the reconstruction of 104 fingers in 69 patients. This is quite a large number, if we compare it with case numbers presented in the literature. In order to shorten the time of treatment we used the technique of the "acute" (single-stage) Filatov tubed flap for 78 of these finger operations. Scheme of the operation (Fig. 1, 2).

Fig. 1.

First stage: transplantation of a single-stage Filatov tubed flap from the abdomen to the stump of the finger or the pedicle metacarpal.

Second stage: section of the nutrient pedicle of the graft.

Third stage: implantation of bone graft into the tube.

The interval between stages averages about 4 weeks.

In most cases bone grafts were taken from the anterior crest of the tibia. Metatarsals with head and periosteum were used 24 times, grafts from the iliac crest 7 times, metacarpals twice.

Some patients refuse operation with bone grafts. In connexion with this, in 1945 we worked out and used a method of forming fingers with the use of a tubed flap and preserved cadaver cartilage, with subsequent fixation of tendons on to it. The tendons of the remaining fingers were frequently lengthened with silk or capron fibres. This method was used in the reconstruction of eight fingers: six using preserved cadaver cartilage and two using heterogenous cartilage conserved in alcohol.

On one occasion the cartilage was extruded due to dehiscence of the wound edges produced by tension at the base of the finger.

In 1948 we worked out a method of finger formation from tubed flaps and phalanges of plastic material, with subsequent transposition of tendons. This method is less physiological, although the plastic implants were used to form fingers, i. e. organs which must bear a significant degree of functional load. The implant causes a certain amount of trauma to the surrounding tissue giving

rise to the formation of a capsule round it. In order to attain better contact between the tissue and the implant, small pits were made in it to facilitate the ingrowth of connective tissue. Of eight operations, five finger constructions were successful. In two patients it was necessary to remove the healed-in implants; in the first of these within two weeks, in the second six months after fixation

Fig. 1, 2. Patient B., aged 25 years. Both index fingers cut off by a cutting press. Operation (1953) : Skin and bone transplantation (Filatov's flap and bone grafts from tibia). Length of fingers 5.5 cm. Restoration of skin sensitivity of translocated Filatov's flap. Good functional power was attained. (Our observation).

of silk fibres to the implant because of the formation of haematomata causing dehiscence of the wound, and which started from tissue trauma caused by the cutting in of the silk fibres on tightening of the tendons. In the third patient the plastic implant did not hold due to stitch dehiscence resulting from an inadequate blood supply to the flap, which had been transplanted to a highly scarred region after frost-bite to all fingers. In the second of the above patients, conserved bovine cartilage was placed into the granulation bed left after removal of the plastic implant. This latter insert took well and the wound healed per primam.

Of 69 patients, there were 41 men, 23 women and 5 children.

A total of 90 fingers were reconstructed on one hand in 64 patients: in 43 patients one finger, in 17 two fingers in three patients three fingers and in one patient four fingers; a total of 14 fingers on both hands were reconstructed in 5 patients (in three patients two fingers each, in one patient three and in one five.

With the reconstruction of four fingers on one hand, two simultaneous tubed flaps were used. The pedicles sectioned at the abdominal wall, they were sutured to the hand so that the flaps formed loops which when divided four weeks later formed four flaps. Then bone was transplanted simultaneously into all four flaps. The double flap method is suggested for use also in the primary treatment of scalped fingers.

Movement of the fingers in most of the patients was assured by the movements of the metacarpals or the phalangeal stumps on to which the bone graft was fixed. This was successful in the reconstruction of digits II and III even when the stumps were very small.

The follow-up period was 2—12 years.

With complete exarticulation of digits II, III and IV, it is sometimes necessary to form actively movable fingers by means of a tendon and muscle plasty. This method was used for the reconstruction of 10 fingers in 9 patients; the tendons were extended with silk capron fibres. On three occasions the fibres were affixed to bone, on two occasions to conserved cartilage and five times to plastic implants.

Because of the insistent demands of a patient in 1949, we worked out a method of accelerated finger plasty in two stages: first stage — transplantation of a tubed flap to the stump; second stage — severing of the nutrient pedicle with the simultaneous implantation of bone into the flap.

This method was used twice in all, since complications are liable to accumu late with the telescoping of stages. The advantage lies in the small number of stages, with better conditions for transplantation of bone and fixation by means of a plaster cast, since this stage is carried out on the free hand after severing of the nutrient pedicle.

In the reconstruction of 104 fingers complications arose on several occasions (dehiscence of stitches, ulcers of the fingertips, haematomata), but in all cases the final result was not affected: the plastic repair was completed and function, within the predetermined limits, was restored. It must be stated that denervation of the tissue of the flap increases the possibility of infection and circulatory disturbances; for these reasons such patients require absolute aseptic and careful treatment, preferrably by one surgeon.

Dynamic observations of the return of sensation in 20 patients (32 fingers) made in collaboration with Soboleva M., have shown that this process starts between 20 and 30 days after transplantation of the tubed flap in the following order: pain, touch, and temperature far later (cold returns earlier and with greater precision).

As an example, in 1½ months sensation spread 2 cm. from the margin of healthy skin, more frequently, however, within 3—5 months. By one year sensation may spread 3—4 cm, extending to 5—6 cm. during the following year. After 2—8½ years sensation improves, becomes more precise, but the zone never extends more than 5—6½ cm. Hyperaesthesia has been observed. Finger tips (0.5) remained insensitive for 3—8 years beyond the range of 5½ to 6 cm.

The rapidity of spread of various types of sensation from the base of the finger is quite steady during the first year. Pain sensation spread more rapidly than the others, touch spreads to a lesser extent.

If the length of the tubed flap exceeds 6—7 cm, to the fingertip, trophic ulcers may develop, as observed in five patients where there was scarring at the base of the graft, or where there had been previous skin grafts with decreased sensation. In these cases "reamputation" of the tip of the flap was carried out.

Since sensation only appears at the base of the graft after 5—8 months, it is necessary from the start to prevent frost-bite, burns and injury (erosion, ulceration) of the insensitive regions of the fingers both at home and at work.

The length of the finger should not exceed 6—7 cm.

After bone union special remedial exercices are carried out to train the fingers and hand to grasp objects. Since at the start sensation is lacking, along with stereognosis, remedial exercises for developing new movement patterns, are undertaken with the help of the optic analysor under visual control particularly after muscle transplantation.

The use of a single stage tubed flap inspired a study of the problems of the blood supply in the transplanted flap. X-ray-vasographic results using Mazayevs method and capillaroscopy did not always correspond to the actual state of blood flow as seen at operation; the test were more favourable.

Capillaroscopic results one month or more after operation have shown that capillary visibility is not clear at the tip of the graft; individual loops were seen to be dilated, with haematomata at some loci. The entire background was cyanotic. In some fields groups of dilated capillaries (Fig. 1 b, 1 c) were seen, with slowed down, interrupted and jerking blood flow. This picture reflected the congestion in the graft. Within two and a half months the capillary network enlarged, blood flow increased and congestion disappeared.

Research into the blood flow by means of Na^{24} has shown a long lasting delay in the reconstructed fingers. In all of these investigations one must take into consideration the functional lability of the system (nervous and vascular). In all patients, reconstructive operations markedly increased the function of the hand; most of the patients were able to return to work.

SUMMARY

1. Reconstruction of the fingers by means of Filatov's tubed flap, bone transplants and implantation of cartilage or plastic material, gives good functional and satisfactory cosmetic results.

2. The method is simple and can be performed by a large number of surgeons; if complications occur the operation can be repeated.

3. The increase in function satisfies the patient and increases his working capacity.

4. The use of a single-stage ("acute") tubed flap shortens the treatment time.

ВЫВОДЫ

Реконструкция кисти и пальцев посредством стебля Филатова, костного трансплантата, хряща или пластмассы

В. Н. Блохин

1. Восстановление пальцев посредством стебля Филатова, костного трансплантата; имплантация консервированного хряща или пластмассы дает хороший функциональный и вполне удовлетворительный косметический результат.

2. Метод прост и доступен широким кругам хирургов; при осложнениях возможно повторение операции.

3. Получаемая функция удовлетворяет больных и повышает их трудоспособность.

4. Применение одномоментного (острого) стебля Филатова позволяет сократить сроки лечения.

RÉSUMÉ

Le reconstruction de la main et des doigts à l'aide d'un lambeau tubulé d'un greffon osseux, du cartilage ou de matières plastiques

V. N. Blochin

1. La reconstruction des doigts à l'aide d'un lambeau cylindrique, d'un greffon osseux, le greffage de cartilage conservé ou de matières plastiques, assurent un bon fonctionnement et donnent des résultats cosmétiques très satisfaisants.

2. La méthode est simple et accessible à un grand nombre de chirurgiens; en cas de complications, il est possible de répéter l'opération.

3. La récupération fonctionnelle qui satisfait les malades augmente en même temps leurs capacités professionnelles.

4. L'emploi d'un lambeau cylindrique primaire permet d'abréger le temps nécéssaire à la guérison.

ZUSAMMENFASSUNG

Hand- und Fingerwiederherstellung durch gestielten Hautlappenplastik, Knochen-, Knorpel-, oder Kunststoffeinpflanzung

V. N. Blochin

1. Die Wiederherstellung der Finger mit gestielten Hautlappen, Knochen, konservierte Knorpel oder Kunststoff gewährt ein funktionell gutes und kosmetisch vollkommen zufriedenstellendes Ergebnis.

2. Die Methode ist einfach und der breiten Masse der Chirurgen zugänglich; bei Komplikationen ist es möglich, die Operation zu wiederholen.

3. Die erzielte Funktionsfähigkeit stellt die Patienten zufrieden und erhöht ihre Arbeitsfähigkeit.

4. Die Benützung eines gestielten Lappens mit einzeitiger Z-Plastik gestattet eine Verkürzung der Behandlungsdauer.

REFERENCES

1. **Blokhin, V. N.:** Khirurgia 11, 51, 1950.
2. **Blokhin, V. N.:** Tezisy dokladov konferentsii po primeneniyu plastmassy v meditsine. (Reports of the conference on the use of plastics in medicine.) P. 8, Moscow 1954.
3. **Blokhin, N. N.:** Ortop. Travm. Protez. 5, 34, 1955.
4. **Blokhin, N. N.:** Voprosy vosstanovitelnoi khirurgii. (Problems of reparative surgery.) P. 105, Gorkiy 1950.
5. **Blokhin, V. N.:** Kozhnaya plastika. (Skin plastic.) Moscow 1955.
6. **Bogoraz, N. A.:** Vosstanovitelnaya khirurgia. (Reparative surgery.) Moscow. Vol. 1, 1948; Vol. 2, 1949.
7. **Boytchev, B., Konforti, B., Chokanov, K.:** Operativnaya ortopedia i travmatologia. (Operative orthopedics and traumatology.) Sofia 1955.
8. **Kuslik, M. I.:** Vestn. Khir. 33, 97—9, 90, 1934.
9. **Mikhelson, N. M.:** Primenenie trupnogo khryashcha v klinike. (The use of cadaver cartilage in clinical work.) Moscow 1946.

10. **Parin, B. V.:** Khirurgiya 5—6, 60, 1942.
11. **Parin, B. V.:** Rekonstruktsia paltsev ruki. (Reconstruction of fingers of the hand.) Moscow 1944.
12. **Priorov, N. N.:** Trudy 20. Syezda rossiyskikh khirurgov. P. 356, Moscow 1929.
13. **Priorov, N. N.:** Ortop. Travm. Protez. 6, 62, 1935.
14. **Svyatukhin, V. M.:** Nov. Khir. 4, 3, 258, 1927.
15. **Shipachev, V. T.:** Rekonstruktsia paltsev i kisti ruk. (Reconstruction of the fingers and palm of the hand.) Irkutsk 1941.
16. **Shipachev, V. T.:** Rekonstruktsia paltsev ruki (po opytu Otechestvennoy voyny). (Reconstruction of fingers of the hand — from the experiences of Second World War.) Moscow 1946.
17. **Shipachev, V. T.:** Rekonstruktsia paltsev i kisti ruki. (Reconstruction of the fingers and palm of the hand.) Irkutsk 1955.
18. **Shushkov, G. D.:** Rekonstruktivnye operatsii na kultyakh verkhnikh konechnostey. (Some reconstructive operations on the stumps of the upper extremities.) Leningrad 1953.
19. **Yusevich, M. S. V.:** Voprosy protezirovania. (Problems of prosthetics.) Trudy Leningradskogo nauchno-issledovatelskogo instituta protezirovania im. prof. G. A. Albrechta. P. 34, Leningrad 1935.
20. **Yusevich, M. S. V.:** Ortop. Travm. Protez. 3, 50, 1940.

(Prof. V. N. Blokhin): Teplyi per. 16 (C. I. T. O.) Moskva G 21, U. S. S. R.