ACTA CHIRURGIAE PLASTICAE

INTERNATIONAL JOURNAL
OF PLASTIC SURGERY

III · 2

1961

Acta chir. plast. 3:2:1961

CZECHOSLOVAKIA · PRAGUE · SZDN

Published four times (in 1959: two times) a year by Státní zdravotnické nakladatelství, Malostranské nám. 28, Praha 1. — Adress of the editorial office: Acta chirurgiae plasticae (M. Dobrkovský, M. D. — Secretary) Legerova 63, Praha 2, Czechoslovakia. — Orders through ARTIA, Smečky 30, Praha 2. — Press: Středočeské tiskárny, n. p., provozovna 101, Hálkova 2, Praha 2. — A-08*11320

ACTA CHIRURGIAE PLASTICAE — 3, 2, 1961

New York University School of Medicine, Institute of Reconstructive Plastic Surgery
New York University, Bellevue Medical Center, New York (USA)
Director: Prof. L. D. Bell, M.D.

THE TECHNIQUE OF CONSTRUCTION OF THE AURICLE IN CONGENITAL MICROTIA

J. M. CONVERSE, L. D. BELL

In an earlier paper (Converse, 1958) the techniques for surgical reconstruction of the auricle employed by the author were reviewed. Tanzer, in 1959, described his techniques which introduced considerable refinement in the shaping of the auricular framework and gave a new impulse to this difficult aspect of reconstructive surgery. The techniques at present employed by the author are adaptations of Tanzer's techniques with the additional contribution of a composite graft from the unaffected ear to provide the concha of the reconstructed auricle. Results obtained by these methods will be described in a later report.

The preliminary opening of the middle ear cavity and the construction of an external auditory canal reported in 1958 has been abandoned. Following observations made in a series of 25 patients operated upon in association with Bellucci, it was concluded that this procedure was contraindicated in unilateral microtia if a normal contralateral ear is present for the following two principal reasons: 1. the improvement in audition is not sufficient to warrant the procedure; 2. the inevitable scarring of the skin of the area hampers the subsequent reconstructive surgery.

PLANNING AND PLACING THE NEW AURICLE

Much of the success of the auricular construction depends upon careful preoperative planning. The size, shape and position of the proposed new auricle must be predetermined. The shape of the new auricle is obtained by tracing an outline pattern of the unaffected auricle (Fig. 1a). This outline is traced in ink on a piece of transparent pliofilm placed over the auricle. It is noted that the auricle normally occupies a position below a horizontal line drawn through the upper edge of the eyebrow and behind a vertical line extending upward from the mandibular angle. These landmarks are of assistance when the head is oriented according to the Francfort horizontal. The angle of the mandible may be located

in an abnormal position on the defective side because asymmetry of the mandible is a deformity frequently associated with congenital microtia; this complicating factor must be considered in planning the position of the new auricle on the defective side. The location of the upper border of the new auricle is best determined by comparison with the unaffected ear on full-face examination (Fig. 1c).

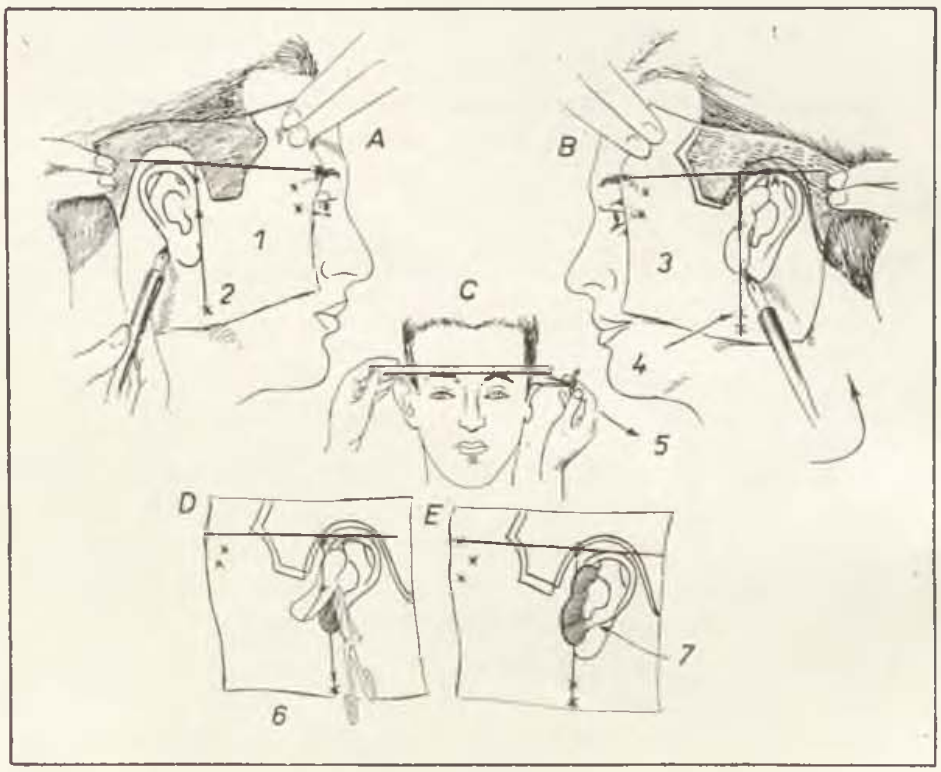

Fig. 1a. A. Tracing the outline of the unaffected auricle on pliofilm. — B. The pliofilm is removed and a tracing is made of the auricular remnants on the defective side. — C. The location of the upper border of the new auricle is obtained by comparing with the unaffected ear on fullface examination. — D. The outline of the auricular remnants is cut-out of the pliofilm. — E. The pliofilm pattern may now be fitted over the remnants which protrude through the cut-out.

A1: Pliofilm. — A2: Angle of jaw. — B3: Reversed pliofilm. — B4: Angle of jaw on defective side. — C5: Transpose measurement to „A" on pliofilm before drawing ear remnant. — D6: Cut out on outline of remnant. — E7: Draw in lower limit of cartilage.

The pliofilm pattern is now placed in position on the defective side (Fig. 1b). The auricular remnants furnish invaluable tissue for the new lobule and should be preserved. The contour of these remnants is outlined on the pliofilm pattern. The area of pliofilm outlined over the remnants is cut through and removed, thus permitting the pattern of the auricle to be placed in the correct position with the auricular remnants protruding through the opening in the pliofilm (Fig. 1d and e). The auricular remnants thus assist in assuring the correct position of the new auricle. The outline of the pattern of the new auricle is cut through (Fig. 1f and g). An additional pattern of the contour of the auricular cartilage is prepared

(pattern no. 2); this second pattern will be employed to outline the costal cartilage graft for the auricular framework.

At operation, pattern no. 1 is placed over the auricular remnants and serves to outline the position of the auricle (Fig. 2). Pattern no. 2 is applied over the area of junction of two adjacent costal cartilages over or in the vicinity of the

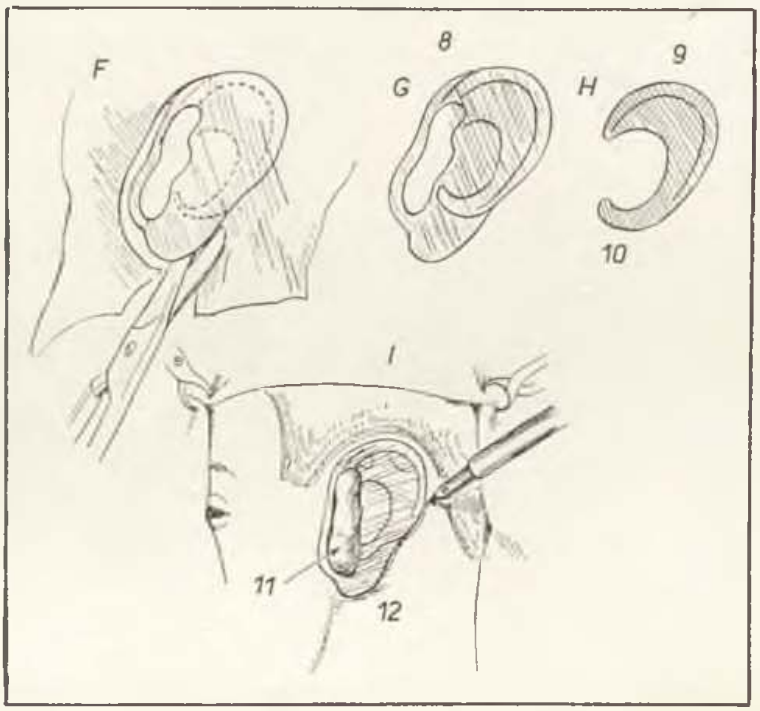

Fig. 1b. F. The outline of the auricular pattern is cut through with scissors. — G. Auricular pattern no. 1 ready for use at operation. — H. Pattern no. 2 representing the contour of the auricular framework. — I. At operation pattern no. 1 is placed over the auricular remnants and an ink outline of the new auricle is traced on the patient's skin.

G8: Pattern No 1 (for position of ear). — H9: Pattern No 2 (for cartilage graft). — H10: Cut patterns of semi-rigid transparent plastic. — I 11: Ear remnant pulled through cutout. — I 12: Pattern No 1.

common cartilage formed by the union of the 8th, 9th and 10th costal cartilages The size of the cartilage graft should be diminished by 3 or 4 millimeters in order to allow for the thickness of the covering skin. The ellipse of cartilage excised from the periphery of the graft serves as the onlay which is applied over and wired to the main graft (Fig. 2b and c), a technique described by Tanzer which is the key to obtaining an adequate helix border. When the costal cartilage is removed from the same side as the defective ear, it is turned inside out to reproduce the outward curvature and inclination of the auricle. The perichondrium of the outer surface then becomes the inner surface and serves as a splint, binding the two adjacent costal cartilages together. The perichondrium of the inner surface, which is the outer surface of the new ear framework, is removed in order to thin the cartilage and carve the depressions which form the characteristic convolutions of the framework.

If the hairline descends too low, an area of scalp is raised as a flap, as practised by Peer (1959) and folded upon itself (Fig. 2, stage 1). The raw area produced by the folding up of the scalp flap is covered by a full-thickness graft of retro-auricular skin removed from the unaffected ear.

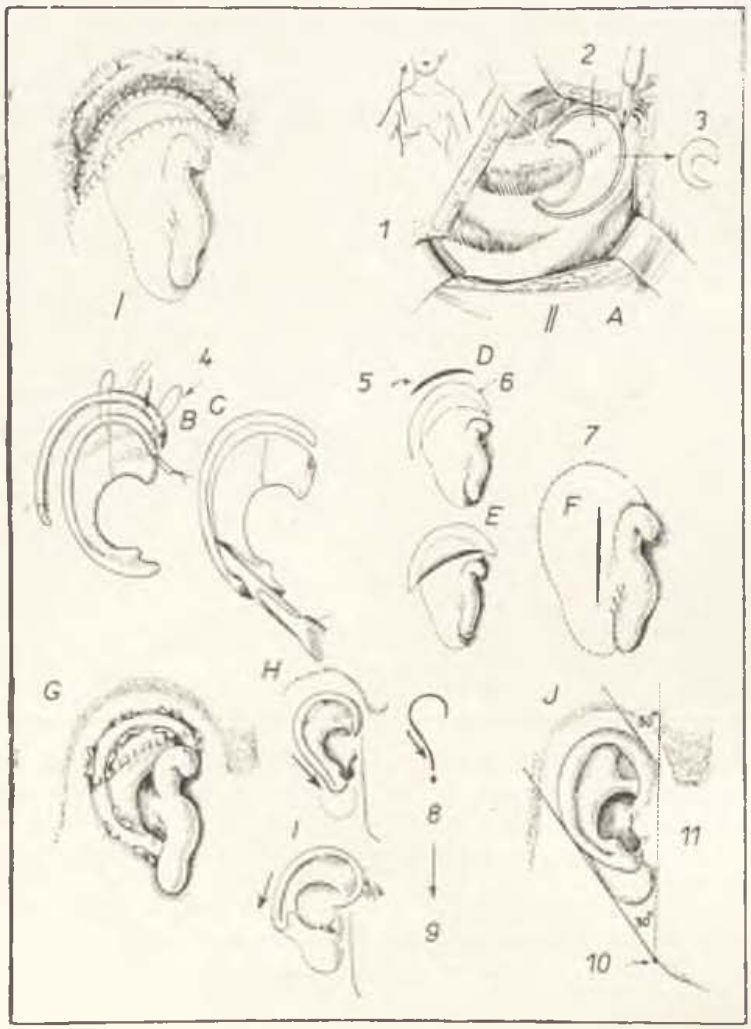

Fig. 2. Stage I. The hairline is moved upward by an upward rolling of the flap upon itself. The remaining defect is covered by a retro-auricular skin graft from the unaffected ear. — Stage II. A. Illustrating the area from which the cartilage graft is removed through the full-thickness of the cartilage. Pattern no. 2 provides the outline of the cartilage graft which is removed, reversed and turned inside-out. — B. and C. Attachment of the cartilage onlay to the cartilage graft by means of fine-calibered stainless steel wire sutures (Tanzer). — D, E and F. Various incisions for the implantation of the cartilage graft. — G. The intimate contact of the skin to the cartilage is provided by a number of vertical mattress sutures bolstered on small pieces of cotton wool (Tanzer). — H, I and J. Illustrating the importance of correct placing of the cartilage graft.

A1: Take cartilage from same side as defective ear. Reverse pattern so that concave surface will become outer surface of ear. — A 2: Pattern No 2. — A 3: Reverse. — B 4: Wire sutures. — D5: Incision above hairline. — D6: Skin graft. — F7: One of the 3 incisions. — H8: Be sure the arm of the questionmark is on an anterior slope. —I 9: Otherwise the ear will be incorrectly placed. — J 10: Angle of mandible. — J 11: Perpendicular.

After a suitable time interval of many weeks, the cartilage for the auricular framework is removed from the area of junction of the 8th, 9th and 10th costal cartilages through a transverse incision placed in a natural skin fold (Fig. 2, stage II, a). The pliofilm pattern is placed, over the surface of the costal cartilages and an ink outline is obtained (Fig. 2, stage II, a). As the transplant is

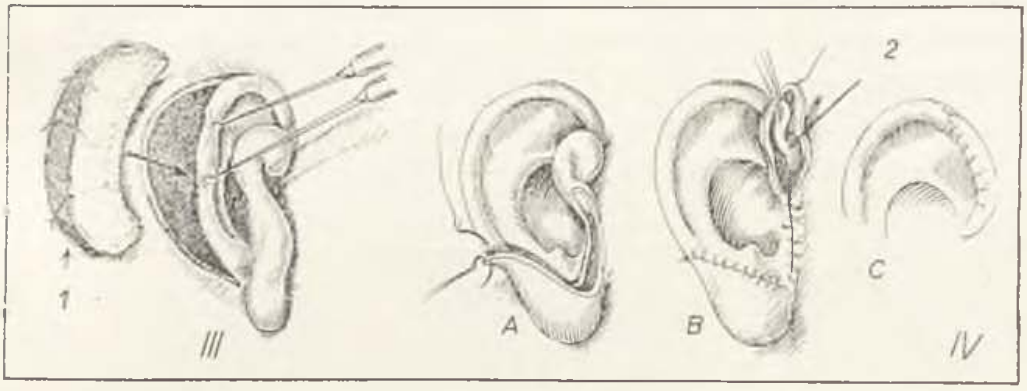

Fig. 3. Stage III. The auricular framework is raised. A split-thickness graft on a dental compound mold is applied to the retroauricular raw area. — Stage IV. A. The lower two thirds of the auricular remnants furnish the lobe of the new auricle. — B. and C. Utilization of the upper one third of the auricular remnants for the anterior position of the helix.

1: Graft over dental compound mold. — 2: Trim and reshape cartilage.

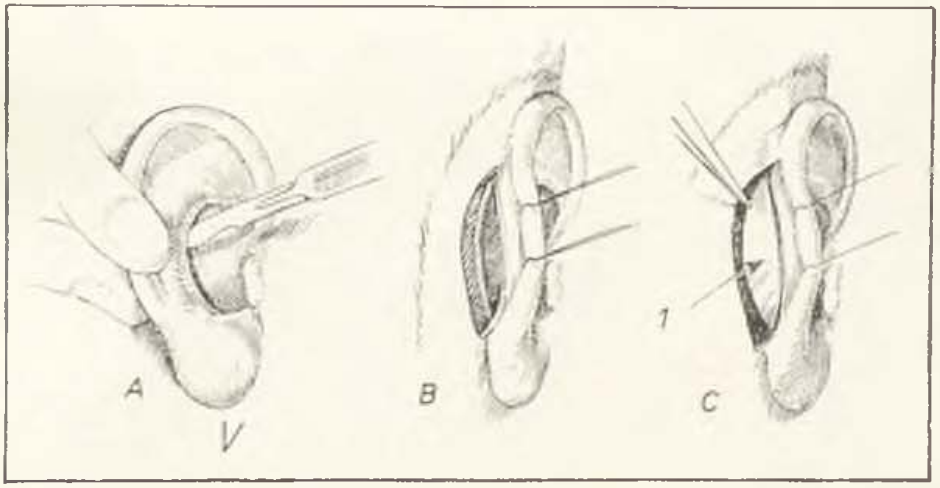

Fig. 4a. The "valise-handle" procedure and composite conchal graft from the unaffected auricle. — A. Incision along the anterior border of the cartilage graft. The incision extends into the retroauricular fold. — B. The reconstructed auricle may now be raised into an adequately protruding position. — C. A soft metal pattern is cut to shape and fitted into the conchal defect. 1: Metal pattern.

removed through the entire thickness of the cartilage, the inner surface of the cartilage must be freed in order that the operator's hand be placed under the cartilage, protecting the pleura. The muscles and pleura are separated extraperichondrially from the cartilage by blunt dissection by means of gauze sponges.

The onlay is obtained from the cartilage at the periphery of the graft from the full-thickness of the cartilage (Fig. 2, stage II, b and c). It is suitably shaped and wired to the lateral aspect of the edge of the auricular framework.

The new auricular framework is implanted in the correct position and the covering skin is adapted to the cartilage by means of vertical mattress sutures bolstered on small pieces of absorbent cotton (Fig. 2, stage II, d, e, f, g). Figures illustrate the precautions to be taken to inset the implant in the correct position (Fig. 2, stage II, h, i, j).

After a time interval of two or three months the auricular framework is raised and the resulting retro-auricular raw area is covered by a split-thickness

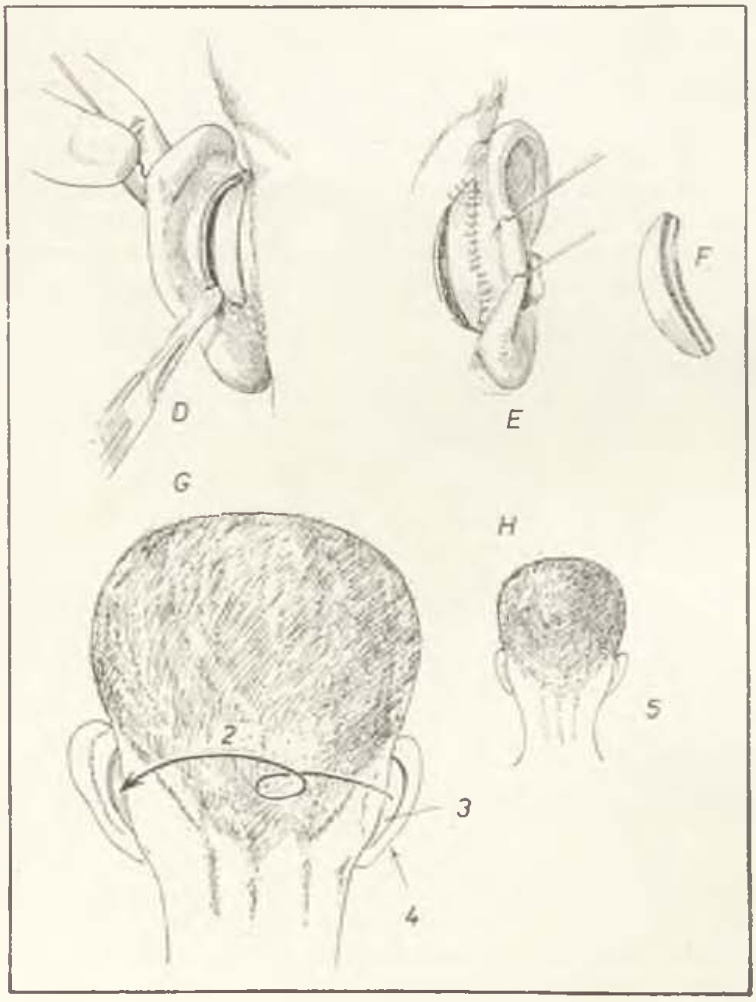

Fig. 4b. D. An outline has been made by tracing an outline of the metal pattern. The composite graft is removed from the full-thickness of the concha. — E. The composite graft is inserted into the conchal defect of the new auricle. — G. Illustrating that the pattern must be turned upside down on the donor ear. In this manner the composite graft will be of the correct shape for the defective auricle. — H. The two auricles now show a symmetrical degree of protrusion.

G2 : Reverse pattern. — G3 : Pattern. — G4 : Reconstructed ear. — H5 : Sides now equalized.

graft removed from the gluteal area, a suitable donor area which avoids scarring of more visible areas in female patients. The dental compound mold technique is usually employed for the fixation of the skin graft (Fig. 3, stage III). It is important that a portion of the upper portion of the auricle remain attached to the cranium to insure fixation of the new auricle and adequate blood supply. In a later stage the auricular remnants are split into two portions, the lower forming the lobe (Fig. 3, stage IV, a), the upper being rotated on itself after

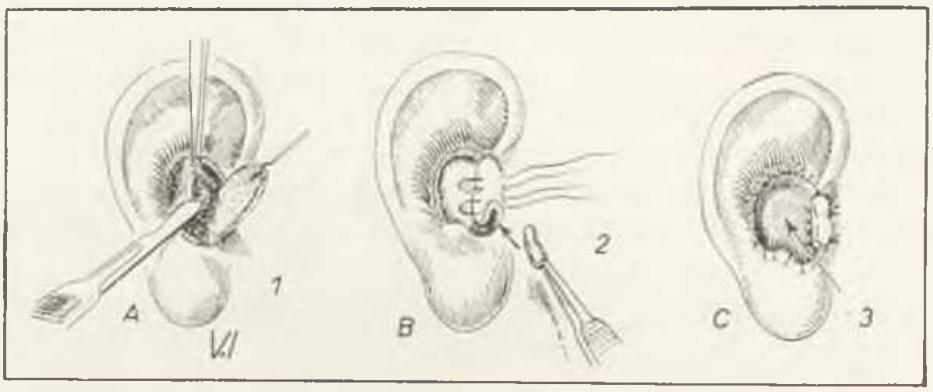

Fig. 5. Stage VI. Construction of the external auditory canal and the tragus. — A. Raising of flap and removal of the subcutaneous tissues. — B. Flap folded on itself over a small cartilage implant. — C. Skin graft applied in the new external auditory canal. The skin graft should extend inward as far as the periosteum over the mastoid bone.

A1: Remove all subcutaneous tissue. — B2: Cartilage implanted beneath flap. — C3: Skin graft.

reshaping or excising the contained cartilage, and joined to the anterior portion of the new helix (Fig. 3, stage IV, b and c). The new auricle has a helix and a lobe but requires a concha, a tragus and a semblance of an external auditory canal. The completion of the auricle is shown in figures 4 and 5 illustrating Stages V an VI; these two stages in the surgical construction of the auricle may be performed in a single stage.

A through and through incision is made along the anterior border of the cartilage implant, extending backward through the skin of the retro-auricular fold (Fig. 4, a and b). The helix may now be raised laterally remaining attached to the cranium above and below. Tanzer (1959) attributes to Kirkham (1940) the conception of this technique. It is referred to in our clinic as the "valise-handle" procedure. The auricle now assumes a position with an adequate degree of protrusion from the side of the head.

The maintenance of the new auricle in this position can be assured by the addition of a composite graft of concha from the unaffected ear (Fig. 4, c, e, f, g, h). In order to obtain a pattern of the conchal graft, a piece of soft metal is cut and shaped to fit the defect (Fig. 4c). The metal pattern is then applied to the concha of the unaffected ear and serves to outline the composite graft. When the composite graft is removed from the donor ear and transferred to the defective ear, the medial edge of the graft becomes lateral and vice-versa. It is necessary, therefore, to place the metal pattern in an upside-down position on

the donor ear in order that the graft, after transfer, will fit the defect as planned (Fig. 4g). The graft is now inserted into the defect and is closely adapted to the edges of the defect by means of close approximation by sutures of the skin edges of graft and defect. This procedure insures the maintenance of an adequate degree of protrusion of the newly constructed auricle; the donor ear is brought closer to the side of the head. An operation for the correction of protruding ears may be required (Converse et al., 1955) to adjust the donor auricle and equalize both auricles.

In the same stage, or in a later stage, the tragus is constructed by means of a flap of skin raised from the area where the external auditory canal should be located and folded upon itself (Fig. 5a and b). The inclusion of a small piece of cartilage will prevent contraction of the skin after folding (Fig. 5b and c). The subcutaneous tissue is excised until the periosteum of the mastoid is reached and a full-thickness retro-auricular skin graft is applied to the area, sutured in position and maintained in the cul-de-sac of the new canal by a dental compound mold. This technique produces a semblance of an external auditory canal.

SUMMARY

The various stages in the construction of a new auricle employed by the author in patients with unilateral congenital microtia are illustrated. A new technique employing a composite graft from the concha of the unaffected auricle for the construction of the concha of the new auricle is described. This technique provides the new auricle with an adequate degree of protrusion.

ВЫВОДЫ

Техника восстановления ушной раковины при врожденной микротии

J. M. Converse, L. D. Bell

Описываются разные этапы восстановления новой ушной раковины применяемой автором у больных с односторонней врожденной микротией. Описывается техника, при которой применяется комплексный трансплантат из ушной раковины здорового уха, предназначенный для создания собственно раковины новой ушной раковины. Данная техника позволяет создать ушную раковину с достаточной степенью выпячиванья.

RÉSUMÉ

La technique de reconstruction du pavillon de l'oreille lors des microties congénitales

J. M. Converse, L. D. Bell

Description des phases successives de la construction d'un pavillon nouveau, utilisées par les auteurs chez des malades atteints d'une microtie congénitale unilatérale. Détails techniques du prélèvement d'un greffon complexe en provénience de la conque de l'oreille saine et devant servir à la construction de la conque du pavillon nouveau. Cette technique permet la formation d'un pavillon présentant un degré de protrusion suffisant.

ZUSAMMENFASSUNG

Die Technik der Rekonstruktion der Ohrmuschel bei kongenitaler Mikrotie

J. M. Converse, L. D. Bell

In der vorliegenden Arbeit werden die verschiedenen Phasen der Konstruktion einer neuen Ohrmuschel beschrieben, wie sie die Verfasser bei Patienten mit einseitiger kongenitaler Mikrotie anwenden. Es wird eine Technik beschrieben, bei der ein komplexes Transplantat aus der Concha des gesunden Ohrs für die Konstruktion der neuen Ohrmuschel verwendet wird. Diese Technik gestattet es, eine Ohrmuschel mit einem hinreichenden Grad von Protrusion zu bilden.

REFERENCES

1. **Converse, J. M.**: Plast. reconstr. Surg. 22 : 150, 230, 1958.
2. **Tanzer, R. C.**: Plast. reconstr. Surg. 23 : 1, 1959.
3. **Peer, L. A.**: Personal Communication 1958.
4. **Kirkham, H. J. D.**: Ann. Surg. 3 : 896, 1940.
5. **Converse, J. M., Nigro, A., Wilson, F. A., Johnson, N.**: Plast. reconstr. Surg. 15 : 411, 1955.

(Prof. J. M. Converse) : 210 East Sixty-Fourth Street, New York 21, N.Y., U.S.A.

Department of Maxillofacial Surgery, Medical Faculty, University of Zagreb (Yugoslavia)
Director: Prof. I. Čupar, M. D.

GROSS AND MICROSCOPIC CHANGES OF SKIN TRANSPLANTS IN THE ORAL CAVITY

I. ČUPAR

The behaviour of skin transplants in a new environment, where they come into contact with tissue of a different structure and into new conditions of life, has been the subject of much clinical and experimental work. In most cases this work actually concerned free skin grafts.

We have studied the behaviour of skin flaps transferred into the mouth in the form of tubed pedicles for the closure of large congenital or acquired defects of the palate.

The observation of such cases through many years showed changes in the skin which we interpreted as accommodation of the skin to the mucous membrane. It therefore seemed natural to undertake histological examination in order to establish what microscopic changes in tissue structure corresponded to the macroscopic changes.

This article presents some clinical observations and histological findings on this subject.

As a rule the first gross changes on the skin surface appear as small or large sharply limited reddish patches which gradually merge into one another so that finally the whole surface of the transplant offers a uniform aspect. The process gives the impression of desquamation of the surface epithelium and, in some places, even of erosion affecting the papillary layer. This might be concluded from the intense red colouring of the surface and from the fact that such areas bleed freely if they are rubbed with a blunt instrument.

The final outcome of the changes shows a characteristic picture: the skin becomes smooth and velvety and its colour reddish so that frequently it cannot be distinguished from the surrounding mucous membrane.

It must be emphasized that the aforesaid changes: (a) never occur immediately but only a few weeks or months after the operation, and (b) they do not occur regularly in each case but we were able to note them in most cases (Fig. 1, 2).

Histological examination established changes covering both the epidermis and the dermis, but we attribute the greatest significance to the changes we found on the surface of the epidermis.

The stratum corneum disappears and a thin layer of flattened cells with flat and pyknotic nuclei appears on the surface instead. This layer is very similar to the parakeratotic layer of the mucous membrane of the mouth. It forms a uniform cover on the deeper layers of epithelium, but in some places it is

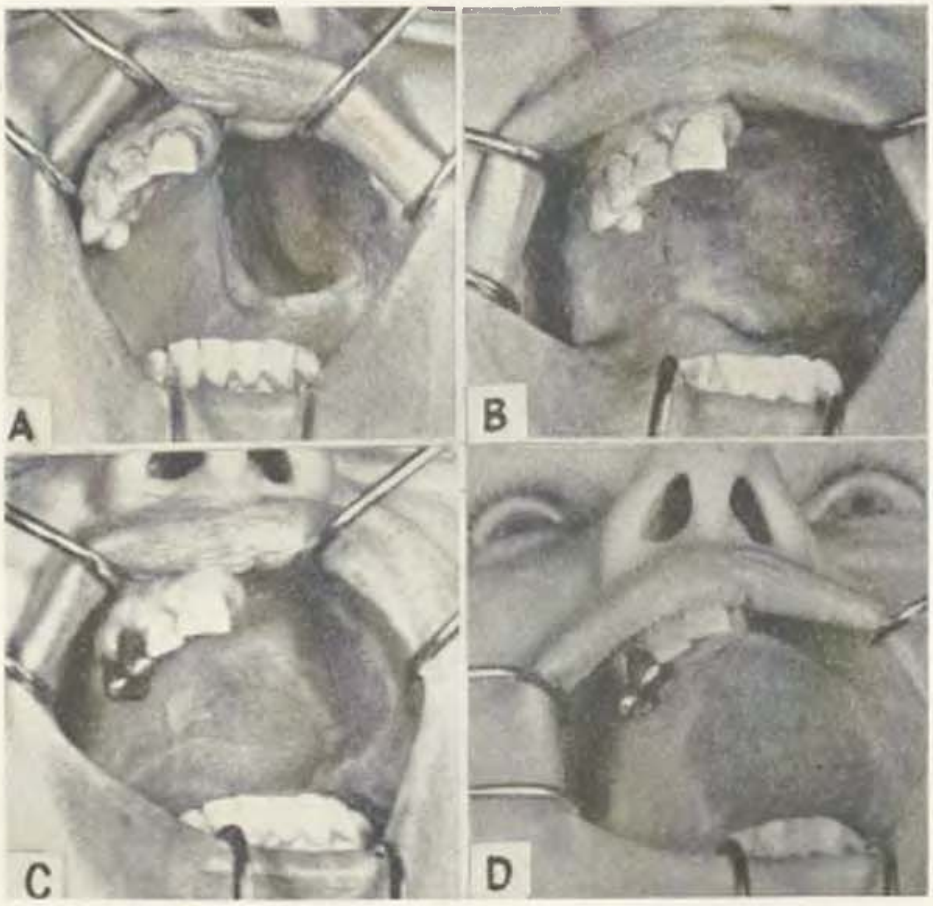

Fig. 1. A. Palatal defect after resection of the maxilla. B. Defect covered with skin. Four months after operation. Reddish patches on the skin surface. C. Two years after operation. Uniform aspect of the surface. D. Eleven years after operation. Velvety surface of intensive red colour.

interrupted in the form of crater-like defects which enter deep into the epidermis. Such craters are filled with a hornified mass (Fig. 3, 4, 5, 6).

It may be concluded that the layer of parakeratotic cells is a newly formed layer while the hornified mass in the defects is a remnant of the lost hornified layer of the skin. It was also established that no granular layer is present wherever the parakeratotic layer has been formed. This finding seems to indicate that the keratohyaline layer, as a preliminary stage of hornification, loses its purpose and disappears from areas in which parakeratosis has set in.

The deeper layers of the epithelium, the stratum spinosum and basale, have in no case shown any changes in tissue structure. Infiltrations were nearly

always found in the dermis, containing polyblasts, plasmacytes, lymphocytes and polymorphonuclear leucocytes (Fig. 7, 8).

With regard to skin appendages the sweat glands showed no degenerative changes and there were no sebaceous glands.

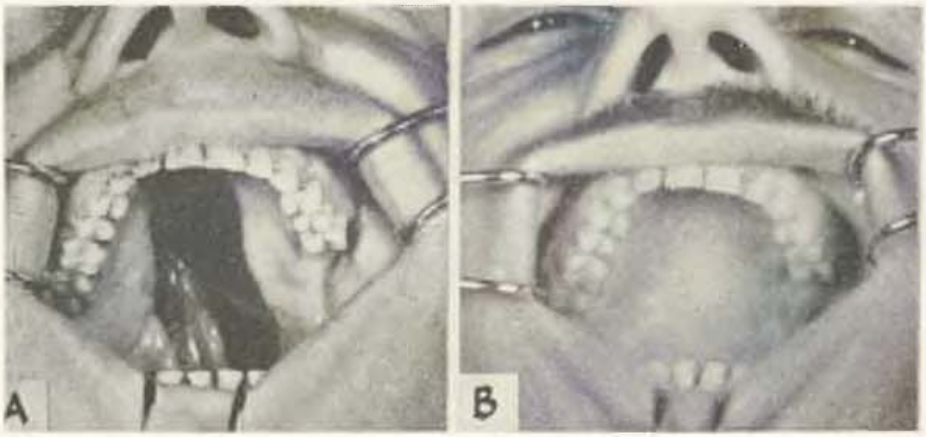

Fig. 2. A. Cleft palate. B. Defect covered with skin. Four years after operation. Skin surface without any changes.

COMMENT

The above mentioned phenomena and changes reflect the changed course of life of the skin. Skin is a foreign body in the mouth. It finds itself under the influence of mechanical, physical, chemical and bacterio-toxic factors forming the complex of new conditions of life. Together they act as a constant stimulus and, since the skin is not adapted, a reaction develops in the tissue.

The changes on the surface of the epidermis can primarily be explained as damaged skin entailing the disappearance of the stratum corneum. This is followed by a regenerative process, which, under the influence of conditions of life new to the skin, turns the differentiation of cells in another direction, resulting in a new structure. We think that this process must be considered as indirect metaplasia, because the causes and the effect of such a change of the elements of tissue correspond to this notion from the viewpoint of pathological morphology.

No changes in the sense of the transformation of tissue were found in the deeper layers of epithelium, but it should be kept in mind that the structure of these layers shows no essential difference between skin and mucous membrane of the mouth and therefore changes of that kind should not be expected.

Infiltrations in the dermis are a sign of more intense work of stroma with a view to balancing out the changed metabolism. According to its elements and its function, the histological substrate represents a reactive inflammation entirely identical to the one found in the mucous membrane of the mouth in the course of physiological resorptive processes and in various irritative conditions. The skin which in the mouth loses its protective covering layer is greatly

exposed to the influence of various irritants. Thus, inflammatory infiltrations in the dermis may prove an example for the similarity of life processes between the mucous membrane and the skin in the mouth.

One last question may be asked: why cannot the changes described be established in each case? It is difficult to give a precise answer. One can only say that much depends on the individual resistance of the skin.

SUMMARY

The paper refers to the behaviour of the skin which was transplanted into the mouth for covering large defects of the palate.

The changes in the skin surface, which becomes reddish like mucous membrane, are explained as an adaptation of the skin to the new environment. Histological findings show structural changes in the superficial layer of the epidermis which are interpreted as indirect metaplasia.

ВЫВОДЫ

Макроскопические и микроскопические изменения кожных трансплантатов в полости рта

I. Čupar

В работе разобрано поведение кожи, пересаженной в полость рта с целью закрытия крупных дефектов неба. Изменения поверхности кожи, которая становится похожей на красноватую слизистую оболочку, объясняются приспособлением кожи к новым условиям. Данные гистологического исследования указывают на структурные изменения в поверхностных слоях эпидермиса, которые считаются непрямой метаплазией.

RÉSUMÉ

Changements macroscopiques et microscopiques des greffons cutanés de la cavité buccale

I. Čupar

Le travail s'occupe du comportement de la peau greffée dans la cavité buccale pour couvrir des défectuosités importantes du palais. Les transformations de la surface de la peau, qui prend un aspect semblable à la membrane rougeâtre de la muqueuse, sont expliquées comme étant des manifestations d'adaptation de la peau aux conditions nouvelles. Les données histologiques montrent des changements de structure des couches superficielles de l'épiderme, considérés comme métaplasie indirecte.

ZUSAMMENFASSUNG

Makroskopische und mikroskopische Veränderungen von Hauttransplantaten in der Mundhöhle

I. Čupar

Die vorliegende Arbeit behandelt das Verhalten von Hauttransplantaten, die in die Mundhöhle zur Deckung grosser Gaumendefekte übertragen worden waren. Die Veränderungen der Hautoberfläche, die Aehnlichkeit mit einer rötlichen Schleimhautmem-

bran annimt, werden als Anpassung der Haut unter neuen Bedingungen aufgefasst. Histologische Befunde weisen auf strukturelle Veränderungen in den oberflächlichen Epidermisschichten hin, die als eine indirekte Metaplasie angesehen werden.

REFERENCES

1. **Brown, J. B., McDowell, F.**: Ann. Surg. 115 : 1166, 1942.
2. **Čupar, I.**: Rad. Jugosl. Akad. knj. 307, 1955.
3. **Horton, C. et al.**: Plast. reconstr. Surg. 12 : 269, 1953.
4. **Peer, L. A.**: Transplantation of Tissues. Vol. II. The Williams and Wilkins Co, Baltimore 1959.
5. **Peer, L. A., Paddock, R.**: Arch. Surg. 34 : 268, 1937.
6. **Rehn, E.**: Verhandl. anat. Gessellsch. 72 : 133, 1931.
7. **Siegmund, H., Weber, R.**: Patholog. Histologie d. Mundhöhle. S. Hirzel Verlag, Leipzig 1926.
8. **Weinmann, J. P.**: J. dent. Res. 19 : 57, 1940.

Delivered at the International Symposium of Plastic Surgery in Mariánské Lázně (Czechoslovakia), June 28, 1960.

(Prof. Dr. I. Čupar): Amruševa 19, Zagreb, Yugoslavia

Universitäts-Klinik für Gesichts- und Halschirurgie der Medizinischen Fakultät (Charité)
Berlin (DDR)
Direktor: Prof. Dr. med. habil. Dr. H. Mennig

SPÄTERGEBNISSE AUSGEDEHNTER SCHLUNDPLASTIKEN MIT RUNDSTIELLAPPEN

H. MENNIG

In meiner Monographie „Plastische Deckung grosser Lücken des Schlundes und der Speiseröhre durch Rundstiellappen" konnte ich über 9 Kranke berichten, die bis zum Jahre 1953 operiert worden waren; später habe ich noch zwei weitere Kranke mit Pharyngostoma als Folge ausgedehnter Tumoroperation nach demselben Verfahren operiert, die Operationsergebnisse waren gleich gut. Zur Zeit untersuche ich, welche Spätergebnisse dieses Operationsverfahren gezeitigt hat, und ich kann heute in einer ersten vorläufigen Mitteilung darüber berichten. Da auch im Schrifttum meines Wissens nichts über Spätergebnisse nach solchen ausgedehnten Schlundplastiken veröffentlicht worden ist, dürfte selbst ein vorläufiger Bericht vielseitiges Interesse beanspruchen; eine nachfolgende Veröffentlichung über Schicksal und Spätergebnis meiner sämtlichen Fälle ausgedehnter Schlundplastiken mit Rundstiellappen bleibt vorbehalten.

Bei diesen Untersuchungen kommt es mir darauf an festzustellen, inwieweit die damals erzielten guten Erfolge bis heute Bestand hatten oder welche Befundänderungen im Laufe der Zeit eingetreten sind. Da die erste Plastik dieser Art von mir bereits im Jahre 1946 vollendet wurde, ergeben sich im Durchschnitt langjährige Berichtszeiträume, soweit die Kranken noch leben oder für die Nachuntersuchung erreichbar waren; in einigen Fällen werde ich bei der späteren zusammenfassenden Berichterstattung allerdings nur auf schriftliche Mitteilungen der Patienten zurückgreifen können.

Als ich mich seit 1945 auf Anregung meines Lehrers *Zange* mit dem Problem der plastischen Deckung grosser Schlundlücken zu beschäftigen begann, galt es vornehmlich drei Forderungen zu erfüllen, um das schwere Schicksal der Kranken mit ausgedehnten Pharyngostoma zu erleichtern:

1. die Wiederherstellung der Schluckfunktion,
2. die Verschaffung einer brauchbaren Ersatzstimme und
3. die Herstellung eines guten äusseren Aussehens.

In Zusammenfassung meiner damaligen Erfahrungen kam ich 1954 zu der Schlussfolgerung: In jedem unserer Fälle erzielten wir ein funktionell und kosmetisch einwandfreies Ergebnis, Wiederherstellung der Schluckfunktion, Ver-

besserung oder Erwerb der Pharynxsprache, gutes Aussehen im ehemaligen Fistelgebiet und gefällige Form des Halses. Nach der Plastik erholen sich die Kranken schnell und leben besonders auch seelisch wieder auf. Soweit das Alter es zulässt, nehmen sie ihre frühere Beschäftigung in vollem Umfange wieder auf.

Abb. 1. Große breite Schlundlücke in der Mitte des Halses unten. Zustand nach Totalexstirpation des Kehlkopfes bei vorausgegangener Röntgenbestrahlung wegen Kehlkopfeingangskarzinom (Fall P.).

An zwei Beispielen der bisher nachuntersuchten Kranken will ich nun über die Spätergebnisse ausgedehnter Schlundplastiken berichten und zwar unter den drei Gesichtspunkten der Schluckfunktion, der Sprache und der Kosmetik.

1. DIE SCHLUCKFUNKTION

Ohne Zweifel bedeutet die Wiederherstellung der Schluckfunktion durch den plastischen Aufbau des Schlundrohres für den Kranken eine entscheidende Wendung seines bedauernswerten Zustandes: Die natürliche Nahrungsaufnahme und der Fortfall des abnormen Speichelabflusses bewirken körperliche Erholung und Gewichtszunahme und machen dem Kranken die Rückkehr in die häusliche Gemeinschaft und in eine geregelte Berufstätigkeit möglich.

An dieser Stelle soll auszugsweise die Krankengeschichte der beiden Kranken wiedergegeben werden.

Fall P.: 1946 Röntgenbestrahlung eines Kehlkopfeingangscarzinoms bei einem 54jährigen Patienten. 7 Monate nach der Bestrahlung musste wegen eines Ortsrezidivs und Lymphknotenmetastasen die Totalexstirpation des Kehlkopfes mit Lymphknotenausräumung vorgenommen werden. Die Ausheilung

Fig. 3. Synoptical picture of the skin. Hypertrophya of epidermis. On the surface parakeratosis and a crater-like defect in the epidermis. Inflammatory infiltration in the dermis. × 28.

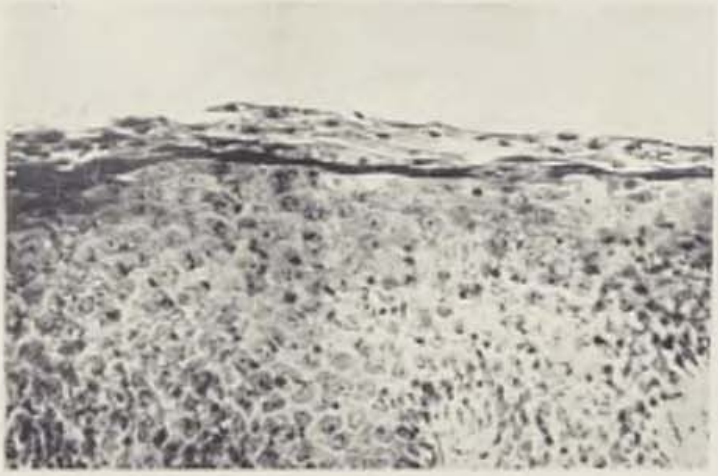

Fig. 4. Newly formed parakeratotic layer on the surface. No granular layer. × 190.

Fig. 5. Eroded part of the surface. Str. spinosum without cover layer. × 100.

Fig. 6. Crater-like defect in the epidermis filled with hornified mass. × 190.

Fig. 7. Inflammatory infiltrations in the dermis. × 100.

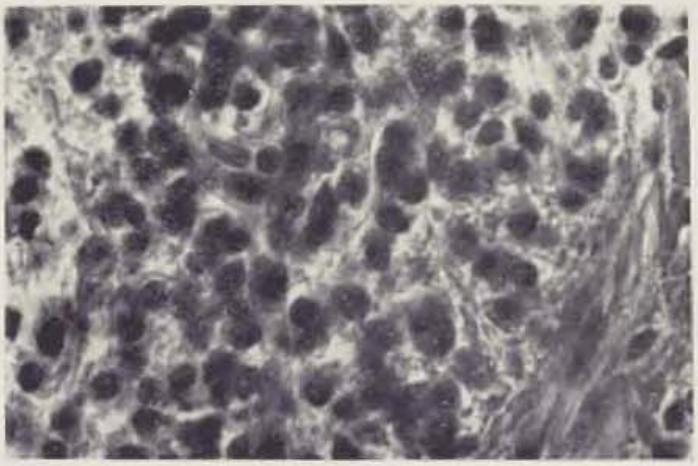

Fig. 8. Cellular elements from the inflammatory infiltration. × 620.

BEHAVIOUR AND FATE OF CONSERVED HOMOGENOUS ARTICULAR CARTILAGE UNDER EXPERIMENTAL CONDITIONS

Fig. 1.

Fig. 2.

Fig. 3.

Fig. 1. H-72711. Cartilaginous head with subcartilaginous bone conserved in F ½ for 10 days two years after transplantation. The union of the implanted bone (upper half of the picture) with the base (lower half) appears as a thin, irregular, black line crossing the centre of the picture horizontally. Haem-eos (150×). — Fig. 2. H-64182. Cartilage disk with a bony lamella conserved in paraffin oil for 14 days. Three months after transplantation. Chondrocytes show preserved structure, nuclei are slightly pyknotic. Only a narrow strip on the surface shows necrosis. Haem-eos. (150×). — Fig. 3. H-64379. Cartilage disk with subcartilaginous bone preserved in paraffin oil for 28 days, four and a half months after transplantation. Superficial layer of necrosis is wider, number of cells in the cartilage is smaller, on the border between the necrotic and viable layers are clusters of larger chondrocytes. On the right of the picture there is a focus of cartilaginous tissue lying within the bone marrow. Haem-eos. (100×).

Fig. 4.

Fig. 5.

Fig. 4. H-64782. Cartilaginous head with subcartilaginous bone conserved in F ½ for 10 days, eight months after transplantation. On the surface there is a narrow layer of necrotic cartilage lying next to multicellular clusters of chondrocytes. Haem-eos. (130×). — Fig. 5. H-72711. Cartilaginous head with subcartilaginous bone conserved in F ½ for 10 days twenty-four months after transplantation. On the surface there is only a very narrow layer of necrotic cartilage with clusters of chondrocytes. Haem-eos. (150×).

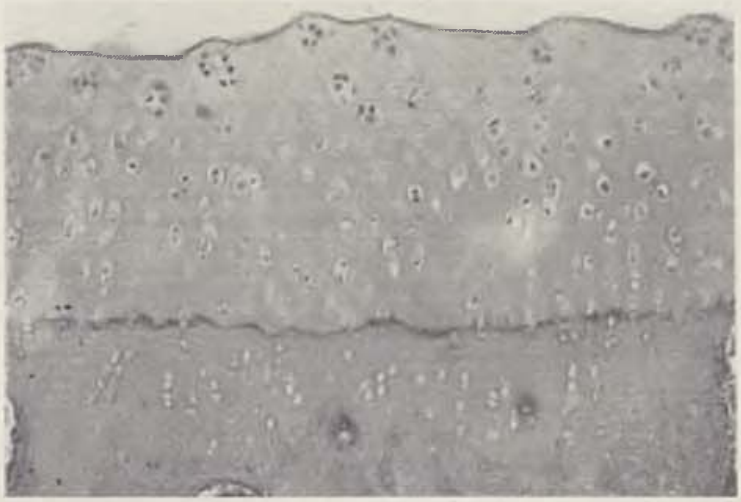

Fig. 6. Cartilage disk with bony lamella conserved in paraffin oil for 14 days fourteen months after transplantation. Number of cells on the cartilage surface is smaller. There are quite numerous optically empty sites remaining from chondrocytes. Near the surface clusters of chondrocytes can be seen.

erfolgte nach einer schweren Wundinfektion unter Ausbildung einer grossen breiten Schlundlücke in der Mitte des Halses. Das Körpergewicht des Kranken, wie ihn Abb. 1 darstellt, betrug damals knapp 40 kg.

1947/48 wurde die Schlundplastik mit einem linksseitigen Flankenlappen, der über den linken Oberarm an den Defekt herangebracht worden war, erfolg-

Abb. 2.

Abb. 3.

Abb. 2, 3. Röntgenkontrastdarstellung des Schluckaktes 12 Jahre nach der Schlundplastik (Fall P.).

reich durchgeführt. Nach Abheilung des Wundgebietes und Entfernung des Magenschlauches war die Nahrungsaufnahme sofort wieder in natürlicher Weise ungehindert möglich.

Bei der Nachuntersuchung 1960, also 12 Jahre nach der Schlundplastik, ergab die Röntgenuntersuchung des Schluckaktes mit Kontrastmittel folgenden Befund: In regelrechtem Schluckakt geht das Kontrastmittel glatt durch den Schlund und durch die Speiseröhre. Oberhalb des Plastikgebietes kommt es zu einem kurzen Verweilen in dem mässig erweiterten Pharynx. Unterhalb dieses Erweiterung, also im ehemaligen Plastikgebiet selbst, zeigt die Speiseröhre etwa blei-

stiftstarkes Lumen und erweitert sich nach kaudal allmählich zu normaler Weite. Es finden sich überall glatte Wandkonturen und zarte Schleimhautfalten (Abb. 2 und 3). Das Körpergewicht beträgt jetzt 100 kg!

Fall T.: Bei der damals 45 Jahre alten Kranken musste wegen eines Tumorrezidivs mit Ummauerung des Ösophaguseinganges — bei vorbehandeltem Kehlkopfkarzinom — 1952 die Totalexstirpation des Kehlkopfes und quere Resektion

Abb. 4.

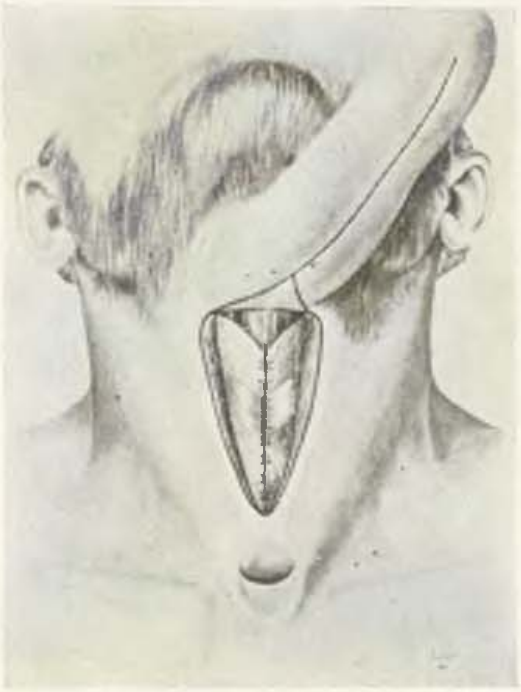

Abb. 5.

Abb. 4. Zustand nach Totalexstirpation des Kehlkopfes mit querer Resektion des Pharynx und Anfangsteiles des Oesophagus bei vorbehandeltem Karzinom des Kehlkopfes. Der Oesophaguseingang liegt ungewöhnlich tief im Tracheostoma (Fall T.). — Abb. 5. Schematische Operationsskizze zur Innendeckung eines Pharynxdefektes mit Darstellung des in Zusammenhang präparierten Resten des M. constrictor pharingis bds.

des Pharynx und Anfangsteiles des Oesophagus durchgeführt werden. Nach Abheilung bestand ein weites Pharyngostoma oben, das Oesophagostoma lag tief im Tracheostoma (Abb. 4). Infolgedessen war die Nahrungsaufnahme sehr schwierig; auch durch eine Kunststoffprothese mit weich-elastischem Plastupalatansatz konnten die Schwierigkeiten nicht beseitigt werden.

Erst die Rollappenplastik zum Wiederaufbau des Schlundrohres in ganzer Ausdehnung ermöglichte eine normale und ausreichende Nahrungsaufnahme. Die Plastik wurde mit einem Rundstiel aus der rechten Flanke durchgeführt, der über den rechten Oberarm an den Oberrand des Defektes verpflanzt wurde.

6 Jahre nach der Plastik wurde die Patientin nachuntersucht, es konnte aus technischen Gründen keine Röntgenuntersuchung durchgeführt werden. Die Kranke gab aber an, dass sie alle Speisen ohne Einschränkung glatt und unbe-

hindert essen kann. Sie hat auch kein Regurgitieren. Ihr Ernährungs- und Kräftezustand ist sehr gut.

Beide Kranke zeigen 6 bzw. 12 Jahre nach ausgedehnter Schlundplastik normale Nahrungsaufnahme; in einem Falle (Patient P.) konnte der einwandfreie Schluckakt röntgenologisch durch Kontrastmittelpassage bestätigt werden. In beiden Fällen ist der Ernährungszustand ausgezeichnet.

Abb. 6.

Abb. 7.

Abb. 6. Der Kranke von Abbildung 1 nach Abschluß der plastischen Behandlung (Fall P.). — Abb. 7. Das kosmetische Ergebnis der Plastik bei dem gleichen Kranken nach zwölf Jahren (Fall P.).

An dieser Stelle sei noch eine operationstechnische Bemerkung erlaubt. Für die Funktion des Schluckaktes nach Großplastiken im Pharynxbereich erscheint uns die teilweise Wiederherstellung des muskulären Schlundringes besonders wichtig. Durch vorsichtiges Präparieren bei der Bildung der Plastiklappen für die Innendeckung ist es oft möglich, die noch vorhandenen Reste des M. constrictor pharyngis im Zusammenhang mit den Innenlappen darzustellen und sie in der Mittellinie zu vereinigen (Abb. 5).

2. DIE SPRACHE

Ebenso wichtig wie die Wiederherstellung des normalen Schluckaktes bei großen Pharynxdefekten nach Exstirpation des Kehlkopfes ist die Verschaffung einer brauchbaren Ersatzstimme (Pharynxsprache). Denn der Erwerb einer guten Pharynxstimme macht den Kranken erst wieder voll berufs- und gesell-

schaftsfähig, stärkt sein Selbstbewußtsein ganz wesentlich, macht ihn sicher im Umgang mit seinen Mitmenschen und im öffentlichen Leben und hebt seine Daseinsfreude. Aber erst durch die plastische Deckung der Schlundlücke und den Wiederaufbau des Schlundrohres ist der Erwerb einer guten Pharynxsprache oder

Abb. 8. Die Kranke von Abbildung 4 unmittelbar nach Abschluß der Plastik (Fall T.).

die Verbesserung einer vorhandenen Ersatzstimme möglich. Allerdings hängt das Ergebnis des Sprechenlernens von dem Willen der Kranken ab, nicht alle benötigten einen systematischen Sprachunterricht; die soziale Lage kann dabei auch eine Rolle spielen. Unter günstigen Bedingungen psychologischer und sozialer Art sind die Spätergebnisse ausgedehnter Schlundplastiken bezüglich der Sprechfunktion als sehr gut und dauerhaft zu bezeichnen.

Das zeigten alle unsere Kranken schon bald nach der Plastik, in einigen Fällen nahmen sie nach Vollendung der plastischen Behandlung systematischen Sprachunterricht zum Erlernen der Pharynxstimme.

Bei der Nachuntersuchung des einen Kranken (Fall P.) nach 12 Jahren, war eine gute Verständigung möglich; er hatte nach der plastischen Wiederherstellung Sprachunterricht genommen. Hingegen benutzte die Kranke (Fall T.) auch 6 Jahre nach der Operation nur eine bucco-labiale Pseudostimme; zu regelrechtem Unterricht im Sprechen hatte sie infolge ihrer sozialen Lage keine Zeit.

Die Spätergebnisse der Schlundplastiken im Hinblick auf die Sprechfunktion sind also unter dem Gesichtspunkt als sehr günstig zu bezeichnen, daß durch die Plastik die Voraussetzungen zum Erwerb der Pharynxsprache oder zur Verbesserung einer vorhandenen Ersatzstimme geschaffen sind.

3. KOSMETIK

Bei dem von mir ausgearbeiteten Vorgehen zur plastischen Deckung großer Lücken des Schlundes kam es auch darauf an, ein denkbar gutes kosmetisches Ergebnis zu erzielen. Neben einem guten Aussehen im ehemaligen Fistelgebiet

Abb. 9. Das kosmetische Ergebnis der Plastik bei der gleichen Kranken nach sechs Jahren (Fall T.).

und einer gefälligen Form der Halspartien sollen durch die Plastik auch auffällige Narben und sichtbare Bestrahlungsveränderungen der Haut soweit beseitigt werden, als es die Sicherheit des Erfolges der Plastik zuläßt; es wird aber auch durch die Rundstielmethode das Entstehen neuer Narben im Bereich des Halses vermieden.

Vergleicht man nun das Ergebnis ausgedehnter Schlundplastiken in kosmetischer Hinsicht kurz nach Abschluß der plastischen Behandlung und viele Jahre später, so zeigt sich, daß die Spätergebnisse durchaus günstig sind. In beiden Fällen ist das zunächst erzielte kosmetische Ergebnis auf Dauer erhalten geblieben, in dem einen Falle trat durch weitgehende Angleichung der Plastikhaut in Dicke, Elastizität und Farbe zur Umgebung der denkbar beste Erfolg ein. Die Abbildungen 6 und 7 stellen 2 Befunde mit einem zeitlichen Intervall von 12 Jahren gegenüber. Das kosmetische Ergebnis nach dieser Zeit ist durch optimale Anpassung sehr gut und im Vergleich zur früheren Aufnahme weiter verbessert (Fall P.). Ähnlich günstig war ein Vergleich des Befundes bei einer Kranken (Fall T.) nach Abschluß der plastischen Behandlung (Abb. 8) mit dem Spätergebnis nach 6 Jahren (Abb. 9).

Alles in allem kann schon aufgrund der Nachuntersuchung von zwei Kranken nach 6 bzw. 12 Jahren gesagt werden, daß die bei ausgedehnten Schlundplastiken mit Rundstiellappen erzielten Ergebnisse auf die Dauer anhalten, und zwar sowohl im Hinblick auf den Schluckakt und die Sprechfunktion als auch für die

Kosmetik. Diese Feststellung ist umso erfreulicher, als Lage, Größe und Besonderheiten der ausgedehnten Schlunddefekte bei nachteiliger Narbenbildung nicht ohne weiteres so günstige Ergebnisse auf die Dauer erwarten lassen konnten, zumal die Plastiken z. T. bei älteren Menschen und nach intensiver Röntgenbestrahlung ausgeführt wurden. Das unterstreicht sehr nachdrücklich den besonderen Wert dieses Vorgehens, wie inzwischen von vielen Autoren bestätigt wurde.

Abschließend muß noch auf die soziale Bedeutung der Wiederherstellung solcher Kranken hingewiessen werden. Bald nach Beendigung der plastischen Operationen können die Kranken ihre frühere Beschäftigung in vollem Umfange wieder aufnehmen, soweit das Alter es zuläßt. Der Kranke (Fall P.) hat in den verflossenen 12 Jahren einen großen Gartenbaubetrieb bewirtschaftet, die Kranke (Fall T.) hat als alleinstehende Frau 3 Kinder großgezogen.

Es ist zu erwarten, daß die Nachuntersuchung der anderen Kranken ebenso günstige Spätergebnisse bringt; darüber soll in einer späteren Mitteilung im Zusammenhang berichtet werden.

ZUSAMMENFASSUNG

Das Schrifttum enthält noch keine Veröffentlichungen über Spätergebnisse nach ausgedehnten Schlundplastiken durch Rundstiellappen. Aus einer Reihe von Nachuntersuchungen wird über 2 Fälle berichtet, die vor 6 bzw. 12 Jahren vom Verf. operiert wurden. Die Ergebnisse werden unter den 3 Gesichtspunkten der Schluckfunktion, der Sprache und der Kosmetik erörtert. In beiden Fällen war der Schluckakt nach der Plastik bis jetzt ohne Störungen, auch röntgenologisch konnte in dem einen Fall durch Kontrastbrei-Passage eine glatte Schluckfunktion dargestellt werden. Auch die Sprechfunktion ist nach ausgedehnten Schlundplastiken auf die Dauer gut, wenn die Kranken die Pharynxsprache erlernen. Hinzu kommt noch ein gutes Aussehen im ehemaligen Fistelgebiet, das im Laufe der Jahre durch weitgehende Angleichung der Plastikhaut in Dicke, Elastizität und Farbe denkbar günstig ist. Eine spätere ausführliche Mitteilung über die Spätergebnisse bei weiteren Fällen ausgedehnter Schlundplastiken mit Rundstiellappen wird angekündigt.

ВЫВОДЫ

Поздние результаты обширной пластики пищевода при помощи стебельчатого лоскута

H. Mennig

В литературе до сих пор нет никаких сообщений о поздних результатах обширной пластики пищевода при помощи стебельчатого лоскута. На основании ряда дополнительных исследований автор докладывает о двух больных, которых он оперировал 6 и 12 лет тому назад. Результаты операции автор оценивает с трех точек зрения, а именно с точек зрения глотания, речи и косметического эффекта. Глотание у обоих оперированных совершается со времени произведенной пластики и до сегодняшнего дня беспрепятственно; у одного больного удалось рентгенологическим путем при помощи контрастного вещества наглядно представить гладкость глотания. Также речь после обширной пластики является

хорошей, поскольку больные освоили пищеводный голос. Все это дополняется еще хорошим видом в месте бывшего свища, который с течением времени, благодаря широкому приспособлению кожной пластики в отношении толщины кожи, эластичности и цвета, стал мыслимо благоприятным. Автор обещает опубликовать позже подробное сообщение о дальнейших поздних результатах обширной пластики пищевода при помощи стебельчатого лоскута.

SUMMARY

The Late Results of Extensive Oesophageal Plastics Using Tubed Flaps

H. Mennig

There is no report of the late results of extensive oesophageal plastics with tubed flaps in the literature. From a series of follow-up examinations the author refers to two cases which he operated on six and twelve years previously. He evaluates the results from three points of view, i. e. with regard to swallowing, to speech and to the cosmetic effect. In both cases swallowing has caused no difficulty from the time of the operation; in one case it was possible to demonstrate normal swallowing by X-ray with a contrast material. Speech is also quite good after extensive plastic operations providing the patients have mastered the technique of pharyngeal articulation. Added to this is a good appearance of the site of the former fistula which, due to the far-reaching adaptation of the transplanted skin with regard to its thickness, elasticity and colour, is as favourable as can be expected. Further detailed reports on other late results of extensive oesophageal plastics with tubed flaps will be published.

RÉSUMÉ

Résultats tardifs des greffes oesophagiennes importantes en lambeau cylindrique

H. Mennig

Nous ne disposons pas, à l'heure actuelle, d'indications littéraires en ce qui concerne les résultats tardifs après greffe en lambeau cylindrique oesophagienne de grande étendue. L'auteur présente deux cas, choisis d'une série d'observations post-opératoires faites sur des malades qu'il avait opérés 6 resp. 12 ans auparavant. Pour l'appréciation des résultats, l'auteur se sert de trois critériums: la faculté de déglutition, l'articulation et le résultat cosmétique. Dans les deux cas, les malades sont capables de déglutir sans difficultés, depuis l'opération jusqu'à l'heure actuelle, et dans un cas on a pu mettre en évidence, par radioscopie à l'aide de substance à contraste, que la déglutition s'opère sans obstacle. L'articulation elle-aussi est bonne, dans la mésure que le malade était capable d'apprendre à articuler par voie pharyngienne. Il s'y ajoute une bonne apparence de l'endroit de l'ancienne fistule, étant donné que le greffon dermique s'est bien adapté, au cours des années, quant à son épaisseur, son élasticité et sa couleur. L'auteur annonce une communication ultérieure plus détaillée au sujet des greffes oesophagiennes de grande étendue par greffe en lambeau cylindrique.

SCHRIFTTUM

1. **Mennig, H.:** Plastische Deckung großer Lücken des Schlundes und der Speiseröhre durch Rundstiellappen, Verlag Volk und Gesundheit, Berlin 1954.

(Prof. Dr. H. Mennig): Philippstrasse 21, Berlin N 4, DDR

Plastic Unit, University Surgical Clinic, Ljubljana (Yugoslavia)
Director: Prof. Dr. B. Lavrič

THE CLINICAL SIGNIFICANCE OF A BIOLOGICAL ASSESSMENT OF THE DEPTH OF BURNS

M. DERGANC

From the time when burns were recognized as a surgical problem, many new aspects of their general and local treatment have arisen.

One of the most outstanding and unsolved questions concerns the early and reliable assessment of the depth of the necrosis in the burned skin.

Essentially, the problem consists of answering the following question:

Did the deep layer of the dermis with its viable epithelial elements survive at the moment of burning?

Clinical observations on this topic might be of course of the greatest help, as Sir Henry Wade said: "The wards are the greatest of all research laboratories".

Our clinical examinations of more than 300 burns in the wards, dressing-room and in the theatre made it possible even in 1953 to see clearly the insufficiency and unadequacy of the contemporary methods designed to assess exactly the depth of burns.

Between the classical second and third degree — or between the modern superficial and deep burns respectively — we felt the existence of a gap.

We therefore introduced a subdivision of the second degree of:

superficial (2A) and deep (2B) second degree.

The 2nd. b degree was found to be of especial importance in our clinical work.

The surgical aspect of burns led some of the British surgeons to use the term "deep dermal burn", which corresponds to our "2b" degree. Wallace (1955) defined the "deep dermal burn" as a special type of burn.

MORPHOLOGICAL CHARACTERISTICS AND DIFFERENCES BETWEEN THE 2A AND 2B DEGREE

THE 2A DEGREE

The borderline between the dead and viable tissue is roughly represented by the papillary zone of the dermis (stratum papillare). The interpapillary parts of the deep layer of dermis, i. e. the stratum germinativum are preserved and in 10—14 days the whole epidermis is regenerated ad integrum, macro- and microscopically.

The new epidermis proves to be soft and of pink colour for the first weeks. A light permanent change in pigmentation sometimes remains. It may be a hypo- or hyperpigmentation, the reason for this phenomenon being unexplained so far.

The 2A degree (1st. degree as well) does not strictly belong to surgical therapy, because it heals very well in a short time, despite unadequate treatment.

The resemblance of a burn of 2A degree to a recent donor area, after taking a thin T. g. is fascinating.

Infection may cause delay in the healing of a 2A degree burn, but cannot prevent its spontaneous healing.

THE 2 B DEGREE

The 2B degree is of utmost importance for the surgeon and we cannot make a useful evaluation of burns without having a proper conception of this type of burn.

The whole superficial epithelium is destroyed (i. e. the whole epidermis). Only the deep epithelial elements of the dermis and subdermis have survived, i. e. the epithelium of the sweat glands (and their efferent ducts), that of the hair follicles and sebaceous glands. It is known that in each square cm. there are about 100 sweat glands and five sebaceous glands (which of course may vary in different regions). It is evident, therefore, that a spontaneous regeneration could take place from those epithelial islands, taking 3—6 weeks.

The growth of the new epithelium depends largely on the individual thickness of the surviving dermis, on the degree of infection, on the local treatment and on the general condition of the patient.

Infection and unbiological local treatment may be responsible for the complete destruction of the epithelial islands, together with the remnants of the dermis. In this way a 2B degree burn changes into third degree, this being quite common in practice.

The macroscopic appearance of the 2B degree is rather like that of 3rd. degree (after the third week), i. e. a raw surface covered by a thin soft layer of granulations, sprinkled with small white-grey points — epithelial islands — growing in diameter and slowly becoming confluent in a continous epithelial surface.

After the epithelisation has ended, the qualities of the skin differ from the normal skin, and the healed skin of a 2A degree burn in appearance, histological structure and functional properties.

The epidermis is thinner, its structure being atypical. The dermis becomes thicker due to fibrosis.

The scarring, which is often depigmented, is visible and tends to take a hypertrophic or even keloid character. The pliability and elasticity of the skin is reduced, contractures and functional disturbances may follow at the joint covering areas.

The 2B degree burn looks similar to a donor area after cutting away a dermatom graft of ¾ thickness of the skin.

A less experienced person may mistake the 2B degree in the stage of granulations for third degree. This explains erroneous reports of "spontaneous" healing of third degree burns, due to local antibiotic or hormonal preparations.

The final appearance of a healed 2B degree burn shows differences when compared with a third degree burn, which has been left to granulate and to epithelize from the margins. The last one represents a fibrous plate, covered by a thin layer of epithelium (pseudoepidermis), which proves to be non-resistant and vulnerable, having reduced functional qualities according to its structure.

After having described the 2B degree of burns we will try to throw some new light on the most difficult problem of the treatment of burns, i. e. the early and reliable diagnosis of the depth of a burn.

THE DIFFICULTIES OF AN EARLY ASSESSMENT

The clinical tests we know (the blood-return test, the pin-prick test, the appearance and the colour of the skin) are not completely reliable, especially with regard to the 2B degree burn.

The testing of necrotic tissues by dyes and the fluoroscopic test are more of academic importance. The same can be said of isotopes.

Jackson's biopsy test (the red colour of the subcutaneous fatty tissues of the third degree burn) is considered to be of limited significance.

All the tests mentioned above are rather static. They do not pay attention to the dynamic biological processes, which are unpredictable, neither can they be followed by the eye.

A burn which seems at the beginning to be of 2B degree, is often found later to be of third degree and vice versa: many times an area of burned skin initially denoted to be certainly of third degree proves eventually to be nevertheless of 2B degree.

Furthermore, we have to take account of the lack of uniformity of the depth of a burn, even in the same anatomical region, for areas of 2B degree and third degree are intermingled.

PRACTICAL CONSEQUENCES

The unreliable demarcation between areas of 2B and third degree in the first two weeks makes a reasonable assessment dificult and sometimes even impossible.

Immediate or early excision in the first two weeks must, therefore, be avoided, especially in extensive burns, because it may involve the risk of removing viable parts of the dermis with epithelial elements.

Under adequate local and general care the 2B degree burn heals spontaneously on quiet and less visible regions, such as the chest, back, abdomen, buttocks and thighs. The functional results are satisfactory. According to Klemenčič (1960) we recommend the local use of antibiotics an 2B degree areas.

We have to keep in mind, especially in extensive burns, the thickness of the dermis at the regions mentioned above, which may be 2—3 times greater than at other sites.

Spontaneous re-epithelisation takes up to six weeks. The application of homografts to a clean raw surface of 2B degree burn may promote definite epithelisation. When histolysis of homografts starts, the regeneration from the remnants of autogeneous epithelium is already finished. Sir Harold Gillies noted a similar case in 1951.

If autografts are applied to the clean surface of a 2B degree burn, a "two-storied" epidermis may result, which appears ugly.

2B degree burns on functional areas, such as the eye-lids, nose, lips, neck, joints, dorsal surfaces of fingers and hands, a more active principle of early excision and grafting is advocated.

It may be re-stated that the quality of skin after the spontaneous healing of the 2B degree burn is as a rule markedly inferior to the normal skin, regarding both function and appearance.

CONCLUSIONS

The reasons for the modified assessment of the depth of burns proposed are neither pretentious nor merely formal.

Steady and careful clinical examination during the last seven years confirmed our method of assessment of the depth of burns as justified and useful.

Particularly the conception of the 2B degree burn proved to have a clinical importance for the following reasons:

1. If the biological events, i. e. the necrobiotic processes in the dermis are to be elucidated, then a dynamic assessment is preferable to a static one.
2. Such a course of assessment includes the time-factor, for the morphological and biological appearance of the burned skin changes with time.
3. Our assessment provides a clear clinical insight and makes a safe prognosis of the local trauma possible.
4. The knowledge of the 2B degree also represents an indispensable element for therapeutic and teaching purposes.

In the vast majority of cases biological processes in the dermis due to the burn take place at first in both directions — necrosis and (or) survival. It is generally accepted that this stage takes about three weeks.

If the deep layer of the dermis with its epithelial elements is perserved viable, under favourable circumstances the course may turn towards spontaneous regeneration. If not, complete necrosis of the dermis with the loss of all epithelial elements results.

Assuming that the necrosis of the dermis was not complete from the beginning, the following factors promote the regeneration of the surviving parts:

1. Absence of subsequent thrombosis in the blood-vessels of the dermis.
2. Absence of infection.
3. A dry and cool milieu.

On the other hand, the factors promoting necrosis are:

1. Secondarily progressive thrombosis in the vascular network of the dermis and subdermis.

2. Infection, which exerts a marked influence on the spreading of the thrombotic process.
3. Local moisture and warmth.

We owe the knowledge of these last facts to the Edinburgh school.

The conception of the 2B degree burn has become common usage and terminology in this country. It has contributed to a better understanding of the local pathology of burns and enabled us to carry out more exact assessment and treatment.

SUMMARY

During several years of systematic clinical examination of more than 300 burns, we felt the existence of a gap between the classical second and third-degree burns or between the modern superficial and deep burns respectively. Therefore in 1953, we introduced the subdivision of the second degree into: superficial (2A), and deep (2B) second-degree. The latter is fairly identical with the term "deep dermal burn", known before in the British literature and cited by Wallace (1955) as a special type of burn.

The morphological characteristics and differences between the "2A" and "2B" degree are described and the reasons and advantage of this classification are outlined.

Recent clinical and experimental research done by different authors confirmed our statement that the dermis is the most resistant part of the skin, containing a sufficient amount of epithelial elements capable of forming the normal skin.

The special importance of the 2B degree for the surgeon is pointed out and the difficulties of its early assessment and distinction from the third-degree are explained. The practical consequences of this conception are shown.

The knowledge of the 2B degree of the depth of burns brings a better understanding of the clinical appearance and adds to a safer plan of surgical management and better teaching, because it takes into account the time factor and includes the perference of a dynamic assessment to the static one.

ВЫВОДЫ

Клиническое значение биологической оценки глубины ожога

M. Derganc

На основании тщательных клинических наблюдений за более чем 300 больных, пострадавших от ожогов, автор констатирует, что применяемый до настоящего времени способ оценки глубины повреждения является недостаточным, а зачастую и неточным.

Ввиду того, что автор наблюдал, что между классической второй и третьей степенями ожога или между т. наз. в настоящее время поверхностным и глубоким ожогом имеется пробел, то он в 1953 году ввел подгруппы второй степени ожога, а именно: поверхностную (II а) и глубокую (II б) степени.

Вторая подгруппа (II б) является идентичной с термином «deep dermal burn», уже прежде известным в британской литературе и цитированным, например, в 1955 году Уольсом (Wallace) в качестве специального типа ожога.

В статье разбираются морфологические изменения и различия между II а и II б группами и обращается внимание на причины и преимущества этой классификации.

Подчеркивается особое хирургическое значение подгруппы II б и разбираются затруднения при ее своевременном определении и дифференцировании от третьей степени.

Обращается внимание на практическую ценность этой собственной классификации.

Автор приходит к следующим выводам:

1. Нельзя упускать из виду биологические изменения в обожженной коже и принимать во внимание динамику процессов в коже, которая может протекать в двух направлениях: к омертвлению, некрозу или к выживлению.

2. Необходимо принимать во внимание фактор времени в связи с его большой важностью в отношении биоморфологической ценности обожженной кожи.

3. Осведомленность о подгруппе II б позволяет лучше понять клинические проявления и способствует более надежному планированию хирургического вмешательства.

4. Термин подгруппа II б или «deep dermal burn» британских авторов стал повседневным в нашей стране и принес пользу в отношении понимания и лечения ожогов.

RÉSUMÉ

L'importance clinique de la différenciation biologique du degré des brûlures

M. Derganc

L'auteur constate, à base d'observations cliniques approfondies, faites sur plus de 300 brûlés que la manière actuelle de l'estimation de la profondeur des lésions s'avère insuffisante et souvent imprécise.

Persuadé qu'il existe une lacune entre le deuxième et le troisième degré classique ou, d'après la terminologie moderne, les brûlures superficielles et profondes, l'auteur avait introduit en 1953 les sous-groupes ainsi conçus du deuxième degré: degré superficiel (IIa) et degré profond (IIb).

Le deuxième sous-groupe (IIb) est identique au terme du „deep dermal burn", employé depuis un certain temps dans la littérature anglaise et cité, p. ex., en 1955 par Wallace comme type spécial des brûlures.

Les echangements et les différences morphologiques entre les types II et IIb vont être décrits en insistant sur les raisons et les avantages de cette classification.

L'importance chirurgicale du sous-groupe IIb est spécialement soulignée et on insiste sur les difficultés de son diagnostic précoce et de sa différenciation du IIIème degré.

L'importance pratique de cette classification propre de l'auteur est démontrée.

Les conclusions peuvent être résumées ainsi:

1. Il est nécessaire de ne pas perdre de vue les altérations biologiques de la peau brûlée et de tenir compte du dynamisme du processus au niveau de la peau qui peut se développer dans deux directions: vers le dépérissement, la nécrose, ou bien vers la survie.

2. On doit tenir compte du facteur „temps" à cause de la grande importance qui lui incombe par rapport à la valeur biomorphologique de la peau brûlée.

3. La connaissance du sous-groupe IIb permet de mieux comprendre certaines manifestations cliniques et aide à préparer avec plus de securité l'intervention chirurgicale.

4. Le terme du sous-groupe IIb ou bien du „deep dermal burn" des auteurs britanniques s'emploie déjà couramment dans notre pays et s'est montré util pour la compréhension et la thérapie des brûlures.

ZUSAMMENFASSUNG

Die klinische Bedeutung einer biologischen Beurteilung der Verbrennungstiefe

M. Derganc

Auf Grund einer sorgfältigen klinischen Beobachtung von mehr als 300 Verbrennungen stellt der Autor fest, dass die bisherige Beurteilung der Schädigungstiefe ungenügend und öfters auch ungenau ist.

Der Autor empfand eine Lücke zwischen dem klassischen zweiten und dritten Grad, oder modern ausgedrückt, zwischen einer oberflächlichen und tiefen Verbrennung. Im Jahre 1953 führte er Untergruppen des zweiten Grades wie folgt ein: oberflächlicher (IIa) und tiefer (IIb) Grad.

Die zweite Untergruppe (IIb) ist identisch mit dem in der englischen Literatur schon früher bekannten Termin „deep dermal burn", den z. B. im Jahre 1935 Wallace als speziellen Verbrennungstyp ausführte.

Die morphologischen Unterschiede zwischen IIa und IIb werden beschrieben, die Gründe und Vorzüge dieser Klassifikation unterstrichen.

Die besondere Wichtigkeit der Untergruppe IIb wird betont und die Schwierigkeiten ihrer rechtzeitigen Feststellung und Unterscheidung vom III. Grad dargelegt.

Der praktische Wert dieser eigenen Klassifikation wird demonstriert.

Die Schlussfolgerungen werden wie folgt zusammengefasst:

1. Die biologischen Veränderungen in der verbrannten Haut dürfen nicht ausseracht gelassen werden, ebenso ist die Dynamik der Prozesse in der Haut zu erwägen, die sich in zwei Richtungen bewegen kann: in der Richtung zur Nekrose oder zum Überleben.

2. Wegen seiner grossen Wichtigkeit für den biomorphologischen Wert der verbrannten Haut ist der Zeitfaktor in Erwägung zu ziehen.

3. Die Kenntnis der „Untergruppe IIb" ermöglicht ein besseres Verständnis der klinischen Erscheinungen und eine verlässlichere Planung des chirurgischen Eingriffe.

4. Der Termin „Untergruppe IIb" oder „deep dermal burn" englischer Autoren ist in unseren Land geläufig geworden und hat sich als nützlich für das Verständnis und die Behandlung von Verbrennungen erwiesen.

REFERENCES

1. **Gillies, H. D., Millard, D. R.:** Principles and Art of Plastic Surgery. Little, Brown. Boston, Toronto 478, 1957.
2. **Klemenčič, H.:** Report at the Ist Yugoslav Congress for Plastic and Maxillo-Facial Surgery 1960.
3. **Pavletić, J.:** Ratna hirurgija. Deo I. 295—351, 1953, SU JNA Beograd.
4. **Wallace, A. B.:** Voj. san. Pregled, 3—4, 113—117, 1956.
5. **Derganc, M.:** Jubilejni zbornik Medic. fakultete v Ljubljani, 303—321, 1956.
6. **Derganc, M.:** Voj. san. Pregled, 3—4, 156—159, 1956.

Delivered at the International Symposium of Plastic Surgery in Mariánské Lázně (Czechoslovakia), June 28, 1960.

(Doc. Dr. M. Derganc): University Surgical Clinic, Ljubljana, Yugoslavia

Department of Surgery, Třebíč Hospital (Czechoslovakia)
Director: K. Holubec, M. D.

THE TREATMENT OF SHOCK CAUSED BY BURNS

K. HOLUBEC

The author submits his conclusions on the treatment of shock due to burns, drawn from observation of individual cases in a country hospital. They are not supported by experimental findings and some have already been published. The reason for their present publication is that they raise again an old question to which, in many cases, there is still no unequivocal answer, i. e. the question of plasma dosage in shock due to burns. The author once attempted to lay the foundations of a new technique for combating shock. Even at that time he was asked whether it was more expedient to be guided by the extent of the burned area or by changes in the haematocrit. That is the first concern. Related to this is the question of whether, when estimating the amount of plasma required according to the extent of the burns, it is sufficient to take only the percentage of the affected area into account, or whether other factors also require consideration.

This may appear to some to be unsuitably schematic, and naturally all the available examination methods should be used and every case of shock following burns should be approached individually, with reference to the patient's general condition. If a guide to substitutional therapy is required, any laboratory is ready to give adequate information on the movements of proteins and electrolytes in the blood stream and on changes in the amount of circulating plasma, so that the dosage of plasma can be regulated exactly, in accordance with the objective findings. The fact that a concrete, simple criterion for such situations is often demanded shows, however, that a simple scheme is nevertheless needed in practice. It is useful for daily practice in country hospitals, with their many other acute worries, and it is equally needed in institutes specializing in the treatment of burns, which are also sometimes overhelmed with work. It has often been stated in the literature that the most reliable of the known simple methods is repeated examination of the haematocrit and that plasma should be administered precisely in accordance with the degree of concentration of the blood. Some authors regard estimation of the dosage by the size of the burned area as an emergency measure only, in cases in which, for technical reasons, the more accurate information provided by the haematocrit cannot be obtained at once. Practice, however, shows that the general plan of plasma consumption must be determined from the very outset, that the amount of plasma required and the transfusion rhythm must be determined beforehand. This can be estimated from the area

of the burns; otherwise the whole of the treatment would simply consist in chasing after haematocrit values, in which it is often impossible to keep step with the development of shock.

The author has for many years used a modification of Harkins' scheme, although he is aware that Evans' method, which also takes body weight into account, probably gives a more accurate estimate of the amount of plasma required. Normally 50 ml. was reckoned for every one per cent of the body area affected, the plasma being administered in a diminishing rhythm. During the first six hours after injury the patient received half the total amount, during the next six hours a quarter of the amount and the remaining quarter over the following 12 hours. This covered the first 24 hours. For the next 24 hours half the amount used on the first day was administered. For concrete situations this general plan was made more precise by repeating the haematocrit examination, 100 ml. plasma being calculated for every section above normal. The patient naturally also received the proper amount of electrolyte solutions and water. The present paper is not, however, concerned with this or with the other methods of global therapy then used for treating shock following burns. The reliability of the above method of substitutional therapy for shock was to some extent verified in an episode which ocurred seven years ago, when two patients were burned at the same time. The extent of their burns was roughly the same. Both were severely shocked. In both cases, in addition to the usual tests, changes in the volume of circulating plasma were also studied photocolorimetrically.

Both patients were scalded simultaneously by steam escaping from an overturned locomotive on an auxiliary tract. Neither could be freed immediately. Useful first aid was rendered by a well trained military first aid worker who happened to be on the spot. Both patients were taken to hospital at the same time, within half an hour after injury.

The first patient, aged 20, was composed when admitted. He answered questions cheerfully and looked forward to going home soon. His blood pressure was 130/80 and his pulse, which was 80/min., was strong. Misled by the patient's good condition, the doctor treated the burns immediately atfer his admission. Two hours later the first 500 ml. plasma was administered. Procain was not given until the second day by intravenous infusion.

The other patient, aged 23, was in much worse condition on admission. He was apathetic, his skin and the visible mucous membranes were grey. He answered questions listlessly, groaned heavily from time to time and shivered as if in rigor. His blood pressure was 160/90 and his pulse 96/min. Local treatment of the burns was not undertaken. A cervical procain block was carried out immediately, tea with alcohol was given and the patient was placed in a heated bed and a plasma infusion was immediately set up. Treatment of the actual burns was not undertaken for another four hours, when the patient's condition had improved.

It should be added that in both patients about 60% of the body area was burned. On going over the case again, this calculation appears to have been, if any-

thing, on the low side. The proportion of third degree burns, which covered coherent areas and were also distributed over the lower limbs, was considerable. They are illustrated in the records and photographs. In both patients the haematocrit was over 50 on admission. The further course of their illness will be described briefly. The condition of the first patient, which at first appeared to be so good (Fig.

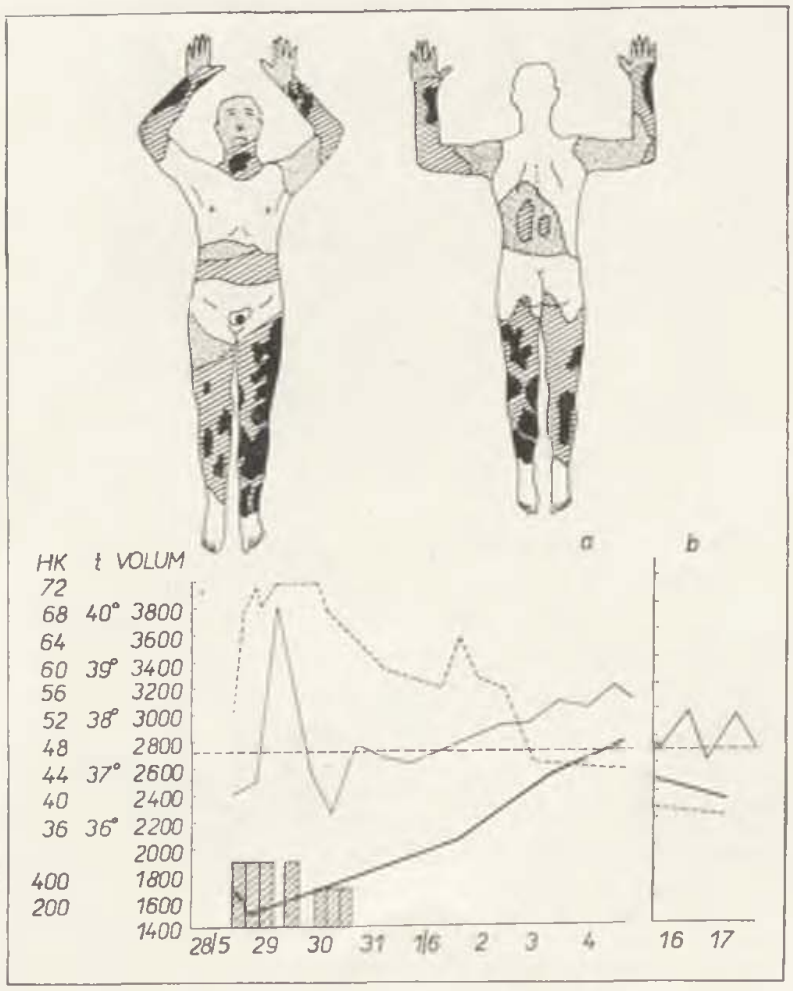

Fig. 1.

1a), afterwards deteriorated severely. The hematocrit reached 71 and haemoglobin 11, while the urine flow fell to 350 ml. daily and the plasma deficit reached 1,228 ml. In the second patient (Fig. 2b), whose condition at first appeared to be worse, the eventual course of the illness was much better. The haematocrit rose to 61 only and haemoglobin to 100, while the urine flow never dropped below 800 ml. a day. The plasma deficit was only 811 ml. The patient did not vomit.

Both patients were given large doses of plasma during treatment for shock — the first patient 2,750 ml., the second 2,500 ml. They were also given the other usual forms of treatment. Both patients recovered and the final functional result, after the necessary plastic operations, was good.

In this case, two patients with burns were treated simultaneously. The mechanism of injury, the extent of the burns and all the other attendant circum-

stances, including definitive treatment were, in general, the same. The further course of the illness, however, differed. Perhaps some conclusions on the treatment of shock can be drawn from these cases, particularly as circulatory changes were checked throughout their course by measuring the volume of circulating plasma colorimetrically.

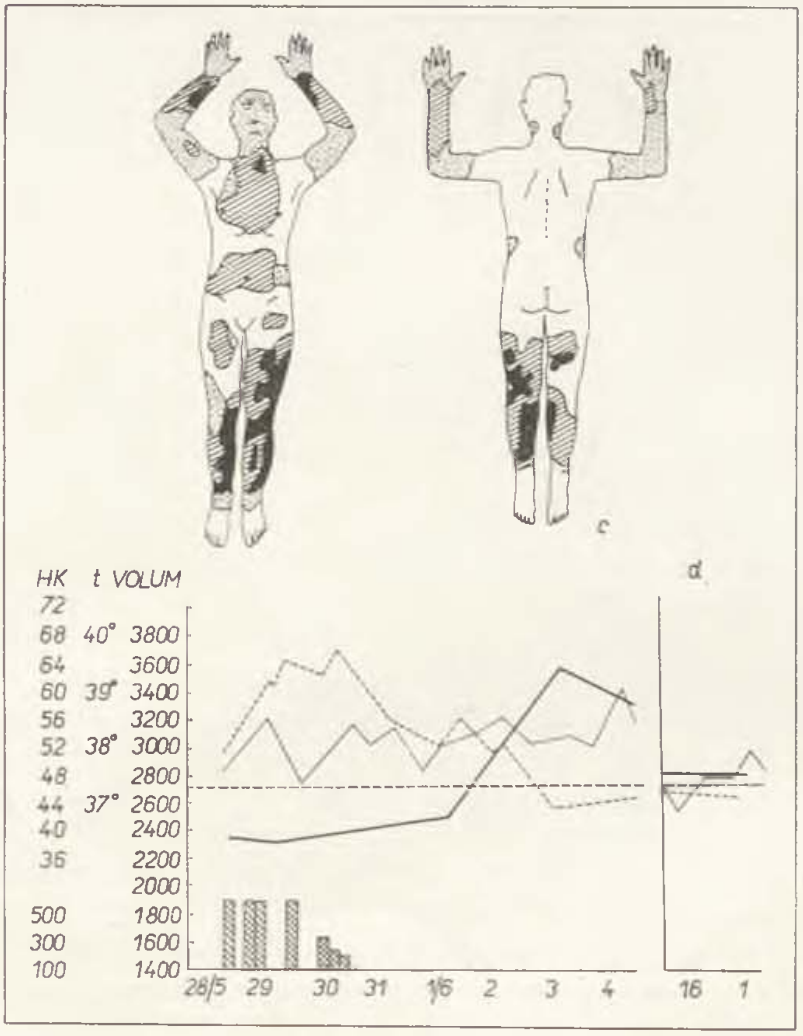

Fig. 2.

In the first place the course of shock was far milder in the patient in whom a procain block was carried out in time and final treatment of the actual burns was postponed until his condition improved. This "masterly neglect", once propagated for burns by the Birmingham school, still seems to the author, after a number of experiences, to be the corner stone of success in the fight against shock following burns. Today it is a firmly established rule. Extensive burns are in themselves sufficient indication, however, that the patient is endangered by shock and that local treatment should be postponed. Shock is not always necessarily clinically manifest and there need not be a marked change in the haematocrit. A procain block or infusion must be given promptly, however, even at the cost of administering through a burned area.

The author is aware that the amount of plasma administered in these two cases was relatively small. The unfortunate localization of the burns made parenteral administration difficult and ultimately impossible. However, in other cases even lower doses were often found adequate after administering procain and good result were obtained. Neither does the lower dosage account the difference in the course of shock in the above two cases, however, which in the one case was favourable, while in the other extra effort and constant attention were needed to save the patient's life. Delay in instituting local treatment and the timely administration of procain were thus justified. Substitution therapy can be expected to be successful only if these prerequisite conditions are fulfilled first.

Secondly, mention should be made of an episode from the phase of the fight for the life of the patient whose condition caused the greatest anxiety. At the time when the whole department, including the laboratory staff, was mobilized day and night on behalf of these patients, the author returned to the department after a brief absence. The staff were just engaged on another protracted operation. They were confident that the patient's condition was satisfactory. They had seen him before commencing the operation and he had then received his dose of plasma. When the author saw the patient, however, his condition was very grave. He was again deeply shocked and his pulse was barely perceptible. He was helped only by a rapid emergency plasma infusion. The haematocrit values were again high.

This again raises the vexed question, already broached above, of what criterion to use when determining the plasma dosage in shock. It is undoubtedly necessary to take into account both the extent of the burns and the haematocrit values. The extent of the burns gives the probable total loss of plasma from the blood stream, i. e. the amount which needs to be replaced. It also indicates the probable rhythm of the loss. An estimate based on the area of the burns thus determines the general conception of the procedure to be adopted in shock, i. e. the strategy of the battle. Repeated examination of the haematocrit or tests of a similar type provide information on variations in the escape of plasma not furnished by an estimate based on area. Tests of the degree of concentration of the blood thus give information on instantaneous situations, i. e. they are a tactical weapon. This was made clear precisely by the above episode.

Special attention should be paid to repeated haematocrit tests in cases in which, after carrying out a block, lower plasma doses are administered than those originally calculated. The possible final loss must constantly be borne in mind, so as to avoid the danger of sudden shock. In these situations the haemotocrit was found to be a reliable guide. The haematocrit curve actually corresponded to the curve of changes in the volume of circulating plasma, (Fig. 1b, 2d), despite discrepancies due to inaccurate work with the difficult, frequently repeated collection of blood. There is obviously no absolutely reliable criterion by which to replace the amount of plasma lost and wage war with shock with one's eyes closed. A critical situation can be overcome only by keeping constant watch on the patient and checking his general condition, with one finger on his pulse

and taking the other factors into account. Changes in the urine flow are also considered important.

Thirdly, the episode involving the two patients described above nevertheless left some doubts as to the accuracy of the stereotyped estimation of plasma loss based only on the extent of the burns. The plasma doses were taken as a whole quite large and in one patient at least they were sufficient — according



Fig. 3.

to the clinical course of the illness — for overcoming shock successfully. As already mentioned, on other occasions even smaller doses proved adequate if procain was administered in time. Even in the patient who made a good recovery, however, the haematocrit values appeared to return to normal disproportionately slowly. This may have been because of the large proportion of third degree burns. Perhaps deep burns require a different plasma dosage and a different quotient when calculating the plasma requirements according to area. It is probably incorrect to claim that in all situations the coagulum of a deep burn seals the surface of the wound and thus lowers the plasma loss.

The infiltration of plasma into blisters and out through wounds is not the only way in which the circulation is impoverished following burns. Protein and electrolyte shifts change the osmotic pressure in the given area and plasma escapes into the intercellular spaces. The resultant tissue oedema is an important component of the pathogenesis of burns shock (Beaconsfield). There are grounds for assuming that tissue oedema is particularly marked in deep burns and that it leads to big losses of plasma from the blood stream. Pronounced oedema was also present in the above patients — to such a degree that in one case it was necessary to loosen the circular bandage on one of the limbs. In extensive and deep trauma caused by high temperatures, the probability of marked oedema should, therefore, also be taken into account when estimating total plasma losses.

This would naturally necessitate accurate diagnosis of the depth of the burns at the very outset. At first glance, however, the depth of fresh burns can only be estimated roughly. With the closed method of treatment it cannot be evaluated with any degree of reliability until the dressings are changed, i. e.

after 10—12 dyas, when the shock has long since passed. With the above patients, however, some of the dressings required changing on the second and third day, since they were too wet in some places. In doing so an interesting finding was made. For the colorimetric measurement of the plasma volume, Evans blue was used. When changing the dressings at this early stage it was observed that where second degree burns were present, the dressings were stained blue, while in

Fig. 4.

places where the burns had probably gone deep, the tissue itself or the crust over the wound was blue. Tissue destroyed by heat had thus absorbed the blue dye. After another ten days, when finally changing the dressing and when the depth of the burns could be evaluated reliably, the first estimate was confirmed (Fig. 3, 4).

The findings are similar to the older experimental observations of Okunyev (1924) and Kuznetsovsky (1925). These authors also observed raised excretion of colloid dyes from the blood vessels into the tissue in burns and this phenomenon is also found in experimental work on burns today. Moreover, the author was particularly interested in absorption of the dye in the presence of burns of different degrees. The difference may have been due to the special conditions formed by the compressive bandage. With the closed method of treatment early identification of the depth of the burns was impossible, as after initial treatment the burned area was hidden by the bandage. Today, however, open methods are beginning to predominate. If it were possible to determine the extent of deep burns during the first hours, it might also be possible to make a more accurate estimate of the amount of plasma required to combat shock. The question of the evaluation of the significance of the depth of the burns for the amount of plasma lost in shock has still not been answered, however.

The figures show the extent of the burns in the two patients concerned (Fig. 1a, 2c). The shaded areas represent second degree burns, the black areas complete loss of the skin. In the recordings of the temperature curve (Fig. 1b, 2d), the unbroken line at the bottom shows changes in the volume of the circulating plasma, while the broken line at the top shows the haematocrit values.

SUMMARY

The question of whether the extent of the burned area or the haematocrit should be the normal criterion for determining the plasma dosage in shock following burns is discussed. The author concludes that both are needed. The estimate based on the extent of the burns determines the general strategy of treatment, while the estimate based on the haematocrit indicates the tactics to be used in the given situation. Recordings of changes in the volume of circulating plasma in two patients with burns are shown. The extent of the burns and the circumstances attending the injury were the same, but the therapeutic procedure differed. It was again confirmed that where there is danger of shock it is better to postpone definitive care of the actual burns. When determining the total amount of plasma needed, however, it is useful to know the depth as well as the extent of the burns. In the author's experience the preliminary estimate of the degree of the burns can be made more accurate by the intravenous administration of Evans blue. In places with deep burns the necrotic tissue absorbs the dye and is stained a deep blue.

ВЫВОДЫ

Лечение ожогового шока

K. Holubec

В предлагаемой работе поставлен вопрос о том, должно ли быть обычным руководством в отношении дозировки плазмы при ожоговом шоке вычисление в зависимости от размеров поверхности ожога или по данным гематокрита. Автор пришел к заключению, что необходимо учитывать оба фактора. Определение в зависимости от размера ожога определяет общую стратегию при лечении шока, между тем, как вычисление по данным гематокрита показывает тактику при данном положении. Приведены записи об изменениях объема циркулирующей плазмы у двух пострадавших от ожога. Размер ожога и сопутствующие травме обстоятельства у обоих больных были одинаковыми, но метод лечения каждого из пострадавших от ожога был другой. Снова было подтверждено, что там, где угрожает шок, необходимо отложить окончательную обработку ожоговой поверхности. Для определения общего количества плазмы для введения полезно знать кроме размеров ожога и его глубину. Предварительное определение степени ожога можно на основании опыта автора уточнить и внутривенным введением синьки Эванса. Некротические ткани в местах глубокого поражения адсорбируют красящее вещество и окрашиваются в выразительный синий цвет.

RÉSUMÉ

Le thérapeutique du choc des brûlures

K. Holubec

Il y a question de quoi se tenir en thérapeutique du choc des brûlures quand du dosage du plasma. Faut-il se diriger d'après la grandeur de la surface brûlée ou d'après l'hématocrite? L'auteur est d'avis, qu'il faut se servir des deux facteurs. Il est bon de se tenir à la grandeur de la surface brûlée pour la stratégie totale durant le thérapeutique du choc, tandis que l'hématocrite nous indique le tactique momentanné. L'auteur nous

sert des données quand aux changements du plasma en circulation chez deux sujets brûlés grièvement. La grandeur de la surface brûlée de même que les circonstances accompagnant le traumatisme étaient les mêmes, mais le thérapeutique différait. Chose connue que le pansement définitif ne doit être pratiqué nulle part, où le choc menace, vient d'être soulignée. Pour fixer le besoin total en plasma, il faut connaître non pas seulement la grandeur de la surface brûlée, mais de même la profondeur de la brûlure. Pour constater celle-ci, l'auteur se sert du bleu d'Evans, appliqué par voie intraveineuse. Le tissu nécrotisé, en lieux de la profonde nécrose, adsorbe le colorant et devient bleu foncé.

ZUSAMMENFASSUNG

Die Behandlung des Schocks bei Verbrennungen

K. Holubec

In der vorliegenden Arbeit wird die Frage erörtert, ob beim Verbrennungsschock als allgemeine Richtlinie für die Dosierung von Plasma die Berechnung nach dem Ausmass der verbrannten Fläche oder nach dem Hämatokritwert dienen soll. Der Verfasser gelangt zu der Schlussfolgerung, dass beide Umstände berücksichtigt werden müssen. Die Bewertung nach dem Ausmass der Verbrennung bestimmt die Gesamtstrategie der Schockbehandlung, während die Berechnung nach dem Hämatokritwert die Taktik für die gegebene Situation angibt. Es werden die Veränderungen im Volumen des zirkulierenden Plasmas angeführt, die bei zwei Patienten mit Verbrennungen registriert wurden. Das Ausmass der Vebrennung und die Begleitumstände des Unfalls waren bei beiden Patienten identisch, das Vorgehen in der Behandlung der Verbrennungen war jedoch verschieden. Wieder einmal bestätigte sich die Ansicht, dass in den Fällen, in denen Schock droht, die definitive Versorgung der Verbrennungsfläche verschoben werden muss. Für die Bestimmung des Gesamtbedarfs an Plasma ist es jedoch von Nutzen, ausser dem Ausmass der Verbrennung auch noch ihre Tiefe zu kennen. Die vorläufige Abschätzung des Verbrennungsgrades kann nach den Erfahrungen des Verfassers noch durch die intravenöse Applikation von Evans-Blau präzisiert werden. Das nekrotische Gewebe an den Stellen tiefgehender Schädigung adsorbiert den Farbstoff und zeigt markante Blaufärbung.

REFERENCES

1. **Beaconsfield, Schwarz:** in book Zimmermann, Levine: Physiologic Principles of Surgery, Saunders Co, p. 59.
2. **Kusnetzowsky:** Z. ges. exp. Med. 44, 646, 1925.
3. **Okuneff:** Pflüger's Arch. ges. Physiol. 204, 261, 1924.
4. **Holubec, Karfík:** Chirurgické léčení popálenin. Státní zdravotnické nakladatelství, Prague 1956.

Delivered at the International Symposium of Plastic Surgery in Mariánské Lázně (Czechoslovakia), June 28, 1960.

(Doc. K. Holubec) : Nemocnice, Třebíč, Czechoslovakia

Stalino Research Institute of Traumatology and Orthopaedics-Stalino (U.S.S.R.)
Director: T. A. Revenko, Cand. Med. Sci.

SIEVE GRAFTS IN SKIN PLASTIC SURGERY

M. I. SINILO

In recent years the efforts of scientists in various countries have enriched plastic surgery with a number of new, original, very promising and effective methods of skin plastic surgery. Surgeons now have at their disposal an adequate choice of different methods and techniques for abolishing skin defects, which, when used alone or combined in different ways, provide a new tegument similar or identical to the surrounding tissues.

Among the many methods of free skin transplantation, the sieve graft, with which great progress has been made and which constitutes a big step forward in reparative surgery, merits special attention.

The advantages of the sieve graft lie in its attainability, technical simplicity, the fact that only one operation is involved, the possibility of covering large defects, the wide choice of sites for removal of the graft, the readiness with which it takes, the absence of depressive states in the patient during the post-operative period and the good cosmetic and functional result, together with the high degree of resistance of the graft, even after long periods.

Its characteristic feature as compared with other methods is that it contains all the skin layers without the subcutaneous connective tissue, and a large number of small openings. This ensures the free escape of secretion from the wound below the skin, raises its resistance to infection, increases the area of resorption of the graft and thus forms favourable conditions for its nutrition — an especially important factor during the first critical days after operation.

This method proved most effective and was used by the author for a wide variety of fresh skin injuries resulting in contracture or disfigurement due to scar tissue, for abolishing syndactyly and post-traumatic synechiae, in the extirpation of trophic ulcer which refused to heal and in the treatment of chemical burns. It proved satisfactory not only for covering defects formed during plastic operations, but also in the preparation of skin for subsequent plastic bone operations (pseudoarthroses) and for covering defects of varying origin on stumps preparatory to the use of a prosthesis.

Clinical studies were carried out in 320 patients aged from one to 55 years, to whom 363 sieve grafts were transplanted in 337 operations.

The indications for the operations and their results were as follows:

Case No.	Indications	Number of patients	Number of ops.	Number of grafts	Results			
					Took completely	Partial necrosis	Total necrosis	Result not known
1.	Post-traumatic contracture	102	104	108	93	12	2	1
2.	Fresh injuries	79	81	88	76	7	3	2
3.	Post-traumatic non-healing wounds and trophic scars	66	72	79	62	13	4	—
4.	Defects on stumps	28	28	29	23	5	1	—
5.	Chemical burns	22	22	22	15	4	3	—
6.	Other conditions	23	30	37	25	8	4	—
	Total	320	337	363	294	49	17	3

An analysis of these clinical observations immediately showed that all cases of contracture and some of synechia were caused by inadequately treated burns. The greatest care should therefore be given to the treatment of patients with burns, including functional reconstruction of the part of the body concerned, so as to avoid poor results.

The above table shows that of the 363 grafts transplanted, 294 healed, while 49 underwent partial necrosis and 17 total necrosis. The group with partial necrosis includes all cases of slight peripheral necrosis, in which the healing process was not impaired and the final good functional and cosmetic result was not affected. Total necrosis was basically associated with inadequacies in the operative technique and in particular with inadequate post-operative care of the site of transplantation. This latter condition is particularly important for a successful result of the operation.

The immediate results of the operations are therefore regarded as completely satisfactory, because even in cases of total necrosis the wounds healed rapidly and completely in every case.

The best places for obtaining these grafts are the anterior lateral surface of the thigh and the anterior portion of the left abdominal wall.

In some patients the operation was carried out in several stages because of the size of the injury and the distribution of the scars.

Observations carried out over a period of more than ten years show that sieve grafts are very resistant and possess good functional properties. In all the patients abolition of the skin defect was permanent. Complete restoration of function was not obtained in six patients only, in whom relapse necessitated another operation. In all other cases, including operations on the sole of the foot and on stumps intended for the use of prostheses, the grafts proved suf-

ficiently resistant to the strain and to different harmful factors in the external environment (trauma, etc.). This was further demonstrated in operations for the formation of pseudoarthroses, in which sieve grafts were used for the preparatory stage and the subsequent incisions led across the grafts. The grafts were sufficiently resistant for this big operation to be performed at the beginning of the third to the fourth month, as a result of reconstruction of the subcutaneous fatty connective tissue they were remarkably mobile and elastic.

A study of the functional state of free sieve grafts showed that during the first two weeks the graft was non-reactive. After two weeks, when it was no longer oedematous, it developed weakly positive exudative and immunoreactive function. After 2½—3 months, all types of sensitivity were found to have been recovered, together with the function of sweat secretion. According to the author's findings, sensitivity was completely recovered (in almost every case) between the fifth and the seventh month in adults and between the third and the fourth month in children, leading not only from the periphery of the graft, but also from its centre, in the form of separate areas and islands.

The morphological changes which took place in the transplanted grafts were characterized during the first phase by acute dystrophic processes, which afterwards became chronic. These processes eventually disappeared during the phase of regeneration of the normal circulation and innervation of the graft from the deeper and surrounding tissues.

When comparing the results of morphological changes with the values obtained from a study of the functional state of the graft, a relationship was found between the function of sweat secretion and the degree of neurotization of the transplanted graft, exudative and immunoreactive functions appearing much sooner in grafts without normal innervation.

A study of the functional state of the recipients of sieve grafts, using plethysmography and comparison of the above data with morphological changes, permits evaluation of the take of the graft and of its functional success and of the degree of neurotization and the times of the reconstruction of nerve connections with the central nervous system.

Considerable personal experience, numerous clinical studies — all of which furnished convincing evidence — and the study of the recovery of function and morphological changes in the sieve graft show that this method should be propagated more widely and can be recommended in every respect for use in plastic surgery.

SUMMARY

Among the various methods of free skin transplantation, special attention should be paid to the sieve graft, which is one of the most successful methods in modern plastic surgery.

The value of the sieve graft lies in its accessibility, technical simplicity, the fact that only one operation is required, the possibility of abolishing large defects, the wide choice of sites for removal of the graft, the rapid take, the

abolishing of post-operative complications and the excellent cosmetic and functional result, together with the good quality of the graft after long periods.

This method proved completely satisfactory and was used by the author on a large scale for different skin injuries or for the sequelae of injuries, such as contracture caused by scars, for the treatment of syndactyly and post-traumatic synechiae, for the extirpation of non-healing ulcer and chemical burns, for covering skin defects formed during plastic operations, in the preparation of skin for subsequent plastic bone operations and for covering skin defects on stumps for the use of prostheses.

Clinical studies were carried out in 320 patients, to whom 363 sieve grafts were transplanted in 337 operations for different causes.

The immediate and late results of the operations are discussed and an analysis of the functional state and morphological changes in free sieve grafts at different stages after the operation is submitted.

Observations made at later stages after the operation demonstrate the high quality of these grafts and their great functional advantages. All types of sensitivity, physiological function and morphological structure usually appear in sieve grafts within five to seven months. In children regeneration takes place still sooner.

It was found that the free sieve graft has qualities which recommend it for use on a large scale and that it merits wide application in plastic surgery.

ВЫВОДЫ

Кожная пластика «лоскутом сито» в восстановительной хирургии

M. I. Sinilo

Среди многочисленных методов свободной кожной пластики заслуживает внимания метод пластики «лоскутом сито», который явился достижением современной эпохи и крупным шагом в восстановительной хирургии.

Пластика «лоскутом сито» привлекает своей доступностью, технической простотой, одномоментностью операции, возможностью замещения больших кожных дефектов, свободным выбором мест взятия лоскутов, быстротой их приживления, отсутствием тягостных состояний у больных в послеоперационном периоде и высоким косметическим и функциональным результатом в сочетании с большой выносливостью пересаженных лоскутов в отдаленные сроки.

Этот метод полностью себя оправдал и нами широко применяется при самых разнообразных повреждениях кожи, их последствий в виде рубцовых контрактур и обезображивании, при устранении синдактилий и посттравматических синехий, при иссечении длительно незаживающих — трофических язв и химических ожогов, при закрытии кожных дефектов, возникающих как в ходе реконструктивных оперативных вмешательств, так и при подготовке кожи для последующих восстановительных операций на костях (при ложных суставах), а также для закрытия дефектов кожи на культях с последующим использованием протезов.

Нами проведены клинические наблюдения над 320 больными, которым в процессе 337 операций по различным показаниям пересажено 363 кожных «лоскутов сито».

В работе представлены данные, характеризующие как ближайшие, так и отдаленные результаты операций с всесторонним изучением функционального состояния и морфологи-

ческих изменений в свободно пересаженных кожных «лоскутах сито» в различные периоды после операции.

Наблюдения в отдаленные сроки после операции позволяют отметить большую выносливость пересаженных лоскутов и их высокие функциональные достоинства. Через 5—7 месяцев в пересаженных «лоскутах сито», как правило, полностью восстанавливаются все виды чувствительности, физиологические функции и морфологическая структура. У детей это восстановление происходит еще быстрее.

Следовательно, метод свободной кожной пластики «лоскутом-сито» в настоящее время имеет широкие свои возможности, привлекать к себе все больше и больше число приверженцев и заслуживает широкого применения в восстановительной хирургии.

RÉSUMÉ

Opérations dermatoplastiques à l'aide de «greffons réticulaires» en chirurgie de reconstruction

M. I. Sinilo

Parmi les différentes méthodes de la transplantation cutanée libre, il faut tout particulièrement attirer l'attention sur celle effectuée à l'aide de „greffons réticulaires" qui représente un des succès de l'époque contemporraine et marque un grand progrès dans la domaine de la chirurgie de reconstruction.

Les opérations plastique à l'aide des „greffons réticulaires" se distinguent par leur accessibilité facile, leur technique simple, l'opération en un seul temps, la possibilité de réparer des lésions étendues, la possibilité de choisir librement l'endroit d'où les greffons vont être prélevés, la rapidité de cicatrisation, l'élimination des complications post-opératoires ainsi que par leurs bons résultats cosmétiques et fonctionnelles et la qualité supérieure des greffons transplantés pour un temps très long.

Cette méthode a fait ses preuves et nous l'employons largement pour réparer les lésions dermiques les plus diverses ou bien les séquelles de ces lésions, telles que les contractions cicatricielles, ainsi que pour la réparation des syndactilies et des synéchies posttraumatiques, lors de l'extirpation des plaies qui ne veulent pas se cicatriser pendant longtemps et des brûlures chimiques, puis lors de la restauration des défectuosités cutanées qui peuvent se manifester aussi bien au cours des interventions de reconstruction que lors de la préparation de la peau aux opérations de reconstruction osseuse, enfin nous nous servons de cette méthode pour couvrir les défectuosités cutanées des moignons devant porter une prothèse.

Nos observations cliniques portent sur 320 malades chez lesquels 363 „greffons réticulaires" dermiques ont été transplantés, pour des raisons diverses, au cours de 337 opérations.

Dans le rapport présenté, nous passons en revue les données caractéristiques aussi bien en ce qui concerne les résultats opératoires immédiats que tardifs, en analysant à fond l'état fonctionnel et les changements morphologiques intervenus dans les „greffons réticulaires" transplantés librement, à des époques post-opératoires différentes.

Les observations effectuées longtemps après l'intervention nous permettent de démontrer la haute qualité des greffons ainsi que leur grande valeur fonctionnelle. Régulièrement, 5 à 7 mois après l'intervention, on assiste au retour de toutes les espèces de sensibilité ainsi que les fonctions physiologiques et les structures morphologiques commencent à réapparaître dans les „greffons réticulaires" transplantés. Chez les enfants, cette régénération a lieu encore plus rapidement.

Il résulte de ce qui vient d'être exposé que la méthode de dermatoplastie libre par „greffon réticulaire" présente aujourd'hui des possibilités très larges d'acquérir des partisans de plus en plus nombreux et mérite d'être employée intensément en chirurgie de reconstruction.

ZUSAMMENFASSUNG

Die Hautplastik mit dem „Sieb-Transplantat" in der Rekonstruktionschirurgie

M. I. Sinilo

Unter einer Reihe von Arten der freien Hauttransplantation verdient besondere Beachtung die Methode der Plastik mittels eines „Sieb-Transplantats", die einen grossen Erfolg der gegenwärtigen Epoche und einen bedeutenden Fortschritt in der Rekonstruktionschirurgie darstellt.

Die Plastik mittels eines „Sieb-Transplantats" zeichnet sich aus durch Einfachheit, technische Anspruchslosigkeit, einzeitige Operation, die Möglichkeit, grosse Defekte zu beseitigen, freie Auswahl des Ortes, an dem das Transplantat entnommen werden soll, durch schnelles Einheilen, Fehlen postoperativer Komplikationen und ein hochwertiges kosmetischen und funktionelles Ergebnis zugleich mit hoher Qualität der übertragenen Transplantate auch noch nach langer Zeit.

Diese Methode hat sich voll bewährt und wir verwenden sie in reichem Masse bei den verschiedensten Hautschädigungen oder bei deren Folgen wie zum Beispiel narbigen Kontrakturen, ferner bei Korrektion von Syndaktylien oder posttraumatischen Synechien, bei der Exstirpation langwieriger nichtheilender Geschwüre und chemischer Verätzungen, zur Deckung von Hautdefekten, die im Verlaufe rekonstruktiver operativer Eingriffe ebenso wie bei der Vorbereitung der Haut für eine nachfolgende rekonstruktive Knochenoperation entstehen, aber auch zur Deckung von Hautdefekten an Stümpfen mit nachfolgender Prothesenbenützung.

Wir beobachteten klinisch 320 Patienten, bei denen im Verlaufe von 337 Operationen aus verschiedenen Gründen 363 Hautübertragungen mittels des Siebtransplantats durchgeführt wurden.

In der vorliegenden Arbeit werden Daten mitgeteilt, die sowohl die Frühresultate als auch die Spätergebnisse der Operationen charakterisieren sowie den funktionellen Zustad und die morphologischen Veränderungen frei übertragener Siebtransplantate in verschiedenen Zeitabschnitten nach der Operation einer allseitigen Analyse unterziehen.

Beobachtungen in längeren Zeitabständen nach der Operation gestatten den Nachweis der hohen Qualität der übertragenen Hauttransplantate und ihrer hervorragenden funktionellen Eigenschaften. Im Verlaufe von fünf bis sieben Monaten treten regelmässig in den übertragenen „Siebtransplantaten" alle Arten der Empfindlichkeit, die physiologischen Funktionen und morphologische Struktur wieder auf. Bei Kindern geht diese Regeneration noch schneller vor sich.

Aus den angeführten Ergebnissen geht hervor, dass die Methode der freien Hautplastik mit dem „Siebtransplantat" mit voller Berechtigung immer mehr Anhänger finden wird und dass sie es vollauf verdient, in der Rekonstruktionschirurgie in breitesten Massstabe Verwendung zu finden.

Delivered at the International Symposium of Plastic Surgery in Mariánské Lázně (Czechoslovakia), June 28, 1960.

(Dr. M. I. Sinilo) : Ul. Vorovskogo 2—9, kv. 37, Stalino - Donbass 45, U.S.S.R.

Clinic of Plastic Surgery, Comenius University, Bratislava (Czechoslovakia)
Director: Doc. Š. Demjén, M. D.

THE SURGICAL TREATMENT OF GRANULATING WOUNDS FOLLOWING DEEP BURNS, USING THICK-SPLIT SKIN GRAFTS

Š. DEMJÉN

The author discusses the treatment of old, infected granulating wounds, which for some reason or other have not been properly treated in time.

If left to heal spontaneously, the area of the defect is covered with granulation tissue within about a week. Rapid formation of granulation tissue is an indication that the organism as a whole is healthy and that healing capacity is good. In the presence of mass infection of the wound surfaces and in organisms exhausted by a chronic disease or prolonged starvation, granulation tissue is formed slowly. At this stage of healing the granulation tissue acts as a mechanical barrier and a physiological filter against invasion of the organism by bacteria. The surface of granulation tissue is never sterile, because bacteria flourish in the warm, moist environment provided by the exudate. They do not penetrate deep, however, because the stroma of the granulation tissue, which is formed of a large quantity of capillaries and phagocytes, is an unsuitable medium for proliferation. This explains the familiar clinical finding that septicaemia usually develops before granulation tissue is formed and that as soon as the wound fills with granulation, pyrexia subsides.

In the further course of the healing process, the fibroblasts of the granulation tissue form a matted mass of collagen fibres. This transformation takes place within the wound, towards the surface, so that in old wounds healing by second intention a fibrous pseudodermic layer of varying depths is found below the granulation tissue. The longer spontaneous healing takes, the deeper is this fibrous layer. Fibrous tissue is also formed from granulation tissue below grafts. The author aims at achieving successful transplantation with the smallest possible layer of fibrous tissue, since if this layer is small, the graft contracts less and softens and recovers its sensitivity sooner.

It is also known from clinical experience that pus is retained in the form of small abscesses below the surface layer of old infected granulation tissue. It is true that washing the surface of the granulation layer with sterile physiological saline considerably reduces the number of bacteria, but it does not do away with them altogether and the saline does not reach the centre of suppuration below

the surface. If the conditions are not suitable for the transplantation of thick-split grafts, it is better to resort to thin Thiersch grafts, which are less exacting and can be expected to take even in this environment.

In some parts this covering is adequate. In others, however, such as the face and hands, it is definitely preferable, both for functional and cosmetic reasons, to use thick-split grafts for covering defects. In such cases the author recommends complete removal of the granulation tissue. This also removes bacteria from the wound and prepares better conditions for healing without suppuration. Biologically inferior tissue, which causes the graft to contract and delays softening and recovery of sensitivity, is also removed from the wound. Complete removal of the granulation tissue improves local conditions to such a degree that thick-split grafts can be expected, with a high degree of probability, to take successfully.

The operative technique is roughly as follows: Before the operation the milieu intérieur must be adjusted, i. e. fluids, blood, proteins, electrolytes and vitamins must be replenished. Local preparation consists in the frequent changing of dressings with hypertonic NaCl solution. This removes the residual dead tissue and bacteria, which are even washed away from the deeper folds of the granulation tissue by the osmotic stream of hypertonic solution. The parenteral administration of antibiotics is useful for prevention or in the case of mild complications, but does not improve the condition of the granulation tissue. In some cases local administration of a suitable antibiotic, selected after a sensitivity test, proves valuable.

After this general and local preparation, which takes only a few days, the whole of the granulation tissue is removed (under anaesthesia and with simultaneous blood transfusion), except for a thin fibrous layer in the subcutaneous fat. If this is done in the correct layer, the removal of granulation tissue is a simple matter and is not associated with copious haemorrhage. Light granulations can usually be removed in one piece. A blunt instrument is recommended for the operation, such as the back of a knife or a large blunt spoon. A sharp instrument would cut the granulations, causing needless haemorrhage, or would perforate the fibrous layer below. If the granulation tissue is removed whole, the residual capillary haemorrhage can soon be controlled by dressings saturated in warm physiological saline or cold penicillin solution.

When the bed is dry and haemorrhage has stopped, the thick-split graft is applied, unperforated, in large pieces. If, for some reason, complete haemostasis is not obtained, a dressing is placed over the wound and transplantation is postponed for 12 to a maximum of 24 hours (delayed transplantation).

The dressing is changed for the first time on the fourth day or even sooner, since these wounds form rather more exudate than completely sterile wounds. After cleaning away any secretion from the edges and emptying any haematoma or seroma, a compressive dressing is again applied very carefully. Further dressings are repeated at different intervals, according to the nature of the wound.

The above technique is used in cases in which the patient is admitted after the necrotic tissue has been eliminated and the defect is filled with clean or

infected granulation tissue, i. e 3—5 weeks after injury. In wounds several months old, the presence of a very thick fibrous layer below the granulations does not assure the thick-split graft adequate nutrition. This layer must be excised right down to a healthy, well vascularized base, in as far as the extent of the wound, the anatomy of the part concerned and the patient's general condition permit. Excision is obviously not possible if it would mean exposing bone, large blood vessels, nerves, cartilage or fascia. If the wound can be excised down to a definitely well vascularized base (fat, muscle), a thick-split graft can be applied. If not, the only alternative is to clean the granulation tissue mechanically and apply thin Thiersch grafts. After the wound has healed, this covering, if unsuitable from the functional or cosmetic aspect, can be exchanged for a thick-split graft or flap.

If a patient with deep burns is admitted before the necrotic parts have been eliminated, the following procedure is used: The first dressing is usually changed 10—14 days after injury. If autolysis and elimination of the dead tissue at the edges of the wound is already in progress, the necrotic parts are removed surgically under light anaesthesia. If the eschar is still firmly connected with the bed, separation of the dead tissue can be speeded up by compresses or bathing with sterile physiological saline. When the dead tissue has been completely eliminated from the wound, transplantation is carried out immediately, without waiting for granulation. If it is not absolutely certain, however, that all the dead tissue has been eliminated, it is better to wait for a few days and continue with physiological saline compresses (or Carelle's drains) until the wound is covered with fresh granulations, which are removed before applying the graft.

Granulation tissue must not be removed when changing dressings. If the granulations are curetted at an unsuitable time, it causes needless pain and haemorrhage and permits infection of the base of the wound, which was protected by the granulation tissue. Granulations can be removed in the operating theatre only, where this natural vasocellular covering can immediately be replaced by a split-skin graft, or in indicated cases by a flap.

SUMMARY

Thick-split graft ensure better functional and cosmetic results than thin grafts. The author gives a detailed account of the general and local preparation needed to ensure thick-split grafts taking in infected wounds following deep burns. Complete removal of granulation tissue is recommended, as this also removes bacteria from the wound and provides better conditions for healing without suppuration and also does away with biologically inferior replacement tissue, which causes the graft to contract and delays softening and recovery of sensitivity. Since in the early stages of healing granulation tissue acts as a mechanical barrier and physiological filter against invasion of the organism by bacteria, granulations are not removed when changing dressings, but only in the operating theatre, where this natural vasocellular covering can immediately be replaced by a free graft or, in indicated cases, by a flap.

ВЫВОДЫ

Хирургическая обработка гранулирующихся ран после глубокого ожога толстым дермоэпидермальным трансплантатом

Ш. Демьен

Толстые эпидермальные трансплантаты гарантируют лучшие функциональные и косметические результаты чем тонкие трансплантаты. Автор подробно описывает общую и местную подготовку, обеспечивающую приживление толстых дермоэпидермальных трансплантатов и на инфицированные раны после глубокого ожога. Автор рекомендует грануляции комплектно устранить. Вместе с грануляциями из раны устраняем бактерии и таким образом приготавливаем более подходящие условия для заживления без гноения. Кроме того из раны устраняем биологически менее ценную заменимую ткань, причиняющую контракцию трансплантата, продлеваем его обмягчение и восстановление чувствительности. Принимая во внимание, что грануляционная ткань в ранней стадии заживания функционирует в качестве механического препятствия и физиологического фильтра против проникания бактерий в организм, грануляции не устраняем в течение перевязок а только лишь в операционной, где это естественное вазоцеллюлярное защитное покрытие можно сейчас же заменить свободным трансплантатом или же в индикованиых случаях лоскутом.

RÉSUMÉ

Le traitement chirurgique des plaies granuleuses, après des brûlures profondes, par des greffons dermo-épidermiques épais

Š. Demjén

Les greffons dermo-épidermiques épais donnent des meilleurs résultats fonctionnels et cosmétiques que les greffons minces. L'auteur décrit en détail la préparation générale et locale qui assurent une bonne adhésion des greffons dermo-épidermiques épais même dans le cas d'une plaie suppurante après une brûlure profonde. Il recommande d'enlever complêtement le bourgeon charnu. Avec les granulations, nous enlevons en même temps les bactéries de la plaie, tout en créant des conditions plus appropriées à la guérison future en évitant la suppuration et, en plus, nous débarrassons la blessure des tissus de remplacement de valeur biologique inférieure qui provoquent la contraction du greffon et retardent son ramolissement ainsi que le retour de la sensibilité. Étant donné que le tissu de granulation joue, au début de la guérison, le rôle d'une barrière mécanique et d'un filtre physiologique empêchant la pénétration des bactéries dans l'organisme, nous ne l'écartons pas au moment des pansements, mais seulement à la salle d'opération où nous avons la possibilité de remplacer immédiatement cette protection vaso-cellulaire par un greffon libre ou, le cas échéant, lobulaire.

ZUSAMMENFASSUNG

Die chirurgische Behandlung granulierender Wunden nach tiefgehenden Verbrennungen mit einem groben dermoepidermalen Transplantat

Š. Demjén

Grobe dermoepidermale Transplantate gewährleisten ein besseres funktionelles und kosmetisches Ergebnis als dünne Transplantate. Der Verfasser beschreibt eingehend die allgemeinen Massnahmen und die lokale Vorbereitung, die das Einheilen grober

dermoepidermaler Transplantate sogar auf infizierten Wunden nach tiefgehenden Verbrennungen sicherstellen. Er empfiehlt eine vollständige Entfernung der Granulationen. Mit den Granulationen werden aus der Wunde auch Bakterien entfernt und so vorteilhaftere Bedingungen für eine Heilung ohne Eitern hergestellt; ferner wird derart aus der Wunde biologisch minderwertiges Ersatzgewebe beseitigt, das eine Kontraktion des Transplantats verursacht und seine Erweichung und das Wiederauftreten der Empfindlichkeit verzögert. Im Hinblick darauf, dass das Granulationsgewebe im Frühstadium der Wundheilung als mechanisches Hindernis und physiologischer Filter gegen das Eindringen von Bakterien in den Organismus dient, werden die Granulationen nicht während des Verbandwechsels, sondern erst auf dem Operationssaal entfernt, da hier diese natürliche vasozelluläre Schutzbarriere sogleich durch ein freies Transplantat oder in indizierten Fällen durch einen Lappen ersetzt werden kann.

REFERENCES

1. **Mc. Cormack:** Plast. reconstr. Surg. 19, 6, 1957.
2. **Eade:** Plast. reconstr. Surg. 22, 7, 1958.
3. **Greely, Curtin:** Plast. reconstr. Surg. 19, 5, 1957.
4. **Goldenberg:** Plast. reconstr. Surg. 8, 7, 1951.
5. **Greeley:** Plast. reconstr. Surg. 9, 1, 1952.
6. **Hempill, Brown, J. B.:** Plast. reconstr. Surg. 14, 8, 1954.
7. **Lelio Zeno:** Free Skin Graft Immobilisation with Plasten.
8. **Mills, J. T., Patherson, J. B., Hauze, R. E.:** Plast. reconstr. Surg. 3, 5, 1948.
9. **Miry-Mir:** Plast. reconstr. Surg. 8, 11, 1951.

Delivered at the International Symposium of Plastic Surgery in Mariánské Lázně (Czechoslovakia), June 28, 1960.

(Doc. Š. Demjén) : Partyzánská 1, Bratislava, Czechoslovakia

Balneology Research Institute, Mariánské Lázně (Czechoslovakia)
Director: Prof. K. Přerovský

EXPERIENCE WITH THE SPA TREATMENT OF PATIENTS RECUPERATING FROM BURNS

P. ŠTEPÁNEK

We have had the opportunity, at the Mariánské Lázně Rehabilitation Institute, to treat a number of patients recuperating from thermal injuries in addition to patients convalescing from accidents and orthopaedic operations. The strikingly good results obtained with the spa rehabilitation program prompted us to present a preliminary report previously (1958). In 1959 we began a systematic study at the Balneology Research Institute and thus far we have treated 30 patients who were referred to us from specialized departments in Prague and Ostrava.

The majority of the patients had suffered 2nd and 3rd degree burns ranging from 10 to 75% of the body surface. When admitted to our Institute they were anatomically either completely or almost completely healed. Hospitalization in the specialized departments had ranged from 1 to 11 months, with an average of 3 months. Twenty-one patients were completely immobilized after the accident for more than 4 weeks. The time interval between the accident and commencement of spa treatment was from 3 months to 3 years.

Clinical and laboratory examinations were directed to obtaining a picture of the effects left by the injury.

In about half of the patients a considerable deterioration in the general condition was noted: fatigue, malaise, shortness of breath and tachycardia with noticeable perspiration upon relatively slight exercise. Local muscle weakness, particularly in the injured limbs, was observed in 18 patients. The reduction in muscle power averaged around one grade in the muscle test. Contractures which restricted the movements of certain joints were found in 9 patients. Frequent complaints of arthralgia and diffuse pains in the lower limbs and lower back pain appeared to be due to relative muscular insufficiency following long immobilization. In exceptional cases the symptoms were related to contractures. The body weight of the majority of patients at the time of treatment in our Institute was approximately that prior to the accident. In only 4 cases was the weight about 10% below that before the accident. In 3 cases it was 15 to 35% above the pre-accident weight. The patients found it difficult to tolerate various forms of

paresthesia described as burning, itching, tingling and smarting, which increased in intensity especially with sudden changes in temperature or at night, waking the patients up. These complaints, to varying degrees, were noted in 22 patients. There was a strikingly frequent occurrence of post-traumatic neurosis which is much more common in patients with thermal injuries than in others. In this respect, the frequency of neurosis is almost comparable to that seen in paraplegics suffering from accidents of the spine and spinal cord. It is believed that this aspect would merit further study.

Curling's ulcers were not found in a single case after careful clinical and X-ray study. In 4 cases severe constipation was noted and was probably related to the long immobilization and weakening of the abdominal wall. Anorexia of a more serious character was seen in 5 patients.

Hepatic function was estimated by ordinary laboratory tests (Weltman reaction, thymol turbidity reaction, Takata reaction, serum bilirubin and in some cases the galactose test). We were conscious of the fact that the tests used are not specific and that the results in burned patients could easily be due to plasma dysproteinaemia. This was the reservation expressed when judging the possible presence of persisting hepatic lesions in 4 patients.

Systematic attention was paid to the kidneys and the urinary tract. Endogenous-creatinine clearance, renal concentration and the chemical and cellular (Addis count) composition of urine were studied, as well as serum non-protein nitrogen. Disturbed renal function was found in 4 patients, as shown by the following table.

	Reduced glomerular filtration	Concentration test	Proteinuria	Urinary sediment	
				ery.	leuc.
1.	34.0%	1,018	1.36 g/24 hr.	++	+
				++	+
2.	50.8%	1,015	0.67 g/24 hr	—	—
3.	42.0%	1,018	———	—	—
4.	27.5%	1,033	opalesc.	—	—
5.	28.5%	1,035	———	—	—
6.	30.5%	1,030	———	—	—

In the first 2 cases there was an increase of both leucocytes and erythrocytes in the Addis sediment with a distinct predominance of erythrocytes. Urolithiasis was not observed in spite of the presumptive evidence that its occurrence would be common due to long-term immobilization and osteoporosis. Urolithiasis has been repeatedly reported in the literature.

The most variable factor in the spa regime is the alternating periods of rest and physical activity which is not only modified in individual cases but also

in the course of treatment itself. The spa surroundings with its varied terrain enables one to select suitable walks, gradually leading to more vigorous walking tours. Remedial excercises are aimed at improving the general body condition as well as muscle strength. They include breathing exercises, postural exercises and exercises to strenghten the abdominal muscles particularly in cases of constipation. They promote better circulation especially in the lower limbs where oedema often persists. Patients are individually instructed in strenghtening groups of muscles, loosening contractures and improving muscle coordination. As a preparation for exercises, particularly in cases of contractures of soft tissues, warming with mud baths or a series of subcutaneous injections of spring gas (CO_2) in amounts of 100—300 ml. have been found to be beneficial. Exercises in the swimming pool or work therapy are suitable in cases which require improved muscle coordination and the training of finer movements.

Good results have been cbtained with carbon dioxide baths in improving trophic function. The paraesthesia mentioned earlier quickly subsides. Scars become softer and more elastic, sores are less common and the red scar surfaces become pale, moreover, unhealed skin defects are quickly covered with epithelium in the carbon dioxide baths. Paraesthesia due to change in temperature is helped by alternating baths with an initial temperature difference of 4—5^0 C., gradually increasing to 15—18^0 C.

Glauber's water (Ferdinand and Cross springs) is usually drunk twice a day in the fasting state for purposes of remineralization. The results have been good in so far as normalization of gastrointestinal function is concerned (constipation). Mineral water from the Rudolph spring which has a diuretic effect is drink 3—4 times in the course of treatment in amounts of 2—3 litres as a preventive measure against nephrolithiasis even though not clinically apparent.

The diet, provided there is no contraindication, contains increased amounts of protein and fresh fruits and vegetables.

Our experiences show that spa therapy can have a beneficial effect and hasten normalization of body functions after burns, shorten the period of convalescence and considerably ease the transition to normal life. It also serves as suitable preparation for further plastic surgery. The most suitable patients are those sent with anatomically healed injuries. In patients, whose injuries were sustained a long time previously, the results are not as good and spa treatment for the burns only is not recommended.

SUMMARY

On the basis of encouraging experiences from the spa Rehabilitation Institute in Mariánské Lázně the author has systematically studied the effect of spa therapy in patients recovering from thermal injuries. In 1959 30 patients sent by specialized departments in Prague and Ostrava undertook the five-week cure. In half of the patients there was a persistence of the effects of injury, i. e, lowered general condition and strength; 60% suffered from a weakening of muscle strength in the injured limbs. Contractures which prevented free movement

were found in 30%; 73% of the patients complained of paraesthesia. There was a strikingly frequent occurrence of post-traumatic neurosis. Curling's ulcers were not found. Severe constipation was present in 13% and possible persistence of the hepatic lesion in 13%. Reduced glomerular filtration (27.5—50.8%) was noted in 6 patients, of whom 3 had reduced tubular concentrating power and 2 proteinuria. Urolithiasis was not seen. The spa regime consists of drinking mineral water to remineralize the body and to overcome constipation as well as to prevent urolithiasis. In addition, carbon dioxide baths improve the circulation and trophic function and alleviate dysthesia and paraesthesia which are often extremely unpleasant for the patient. The baths promote quick healing of persisting small skin defects. Mud baths are used as a preparation for exercises to overcome contractures. Remedial training, both general and local, exercises in the swimming pool and work therapy are used to a great extent. Walking tours of graded intensity to the surrounding hillsides permit gradual improvement of the patients' general condition. Diet consists of large amounts of fresh fruit and vegetables and a high protein content, provided the later is not contraindicated.

ВЫВОДЫ

Первый опыт долечивания на курорте послеожоговых состояний

P. Štěpánek

На основании ободрительного опыта из Института восстановительной терапии в г. Марианске Лазне, автор начал накоплять опыт в курортном долечивании пострадавших от ожога. В 1959 г. постепенно подвергались пятинедельному курсу лечения 30 больных, выбранных специализированными отделениями в Праге и Остраве. У половины больных наблюдалось существенное ухудшение физического состояния и понижение работоспособности. Шестьдесят процентов больных страдало уменьшением силы мышц пораженных конечностей. Контрактуры, ограничивающие движения в суставах, наблюдались у 30 %. На парестезии жаловалось 73 %. Поразительно часто встречались посттравматические неврозы. Изъязвления Керлинга не были доказаны. Упорный запор со времени ожога был — 13 %, подозрение на существующее до сих пор поражение паренхимы печени было выражено у 13 %. Понижение клубочковой фильтрации (на 27,5—50,8 %) наблюдалось у 6 больных, из числа которых одновременно у трех больных была патологически понижена концентрационная способность почек, а у двух была установлена протеинурия. Уролитиаз у этой сравнительно небольшой группы не был доказан. Курортное лечение использует питье местных минеральных вод с целью реминерализации, для воздействия на запор и с целью предупреждения образования мочевых камней. Углекислые ванны улучшают отношения кровообращения и трофики, они оправдали себя при субъективно зачастую очень неприятных дизестезиях и парестезиях; эти ванны способствуют быстрому заживлению существующих еще мелких кожных дефектов. Грязевые компрессы применялись для согревания перед упражнениями пораженных контрактурами суставов. Широко используется местная и общая лечебная физкультура, упражнения в бассейне и лечение трудом. Дозированное лечение прогулками предоставляет возможность постепенно нагружать организм соответственно улучшению общего состояния. Лечебное питание заключается в наибольшем содержании в пище фруктов и овощей в сыром виде, а поскольку нет противопоказаний, также в большом содержании в пище белков.

RÉSUMÉ

Les premières expériences avec la balnéothérapie des séquelles des brûlures

P. Štěpánek

Suivant les expériences favorables obtenues en Institut de la balnéologie et physiotherapie en M. L., l'auteur ramassa les expériences de la balnéotherapie des brûlés. En 1959 en somme 30 malades qui ont subi des brûlures graves, ont été soignés au cours de 5 semaines, à l'Institut cité ci-dessus. Tous ont été envoyés par les cliniques spécialisées de Prague et d'Ostrava. La moitié de ces malades souffrait d'une importante perte de la force exécutive et se plaignait d'une remarquable faiblesse de constitution. 60 pour cent en souffraient de la faiblesse musculaire des membres endommagés. 30 pour cent en avaient des contractures qui gênaient les mouvements des articulations. 73 pour cent se plaignaient des paresthésies. Le frappant, c'était les nombreuses névroses posttraumatiques Les ulcères de Curling n'ont jamais été signalés. 13 pour cent en souffraient d'une constipation grave. Auprès de 13 pour cent de malades se trouvai suspect d'une lésion du parenchyme hépatique. L'abaissement de la filtration glomérulaire (27,5—50,8 %) se trouvait chez 6 des malades, 3 d'entre eux avaient en surplus un abaissement pathologique de la faculté de concentration d'urine et deux d'entre eux souffraient d'albuminurie. Urolithiase, peut-être faute de peu de cas, était absente. La thérapie balnéologique se sert de la cure de boisson, pratiquée à l'aide des eaux minérales pour obtenir la reminéralisation de l'organisme, pour maîtriser la constipation, et pour prévenir l'urolithiase. Les bains carbo-gazeux améliorent la circulation du sang et la trophicité des tissus : ils ont été favorables au cas des dysesthésies et paresthésies bien mal supportées. Ils favorisent la guérison de petites lésions cutanées de longue durée. Bain de boue fut employé pour réchauffer les mebres avant l'exercice des contractures. On emploie bien souvent de la gymnastique médicale pratiquée même au cours du bain, et la thérapeutique par le travail. La thérapeutique par le sport, bien organisée, permet de charger successivement l'organisme en corrélation avec l'ammélioration de son état general. La thérapeutique alimentaire, riche en légumes et fruits crus de même qu'en protéines partout, où il n'y a pas de contraindications, c'est prouvée nécessaire.

ZUSAMMENFASSUNG

Die ersten Erfahrungen mit der Nachbehandlung in Badeorten bei Zuständen nach Verbrennungen

P. Štěpánek

Auf Grund von ermutigenden Erfahrungen aus dem Bäderrehabilitationsinstitut in Marienbad begann der Autor Erfahrungen mit der Bädernachbehandlung von Verbrennungen zu sammeln. Auf Vorschlag von Spezialabteilungen in Ostrau und Prag unterzogen sich im Jahre 1959 30 Kranke einer fünfwöchigen Kur. Bei der Hälfte bestand eine wesentliche Herabsetzung der körperlichen Kräfte und Leistungsfähigkeit. Sechzig Prozent litten an einer Herabsetzung der Muskelkraft der betroffenen Extremitäten. Kontrakturen, die den Bewegungsumfang in den Gelenken einschränkten, waren in 30 % vorhanden. Über Paraesthesien beklagten sich 73%. Auffallend häufig war das Vorkommen von posttraumatischen Neurosen. Curlingsche Ulzerationen waren nicht nachweisbar. Eine hartnäckige Obstipation seit dem Unfall bestand bei 13%, Verdacht auf eine andauernde Schädigung des Leberparenchyms bei 13%. Eine Senkung der glomerulären Filtration (um 27,5—50,8%) bestand bei 6 Kranken. Gleichzeitig war bei ihnen dreimal eine pathologisch herabgesetzte Konzentrationsfähigkeit der Nieren und zweimal

Proteinurie vorhanden. Urolithiasis konnte bei diesem relativ kleinen Krankengut nicht nachgewiesen werden. Die Bäderbehandlung verschreibt die Trinkkur mit örtlichen Mineralwässern zur Remineralisation, Beeinflussung der Obstipation und Prophylaxe einer Urolithiasis. Kohlensäurebäder verbessern die Zirkulations- und trophischen Verhältnisse und haben sich bei subjektiv manchmal sehr unangenehmen Dysästhesien und Parästhesien bewährt. Sie unterstützen eine rasche Abheilung von noch bestehenden kleinen Hautdefekten. Moorpackungen wurden zur Vorwärmung vor Gelenksübungen bei Kontrakturen verwendet. In reichlichem Ausmass wurde auch allgemein und lokal abzielende therapeutische Heilgymnastik, Übungen im Bassin und Arbeitstherapie verwendet. Eine dosierte Terrainbehandlung bietet die Möglichkeit, den Organismus entsprechend dem sich bessernden Allgemeinbefinden einer allmählich steigenden Belastung auszusetzen. Die Diät soll einen möglichst grossen Anteil von Rohobst und Gemüse und — soweit es nicht kontraindiziert ist — auch einen hohen Eiweissgehalt aufweisen.

REFERENCES

1. **Štěpánek, P., Štěpánková, J.:** Voj. zdrav. Listy 27 : 557—560, 1958 (12).
2. **Zeman, J.:** Návratná starostlivosť u stavov o popáleninách. Have been introduced on the Dermatovenerological Conference, Smrdáky 1957.
3. **Kostka, D.:** See above mentioned paper.

Delivered at the International Symposium of Plastic Surgery in Mariánské Lázně (Czechoslovakia), June 28, 1960.

(Dr. P. Štěpánek) : Výzkumný ústav balneologický, Mariánské Lázně, Czechoslovakia

Uritsky Hospital, Leningrad (USSR)
Director: Prof. D. A. Shushkov, MD, Cand. Med. Sc.

THE USE OF FOREARM TISSUE ON A NEUROVASCULAR PEDICLE FOR RECONSTRUCTION OF THE UPPER EXTREMITY IN PLACE OF HIGH AMPUTATION OR EXARTICULATION

J. B. RYVLIN

In 1946 the author's report on "Lengthening of a Thigh Stump by Transplantation of the Leg on a Vascular Pedicle" was published in Vestnik Chirurgii No 1.

The method used differs considerably from the operation suggested by Sauerbruch. Its significance lies in the fact that the extent of mutilation may be diminished in cases where amputation in the upper third of the thigh is indicated. The lengthening of the thigh stump by means of the transplanted leg facilitated the fitting of an artificial limb, but mainly ensured satisfactory walking. The author performed this operation in three patients, one of whom was afterwards followed up for five years. He used his artificial limb very well and continued working in his original occupation as foreman of a workshop (Fig. 1). The stump was in very good condition. From a neurological point of view the only difference was in the sensation the patient experienced on scratching his thigh; he had the feeling that he was scratching his leg. This shows that no transformation of the segmentary nerve supply in the leg had taken place up to that date. As far as its anatomico-physiological function was concerned, the leg transplanted to the thigh still remained a leg. Lengthening of the thigh provided all preconditions for its serving as an endbearing stump.

Having thus ascertained that no disorder of the blood supply to the extremity develops on transplantation of the leg on a vascular pedicle, the author soon afterwards performed an analogous operation on the upper extremity. This case proved very interesting.

On May 23, 1943 a woman — J., aged 52 — was admitted to the surgical department of the Central Institute of Medical Radiology with a growing tumour in the upper third of the right arm. She complained of losing weight and of lack of sleep caused by pain. The tumour, first considered to be a benign neurinoma, had been removed by operation twice previously; in 1942 and 1944. At the time of admission to the department the patient had completed a course of X-ray treatment which, however, was ineffective. Exarticulation of the upper extremity

was recommended, but the patient categorically refused to submit to such an operation.

On the anterior aspect of the arm there was a scar 20 cm. long. The tumour, the size of an adult double-fist, was situated in the upper third of the scar near the shoulder joint crossing the delto-pectoral groove on the medial side onto

Fig. 1. View of the thigh after transplantation of the leg on a neurovascular pedicle (the author's own observation).

the pectoral muscles, and on the lateral side extending into the axilla. The tumour had a tough elastic consistency and was firmly adherent to the pectoralis major. The skin covering the tumour was thinned, the movements of the shoulder joint limited. All types of sensitivity were intact. The author, therefore, recommended replacement of the arm by the forearm to which the patient agreed.

On May 31, 1945 the operation was performed under general ether anaesthesia. A blood transfusion was given at the same time. The incision skirting the tumour was made into healthy tissue and severed the pectoral muscles on the one side and the upper third of the arm on the other. The tumour was then removed together with parts of the pectoralis major and minor and with the axillary glands. During the operation it became evident that the tumour had invaded the shoulder joint capsule. The radical removal of the tumour and the exarticulation of the humerus produced an extensive wound defect reaching from the shoulder joint to the elbow.

In the flap suspending the forearm and hand from the shoulder the vessels and nerves of the arm remained intact, together with parts of the extensor muscles and the skin of the dorsal aspect of the arm. In order to make a stump

from the forearm the following was necessary: The hand was amputated above the styloid processes. The skin of the forearm was incised along its anterior aspect and mobilized on both sides. The cartilage of the articular surface of the glenoid cavity was removed. The forearm was rotated in a sagittal plane by 180 degrees and inserted with the sawn-off end into the glenoid cavity. To close the

Fig. 2. Patient after replacement of the arm by the forearm.

wound on the thorax the breast had to be mobilized by a special incision and transposed so that a definite covering of the postoperative wound defect could be achieved immediately. Finally, a plaster cast was applied with the stump in a functionally suitable position.

This time the microscopic examination showed a polymorphonuclear sarcoma. Two months later the plaster cast was removed and on October 10, 1945 the patient was discharged home. The range of movements performed by the movement of the shoulder blade was satisfactory. For two years the patient was able to use the stump and to look after herself. After this period deterioration of the general condition took place, and the patient died. On post mortem examination tumour secondaries were found in the lungs. The operation region was without metastases and no local recurrence of the tumour was found.

As can be seen by the case described above, the replacement of the arm by the forearm could be performed without much difficulty. As with the lower extremity, healing-in of a great part of the limb transposed on a neurovascular pedicle could be achieved though there was considerable bending of the arteries, veins and nerves (Fig. 2, 3).

This patient, like the patient with the surgically lengthened stump of the thigh, also persistently experienced a sensation on scratching or pressing on the transplant as though the forearm were still in its original position.

Transposition of the leg in place of the thigh or of the forearm in place of the arm by a rotation of 180 degrees does not, inspite of the nerves running in

Fig. 3. Skiagram of patient with replacement of the arm by the forearm. Both forearm bones are visible the distal ends of which are inserted into the glenoid cavity.

a direction contrary to nature, evoke any transformation of the respective cortical centres regardless how long a period has elapsed from the operation; whether months or years. The condition of the transplanted part of a limb, as described above, has nothing in common with the phantom syndrome and does not handicap the patient in the use of a prosthesis.

From these experiences the idea emerged of widening the scope of the reconstructive operation by replacing the arm without amputation of the hand, which may be left in place until the transplant has healed into the wound defect.

In the further course, based on the intact segmentary innervation and a good blood supply, it should be possible not to leave the forearm at its new site, but after forming a support for the arm to return it to its original position.

With regard to the present standard of plastic surgery concerning the replacement of the skin defects and to the powerful effect of antibiotics in combating pyogenic infection, the author considered it possible to perform this type of reconstruction of a limb in two stages.

First stage: The humerus is exacticulated at the shoulder joint through an atypical incision and removed together with the affected soft parts after having been sawn off above the level of the epicondyles. The flap connecting the shoulder with the forearm must always contain the intact brachial artery and if possible all nerves including the radial nerve.

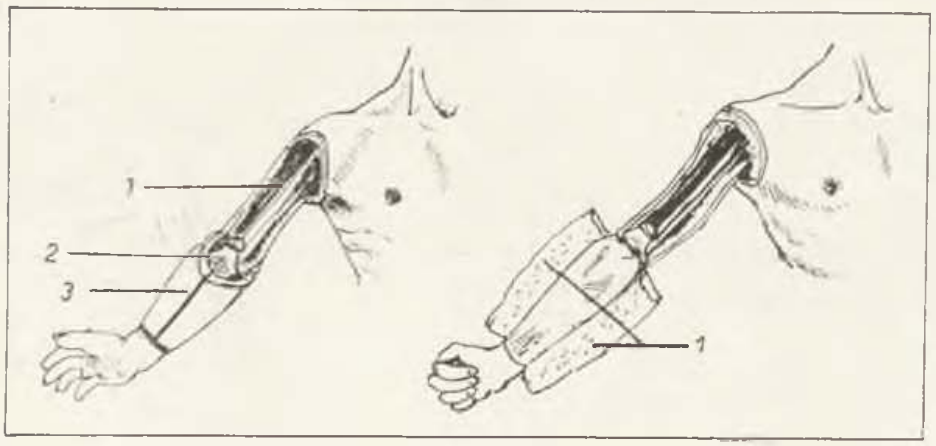

Fig. 4. Fig. 5.

Fig. 4. View of the upper extremity after removal of the humerus and a considerable part of the soft tissue. 1 — neurovascular pedicle, 2 — remainder of the humerus, 3 — skin incision on the forearm for shaping the flaps on its anterior aspect. — Fig. 5. The flaps (1) are mobilized on both sides. They consist of skin and subcutaneous tissue. On the anterior aspect of the forearm the common fascia can be seen.

On the dorsal side part of the triceps muscle and the skin of the dorsal aspect of the arm should be preserved. On the anterior surface of the forearm a T-shaped skin incision is made severing the subcutaneous tissue down to the fascia (Fig. 4). Through this incision the skin is mobilized on both sides so that two flaps are formed big enough to cover the wound defect in the region of the uncovered neurovascular bundle of the arm and to form a reserve of skin for the second stage operation (Fig. 5). The second stage can be performed in two ways.

First alternative: the forearm, which has healed-in at its new site, is separated from the arm so that part of its skin and subcutaneous tissue remains on the arm and can be used to close the wound after the plasty has been completed. The separated forearm is then temporarily extended. On the arm a bed is formed for a bone transplant reconstructing the humerus in order to give support to the limb. For this purpose the patient's fibula can be used. A piece of sufficient length is resected and inserted into the remnant of the humerus left from the first stage (region of the epicondyli) at the one end and into the glenoid cavity at the other. The operation wound is then sutured. For the osteoplasty lyophilized homografts of the fibula from fresh cadavers or even nails of artificial material sufficiently long and thick may also be used (Fig. 6 and 7).

The second alternative is based both on the peculiar mode of biological adaptation of arteries bent at various angles and in different planes, and on local bone autoplasty. The incision on the forearm is made so that after separating the forearm from the arm, sufficient skin should remain to cover the defect in the arm together with its new bone support.

For this purpose it is necessary to make the skin incision on the dorsal aspect of the forearm at a level corresponding to the interosseal space and on the volar aspect along the scar or somewhat medial to it.

Then the bone graft of sufficient length is cut out of the radius by an electric saw just medial to the radial artery. After sawing through, the graft remains

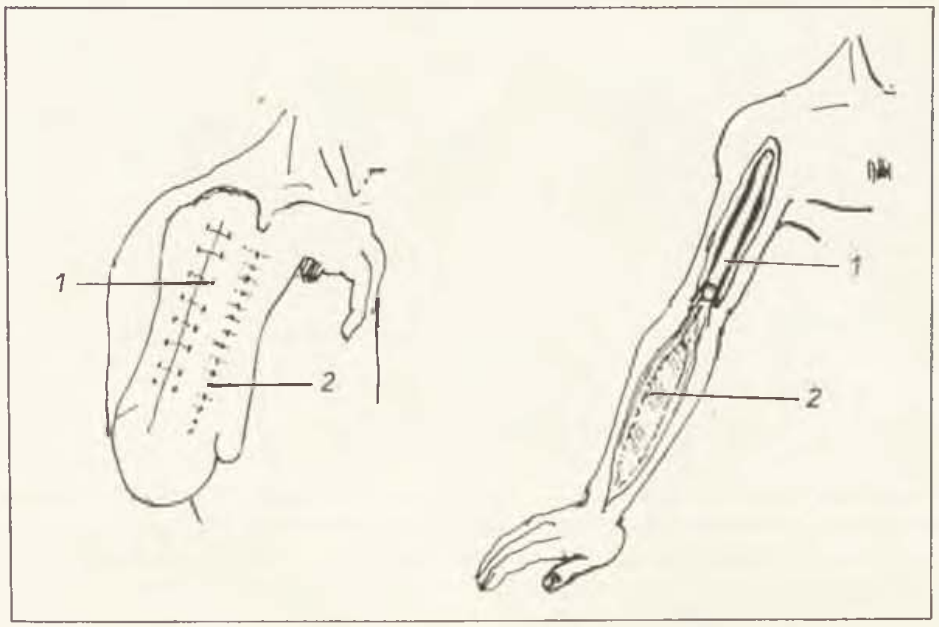

Fig. 6. Fig. 7.

Fig. 6. The view of the "new" arm after suturing of the forearm to the remnants of the arm. 1 — the suture line on the lateral side of the arm, 2 — the dotted line indicates the row of stitches on the medial side of the arm. — Fig. 7. Diagram of the second stage operation. The forearm has been separated from the arm, 1 — transplant of the fibula lies in the prepared bed of the arm, 2 — the skin defect after returning the forearm to its original position and the use of parts of its skin to cover the graft in the arm.

attached to the periosteum and the radial artery. The latter is then tied just above the radiocarpal joint by two ligatures and severed between them. The graft together with the artery is then turned up so that its distal end can be fixed into the glenoid cavity. The other end is fixed to the remainder of the humerus left from the first stage operation. The remaining part of the radius is left *in situ.*

The second alternative is more complicated than the first, but by this method of reconstruction of the humerus the transplant always takes. In the further course no transformation of the transplanted section of the radius takes place, such as occurs in a freely transplanted bone graft and which does not always result in adequate bone regeneration.

In conclusion the skin defect of the forearm must be closed. The simplest method is to cover it by the transplantation of a full-thickness free skin graft from the back (Fig. 8).

The end result of the operation is ankylosis of the shoulder joint in the best functional position for the extremity.

The author performed both alternatives on cadavers many times and is convinced that the use of a forearm transplant with the neurovascular bundle preserved for the reconstruction of the arm emerges quite naturally from contemporary experience with osteoplastic surgery, founded by the ingenious surgeon N. J. Pirogov.

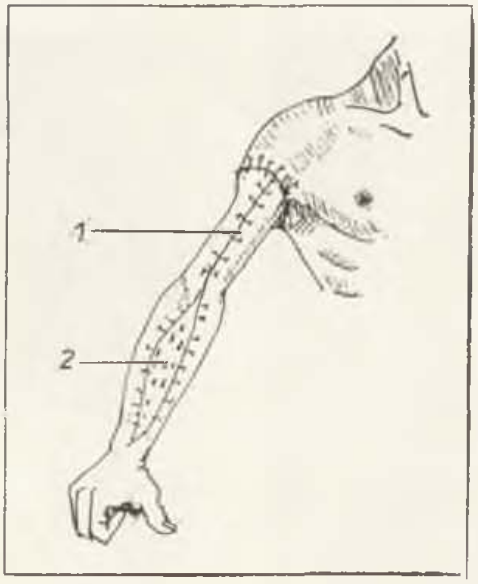

Fig. 8. View of the extremity after completion of the second stage operation. 1 — the transplant of the arm covered with skin, 2 — the skin defect on the forearm covered with a free skin graft.

The following patient was operated on by one alternative, described above:

N., a man aged 26, was admitted with pain in his right shoulder accompanied by limitation of movement in the joint and anorexia, in May 1947. In the upper third of the arm there was a tumour the size of an egg, tender on pressure. The movement of the shoulder joint was free but painful. Further, slight hypochromic anaemia and a general muscular weakness was found. The X-ray showed evidence of an osteogenic sarcoma of the arm. Skiascopy of the lungs and skiagraphy of the other bones did not show any secondaries. Exarticulation of the limb was recommended which, however, the patient categorically refused. Therefore replacement of the arm by the forearm with preservation of the hand and subsequent reconstruction of the extremity was suggested.

On June 15th the operation was performed under ether anaesthesia and with a blood transfusion running simultaneously. The incision was made mainly on the posterio-lateral and partly on the anterior aspect of the arm, and then exarticulation both at the shoulder and elbow joints with removal of a considerable part of the soft tissues, was performed. The nerves and vessels of the arm remained preserved. The incision was then extended onto the forearm almost to the wrist. Two skin flaps were formed on the anterior aspect of the forearm which was then swung upwards. The skin remaining on the posterior aspect of the arm was sutured to the skin of the flaps of the forearm. The rest of the wound was then sutured and a plaster slab was applied for immobilization.

From the second day after operation the patient was able to move his hand and fingers freely. On the 10th day the slab was removed and the stitches taken out. The wound had healed by first intention. The patient was able to grasp objects with his fingers without difficulty. The range of movement in the radiocarpal joint was normal (Fig. 9 and 10).

Fig. 9.

Fig. 10.

Fig. 9. View of the extremity after replacement of the arm by the forearm on a neurovascular pedicle. On the lateral aspect remnants of skin of the arm and the scar indicating the border line between the arm and the forearm, are visible. — Fig. 10. Anterior view of the transplanted forearm. Movements of the hand and fingers completely preserved. On the medial aspect remnants of the skin of the arm and the scar, where it joins that of the forearm, are visible.

As can be seen from the figures the radial side of the forearm was applied to the remaining soft tissue of the arm. The skin reserve for the second stage operation was quite sufficient. The second stage was planned a month after the first. Due to circumstances, over which the author had no control, the second stage operation could not be performed at the fixed date. Four months after operation the patient died from lung secondaries.

At *post mortem* the extremity together with the shoulder blade was removed for contrast angiography. This proved absolute patency of the main and numerous collateral vessels.

As can be seen from the photograph of the patient, leaving the extremity in this position is more useful to the patient than amputation or exarticulation.

After the first stage operation full range of movements of the hand and fingers was preserved. For four months the patient was able to look after himself and with the aid of the remaining part of the extremity to eat, dress and wash himself. He could even write with this hand.

In this way we reach the second stage in the reconstruction of the extremity, instead of performing an exarticulation which always causes considerable mutilation.

We had no chance of carrying out the idea of reconstructing an extremity in two stages, although the author was firmly convinced that the second stage operation was not only possible but expedient. He, therefore, decided to chose the most difficult alternative of reconstruction of the upper extremity in an experiment with dogs. A total of five experiments was carried out on the forelegs, one of which is described below.

On May 17, 1956 a male dog weighing 8 kg. was operated on under ether anaesthesia. Extirpation of the humerus together with parts of the soft tissues was performed and the wound sutured. The postoperative course was complicated by partial suppuration. Three and a half months later the second stage operation was carried out. The radius was layed bare and sawn through just above the radiocarpal joint. The interosseous membrane was severed. The distal end of the radius was then placed into the glenoid cavity and fixed there by silk sutures. The radial and interosseal arteries, the size of the latter equalling that of the ulnar artery, remained attached to the radius. After that the forearm was completely separated from the arm and returned to its original position. The placing of both bones in a mutually reversed position was accompanied by some difficulties due to contracture and partial fibrotic degeneration of the muscles which caused a fracture of the ulna in the lower third without displacement. The wound was sutured and the extremity immobilized in a plaster cast. Immobilization was discontinued after two months during which the plaster cast was changed twice. Three months after operation the dog used its foreleg on walking and gnawing a bone although it remained somewhat shorter.

On the X-ray the position of the arm and forearm bones can be seen. The radius has taken over the function of the humerus and is slightly thickened. At the site of the fracture callus formation is visible. The dog was under observations more than one year.

The described operation is indicated in the following disorders:

1. Tangential gunshot wound of the arm which has caused severe laceration and contusion of the soft tissues and, at the same time, total loss of bone in the whole extent of the arm, but where the neurovascular bundle has been preserved.
2. Analogous injuries after industrial and road accidents.
3. Extensive benign tumours necessitating amputation or exarticulation (osteoma, ostechondroma, chondroma, some forms of osteitis fibrosa cystica).
4. Extensive chronic and exacerbating osteomyelitis of the entire humerus affecting the soft tissue with early signs of amyloidosis.
5. Initial forms of sarcoma of the humerus or the soft tissues in cases where the patient refuses high amputation or exarticulation.

The latter indication is to be regarded as a relative one. It has been mentioned, because this operation makes it possible to remove the whole of the affected parts as in exarticulation of the extremity as well as to extirpate all axillary glands radically as in amputation of the breast for carcinoma.

SUMMARY

1. The author considers it as proved that the arm can be replaced by a transplant of the forearm on a neurovascular pedicle. The normal blood circulation in the reconstructed arm is secured by the high elasticity of the vessels easily permitting rotation by 180 degrees. The same may be said about the nerves of the extremity.

2. Preserving of the hand with its fingers on replacement of the arm by the forearm created the prerequisite for the subsequent stage of the operation, the aim of which is the reconstruction of the whole extremity.

3. This possibility is borne out by the results of the experiments on cadavers and in animals.

4. If reconstruction of the upper extremity is being conceived in place of amputation or exarticulation, it is necessary to carry out the second stage one month after the first operation at the latest.

ВЫВОДЫ

Материалы к реконструкции верхней конечности из предплечья на сосудисто-нервной ножке вместо высокой ампутации или экзартикуляции ее

Я. Б. Рывлин

1. Можно считать доказанным факт замещения плеча предплечьем на сосудисто-нервной ножке. Нормальное кровообращение восстановленного плеча обязано высокой пластичности сосудов, легко выносящих поворот на 180.

То же можно сказать и о нервах конечности.

2. Сохранение кисти и пальцев при замещении плеча предплечьем создает предпосылки для следующего этапа реконструктивной операции, имеющей целью восстановление всей конечности.

3. Опыты на трупах, а также эксперименты на животных подтверждают эту возможность.

4. При производстве двухэтапного восстановления верхней конечности вместо высокой ампутации или экзартикуляции ее следует второй этап операции производить не позднее месяца после первого.

RÉSUMÉ

L'emploi des tissus de l'avant-bras sur pédoncule vasculo-nerveux pour la reconstruction de l'articulation supérieure, remplaçant la haute-amputation ou l'exarticulation

J. B. Ryvlin

1. Nous considérons comme démontré qu'il est possible de remplacer le bras par greffe de l'avant-bras sur pédoncule vasculo-nerveux. La circulation normale à l'intérieur du bras reconstruit se trouve assurée, grâce au fait que les vaisseaux sont extrêmement

plastiques et supportent facilement une torsion de 180°. Il en est de même en ce qui concerne les nerfs des articulations.

2. La conservation de la main et des doigts lors du remplacement du bras par l'avant-bras permet de créer les conditions nécéssaires aux étapes ultérieures des opérations de reconstruction, dont le but final est la reconstruction du membre tout entier.

3. Les résultats obtenus par des expériences faites sur des cadavres et des animaux confirment cette possibilité.

4. Lors de la reconstruction du membre supérieur en deux étapes, il faut exécuter la deuxième étape un mois après la première opération au plus tard.

ZUSAMMENFASSUNG

Die Verwendung von Oberarm-Gewebe auf einem arteriellen Lappen zur Rekonstruktion der oberen Extremität als Ersatz einer hohen Amputation oder Exartikulation

J. B. Ryvlin

1. Den Ersatz des Armes durch Transplantation des Oberarmes mit einem arteriellen Lappen betrachten wir als erwiese Möglichkeit. Die normale Blutzirkulation wird dank der Tatsache gesichert, dass die Gefässe in einem wesentlichen Ausmass plastisch sind und leicht eine Drehung von 180° vertragen. Dasselbe kann auch über die Nerven der Extremität gesagt werden.

2. Durch Erhaltung der Hand und Finger beim Ersatz des Armes durch den Oberarm werden Voraussetzungen für eine Durchführung der nachfolgenden Etappe der Rekonstruktionsoperation geschaffen, deren Endziel die Erneuerung der ganzen Extremität ist.

3. Diese Möglichkeit bestätigen die Versuchsergebnisse an Leichen und Tieren.

4. Bei der Rekonstruktion der oberen Extremität in 2 Etappen statt der hohen Amputation oder Exartikulation, ist es notwendig die zweite Etappe spätestens einen Monat nach der ersten Operation durchzuführen.

(Prof. Dr. Med. Sci. J. B. Ryvlin) : Degtjarnaja ul. 13, kv. 9, Leningrad S-144 U.S.S.R.

Second Surgical Clinic, Budapest (Hungary)
Director: Jan Stefanics, M. D.

REPLACEMENT OF AN OSSIFIED ACHILLES TENDON BY A CORIUM GRAFT

Z. MEGYESI, R. KÓS, I. FARKAS

On Jan. 10, 1960, a man aged 60 years was admitted for treatment. He complained that for several months he had had pain at the site of the left Achilles tendon. Latterly the pain had become so intense that he was unable to walk unless aided by a stick. The case history showed that the patient had had Heine-

Fig. 1.

Fig. 2.

Medin's disease at the age of three, leaving him with talipes equinovarus. In order to relieve this condition, tenotomy of the affected tendon had been performed at the age of six. Other findings included otosclerosis, myocardial degeneration and slight lowering of the oscillometric index in both lower limbs. A hard mass about 3—5 cm. wide could be palpated in the left Achilles tendon for a distance of about 16 cm. (Fig. 1). The radiogram showed a shadow 16 cm.

in length (Fig. 2). Calcification was observed in the blood vessels. The patient compensated the pathological position of the foot well when walking, but when pressure was placed on the foot he felt pain, which hindered walking. Since the pain did not disappear after four days' conservative treatment and two weeks' rest in bed, it was decided to remove the induration from the tendon.

The operation was performed on Feb. 19, 1960, from a lateral incision. It was found that the hard mass in the tendon had resulted in dorsal weakening of the

Fig. 3.

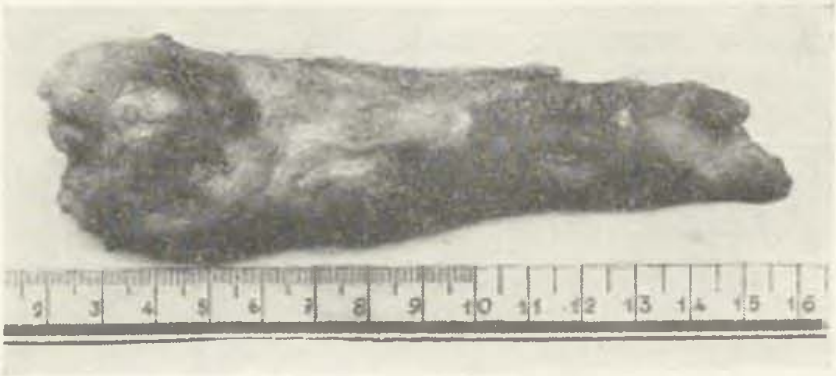

Fig. 4.

skin until it was almost worn through. The skin was raised very sparingly at this site and the induration was removed for a distance of 16 cm. In view of the patient's age and the fact that the circulatory conditions in the limb were not altogether satisfactory, it was decided to replace the ossified tendon by a corium graft instead of the usual fascial graft.

Using an electrodermatome, a corium graft 20 cm. long and 4 cm. wide was obtained from the skin of the left thigh. This was doubled by folding over and

was sutured under moderate tension into the site of the defect in the Achilles tendon (Fig. 3). The excised portion of ossified tendon measured 16 cm. and weighed 65 g (Fig. 4). After arresting haemorrhage, the skin was sutured and a plaster bandage was applied. The wound healed except for periferal necrosis of the skin 5 mm wide. A number of nylon skin sutures were also successively eliminated. After the wound had healed, the pain disappeared (Fig. 5). Micro-

Fig. 5.

scopic examination showed that the tendon had been transformed into bone. Spongy bone with comparatively thick trabeculae had been formed below the tendon sheath. Fatty tissue had been deposited in the intervening spaces. Signs of chronic inflammation were found in the lateral parts. The collagen connective tissue of the tendon merged smoothly into the bony tissue (Fig. 6).

Ossification at the site of insertion of the tendon is a relatively common phenomenon. According to Handeck and Hess, ossification develops directly from the adjacent periosteum. This was also demonstrated by Krompecher's experiments. According to other authors, traumatic bursitis can also cause ossifying periostitis. Ossification in places at some distance from the insertion is observed much less frequently. It usually occurs at the transition from tendon to muscle (myotenonitis ossificans traumatica). In some cases ossification appears in the middle of the tendon (tenonitis ossificans). The present case is of interest because ossification involved the entire length of the Achilles tendon.

Injury and operation play a role in the aetiology of ossification of the tendon. It can be presumed that operation or trauma can be the local factor which may lead, as a result of an increase in chondriotin-sulphate, to impregnation with calcium. Other possible factors in the spread of the process include muscle strain in the lower limbs, renal disease, tabes dorsalis, injury to the

spinal or peripheral nervous system and arteriosclerosis. Volkmann described five cases of callus in a scar on the Achilles tendon due to injury or operation. In his view the basis of all these cases was the healed rupture and in one patient "pseudoarthrosis" of the Achilles tendon developed, with callus luxurians.

In the prevention of this condition emphasis is therefore placed on the importance of immobilizing tendons which have been injured or undergone

Fig. 6.

operation. Bone formation in the Achilles tendon can produce serious disturbances, since in walking the bone irritates the adjacent tissue and the overlying skin, which has no proper foundation, is chafed by the shoes. In such cases, extirpation and replacement of the ossified tendon is the only possible treatment.

In the case in question a number of factors contributed to the tissue change: acute anterior poliomyelitis, tenotomy (after which callus was probably formed in the scar) and arteriosclerosis, which was plainly evident in the radiogram.

This case is also interesting because of the extent of ossification of the Achilles tendon. The authors wish to emphasize that they did not replace the extirpated part with the usual Kirschner fascia graft, but used a free corium graft.

SUMMARY

Ossification of the entire Achilles tendon was found in a 60-year-old male patient who had had Heine-Medin's disease in childhood, followed by tenotomy of the Achilles tendon. The ossified tendon was extirpated and was replaced by a free corium graft instead of the usual Kirschner fascia graft. Transformation

of the corium graft into tendon can be anticipated on the principles of Rehn's functional metaplasia. On the basis of this experience, the use of a corium graft can be recommended for replacing the Achilles tendon, since it is easily available, takes well and ensures good function for a certain time.

ВЫВОДЫ

Замещение окостенелого ахиллова сухожилия трансплантатом собственно кожи

Z. Megyesi, R. Kós, I. Farkas

У 60-летнего мужчины, который в детстве перенес болезнь Гейне-Медина, а после нее подвергся тенотомии ахиллова сухожилия, сухожилие по всей длине окостенело. Иссеченное окостенелое сухожилие было замещено свободно пересаженным трансплантатом собственно кожи вместо обычно применяемой пластики по Киршнеру путем применения фасции. В данном случае можно ожидать, что трансплантат собственно кожи преобразуется в сухожилие в смысле функциональной метаплазии по Рену. На основании полученного опыта трансплантат собственно кожи можно рекомендовать в качестве материала для замещения ахиллова сухожилия, так как он является легко доступным, хорошо приживает и через определенное время обеспечивает хорошую функцию.

RÉSUMÉ

Remplacement d'un tendon d'Achille ossifié par un greffon dermique

Z. Megyesi, R. Kós, I. Farkas

Un malade âgé de 60 ans qui, dans son enfance, avait passé une maladie de Heine-Medin et ensuite une tenotomie du tendon d'Achille, présentait des ossifications du tendon dans toute son étendue. Nous avons remplacé le tendon ossifié extirpé par un dermo-greffon en greffage libre, au lieu de nous servir de la plastie fasciale de Kirschner habituelle. Nous sommes en droit de supposer que le greffon dermique se transforme en tendon, dans le sens de la métaplasie fonctionnelle de Rehn. D'après nos expériences, nous pouvons recommander le remplacement du tendon d'Achille par un greffon dermique, facilement accessible et qui s'incorpore bien, tout en assurant un fonctionnement satisfaisant pendant un certain temps.

ZUSAMMENFASSUNG

Ersatz der verknöcherten Achilles-Sehne mittels eines Korium-Lappens

Z. Megyesi, R. Kós, I. Farkas

Bei einem 60 jährigen Mann, der in der Jugend eine Heine-Medinsche Erkrankung mit nachfolgender Tenotomie der Achilles-Sehne durchgemacht hatte, kam es zu einer völligen Verknöcherung der Sehne. Die exstirpierte verknöcherte Sehne wurde durch freie Übertragung eines Korium-Lappens statt der üblichen Kirschnerplastik mittels Faszie ersetzt. Vom Korium-Lappen ist die Umwandlung in eine Sehne im Sinne einer funktionellen Metaplasie nach Rehn zu erwarten. Auf Grund unserer Erfahrung können wir den Korium-Lappen als Ersatz der Achilles-Sehne empfehlen, da er leicht zugänglich ist, gut einheilt und nach einer bestimmten Zeit eine gute Funktion gewährleistet.

REFERENCES

1. **Abalikhine:** Vest. Rentgenol. 23, 50—52, 1939.
2. **Borsay, Csipak, Dettre:** Z. Orthop. 81, 1952.
3. **Bürkle de la Camp, Rostock:** Handbuch der gesamten Unfallheilkunde. Enke, Stuttgart 1956.
4. **Brunner, Henschen:** Lehrbuch der Chirurgie. Schwabe, Basel 1949.
5. **Chigot:** Mém. Acad. Chir. 83, 1957.
6. **Ghomberg:** J. Bone Jt. Surg. 20, 1938.
7. **Krompecher, S.:** Dtsch. Z. Chir. 281, 1956.
8. **Hufnagel:** Münch. med. Wschr. 1410, 1937.
9. **Mazzini:** Rev. Orthop. 5, 44—59, 1935.
10. **Palla, E.:** Beitr. klin. Chir. 63, 1909.
11. **Rieder:** Zbl. Chir. 1703, 1952.
12. **Schnaberth:** Arch. orthop. Chir. 40, 594, 1940.
13. **Schneider, H.:** Die Abnützungserkrankungen der Sehnen und ihre Therapie. Thieme, Stuttgart 1959.
14. **Volkmann:** Zbl. Chir. 2636, 1938.
15. **Zadek:** Surgery 61, 662, 1935.
16. **Zadek:** J. Bone Jt. Surg. 22, 1070, 1940.
17. **Young, Harris:** Surg. Gynec. Obstet. 61, 1935.

(Dr. Z. Megyesi) : Bavoss u. 23—25, Budapest VIII., Hungary

Orthopaedic Clinic, Director: Prof. J. Vavrda, M. D., Institute of Pathology, Director: Prof. A. Fingerland M. D., Dr. Sc., Tissue Bank, Director: R. Klen, M. D. Hradec Králové (Czechoslovakia)

BEHAVIOUR AND FATE OF CONSERVED HOMOGENOUS ARTICULAR CARTILAGE UNDER EXPERIMENTAL CONDITIONS

O. FIALA, V. HEROUT, R. KLEN

Recently, the problem of reconstructing the articular surface with tissue nearest to that of the joint, i. e. with a bone-cartilage graft, has come to the forefront. For practical reasons it is mainly conserved homogenous tissue that can be taken into account. In order to be able to use this material it is necessary to find a suitable medium for conservation, define the time of the expiration of the graft and choose the correct operation technique.

The experiments were carried out on dogs. The grafts of articular cartilage with subcartilaginous bone were conserved at a temperature of $+4^0$ C in gauze soaked with F ½ solution (physiological saline plus 5% glucose 1 : 1), further in 10% homogenous serum and paraffin oil. Then, after 14, 28, and 84 days, the grafts were examined histologically and implanted into a circular bed made in the patellar surface of the knee joint of the experimental animals. Three months after transplantation the macroscopic and microscopic appearance of the graft was assessed. Grafts conserved in F ½ solution could be transplanted successfully up to 14 days after excision, those conserved in 10% serum and paraffin oil even after four weeks (6, 10).

In order to verify the correctness of the operation technique transplantation of the osteocartilaginous cap of femoral heads was performed in 25 animals. Where the graft fitted perfectly and was firmly fixed, i. e. in more than one third of the animals, the transplant took well and remained viable (7). Since the congruence of joint surfaces is one of the basic preconditions for successful transplantation, the authors recently tried to transplant whole joints.

This report is centred on the study of the fate of an osteocartilaginous graft two to twenty-four months after transplantation. The authors were well aware that an osteocartilaginous graft, replacing part of the whole of a joint surface, is placed in an entirely different milieu than it would be if implanted into soft tissues. The bony part of the graft fits onto the bone of the recipient and its cartilaginous part is washed by the synovial fluid. Both parts, therefore, will undergo changes which will depend on the nature of the transplanted tissue

and on the conditions created by the new milieu. The purpose of the study was to find an answer to the following questions:

1. how and when does the graft take,
2. what changes take place in the cartilaginous part of the graft,
3. what influence is exercised by the synovial fluid,
4. what are the conditions for the survival of a conserved homogenous graft.

RESULTS OF THE STUDY

The transplanted bone lamella of the graft firmly unites with its bed within six weeks after transplantation and in the majority of cases becomes transformed within three months. A line between the tissue of the graft and that of the recipient can be distinguished only in some parts.

The cartilaginous component of the graft shows only slight signs of necrosis between the second and fourth month after transplantation which manifest themselves by slight pyknosis of the cell nuclei and even by the death of some cells as well as by a slight decrease in substances of the type of acid mucopolysaccharides, glycogen and fats. From the fifth month after transplantation necrosis of the cartilage cells evidently becomes more intensive. The superficial layers are affected most; less affected are the middle and least the basal layers. In the basal layers many cells survive and gradually infiltrate right up to the superficial layers. Where these cells come into contact with necrotic cartilage, they form clusters of chondrocytes. By 24 months after transplantation the cartilage graft is virtually cellular throughout its entire thickness. The cells contain an adequate amount of substances of the type of acid mucopolysaccharides, glycogen and fats. The number of cells is, however, on the whole smaller than that of normal cartilage.

DISCUSSION

The fate of transplanted cartilage depends on many factors:

1. On the method and the duration of conservation. The best morphological appearance of the cartilage was found after conservation with paraffin oil at a temperature of $+4^0$ C. The shorter the conservation (14 days) the smaller were the signs of necrosis, and after more than 28 days of conservation the cartilage often broke down and was replaced by fibrocartilage (5).

2. On the thickness of the simultaneously transplanted bony lamella. A thickness of 2 mm. proved best. When the layer of subcartilaginous bone was thinner the transplant could be fixed to its bed only with difficulty, and where the layer was too thick the smooth surface of the cartilage was damaged due to the transformation and absorption of the underlying bone, and as a result of this the cartilage broke down (7).

3. On the proper fitting and fixation of the graft to its bed. If the graft does not fit and is badly fixed it breaks down and is not replaced by fibrocartilage (6, 7).

4. The synovial fluid maintains, no doubt, the nutrition of the superficial layers of cartilage. It also contributes to the viability of the autogenous cartilage transplants (17) which may be borne out by the survival and even growth of joint mice. It seems, however, that the influence of the synovial fluid on an homotransplant is not so favourable. From the experiments referred to above it follows that after a certain time, i. e. between the fourth and fifth month total necrosis of the superficial cartilage cells takes place in the graft, whereas in the basal layers only a few cells are affected. The chondrocytes near the surface of a homogenous graft, are, no doubt, insufficiently protected by a layer of cartilaginous matrix (2) and thus become prone to necrosis. The cells of the basal layer are on one side covered by a thick layer of intercellular substance, and on the other by a layer of subcartilaginous bone. Before the transformation of the entire thickness of the bone has been completed (6, 7), the chondrocytes situated at the base are probably capable of surrounding themselves with a sufficient layer of intercellular substance and thus adapting themselves to the new conditions (8, 16).

On comparing the authors' experiments with those of Schatten et al., who transplanted fresh homogenous costochondrial-junctions into soft tissue, similar regular features could be observed, although the former used quite different material, i. e. conserved articular cartilage. The authors also observed distinct growth of the surviving cartilage cells only from the fourth to fifth month after transplantation. Schatten and his collaborators found that cartilage homografts took up the same amount of sulphur S^{35} as autografts, but only around the twelfth month after transplantation (16). This would indicate that a certain time is needed for the surviving chondrocytes to adapt themselves to the new conditions. In the experiments reported above the number of surviving chondrocytes was greatest where the conserving medium chosen was most suitable and the time of storage of the graft was short (paraffin oil for 14 days).

In conclusion the question put above can now be answered: What are the conditions for the successful transplantation of conserved homogenous articular cartilage? The answer is quite unequivocal: the preservation of full viability of the chondrocytes. This can be achieved by the conserving medium being correctly chosen, by never exceeding the expiration time, by leaving a proportionate layer of subcartilaginous bone, by careful operation technique and by firm fixation of the transplant.

SUMMARY

The authors studied the morphological appearance of an osteocartilaginous graft conserved in different conserving media for various lengths of time by experiments in dogs. On the basis of the results attained from transplantation of a small part of joint surface they ascertained the time of expiration. At a temperature of $+4^0$ C it was fourteen days for F ½, twenty-eight days for 10% homogenous serum and paraffin oil. In 25 dogs they performed transplantation of the cap of the femoral head.

After transplantation into a joint, conserved homogenous articular cartilage

undergoes the following changes: Up to three months only signs of slight necrosis can be observed, in the fourth and fifth month necrosis intensifies and affects mainly the superficial layers. Viable chondrocytes of the basal layers grow and gradually replace the necrotic cells of the superficial layer. By 24 months after transplantation the graft is virtually cellular throughout its entire thickness. The number of cells, however, is on the whole smaller as compared with normal cartilage.

ВЫВОДЫ

Изменения консервированного гомогенного суставного хряща и его судьба в опытах

O. Fiala, V. Herout, R. Klen

В опытах на собаках авторы изучали морфологическое состояние костнохрящевого трансплантата, храненного в разных консервирующих средах в течение различного времени. На основании результатов пересадки небольшой части суставной поверхности определялся срок годности. При темнературе + 4° С в растворе Ф ½ он составлял 14 дней, а в 10 % гомогенной сыворотке и в парафиновом масле — 28 дней. У 25 собак была произведена пересадка хрящевой поверхности головки бедренной кости.

В консервированном гомогенном суставном хряще происходят после пересадки в сустав следующие изменения: до 3 месяцев можно наблюдать только признаки небольшого некроза, на 4 и 5 месяце некроз становится более глубоким и поражает прежде всего поверхностные слои. Из базальных слоев хряща разрастаются сохранившиеся хрящевые клетки и постепенно замещают некротические поверхностные слои. До 24 месяцев трансплантат становится практически клеточным во всех слоях. Однако клеточность является по существу меньшей при сравнении с нормальным хрящем.

RÉSUMÉ

La conduite et le sort du cartilage homogène de l'articulation en expérimentation

O. Fiala, V. Herout, R. Klen

Dans leurs expérimentations, faites sur les chiens, les auteurs observaient l'allure morphologique du greffon cartilage-osseux conservé dans de différants milieux en différante période. À l'égard du résultat obtenu en transplantant une petite partie de la surface articulaire, ils ont observé son exspirium. Celui-ci parvint en quinze jours dans la température de +4° de Celsius en F ½, et en vingt-huit jours au sérum homogène de dix pour cent et en paraffine liquide. Chez les vingt-cinq chiens, ils ont pratiqué la transplantation de la surface cartilagineuse de la tête de fémur.

Le cartilage homogène de l'articulation subit après la transplantation dans l'articulation de suivantes changements: durant la période de trois mois, on peut observer rien que des marques d'une légère nécrose. En quatrième et cinquième mois, la nécrose devient plus profonde, mais elle reste localisée surtout dans les couches superficielles. Des couches basales du cartilage, les cellules cartilagineuses, restées intactes, se mettent à croître et, petit à petit, remplacent les couches superficielles nécrotiques. Les vingt-quatre mois passés, voici le transplant devenu cellulaire en toute sa largeur. La richesse en cellules reste pourtant bien plus petite en comparaison avec celle du cartilage normal.

ZUSAMMENFASSUNG

Verhalten und weiteres Schicksal von konserviertem homogenen Gelenksknorpel im Versuch

O. Fiala, V. Herout, R. Klen

In Versuchen an Hunden verfolgten die Verfasser das morphologische Bild von Knochen-Knorpel-Transplantaten, die verschieden lange Zeit in verschiedenen Konservierungsmitteln aufbewahrt worden waren. Auf Grund des Ergebnisses der Transplantation eines kleinen Stücks der Gelenksfläche bestimmten sie die Exspirationszeit. Bei +4° C betrug diese in F ½ 14 Tage, in 10% homogenem Serum und in Paraffinöl 28 Tage. Bei 25 Hunden führten sie eine Transplantation der knorpeligen Oberfläche des Femurkopfes durch.

Konservierter homogener Gelenksknorpel macht nach der Transplantation folgende Veränderungen durch: Innerhalb 3 Monaten können nur Anzeichen einer leichten Nekrose beobachtet werden, im 4. und 5. Monat vergrössert sich die Nekrose und betrifft vor allem die oberflächlichen Schichten. Von den basalen Knorpelschichten sprossen intakte Knorpelzellen hervor, die allmählich die nekrotischen oberflächlichen Schichten ersetzen. Innerhalb 24 Monaten ist das Transplantat praktisch in seiner ganzen Schichtdicke zellhaltig. Der Gehalt an Zellen ist jedoch im Vergleich mit normalem Knorpel wesentlich geringer.

REFERENCES

1. **Allbrooc, D., Kirkaldy, W. H.:** J. Bone Jt. Surg. 40-B, 742, 1958.
2. **Bacsich, P., Wyburn, G. M.:** Proc. roy. Soc. (Edinburgh) 62, 321, 1947.
3. **Bennett, G. A., Bauer, W.:** J. Bone Jt. Surg. 17, 141, 1935.
4. **Craigmyle, M. B. L.:** Brit. J. Plast. Surg. 8, 93, 1956.
5. **Craigmyle, M. B. L.:** Plast. reconstr. Surg. 22, 123, 1958.
6. **Fiala, O., Herout, V., Klen, R.:** Sborník věd. prací lék. fak. KU; in Hradec Králové 2 : 4, 478, 1959.
7. **Fiala, O., Urbánek, K., Dvořák, J., Herout, V., Klen, R.:** Bruns' Beitr. Klin. Chir. 200, 12, 1960.
8. **Gibson, T., Davis, B. W., Curran, R. C.:** Brit. J. Plast. Surg. 11, 177, 1958.
9. **Horwitz, T., Morrow, R. E., Springer, T. R.:** Surg. Gynec. Obstet. 109, 67, 1959.
10. **Klen, R., Herout, V., Fiala, O.:** Folia biol. 5, 367, 1959.
11. **Laskin, M. D., Sarnat, B. G.:** Surg. Gynec. Obstet. 96, 493, 1953.
12. **Lyndon, Peer, A., M. D.:** Transplantation of Tissues. Baltimore 1955.
13. **De Palma, A. F., Sawyer, J., Hoffman, J. D.:** J. Bone Jt. Surg. 41-A 1352, 1959.
14. **Priorov, N. N.:** Ortop. Travm. Protez. 6, 27, 1959.
15. **Sarnat, B. G., Laskin, D. M.:** Intern. Abstr. Surg. 99/2, 521, 1954.
16. **Schatten, W. E., Bergenstel, D. M., Kramer, W. M., Swarm, R. L.:** Plast. reconstr. Surg. 22, 11, 1958.
17. **Vavrda, J., Škrovina, B., Kotrba, F.:** Acta Chir. Orthop. Traum. Czech. 25, 165, 1958.

(Dr. O. Fiala) : Nerudova 3, Hradec Králové, Czechoslovakia

PLASTIC SURGERY MOURNS THE LOSS OF TWO GREAT PERSONALITIES

F. BURIAN

The year 1960 has brought great loss to plastic surgery in the death of Harold Gillies and Archibald McIndoe.

Sir Harold D. Gillies died on September 10th. He was born in New Zealand in 1882, studied at Cambridge and graduated from London. There he also started his medical career, specialized in surgery, got his FRCS in 1910 and was appointed chief of the otorhinological unit of a surgical department in London.

Sir Harold Gillies during his last visit to prof. Burian in Prague, 1956.

In 1915 he joined the Expeditionary Forces in France. There he saw Morestin performing reconstructive surgery of the face, which captured his interest to such an extent that he decided to take up plastic surgery for good. He met with full understanding on the part of the Army medical administration which set up a department for war facial surgery for him at Aldershot, and a year later a similar department at Sidcup in Kent.

There he developed tremendous activity in organizing, operating and teaching. A continuous stream of surgeons, first British then American, came to him for training and his growing authority also attracted many surgeons from other countries. Gillies was an excellent operator, teacher, debater and ingenious innovator. He modified the old methods of plastic surgery and designed new ones. He had the talent of giving a clever name to each innovation. In 1920 he published his experience and methods in the book "Plastic Surgery of the Face" which became the basic textbook of modern plastic surgery.

At the time when military hospitals were closed down, Gillies already had an extensive private practice. His patients needed plastic treatment so that he could afford to remain in that branch. Only in 1930 did he obtain a position in a public hospital, but then only with eight beds.

In the Second World War, Gillies was immediately called up to organize a plastic surgery service. The hospital at Basingstoke was put at his disposal. There he trained surgeons for directing new plastic surgery units. Soon, this hospital turned into a training centre where surgeons, who wanted to specialize in plastic surgery, gathered from all over the world.

In 1957, Gillies together with his pupil Millard published the great book "The Principles and Art of Plastic Surgery". This is an extremely interesting and ingeniously composed book which gives a picture of Gillies' work from the very beginning during the First World War. I wrote a review of this book in the journal „Časopis lékařů českých" ; Gillies had this translated into English and distributed it among his friends.

Harold Gillies was a sincere friend of Czechoslovakia. He was our guest at the symposium in 1956. At that time he also lectured at the concurrent Congress of Stomatology and at the Faculty for Hygiene to senior students of the Prague Medical Faculties. He greatly admired Czechoslovakia's Health Service and its tremendous development since the liberation.

Harold Gillies was a manysided personality. He was an excellent sportsman : rower, golf player, enthusiastic angler, and a successful painter. In 1959 I visited an exhibition of his paintings in London. He was very sociable and had a great sense of humour. In his jokes he sometimes overstepped the mark towards boyish mischievousness, but somehow he always got away with it. Nobody could really be angry with him.

Sir Archibald McIndoe died before his teacher passed away. He was one of the most successful pupils of Gillies, his cousin, and came from the same town in New Zealand. Born in 1900, he studied first in America, and in 1930, he came to work with Gillies. During the Second World War, he became director of the new plastic surgery centre in East Grinstead, Sussex. Most of the airmen of the Allied Forces, who participated in the Battle of Britain, were treated there. McIndoe saved the life of many a Czech airman and many owe gratitude to him for surgical reconstruction after severe and mutilating injuries. McIndoe took great care of his patients even from the aspect of mental rehabilitation. He provided them with both entertainment and work and was very popular with them.

PROF. VLADISLAV RAPANT, M. D. AND COL.

CHIRURGIE VELKÝCH KRVÁCENÍ

Surgery of Heavy Bleeding

The contents of the book consist in a collection of publications on the results of nation-wide importance concerning the problem of massive, sudden and life-endangering haemorrhage. Mention is further made of work achieved in various institutions with summaries of clinical observations, informations and experiences on massive bleeding, its pathogenesis and clinical picture. Designed for surgeons, specialists of all operative branches internists, phthiseologists and general practitioners.

260 pages, 57 illustrations, price of a bound copy $ 4,73

LECT. FRANTIŠEK URBAN, M. D. — LECT. LEON SAZAMA, M. D.

ÚRAZY OBLIČEJOVÝCH KOSTÍ

Injuries of Facial Bones

In the first general part of the monography there is discussed anatomy of facial nerves and vessels, aetiology and division of injuries of the jawbone, general symptoms and examination methods of maxillar injuries, therapy, etc. In the conclusion of this part information is given on the care and feeding of injuried patients. In the second, special part the authors describe fractures, all kinds of injuries, including war injuries, and the method of their management. The work is furnished with many photographs and instructive diagrams.

424 pages, 322 illustrations, price of a bound copy $ 7,—

The books ordered will be delivered to you by the export corporation

ARTIA

ARTIA, Smečky 30, Praha 2 — ČSSR

TABLE OF CONTENTS