ACTA CHIRURGIAE PLASTICAE

INTERNATIONAL JOURNAL OF PLASTIC SURGERY

V · 2

1963

Acta chir. plast. 5 : 2 : 1963

CZECHOSLOVAKIA · PRAGUE · SZDN

Published four times (in 1959: two times) a year by Státní zdravotnické nakladatelství, Malostranské nám. 28, Praha 1. — Adress of the editorial office: Acta chirurgiae plasticae (M. Dobrkovský, M. D. — Secretary) Legerova 63, Praha 2, Czechoslovakia. — Orders through ARTIA, Smečky 30, Praha 2. — Press: Středočeské tiskárny, n. p., provoz 101, Hálkova 2, Praha 2. — A-08*31247

Surgical Clinic of the Bashkir Medical Institute, Ufa (U.S.S.R.)
Department Director: Prof. L. G. Granov — Rector: Doc. N. F. Voroblyev

EARLY AND LATE RESULTS OF PLASTIC LINING OF BONE CAVITIES WITH PERFORATED FREE SKIN GRAFTS IN CHRONIC OSTEOMYELITIS

I. I. ZAKHAROV

The treatment of chronic osteomyelitis has hitherto been one of the difficult tasks of septic surgery. The frequent recurrence of osteomyelitis after sequestrectomy is explained by the persistence of a bone cavity.

In recent years it has been proven by the work of the Soviet surgeons (Petrov, Krasnobayev, Gomzyakov, Lidski, Vlasenko, Antelava, Chaklin, Aryev, Kornev, and others) that the only rational treatment of chronic osteomyelitis was the plastic lining of the residual bone cavity with viable, blood-supplied and biological tissue.

Of the biological tissues suitable for this purpose muscle or skin flaps on a nutritive pedicle are frequently used.

The absence of muscles on the anterior aspect of the leg, particularly in its lower third, and the limited possibility of mobilizing local skin after excision of the scars, makes completion of the operation by simple suture very difficult, not to speak of a plasty of the residual bone cavity with local tissue. In their papers Antelava, Chaklin, Nikitin, Schepelmann, Franke, Stotz, Livingston, Khodkevich, Fridland, Girgolav, Aryev and others have dealt with these difficulties.

The recommended coverage of the bone cavity by means of mobilized local skin (Chaklin, Khromov, Lord, etc.), transplantation of muscle from the contralateral extremity (Aryev and Nikitin, Lindenbaum, Dudin, etc.) and a skin flap plasty by the Italian method or with an unfolded Filatov tubed flap (Smirnov, Sokolov, Keropyan and Gobuyev, Ryvkina-Furman, and others) in multilocular bone cavities are technically hard to perform and not always successful. In addition, these methods necessitate an unnatural position of the patient's extremities.

The long time taken for the healing of a bone cavity left after sequestrectomy incited surgeons many years ago to apply free skin plasty by using Thiersch's dermo-epidermal grafts (Politzer 1904; Esser 1916; Schepelmann 1918; Armstrong and Jarman 1936). The operation was divided into two stages; seven to ten days

after the first stage, Thiersch grafts were implanted by means of a mould. The mould together with the skin graft were left in place for ten days during which the graft took.

Most authors (Kelly, Rosati, Murray 1945, 1946; Medvedev, Bocharov 1959 and others) consider the use of thin dermo-epidermal grafts for bone cavity plasties as not expedient, since these grafts frequently disintegrate in the pus or, after taking, give rise to scarring, eczema or other complications. They re-

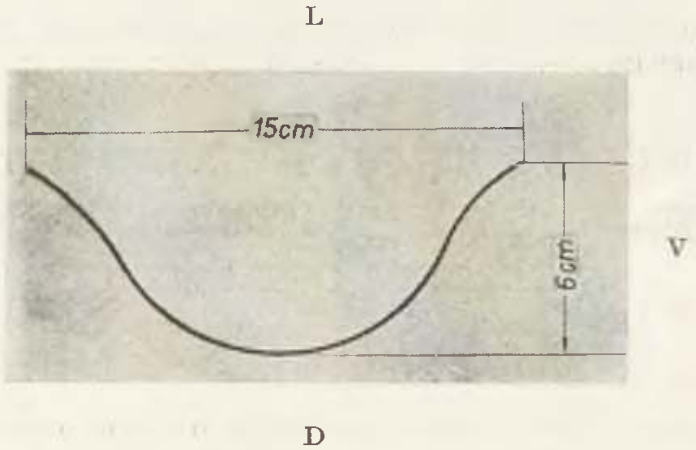

Fig. 1. Bone cavity after sequestrectomy, L=length=15 cm. W=width=4 cm. D=depth= =6 cm.

commended grafting of free skin transplants in bone cavities onto firm granulations three to four weeks after the first-stage operation.

Aryev and Nikitin, 1955, explain the shortcomings of free skin grafting by "not being able to use it in deep and multilocular cavities". These drawbacks have been overcome by the author's new modification of lining the bone cavity with free perforated full-thickness skin grafts. The clinical observations have shown this modification to give fully satisfactory results. It is carried out in two stages. In the first, the radical sequestrectomy, material is taken for culture from various parts of the purulent focus (muscles, periosteum, bone and tissue from within the bone cavity). Within three to four days the bacterial flora and its sensitivity to the various antibiotics are determined. Only after determination of the antibiotic efficacy and five to six days after the first stage, is the second stage, i. e. the actual bone cavity plasty, performed, at the same time, applying the antibiotic which is most effective against the given microflora. More effective still appears to be the local application of antibiotics in large doses (in solutions of 300,000 to 500,000 i.u.) at operation and the intramascular administration of 100,000 i.u. four-hourly during the first three or four days after operation.

The use of antibiotics as preoperative treatment is considered inadvisable or even harmful, because by the time of the operation, strains of microbes resistant to antibiotics may have developed.

The first-stage operation is performed under general, ether-oxygen or spinocerebral, intraosseal anaesthesia with a tourniquent applied to the limb. In the second stage local anaesthesia is used, except in children. After radical sequest-

rectomy the bone cavity takes on the shape of a little "boat", "trough" or "forage-cap" with sloping sides. The operation is concluded by rinsing the bone cavity with warm saline injected under pressure with a Janet syringe. Then the cavity is filled with swabs soaked in 0.5% hydrochloric acid (according to Fridland).

Five to six days later the second-stage operation, i. e. transplantation of a perforated free skin graft, is performed. After preparation of the operation field and the removal of the swabs the cavity is again rinsed with warm saline

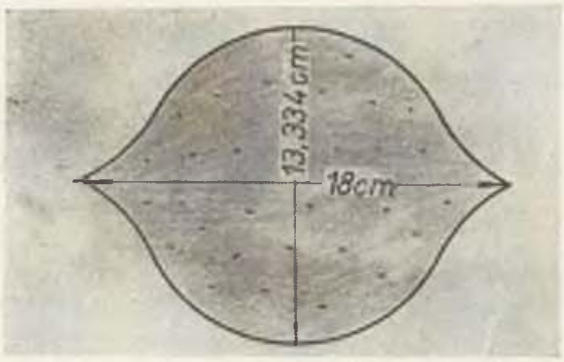

Fig. 2. Perforated skin graft for bone cavity plasty taken by following calculation: $L' = L+1/5L=15+3=18$ cm.; $W' = (12+W) - 1/6.(12+W) = (12+4) - 2.66=13.334$ cm. L' = length of skin graft; W' = width of skin graft; $A = 15.(12+4) = 240$ cm.^{2}; $A' = 18 \times 13.334 = 240$ cm.^{2}; A = area of bone cavity; A' = area of skin graft.

Fig. 3. After joining the two opposing edges of each half, the skin graft acquires the shape of a forage-cap.

and then, whilst the skin graft is being prepared, filled with gauze pads soaked in a solution of the appropriate antibiotic (i. e. of the most effective preparation with regard to the microflora of the wound as ascertained a few days before from the culture of the material at the first-stage operation).

A full-thickness perforated skin graft is then taken freehand either (and more often), from the anterior aspect of the thigh or from the abdomen and of a size corresponding to that of the general surface area of the bone cavity disregarding the exact form and shape of the defect.

With the author's modification a large enough skin graft is taken to completely cover the defect. Its length compensates for its width. By measuring the length, depth and width of the bone cavity the general area of the cavity is calculated. The skin graft of the following dimensions is then excised: The length exceeds by 1/5 the length of the bone cavity; the width, however, is 1/6 less than the width plus twice the depth of the cavity.

These dimensions of the skin graft give an area which equals the surface area of the bone cavity (Fig. 1).

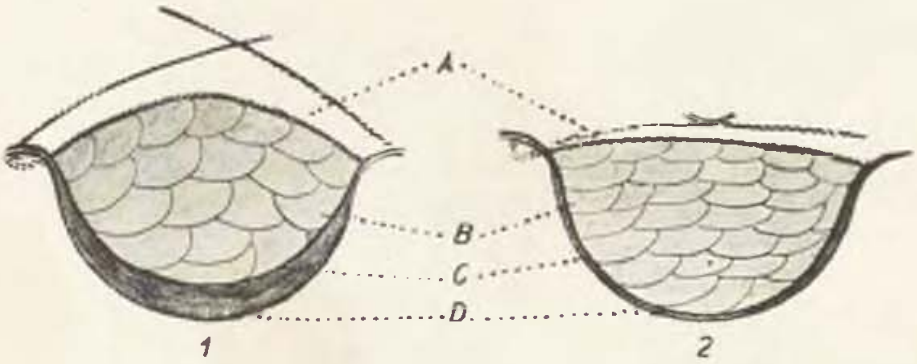

Fig. 4. Gause swab pressure sutures. — A = Silk — B = Gause Swabs — C = Skin graft — D = Wall of bone cavity. — 1 = before tying; 2 = after tying of threads.

Fig. 1 shows the shape and dimensions of the bone cavity left after sequestrectomy: L = length = 15 cm., D = depth = 6 cm., W = width = 4 cm. (not shown in fig).

Fig. 2 shows the shape and dimensions of the excised perforated skin graft to be used for lining the bone cavity with an area $A' = L' . W'$ (A being the surface area of the bone cavity, A′ the area of the skin graft, L the length of the cavity, L′ the length of the skin graft, W the width of the cavity and W′ the width of the skin graft):

$$L' = L + 1/5\,L = 15 + 3 = 18 \text{ cm.}$$

$$W' = (2D + W) - 1/6 = 12 + 4 - 2.66 = 13.34 \text{ cm.}$$

$$A = A';\ A = 15\,(12+4) = 240 \text{ cm}^2;\ A' = (15+3)\,.\,(12+4-2.66) = 240 \text{ cm}^2.$$

This calculation permits the obtaining of a graft whose area corresponds to that of the surface area of the bone cavity and this makes it possible to cover the defect without applying tension to the graft. The above formula for calculating the dimensions of the skin graft takes into acount both the way in which the skin graft will shrink and the shape of the defect in the donor area whose covering is facilitated by this calculation.

After calculating its dimensions the outlines of the skin graft are marked by an incision reaching into the subcutaneous tissue. Then perforations 3—4 mm. long and in a chessboard pattern, one per 9 cm.^{2}, are made with the pointed end of the scalpel through the whole thickness of the skin (Fig. 2). In order to facilitate the closest contact between the skin graft and the surface of the bone cavity the graft is given the shape of little boat or trough or any other form

corresponding to that of the bone cavity. For this purpose the outlined graft is divided into two equal halves along its longer axis. If the width of the graft exceeds 12 cm. it is better to take each half from another part of the body, e. g. one from the right, the other from the left thigh. A graft up to 15 cm. may be taken from the abdomen, from the thigh one up to 12 cm. in men and 10 cm in women.

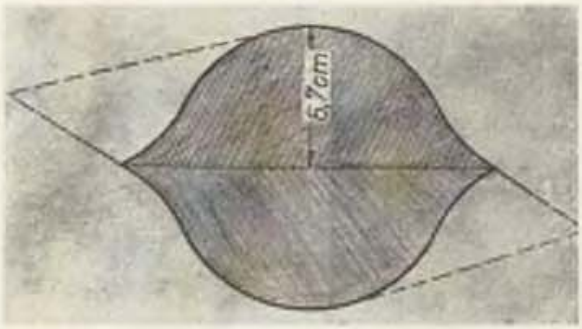

Fig. 5. Length of skin defect at donor site after excision of skin graft lengthened by two oblique incisions through skin and subcutaneous fat.

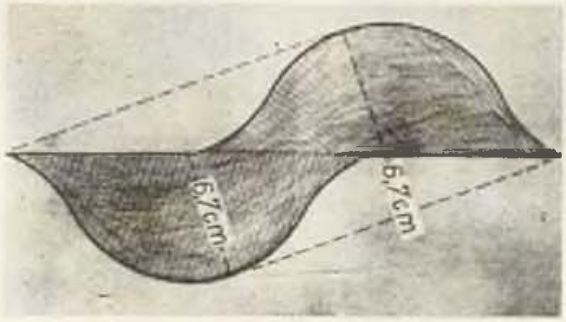

Fig. 6. Width of skin defect at donor site diminished to one half after transposition of two opposing triangular skin flaps.

After excision of both halves, the opposing free edges of the graft are joined together by an interrupted silk suture, after which the graft takes on the shape of the bone cavity (Fig. 3).

With this shape the graft fits into the bone cavity so that its raw surface lies against the cavity wall. The graft is been fixed to the edges of the defect by interrupted silk sutures and to the cavity wall by means of a pressure bandage consisting of gauze swabs kept in place by additional silk sutures (Fig. 4). Depending on the length of the bone cavity (Fig. 4) two to three or even more of these stitches are placed at intervals of 7—8 cm. The dressing is then soaked with a solution of the appropriate antibiotic and covered by a simple plaster cast with a window.

The first change of dressings is performed six to seven days later. The skin sutures are taken out on the eleventh or twelfth day.

In order to close the large defect left in the donor area after excision of the graft, the author uses two additional oblique incisions starting at either corner of the wound, cutting through skin and subcutaneous tissue and measuring 5—10 cm. each (Fig. 5). The layer of subcutaneous fat left after the excision of the skin graft is then excised completely. The skin at the wound edges is mobilized on either side to the depth of 5—8 cm. which permits the edges to be dis-

Fig. 7. T. R., girl of 18 with chronic traumatic osteomyelitis of lower third of left tibia (prior to operation).

Fig. 8. The same, aged 28, ten years after free skin plasty of bone cavity with perforated graft.

placed easily as in a Z-plasty (according to Limberg), which diminishes the width of the skin defect to one half (Fig. 6). For the approximation of the wound edges gauze roll tension sutures are used which make it possible to close even a quite large defect by simple stitches, i. e. without tension at the wound edges, since this is borne by the tension sutures. In the author's experience no case of skin necrosis along the suture line, cutting through of stitches or wound edge gaping has occurred after this wound closure. The technique of the gauze roll tension sutures is very simple.

A double No. 5—6 silk thread, the ends of which are knotted over a gauze roll, is introduced 3 cm. from one wound edge into the skin and subcutaneous tissue, led over the wound floor and under the opposite wound edge, brought out through the same layers on the opposite side and also knotted there over a gauze roll. These tension sutures are made at intervals of 8 cm. along the whole length of the wound. After tying the tension sutures, the wound edges are sutured with thin silk stitches taking hold of skin only at intervals of 1 cm.

The tension sutures are removed after four days at which time the skin oedema has also subsided and the wound edges are beginning to adhere. Leaving the gauze rolls longer, may cause pressure sores in the skin, because the rolls get dry after four days; in the first days they remain moist as they are soaked with the haemorrhagic discharge from the wound. The skin sutures are removed on the eleventh or twelfth day.

Tab. 1. Localisation of Bone Cavities Lined with Free Skin Grafts

Localisation of bone cavity	Type of chronic osteomyelitis			
	Number of patients	haematogenous	gunshot wound	traumatic
Femur	2	—	2	—
Fibula	40	21	11	8
Calcaneum	2	—	2	—
Stump of foot	4	2	1	1
Os coxae	1	—	—	1
	1	—	—	1
Total	50	23	16	11

The author's clinical material of cases in which he has performed a skin plasty of bone cavities with a perforated free skin graft comprises 50 patients with chronic osteomyelitis, 45 of whom were men and five women, their age ranging between nine and 56 years. The localisation of the bone cavity and the type of chronic osteomyelitis is given in Tab. 1.

The table shows that 80% of cases in which a free skin plasty of the bone cavity was performed, were patients with chronic osteomyelitis of the tibia. In two cases this operation was carried out for chronic osteomyelitis in the lower third of the femur following a gunshot wound and after a muscle plasty had proved unsuccessful.

Here are some short excerpts from the case histories:

First patient, I. G. S., aged 55 (case paper No. 4187), was admitted to the clinic on Sept. 7, 1955, with a diagnosis of chronic osteomyelitis following gunshot fracture of the lower third of the left femur. Before admission to the Clinic he had undergone 16 sequestrectomies including one attempt at plastic closure of the bone cavity with muscle.

On Feb. 7, 1956, the operation, plastic lining of the bone cavity with a perforated free skin graft, was performed. The graft took completely. The patient was re-examined after five years: he felt well, had no pain, and the fistulae had

never opened again. At the site of the former bone cavity there was a small depression 2.5 cm. deep.

Second patient, G. M. P., aged 41 (case paper No. 808), was admitted to the Clinic on March 23, 1961 which a diagnosis of chronic osteomyelitis following gunshot fracture of the lower third of the left femur. Before admission to the Clinic he had undergone 28 operations including two attempts at closure of the bone cavity by a muscle plasty. The fistulae were still discharging.

Fig. 9. P. P., man of 23, six months after free skin plasty for chronic haematogenous osteomyelitis of right tibia.

Fig. 10. G. R., man of 32, six years after fre skin plasty for chronic haematogenous osteomyelitis of left tibia.

On March 28, radical sequestrectomy and on April 3, the second-stage operation, plastic lining of the bone cavity with a perforated free skin graft, were performed. The graft took completely and the patient was discharged cured.

The immediate results of plastic lining of bone cavities with free skin grafts in 50 patients were as follows: good 44, satisfactory 5, unsatisfactory 1. Good results are cases with a complete take of the skin graft; satisfactory those with partial necrosis of the graft and the wound closing by secondary epithelization; unsatisfactory those with complete necrosis of the graft and where the patient was discharged from hospital with the wound unhealed.

The late results after plastic lining of bone cavities with perforated free skin grafts were registered in 46 patients at various periods ranging between one and ten years after operation. They were as follows: stable cure in 42 patients, improvement in two, deterioration in two. A detailed study of these results showed

that the full-thickness free skin graft did not only serve to cover the skin defect in a bone cavity, but also improved the trophic conditions of bone tissue and accelerated the regenerative and reparative processes. After a time the bone cavity became considerably smaller and only a slight depression marked the site of the previous cavity.

For illustration of the above, the author presents photographs of patients before operation and at various periods after.

CONCLUSION

1. The author's modification of a free skin plasty in the treatment of chronic osteomyelitis by using a perforated full-thickness skin graft has, due to the division of the operation into two stages and the application of antibiotics most effective against the microflora of the purulent focus, given the most favourable and stable results hitherto published in the literature.

2. The introduction of the plastic lining of bone cavities with perforated free skin grafts is of practical significance for the treatment of chronic osteomyelitis of the tibia and the foot.

3. The author's modification of the plastic lining of bone cavities with free skin grafts is not a complicated operation and the patients tolerate it well.

SUMMARY

Covering of a bone cavity by means of a muscle or skin flap on a nutritive pedicle in the treatment of chronic osteomyelitis is considered the method of choice.

The absence of muscles on the anterior aspect of the leg, particularly in its lower third, and the limited possibility of mobilizing skin for covering the defect after the excision of scars, make conclusion of the operation by simple suture impracticable.

The closure of bone cavities by means of mobilized local skin (Chaklin, Khromov, Lord and others), transplantation of muscle from the other leg (Aryev and Nikitin, Lindenbaum, Dudin and others), or the Italian plasty with an unfolded or not unfolded Filatov flap (Smirnov, Sokolov, Keropyan and Gobuyev, Rybkina-Furman and others) are difficult to perform in multilocular bone cavities and not always successful. In addition, these methods necessitate an unnatural position of the patient's extremities.

The drawbacks have been overcome by the author's new modification of the plastic lining of bone cavities with perforated fullthickness free skin grafts. His clinical observations showed that this method gives fully satisfactory results. The operation is performed in two stages: the first, consisting in radical sequestrectomy, the second, five to six days later, in the transplantation of a perforated free skin graft directly onto the raw bone of the bone cavity inner surface prepared by the first-stage operation.

The immediate results of free skin lining of bone cavities carried out in 50 patients are as follows: good in 44, satisfactory in 5, unsatisfactory in 1.

The late results of free skin lining of bone cavities were studied in 46 patients one to ten years after operation. Stable cure has been attained in 42 patients, improvement in 2, deterioration was registered in 2.

ВЫВОДЫ

Ближайшие и отдаленные результаты свободной кожной пластики дырчатым лоскутом костных полостей при лечении хронического остеомиелита

И. И. Захаров

Пластика костных полостей при помощи мышечного и кожного лоскута на питающейся ножке в лечении хронического остеомиелита является методом выбора.

Однако, отсутствие мышц на передней поверхности голени, особенно в нижней трети ее, ограниченная возможность мобилизации кожных покровов после иссечения рубцов не дает возможности заканчивать оперативное вмешательство наложением глухого шва.

Предлагаемая пластика костных полостей при помощи мобилизации местной кожи [В. Д. Чаклин, Б. М. Хромов, И. Лорд (I. Lord] и др.], пересадка мышц с другой конечности (Т. Я. Арьев и Г. Д. Никитин, И. С. Линденбаум, В. А. Дудин и др.) и несвободная кожная пластика по итальянскому способу или развернутым, неразвернутым филатовским стеблем (И. А. Смирнов, А. П. Соколов, К. С. Керопян и Н. Е. Гобуев, Р. М. Рывкина-Фурман и др.) при многопрофильных костных полостях технически трудно выполнима и невсегда оказывается удачной. Кроме того, она связана с вынужденным положением конечностей больного.

Этот недостаток пластики был устранен нами новой модификацией свободной кожной пластики костных полостей дырчатым полнослойным кожным лоскутом. Наши клинические наблюдения показали, что свободная кожная пластика костных полостей в нашей модификации дает вполне удовлетворительные результаты. Операция производится в два этапа. В первый этап операции — радикальная секвестротомия; через 5—6 дней после первого этапа производится второй этап операции — свободная кожная пластика дырчатым лоскутом непосредственно на обработанные стенки костной полости.

Непосредственные результаты свободной кожной пластики костных полостей следующие: хорошие — у 44 из 50 больных, удовлетворительные — у 5, неудовлетворительные — у 1.

Отдаленные результаты свободной кожной пластики костных полостей изучены у 46 больных в сроки от 1 года до 10 лет.

Результаты: стойкое выздоровление наступило у 42 больных, улучшение — у 2, ухудшение — у 2.

RÉSUMÉ

Les résultats précoces et tardifs du remplissage plastique des cavités osseuses, à l'aide de greffons cutanés perforés libres, lors des ostéomyélites chroniques

I. I. Zacharov

On considère la couverture d'une cavité osseuse à l'aide d'un lambeau musculaire ou cutané, sur un pédicule nutritif, comme la méthode de choix pour le traitement de l'ostéomyélite chronique.

L'absence de muscles du côté antérieur de la jambe, surtout en ce qui concerne le tiers inférieur, ainsi que les possibilités très limitées d'une mobilisation de la peau pour couvrir la défectuosité persistance après l'excision des scarifications ne permet pas de terminer l'opération par une suture simple.

La fermeture des cavités osseuses à l'aide d'une mobilisation locale de la peau (Chaklin, Kromov, Lord et d'autres), une greffe musculaire prélevée de l'autre jambe

(Ariev et Nikitin, Lindenbaum, Dudin et d'autres) ou bien la greffe dite italienne à l'aide d'un lambeau de Filatov plié ou non (Smirnov, Sokolov, Keropyan et Gobujev, Rybkina-Furman et d'autres) ne s'opèrent que difficilement en présence de cavités osseuses multiloculaires et ne sont pas toujours couronnées de succès. En plus, ces méthodes nécéssitent une position pas naturelle des extrémités du malade.

Ces difficultés ont été surmontées à l'aide de la modification nouvelle pratiquée par l'auteur et qui consiste dans une couverture plastique de la cavité osseuse par des greffons cutanés libres dans son épaisseur toute entière. Ses observations cliniques montrent que cette méthode donne des résultats tout à fait satisfaisants. On pratique l'opération en deux étapes: la première consiste dans une séquestration radicale, la deuxième, pratiquée 5 à 6 jour plus tard, comporte l'implantation d'un greffon cutané perforé libre directement dans l'os de la surface intérieure de la cavité osseuse, préparé par l'étape première.

Voici les résultats immédiats, obtenus après couverture des cavités osseuses par des lambeaux cutanés libres, telle qu'elle a été pratiqué sur 50 malades: bons résultats dans 44 cas, satisfaisants chez 5 et non-satisfaisant chez un malade.

Les résultats tardifs ont pu être étudiés sur 46 malades, une à 10 années après l'intervention. Une guérison stable fut atteinte chez 42 malades, une amélioration chez 2 et une détériorisation a été constatée chez 2 malades.

ZUSAMMENFASSUNG

Früh- und Spätergebnisse der freien Hautplastik von Knochenhöhlen mit einem perforierten Spaltlappen bei der Behandlung der chronischen Osteomyelitis

I. I. Sacharow

Die plastische Korrektion von Knochenhöhlen mit Hilfe eines Muskel-Hautlappens, der einen die Ernährung sicherstellenden Stiel besitzt, ist bei der Behandlung der chronischen Osteomyelitis die Methode der Wahl.

Der Mangel an geeigneten Muskeln an der Vorderseite des Schienbeins, insbesondere in seinem unteren Drittel, der die Möglichkeit einer Mobilisierung der Haut nach Excision der Narben einschränkt, gestattet es jedoch nicht, den operativen Eingriff durch Anlegen einer üblichen Naht zu beenden.

Di vielfach vorgeschlagene Plastik von Knochenhöhlen mit Hilfe der Mobilisierung der lokalen Haut (W. D. Tschaklin, B. M. Chromow, I. Lord und andere), der Uebertragung von Muskeln von der anderen Extremität (T. Ja. Ariew und G. D. Nikitin, I. S. Lindenbaum, W. A. Dudin und andere) sowie einer nicht-freien Hautübertragung nach italienischer Art beziehungsweise eines aufgerollten oder nicht aufgerollten Filatowschen Lappens (I. A. Smirnow, A. P. Sokolow, K. S. Keropjan und N. Je. Gobujew, R. M. Rywkina-Furman und andere) ist bei ungleichmässigen Knochenhöhlen technisch mit bedeutenden Schwierigkeiten verbunden und durchaus nicht immer erfolgreich. Ueberdies bedingt sie eine erzwungene Lage der Extremität des Patienten.

Diesen Nachteil der Plastik vermeidet der Verfasser durch eine neue Modifikation der freien Hautplastik von Knochenhöhlen mit Hilfe eines perforierten Spaltlappens in ganzer Hautschicht. Klinische Beobachtungen ergaben, dass die freie Hautplastik von Knochenhöhlen in der Modifikation des Verfassers völlig zufriedenstellende Resultate liefert. Die Operation wird in zwei Etappen durchgeführt: zuerst wird eine radikale Sequestrotomie ausgeführt ; nach 5 bis 6 Tagen erfolgt die zweite Etappe der Operation — eine freie Hautplastik mittels eines perforierten Spaltlappens unmittelbar auf die präparierte Wand der Knochenhöhle.

Die unmittelbaren Resultate der freien Hautplastik von Knochenhöhlen waren gut bei 44 von 50 Patienten, zufriedenstellend bei 5 und unbefriedigend bei 1 Kranken.

Die Spätresultate der freien Hautplastik von Knochenhöhlen wurden bei 46 Patienten 1 bis 10 Jahre nach der Operation untersucht. Sie ergaben: Dauerheilung bei 42 Patienten, Besserung bei 2, Verschlechterung bei 2 Kranken.

REFERENCES

1. **Antelava, N. V.**: Khirurgia, (Mosk.) vol. 10, p. 36—43, 1945.
2. **Aryev, T. Y.**: Chronic Gunshot Osteomyelitis (Pathology, Pathogenesis, Clinical Features and Treatment); dissertation, Leningrad 1949.
3. **Aryev, T. Y., Nikitin, G. D.**: Muscle Plasty of Bone Cavities, Medgiz, Moscow 1955.
4. **Bocharov, A. A.**: Paper read at the 1233rd session of the Pirogov Surgical Society on April 8, 1959.
5. **Gabuyev, N. E**: Khirurgia (Mosk.) vol. 12, p. 14—16, 1948.
6. **Girgolav, S. S., Aryev, T. Y.**: Vrach. Delo vol. 11, 1947.
7. **Gomzyakov, G. A.**: Vestn. Khir. im. Grekova vol. 3, 1945.
8. **Zakharov, I. I.**: Vestn. Khir. im. Grekova vol. 4, p. 73—76, 1957.
9. **Kornev, P. G.**: Pathogenesis and Development of Traumatic Osteomyelitis; from the book «Works of the Leningrad Branch of the All-union Institute of Experimental Medicine», Moscow 1946.
10. **Krasnobayev, T. P.**: Nov. Khir. Arkh. vol. 44, 4, p. 264—272, 1939.
11. **Lidski, A. T.**: Infected Gunshot Fracture, Gunshot Osteomyelitis, Sverdlovsk 1946.
12. **Medvedev, P. M.**: Vestn. Khir. im. Grekova vol. 12, p. 116—117, 1959.
13. **Nikitin, G. D.**: Khirurgia (Mosk.) vol. 4, p. 48—52, 1955.
14. **Rybkina-Furman, R. M.**: Surgical Treatment of Chronic Gunshot and Haematogenous Osteomyelitis in Long Bones. Novosibirsk 1960.
15. **Smirnov, I. A.**: Nov. Khir. Arkh. vol. 4, p. 524—536, 1928.
16. **Sokolov, A. P.**: Vestn. Khir. i Pogranich. Obl. vol. 16, 47, p. 96—99, 1929.
17. **Fridland, M. O.**: Purulent Osteomyelitis, Medgiz 1946.
18. **Chaklin, V. D.**: Ortop. Travm. Protez. vol. 5, p. 21—26, 1955.

(I. I. Zakharov): ul. Vavilova, 13, flat 3, Ufa, B.A.S.S.R

Universitätsklinik für Gesichts- und Halschirurgie der Medizinischen Fakultät (Charité)
Berlin (DDR)
Direktor: Prof. med. habil. Dr. H. Mennig

ÜBER NASOFRONTALE ENCEPHALOCELEN

H. MENNIG

Die nasofrontalen Encephalocelen werden den angeborenen sogenannten Spaltbildungen des Schädels im Formenkreis der dysrhaphischen Mißbildungen zugeordnet; sie gehören mit den Fehlbildungen im Bereich der Wirbelsäule zu den congenitalen Anomalien, die man nach Peters besser als Schlußstörung bezeichnet. Wir unterscheiden im Bereich des Schädels je nach dem Sitz vordere und hintere Encephalocelen, ein geringer Prozentsatz hat seine Lokalisation an anderen atypischen Stellen des Schädels.

Nach pathologisch-anatomischen Gesichtspunkten handelt es sich bei den Encephalocelen um hernienartige Ausstülpungen des Schädelinhaltes durch Lücken der knöchernen Schädelkapsel. Sind nur Teile der Hirnhäute durch die Knochenöffnung getreten, sprechen wir von Meningocelen; befinden sich auch vorgefallene Hirnteile in dem Hautsack, nennen wir sie Encephalo- bzw. Encephalocystocelen; oft kann die genaue Feststellung der Celenart erst bei der Operation getroffen werden. Stets stehen die Celen mit dem Liquorsystem in Verbindung und nehmen somit an den physiologischen und pathologischen Druckveränderungen im Schädel teil. Zwar findet sich öfter ein gleichzeitiger Hydrocephalus internus, jedoch nicht immer; auf Grund dieser Tatsache wird er von manchen Autoren als Ursache der Mißbildung abgelehnt. Zverev und Bachtijarov berichten, daß der Schädelumfang im allgemeinen bei Encephalocelen geringer ist als im Durchschnitt. Die Knochenlücken in der Schädelkapsel liegen ausgesprochen in der Mittellinie; auf dem Röntgenbild erweisen sie sich als runde, glattrandige Öffnungen; Sektionsbefunde bestätigen diese klinische Feststellung. Häufig sind Encephalocelen mit anderen Mißbildungen des Gehirns verbunden, zum Beispiel wurden Kombinationen mit Mikrencephalie, Mikrogyrie, Großhirn- und Kleinhirnasymmetrie, sowie Fehlen ganzer Hirnteile beobachtet; Zverev und Bachtijarov zum Beispiel fanden unter 104 Kranken mit angeborenen Encephalocelen 12 mal eine ausgesprochene Mikrocephalie. Ein klinischer Bericht von Benzer und Schönbauer nennt unter den zusätzlichen Mißbildungen bei Hirnbrüchen noch schwerste Myopie, sehr große beidseitige Leistenbrüche, Lippengaumenspalten und Plexuslähmung.

Nach einem Vortrag auf dem Tschechoslowakischen Medizinischen Kongreß vom 12. bis 17. November 1962 in Prag

Entwicklungsgeschichtlich wird verschiedentlich ein frühembryonaler Entwicklungsfehler im zentralen Nervensystem angenommen; als Bestätigung dafür werden auch hirnhistologische Untersuchungen angeführt. Ostertag jedoch betrachtet die frontalen Encephalocelen als Mangelbildung am Schluß der frontobasalen Schädelknochen bzw. deren Ossifikation. Im Gegensatz zu den dorsalen Meningocelen nimmt er bei den vorderen Brüchen im Gebiet des gesamten Schädels an, daß vielfach keine primäre Gehirnerkrankung, sondern Hypoplasien oder Fehlanlagen des Visceralskeletts vorliegen. Manche Autoren betonen, daß diese Entwicklungsstörung weder hereditär noch familiär auftritt und nicht mit anderen Mißbildungen kombiniert sein muß (Dodge, Love und Kernohan).

Es ist nicht leicht, exakte Zahlen über die Häufigkeit der Encephalocelen zu erhalten. Eine Zusammenstellung großer Zahlen neueren Datums gibt Ivy, R. H. in seiner Veröffentlichung über „Congenital Anomalies Recorded on Birth Certificates in the Division of Vital Statistics of the Pennsylvania Department of Health 1951—1955" und den dazugehörigen Ergänzungstabellen.

In diesem Zeitabschnitt kamen bei 1 201 976 Geburten 9 829 Mißbildungen (8,2 auf 1 000) zur Beobachtung, davon betrafen 2 280 (23,2 % der Mißbildungen überhaupt und 2 auf 1 000 Geburten) den Kopf. Von diesen 2 280 Mißbildungen des Kopfes waren 176 Meningocelen, das heißt 8 % der Kopfmißbildungen und ungefähr 2 % der Mißbildungen überhaupt oder 1,5 Meningocelen auf 10 000 Geburten oder anders ausgedrückt, auf 6 000 bis 7 000 Geburten ein Hirnbruch. Die Bezugszahlen für die Berechnung der Häufigkeit schwanken allerdings zwischen 4 000 (Bergmann) und 11 500 (Zverev und Bachtijarov) Geburten für eine Encephalocele.

Eine Aufteilung der statistischen Erhebungen Ivy's nach Beobachtungsjahr und Geschlecht ergibt für die Meningocelen die Tabelle 1. Eine Zunahme auch der Meningocelen im Formenkreis der angeborenen Mißbildungen ist an dieser Zusammenstellung erkennbar; das deckt sich mit zahlreichen Angaben des Schrifttums der letzten 10 Jahre. Während allgemein bei den Mißbildungen 60 % auf männliche und 40 % auf weibliche Neugeborene insgesamt entfallen, ist bei den Meningocelen des Kopfes das Verhältnis weiblich zu männlich umgekehrt 3 zu 2 (64 % zu 36 %).

Tab. 1. Häufigkeit von Hirnbrüchen bei 1 201 976 Lebendgeborenen im Zeitraum 1951—1955 (nach Ivy, R. H.: Congenital Anomalies)

Jahr	1951	1952	1953	1954	1955	gesamt
männlich	12	11	16	11	14	64
weiblich	14	22	28	16	32	112
gesamt	26	33	44	27	46	176

Über die Häufigkeit der sincipitalen Encephalocelen unter den Hirnbrüchen liegen die Angaben von Reali (zitiert bei Cordes) vor; aus der Gesamtzahl von 140 Hirnbrüchen waren 33 = 24 % sincipitale Encephalocelen, wobei die ganz überwiegende Mehrzahl (31) auf die reinen Encephalocelen (19) und die Encephalocystocelen (12) entfällt, während Meningocelen nur 2 mal vorkommen (Tab. 2). Dodge, Love und Kernohan geben an, daß auf 3 500 bis 4 000 Geburten eine Encephalocele anterior kommt; diese Häufigkeit erscheint nach dem Überblick in der Literatur und den genauen Zahlen von Ivy doch unwahrscheinlich groß.

Tab. 2. Lokalisation von 140 Hirnbrüchen und Häufigkeit der sincipitalen H. (nach Reali)

	Reine Encephalocelen	Encephalocystocelen	Meningocelen	Gesamt
Gesamt	60	50	30	140
occipital	31	36	19	
sincipital	19 (= 32 %)	12 (= 24 %)	2 (= 6,7 %)	**33** (= **24** %)
sagittal	6	2	4	
lateral	4	—	4 (+1 basal)	

Über die Häufigkeit der nasofrontalen Encephalocelen unter den sincipitalen Encephalocelen im besonderen und den Encephalocelen des Kopfes im allgemeinen lassen sich schwerlich Zahlen zusammenstellen. Klier hat aber schon früher betont, daß die Cephalocele nasofrontalis bei weitem die häufigste der vorderen Cephalocelen ist.

Zwar unterscheiden wir in grober Einteilung nach dem Sitz der Mißbildung am Kopf vordere (sincipitale) und hintere (occipitale) Encephalocelen; doch läßt sich die Lokalisation noch weiter differenzieren. So findet man im Schrifttum Unterscheidungen zwischen einer Cephalocele occipitalis superior und inferior, je nachdem der Sitz oberhalb oder unterhalb des Hinterhauptshöckers ist. Bei den vorderen, auch sincipitale Encephalocelen genannt, trennt man je nach der Richtung des Vordringens die nasofrontalen von den nasoethmoidalen und den nasoorbitalen; vereinzelt wurde der Durchtritt in die Nasen-Rachenhöhle, in die Fossa sphenomaxillaris oder durch eine Gaumenspalte in die Mundhöhle beschrieben.

Die nasofrontale Encephalocele tritt an der Glabella durch eine Verschlußlücke des Schädelknochens aus, und zwar im Bereich des Stirnbeines und der Ossa nasalia, sie sitzt demnach an der Grenze von Nasenwurzel und unterem Stirnbeinanteil. Der Erwähnung bedarf eine Beobachtung von Brunetti, der bei

der Operation eines Tumors mit typischem Sitz an der Glabella keine Verbindung mit der Schädelhöhle fand und auf Grund des histologischen Befundes am Operationspräparat, der auf degenerierte Hirnsubstanz lautet, eine nasofrontale Encephalomeningocele annimmt, die nachträglich gegen die Schädelhöhle abgeschlossen wurde.

Sehen wir einmal von den gewiss seltenen, zum mindesten sehr selten beobachteten und beschriebenen occulten Cephalocelen, bei denen nur eine Knochen-

Abb. 1.

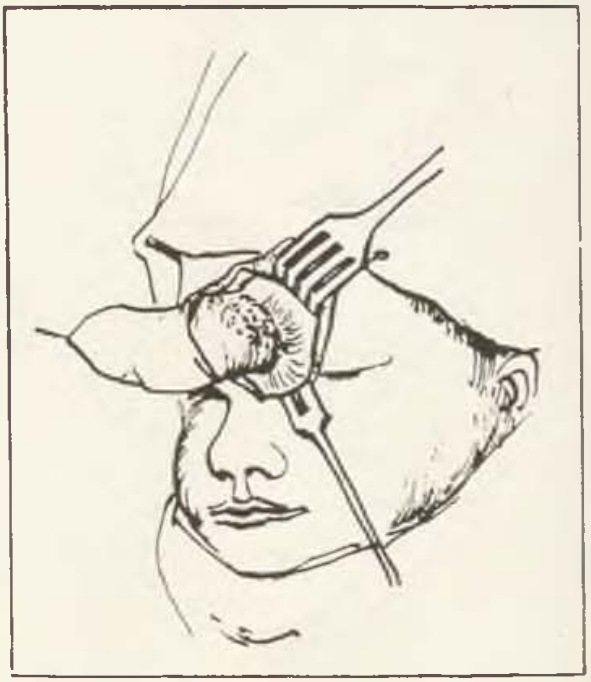

Abb. 2.

Abb. 1. Zeichnung von einem 3 Monate alten Säugling mit großer, wurstförmiger nasofrontaler Encephalocele (2. Beobachtung). — Abb. 2. Operationsskizze zur Schnittführung.

lücke ohne Hirnbruch besteht, ab, finden wir immer im Gebiet der Glabella eine mehr oder weniger starke Vorwölbung, die aber auch erst bei einer gewissen Größe den klinischen Verdacht auf eine Cephalocele erweckt. So kann es nicht überraschen, daß Verwechselungen mit medianen Nasencysten hohen Sitzes oder Angiomen durchaus möglich sind.

1. Beobachtung: Bei einem 3 Monate alten Säugling weiblichen Geschlechts war von Geburt an eine langsam wachsende weiche Schwellung an der Nasenwurzel festgestellt worden; sie hatte jetzt etwa Kirschgröße erreicht. Unter der Verdachtsdiagnose einer medianen Nasencyste wurde das Kind operiert; es fand sich ein Tumor, der mit einem Stiel durch einen kreisrunden linsengroßen Defekt des Schädelknochens an der Nasenwurzel Verbindung zum Schädelinnern hatte. Die histologische Untersuchung des Operationspräparates ergab Hirngewebe, so daß es sich also zweifellos um eine nasofrontale Encephalocele handelte.

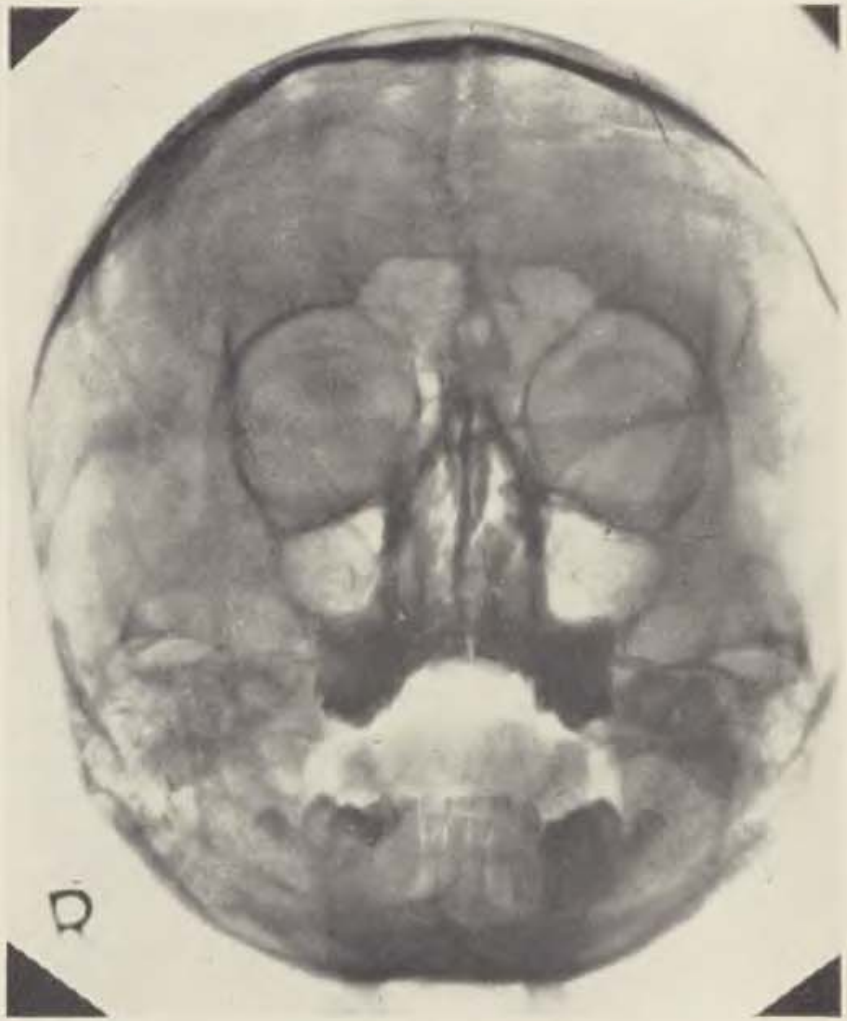

Abb. 6. Die Röntgenaufnahme des Schadels zeigt den Knochen defekt an der Nasenwurzel 11 Jahre nach der Operation (1. Beobachtung).

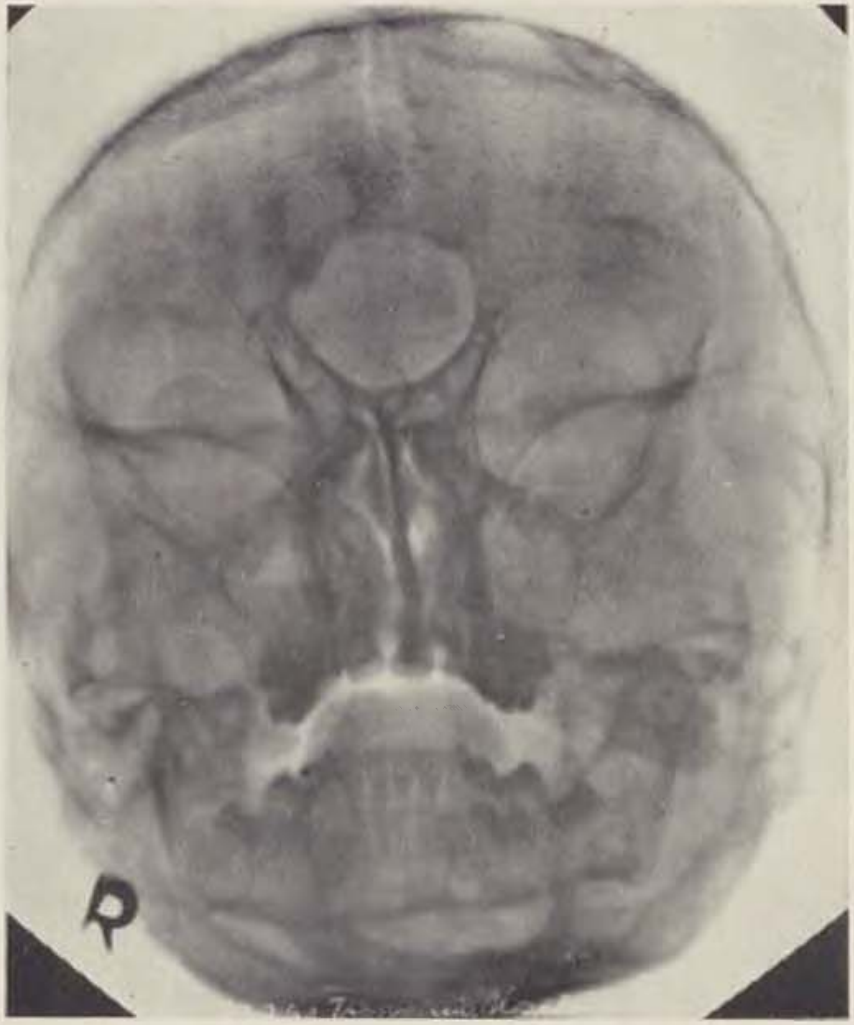

Abb. 9.

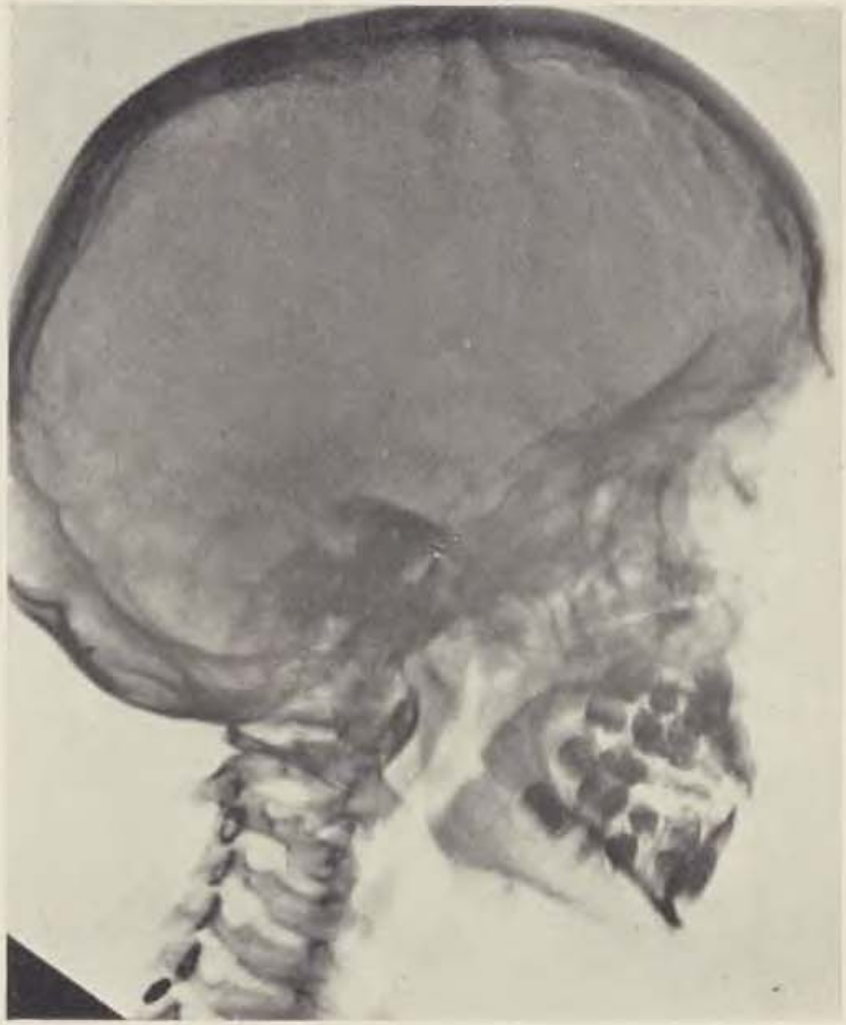

Abb. 10.

Abb. 9 und 10. Die Röntgenaufnahmen des Schädels lassen den großen Knochendefekt im Stirnbein erkennen (2. Beobachtung).

Die Größe der nasofrontalen Encephalocelen schwankt in weiten Grenzen. Muscatello und auch Luz beschreiben je eine orangegroße Meningocele an der Nasenwurzel, die das linke Auge bedeckte, bzw. im linken Nasenaugenwinkel saß. Schwalbe erwähnt, daß schnelles Wachstum nach der Geburt zunächst kleine Encephalocelen bis zur Größe eines Kindkopfes werden läßt.

2. Beobachtung: Erhebliche Größe hatte auch bereits die nasofrontale Encephalocele unserer zweiten Beobachtung, als der Säugling im Alter von 14

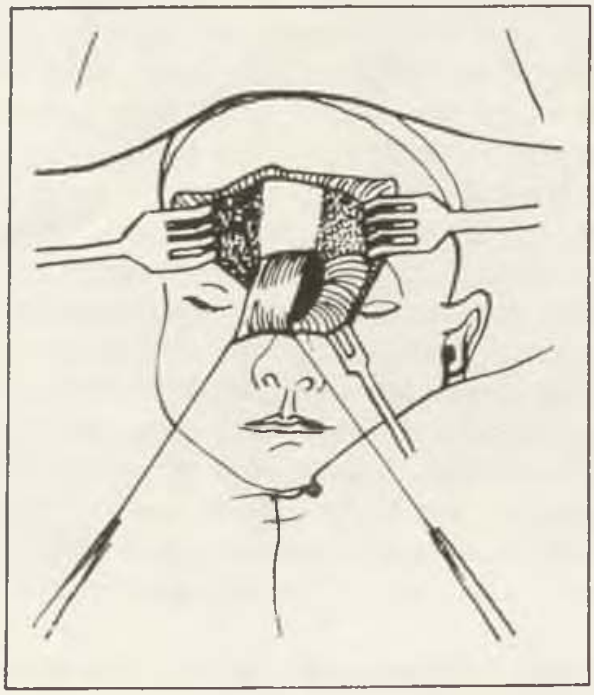

Abb. 3. Operationsskizze von der Bildung des Periostlappens aus der Stirn, der nach unten über die Knochenlücke gezogen ist.

Tagen vorgestellt wurde. Im Alter von ¼ Jahr kam er mit folgendem Befund zur Operation: Oberhalb der Nasenwurzel findet sich eine wurstförmige Ausstülpung der äußeren Haut von etwa 5 cm Länge und 2,5 cm Durchmesser. Der Inhalt ist von weicher Konsistenz und zeigt deutliche Fluktuation. Im Stirnbein ist eine etwa 1,5 mal 1,5 cm große Knochenlücke zu tasten (Abb. 1).

In beiden Fällen ließ sich röntgenologisch eine Knochenlücke an der Glabella nachweisen, die im zweiten Falle besonders ausgedehnt war. Der letztere Fall wurde folgendermaßen operiert:

Die Umschneidung der Haut am Fuße der Encephalocele wird so angelegt, daß für den späteren Hautverschluß ausreichend Material vorhanden ist (Abb. 2). Die Encephalocele wird bis an die Schädellücke heran präpariert und dort abgesetzt. Doppelte Übernähung der Dura. Zur weiteren Verstärkung der Duranaht wird aus dem Periost des Stirnbeins ein am oberen Defektrand gestielter Lappen gebildet, über die Knochenlücke heruntergezogen und allseitig eingenäht (Abb. 3). Darüber exakte Hautnaht.

Während früher die Meningocelen möglichst nicht operiert, sondern vielmehr mit Kompression, Abschnürung, Punktionen und Alkohol- bzw. Jod-Injek-

tionen behandelt wurden, hat sich die operative Behandlung mehr und mehr durchgesetzt. In neuerer Zeit wird der frühzeitige plastische Verschluß der Dura mit freier Transplantation von Fascie aus der Fascia lata und die spätere Deckung der Knochenlücke mit Knochenstückchen aus der Darmbeinschaufel empfohlen; über die erfolgreiche osteoplastische Behandlung einer Encephalocele sincipitalis mit bohnengroßer Knochenöffnung berichtete Neugebauer übrigens bereits im Jahre 1897!

Während früher der Exitus an einer Meningitis häufig war, haben die Möglichkeiten der antibiotischen Prophylaxe die Prognose entscheidend gebessert. Noch 1928 vertraten Piquet und Tramblin den Standpunkt, kleine Encephalocelen in der Frontalgegend wegen der Gefahr einer meningealen Infektion nicht zu operieren. Die postoperative Sterblichkeit war in der vorantibiotischen Zeit sehr hoch, wie alle Berichte des Schrifttums ausweisen; sie wird von Rodzinski mit 45 bis 55 % angegeben (nach Cuttler). Die Anwendung der Antibiotica als Vor-, Schutz- und Nachbehandlung brachte für die Operationsmortalität eine grundlegende Wende; weitere Verbesserungen der Operationsergebnisse wurden durch die genauere Kenntnis der anatomischen Zusammenhänge (Cobb), die Anwendung der modernen Narkoseverfahren und die Verwertung neurochirurgischer Operationsgrundsätze (Davis und Alexander) möglich.

Es dürfte aber unter diesem Aspekt auch für unsere antibiotische Ära wohl noch immer und in verstärktem Maße gelten, was Cordes schon 1927 über die Aussichten der Cephalocelenträger in der aseptischen Ära sagte, daß die Besserung der Prognose nur „quoad vitam", nicht „qoad valitudinem completam" zu beurteilen ist.

Während man früher den Zeitpunkt für die Operation der Encephalocelen im allgemeinen in die ersten Lebenswochen gelegt wissen wollte (Piquet und Tramblin), wird die zeitliche Indikation für den operativen Eingriff jetzt mehr in das höhere Säuglingsalter verlegt; auf Grund der Fortschritte in der Kinderchirurgie empfiehlt Zettler für die Operation der Meningocelen die Zeit nach dem 8. Lebensmonat.

Als günstigsten Zeitpunkt für die Operation der Fehlbindungen des Schädels allgemein nennt Burmeister wegen der erheblichen Operationsgefährdung im Säuglingsalter die Zeit nach dem 6. oder sogar nach dem 12. Lebensmonat; Cephalocelen ohne wesentliche Hirnbeteiligung und ohne Perforationsgefahr können mit geringerem Operationsrisiko auch noch im frühen Kindesalter operiert werden. Das mag für viele Formen der Hirnbrüche gelten, bei den großen nasofrontalen Encephalocelen aber liegt die Situation ganz anders.

Eine solche Mißbildung bringt eine so große Entstellung des Gesichtes mit sich, daß die Eltern des Kindes die Beseitigung der Encephalocele dringend wünschen und der Arzt sich diesem Wunsche nicht verschließen kann. Wegen der angeborenen Größe oder des raschen Wachstums der Encephalocele ist der Wunsch der Eltern nach frühzeitiger Hilfe ebenso verständlich, und so steht der Chirurg vor der Frage der Frühoperation.

Leider ist im einschlägigen Schrifttum nur sehr wenig über das spätere Schicksal operierter sincipitaler Encephalocelen bekannt geworden. Cordes referiert die Dauerresultate nach Operationen der Gehirn enthaltenden Ence-

Abb. 4.

Abb. 5.

Abb. 4 und 5. Befund 11 Jahre nach Entfernung einer kirschgroßen nasofrontalen Encephalocele (1. Beobachtung).

phalocelen nach einer Zusammenstellung von Bolle wie folgt: von 11 Fällen starben 5 früh, 5 lebten noch im Alter von 1, 2, 11 und 12 Jahren, alle in traurigem Zustand, mit Hydrocephalus, gelähmt, stumm, blind oder idiotisch, jedenfalls in körperlicher und geistiger Entwicklung weit zurückgeblieben (ein Fall konnte nicht ermittelt werden). Zusammenfassend beurteilt er das Schicksal der Cephalocelenträger auch nach der Operation sehr trübe, vor allem im Hinblick auf Fernresultate. Allerdings räumt er den Meningocelen mit engem Stiel und kleinen Encephalocelen am Vorderhaupt noch relativ günstige Aussichten ein.

Hier möchte ich wieder an unsere beiden Krankengeschichten anknüpfen. Um mir über die Fernresultate der Operation ein Urteil bilden zu können, habe ich beide Kinder 8 bzw. 11 Jahre nach der Operation zur Nachuntersuchung gehabt und sie neurologisch-psychiatrisch beurteilen lassen.

Das Kind mit der kirschgroßen nasofrontalen Encephalocele (1. Beobachtung) war bei der Nachuntersuchung 11 Jahre alt. Die Entwicklung des Mädchens war regelrecht verlaufen, die Schulleistungen sind nach Angaben der Eltern zufriedenstellend. Örtlich fand sich eine feine reizlose Narbe, senkrecht über Glabella und Nasenwurzel verlaufend (Abb. 4, 5). Das Röntgenbild (Abb. 6) zeigt den linsengroßen Knochendefekt an der Glabella, durch den der Stiel der Encephalocele in das Schädelinnere führte.

Bei der neurologisch-psychiatrischen Untersuchung konnten keine verwertbaren pathologischen Befunde erhoben werden, die für eine Hirnläsion sprechen könnten. Psychisch war das Kind unauffällig.

Abb. 7.

Abb. 8.

Abb. 7 und 8. Aufnahmen mit dem Befund 8 Jahre nach Entfernung der großen, wurstförmigen nasofrontalen Encephalocele (2. Beobachtung).

Einige Berichte über ähnliche gute Ergebnisse der operativen Behandlung nasofrontaler Encephalocelen sind auch im Schrifttum zu finden. So hat Achutin einen 15 Monate alten Knaben mit kirschgroßer Encephalocele sincipitalis nasofrontalis durch Abtragung und plastischen Verschluß des Defektes geheilt. Benzer und Schönbauer berichten unter den Spätergebnissen nach operativer Behandlung von 4 sincipitalen Meningoencephalocelen: ein Fall (im Alter von 5 Jahren operiert) war 11 Jahre nach der Operation „gut", die Operationsstelle unauffällig; es bestanden anfallsweise Kopfschmerzen, in der Schule sei er etwas schwach. Viele andere Autoren mit gleich guten Erfolgsberichten könnten hierzu noch angeführt werden. Über ein besonders günstiges postoperatives Ergebnis berichtet Šafránek: Nach der Operation eines Hirnbruches im medialen Lidwinkel links, der bei einem 16jährigen psychisch zurückgebliebenen Mädchen seit Geburt bestand, besserte sich die Intelligenz nach der Operation.

In unserem zweiten Fall fand die Nachuntersuchung 8 Jahre nach der Operation statt. Das Mädchen hatte in der Zwischenzeit im Alter von 2½ Jahren einen Unfall: es fiel in den Sand, war zyanotisch und kurze Zeit bewußtlos. Es sollen vorübergehend schlaffe Lähmungen bestanden haben. In der folgenden Nacht seien die Augenlider angeschwollen, die Schwellung ging aber schnell zurück. — 3 Jahre später wurde wegen Mastoiditis die Mastoidektomie links durchgeführt.

Bei der Nachuntersuchung war das 8jährige Mädchen in gutem Ernährungs- und Kräftezustand.

Über der Nasenwurzel erhebt sich eine pulsierende Vorwölbung, die deckende Haut zeigt reizlose Narben. In der Tiefe läßt sich der glatte Rand eines etwa Markstückgroßen Knochendefektes tasten. Die Bulbi stehen weit auseinander (Abb. 7 und 8).

Die Röntgenaufnahmen p. a. und seitlich zeigen den großen Knochendefekt an der Glabella mit glatten Rändern (Abb. 9 und 10).

Von größtem Interesse ist der neurologisch-psychiatrische Status und seine Bewertung. Die intellektuelle Ausstattung des Kindes liegt etwa 2 Jahre zurück. Psychisch verhält es sich völlig distanzlos und ungehemmt, es ist sehr lebhaft und unruhig. Es besteht ein deutlicher Konzentrationsmangel. Die geistigen Leistungen sind wechselnd. Der psychische Befund wird als Ausdruck einer Orbitalhirnschädigung beurteilt; der neurologische Befund ist krankhaft verändert und weist auf eine tieferreichende Hirnschädigung hin, wobei offenbleibt, ob angeboren oder bei dem Unfall entstanden.

In Anbetracht der Größe der Encephalocele bei dieser Beobachtung kann man das Ergebnis als zufriedenstellend ansehen, wenn auch funktionell von seiten des Gehirns eine Schädigung festzustellen ist. Es erhebt sich epikritisch die Frage nach den Indikationen zur Operation der nasofrontalen Encephalocelen.

Wie die erste Beobachtung mit der kirschgroßen nasofrontalen Encephalocele zeigt, ist die Prognose der Operation kleiner vorderer Hirnbrüche sowohl hinsichtlich der Hirnfunktion als auch der Kosmetik sehr günstig; ein operativer Eingriff hat beste Aussichten auf vollkommene Heilung.

Bei den großen Encephalocelen, auch mit sincipitalem Sitz, wird die Indikation zum chirurgischen Eingreifen viel zurückhaltender gestellt; die oben zitierte Ansicht von Cordes über das traurige Schicksal von Cephalocelenträgern nach der Operation und die geringe Zahl von Veröffentlichungen über günstige Fernresultate mögen zu dieser Einstellung beigetragen haben.

Bei den großen nasofrontalen Encephalocelen drängt jedoch neben allen anderen Überlegungen ein besonderer Umstand zum operativen Eingriff: die Beseitigung der durch die Mißbildung verursachten groben Entstellung des Gesichtes wird von den Eltern dringend gewünscht. Für die chirurgische Behandlung speziell dieser Mißbildung treten wieder ästhetische, kosmetische Gesichtspunkte in den Vordergrund.

Unsere zweite Beobachtung berechtigt zu der Empfehlung, die Anzeige für die Operation auch der großen nasofrontalen Encephalocelen weiter zu stellen, als früher allgemein geschehen, und die Frühoperation dieser Mißbildung mehr als bisher in Erwägung zu ziehen; eine Hirnschädigung gewissen Umfanges muß dabei allerdings unter Umständen in Kauf genommen werden.

ZUSAMMENFASSUNG

Die Indikation zur chirurgischen Behandlung der selteneren angeborenen Mißbildungen wie der Meningocelen und Encephalocelen, ist vor allem bei schweren Formen noch umstritten; man trifft häufiger auf ablehnende als auf zusprechende Einstellung zum operativen Vorgehen. Bei den nasofrontalen Encephalocelen drängt aber neben allen anderen Überlegungen ein besonderer

Umstand zum Handeln: die Beseitigung der durch die Mißbildung verursachten groben Entstellung des Gesichtsanblickes wird von den Eltern dringend gewünscht; und aus dem gleichen Grunde wird man auch die Frühoperation mehr in Erwägung ziehen müssen.

Leider wird in der Literatur nur sehr wenig über das spätere Schicksal operierter sincipitaler Encephalocelen bekanntgegeben. Der Bericht über je einen Fall acht Jahre und elf Jahre nach der Operation kann vielleicht dazu beitragen, die Anzeige zum chirurgischen Eingreifen weiter zu stellen, als bisher allgemein geschehen.

SUMMARY

Nasofrontal Encephalocoele

H. Mennig

The indications for the surgical treatment of rare congenital malformations like meningocoele and encephalocoele are still a matter of controversy, especially in the case of severe forms. More authors tend to be against operation rather than in favour. In nasofrontal encephalocoele a special factor has to be taken into account in addition to all the usual considerations. The parents press for removal of the gross facial disfigurement and for this reason the possibility of prompt operation will have to be taken into consideration more frequently than hitherto.

The literature unfortunately contains few references on the later fate of patients operated on for sincipital encephalocoele. This report of one case eight years and of another eleven years after operation may help to widen the scale of indications for operation.

RÉSUMÉ

A propos des encéphalocèles rhino-frontales

H. Mennig

L'indication pour la thérapie chirurgicale des malformations congénitales rares, telles que la meningocèle et l'encéphalocèle, surtout leurs formes graves, continue à être discutée. Nous rencontrons plus souvent une opinion négative qu'un encouragement à l'opération. En présence des encéphalocèles rhino-frontales, il faut encore, en dehors de toutes les autres conditions, tenir compte d'une circonstance spéciale: les parents exigent énergiquement l'écartement de cette défiguration grave; et pour cette raison même, il sera nécessaire d'envisager une opération à temps plus fréquemment que ce n'était le cas dans le passé.

Dans la littérature, on ne trouve malheureusement que de très rares indications au sujet des résultats tardifs des encéphalocèles sincipitales opérées. La presentation d'un cas 8 ans après l'opération et d'un autre après 11 ans va peut-être contribuer à l'élargissement de l'indication pour l'intervention chirurgicale dans une mésure plus grande que ce n'était le cas jusqu'à présent.

RESUMEN

Algunas notas acerca de los encefaloquelos nasofrontales

H. Mennig

Las indicaciones para un tratamiento quirúrgico de las malformaciones congénitas raras, como por ejemplo meningoquelos y encefaloquelos, en las formas graves en particular, son hasta ahora problemáticas; más a menudo encontramos el punto de vista

negativo que positivo en cuanto a una intervención operatoria. En los encefaloquelos, aparte de las demás premisas, existe una condición especial exigiendo acción. Los padres demandan muy urgentemente la liquidación de las malformaciones de la cara y así del mismo motivo será necesario tomar en consideración una intervención operatoria más temprano y efectuarla a tiempo.

Por desgracia la literatura que existe dice poco acerca de los resultados de la operación tardía de los encefaloquelos sincipitales. La información sobre un caso después de 8 años y sobre un caso después de 11 años después de la operación quizá contribuya a la extensión de la indicación para una intervención operatoria en la escala más grande que hasta ahora.

SCHRIFTTUM

1. **Achutin, M.:** Ref. Zentr.-Org. Chir. 49, 31, 1930.
2. **Alexander, E.:** s. bei Davis.
3. **Bachtijarov, V. A.:** s. bei Zverev.
4. **Benzer, H., Schönbauer, L.:** Münch. med. Wschr. 100, 565, 1958.
5. **Bergmann:** zit. bei Rodzinski.
6. **Bolle:** zit. bei Cordes.
7. **Brunetti, C.:** Ref. Zentr.-Org. Chir. 43, 446, 1928.
8. **Burmeister, H.:** Zbl. Chir. 87, 220, 1962.
9. **Cobb, C. A.:** Ref. Zentr.-Org. Chir. 138, 167, 1955.
10. **Cordes, E.:** Erg. Chir. 22, 258, 1929.
11. **Cuttler:** zit. bei Rodzinski.
12. **Davis, C. H.:** Ref. Zentr.-Org. Chir. 159, 268, 1960.
13. **Dodge, H. W., Love, G., Kernohan, J. W.:** Ref. Zentr.-Crg. Chir. 159, 267, 1960.
14. **Ivy, R. H.:** Plast. reconstr. Surg. 20, 400, 1957.
15. **Ivy, R. H.:** Ergänzungstabellen zu vorstehendem Titel.
16. **Kernohan, J. W.:** s. bei Dodge.
17. **Klier:** zit. bei Cordes.
18. **Love, G.:** s. bei Dodge.
19. **Luz, F.:** Ref. Zentr.-Org. Chir. 12, 76, 1921.
20. **Muscatello:** zit. bei Schwalbe.
21. **Neugebauer, F.:** Zbl. Chir. 24, 1203, 1897.
22. **Ostertag, B.:** in Henke-Lubarsch: Handbuch der Speziellen pathologischen Anatomie und Histologie. B. 13, 4. Teil, S. 409. Springer Verlag, Berlin-Gottingen-Heidelberg 1956.
23. **Piquet, J., Tramblin, R.:** Ref. Zentr.-Org. Chir. 40, 19, 1928.
24. **Reali:** zit. bei Cordes.
25. **Rodzinski, R.:** Ref. Zentr.-Org. Chir. 38, 428, 1927.
26. **Šafránek, J.:** Ref. Zentr.-Org. Chir. 30, 26, 1925.
27. **Schönbauer, L.:** s. bei Benzer.
28. **Schwalbe, E.:** Morphologie der Missbildungen. B. III, Kap. II: Missbuldungen des Nervensystems, S. 110, G. Fischer Verlag, Jena 1909.
29. **Zettler, F.:** Münch. med. Wschr. 100, 840, 1958.
30. **Zverev, A. F., Bachtijarov, V. A.:** Ref. Zbl. Hals- usw. Heilk. 46, 201, 1953.

(Prof. Dr. Dr. H. Mennig): Berlin-Rahnsdorf, Seestraße 43, DDR

Abteilung für Plastische Chirurgie, Zentral Spital, Budapest (Ungarn)
Vorstand: Doz. Dr. med. J. Zoltán, CSc.

AUGENBRAUENERSATZ NACH DEM „TRANSPORTLAPPEN"-VERFAHREN

J. ZOLTÁN

Die Augenbrauen werden meistens durch Verbrennung, seltener infolge einer direkten mechanischen Einwirkung (Schuß, Skalpierung) und nur ausnahmsweise durch eine Erkrankung, vor allem durch einen chronisch-entzündlichen Prozeß (Tbc, Lepra), zerstört. Ihr Ersatz ist auch in funktioneller Beziehung wichtig (die Augenbraue schützt das Auge vor dem hineinwehenden Staub, vor Wind und dem herabrinnenden Schweiß), aber zumeist wird die Operation mit ästhetischer Indikation vorgenommen, die bei Männern noch wichtiger erscheint als bei Frauen, die sich — der Mode entsprechend geformte — Augenbrauen malen können.

Der Augenbrauenersatz kann mittels freier Transplantation oder durch Stiellappenplastik ausgeführt werden. Die freie Transplantation (Braun-Wagner) ist die riskanteste Methode, weil die meisten Haare aus der transplantierten Haut ausfallen. Zwecks Verbesserung des Ergebnisses hat man verschiedene technische Lösungen erprobt: Der die Haare enthaltende behaarte Kopfhautstreifen (von der Temporal-, Retroaurikulär oder Okzipitalgegend) wurde so entnommen, daß er mit der Galea in Verbindung blieb; die Schnittlinien wurden schräg nach außen geführt (so daß das Transplantat im Querschnitt trapezförmig war); man überpflanzte einen breiten Streifen in der Hoffnung, daß die Haare in der Mitte erhalten bleiben bzw. transplantierte man mehrere Streifen usw. Alle diese Modifikationen haben kaum zu einer Verbesserung des unsicheren Verfahrens geführt.

Viel sicherer und mit besserem Resultat läßt sich die Augenbraue mit dem Stiellappenverfahren ersetzen. Auch diese Methode hat viele Varianten, und die Wahl des Verfahrens hängt von den lokalen Verhältnissen ab.

Man kann von der behaarten Kopfhaut einen einfachen einstieligen Lappen auf den Platz der Augenbraue rotieren (wenn keine zu große Entfernung zwischen dem Rand der behaarten Kopfhaut und der Augenbraue besteht), oder man kann einen zweistieligen (Brücken-, Visier-) Lappen anwenden, dessen Blutversorgung gewährleistet ist, weil der Lappen die Arteria temporalis-Zweige enthält (Senn, Gillies, Santos u. a.). Letzterer wird hauptsächlich zum Ersatz des bilateralen Augenbrauendefektes in Anspruch genommen. Gillies benutzte den

an einem Rand des zum Nasenersatz exzidierten großen Skalplappens befindlichen behaarten Kopfhautabschnitt zum gleichzeitigen Ersatz der Augenbraue. Zaikowá präparierte an der Temporal- bzw. Retroaurikulärgegend einen Rundstiellappen und ließ diesen erst zur Stelle der einen, dann zu der der anderen Augenbraue wandern.

Bei einseitigem Defekt ließ Passot den durch longitudinale Halbierung der intakten Augenbraue gewonnenen Lappen zum Defekt rotieren.

Abb. 1. Die Patientin vor der Operation.

Millard ließ einen von der Schambehaarung entnommenen Lappen unter Vermittlung eines Fingers zur Augenbrauenstelle wandern.

Der Ersatz mittels Stiellappen stellt ein sicheres Verfahren dar, welches lediglich den geringen Nachteil hat, daß in der Regel ein breiterer Streifen überpflanzt und der Überschuß in einer besonderen Sitzung entfernt werden muß. Diesem Nachteil kann durch das von Esser beschriebene sog. „Arterienlappen" - Verfahren abgeholfen werden, das zweifellos das schönste Ergebnis bietet. Technisch beansprucht es sehr präzise Arbeit, weil der Lappen nekrotisiert, wenn das den Stiel bildende Gefäßpaar lädiert oder komprimiert wird. Statt die Gefäße ganz herauszupräparieren, dürfte es zweckmäßiger sein, sie von Bindegewebe umgeben zu separieren, weil sie auf diese Weise besser geschützt sind.

Wie das bei der plastischen Chirurgie so häufig vorkommt, wird der Operateur auch bei dem Augenbrauenersatz mitunter vor Aufgaben gestellt, bei denen die bekannten Verfahren nicht angewendet werden können.

So geschah es auch im folgenden Fall, bei dem das in Abb. 1 dargestellte 16jährige Mädchen operiert werden sollte, das als kleines Kind eine Verbrennungsverletzung erlitt und bei dem die im Verlauf der sekundären Wundheilung entstandenen hypertrophischen Narben das ganze Gesicht, fast die Hälfte der behaarten Kopfhaut und die Rückenfläche beider Hände und Unterarme bedeckten. Im Gesicht der Patientin waren im Laufe der Jahre — leider ohne Erfolg — mehrere Operationen vorgenommen worden. Hierbei versuchte man

Abb. 2. Situation nach der ersten Sitzung des Augenbrauenersatzes: der vereinigte Augenbrauen- und Transportlappen.

auch den Ersatz der fehlenden Augenbrauen; von den frei transplantierten Hautstreifen fielen indessen die meisten Haare aus, und die verbliebenen wenigen Haare änderten nichts an der Entstellung.

Zuerst waren wir bestrebt, die unschönen Narben zu entfernen und mit intakter Haut zu ersetzen, d. h. die Stirnhaut ersetzten wir mit Hilfe der Spalthautlappenplastik und gleichzeitig placierten wir die erhalten gebliebenen behaarten Kopfhautpartien so um, daß diese an die Randteile zu liegen kamen und das wachsende Haar die zentral gelegenen kahlen Stellen bedeckte. In der 2. Sitzung entfernten wir (gleichfalls in Intratrachealnarkose) die Narben von den anderen Gesichtspartien und deckten das Gesicht unter Beachtung der funktionellen Einheiten (Gonzalez-Ulloa, Karfík) durch freie Transplantation von Spalthautlappen.

Nunmehr kam der Augenbrauenersatz an die Reihe. Freie Transplantation zogen wir gar nicht in Betracht, und die Stiellappenplastik konnte nach den bekannten Verfahren nicht angewendet werden, weil die restliche behaarte Kopfhaut voller Narben war, die teils noch von der Verbrennung und teils von den späteren Operationen stammten.

Unter Berücksichtigung der Verhältnisse erfolgte der Augenbrauenersatz nach folgender Methode:

I. Operation. Am Platz der Augenbraue schnitten wir einen zur Temporalgegend gestielten Lappen, der den dorthin frei transplantierten und haarlos gewordenen Streifen enthielt. Dieser wurde unterminiert, herausgehoben und die Stelle mit Einzelnähten geschlossen. Den Lappen bogen wir in Richtung der behaarten Kopfhaut der Temporalgegend heraus, und in seiner Nachbarschaft, an der in Abb. 4 sichtbaren Stelle, exzidierten wir einen in Form und Größe der zu ersetzenden Augenbraue entsprechenden Lappen, der gleichfalls aufpräpariert

Abb. 3. Die Patientin nach Beendigung der Operationsserie.

wurde, wonach wir die Entnahmestelle schlossen. Dieser zweite Lappen wurde so auf den von der Augenbrauengegend herausgebogenen Lappen gelegt, daß die Wundränder einander berührten. In dieser Lage vereinigten wir die Lappenränder mit einigen Einzelnähten, während wir ihre ungedeckten, zum Stiel blickenden Oberflächen mittels freier Transplantation eines Spalthautlappens abdeckten (Abb. 2, 5, 6). Form und Richtung des Kopfhautlappens wurden so gewählt, daß die Wachstumsrichtung der im Lappen befindlichen Haare an der Empfangsstelle mit der der Augenbraue übereinstimme (in den Abb. durch kleine Pfeile bezeichnet).

II. Operation. Nach 3 Wochen wurde das Ende des von der behaarten Kopfhaut entnommenen Lappens von seiner Basis abgelöst. An der dem abgerundeten Lappenende entsprechenden Stelle, in der medialen Hälfte des Augenbrauenplatzes, exzidierten wir die Haut in entsprechender Form und nähten den Lappen mit einigen Stichen in den auf diese Weise angelegten Defekt ein (Abb. 7). Der „Augenbrauenlappen" wurde von den ihn tragenden „Transportlappen" ausgezeichnet ernährt, und seine Einheilung am neuen Platz ging störungsfrei vonstatten.

III. Operation. Nach weiteren 3 Wochen, als wir uns durch Abklemmung des Transportlappenstiels davon überzeugt hatten, daß die Lappen-Duplikatur vom medialen Ende her zufriedenstellend versorgt wird, lösten wir den Trans-

Abb. 4.

Abb. 5.

Abb. 6.

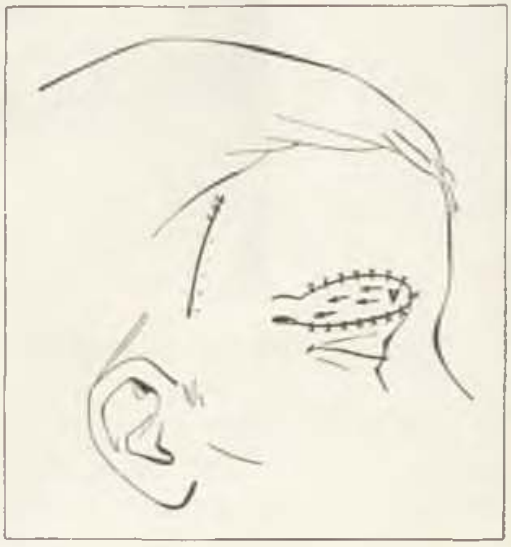

Abb. 7.

Abb. 8.

Abb. 4. Die Schnittlinien des „Augenbrauenlappens" und des „Transportlappens". — Abb. 5. Die aufpräparierten und einander angenäherten Lappen. Die kleinen Pfeile zeigen die Richtung des Wachstums der Haare. — Abb. 6. Das Aneinandernähen der Lappen. — Abb. 7. Das Einnähen des „Augenbrauenlappens" in die vorbereitete Empfangsstelle. — Abb. 8. Zustand vor dem Endstadium der symmetrisch durchgeführten Operation.

portlappen ganz vom Augenbrauenlappen ab und entfernten ersteren vollständig, indem wir in einem der noch fehlenden lateralen Augenbrauenhälfte entsprechenden Gebiet die Empfangsstelle vorbereiteten. Das freie Ende des durch Ablösung des Transportlappens aufgefrischten Augenbrauenlappens wurde mit einigen Stichen in das auf diese Weise vorbereitete Wundbett eingenäht. Auch nach der 3. Operation kam es zu ungestörter Wundheilung.

Naturgemäß haben wir die Operationsserie auf beiden Seiten gleichzeitig, symmetrisch durchgeführt (Abb. 8). Die keinerlei Korrektion erfordernde, zufriedenstellende endgültige Form der nach einem sich zwangsläufig ergebenden Verfahren ersetzten Augenbrauen zeigt Abb. 3.

ZUSAMMENFASSUNG

Eine neue Methode des Augenbrauenersatzes wird beschrieben, die im wesentlichen darin besteht, daß ein vom Platz der Augenbraue entnommener, temporal gestielter Lappen als „Transporteur" zur vorübergehenden Ernährung bzw. Wanderung des von der behaarten Kopfhaut entnommenen „Augenbrauenlappens" verwendet wird. Die in drei Sitzungen durchgeführte Operation ermöglicht den endgültigen Ersatz der Augenbrauen.

ВЫВОДЫ

Восстановление бровей при помощи «транспортного лоскута»

J. Zoltán

Описан новый метод восстановления бровей, заключающийся, главным образом, в том, что временно применяется лоскут на ножке в качестве «транспортера» для временного снабжения питанием и пересадки «бровного лоскута», взятого с покрытой волосами кожи головы. Операция, сделанная в трех этапах, позволила произвести с успехом восстановление бровей.

SUMMARY

Reconstruction of Eyebrows with «Transport Flap»

J. Zoltán

A new modification of the reconstruction of eyebrows has been described. It consists in the use of a transport flap for the transplantation of a skin flap from the hairy part of the temples destined to form the eyebrows.

The operation which is completed in three stages, permits perfect reconstruction of the eyebrows.

RÉSUMÉ

La réconstruction des sourcils à l'aide du „lambeau de transport"

J. Zoltán

Une nouvelle modification de la réconstruction des sourcils vient d'être décrite. Elle consiste en utilisation d'un lambeau de transport servant à transplanter un lambeau de cuir de la partie temporale chevelue, destiné à former les sourcils.

L'opération, réalisée en trois étapes, a permis de compléter la réconstruction parfaite des sourcils.

RESUMEN

Reconstrucción de las cejas con ayuda de un „lóbulo transportador“

J. Zoltán

En este papel se describe una modificación nueva de la reconstrucción de las cejas. Consiste en el empleo de un „lóbulo transportador“ designado para la transplantación de un lóbulo cutáneo de la parte cubierta de pelo de las sienes con el motivo de formar las cejas.

La operación que se completa en tres etapas permite una reconstrucción perfecta de las cejas.

(Doc. Dr. J. Zoltán, C. Sc.): Lepke utca 16, Budapest II, Ungarn

Clinic of Plastic Surgery, Brno (Czechoslovakia)
Director: Prof. V. Karfík, M.D.

NEW METHOD OF TREATING AVULSION OF THE INSERTION OF THE DORSAL APONEUROSIS

L. HASMAN

Injury of the extension system of a finger is not unusual and can be met with in persons of various professional and social strata.

Most frequently the distal part, i.e. the insertion of the dorsal aponeurosis, is affected and this injury has come to the forefront of our interest mainly because its treatment has, up to the present, not been very successful. Recommendations of new therapeutic methods keep appearing in the literature.

Damage to the dorsal aponeurosis can be caused by an open injury, such as a cut, or by a closed mechanism, e.g. a forcible flexion of an extended finger.

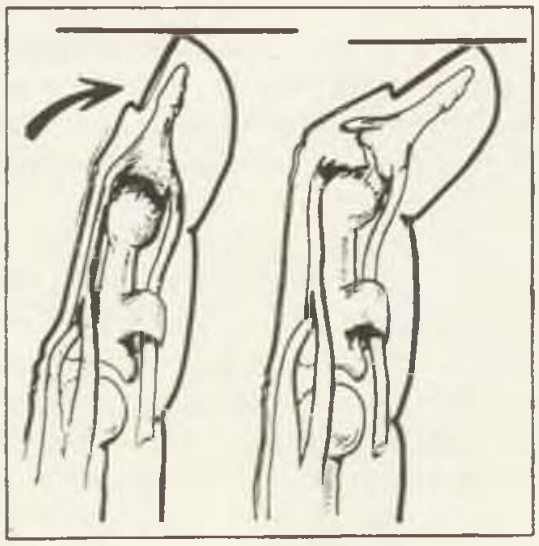

Fig. 1.

The closed injury to the insertion of the dorsal aponeurosis occurs more frequently and belongs mainly to the group of sport and domestic accidents, whereas the open injury caused by a sharp instrument is predominantly found in work accidents.

Sharp severing of the aponeurosis insertion is facilitated by the anatomical structure of the dorsal aspect of the finger. The thin and fine skin with its

thin layer of subcutaneous tissue lies immediately on the flat tendinous insertion and represents no obstacle to the sharp edge penetrating right to the aponeurosis, even if little force is applied.

The closed injury is the result of sudden and unimpeded passive flexion of the terminal phalanx with the small muscles and extensors contracted (Fig.

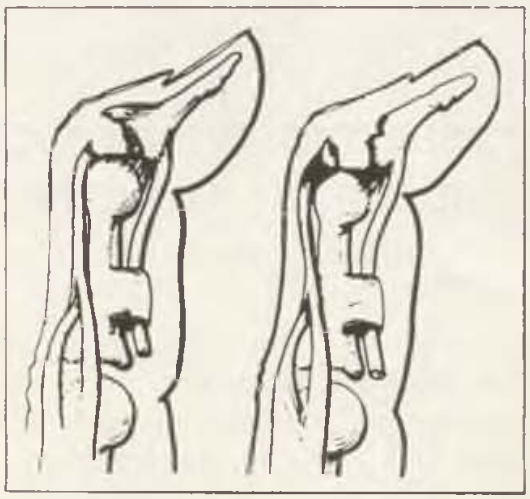

Fig. 2.

1). By the impact with the obstacle the terminal phalanx is flexed to an extent exceeding that of the firmness of the tendon tissue.

The force acting at the base of the terminal phalanx causes injury to the tendon at the most exposed point, i.e. at the point of insertion or in its immediate vicinity. In a particularly forcible impact the angle of flexion becomes still greater and the resulting increase in the tension of the dorsal aponeurosis leads to avulsion of bone at the base of the terminal phalanx at the site of the tendon insertion (Fig. 2).

Thus two types of closed injury of the aponeurosis insertion develop which must be well differentiated from a therapeutic point of view. Apart from these, a third, rather rare form of closed injury develops by overstraining the tendon where it crosses the joint which leads to fraying of the tendon fibres and thus to lengthening of the tendon insertion without macroscopic disruption of its continuity. The resulting deformity is essentially the same as that of the other two types, i.e. the extension system is incapable of extending the terminal phalanx to the full range because of lengthening of the part of the tendon at the insertion.

In the literature, the resulting deformity of the terminal phalanx is generally termed mallet finger. The mechanism of this injury, however, is better characterized by the English expression baseball or volleyball finger.

The patients usually pay little attention to a closed injury of the insertion of the dorsal aponeurosis immediately after the accident. This is mainly due to their considering it to be only a small sprain accompanied by comparatively little pain. Only avulsion of the bone of the base of the terminal phalanx causes pain of greater intensity.

Haemorrhage and oedema of the entire region developing shortly after the accident, too, may camouflage the deformity, and only the unchanging faulty position of the phalanx and the incapability of extending it induce the patient to seek medical advice.

In open injuries of this kind we do not meet with such indifference, because

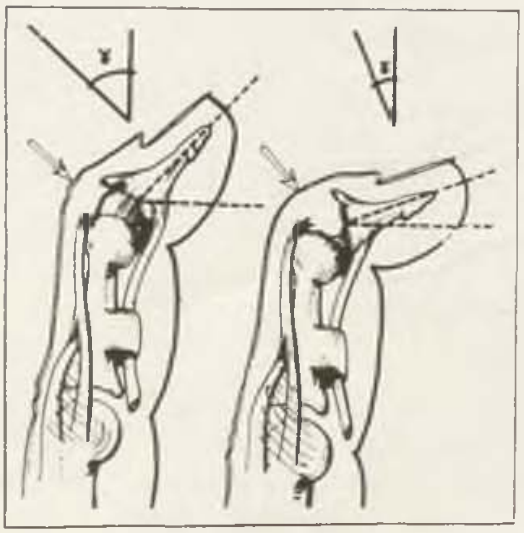

Obr 3.

Obr. 4.

the nature of the injury itself compels the patient to seek surgical treatment at once, and also because of the deformity being conspicuous immediately.

Due to the typical position of the terminal phalanx, the diagnosis of the injury meets with no difficulties. X-ray skiagraphy in the lateral projection should be regarded as an indispensable complement to examination. Slight dislocation of the terminal phalanx together with gaping of the articular fissure indicates additional damage to the dorsal aspect of the joint capsule whose tension — when intact — counteracts the pull of the flexor profundus.

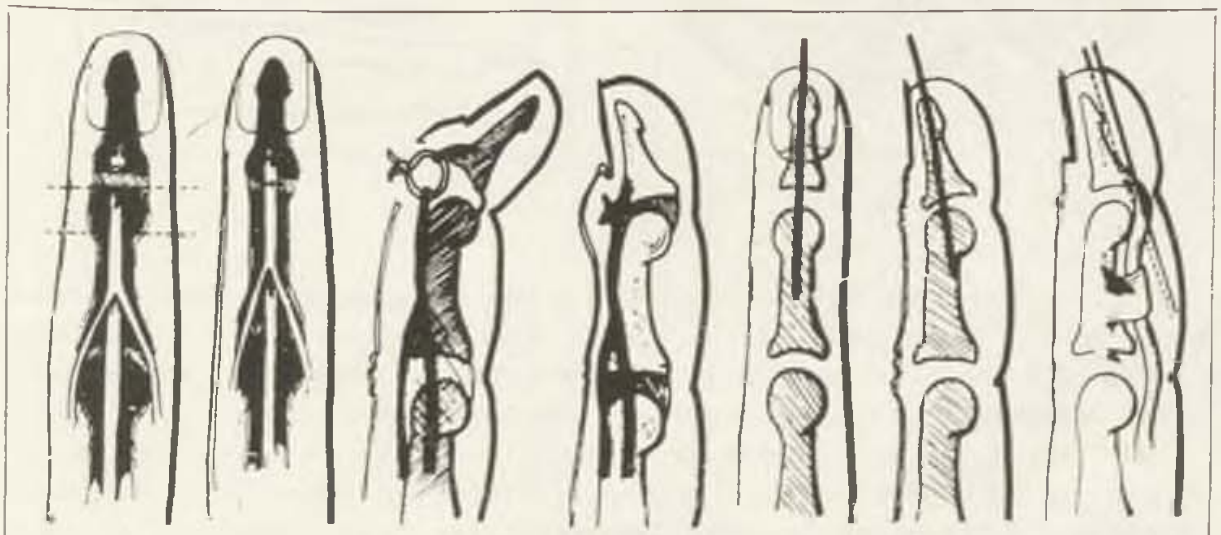

Fig. 5a. ISELIN Fig. 5b. NICHOLS Fig. 6a. PRATT Fig. 6b. VERDAN

The second type of closed injury, is characterized in the diagram, by the clearly visible bone fragment avulsed from the base of the terminal phalanx and dislocated proximally into the close vicinity of the head of the middle phalanx.

Interruption of the firm connection of the aponeurosis with the base of the terminal phalanx leads to a disturbance of the functional equilibrium between the flexor and extensors in favour of the flexor profundus. The avulsed insertion

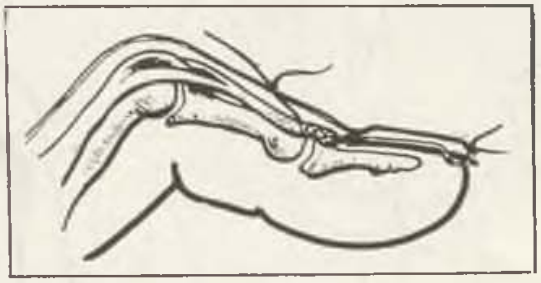

Fig. 7.

is pulled proximally by the action of the small muscles and the extensor. As long as the joint capsule has remained intact this proximal shift is usually small (about 3—4 mm.), because the insertional part of the aponeurosis is closely adherent to the dorsal part of the capsule. This impediment ceases to act as soon as the dorsal part of the capsule is also torn so that the proximal shift of the avulsed insertion increases (Fig. 3). When the firm connection of the aponeurosis is lost, the lateral bands are also retracted by the action of the small muscles. The edge of the proximal stump thus reaches the level of the now prominent head of the middle phalanx and behaves like a severed tendon

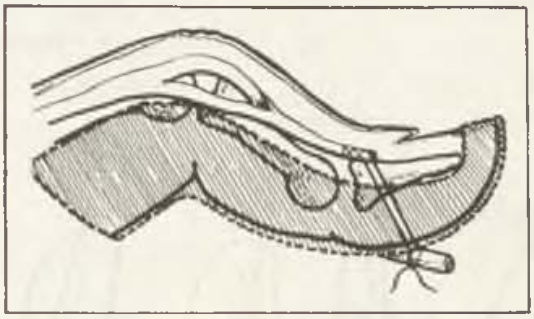

Fig. 8a.

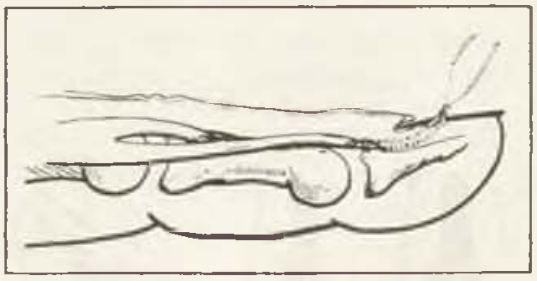

Fig. 8b.

(Fig. 4). It soon sends out budding pseudopodial fibres which become adherent to the head of the middle phalanx and fix it to its surroundings so that soon after the accident it will be firmly embedded. Thus, within two to three weeks of the accident, a permanent deformity has developed.

The tear in the joint capsule between the base of the terminal phalanx and the head of the middle phalanx is gradually bridged by a tough, initially hypertrophic scar firmly connected with the surrounding tissue throughout its entire extent. In untreated cases this scar is thin and becomes distended due to the

flexed position of the terminal phalanx. After conservative treatment particularly of a subtotal tear or of fraying of the insertion, i.e. after immobilization of the joint in hyperextension, a firm scar develops, which when it becomes rigid together with the joint capsule, may imitate a good result. However, it soon gives way to the pull of the flexor profundus and the typical flexion deformity of the terminal phalanx recurs (Novák).

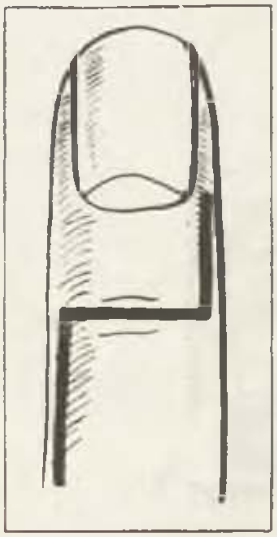

Fig. 9.

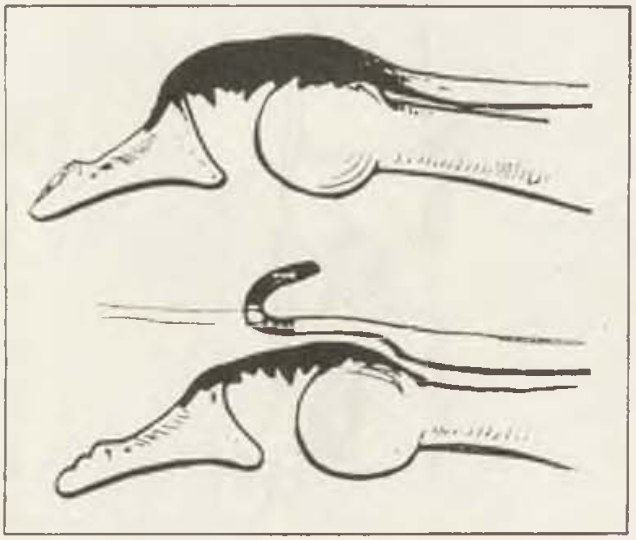

Fig. 10.

As to the question of treatment of the injured dorsal aponeurosis insertion, opinions differ between the advocates of conservative and those of surgical methods. In their papers the representatives of the conservative school demonstrate evidence to the fact that very good results may be achieved by the employment of the proper method of immobilization for a long enough period — at least six weeks — without damage to the nail bed and without scars both of which usually appear after surgical treatment.

The conservative method of treatment of the injured dorsal aponeurosis insertion is widely favoured because it is simple and can easily be employed under the most difficult conditions in out-patients.

Critical evaluation of the results after conservative treatment, however, has diminished the initial enthusiasm proportionately to the percentage of failures which also represent a considerable economic loss due to the patient being unfit for work for a long period. Only in cases where the injured tendon insertion has been treated immediately after the accident or where it has been possible to reduce the bone fragment evulsed together with the tendon insertion to the base of the terminal phalanx, is a certain percentage of success to be expected from conservative treatment. In children, in whom shorter immoblization is required the results of conservative treatment are more satisfactory.

At the end of the last century, Duchenne and Cruveilhier described the anatomical and functional complexity of the dorsal aponeurosis, but — up to recently — this was not generally known. Its function was frequently identified with that of the extensor longus; little importance was ascribed to the small

muscles. The surgical methods based on this conception could never bring about satisfactory results.

Iselin attempted direct suture of the insertional part by a relative lengthening of the distal part of the dorsal aponeurosis through resection of the head of the middle phalanx. After the operation he immobilized the finger for five weeks. This method, however, was objected to by the advocates of conservative

Fig. 11.

Fig. 12.

treatment. We, too, cannot agree with such an unjustifiably mutilating operation (Fig. 5 a).

Neither can the operation of Nicols, who uses a strip of the palmaris longus tendon for suturing the torn end of the aponeurosis, be regarded as correct. In this way, admittedly, firm union of the tendon stumps may be achieved, but the coarse suture material inevitably leads to disturbances of the delicate functional mechanism of the dorsal aponeurosis, not to speak of the bad cosmetic effect due to the elevated dorsal aspect of the distal interphalangeal joint (Fig. 5 b).

The failures after suturing were explained by inadequate immobilization of the terminal phalanx provided by a plaster cast. Pratt, therefore, uses a thin Kirschner wire introduced through the bone of the terminal phalanx and through the distal interphalangeal joint into the head of the middle phalanx whereby the terminal phalanx is immobilized in hyperextension. He then frequently even omits suturing the torn insertion of the aponeurosis. The wire is removed after six weeks. The transarticular fixation is, however, connected with the great risk of causing ankylosis of the distal interphalangeal joint or limitation of flexion which, from a functional point of view, is more important than extension. Necessary immobilization can — according to our opinion — be achieved by other, less risky means (Fig. 6 a).

The method of Verdan attains immobilization of the terminal phalanx with two needles introduced into the pulp of that phalanx piercing the tendon of

Fig. 13.

Fig. 14.

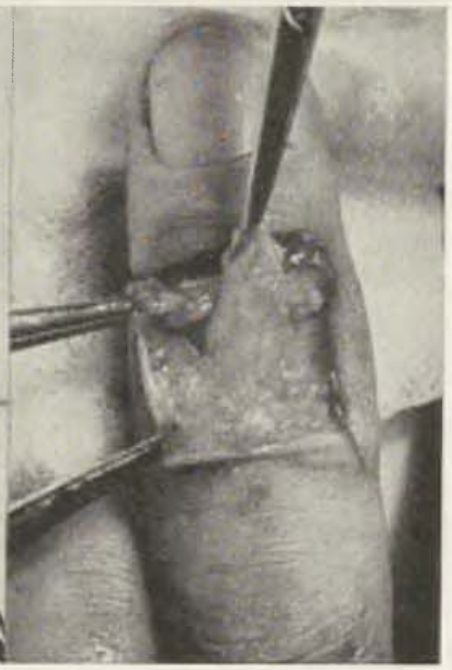

Fig. 15.

flexor profundus just below its insertion into the base of the terminal phalanx (Fig. 6 b), but holds a similar risk.

Bunnell's studies of the extention mechanism formed the foundation of a more intricate but also more successful surgical procedure. The removable suture and atraumatic technique as well as a perfect knowledge of the anatomic-functional features of the extension aponeurosis are Bunnell's contribution in support of the conception of surgical treatment. He exposes the injured insertion

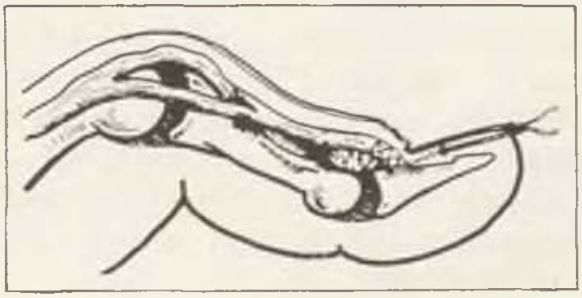

Fig. 16.

of the aponeurosis by an incision in the shape of an inverted "L" and, after mobilizing it from the head of the middle phalanx and the joint capsule, introduces a removable suture into the proximal stump of the tendon, leads it out above the nail and ties it there. He then immobilizes the distal interphalangeal joint in hyperextension and the proximal interphalangeal joint in flexion by means of a plaster cast for a period of five to six weeks (Fig. 7).

Bunnell's physiological procedure laid the foundation of a number of modifications. In the Czechoslovak literature the method of Kuchař et Rypáčková

Fig. 17a.

Fig. 17b.

Fig. 17c.

in which stress is layed on exact immobilization while using a removable suture (Fig. 8 a), and the method of Kirschner who uses a removable suture led under the nail bed and out onto the nail surface where it is knotted (Fig. 8 b), deserve mention.

Neither the original method of Bunnell nor any of its modification, however, are completely satisfactory, because they lead to certain complications, and their functional results are inadequate. The treatment particularly of inveterated injuries to the dorsal aponeurosis insertion still remains an unsolved problem. The repair of these conditions shows a relatively high percentage of failures.

On surgical exposure of untreated or primarily unsuccessfully treated cases we frequently found the avulsed part of the dorsal aponeurosis firmly adherent to the head of the middle phalanx. In our opinion, this adhesion is the cause of failure both of conservative and surgical treatment, including Bunnell's method and its modification, because the volar surface of the freed insertion unites with the head of the middle phalanx and the joint capsule even after its re-insertion to the base of the terminal phalanx.

In order to prevent this adhesion, we supplemented Bunnell's procedure by the interposition of a small flap of fatty tissue.

The operation is carried out under local anaesthesia. For the mobilization of the skin flaps over the injured insertion a bayonet incision is made which proved better than incisions of any other type used by Czechoslovak or other authors (Fig. 9).

The exposed part of the dorsal aponeurosis is then carefully mobilized. Over the distal third of the middle phalanx a blunt bone elevator is pushed under the lateral bands already united at this level. No difficulty is encountered on lifting them from the diaphysis of the bone. More difficult, however, is the

Fig. 18a.

Fig. 18b.

Fig. 18c.

severing of the adhesions between the tendon and the head of the middle phalanx or the joint capsule of the distal interphalangeal articulation. Just above the head of the phalanx, where the proximal stump of the tendon is usually adherent, full-thickness mobilization of the tendon stops and from there distally the scar is divided tangentially by sharp disection (Fig. 10). The volar layer of the scar is left to form a thin cover to the joint. The dorsal, thicker layer is traced up to the base of the terminal phalanx and severed at the level of the insertion or even beyond it, in order to get a longer tendon stump.

The entire scar tissue, including the periosteum, is then removed with a small chisel from the base of the terminal phalanx and a 3 mm. deep pocket is prepared for the subsequent re-insertion of the tendon (Fig. 11).

In an inveterated injury, where a bone fragment, together with the insertion of the dorsal aponeurosis has been avulsed from the base of the terminal phalanx, we do not recommend open reduction. We remove this fragment, because it impedes passive movements of the joint. When left in place for some time, this fragment increases the mallet deformity of the finger and causes painful progressive arthritis of the distal interphalangeal joint.

A removable suture is layed into the freed proximal stump of the tendon and the tendon is folded over proximally. A flap of fatty tissue, 10—15 mm. in length and 6—8mm. in width, is formed on one side of the finger and layed across the head of the middle phalanx and the scar on the dorsal aspect of the interphalangeal joint (Fig. 12 and 13). The pedicle of this flap may — in dependence of the local conditions — be placed either distally (which is the more frequent) or proximally. The free end of this flap is fixed by a fine catgut stitch to the opposite side of the finger. If the critical zone cannot be covered entirely by one flap, there is no obstacle to forming a similar flap on the opposite side.

Fig. 19a.

Fig. 19b.

Fig. 19c.

The blood supply to the fatty tissue flap is usually good and, provided preparation has been carried out carefully, no disruption of it need be anticipated. The vessels, which branch off the digital artery at the level of the middle phalanx, form rich superficial arcades ensuring a good blood supply to the subcutaneous tissue at the base of the terminal phalanx.

The freed end of the aponeurosis is then layed across the fatty tissue flap and each end of the removable suture is led out at opposite sides of the nail (Fig. 14, 15 and 16). Now, the end of the tendon stump is inserted into the prepared bone pocket at the base of the terminal phalanx with the distal interphalangeal joint in hyperextension and the proximal interphalangeal joint in 60^0 flexion. This position ensures maximal relaxation of the lateral bands of the aponeurosis and a minimal pull of the tendon suture. The free ends of the Bunnell stitch are tied under the free margin of the nail and, after suturing the skin wound, the finger is immobilized in the typical position by an exactly moulded plaster splint for a period of four weeks.

By this method, 17 patients with injury to the insertion of the dorsal aponeurosis were operated on at the Clinic of Plastic Surgery in Brno, Czechoslovakia. In another 21 patients the method recommended by Bunnell was employed. Check-ups of the results were carried out in 34 patients at periods between six months and six years after operation. In the remaining four patients the ultimate condition could not be ascertained, because they interrupted rehabilitation before time and did not present themselves for check-up when written for.

On evaluation, we regarded full-range active movement of the distal interphalangeal joint or a slight limitation of extension up to ten degrees as a very good result. Sixteen out of the 17 patients operated on by the method described above, showed very good results both from a functional and cosmetic point of

wiew (Fig. 17 a, b, c; 18 a, b, c; 19 a, b, c). The one failure was due to incorrect indication.

In the group of 17 patients operated on by Bunnell's method only five cases could be evaluated as very good and another four as functionally just satisfactory with a limitation of extension ranging between 20 and 30 degrees.

CONCLUSION

The satisfactory results in the patients operated on by our method prove that interposition of a flap of fatty tissue prevented union of the re-inserted tendon with the joint capsule and the head of the middle phalanx, thus permitting the tendon to remain permanently mobile.

This we consider the main contribution of our method.

Although the good results on check-up actually prove that our procedure is correct, we are still conscious of the fact that the number of patients operated on is not big enough and that only wide usage of the method at many hospitals will permit us to come to a final conclusion.

SUMMARY

The author describes a new method of surgical treatment of the evulsed insertion of the dorsal aponeurosis of a finger. He regards recurrence of the adhesion of the proximal stump of the aponeurosis to the head of the middle phalanx and the joint capsule of the distal interphalangeal joint, which prevents active extension of the terminal phalanx, to be the main cause of the failure after operation with the methods used hitherto.

In order to prevent this adhesion recurring after re-insertion of the tendon, he interposes a small flap of fatty tissue taken from the side of the finger. The results achieved confirm the correctness of this procedure.

RÉSUMÉ

Méthode nouvelle du traitement de l'avulsion de l'insertion de l'aponévrose dorsale

L. Hasman

L'auteur décrit une méthode nouvelle du traitement chirurgique de l'insertion arrachée de l'aponévrose dorsale d'un doigt. Il considère que la cause essentielle des insuccès qui se présentent à la suite des opérations effectuées selon les méthodes en usage jusqu'à maintenant consiste dans la recurrence de l'adhésion du moignon proximal de l'aponévrose de la tête de la phalange moyenne et la capsule articulaire de l'articulation interphalangienne distale, ce qui empêche l'extension active de la phalange terminale.

Pour empêcher le développement de cette adhésion après la remise en place du tendon, l'auteur intercale une petite bande de tissu adipeux, prélevée du bord du doigt. Les résultats obtenus confirment la valeur de cette méthode.

ZUSAMMENFASSUNG

Eine neue Art der Behandlung bei verletztem Ansatz der dorsalen Aponeurose der Finger

L. Hasman

Der Verfasser beschreibt eine neue Art der chirurgischen Behandlung bei Verletzung des Ansatzes der dorsalen Aponeurose der Finger. Die Hauptursache des Misserfolges der bisherigen Verfahren erblickt der Verfasser im Verwachsen des proximalen Abschnitts der zerrissenen Aponeurose mit dem Gelenkskopf der mittleren Phalange und der Gelenkskapsel, was ein Hindernis für die Restitution der Funktion der distalen Phalange darstellt.

Um dieses Verwachsen des reinserierten Ansatzes der dorsalen Aponeurose zu vermeiden, interponiert der Verfasser ein Fettläppchen, das der lateralen Seite des Fingers entnommen wird, zwischen den Gelenkskopf der mittleren Phalange und die reinserierte Aponeurose.

RESUMEN

Nuevo método de trata le avulsión de la inserción de la aponeurosis dorsal

L. Hasman

El autor describe un nuevo método del tratamiento quirúrgico de la inserción avulsada de la aponeurosis dorsal de un dedo. Observa y considera la reaparición de la adhesión del muñón próximo de la aponeurosis hacia la cabeza de la falange media y la cápsula de articulación de la articulación interfalangeal distal, que previene activa extensión de la falange terminal, como la causa principal del fracaso después de la operación con los métodos usados hasta ahora.

Para prevenir esta adhesión que recurre después de la re-inserción del tendón el autor interpone un pedazito del tejido craso tomado del lado del dedo. Los resultados adquiridos confirman la justeza de este procedimiento.

REFERENCES

1. **Bunnell, St.**: Surgery of the Hand. Lippincott 1944.
2. **Rank, B. K., Wakefield, A. R.**: Surgery of Repair as Applied to Hand Injuries. Livingstone Ltd., London 1953.
3. **Nichols, H.**: J. Bone Jt. Surg. (Boston), 33:836, 1951.
4. **Pratt, D. R.**: J. Bone Jt. Surg. (Boston), 34:785, 1952.
5. **Kuchař - Rypáčková**: Rozhl. Chir. 10:613, 1956.
6. **Kirschner, R.**: Acta Chir. orthop. Traum. Čech. 2, 1959.
7. **Kroemer, K.**: Die verletzte Hand. Maudrich, Wien 1945.
8. **Iselin, M.**: Chirurgie de la main. Masson, Paris 1945.

(Dr. L. Hasman): Koterovská 80, Plzeň, Czechoslovakia

Institute of Forensic Medicine, Medical Faculty, Charles University, Prague
(Czechoslovakia)
Director: Doc. S. Hájek, M. D.

DISORDERS OF THERMOREGULATION IN BURNS

S. HÁJEK

The constant temperature of the human organism is maintained by the equilibrium between the various centres of the autonomic nervous system. As regards their functions these centres can be grouped into two strictly antagonistic systems: the sympathetic system with an ergotropic and the parasympathetic system with a trophotropic-endophylactic effect. The ergotropic effect of the sympathetic manifests itself by processes leading to a rise in temperature i.e. by a predominance of dissimilation in the metabolism and by vasoconstriction in the skin. The trophotropic-endophylactic effect of the parasympathetic is characterised by a drop in temperature; the metabolism is dominated by assimilatory processes and the dilatation of skin vessels leads to an increased loss of heat (1, 2, 4, 5, 6).

Stability of body temperature, therefore, depends on the ergotropic and trophotropic-endophylactic effects of the autonomic nervous system, actually on the equilibrium between them. Interference with one of these systems disrupts this equilibrium and brings about a rise or drop in temperature.

The centres of both the sympathetic and parasympathetic systems are situated in the hypothalamic region of the diencephalon: in rostral region the parasympathetic, in the caudal the sympathetic zone.

We were induced to study the hypothalamic part of the diencephalon, because disorders of homoiothermia were frequently observed in the course of burns sickness; some patients die with a high, others with a low temperature (3). We, therefore, started to study the morphology of the hypothalamus with regard to the region where the centre of thermoregulation is situated.

METHODS

The hypothalamus, excised immediately after removal of the brain and prior to the post mortem proper, was fixed in formalin, embedded in paraffin and cut into serial, parasagittal sections 5 μ thick. Every fifth section was glued on with glycerin-protein and stained by Krichelsky's modification of the Mallory method (8). All slides (except those of case A. O. where the hypothalamus was sectioned in a frontal plane and where the region of the commissura rostralis

had not been included) were cross-sections of the whole of the hypothalamus; towards the rostrum the blade passed immediately in front of the commissura rostralis, caudally through the upper margin of the mesencephalon and the dorsal region lying in front of the commissure which runs closely behind the commissura rostralis and in front of the massa intermedia. The lateral sections included the tissue up to 8—10 mm. from the sagittal plane. The situation of the changes was determined by the serial number of the section in the medio-lateral direction and directly from the slide from its topographical position in the specimen.

Because of the autolytic changes in the tissue due to the long interval between death and fixation (an average of 20 hours) only the contents of the vessels and their immediate surroundings were evaluated. The anatomical terminology of Wahren (9) was used for indicating the respective region.

ACTUAL OBSERVATIONS

1. A. O., man of 41, parquet floor layer, injured by burning Parketolit. — Findings: Second and third degree burns of head, trunk and extremities over an area of 70% of body surface. — Survival: 8 days. — Temperature from the third day of his stay in hospital, showed a tendency to rise and on the last day exceeded 40° C. Last temperatures registered 120 and 60 minutes prior to death, were 42° C with the note "scale of thermometer insufficient". — Histology of hypothalamus (right side): Immediately below the ependyma in the region of the nucleus paraventricularis there are minute vessels completely thrombosed with a rim of erythrocytes around each of them. In the larger vessels of this region needle-like fibrin fibres forming tufts can be seen; in the surroundings minute extravasations. The region of the commisura rostralis was not included in the specimen and the left side of the hypothalamus was not investigated.

2. B. H., woman of 65, old-age pensioner, burned in a mountain hut during an explosion of a butane cylinder. After the accident she had rushed out of the hut and ran about in the frosty mountain air for ten minutes. — Findings: Third degree burns and frost bites of the face and both upper extremities over an area of 29% of body surface. Burns sepsis. Initial stage of pneumonia. Sclerosis of coronary arteries. Degeneration of the myocardium. — Survival: 26 days. — Temperature: During her stay in hospital only subfebrile temperatures with two swings over 38° C and 39° C respectively of short duration. In the last 24 hours steep rise to 40.9° C at which the patient died. — Histology of the hypothalamus (right side): In the region of the nucleus prothalamicus periventricularis dorsalis, close to the rostro-dorsal margin of the commisura rostralis and immediately below the ependyma of the third ventricle, minute vessels are thrombosed and show a perivascular rim of erythrocytes. Scattered minute foci of recent haemorrhages. In the lumen of larger vessels there are fibrin fibres forming small tufts. The left half of the hypothalamus shows the same picture.

3. J. Ř., man of 23, welder, burned by a welding set. — Findings: Third degree burns on right upper extremity, lower half of trunk and both lower extremities over an area of 66% of body surface. Burns sepsis. Lobular pneumonia. — Survival: 32 days. — Temperature of septic character: Last temperature, register-

ed about three hours before death, was 39.4° C. — Histology of hypothalamus (right side): In the lumen of larger vessels rostrally to the commissura rostralis and immediately below the ependyma, tufts of fibrin fibres can be seen. The same picture is present in the left half of the hypothalamus.

4. V. B., man of 53, manual worker, burned in a explosion of a distillation apparatus. — Findings: Second and third degree burns of face, thorax and both upper and lower extremities over an area of 65% of body surface. Burns shock. Slight atherosclerosis of aorta, coronary and cerebral arteries. Adhesive pleurisy on right side. — Survival; 18 hours. — Temperatures during his stay in hospital were low; last temperature registered 40 minutes before death was 35.1° C. — Histology of hypothalamus (right side): Laterally to the nuclei mammillares some foci of recent haemorrhages can be seen. The lateral part of nucleus mammillaris medialis is also partly affected by haemorrhage. The same picture on the left side.

5. F. J., man of 73, old-age pensioner, burned while making tea. — Findings: Third degree burns of face and right upper extremity over an area of 7% of body surface. Recent thrombosis of the left coronary artery. Infarction of myocardium. — Survival: 20 hours. — Temperatures during his stay in hospital normal or lower. Last temperature registered 50 minutes before death was 35.2° C. — Histology of hypothalamus (right side): At sites lateral, dorsal and caudal to the corpus mammillare, minute vessels are thrombosed. The same picture on the left half of hypothalamus.

6. R. V., man of 68, old-age pensioner, found aflame in his flat. — Findings: Second and third degree burns over almost the whole surface of the body. Burns shock. Slight oedema of the lungs. Medium atherosclerosis of the aorta. Degeneration of the myocardium. Bilateral adhesive pleurisy. Osteoarthritis of the thoracic spine. Gall stones. — Survival: 4 hours. — Temperatures during his stay in hospital subfebrile. Last temperature registered 20 minutes before death was 37.3° C. — Histology of hypothalamus: No signs of haemorrhage, thrombosis or formation of fibrin can be seen in the right or left half.

7. A. B., woman of 68, old-age pensioner, burned while pouring spirit into a cooker. — Findings: Third-degree burns of upper extremities and trunk over an area of 40% of body surface. Valvular disease of the heart. Brown atrophy of the myocardium. Oedema of lungs. Cirrhosis of liver. Bilateral hydrothorax. Emphysema of lungs. — Survival: 16 days. — Temperature during her stay in hospital normal except for two rather short swings over 38° C. Last temperature registered 12 hours before death was 36.6° C. — Histology of hypothalamus: No signs of haemorrhage, thrombosis or formation of fibrin can be seen in the right or left half.

As may be seen from the above, vascular changes in the hypothalamus in our cases are represented by minute foci of haemorrhage (Fig. 1), thrombosis of small vessels sometimes accompanied by agglomeration of erythrocytes around the capillaries (Fig. 2) and by the formation of fibrin fibres in the larger vessels (Fig. 3). As far as could be ascertained, these findings were always bilateral.

On comparison of the "terminal" temperatures it can be seen that low temperatures (35.1° C and 35.2° C) were registered in changes situated in the posterior parts of the hypothalamus (laterally to the nuclei mammillares), whereas high temperatures (42° C, 40.9° C and 39.4° C) were registered in changes in the anterior parts of the hypothalamus (nucleus prothalamicus periventricularis dorsalis, the region of the nucleus paraventricularis). In the two cases in which the pathological findings were negative, the patients died with a normal temperature (36.6° C and 37.3° C).

When comparing the "terminal" temperatures with the time of survival it becomes evident that during shock the patients died with hypothermia, whereas later with hyperthermia. These findings are in full accord with those registered from several dozens of observations referred to in a previous paper (3).

Because of the small number of observations this study cannot yet be considered concluded. It is, however, certain that it opens a new view into the pathogenesis of burns sickness. It may suffice to bear in mind that the centres of the autonomic system are affected and one can understand that apart from thermoregulation all other vegetative functions may be affected to a larger or lesser degree; some of them may be of vital importance.

On the other hand, however, it still remains unknown how these changes come about. From the anatomical picture it may be assumed that all the above mentioned changes have in common retardation or arrest of blood flow in a certain region, accompanied — in accordance with the nature of the change — by processes of coagulation and haemorrhage. Double location of the findings, i.e. once at sites predominantly supplied from the carotid and at other times those supplied from the vertebral vascular bed, points to the route by which selective haemodynamic changes occur in the brain of patients with burns at different periods after the accident. A more detailed analysis of the question, however, would exceed the scope of this article and, therefore, it will be dealt with in some future papers.

SUMMARY

In seven post mortems of patients dying from burns sickness, thrombosis in vessels and minute foci of haemorrhage were found in the hypothalamic part of the diencephalon. The situation of these changes was closely related to the temperature prior to death. In three patients who died with hyperthermia, these changes were situated in the rostral part of the hypothalamus (nucleus prothalamicus periventricularis dorsalis and the region of the nucleus paraventricularis). In two patients who died with hypothermia, the changes were found in the caudal part of the hypothalamus laterally to the nuclei mammillares. In two patients who died with normal temperatures, no changes were found in the vessels of the hypothalamus.

RÉSUMÉ

A propos de la question des troubles de la thermórégulation chez les brûlés

S. Hájek

Chez 7 sujets décédés à la suite de brûlures on a pu mettre en évidence, dans la portion hypothalamique du diencéphale, une thrombose vasculaire et des hémorragies focales de petite étendue. La localisation de ces alteration était en rapport étroit avec la temperature terminale. Chez trois de ces malades, morts en état d'hyperthermie, ces altérations se trouvaient localisées dans la partie rostrale de l'hypothalamus (nucleus prothalamicus dorsalis, et de la région du nucleus paraventricularis). Chez deux autres malades, morts en état d'hypothermie, les altérations se trouvaient situées dans la partie caudale de l'hypothalamus, à côté des nuclei mamillares. On n'a pu constater aucun changement chez deux malades, morts dans des conditions normothermiques.

ZUSAMMENFASSUNG

Zur Frage der Thermoregulationsstörungen bei Verbrennungen

S. Hájek

Bei sieben, infolge von Verbrennungen, Verstorbenen wurde im hypothalamischen Anteil des Diencephalon Gefässthrombotisationen und kleine Herdblutungen nachgewiesen. Die Lokalisierung dieser Veränderungen hängt eng mit der terminalen Temperatur zusammen. Bei drei Patienten, die in Hyperthermie starben, waren die Veränderungen im rostralen Teil des Hypothalamus (Nucleus prothalamicus periventricularis dorsalis und das Gebiet des Nucleus paraventricularis) lokalisiert. Bei zwei Patienten, die in Hypothermie starben, waren Veränderungen im caudalen Teil des Hypothalamus lateral von Nuclei mammilares vorhanden. Bei zwei Patienten, die in Normothermie starben, wurden keine Veränderungen vorgefunden.

RESUMEN

Algunas notas al problema de la termorregulación en las personas con quemaduras

S. Hájek

En siete personas fallecidas a causa de las quemaduras en la parte diencefálica fue comprobada la trombotización de los vasos y las hemorragias diminutivas de los depósitos. La lozalización de estos cambios tenía una relación muy estrecha con la temperatura terminal. En tres pacientes quienes morían en hipertermia los cambios fueron localizados en la parte rostral de hipotálamo (nucleus prothalamicus periventricularis y la región de nucleus paraventricularis). En dos pacientes, que morían en hipotermia, los cambios en la parte caudal del hipotálamo fueron localizados de manera lateral de los núcleos mamilares. No se hallaron cambios en dos personas quienes morían en normotermia.

REFERENCES

1. **Gottschick, J.:** Die Leistungen des Nervensystems. Jena 1952, p. 402 etc.
2. **Grastchenko, N. I.:** Clinical and Physiological Analysis of Some Features of Diencephalic Pathology. From Collected Works of Grastchenko and Tsuker; chapter: Vascular and Inflammatory Diseases of the Nervous System and the Features of Diencephalic Pathology; p. 206 etc., Moscow 1959.

3. **Hájek, S., Gregora, Z., Štefan, J., Král, Z., Růžička L., Chyba, J., Dobrkovský, M., Doležalová, J.**: Analysis of Thermic Injuries with Fatal Outcome (in print).
4. **Hess, R. W.**: Die funktionelle Organisation des vegetativen Nervensystems, Basel 1948, p. 83 etc.
5. **Hoff, F.**: Vegetatives Nervensystem und innere Sekretion. From the book of Bohnenkamp, H. et al.: Lehrbuch der speziellen pathologischen Physiologie, Jena 1951, p. 511 etc.
6. **Hrbek, J.**: Experimental and Clinical Pathophysiology of the Nervous System, Prague 1956, p. 179 etc.
7. **Nordmann, M.**: Peristatische Hyperaemie mit Diapedesisblutungen. From the book of Lubarsch, O., Henke, F., Roessle, R.: Handbuch der speziellen pathologischen Anatomie und Histologie, V XIII (Nervensystem), p. I, s. B, p. 1189, etc. Berlin, Goettingen, Heidelberg 1957.
8. **Vacek, Z.**: Histology and Histological Technique, Prague 1954, p. 183.
9. **Wahren, W.**: Anatomie des Hypothalamus. From the book of Schaltenbrand, G., Bailey, P.: Einführung in die stereotaktischen Operationen, Stuttgart 1959.

(Doc. St. Hájek): Šrobárova 50, Praha 10, Czechoslovakia

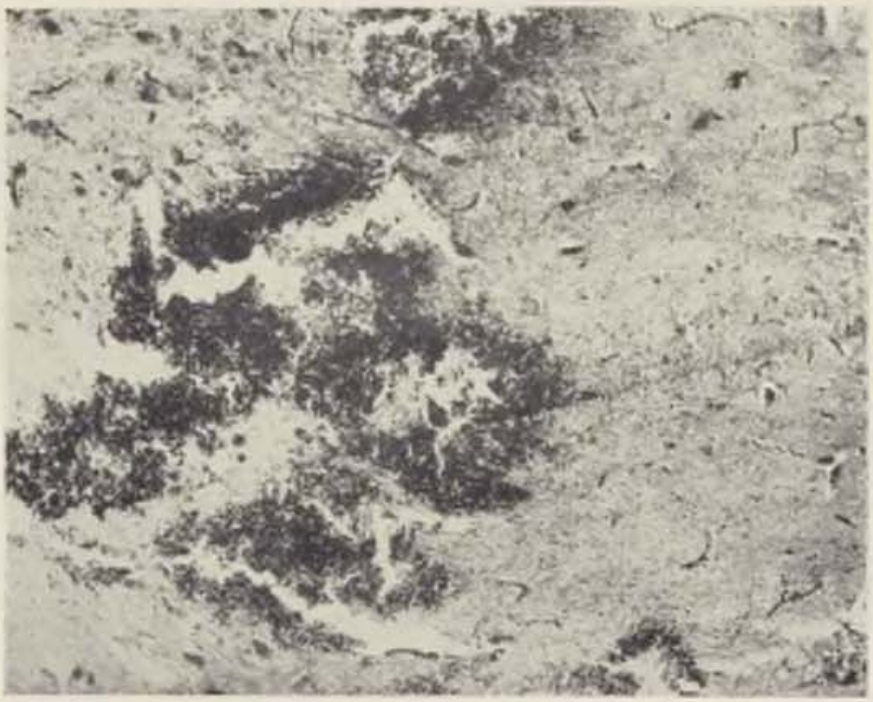

Fig. 1. Foci of recent haemorrhages laterally to nuclei mammillares partly also affecting the lateral part of nucleus mammillaris medialis (case V. B.)

Fig. 2. Thrombosis in minute vessels with a rim of erythrocytes immediately below the ependyma in the region of nucleus paraventricularis (case A. O.)

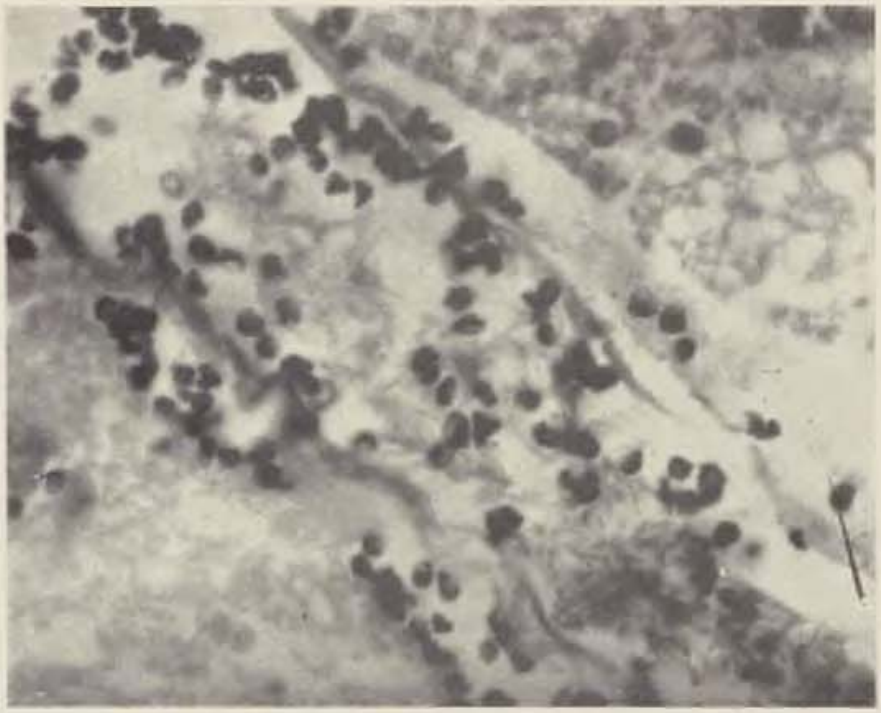

Fig. 3. Needle-like of fibrin forming tufts in large vessels in the region of nucleus paraventricularis (case A. O.)

A. V. Ayvazyan

EXPERIMENTAL AUTOTRANSPLANTATION OF PART OF KIDNEY (RE-WRITTEN PUBLICATION)

Fig. 1. — Border between taken kidney graft and host kidney. Proliferation of mature connective tissue enclosing atrophic glomeruli with distended capsules. Haematoxylin-eosin, ocular 3, objective 8.

Smolensk Medical Institute, Smolensk (U.S.S.R.)
Director: Prof. G. M. Starikov

EXPERIMENTAL AUTOTRANSPLANTATION OF PART OF KIDNEY*)
(re-written publication)

A. V. AYVAZYAN

We were unable to find any paper in the Soviet or foreign literature dealing with the autotransplantation of part of a kidney. Experimental elaboration of methods employed in the free transplantation of organs by joining the vessels by suture, began in the years 1900—1901, when it was first shown that it is possible to transplant organs with preservation of their function. The first experiments with the transplantation of kidneys were carried out by Ulman, Exler et de Castello and Carrel et Guthrie. Transplantation of organs is a problem of great theoretical and practical significance. For the last 50—60 years a tremendous number of papers have been dedicated to it, among them those of Russian authors, such as Bogomolets, Vishnevsky et al., Voronoy, Demikhov, Lapchinsky, Sokolov, Unik, Shpuga and many more. Conferences in various countries (USSR in 1957 and 1958, USA in 1954 and 1957, Czechoslovakia in 1957 and 1960) discussed the problem of homotransplantation. The numerous papers, published and read at conferences, bear witness that the problem of auto- and homotransplantation as well as that of the conservation of organs is being dealt with quite successfully both in the Soviet Union and abroad. Despite the fact that the problem of transplantation immunity, i.e. the immunological response of the organism to homo- and heterotransplantation of various tissues, is, at present being studied on a wide scale, the question of biological tissue compatibility which still remains open, seems to be the main obstacle for the solution of the problem of the transplantation of organs. Demikhov adheres, in this respect, to a special point of view. In his experiments with the transplantation of organs, he found that if normal metabolism was re-established in the transplanted organ by way of the renewal of blood circulation and if infection was absent, the transplanted organ showed normal function and took rapidly. At the basis of immunological incompatibility of tissues there are two firmly established facts: 1. the presence of antigens in the donor which are different from those of the recipient, 2. the capacity of reacting specifically to the antigens present in the tissues of the donor. This also causes elimination

*) Read at 14th Scientific Session of S.G.M.I., 1961.

of the transplant as immunologically alien to the organism. This incompatibility is manifested by the frequent incidence of the specific defence of the organism against foreign proteins.

Therefore, neither brilliant surgical technique nor modern methods of conservation and storage will give the required effect; the transplants will rapidly undergo necrosis and be replaced by the tissues of the host. We set ourselves the task of studying the possibility of a partial autotransplant (one pole) of a kidney taking and preserving its function.

METHOD

The experiment was carried out in 16 dogs. Under morphine-ether anaesthesia laparatomy was carried out and both kidneys brought out of the wound. After placing a rubber tourniquet round the hilum or under digital compression, the upper pole was resected on both sides (in 4 animals), and the resected pole of the right transferred to the defect in the left kidney, and vice versa. The transplant was fixed to its bed by interrupted catgut or continuous atraumatic sutures. In 12 animals nephrectomy was performed on one side. The pole of the other kidney was resected and replaced by the pole of the extirpated kidney. The resected pole weighed about ⅓ to ¼ of the total weight of one kidney. The time interval between nephrectomy and transplantation of the pole was 20 to 40 min.

RESULTS

In 12 of the 16 dogs the transplanted poles of kidneys underwent necrosis and later colliquation and incapsulation (time of observation 7 days to 24 months). After a longer period, partial resorption and organization of the necrotic masses was observed both macro- and microscopically.

In 4 cases the grafted poles took and both their structure and function were preserved. For illustration here is a short account of one experiment together with the final pathohistological findings: The dog "Zhuk", aged three, weight 14 kg. was operated on under general morphine-ether anaesthesia on Nov. 30, 1957. Through a laparatomy cross transplantation of the pole of one kidney to the other kidney and vice-versa was performed. Six months later, on May 19, 1958, a second laparatomy was carried out and it was found that both transplanted poles had taken well and looked like ordinary kidney tissue; after pinching they started bleeding. One kidney was then removed and investigated histologically (doc. G. M. Tsvetkova). It was shown that the tissue of the transplanted pole had, on the whole, preserved its structure, although some changes had taken place, which manifested themselves by the uneven filling of blood vessels of the glomeruli; some showed congestion, others were quite ischaemic and atrophic. In the capsules of some glomeruli there were deposits of proteinous masses and agglomerations of endothelium. The cells of the epithelium of the convoluted tubules showed unclear contours and in some the nuclei were absent. The lumina of the tubules were filled with proteinous masses. In the interstices there was hyperaemia, in some places with stasis and perivascular haemorrhages.

On the border between the graft and the host connective tissue had proliferated on a broad area which enclosed atrophic and deformed glomeruli with distended capsules filled with proteinous masses. Tubules could not be found at all in these parts (see microphotograph 1).

A similar picture was found in the other three dogs in which the transplanted poles of kidneys had taken.

On the basis of the above histological findings it may be concluded that the taken transplants of parts of kidneys have preserved their structure and are capable of normal life and function.

SUMMARY

On the basis of the above experiments and the histological findings it may be stated that transplantation of parts of kidneys can be carried out which may result in a full take of the graft with preservation of its function and may be used in operations immediately after resection of parts of kidneys for cystic changes as well as in cases with injury of the kidneys.

RÉSUMÉ

L'essaye de l'autotransplantation de la part du rein

A. V. Ajvazjan

Vis-à-vis des résultats obtenus par les expériments cités ci-dessus ainsi qu'aux données histologiques on peut dire que la transplantation des parties du rein est practicable et, au surplus, qu'elle peut être suivie de la fonction normale du transplant. Les expériences citées imposant son emploie dans la chirurgie des résections partielles du rein faute des cystes ou des lésions traumatiques.

ZUSAMMENFASSUNG

Die Autotransplantation eines Teils der Niere im Experiment

A. W. Ajwasjan

Auf Grund der angeführten Versuche und der nachträglichen histologischen Untersuchungen kann angenommen werden, dass die Übertragung eines Teils der Niere mit dauerndem Überleben des Transplantats und Erhalten seiner Funktion vollkommen im Bereich der Möglichkeit liegt und bei Nierenresektionen wegen kavernöser Prozesse oder wegen traumatischer Schädigungen zur Anwendung gelangen kann.

RESUMEN

Autotransplantación de una parte de los riñones

A. V. Ajvazjan

En la base de los experimentos citados arriba y de los hallazgos histológicos podemos decir que la transplantación de las partes de los riñones se puede realizar, lo que puede resultar en la toma completa del injerto de piel con preservación de su función y puede ser usado en operaciones inmediatamente después de la resección de las partes de los riñones para los cambios císticos así como en casos con injurias de los riñones.

REFERENCES

1. **Vishnevsky, A. A. et al.**: Khirurgia (Mosk.) 8, 5—12, 1952.
2. **Voronoy, U. U.**: Nov. khir. Arkh. V 22, 1—2, 200—203, 1931.
3. **Voronoy, U. U.**: Vrach. Delo 9, 814—815, 1950.
4. **Demikhov, V. P.**: Khirurgia (Mosk.) 9, 27—33, 1953.
5. **Demikhov, V. P.**: Transplantatinon of Vital Organs, 1960.
6. **Lapchinsky, A. G.**: Khirurgia (Mosk.) 4, 54—59, 1955.
7. **Unik, V. I.**: Bulletin of Experimental Biology and Medicine 8, V 40, 22—26, 1955.
8. **Shpuga, G. M.**: Exper. Surg. 1, 19—27, 1956.
9. **Carrel, A., Guthrie, C. C.**: Science 22, 473, 1905.
10. **Exler, A., de Castello**: Wien. klin. Wschr. 11, 1902.
11. **Ulman**: Wien. klin. Wschr. 11, 1902.

(Doc. A. V. Ayvazyan): Tscheremushkinskaya, 63/10, flat 55, Moscow, U.S.S.R.

Sverdlovsk Scientific Research Institute for Traumatology and Orthopaedics,
Sverdlovsk (U.S.S.R.)
Director: Z. P. Lubegina, Cand. Med. Sc.

RECONSTRUCTION OF THE EYELID WITH ACUTELY FORMED PEDICLE FLAP GRAFT

M. V. ZAYKOVA

Only a few authors have dealt in the medical literature with the use of an acutely formed pedicle graft in the reconstruction of the eyelid (Preobrazhensky 1925, Frankenberg 1936, Khayutin 1954).

It is, however, well known that an acutely formed pedicle graft has been rather widely used in the reconstruction of various facial defects (Gillies 1920, Yurov 1950, Balon 1955, and others) and has, apparently, also been widely employed in the reconstruction of the eyelid, but we have not met with any paper dealing with this problem in general.

We carried out reconstruction of an eyelid with the aid of an acutely formed pedicle flap graft in 67 patients with defects and deformities of eyelids, mainly resulting from injury or burns. There was scar ectropion of an eyelid in 13 patients, scar ectropion and a missing eyebrow in 4, shortening and deformation of the eyelid in 6, displacement of the eyelids in 6, loss of the eyebrow in 5, partial defect of an eyelid in 6, total defect of an eyelid in 18, defect of eyelids and of part of the orbital wall in 9.

The pedicle flap was excised from the skin of the temples or the eyelids.

A pedicle flap graft, acutely formed from the skin of the temporal region, was used in 23 patients. The method consists in the following:

First the skin of the temporal region is shaved, then, prior to operation, the basic incisions are marked with 1% brilliant green. The pedicle graft is planned so that the postoperative scar will run along the hair line. At the same time the course of the branch of the superficial temporal artery, to be included into the skin flap, is determined by palpation.

Two incisions, slightly curved to the sides are made 3.5—4 cm. apart, measuring 10—12 cm., which means that the ratio between the width and the length of the flap amounts to about 1 : 3. At the bottom of the posterior incision an additional triangular skin flap is formed above and behind the auricle, with sides measuring 3 cm. each (Fig. 1A). The skin incision is made down to the fascia and the skin flap is separated by blunt dissection. The edges of the donor site defect are also widely mobilized. The triangular flap, formed above the auricle, is tilted and sutured into the defect which makes it possible to close

the lower half and, sometimes, even the upper half of the donor site wound by a simple suture. In some cases, particularly in young patients, the upper half of the wound cannot be closed by simple approximation of the wound edges. In these cases the defect is covered by a free skin graft. The pedicle is formed by approximating the skin edges at the base of the flap with a few stitches (Fig. 1B). The free end of the flap is then usable for the repair of defects in the eyebrow, eyelids and the orbit (Fig. 1C).

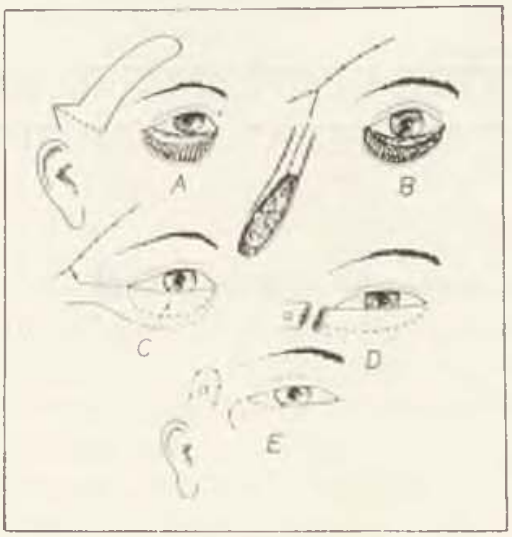

Fig. 1. Diagram of reconstruction of full-thickness defect of lower eyelid with acutely formed pedicle flap graft plus free mucosa graft.

Second-stage operation — resection of the pedicle or its replacement to the temporal region — is performed 2—4 weeks after the first stage (Fig. 1D, E).

We used this method for the repair of scar ectropion of one or both eyelids and at the same time, for the reconstruction of the eyebrow.

Reconstruction of the lid surface with an acutely formed pedicle flap graft consists of the following stages:

1. A broadly mobilizing incision is made through the skin along the margin of the eversed eyelid, the cutaneous and subcutaneous scars are excised and the lid margin is replaced to its normal position. Thus the extent of the defect in the eyelid is revealed. The free end of the pedicle flap acutely formed from the skin of the temporal region, is then sutured into the defect. If an eyebrow defect is present, it can be repaired at the same stage.

2. The second-stage operation is performed 3—4 weeks later: The pedicle of the flap graft is either excised or returned to the donor site in the temples. In some cases, in order to reduce the size of the reconstructed eyelid, an incision is made along the scar between the taken graft and the local tissue and the subcutaneous layer is excised together with the hair bulbs (except in the region of the reconstructed eyebrow).

Where both eyelids are eversed the skin incision in the first stage is made along the margin of both the upper and lower lid, and the wound edges are

mobilized. The lower wound edge in the upper lid is then sutured with catgut to the upper wound edge in the lower lid, leaving unsutured only the medial part of the palpebral fissure for drainage. Then the free end of the temporal pedicle flap graft is sutured to the defect in the lids and the brow. In the second stage the pedicle of the flap graft is returned to the temporal region. The eyelids, united by suture in the first stage are separated by an incision excising, at the same time, the surplus of subcutaneous fatty tissue from the taken graft and the hair bulbs in the area of the eyelid.

In a full-thickness eyelid defect with loss of the eyeball, we repair the skin defect with an acutely formed pedicle flap graft and the defect in the conjunctiva with a free mucosa transplant from the lip or the cheek, in one stage. The free end of the pedicle graft is sutured to the mobilized edges of the skin defect in the lower and upper lids. Then, from the inner lining of the cheek or the lip, a free graft of mucosa, the size of the conjunctival defect in the eyelids, is excised and sutured to the edges of the conjunctiva. The free margins of the eyelids are formed by suturing the free edges of the skin flap and those of the free mucosa graft to each other (Fig. 1 A, B, C). In the second stage the pedicle is either resected or replaced to the donor site in the temples (Fig. 1 D, E).

In a number of patients we saw, as a result of large burns, complete destruction of eyelids and eyebrows together with a complete obliteration of the conjunctival sac. In these cases the reconstruction consisted of the following operations:

First stage-reconstruction of the eyelids and eyebrow with an acutely formed pedicle flap graft: An incision is made along the edge of the entire defect and the gross scars are excised. The resulting tissue defect is measured, a pedicle flap graft is formed from the temporal region of a size corresponding to that of the wound area and its free end sutured to the defect.

Two to three days after this operation and after appropriate preparation of the operation field, a penetrating incision is made for drainage through the free end of the flap graft. This incision corresponds in size and shape to the palpebral fissure.

Second stage-reconstruction of the inner lining of eyelids (carried out 4—5 weeks later): The pedicle of the flap grafts is severed and the wound in the temporal region closed by simple suture.

Where the bone margin of the orbit has been left uncovered by soft tissue and has undergone sequestration, all exposed bone must be removed with a chisel at the second-stage operation.

In order to reconstruct the inner lining of the eyelids, the pedicle is divided by a longitudinal incision into two flaps which are then unfolded but without excising the subcutaneous tissue. A circular incision from inside is made through the scar tissue following the orbital margin and the tissue is broadly mobilized. The cavity resulting from this mobilization is then lined with the two unfolded skin flaps of the pedicle, whose edges are sutured with catgut to the edges of the defect. The ends of both flaps meet at the medial corner of the palpebral

fissure and are there sutured to each other. Then an eye prosthesis is inserted into the newly formed conjunctival sac.

Third stage-reconstruction of the temporal and nasal commissures of the eyelids: An incision is made along the margins of both reconstructed eyelids and at the site where the pedicle flaps fold over. The surplus subcutaneous tissue in the reconstructed eyelids is excised together with the hair bulbs up to the region of the eyebrow. The edges of the skin and those of the inner lining

Fig. 2.

Fig. 3.

Fig. 2. Patient N. prior to operation: Complete loss of eyebrow and both eyelids on left side resulting from burns. — Fig. 3. First-stage operation: reconstruction of eyebrow and eyelids on left side with acutely formed pedicle flap graft.

of both eyelids are then sutured together with hair sutures thus forming the temporal and nasal commissures.

For illustration a short excerpt of case history No 35,189 is given below.

Patient S.M.N., born 1914, was first admitted to SNIITO*) on July 26, 1961, with a leftsided facial defect: The eyeball, both eyelids, the eyebrow and the conjunctival sac were missing and there was a defect in the left ala nasi.

On April 22, 1961, in an epileptic fit, he fell on the edge of a hot kitchen stove and sustained deep burns of the left orbital region with complete destruction of the eyeball.

On admission the left eyeball was missing. The eyebrow and both eyelids, the conjunctival sac and the surrounding tissue were completely destroyed. The orbital margin and the nasal bone were denuded of their periosteum, and the bone showed darkening on the entire exposed area. The orbit was filled

*) Sverdlovsk Scientific Research Institute for Traumatology and Orthopaedics.

with cicatrizing granulations. The tissue defect was surrounded by a mound of scar tissue. The total area of the defect measured about 60 cm^2. The right eye was intact and its vision 1.0 (Fig. 2).

On August 3, 1961, the first-stage operation, reconstruction of the eyelids with an acutely formed pedicle flap graft, was performed according to the method described above.

On August 12, 1961, under local infiltration anaesthesia, the free end of the

Fig. 4.

Fig. 5.

Fig. 4. Reconstruction of inner lining in both eyelids with pedicle of an acutely formed flap graft. — Fig. 5. Patient N. 10 months after operation.

flap graft was divided by an incision 2.5 cm. long and symmetrical to the palpebral fissure on the other side (Fig. 3).

On December 5, 1961, reconstruction of the inner lining of the eyelids was carried out (Fig. 4).

On December 21, 1961, the nasal and temporal eyelid commissures were reconstructed.

Thus the eyebrow, both eyelids and the conjunctival sac were reconstructed from a single, acutely formed pedicle flap graft. The colour of the taken graft does not differ from that of the surrounding facial skin, and the hair on the eyebrow is sufficiently dense. They eye prosthesis is maintained in the proper position. The scars and the taken free skin graft in the temporal region are masked by the hair of the scalp. Fig. 5 shows the condition 10 months after the first operation.

In the above case we thus succeeded, in a comparatively short time, in reconstructing the eyebrow, the conjunctival sac and both eyelids with a single, acutely formed pedicle flap graft from the temporal region.

We have also used an acutely formed pedicle flap graft from the temporal region for the reconstruction of the eyebrow destroyed as a result of burns.

In the first stage, an incision is made in the region of the missing eyebrow and the wound edges are mobilized. A flap graft is excised from the hairy

part of the temporal region whose free end is then sutured to the wound. In the second stage the pedicle is resected or returned to the temporal region. Thus we were able to reconstruct the eyebrow with a stable late result which we have followed up for three years.

For the repair of defects in the bony walls of the orbit we used homotransplants of bone or cartilage which we implanted at the same time, as we undertook reconstruction of the eyelids by an acutely formed pedicle flap graft. In the first stage we covered the defect in the orbital wall with a homotransplant of bone or cartilage and sutured the free end of the flap graft to the skin edges of the defect in the eyelids. In a number of cases, however, we were able to close a minor defect in the orbital wall without resorting to homotransplants of supporting tissues simply by using the sufficiently thick layer of subcutaneous tissue of the flap graft.

The pedicle graft acutely formed from the skin of the temporal region has, in our opinion, quite important advantages over any other pedicle graft. Firstly, the closed pedicle of the acutely formed flap provides a very good protection against infection. Secondly, the mobile pedicle of the flap makes it possible to avoid additional transverse scars between the temporal corner of the palpebral fissure and the hairy part of the temples, a feature which is very important from a cosmetic point of view. Thirdly, it provides for reconstruction of the eyebrow and, at the same time, for the coverage of the donor area by way of the transposition of a triangular flap formed above and behind the auricle. Fourthly, the inclusion of a thick arterial branch guarantees a good blood supply to the flap graft and thus a good take under the most unfavourable conditions of the cicatrized recipient bed. Fifthly, the acutely formed flap graft has no continuous sutures between the matrix and the pedicle.

In 44 patients we used a microflap graft acutely formed from the skin of one eyelid for the reconstruction of the other. In the literature we did not meet with information about the use of such a skin flap on a closed, round pedicle, i.e. of an acutely formed microflap graft.

We have used two types of acutely formed microflaps in eyelids: a) with one round pedicle, b) with two round pedicles.

The one-pedicle flap graft is formed in the following way: Two incisions, 2—4.5 cm. long, are made on the upper or lower lid 1—1.5 cm. apart but on one side both incisions meet. This makes a pedicle graft. The pedicle of the flap is placed either temporally or nasally, depending on the situation of the defect. In order to avoid tension at the base of the pedicle a triangular flap, whose sides measure 1 cm. each, is made at one end of the upper incision in the upper or the lower incision in the lower lid, so that the perpendicular from the apex of the triangle to its base meets the corresponding end of the second incision (Fig. 6/I). The flap graft is mobilized within the layer of the orbicular muscle thus including muscle fibres in the graft. Transposition of the triangular flap to the base of the graft avoids shortening of the inner half of the eyelid.

According to Yurov (1950) the ratio between the length and width of any acutely formed pedicle flap graft ought to be 1 : 2 or 1 : 5.5. Taking into account the peculiarities of the blood supply to the face, we adhere to a ratio of 1 : 3 when forming a microflap from an eyelid.

If the skin of the eyelid, particularly of the upper lid, is folded into fine creases instead of forming a triangular skin flap, we extend the end of both incisions by further incisions, 0.5 cm. each, running at an angle of 45° from

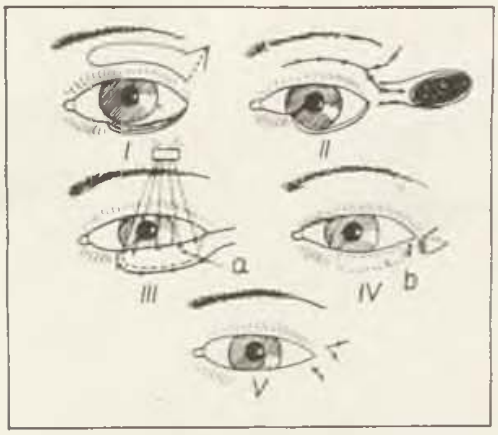

Fig. 6. Subtotal reconstruction of lower eyelid by combined method (microflap graft from upper lid plus free mucosa graft from cheek).

the base. After mobilizing the edges of these two incisions, the donor wound is closed by a simple interrupted hair or silk suture.

In both instances, the pedicle of the microflap is formed by approximating the wound edges at the base of the flap graft with three to four stitches inserted no more than 1 mm. from either wound edge (Fig. 6/II). We have used the free end of this flap graft for various reconstructive operations in the region of the eyelids and the conjunctival sac.

The method of forming a two-pedicle microflap graft consists in the following: Two parallel incisions, 4—4.5 cm. long and 1—1.5 cm. apart, are made through the skin of one eyelid (more often the upper) and two additional triangular flaps with sides 12 mm. long are formed on either end of the upper or lower incision, on the upper or lower lid respectively. The perpendiculars from the apex of these triangles to their bases should also join the corresponding ends of the other incision. These triangular flaps are transposed and their sides sutured to the edges of the donor site defect at either end, thus decreasing the tension in the pedicles of the microflap. The sutures are layed in the following order: first the wound is closed where the triangular flaps have been formed, then these flaps are sutured to the donor site in the eyelid and after this the rest of the donor area is closed by a simple suture; last the edges of the bridge flap are approximated at either end by three to four stitches thus forming the pedicles (Fig. 10/I—II).

However, on employing the above method in elderly patients, we did not

make triangular flaps when forming an acute microflap, but extended each of the basic incisions by 0.5 cm., the extensions diverging at an angle of 45° from the basic incisions. The pedicles of the microflap are formed in a similar way as described above, i. e. by approximating the edges of the bridge flap at either end by 3—4 stitches.

The free end of the one-pedicle or the middle piece of the two-pedicle microflap graft is sutured to the skin defect in the other lid, i.e. is used for

Fig. 7. Patient M. prior to operation: Loss of lower eyelid on right side after burns.

blepharoplastic purposes. We used this method in 25 patients for the reconstruction of skin defects in eyelids.

In scar ectropion or shortening of an eyelid, the first stage of the operation consists in the excision of the scars in the skin and the subcutaneous tissue and the reduction of the lid margin to its proper position. The free end of a microflap formed in the other lid is then sutured to the edges of the thus created skin defect. If the margin of the reconstructed lid has become too long, lateral blepharorrhaphy or partial, wedge-shaped resection of the lid is performed.

In order to prevent recurrence of the ectropion and to provide a stable position of the reconstructed skin cover in some patients, a small shaving of homogenous cartilage was implanted under the lower half of the flap into a pocket made from the lower incision. In cases where the medial half of the lid had been displaced downwards, we implanted the piece of cartilage perpendicular to the length of the wound. The one end of the implant came to lie against the lacrimal sac, supporting it and replacing it to its proper position.

We have performed reconstruction of an eyelid in 19 patients, six of whom had a partial and 13 a complete full-thickness defect of one lid.

Reconstruction of a full-thickness defect of an eyelid consists in the following:

First-stage blepharoplasty with an acutely formed microflap graft plus a free mucosa graft: A skin incision is made along the scar around the entire defect, the wound edges are mobilized and the scars excised. The remnants of the eyelid

are divided into two leaves to the depth of 2—3 mm. From the other lid a microflap is formed, its size corresponding to that of the defect, whose free end is sutured to the skin edges of the defect by hair stitches. From the inner lining of one lip a free mucosa graft is excised and sutured first to the edges of the conjunctiva defect and then to the free margin of the microflap. We used thin catgut as suture material (Fig. 6/I—III).

Second stage — resection of the pedicle — is performed 2—4 weeks later.

Fig. 8.

Fig. 9.

Fig. 8. First stage of reconstruction of lower eyelid with acutely formed microflap graft. — Fig. 9. Patient M. after operation.

In some cases the pedicle of the microflap is severed at its base, unfolded, and can be used for lengthening of the reconstructed lid. A shaving of homogenous cartilage is implanted between the skin and mucosa grafts for support (Fig. 6/IV—V).

For illustration a short excerpt of a case history is given below:

Patient V. M. M., case paper No 31,443, a woman, born in 1939, was admitted to SNIITO on July 29, 1959, with a complete full-thickness defect of the lower eyelid together with keratoleucoma of the eye on the right side and with large scars in the face.

On July 5, 1959, while working on the roof of a tram car, she sustained electric burns.

On admission, complete loss of the lower lid down to the conjunctival fornix was found. At the temporal and nasal commissures there were remnants of the lid margin measuring about 0.5 cm. each. The lower half of the cornea was densely blurred. The eye fundus was without visible changes. The vision of the right eye was reduced to 0.05 and was incorrectable. The left eye was intact with a vision of 0.4—0.5, D = 0,9 (Fig. 7).

Plan of treatment: 1. reconstruction of the lower lid with an acutely formed microflap plus a free mucosa graft, 2. correction of the eyelid using the pedicle of the microflap.

On Sept. 30, 1959, the first stage of the reconstruction of the lower eyelid was completed by a combined method. The incision was made around the edge of the defect in the lower lid and a thin strip of scar tissue excised. Then the wound edges were mobilized and the remnants of the lid at the lateral corner of the eye were divided into two leaves. Now a microflap with the pedicle pointing nasally was formed on the upper lid measuring 4,5×1.5 cm., and its free end sutured to the skin defect in the lower lid. From the inner lining of the lower lip a free

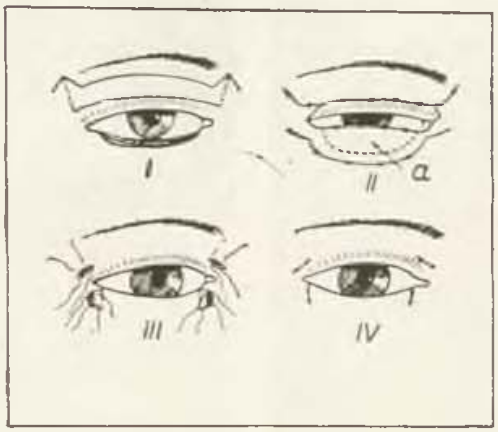

Fig. 10. Blepharoplasty of lower eyelid employing an acutely formed microflap graft with two pedicles plus a free mucosa graft from lip.

mucosa graft, 4.0×1.5 cm. in size, was excised and sutured to the edges of the conjunctival defect. The free edges of both grafts were then united with long hair sutures forming the margin of the reconstructed eyelid (Fig. 8).

On Nov. 12, 1959, the second-stage operation was performed: The pedicle of the microflap was separated from its base on the upper lid and the wound in the donor site closed by a simple suture. Then the pedicle was unfolded completely. An incision was made along the margin of the reconstructed part and extended for 3 mm. onto the intervertebral space of the laterally preserved part of the eyelid. From the tip of the taken microflap a strip of scar was excised. Part of the lateral section of the lid was mobilized and sutured to the tip of the flap; the sutures were inserted obliquelly, i.e. the entry at the flap margin was higher than the exit in the skin of the original part of the lid. The oblique suture made it possible to move the entire taken flap, including its pedicle, temporally and by it lengthen the eyelid by 4 to 6 mm. Then the surplus of the pedicle was excised and the lid margin sutured with hair stitches.

As a result of this operation, the eyelid has been completely reconstructed, maintains a natural position and the eye can be closed. The colour of the taken microflap does not differ from that of the surrounding skin. The inferior fornix of the conjunctiva is deep, the scars on the upper lid are indiscernible. Fig. 9 shows the patient three years after operation.

The deep cicatrizing process following gunshot wounds and burns is an adverse condition for the take of a microflap. In these cases we, therefore, use a two-pedicle microflap which is formed in the other eyelid and whose free part

is sutured to the edges of the defect. The defect in the inner lining of the eyelid is repaired with an autogenous mucosa graft taken from the lip or the cheek and sutured to the edges of the defect in the conjunctiva (Fig. 10/I—II).

In the second stage, resection of both pedicles of the microflap is carried out (Fig. 10/III—IV).

We assume that the basic advantage of the employment of an acutely formed microflap graft in the reconstruction of an eyelid lies in its round and closed pedicle which is well protected against infection. Formation of the microflap from the skin of the other eyelid avoids continuity of sutures between the pedicle and its matrix. This actually leads to per-primam healing of the wound in the donor site. Due to the presence of the pedicle we can bring the free part of the microflap to a defect in any part of the eyelid without any difficulty. When using a microflap acutely formed from the skin of one eyelid for the reconstruction of the other, we did not make any additional incisions at the corners of the palpebral fissure which, as is known, is an integral part of a plasty using any other pedicle skin flap graft. The mobile pedicle of the microflap makes it possible to bring the flap across the corner of the palpebral fissure forming a bridge. As has been shown by observation, the microflap graft acutely formed in one and taken to the other eyelid does not differ in colour or structure from the surrounding skin. On later check-up it was found that the skin of the taken microflap remained thin and could easily be folded into creases.

The late results of blepharoplasty were, up to 3 years after operation, checked up in 61 patients. In all operated on subjects where an acutely formed flap graft with a temporal pedicle had been used, the repair of the defect in the eyelid and eyebrow was stable and the transplant did not show any tendency for resorption. Employment of a microflap graft acutely formed from the skin of one eyelid showed good results in 36 patients; only two were considered failures, because the reconstructed eyelid had been displaced towards the defect in the orbit. This experience led us to the conclusion that any larger defect in the orbital walls contraindicates employment of a microflap graft acutely formed from the skin of an eyelid.

On the basis of the experience reported above we came to the conclusion that an acutely formed pedicle flap graft has a wide range of application in the repair of various defects in the eyelids and eyebrows.

SUMMARY

1. Employment of a flap graft acutely formed from the skin of the temporal region is indicated in the following large defects of eyelids and orbit: a) complete ectropion of both lids and loss of the brow; b) total loss of upper lid and brow; c) total loss of lower lid; d) total loss of both lids and brow; e) total loss of both lids; f) loss of eyebrow with the pulse of the superficial temporal artery absent; g) total loss of lid and defect in one wall of the orbit.

Employment of an acutely formed flap graft is contraindicated in: a) deep, cutaneous and subcutaneous, scar formations in the temporal region; b) large defects involving the eyelids and the medial wall of the orbit.

2. Inclusion of a thick arterial branch to the acutely formed flap graft improves the latter's viability. The triangular skin flap formed at the start of the lateral incision just above the auricle not only facilitates transposition of the flap forward, but also provides partial cover to the defect in the donor area.

3. Two types of a microflap acutely formed from the skin of an eyelid are employed: a) the acutely formed microflap with one round pedicle; b) the acutely formed microflap with two round pedicles.

4. Employment of a microflap acutely formed from the skin of an eyelid is indicated in the following isolated palpebral deformities: a) scar ectropion of one lid; b) shortening of one lid by a scar; c) slight displacement of the medial half of one lid; d) partial defect in the lower or the upper lid; e) total loss of one lid with surroundings intact.

Employment of an acutely formed microflap is contraindicated in: a) scar formations of the other (donor) lid; b) a defect in the bony wall of the orbit; c) large defects with loss of one lid and destruction in the adjacent parts of the face.

RÉSUMÉ

La blépharoplastie à l'aide d'un lambeau pédiculé aigu

M. W. Sajkova

1. L'indication pour l'emploi d'un lambeau pédiculé aigu, prélevé sur la peau de la région temporale, est donnée au cas des défectuosités importantes des paupières et des orbites que voici: a) Eversion cicatricielle complète des deux paupières et défectuosités du sourcil; b) défectuosité complète de la paupière supérieure et du sourcil; c) défectuosité complète de la paupière inférieure; d) défectuosité complète des deux paupières et du sourcil; e) défectuosité complète des deux paupières; f) défectuosité du sourcil et absence des pulsations de l'artère temporale superficielle; g) défectuosité complète d'une des paupières et d'une des parois orbitaires.

L'application de cette méthode est contre-indiquée en présence des données suivantes: a) Cicatrices profondes de la peau et du tissu sous-cutané dans la région temporale; b) défectuosités larges combinées des paupières, accompagnées d'une destruction de la paroi orbitaire inférieure.

2. L'inclusion d'un gros tronc artériel dans le lambeau pédiculé aigu augmente la vitalité de celui-ci. Un lambeau cutané triangulaire, prélevé du bord latéral de l'incision cutanée, au-dessus du pavillon de l'oreille, permet non seulement de déplacer en avant le lambeau pédiculé aigu, mais aussi de remplacer partiellement la lésion cutanée, pratiquée dans la région temporale.

3. Il y a deux modifications de l'emploi d'un lambeau pédiculé aigu micro, prélevé sur la peau de la paupière: a) sous forme d'un micro-lambeau pédiculé aigu à pédicule arrondi, b) sous forme d'un micro-lambeau pédiculé aigu présentant deux pédicules.

4. L'emploi du micro-lambeau pédiculé aigu, prélevé sur la peau de la paupière, est indiqué en présence des défectuosités isolées de la paupière que voici: a) Eversion cicatricielle d'une paupière; b) Raccourcissement cicatriciel d'une paupière; c) Déplacement peu important des parties nasales des paupières; d) Défectuosité partielle de la paupière supérieure ou inférieure; e) Défectuosité isolée complète d'une des paupières.

L'emploi du micro-lambeau cutané pédiculé aigu est contre-indiqué si l'on constate les lésions suivantes: a) Cicatrices sur l'autre paupière; b) Lésion de la paroi orbitaire osseuse; c) Défectuosités importantes de la paupière, accompagnées de destructions des régions faciales avoisinantes.

ZUSAMMENFASSUNG

Die Blepharoplastik mittels des akuten gestielten Lappens

M. W. Sajkowa

1. Die Indikation zur Verwendung des akuten gestielten Lappens, der der Haut der Schläfengegend entnommen wird, bilden folgende ausgedehnte Defekte der Augenlider und Orbita: a) Vollständige narbige Eversion beider Lider und Defekt der Augenbraue; b) Vollständiger Defekt des oberen Lids und der Augenbraue; c) Vollständiger Defekt des unteren Lids; d) Vollständiger Defekt beider Lider und der Augenbraue; e) Vollständiger Defekt beider Lider; f) Defekt der Augenbraue bei fehlenden Pulsationen der Arteria temporalis superficialis; g) Vollständiger Defekt eines Lids und einer der Orbitawände.

Eine Kontraindikation gegen die Anwendung dieser Methode bilden folgende Befunde: a) Tiefe Narben der Haut und des Unterhautgewebes in der Schläfengegend. b) Ausgedehnte kombinierte Defekte der Lider in Verbindung mit Zerstörung der inneren Orbitawand.

2. Die Einbeziehung eines grossen Arterienstamms in den akuten gestielten Lappen erhöht dessen Lebensfähigkeit. Ein dreieckiger Hautlappen, der am lateralen Rand des Hautschnittes oberhalb der Ohrmuschel entnommen wird, gestattet es nicht nur, den akuten gestielten Hautlappen nach vorn zu verlagern, sondern ersetzt teilweise auch den in der Schläfengegend gesetzten Hautdefekt.

3. Ein akuter gestielter Mikrolappen aus der Lidhaut gelangt in zwei Modifikationen zur Anwendung: a) als akuter gestielter Mikrolappen mit einem runden Stiel; b) als akuter gestielter Mikrolappen mit zwei runden Stielen.

4. Die Indikation für die Verwendung des akuten gestielten Mikrohautlappens aus der Lidhaut bilden folgende isolierte Liddefekte: a) Narbige Eversion eines Lids; b) Narbige Verkürzung eines Lids; c) Unbedeutende Verlagerung der nasalen Lidhälften; d) Teilweiser Defekt des oberen oder unteren Lids; e) Vollständiger isolierter Defekt eines Lids.

Eine Gegenanzeige gegen die Anwendung des akuten gestielten Mikrohautlappens bilden folgende Befunde: a) Narben des anderen Lids; b) Defekt der knöchernen Orbitawand; c) Ausgedehnte Liddefekte mit Zerstörung der benachbarten Gesichtsabschnitte.

RESUMEN

La reconstrucción del párpado por medio del injerto de piel formado como un pedículo agudo

M. V. Zaykova

1. El uso del injerto formado agudamente de la piel de la región temporal forma y resulta en los siguientes defectos grandes de los párpados y de la órbita: a) ectropion completo de ambos párpados y la pérdida de las cejas; b) pérdida total del párpado superior y de la ceja; c) pérdida total del párpado inferior; d) pérdida total de ambos párpados y cejas; e) pérdida total de ambos párpados; f) pérdida de la ceja con el pulso ausente le la arteria temporal superficial; g) pérdida total del párpado y el defecto en una pared de la órbita.

El uso de un injerto de piel formado de manera aguda está contraindicado en: a) las formaciones de cicatrices profundas, cutáneas y subcutáneas en la región temporal; b) grandes defectos envolviendo los párpados y la pared medical de la órbita.

2. La inclusión de una rama arterial fuerte al injerto de piel formado agudamente mejora su viabilidad. El injerto de piel de forma triangular formado al margen de la

incisión lateral precisamente arriba de la aurícula no solamente facilita transposición del injerto en la dirección delantera sino también proporciona una cubierta parcial al defecto en la región temporal.

3. Se usan dos tipos de micro-injertos formados en forma aguda de la piel de un párpado: a) el micro-injerto de forma aguda con un pedículo redondo; b) el micro-injerto de forma aguda con dos pedículos redondos.

4. El uso de un micro-injerto de forma aguda formado de la piel de un párpado resulta en las siguientes deformidades palpebrales aisladas: a) ectropion de cicatriz de un párpado; b) acortamiento de un párpado por una cicatriz; c) un deslojamiento de poca importancia de la mitad media de un párpado; d) un defecto parcial del párpado inferior o superior; e) pérdida total de un párpado mientras que los alrededores se quedan intactos.

El uso de un micro-injerto de forma aguda está contraindicado en: a) las formaciones de cicatrices del otro párpado; b) un defecto dentro de la pared ósea de la órbita; c) grandes defectos con pérdida de un párpado y la destrucción en las partes adyacentes de la cara.

REFERENCES

1. **Balon, R. L.:** Vestn. Khir. im. Grekova 5, 85—91, 1955.
2. **Preobrazhensky, V. N.:** Vrach. Gazeta 21, 513—514, 1925.
3. **Frankenberg, B. E.:** Reconstructive Surgery of the Face, 1936.
4. **Khayutin, S. M.:** Vestn. Oftalm. 2, 19—20, 1954.
5. **Yurov, V. S.:** Khirurgia (Mosk.) 3, 35—40, Moscow 1950.
6. **Gillies, H. D.:** Plastic Surgery of the Face, London 1920.

(M. V. Zaykova): flat 3, ul. Belinskogo 88, Sverdlovsk 26, USSR

Universitätsklinik für Gesichts- und Halschirurgie der Medizinischen Fakultät (Charité)
Berlin (DDR)
Direktor: Prof. Dr. med. habil. Dr. H. Mennig

VERSCHIEBEPLASTIK MIT MEDIANEM STIRNLAPPEN*)

E. KITTEL

Für Hautplastiken im oberen Bereich der Nase ist der Stirnlappen das Mittel der Wahl; weil seine Verwendung alle Vorteile der Nahplastik garantiert; auch *Escoffier* bezeichnet ihn bei Nasenplastiken als die einfachste und zufriedenstellendste Methode und hält sie, wie viele andere Autoren, in der Mehrzahl der Fälle für angezeigt. Man erhält einen dicken vollwertigen Hautlappen, der in Konsistenz, Aufbau und Farbe der normalen Nasenhaut am ähnlichsten ist und sich funktionell und kosmetisch optimal in seine neue Umgebung einfügt. In weiten Grenzen der Lage und Form des Stirnlappens ist die Ernährung vom Stiel während der Einheilung gesichert, so daß Randnekrosen selten sind, vielmehr glatte Einheilung die Regel darstellt. Darauf müssen wir ja besonders bei den

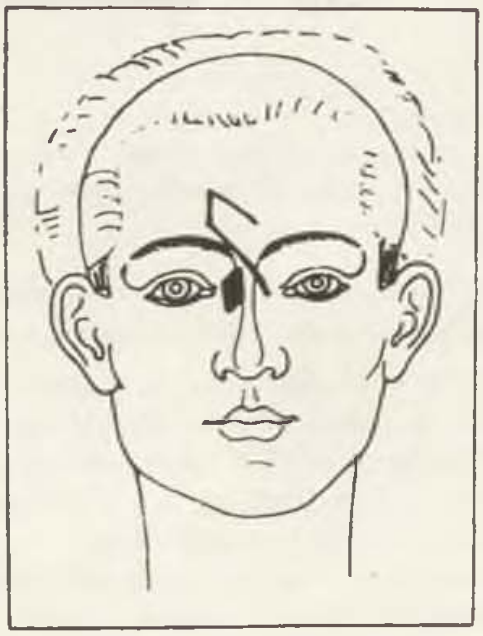

Abb. 1. Schematische Darstellung des Defektes an der seitlichen Nase nach Narbenexcision und der Schnittführung für die Schwenklappenbildung (Beispiel 1)

*) Herrn Prof. Dr. Dr. h. c. K. Velhagen zum 65. Geburtstag.

Fällen achten, wenn wir in ein minderwertiges Gewebsbett implantieren, wie es zum Beispiel beim Ersatz strahlengeschädigter Haut nicht zu vermeiden ist. Die Nahplastik mit dem Stirnlappen schafft auch günstige Voraussetzungen für später notwendige Unterpflanzungen zur Behebung eines Sattels am Nasenrücken, die immer eine kräftige Hautdecke erfordern; solche zusätzlichen Kor-

Abb. 2.

Abb. 3.

Abb. 2, 3. (Foto frontal und seitlich): Atrophische Narbe in der oberen Nasenhälfte beiderseits und starke Einsenkung des Nasenrückens (Beispiel 2). Auf dem frontalen Bild ist die Schnittführung angezeichnet.

rekturen sind aber wieder besonders nach den Strahlenschädigungen im Kindesalter infolge Entwicklungsstörung des Stützgerüstes der Nase unerlässlich.

Der Stirnlappen wird üblicher Weise in Form eines Drehlappens verarbeitet. Trotz weitgehender Möglichkeiten sind dem Drehlappen doch gewisse Grenzen gesetzt: die Größe des Lappens ist mit Rücksicht auf die unvermeidlichen Narben im Entnahmegebiet begrenzt. Eine Drehung des Lappens bis zu 90° dürfte noch die besten Aussichten auf gute Einheilung bieten. Hingegen können sich bei weiterer Drehung Schwierigkeiten sowohl hinsichtlich der Ernährung als auch der Narbenbildung im Entnahmegebiet ergeben. Aus diesen Gründen ist der Stirnschwenklappen vor allem für den Ersatz eines *seitlich an der Nase gelegenen Defektes* am günstigsten, wie das erste Beispiel zeigt.

Beispiel 1: Bei dem 17jährigen Mädchen war nach intermittierender Radium- und Röntgenbestrahlung eines Haemangioms an der Nasenwurzel rechts im Alter

von 4 Wochen bis 2½ Jahren eine schwere Strahlenschädigung der Haut mit Hypoplasie des Nasengerüstes entstanden.

Unter den verschiedenen Möglichkeiten des Hautersatzes wählten wir aus den bereits genannten Gründen die Schwenklappenplastik von der Stirn (Abb. 1), nicht zuletzt auch wegen des später notwendigen Sattelausgleiches. Das Ergebnis

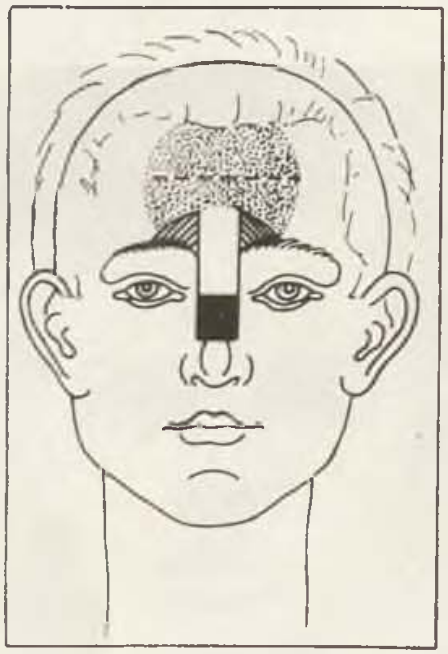

Abb. 4. Schematische Darstellung des Defektes in der oberen Nasenhälfte beiderseits und der Schnittführung zur Bildung des medianen Verschiebelappens (Beispiel 2). Erläuterung: Narbenexcision schwarz, excidierte Dreiecke schraffiert, Ausdehnung der Mobilisation punktiert, Linie der Periostincision gestrichelt (s. Text!)

der Plastik war bei glatter Einheilung sehr gut. Die inzwischen durchgeführte Korrektur der Sattelnase verlief dank des vollwertigen Gewebelagers ohne die geringste Störung.

Wollte man nun den gleichen Schwenklappen aus der Stirn für den *Hautersatz auf beiden Seiten des Nasenrückens* anwenden, müßte man ihn horizontal über der Augenbraue entnehmen, um eine zu starke Drehung am Lappenstiel zu vermeiden. Bei dem Primärverschluß des Entnahmedefektes kommt man dann unweigerlich in Schwierigkeiten, abgesehen von den Gefahren für die Ernährung des Lappens und für die Einheilung infolge der starken Stauchung des Gewebes am inneren Drehpunkt der Schwenkung; auch sind nachträgliche Korrekturen meist unvermeidlich. Vor einer solchen Situation standen wir in unserem zweiten Beispiel.

Beispiel 2: Bei dem 17jährigen Mädchen war im Säuglingsalter ein Blutschwamm am Nasenrücken mit Alkoholinjektionen behandelt worden. Im Laufe der Entwicklung kam es zu dem Befund, wie er in Abbildung 2 wiedergegeben ist. Die etwa groschengroße Narbe über der ganzen Breite der oberen Hälfte des Nasenrückens ist atrophisch und auf der Unterlage adhaerent. Im Narben-

gebiet sind noch einige Haemangiomreste zu sehen. Das Knochengerüst der Nase ist stark unterentwickelt, die untere Nasenhälfte nach oben verzogen. Dadurch entsteht eine tiefe Einziehung der Nasenrückenlinie mit extrem starker Sattelbildung (Abb. 3).

Die Anforderungen an die Plastik waren die gleichen wie im ersten Fall. Für den plastischen Ersatz kam also nur die Stirnhaut infrage. Wegen der

Abb. 5. (Foto frontal): Kosmetisches Ergebnis der Verschiebeplastik mit medianem Stirnlappen (Beispiel 2).

besonderen Lage des Defektes, der die ganze Breite des oberen Nasenrückens einnahm, kamen wir zu der Überlegung, daß ein aus der Stirnmitte gebildeter, gestielter Lappen, der mit der ganzen Stirnhaut gegen die Nase hin verschoben wird, bessere Einheilungsmöglichkeiten als ein Schwenklappen bieten würde. Die Vorteile eines solchen Lappens gegenüber dem Stirnschwenklappen bestehen erstens in der günstigeren Lage der Narben in den Augenbrauen und der seitlichen Nase und zweitens in einer breiten Ernährungsbasis, die keinerlei Drehung unterworfen ist.

Unser Vorgehen gestaltete sich folgendermaßen: Nach Entfernung der minderwertigen Haut und Mobilisation der Hautränder entsteht ein Hautdefekt über der ganzen Breite der Nasenwurzel. Durch Vernähung der beiden spitzenwärts gelegenen Ecken wird die Gesamtbreite des Defektes im unteren Teil etwas verringert. Die Umschneidung des Stirnlappens wird den Abmessungen des Defektes entsprechend (Abb. 4) vorgenommen, der Hautlappen mit Periost und die Weichteilbedeckung der ganzen Stirn bis zur Haargrenze abgelöst. Über dem Kopf beider Augenbrauen wird je ein dreieckiges Hautstück excidiert. Der Haut-

lappen kann aber erst dann in voller Ausdehnung über den Defekt gezogen werden, nachdem eine Periostincision in halber Höhe der Stirn gelegt wird. *Diese Periostincision ist außerordentlich wichtig, weil sie durch bessere Beweglichkeit die völlig spannungslose Lage des verschobenen Lappens gewährleistet.* Zur weiteren Entlastung werden im Bereiche der beiden dreiecksförmigen Hautexcisionen oberhalb der Augenbrauen weitgreifende Seidennähte über Kunststoffknöpfen gelegt.

Die Einheilung des Lappens erfolgte ohne Komplikationen, das kosmetische Ergebnis zeigt Abbildung 5. Die spätere Korrektur der Sattelnase durch Spanunterpflanzung verlief wie im ersten Falle dank des vollwertigen Hautersatzes ohne Zwischenfall.

Durch die Gegenüberstellung der bisherigen durchaus bewährten Form des Plastiklappens aus der Stirn für den Ersatz von Nasenhaut und einer neuen Modifikation des Stirnlappens als Verschiebeplastik mit medianem Stirnlappen dürften die Vorteile und Indikationen unseres Vorgehens deutlich geworden sein. Wir können diese Modifikation in entsprechenden Fällen sehr empfehlen. Da wir in dem uns vorliegenden Schrifttum keine Beschreibung eines solchen medianen Verschiebelappens fanden, halten wir uns zur Veröffentlichung des Falles berechtigt.

ZUSAMMENFASSUNG

Nach Abgrenzung der Verwendungsmöglichkeiten für den Stirnschwenklappen zum Ersatz von geschädigter Nasenhaut wird ein medianer Verschiebelappen zur Deckung von symmetrisch am Nasenrücken gelegenen Defekten beschrieben und seine Vorteile gegenüber dem Schwenklappen zur Deckung dieser Art von Defekten dargelegt.

SUMMARY

Medial Forehead Flap Plasty

E. Kittel

After determining the limits of the employment of a curved forehead flap for the replacement of damaged skin on the nose, the use of a medial flap for the repair of defects situated symmetrically on the dorsum nasi is described and its advantages in such cases over the curved flap are given.

RÉSUMÉ

La plastie à l'aide du lambeau frontal médial par glissement

E. Kittel

Tout en soulignant les avantages et les possibilités d'emploie du lambeau frontal médial par rotation, dans des cas de l'endommagement de la peau du nez, l'auteur nous impose sa méthode du lambeau frontal par glissement dans les cas des endommagements symétriques du radix nasal. Ses avantages envers le lambeau frontal médial par glissement dans des cas cités ci-dessu viennent d'être décrits.

RESUMEN

La plástica hecha por transferencia con el lóbulo frontero medio

E. Kittel

Después de fijar los límites en cuanto a la utilizatión del lóbulo descendido como substitución de la piel dañada de la nariz se describe en este papel el lóbulo frontero medio para cubrir los defectos localizados de manera simétrica sobre el dorso de la nariz. Con el motivo de cubrir los defectos de este tipo se acentúan sus ventajas a diferencia del lóbulo descendido.

SCHRIFTTUM

Escoffier, J. B.: Plast. reconstr. Surg. 21, 94, 1958.

(Dr. E. Kittel): Berlin N 4, Philippstraße 21, DDR

Clinic of Plastic Surgery, Purkyně University, Brno (Czechoslovakia)
Director: Prof. V. Karfík, M.D.
Obstetric and Gynaecology Clinic, Purkyně University, Brno
Director: Prof. L. Havlásek, M.D.

CAN METHODS OF PLASTIC SURGERY CONTRIBUTE TO OPERATIVE GYNAECOLOGY?

J. KRENAR, L. HAVLÁSEK

The aim of plastic surgery is to restore the appearance and function of parts of the body lost or damaged through disease, injury or operation, of congenitally deformed parts of the body or unsightly features which detract from the personal and social worth of the person concerned (as defined by Academician Burian, the founder of plastic surgery in Czechoslovakia). In other words, the purpose

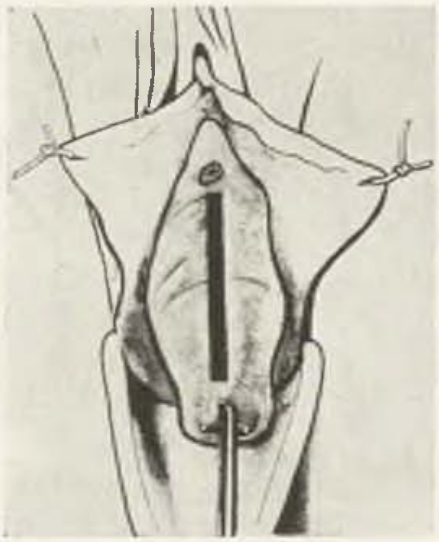

Fig. 1. Scheme of usual longitudinal incision in anterior vaginal wall in colporrhaphy.

of a reconstructive operation is to carry out plastic repair of injured or missing tissue so as to restore the function and appearance of the part of the body affected.

In gynaecology, as in all branches of surgery, situations are encountered in which, for various reasons, the form or position of the organs is disturbed or tissue has been lost, thus disturbing function and necessitating operation.

These include extensive, recurring vesicovaginal fistulae, often associated with a defect, e.g. complete loss of the urethra after previous operations, or states following radical mutilating vulvectomy and also congenital aplasia of the vagina.

Complex reconstructive techniques are needed to replace the missing parts, whether tissue is taken from the immediate vicinity or (less frequently) from more distant parts.

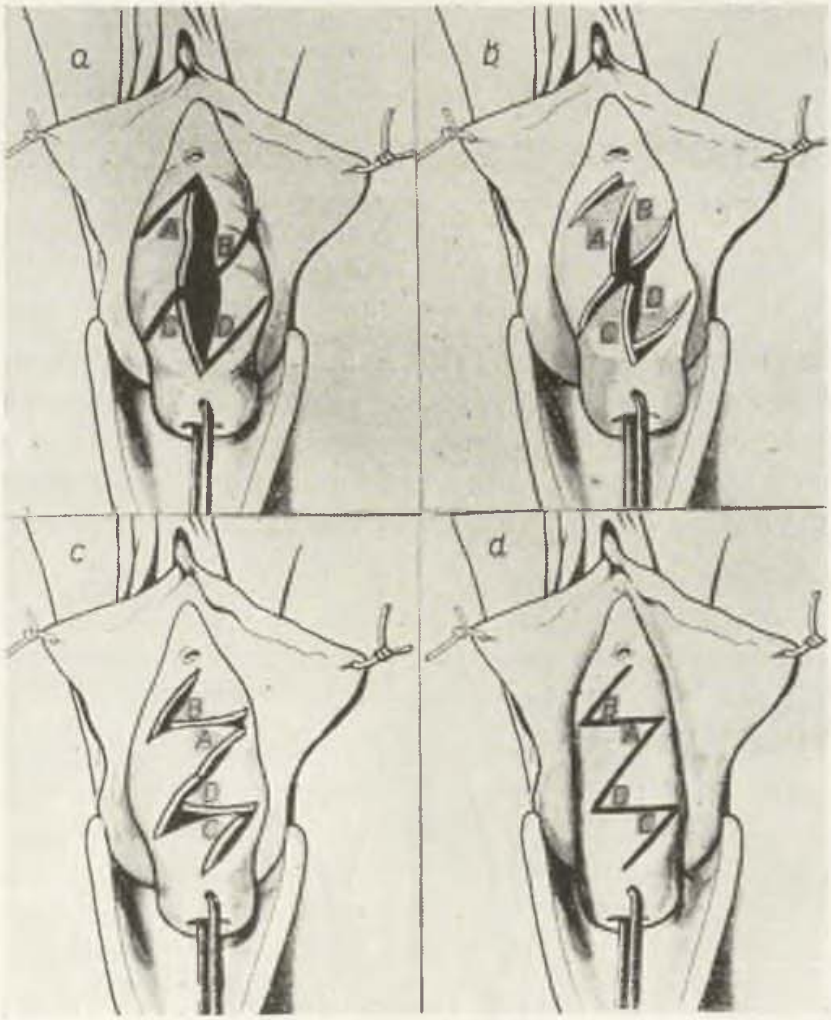

Fig. 2 a—d. Scheme of double transposition (Z-plasty) of triangular flaps in anterior vaginal wall. Fig. 2 b shows the extent of reduction of the individual wedges (dotted line) in the vaginal wall.

A number of operative techniques for repairing tissue defects in the urogenital region are to be found in the gynaecological literature. The most enterprising surgeons even succeeded in shifting flaps from some distance. This is evidence of their advanced surgical skill and constructive imagination. From the aspect of gynaecology this is undoubtedly new, pioneering work. Most of these operations, however, developed, out of fortuitous situations, without any knowledge of the modern principles of tissue transposition in plastic surgery.

They are therefore usually very complicated, unmethodical and isolated and cannot as a rule be copied by other operators. That is why they have not been generally recognized and propagated.

It is known from experience, however, that when correcting a tissue defect, it is not sufficient merely to draw together and suture the tissue remaining in the immediate vicinity. The missing tissue must be replaced by transposition

Fig. 3. Situation after radical mutilating vulvectomy for carcinoma of the vulva, before reconstruction (details in text).

of tissue from the adjoining or more distant parts, e.g. by free grafts. An insensitive surgical technique leads to complications in healing, due to disturbance of tissue nutrition, necrosis, extension of the defect and worsening of the prospects for satisfactory reconstruction.

1. Local shifts of tissue from the immediate vicinity or more distant parts,
2. free transplantation of tissue and
3. an atraumatic surgical technique

are thus the means by which to achieve the aims of reconstruction, not only in plastic surgery, but in all branches of surgery, including operative gynaecology.

It was on this basis that close collaboration was established between the Obstetric and Gynaecology Clinic and the Clinic of Plastic Surgery in Brno, largely because the results of previous reconstructive operations in the female urogenital region had not always been altogether satisfactory. Discussion revealed a whole series of possibilities of using plastic surgery in gynaecology. Through the combined efforts of gynaecologist and plastic surgeon a number

of difficult problems were successfully resolved. Some of the basic elements of their collaboration are given below, together with a preliminary report on their first experiences.

SURGICAL TECHNIQUES

One of the main methods of shifting of tissue, which is the most widely used in plastic surgery and forms a transition to flap grafting, is the transposition of triangular flaps of skin or mucous membrane, known as Z-plasty. This classic

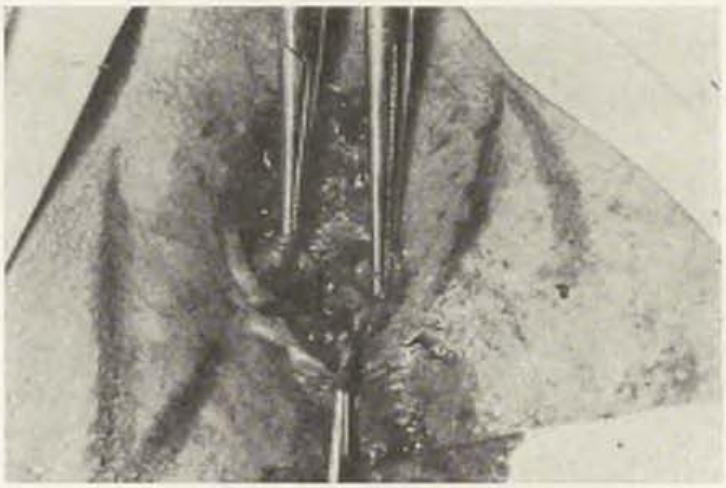

Fig. 4. During operation: the external orifice of the urethra has been drawn out proximally, anterior colporrhaphy has been completed, together with suture of the vesicovaginal septum and of both levatores ani. The skin incisions are shown.

method of plastic surgery was tried in anterior colporrhaphy, after first suturing the vesicovaginal septum. After typically drawing together and suturing the vesicovaginal septum in a longitudinal direction, incisions were made according to the scheme in Fig. 2, the triangular flaps of mucous membrane were transposed as in Z-plasty and after fitting them into one another the vagina was sutured. In this case there is usually an excess of mucous membrane and the triangular flaps in the anterior vaginal wall are partly reduced (Fig. 2b). Experiences showed that this improves postoperative healing because the sutures in the vesicovaginal septum and the anterior vaginal wall do not lie parallel to each other. It also prevents frequent puckering of the scar and postoperative shortening of the anterior wall of the vagina.

This technique is regarded as particularly valuable in cases in which simultaneous replacement of a large defect in the anterior vaginal wall is required.

This is usually the case with large vesicovaginal fistulae operated on several times without success, in which postoperative complications may even have led to loss of the urethra, which also needs to be replaced. Three such patients were operated on recently. In another patient a rotation flap from the

adjacent mucous membrane was successfully used to close a vesicovaginal fistula. These techniques and results have already been described (9).

In the present paper the authors describe a case after radical mutilating vulvectomy carried out for carcinoma of the vulva which developed from kraurosis. In this case an attempt was made to reconstruct the vulva by an intricate local shift of tissue. The local state before the operation is shown in Fig. 3.

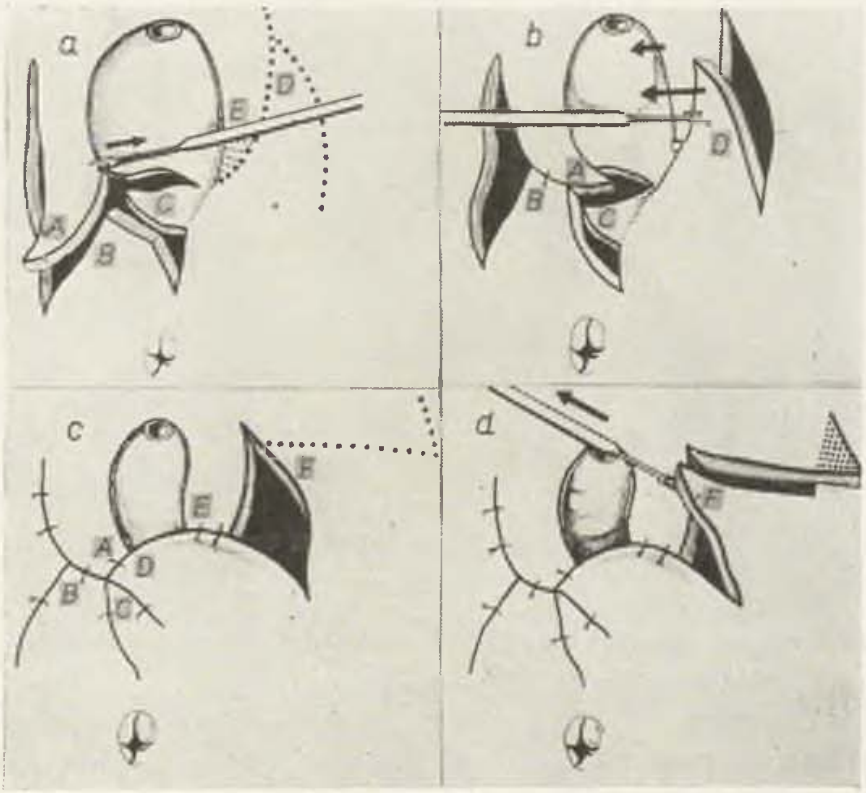

Fig. 5 a—d. Scheme of local shifts in reconstruction of gaping vulva (description in text).

The vulva gaped and measured 8 X 5 cm. At the transition from the skin to the vaginal mucous membrane was a resistant fibrous scar, which was painful on examination. The external orifice of the urethra was wide open and was situated low below the symphysis pubis, while the mucous membrane of the urethra was everted. The anterior vaginal wall formed a large cystocele and rectocele.

DESCRIPTION OF THE OPERATION

An incision was first made round the everted external orifice of the urethra, the anterior part of the urethra was partly mobilized and the external orifice was drawn forward in a proximal direction. The cystocele was then corrected by drawing the vesicovaginal septum together in the typical manner. The anterior vaginal wall was repaired by twofold transposition of triangular flaps of mucous membrane on the lines of Z-plasty, for the reasons given above.

After suture of both levatores ani, the actual reconstruction of the vulva was undertaken. The aims of the operation were

1. to remove the circular scar, which caused pain on coitus,
2. to make the introitus narrower,
3. to form folds of skin with subcutaneous fat at the sides, replacing the labia majora and enclosing the introitus,
4. to make the perineum sufficiently high.

Fig. 6. After completing the first operation.

The local shift of tissue by which it was hoped to achieve reconstruction of the vulva is illustrated in Fig. 5 a—d.

First of all, a triangular flap of skin, together with the subcutaneous fat, with a proximally situated base and its apex pointing in a paraanal direction, was freed in the right paralabial area to the right of the gaping vulva. This flap (marked A in the diagram) was shifted in a medial direction. Another triangular flap, based in the right half of the perineum, i.e. above the anal orifice (marked B), was transposed in place of flap A. A medial shift of flap A gave tissue replacing the right labium majus, while the exchange of flap B for flap A filled in the defect left by shifting the latter (Fig. 5 a).

The next task was to raise the perineum. Another, even larger triangular flap of skin and subcutaneous tissue was obtained in the left genitofemoral groove, with its base in the left paraanal region (marked D). Medial rotation of this flap by almost 90^0 made it possible to raise the perineum to more than twice its previous height (Fig. 5 b).

When freeing flap D from the left genitofemoral region, a smaller paralabial flap was formed to the left of the vulva (E). This was also shifted in a medial direction, like flap A from the right side, thus obtaining tissue to replace the left labium majus.

A large triangular defect was left in the left genitofemoral region, however, which was filled in by shifting another flap (F) from the left medial femoral region (Fig. 5 c, d).

The resultant reconstruction of the vulva after completing this operation is shown in Fig. 6.

After the operation dehiscence of the anterior part of the suture of the vaginal wall occurred and the external orifice of the urethra retracted back below the symphysis and became everted. A second operation was therefore carried out five months later, in which the anterior part of the urethra was again mobilized, its external orifice was drawn out in a proximal direction and

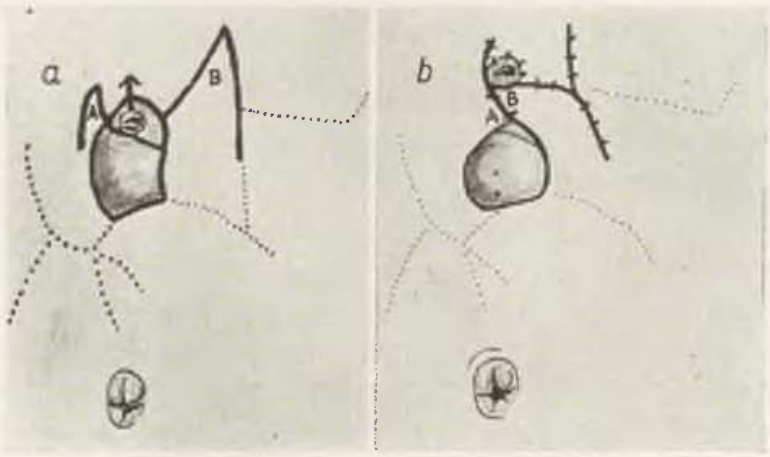

Fig. 7. a—b. Scheme of second operation.

was supported from below by skin flaps from the sides, from the anterior part of the previously formed labia (Fig. 7).

Fig. 8 shows the result three months after healing. The introitus of the vagina admits two fingers. It is bounded on both sides by folds of skin corresponding to the labia majora. The anterior colporrhaphy has healed well and the levatores ani have been sutured. The perineum is sufficiently high. The external orifice of the urethra is correctly situated, but it is still somewhat everted.

DISCUSSION

It has more than once been found that the discovery of a mutual relationship between two different branches of science has led to their further development and growth (Ashby, 1). As stated by Norbert Wiener in his book "Cybernetics" (13), "fields of contact" exist between contiguous branches of science. These fields of contact are often neglected, are thus not sufficiently investigated and therefore provide rich possibilities for research. This is because the specialized branches themselves are constantly growing and being elaborated by new findings, but the extent of these findings limits the possibilities of studying advances in contiguous branches. Despite the fact that these modern methods of work — and particularly research work — consisting in collaboration between experts in contiguous or similar branches is now quite customary in many fields of

medicine, no mention was found in the available literature of collaboration between the gynaecologist and plastic surgeon in resolving complicated gynaecological reconstructive operations.

Papers published by McIndoe on repair of congenital aplasia of the vagina by the transplantation of free skin grafts form the only exception. It should be emphasized, however, that in Czechoslovakia this operation was described

Fig. 8. Results of reconstruction of the vulva three months after second operation.

by Academician Burian, together with Prof. Ostrčil, as early as 1924 (8). This question is now being studied jointly by workers of the Clinics of Gynaecology and Plastic Surgery in Bratislava.

Although the number of operations performed on women with tissue defects in the urogenital region (i.e. with small or large tissue losses, usually after previous unsuccessful attempts at surgical reconstruction) is only small, the results of collaboration between gynaecologist and plastic surgeon can be regarded as so significant as to justify the use and systematic introduction of methods of plastic surgery into gynaecology. From its earliest beginnings, plastic surgery has elaborated detailed methods for individual reconstructive operations, has applied its experiences in general practice and has gradually transferred them to other branches of surgery. This elaboration of the methods of plastic surgery and their introduction into other branches of surgery is one of the conditions of progress in operative procedures and is a gain both to surgery and to the patients.

CONCLUSION

The question of reconstruction in operative gynaecology has not yet been satisfactorily resolved. The theoretical possibility of using methods of plastic surgery in reconstructive operations on the female urogenital region indicates one way of resolving the problem. The authors are of the opinion that their few, but encouraging results of cooperation between gynaecologist and plastic surgeon show the need for systematic research.

SUMMARY

In gynaecology, as in other branches of surgery, states are encountered in which, for various reasons, the form and position of organs has been disturbed, or tissue has been lost, thus disturbing function and necessitating surgical reconstruction. With tissue defects it is usually not sufficient simply to draw the parts together or to suture the residual tissue in the immediate vicinity. The missing tissue must be replaced by shifting tissue from the immediate or more distant vicinity or by free grafts. This, together with an atraumatic surgical technique, is the essence of plastic surgery.

Plastic surgery systematically elaborates methods for using these means in individual reconstructive operations, generalizes them and introduces them into other branches of surgery.

Since the results of reconstructive operations in the female urogenital region were not yet altogether satisfactory, close collaboration was established between gynaecologist and plastic surgeon. As a result of their combined efforts, some very difficult cases were treated successfully. Using plastic surgery techniques (in particular Z-plasty and local shifts of skin and mucous membrane from the immediate vicinity), the authors obtained good results in cases in which repeated operations for recurring vesicovaginal fistula had led to loss of the anterior vaginal wall, which had to be replaced. The external genitalia were likewise successfully repaired in a similar manner after radical mutilating vulvectomy.

Although this form of cooperation has so far been carried out on a small scale only, the good experiences which it has brought indicate the need for systematic research.

RÉSUMÉ

Est-ce que les méthodes de la chirurgie plastique peuvent être utiles à la gynécologie opérative?

J. Krenar, L. Havlásek

En gynécologie, de même que dans les autres disciplines chirurgiques, nous rencontrons des cas où, pour une raison ou pour une autre, il y a eu trouble de la forme ou de la position de l'organe, mais surtout des pertes tissulaires qui produisent des troubles fonctionels, situation qui doit être réparée par une intervention chirurgicale de reconstruction. Pour réparer la défectuosité tissulaire, il ne suffit pas, en général, de rapprocher ou de suturer simplement les bords des tissus restés à disposition dans le voisinage le plus proche. Il faut remplacer le tissu manquant à l'aide de déplacements à partir d'un endroit plus ou moins éloigné ou, le cas échéant, à l'aide d'une greffe libre.

Nous y disposons, à côté de la technique opératoire atraumatique, des moyens utilisés par la chirurgie plastique.

Les spécialistes en chirurgie plastique s'occupent de la mise à point très minutieuse de l'emploi de ces moyens, utilisés pour les différentes interventions reconstructrices, tout en le généralisant et en introduisant leurs expériences dans les autres disciplines chirurgicales.

Etant donné que les résultats actuels des interventions reconstructrices faites dans la région urogénitale de la femme ne sont pas encore tout à fait satisfaisants, des gynécologues et des spécialistes en chirurgie plastique se sont mis d'accord pour collaborer plus étroitement. Par leurs efforts réunis, ils ont pu obtenir des succès satisfaisants dans certains cas très difficiles, en utilisant des méthodes employées en chirurgie plastique, surtout celle dite „plastie Z", qui consiste dans le déplacement de lambeaux cutanés et de la muqueuse des endroits voisins. Les auteurs ont obtenu ainsi, à plusieurs reprises, de bons résultats dans des cas où, après des opérations répétées d'une fistule vésico-vaginale récidivante, il y avait eu perte de la paroi urétrale antérieure qu'il fallait remplacer; de façon analogue, ils ont restitué les organes génitaux extérieurs, après vulvectomie radicale mutilante.

Les résultats positifs obtenus à l'aide de cette collaboration, très modestes encore à l'heure actuelle, encouragent pourtant des recherches systématiques.

ZUSAMMENFASSUNG

Können Methoden der plastischen Chirurgie der operativen Gynäkologie nützlich sein?

J. Krenar, L. Havlásek

In der Gynäkologie, gleichfalls wie in den übrigen chirurgischen Disziplinen, begegnen wir Zuständen, wo es aus verschiedenen Gründen zu einer Störung der Form, Organlage, besonders jedoch zu einem Gewebsverlust und einer dadurch bedingten Funktionsstörung kommt. Es ist daher notwendig diesen Zustand durch einen rekonstruktiven chirurgischen Eingriff zu regeln. Eine einfache Annäherung oder chirurgische Naht eines in der nächsten Umgebung verbliebenen Gewebsrestes genügt gewöhnlich nicht den Gewebsdefekt zu regeln. Das fehlende Gewebe ist durch eine Verschiebung aus der nahen oder entfernteren Umgebung resp. mittels freier Transplantation zu ersetzen. Zusammen mit der atraumatischen Operationstechnik stehen uns Mittel zur Verfügung, die in der plastischen Chirurgie verwendet werden.

Die Methodik dieser Mittel wird bei den einzelnen Rekonstruktionsoperationen von der plastischen Chirurgie zielbewust durchgearbeitet, verallgemeinert und ihre Erfahrungen in die übrigen chirurgischen Disziplinen eingeführt.

Da die bisherigen Erfolge der rekonstruktiven Eingriffe im Bereich des weiblichen Urogenitales bis jetzt nicht völlig befriedigend sind, kam es zu einer engeren Zusammenarbeit des Gynäkologen mit dem plastischen Chirurgen. Dank ihren gemeinsamen Bemühungen gelang es einige sehr schwierige Zustände zu lösen. Durch Anwendung von Mitteln der plastischen Chirurgie, besonders der sog. Z-Plastik, Lokalverschiebung von Haut- und Schleimhautlappen aus der nächsten Umgebung, haben die Autoren in einigen Fällen Zustände erfolgreich gelost, wo es nach wiederholten Operationen infolge einer vesikovaginalen Fistel zu einem Verlust der Urether-Vorderwand kam, der einen Ersatz notwendig machte; in analoger Weise wurde mit Erfolg das äussere Genitale nach einer radikalen mutilisierenden Vulvektomie geregelt. Trotzdem die bisherigen guten Erfahrungen, die aus dieser Zusammenarbeit stammen, vorläufig bescheiden sind, regen sie zu einer systematischen Forschung an.

RESUMEN

Pueden los métodos de la cirugía plástica traer provecho a la ginecología operatoria?

J. Krenar, L. Havlásek

En ginecología, igualmente como en otros ramos de la cirugía, podemos observar ciertos estados causados por varios motivos durante los cuales apareció un perjuicio de las formas, de la posición de los órganos, especialmente cuando sucedió pérdida de los tejidos, lo que causó un defecto de las funciones las que fue necesario ajustar por una intervención quirúrgica reconstructora. Para ajustar el defecto de los tejidos no es suficiente de costumbre conseguir un acercamiento simple o coser los tejidos restantes por medio de una transferencia de las afueras cercanas y lejanas, eventualmente por una transferencia libre. Simultáneamente con la técnica operatoria atraumática tenemos a nuestra disposición los medios que usa la cirugía plástica.

La cirugía plástica está elaborando con firmeza y obstinación los problemas de los métodos de estos medios en las operaciones reconstructoras individuales, dándolos un sentido universal y introduce sus experiencias en otros ramos de la cirugía.

En vista del hecho que los resultados de las operaciones reconstructoras en la esfera de las uro-genitales femeninas no han llevado un gran éxito hasta ahora, se introduce una colaboración más estrecha entre el ginécologo y el cirujano plástico. Con ayuda de éstos fue posible dar una solución exitosa de algunos estados muy difíciles. Empleando los medios de la cirugía plástica, especialmente la llamada Z-plástica, por medio de la transferencia de los lóbulos cutáneos y mucosos tomados de la cercanía los autores tuvieron éxito en algunos casos en la solución de los estados, durante los cuales después de la operación repetida de la fístula vesicovaginal reincidente sucedió una pérdida de la pared frontal de la uretra, la que tenía que ser sustituída; de parecida manera los autores ajustaron con éxito los genitales exteriores después de una vulvectomia mutilante radical. Las buenas experiencias adquiridas de esta colaboración, aunque siendo muy pocas hasta ahora, estimulan una investigación sistemática.

REFERENCES

1. **Ashby, W. R.**: Cybernetics. Orbis, Prague 1961.
2. **Burian, F.**: Plastic Surgery. ČSAV, Prague 1959.
3. **Crossen, H. S., Crossen, J. R.**: Operative Gynecology. IV. ed. C. V. Mosby comp., St. Louis 1948.
4. **Mc Indoe, A.**: Brit. J. Plast. Surg. 2, 254, 1949; Surgery 1, 535, 1937.
5. **Havlásek, L.**: Operative Treatment of Vesicovaginal Fistulas. Thomayerova sbírka No. 297, Stát. zdrav. nakl., Prague 1951.
6. **Havlásek, L.**: Bratislav. lek. Listy XLI, V. 1, 2, 102, 1961.
7. **Karfík, V., et all.**: Plastic Surgery of the Injured Face. Stát. zdrav. nakl., Prague 1961.
8. **Karfík, V.**: Personal communication.
9. **Krenar, J., Havlásek, L.**: The Possibilities of Plastic Surgery in Operative Gynecology. Čs. Gynekol., in press.
10. **Marion, G., Pérard, J.**: Technique des opérations plastiques sur la vessie et sur l'urethre. Masson, Paris 1942.
11. **Martius, H.**: Die gynekologischen Operationen. S. Aufl., G. Thieme Verlag, Stuttgart 1960.
12. **Stoeckel, W.**: Gynekologische Urologie, II. Teil. Handbuch der Gynekologie, X. Bd., J. F. Bergmann Verlag, München 1938.
13. **Wiener, H.**: Cybernetics. Stát. techn. nakl., Prague 1960.

(Dr. J. Krenar): Trávníky 49, Brno, Czechoslovakia

Clinic of Plastic Surgery, Medical Faculty, Comenius University, Bratislava
(Czechoslovakia)
Director: Š. Demjén, M. D.

THE QUESTION OF THE AETIOLOGY OF TRIGGER THUMB

A. TÖRÖKOVÁ

Trigger thumb in infants is included among congenital deformities of the hand, although there is not always a history of this condition from birth. Until recently is was considered to be rare, since few papers had been published on the subject. In an article published in the Journal of Bone and Joint Surgery, Fahey and Bollinger (1954) state that they found only 93 cases of trigger thumb in the literature and only three cases of trigger finger in children including their own cases. They were probably not acquainted with Chiari's paper in the Zentralblatt für Chirurgie (1953), in which the author described his experiences with 100 children under the title "Treatment of Congenital Contracture of the Thumb by Subcutaneous Division of the Flexor Fibrous Sheath". Several publications have appeared in recent years and experiences have been described in more cases than in the past, probably as a result of improved diagnosis.

During the past five years, at the Clinic of Plastic Surgery in Bratislava, the author treated 16 children and five adults with trigger thumbs and one child with trigger fingers. Many of these patients were sent to the clinic with a wrong diagnosis.

The diagnosis, pathology and therapy will not be discussed here, since an article was published on this subject in the Bratislava Medical Journal in 1961. Briefly described, the condition consists in stenosis of the fibrous sheath of the tendon of the flexor pollicis longus or the flexor of the fingers in the region of the metacarbophalangeal joint and in clearly defined swelling along the course of the tendon of the flexor pollicis longus or of the flexor superficialis, proximally or distally to the stenosis of the fibrous sheath. In most patients the swelling occurred proximally to the narrowing of the fibrous sheath and the thumb was fixed in a flexed position. In one child and one woman it was fixed in an extended position and the tendon was swollen distally to the narrowing of the fibrous sheath.

Biopsy of material excised from six tendons showed proliferative and degenerative changes and material excised from the fibrous sheath also showed signs of chronic, nonspecific inflammation.

As far as the aetiology is concerned, some of the observations made since last year are in favour of the author's assumption that this is a developmental deformity, not only in children, but in some cases in adults also.

The following observations indicate that this condition is of congenital aetiology:

1. Its bilateral incidence in children. This was found in five of the author's series of 17 children, including one child with trigger finger of the third and

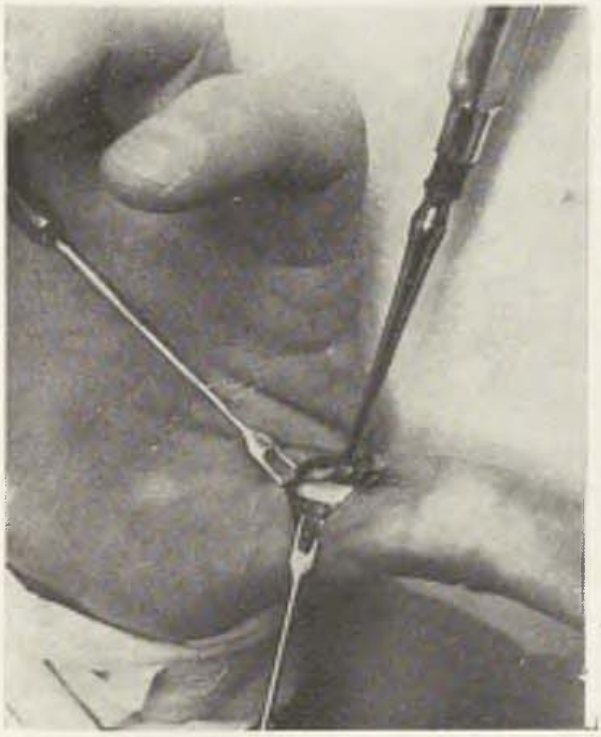

Fig. 1.

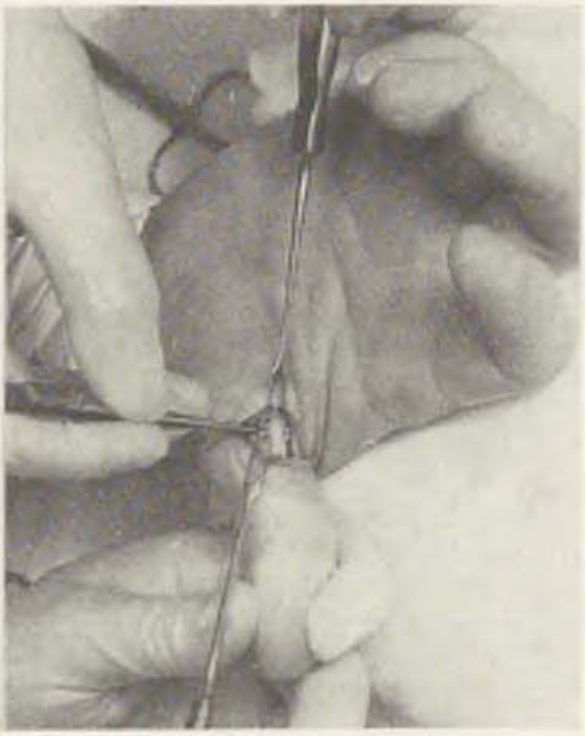

Fig. 2.

Fig. 1. Finding on operation of patient H. K., aged 48: Nodule in tendon prior to discission of tendon sheath. — Fig. 2. Finding on operation of patient H. K., aged 48: Nodule in tendon after discission of narrowed part of tendon sheath. Picture also shows retracted edges of tendon sheath after discission.

fourth fingers of both hands. The parents noticed the deformity when the child was a year and a half old, but did not go to the hospital until the child was five and one finger was fixed in a flexed position.

2. Familial incidence. One girl aged three years with right trigger thumb was accompanied by her father, who stated that he himself, at the age of 3—4 years, had also suffered from the same condition in his right thumb, but that it had straightened itself without operation. White and Jensen described a familial incidence in two of seven cases of trigger thumb in infants. Fahey and Bollinger found trigger thumb in infant twins and trigger finger in male twins aged 53.

3. The presence of another developmental deformity in the same patient or in his family (in nine of the author's 22 cases).

4. Bilateral incidence in adults. Four of the five adult patients were women, three of whom had bilateral trigger thumb. The following interesting finding was made after publication of the author's paper in 1961. In a patient (a dressmaker) in whom right-sided trigger thumb had been put down to chronic traumatization, the same process appeared four years later in the left thumb, although the patient no longer did any sewing. Another patient who had originally had trigger thumb of the left hand, developed trigger thumb of the right hand half a year later. Both were women aged 48—52 years. The third patient with bilateral trigger thumb was 31. Her history showed that the symptoms in her right thumb lasted for eight months and in her left for two.

SUMMARY

The author concludes from her experiences that trigger thumb is a developmental deformity, not only in children but in some cases also in adults and that it is to some extent influenced by heredity. A thorough investigation of family history would contribute to the better elucidation of this problem.

RÉSUMÉ

La question de l'étiologie du pouce à ressort

A. Töröková

A base de nos observations modestes, nous sommes d'avis que le pouce à ressort représente un vice de développement et ceci non seulement en ce qui concerne les enfants, mais dans quelques cas aussi chez les adultes et que certaines dispositions héréditaires influencent, dans une certaine mésure, le développement de cette défectuosité. En présence de cette maladie, une anamnèse tenant compte de sa fréquence familiale contribuerait donc à l'éclaircissement meilleur de cette question.

ZUSAMMENFASSUNG

Zum Problem der Aetiologie des schnellenden Daumens

A. Töröková

Auf Grund unserer bescheidenen Erfahrungen setzen wir voraus, dass der schnellende Daumen eine Entwicklungsstörung ist, nicht nur bei Kindern, sondern in manchen Fällen auch bei Erwachsenen, und dass auf die Etnwicklung dieser Missbildung auch Heredität einen gewissen Einfluss hat. Deshalb könnte bei dieser Krankheit eine eingehende Anamnese, die auf familiäres Auftreten dieser Störung achtet, die Problematik besser erhellen

RESUMEN

Algunas notas al problema de la etiología de un pulgar „saltante"

A. Töröková

A base de nuestras observaciones modestas suponemos que el pulgar „saltante" es un defecto de evolución que aparece no solamente en los niños sino también, en algunos casos, en los adultos y que el origen de este defecto tiene cierta influencia sobre la herencia. Por este motivo en esta enfermedad sería mejor hacer una anamnesia afectuada en vista de la existencia familiar podría contribuir a solver este problema.

REFERENCES

1. **Bunnell, S.**: Surgery of the Hand. J. B. Lippincott Co., Philadelphia, London, Montreal 1952.
2. **Fahey, J., Bollinger, J.**: J. Bone Jt. Surg. 36, 1200, 1954.
3. **Chiari, K.**: Zbl. Chir. 78, 101, 1953.
4. **Chytilová, M.**: Acta Chir. orthop. Traum. Čech. 18, 126, 1951.
5. **Iselin, M.**: Chirurgie de la main. Masson et Cie, ed. Librairie de l'Académie de médicine, Paris 1955.
6. **Kaplan, E. B.**: Functional and Surgical Anatomy of the Hand. J. B. Lippincott Co., Philadelphia, London, Montreal 1953.
7. **Proček, J.**: Prakt. Lék. 38, 28, 1958.
8. **Tischer, W.**: Z. ärztl. Fortbild. 52, 20, 1958.
9. **White, W., Jensen, W. E.**: Amer. J. Dis. Child. 85, 141, 1953.
10. **Wolin, I.**: Surg. clin. N. Amer. 2, 53, 1957.

(Dr. A. Toroková): Partizánska 1, Bratislava, Czechoslovakia

NEW BOOKS

János Zoltán: **A félvastag bör szabad átültetése** (Transplantation of Free Intermediate or Split-skin Grafts). Published by Medicína, Budapest 1960. 315 pp., 93 drawings. 195 black-and-white and 58 coloured photographs. Price 95 Ft.

The author is known in the professional literature for his many publications in the field of plastic surgery and as co-author of a two-part textbook on plastic surgery (Érczy and Zoltán: Plasztikai sebészet — Plastic Surgery. Published by Medicína, Budapest 1958).

His comprehensive monograph on free split-skin grafts is based on experiences in many operations performed by himself, together with a review of the relevant world literature. The intermediate split-skin graft (known in the Czechoslovak literature as a dermoepidermal graft) contains the epithelium and part (half) of the corium.

The contents of the book are divided into four parts.

Chapter I gives a historical review of skin grafts. The various methods of transplanting skin are described clearly and with illustrations in chronological order. They are divided into the group of small islets of skin (Reverdin, etc.), larger epidermal grafts (Thiersch etc.), full-thickness grafts (Blair etc.) and split-skin grafts.

In chapter II the physiology of the take of a free graft is discussed. The nutrition of the graft is explained from the time it is placed on the recipient area until it has completely taken. Emphasis is placed on the importance of a good blood supply of the base upon which the graft is applied. The take of split-skin grafts and other skin grafts is compared, with special reference to the advantages of the split-skin graft during and after taking. A free full-thickness skin graft is exacting during healing, but when it has taken it completely replaces the lost skin. Thiersch's thin epidermal graft has fewer requirements during healing, but it only imperfectly replaces the loss. The advantage of a split-skin graft is that it takes easily and completely replaces the lost skin. Another advantage is that spontaneous epithelization occurs at the donor site, while the defect left by a full-thickness graft has to be covered with another free skin graft.

Physiologically, and on the basis of the statistics in 600 cases the author demonstrates the advantages of split-skin grafts for covering suitable defects. In a separate section he discusses the functional and aesthetic results after free split-skin grafting. He also describes a method of preserving cut skin grafts.

In chapter III he describes the operative technique for skin grafting and gives a detailed analysis of the preparations for the operation, including preparation of the recipient site for the graft. Special attention is paid to the care of loss due to injury and operation. The preparation of an infected granulation surface is described in a separate section. The selection of the donor site, the technique of cutting of the graft, the way in which it is fixed in position and the postoperative treatment are also described in this chapter.

Chapter IV discusses the indications for the use of split-skin grafts. The author elaborates the wide range of possibilities of using this method and demonstrates them by illustrations and photographs.

In every chapter the author gives a comprehensive review of the methods employed by different authors, together with his own views and the methods which he himself uses.

Although detailed, the subject matter is presented very clearly. Special mention should be made of the tasteful arrangement of the book, of the drawings and of the excellent photographs.

In general it can be said that Zoltán's book is a comprehensive review of the possibilities of using split-skin grafts. The author has studied the abundant literature on this problem. His citations of the world literature are detailed and extensive. His style is clear and good.

The author has in every way fulfilled his aim — stated in the introduction — of presenting surgeons with a practical guide to the use of free skin grafts and of aiding plastic surgeons in their everyday work and their research work.

Zoltán's book is a valuable contribution to the literature of plastic surgery.

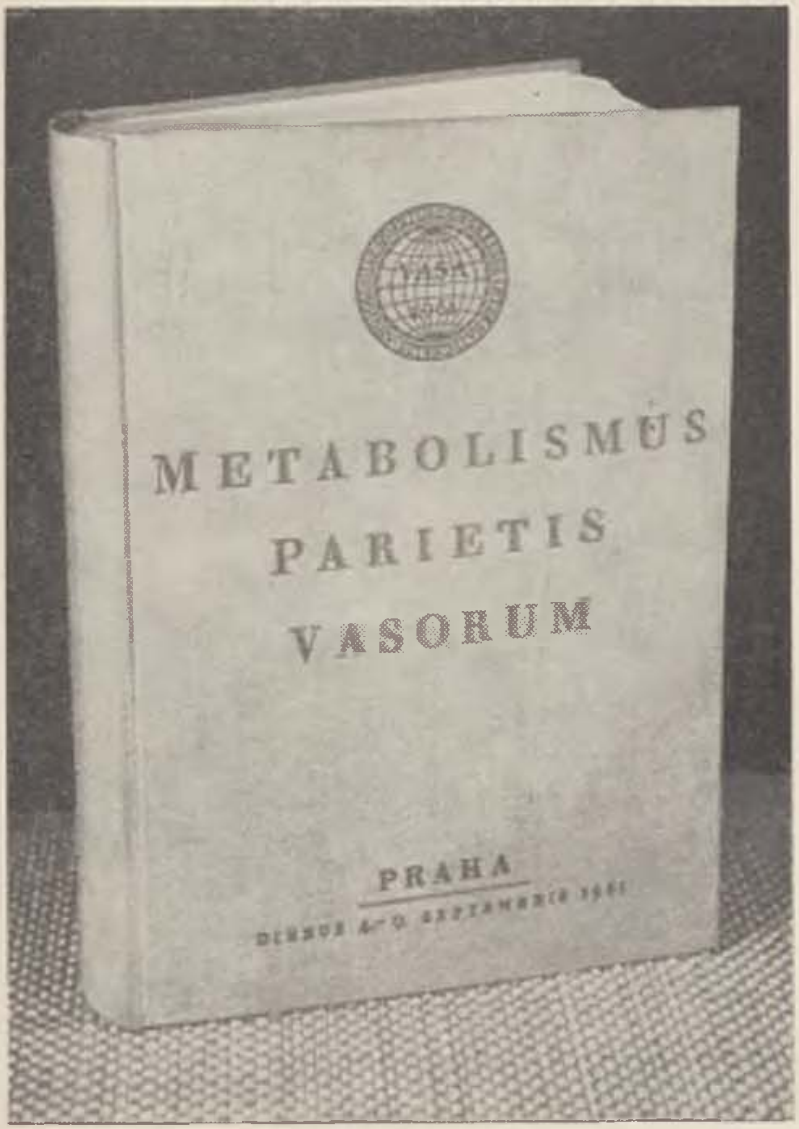

EDITORS:

B. PRUSÍK,

Z. REINIŠ,

O. RIEDL

The publication has 1144/64 pages and 638 illustrations; price of a bound copy $ 17

This almanac of the IVth International Angiological Congress held in Prague on September 4—9, 1961, gives results of the most recent research into pathogenesis, diagnostics and therapy of vascular diseases with special reference to diseases of arteries, veins and the lymphatic system. Prominent specialists from 30 countries present in this publication their experiences in the form of 40 papers and 160 communications. The various contributions are published in official languages (English, French, Russian, and German) and are supplemented with short summaries. Papers published in Russian have Russian and English summaries. The majority of the contributions have ample documentation.

May be ordered at

ARTIA

Praha 1, Smečky 30

ČSSR

Published by the

State Medical Publishing House,

Prague

April 1963

TABLE OF CONTENTS