ACTA CHIRURGIAE PLASTICAE

INTERNATIONAL JOURNAL
OF PLASTIC SURGERY

VIII · 2

1966

Acta chir. plast. 8: 2 : 1966

CZECHOSLOVAKIA · PRAGUE · SZDN

Published four times (in 1959: two times) a year by Státní zdravotnické nakladatelství, (Czechoslovak Medical Press), Malostranské nám. 28, Praha 1. — Adress of the editorial office: Acta chirurgiae plasticae (M. Dobrkovský, M. D. — Secretary) Legerova 63, Praha 2, Czechoslovakia. — Orders through ARTIA, Smečky 30, Praha 2. — Press: Středočeské tiskárny, n. p., provoz 101, Hálkova 2, Praha 2. — A-16*61185

TABLE OF CONTENTS

EDITORIAL

Development and Present State of Plastic Surgery

In his welcoming speech at the Stockholm International Congress of Plastic Surgeons, Sir Harold Gillies, President of the Society, said that apart from photography there had been nothing new in this field of late. On thinking his words over, we are bound to note with surprise that many so-called new methods were in essence suggested or applied 50, 100 and even 1,000 years ago. Already at that time there were skilful surgeons who were in a similar position to Demichov, Dempster and others, for instance, today, who with brilliant technique are capable of sewing a second head or heart, or another limb, onto an animal but who, for known and unknown reasons, have failed to achieve permanent success.

The history of plastic surgery dates back to ancient times; actually it is as old as medicine itself. Since time immemorial children have been born with deformities, and man in the struggle with nature has suffered injury leading to serious consequences. Ancient surgery was in essence reconstructive surgery. Of course, it was possible to perform only the most necessary, life-saving operations, manipulate tissues only locally — and to wait and see. Pain, loss of blood, infection, insufficient experience, superstition and religious prejudice hampered the development of surgery for many centuries. At that time surgeons were not held in great esteem in medical circles and were called upon by doctors to perform the dirty work which was below their dignity. Such was the situation for many hundred years.

During the long period of development surgery remained essentially a craft. Surgeons performed the operation but the fate of the wound and patient rested, as the saying goes, in the hands of God. The patient survived the operation or did not survive — there was no other alternative. Even if he survived the immediate operation, he often died from the late effects. Pain, loss of blood and wound contamination were all accepted as necessary evils.

It is only possible to regard surgery as a science from the time when in addition to routine work, surgeons started to make experiments, became biologists and began to treat the organism as a whole and not only the wound.

Four great discoveries made the development of modern surgery possible: anaesthesia, aseptic technique, transfusion and antibiotics. We believe that the

time is not far off when further discoveries will lead to extention of the present scope of treatment. The immediate requirements are a better knowledge and more complete mastery of complex functional pathophysiological conditions developing after operations and injuries and the solving of the problems of tissue incompatibility in homotransplantations; after this, new and tremendous perspectives will open before us. There still remains the problem of cancer, but it seems that the final solution of this problem does not rest mainly with the surgeon.

What lines is the development of plastic surgery taking and what is the standing of plastic surgery among the other branches of surgery?

Our branch has long passed the stage when it was more or less confined to the repair of nose deformities, or earlier, during World War I, to maxillo-facial surgery. The pioneers of plastic surgery were actually people who operated within the framework of their own specialized fields, e.g. otorhino-laryngologists, ophthalmologists, orthopaedic surgeons, stomatologists and others. However, they had no training in general surgery and medicine; in fact, for their purely local operations such training was not even necessary.

Between the two world wars plastic surgery was confined to aesthetic or so-called cosmetic surgery.

Since World War II the scope of our work has changed. It was necessary to treat a great many complicated fractures, to replace lost structures, to treat paraplegic ulcers, frostbite and burns and to prepare soft tissues for orthopaedic surgery. Thus, the surgery of the hand and surgical treatment of burns was developed; new methods of treating injury to the soft parts were introduced and the method of tissue transplantation improved. In this way reconstructive surgery, as it is now known, came into being.

As the scope increased, the training of plastic surgeons had to be improved. This new concept entails extensive experience in the basic disciplines, primarily in general surgery.

Training in general surgery must, of course, not be confined to technical training. Before passing the first postgraduate examination the plastic surgeon must acquire a certain knowledge of pathophysiology, of fluid and electrolyte shifts under various circumstances, master the basic principles of transfusion, haemodynamics, anaesthesiology and oncology. Only when equipped with the knowledge of general principles common to all fields of surgery, should he be admitted to postgraduate specialized training in plastic surgery.

What is our conception of the training of plastic surgeons? We consider at least four years of general surgery and specialization in this field as well as five years' work in a plastic surgery department, with at least 50 beds, in a teaching hospital to be essential. It is of great advantage if such a department is in close contact with a department of general surgery, and better still, if the hospital has other specialized departments, so that team work can easily be arranged; we are guided by the principle that a good team of surgeons is better than a team of good surgeons.

A plastic surgeon thus becomes a general plastic surgeon. On the basis of experience in general surgery he performs specialized work in all branches of surgery. He should not work in isolation but be in close contact with medicine from which he draws new general knowledge, and in return, pays back his debt in the form of specialized aid to the basic and other branches.

Independent and specialized hospitals, in our case, university hospitals, whose task it should be to verify and elaborate new methods of treatment, to engage in research work and to teach in the broadest sense of the word are of the utmost importance for the development of plastic surgery. For curative purposes specialized departments should be established at each larger hospital, if possible next to departments of general surgery, so that specialized aid of the plastic surgeon is available immediately after the admission of patients with injuries or disease.

Patients of a certain type are concentrated at specialized departments and thus special experience is gathered. However, it would be a mistake if the specialized disciplines became isolated and the specialists concerned only discussed their problems among themselves.

Separate questions such as research problems should be discussed in smaller groups where ideas can be exchanged and criticism induces self-criticism. However, it is important to put the experience thus gained at the disposal of a larger forum of plastic surgeons where knowledge can be mutually exchanged. In this way a joint contribution is made to progress.

Good instruments are of great importance to progress in surgery, in our case, for instance, the dermatome which enabled the surgeon to perform operations which were not possible prior to its invention and introduction into practice. It is important, however, to learn how to handle these instruments properly or else more harm can be done than good. The introduction of such instruments into practice made the surgical treatment of deep burns possible. During World War II. orthopaedic surgeons, neurosurgeons and traumatologists gave plastic surgeons the chance to develop methods of free and flap skin transplantation, and plastic surgeons are ready to return their debt and pass their experience to all who are interested in this field. Every surgeon should master the basic principles of plastic surgery.

For the plastic surgeon there remains work which requires specialized training and further specialization (surgery of clefts, of the hand and the treatment of burns) taking up much time and entailing the manipulation of tissues in stages; there is no time at busy traumatological or surgical departments for such work (flaps, otoplasty, rhinoplasty, etc.).

Research in plastic surgery is chiefly concerned with the problems of wound healing, the aetiopathogenesis of congenital deformities, homotransplantation, the search for artificial substances which would be tolerated by the human organism and could substitute live tissue.

The problem of prevention of congenital deformities is still waiting solution. No essential discoveries have yet been made though numerous institutions

throughout the world are engaged in research on these questions. The struggle goes on along two lines: a) to find the cause and thus interefere causally, b) to rehabilitate the patient in the best possible way. However, not even in the latter approach is there a unity of viewpoint though the results achieved in this field might seem very good when compared with those of twenty years ago.

It has been found that our "good" results lead to an increased incidence of congenital deformities. Today, it is easier for such a patient to find his proper place in society and married life than it was for patients operated on twenty years ago. We cannot deal in detail with this problem and refer to it, therefore, only as an indication of progress — which is rather symptomatological and not etiological.

These dynamic aspects have given a new scope to plastic surgery, which some years ago was to a certain extent static. All these aspects are of vital importance for the other branches of surgery, including general surgery. However, plastic surgeons are particularly interested in the solution of these problems because they are confronted by them every day as an unsurmountable obstacle in prevention or, at least, in attempts for more rational treatment of pathological conditions falling within their discipline.

In view of the very controversial and not defined views on aesthetic surgery, permit me to express the standpoint of the plastic surgeon. During the period between the two world wars, the work of the plastic surgeons proceeded somehow along one track. After World War II the terrific amount of work in traumatology resulted in the fact that the younger generation was not sufficiently trained for the solution of aesthetic problems. They even developed a certain aversion to plastic surgery. In such an atmosphere one was afraid to read a paper on aesthetic surgery before a surgical gathering so as not to be labelled a craftsman. Of course, it would not be correct to fall into the other extreme. True enough, aesthetic surgery puts higher demands on technical skill than on physiology, but life brings not only pain caused by pathological conditions but also distress from psychosomatic problems and in the latter case aesthetic surgery is a powerful causal remedy. It is sufficient to look round to see how many people are afflicted by visible anomalies. There are people living among us who because of certain deviations from the aesthetic norm suffer mental derangement to such an extent that they cannot work in certain occupations. Many suffer from complexes and our surgical help is of great value to them.

Prof. Š. DEMJÉN, M.D.

The Czechoslovak Academy of Science, Laboratory of Plastic Surgery, Congenital Malformation Research, Prague (Czechoslovakia)
Director: Academician F. Burian

THE NOMENCLATURE FOR CLEFT LIP AND/OR PALATE

F. BURIAN

Since my start in the surgery of clefts, that is since World War I, I have been using the classical Greek-Roman nomenclature. It proved to correspond perfectly to the developmental view: when Veau and Pollitzer (1937) studied the embryonic formation of the upper jaw and palate, they established two groups: the primary and the secondary palate as two developmental units. Thus, the anomalies: Cheilo-schisis, cheilo-gnatho-schisis, gnatho-schisis are clefts of the primary palate, palato-staphylo-schisis clefts of the secondary palate, and cheilo-gnatho-palatostaphylo-schisis clefts of the primary and the secondary palate or the total cleft. Twenty years later P. Fogh-Andersen discovered that the two developmental groups are genetically different too.

So when Stark and Kernahan in 1958 proposed the developmental nomenclature for cleft-lip and palate I was quite ready to accept it. Later on I proposed it to the former Cleft-Palate-Committee of the International Confederation of Plastic Surgeons to be recommended for general use.

There are naturally some difficulties for strict clear-cut divison, e.g. there is not a sharp delimitation between the cheilo-schisis and the cheilo-gnatho-schisis.

Only the microforms of cleft-lip or at most the one third clefts of the lip can be pure without any change in the upper jaw, the second incisor, deepening of the piriform aperture on X-rays, deviation of the base of columella, and of the axis of nose, etc., in unilateral cases. In microforms of bilateral cleft-lip the complications are: the shortening of columella, broadening of nostrils and widening of the distance between the alae, besides the changes on the 2nd incisors and the broadening and deepening of the piriform aperture.

The same is true with the complete staphylo-schisis which is generally associated with a notch in the posterior border of the hard palate. To make a special group of these cases would complicate the scheme.

Contrary to the prevailing usage I include the so-called microform (considered by many to be cleft, healed during intrauterine development) into the sub-group of cleft-lip. They may appear as pigmented vertical lines or slight grooves, descending in the skin from under the threshold of the nostril with or

without a slight nick in the vermilion border. These are anomalies, not variations, they do not occur in the normal population. The dental "microforms" I include are dental anomalies associated with evident changes in maxilla and/or nose which exceed the extent of variations. Isolated changes in size and/or shape, position or even the absence of the second incisor are not included. Such variations of the second incisors are found in 1.32% of our population of from 11 to 15 years of age (Novák J.: Thesis 1951). In families of 336 cleft-probands (personal communication) Dobrkovský found incisor anomalies in 2.8%, in his material Fogh-Andersen found them in 2.5%.

In the different sub-groups the maximal degree of cleft is denoted "complete" (may be $^3/_3$). The complete cleft of the primary and secondary palate we call "total".

Special attention must be paid to the tissue-bridges to be found frequently with cheilo-gnatho-schisis and cheilognatho-palato-schisis. They vary from thin strings, stretched between the upper border of the lateral part of lip and the corresponding point of the medial part or the border of alveolus or neck of premaxilla to a real threshold of nostril or even incomplete cleft lip. In total clefts (primary plus secondary) these bridges may contain bone from the maxillary arch and even from a part of the hard palate as well. Then we speak of combined bridges. There is a not uncommon variety with extremely broad combined connections, which may present like an incomplete cleft-lip and incomplete cleft palate. I include these cases into a special group.

I do not include the "median" cleft-lip into the common cheilo-gnatho-palato-schisis because of a different embryo-genesis of this relatively rare congenital anomaly.

As I mentioned at the beginning, in the Prague Clinic of Plastic Surgery we use the classical nomenclature, the sub-groups of which and occasional notes, indicate the severity of individual cases.

The following scheme may illustrate the method of proceeding. Signs of groups and are added for statistical purposes.

Group A — Clefts of the primary palate:

a) Clefts of lip: (cheiloschisis)

1. Microform (mi) Sign: A, a, 1., r/1/bilat., sym. asym.
2. Incomplete cleft of lip (lower third cleft), with or without changes in teeth and/or maxilla. — Sign: A. a, 2, r/1, Bilat., sym/asym.
3. Incomplete, lower two thirds of lip are cleft, the lip thinned above the cleft, a shallow groove going up from the apex of the cleft, marked changes in maxilla. Sign: A. a. 3, r/1/Bilat, sym/asym.
4. Complete cleft of lip (3/3 cleft lip). An absolute rarity without cleft maxilla; there is at least a lower and upper notch in maxilla and severe disorder of the second incisor and the teeth in the vicinity. Sign: A. a. 4, r/1/bilat, sym/asym.

b) G n a t h o s c h i s i s. Cleft of the maxilla (primary palate). Subgroup 3. most rare without cleft-lip.

1. Incomplete (1/3) — only a notch in alveolar process, deepening of aperture piriformis, and disorder in the second incisor and neighbours as above. Sign: A, b, 1, r/1, bilat., sym/asym.
2. Incomplete (Medium, 2/3). Alveolar process is cleft, severe disturbances in 2,1 and 3 teeth, notch in upper border of maxilla and marked deepening of apertura piriformis. This part of maxillary arch substantially thinned or split. Sign: A, b2, r/1, bilat., sym/asym.
3. Complete (3/3), reaching into the incisor foramen. When unilateral, there is a deviation of premaxilla, when bilateral without bridges, the premaxilla may project far. In symmetrical cases the premaxilla is straight, in asymmetrical cases with bridge on one side or with bridges unequally strong or as a result of former one-sided bridge, more or less deviated. This group may be called cheilo-gnatho-schisis. It is practically identical with the group A, a, 4. Changes in maxilla and alveolus dominate the appearance. Sign: A, b, 3, r/1, bilat., sym/asym: ± bridge.

Group B — Palato-staphylo-schisis. Cleft of secondary palate

a) S t a p h y l o - s c h i s i s

1. Incomplete: (1/3) = uvula — cleft, Sign: B, a, i.
2. Incomplete: (2/3) = half of velum cleft, Sign: B, a, 2.
3. Complete: (3/3) = the whole velum cleft, mostly with a submucous cleft of the posterior border of the hard palate. Sign: B, a, 3 ± B, b, 6.

b) S t a p h y l o - p a l a t o - s c h i s i s

1. Staphylo-palato-schisis incomplete. Cleft of soft palate and posterior third of hard palate (the part of hard palate built by the horizontal laminae of the os palatinum). May be complicated by submucous cleft of the rest of the secondary palate. Sign: B, b, 1 ± B, b6.
2. Incomplete (2/3) cleft of palate reaching to the summit of the palatinal vault. Sign: B, b, 2 ± 6.
3. Complete (3/3) cleft of palate, reaching into the incisive foramen.

   Breadth: 1/3, 2/3 of the breadth of the palate vault; 3/3 horseshoe form, the whole vault lacking, only small shelves of palatal bones are present. Sign: B, b, 3 (1/3, 2/3, 3/3).
4. Unilateral, a very rare form of cleft, the vomer adhering to the shelf of one side. The case has to be strictly examined to ascertain if there is not at least a microform of cleft-lip (disturbance on the 2nd incisor and/or alveolus and the piriform aperture), in which case it would belong to special unclear group described at the end. Sign: B, b, 4.

5. Isolated cleft of hard palate, very rare: a round hole or an oblong gap usually in median line, which may be accompanied by submucous cleft of the rest of the palate. Sign: B, b, 5.
6. Submucous clefts, generally with at least cleft uvula, passing through the soft palate, the soft and a part of the hard palate, or till to the incisive foramen. Sign: B, b, 6.
7. Short palate, hypoplastic, unable to reach the posterior pharyngeal wall and to attend occlusion, often combined with cleft uvula and/or submucous cleft. Sign: B, b, 7 ± 6.

Group C — Total clefts. Clefts of the primary and secondary palate, A and B, cheilo-gnatho-palato-staphylo-schisis. Onesided or bilateral, with or without bridges (soft or combined), symmetrical or asymmetrical, i.e. bridge on one side only or unequal on either side. Sign: C, r/1/ bilat, +/ — bridge sym/asym.

Premaxilla = adequate, hyperplastic, hypoplastic, protruding moderately, strongly

deviated — r/1, rotated — r/1 up.

Group D — A special group: cleft lip +/— cleft of maxilla (incomplete or even complete cleft of primary palate) and a slight degree of soft palate cleft (1/3—2/3 and/or submucous). These cases could be considered as total clefts with extremely broad combined bridges, but in view of their relative frequency, many colleagues in Czechoslovakia consider them to be a special group. We are undertaking research to find out if there are special genetic conditions with the cases in this group.

I think, this schematic pattern would facilitate communication. Of course, the details attached to the members of the subgroups to designate their severity, belong properly to qualification, but it is felt necessary to denote the degrees. One could agree upon other designation for statistical purposes, e.g. initial letters Ch = lip-cleft, P = palate cleft, G = maxilla cleft, Ch, G, P, S = cheilo-gnatho-palato-staphylo-schisis. For graduation of severity, instead of the vulgar fractions of three, the terms mild, middle and severe could be used, provided their mathematical or physical values were agreed upon.

As to the graphical representation, plates containing the whole series of types should be provided for consulting rooms, laboratories and offices where any clinical research, registration and documentation work is going on. For the patients registers the individual figures may be stamped in or pasted in or a schematic figure of the normal complex concerned in which the individual deformity could be marked.

The introduction of a uniform international nomenclature would be real progress but not the solution of the whole task. It would not enable us to establish a prognosis of the individual case, to evaluate the method of treatment used and to compare the values of different methods of treatment.

It is therefore necessary to establish a uniform qualification, which should be based on the special personal, familial and social particularities of the case:

the term of gravidity at birth, birth weight and length, the course of adaptation to the new environment during the first weeks after birth. This would provide information on the constitution of the infant and together with the anatomical (and anthropological), biological and dynamic data, the familial heredity, health and social conditions would enable us to make a prognosis of the final result. All these details summarized in agreed numerical values would constitute an objective qualification on the basis of which the effectiveness of different methods of habilitation of cleft lip and palate could be compared.

Research should be directed to this end.

SUMMARY

The author suggests the terminology for clefts of lip and palate. On the basis of the classical nomenclature, he specifies subcategories according to the degree of the malformation. He also includes microforms. A special category is formed by clefts of lip combined with clefts of the soft palate, and the author recommends detailed genetic research into this group. He also suggests his terminology of categories and subcategories for statistical evaluation.

The author's proposition is a contribution to the discussion of the international subcommittee on terminology of clefts of lip and palate, and expresses the opinion of Czechoslovak surgeons including that of the author, who was a member of the above subcommittee.

RÉSUMÉ

Résumé de la problématique des fentes de lèvres et des fissures palatinales

F. Burian

L'auteur nous présente le projet de la terminologie des fentes des lèvres et des fissures palatinales. Il se tient à la terminologie clinique et, dans les sous-grouppes, il entreprend la qualification du degrès du défaut en question. Il entasse de même les microformes. Une grouppe spéciale est faite des fentes de lèvres accompagnées de la fissure de la voile et recommende une recherche basée sur la génétique. Il souligne l'importance de la terminologie des grouppes et sous-grouppes respectives à l'égard du travail statistique.

Ce projet fait partie de la discussion du sous-comité international de la terminologie des fentes de lèvres et des fissures palatinales et présente l'avis des cliniques tchècoslovaques ainsi qut celuí de l'auteur — membre de ce sous-comité.

ZUSAMMENFASSUNG

Zur Systematik der Lippen- und Gaumenspalten

F. Burian

Der Verfasser schlägt eine Nomenklatur der Lippen- und Gaumenspalte vor, wobei er von der klassischen Nomenklatur ausgeht und in den Untergruppen den Grad der Missbildung angibt. Es werden auch Mikroformen miteinbezogen. Lippenspalten, die mit Spalte des weichen Gaumens kombiniert sind, werden in eine besondere Gruppe

eingereiht; der Verfasser empfiehlt, diese Gruppe eingehend genetisch zu untersuchen. Er schlägt auch eine Bezeichnung der Gruppen und Untergruppen für die statistische Bearbeitung vor.

Dieser Vorschlag stellt einen Beitrag zur Diskussion des internationalen Unterausschusses über die Nomenklatur von Lippen- und Gaumenspalten vor und entspricht der Stellungsnahme der tschechoslowakischen Arbeitstätten sowie des Verfassers, der Mitglied dieses internationalen Unterausschusses ist.

RESUMEN

Al problema de las fisuras labiales y palatinas

F. Burian

En este papel el autor presenta su proposición referente a la terminología de las fisuras labiales y palatinas. Su proposición está basada en la terminología clásica y en los subgrupos califica el grado del defecto. Incluye las microformas. A un grupo especial él incorpora las fisuras labiales combinadas con una fisura del velo y recomienda que este grupo sea investigado en detalle del aspecto genético. Pues propone la terminología de los grupos y sub-grupos para los objetos estadísticos.

Esta proposición forma una parte de la discusión del subcomité internacional, que se ocupa de la terminología de las fisuras labiales y palatinas, expresa la opinión de los lugares de trabajo checoslovacos y del autor quien es el miembro de este subcomité internacional.

(Prof. F. Burian): Šrobárova 50, Praha 10, Czechoslovakia

Divisions of Oral Pathology and Orthodontics, University of Minnesota, School of Dentistry, Minneapolis, Minnesota (U.S.A.)

CLEFT UVULA — A MICROFORM OF CLEFT PALATE

L. H. MESKIN, R. J. GORLIN, R. J. ISAACSON

A historical review of cleft palate literature reveals a large number of speculative reports concerning possible microforms of cleft lip and/or cleft palate. Included in these reports are such entities as missing or peg-shaped, permanent, maxillary lateral incisors (1, 3); cleft uvula (4, 5); submucous palatal clefts (6); supernumerary teeth (7); high, narrow palate (8); hairline indentations of the lip; deviations of the nasal septum and palatal defects demonstrated by laminographic examination (9). Except in isolated instances prevalence studies of these minor defects are not to be found in the literature and therefore thwart attempts to associate them with clefts.

If any of these anomalies are microforms of cleft palate, rigidly controlled studies should be instigated with adequate and representative sample and control groups. It must be emphasized that such studies would be of more than academic interest since if true microforms could be demonstrated, research into the etiology of clefts of the lip and palate would be greatly facilitated.

Cleft palate occurs approximately once in each three thousand live births. A microform of cleft palate that is five or ten times as common would allow larger studies with a much smaller population group. New insights into the genetic risks might be obtained as well as information on environmental effects concerning the initiation, penetrance and extent of this defect. For this reason the authors have been working in the area of one specific microform, cleft uvula.

Previous studies of the prevalence of cleft uvula in the general population have demonstrated that this congenital defect occurs more frequently than does the similar, but more severe malformation of isolated cleft palate (4). The morphologic parallels between these two defects suggest that cleft uvula is the most minimal discrete manifestation of cleft palate and therefore, a microform of cleft palate. Indeed, one recent study reported that the genetic transmission of these two malformations closely follows a similar pattern (5). More conclusive evidence of the relationship between these two defects must be established before the knowledge of cleft uvula can be utilized in genetic counseling or in further etiologic studies.

If cleft uvula is in fact a microform of cleft palate, relatives of cleft palate probands should show an increased prevalence of cleft uvula. Conversely, the

relatives of cleft uvula probands would be expected to demonstrate an increased prevalence of cleft palate. On the other hand, if cleft uvula is either a normal variation of palatal morphology or a separate genetic entity, relatives of cleft palate probands would be expected to show a normal prevalence of cleft uvula. Relatives of cleft uvula probands should also manifest a normal prevalence of cleft palate.

These relationships are hypothesized in tabular form in Tab. 1.

To test the hypothesis that cleft uvula is a microform of cleft palate a study was designed to ascertain if the prevalence of cleft uvula was higher among the relatives of cleft palate probands than in a group of control families.

Tab. 1. Hypothesized Basis of Cleft Uvula and the Resulting Anticipated Frequency of Cleft Uvula Among Relatives of Cleft Palate Probands and Also the Anticipated Frequency of Cleft Palate among Cleft Uvula Probands

If Cleft Uvula Is A	Expected Frequency of Cleft Uvula among Relatives of Cleft Palate Probands	Expected Frequency of Cleft Palate among Relatives of Cleft Uvula Probands
A. Microform of Cleft Palate	High	High
B. Normal Variation	Normal	Normal
C. Separate Genetic Entity	Normal	Normal

METHODS AND MATERIALS

Families for this study were drawn from the active files of the cleft palate team of the Kenny Rehabilitation Institute and Foundation, Minneapolis, Minnesota.

Selection was on a geographic basis, i.e. families living within a thirty mile radius of the Kenny Institute were investigated, and thirty families represented by a cleft lip / cleft palate proband and twenty families represented by a cleft palate proband were selected. After clearance from the family physician, the families were contacted and an appointment for a home interview and examination of the uvula were made. At this interview, names and addresses were obtained of living and locally-situated grandparents, aunts and uncles of the probands. These people were contacted and appointments for uvular examinations were made. A total of 343 family members were examined of which 222 were parents or siblings of the probands. A control group selected at random from entering freshman students at the University of Minnesota was composed of families which included 281 individuals.

The uvulae of all individuals were examined by oral inspection and were classified into four arbitrary categories as in earlier studies: Type A: normal uvula, Type B: uvula bifurcated up to one-fourth its total length, Type C: uvula bifurcated from one-fourth to three-fourths of its length, and Type D: uvula bifurcated from three-fourths to its total length.

RESULTS

Eleven of the 30 families represented by a cleft lip / cleft palate proband demonstrated at least one relative with a cleft uvula. Similarily 9 of the 20 families represented by a cleft palate proband had at least one member with a cleft uvula. Thus 20 of the original 50 proband families showed a minimum of one proband relative with some degree of cleft uvula.

Tab. 2.
Prevalence and Distribution of Cleft Uvula among the Relatives of CL/CP and CP Probands

Relative	Probands CL/CP N = 30	Probands CP N = 20	Total N = 50
Siblings N = 127	11/77 14.4 %	9/50 18.0 %	20/127 15.7 %
Parents N = 95	4/57 7.0 %	6/38 15.9 %	10/95 10.5 %
Other Relatives N = 121	5/90 5.6 %	0/31	5/121 4.1%
Total N = 343	20/224 8.9 %	15/119 12.6 %	35/343 10.2 %

The prevalence and distribution of these cleft uvulae among the various family groups are shown in Tab. 2. Of the 343 relatives examined, 35 individuals (10.2%) demonstrated cleft uvula. Most frequently affected were proband siblings (15.7%) while proband parents were second most commonly affected (10.5%) with proband relatives least affected (4.1%). It should also be noted that some tendency was shown for the immediate family (i.e. siblings and parents) of the cleft palate probands to demonstrate cleft uvula more commonly than the same relatives of the cleft lip / cleft palate probands. This tendency was small, however, and the frequency of cleft uvula among both proband groups was significantly greater than the frequency of cleft uvula reported in previous studies (4, 10, 11).

In the control group, 4 observations of cleft uvula were noted with 1 of the 4 having a relative with cleft palate. None of the families in this group had more than one member affected with cleft uvula.

The distribution of cleft uvula according to the sex of the affected relatives and the severity of the uvular defect, shown in Tab. 3, indicated no apparent difference between the prevalence of cleft uvula in male and female relatives. The severity of the uvular defects was related inversely to the frequency of their occurrence — a finding compatible with studies of cleft uvula among other, less biased populations.

DISCUSSION

The prevalence of cleft uvula in other groups has been reported as high as 1.82% (10) and as low as 0.2% (11). In this study, a prevalence of 10.2% was recorded. Moreover, among the immediate relatives of the probands (sibs and parents), 30 cleft uvulas were noted among 222 individuals — a prevalence of 13.5%.

Tab. 3. Sex Distribution and Severity of Cleft Uvula among the Relatives of Cleft Lip/Cleft Palate and Cleft Palate Probands

Type of Cleft	Male Relatives			Female Relatives			Total Relatives		
	CL/CP N=117	CP N=59	Total N=176	CL/CP N=107	CP N=60	Total N=167	CL/CP N=224	CP N=119	Total N=343
Type B			14			10			24
Type C			5			5			10
Type D			1			0			1
Total All Types	11	9	20	9	6	15	20	15	35
Percent	9.4	15.3	11.4	8.4	10.0	9.9	8.9	12.6	10.2

The markedly increased frequency of cleft uvula in the families of cleft probands as compared to the frequency of cleft uvula found in normal control families clearly indicates that cleft uvula must be at least tentatively accepted as the most minimal discrete manifestation of cleft palate and should, therefore, be regarded as a microform of cleft palate.

It is interesting to note that while the frequency of cleft uvula was greater in the relatives of cleft palate probands it was also markedly increased in the relatives of cleft lip / cleft palate probands. Since evidence has been reported that isolated cleft palate is a different genetic entity from cleft lip / cleft palate (12), what relationship does cleft uvula bear to the latter?

A further hypothesis that cleft uvula is also a microform of the cleft palate segment of the cleft lip / palate complex might explain the high incidence of cleft uvula noted in the cleft lip / cleft palate families. If this is true, other types of microforms might also be expected to exist in the areas of the lip, alveolar process and hard palate. Such findings in family relatives of cleft lip and cleft palate probands have been noted by Fukuhara (9) who observed both laminographic bony defects as well as facial soft tissue defects in otherwise normal appearing relatives of cleft lip / cleft palate patients. Fukuhara concluded that a search for such microforms might increase the familial manifestations of facial clefting to a frequency of 50%.

Although the findings of this study suggest a similar prevalence of cleft uvula in the relatives of isolated cleft palate probands and cleft lip / cleft palate

probands, the important fact is that a conclusive relationship between uvular defects and both of these more severe defects was demonstrated. If the further hypothesis that cleft uvula is a microform of both isolated cleft palate and the palatal portion of the cleft lip / cleft palate complex is correct, no contradiction exists with evidence reporting isolated cleft palate as a different genetic entity from cleft lip / cleft palate (12).

Of a more immediate and practical nature is the new importance given to the presence of cleft uvula by Pruzansky. In a recent report Pruzansky (13) demonstrated a significant relationship between the removal of adenoid tissue and the production of hypernasality in cleft uvula probands. Thus any group of people who show a high frequency of cleft uvula should be made aware that indiscriminant removal of adenoid tissue may produce a life-long speech difficulty.

SUMMARY

A marked increase in the prevalence of cleft uvula was noted in the families of probands with isolated cleft palate and cleft lip / cleft palate when compared to a control group of normal families. These data support the hypothesis that cleft uvula is a microform of cleft palate and also the cleft palate portion of the cleft lip / cleft palate complex.

Acknowledgments. Much appreciation is due to Dr. Samuel Pruzansky, Associate Director of the Cleft Palate Clinic, University of Illinois and Dr. Sheldon Reed, Director of the Dight Institute, University of Minnesota for their critical evaluation of this paper.

RÉSUMÉ

La fissure de la luette en tant que microforme de bec-de-lièvre

L. H. Meskin, R. J. Gorlin, R. J. Isaacson

Les auteurs ont remarqué une augmentation significante de l'apparition du bec-de-lièvre dans des familles en épreuve, atteintes non pas seulement des fissures palatinales, mais aussi des becs-de-lièvres complets, en comparaison avec une groupe des familles vierges. Ces données soutiennent l'hypothèse du fait que la fissure de la luetta présente non pas seulement une microforme d'une fissure palatinale isolée, mais de même du segment palatinal dans le complexe du bec-de-lièvre complet.

ZUSAMMENFASSUNG

Die Uvula-Spalte, eine Mikroform der Gaumenspalte

L. H. Meskin, R. J. Gorlin, R. J. Isaacson

In den Familien der untersuchten Personen, die einerseits isolierte Gaumenspalten, anderseits Gaumen- und Lippenspalten aufwiesen, wurde im Vergleich mit einer Kontrollgruppe normaler Familien eine markante Steigerung der Frequenz von Uvula-Spalten gefunden. Diese Befunde bekräftigen die Hypothese, dass die Uvula-Spalte eine Mikroform sowohl der isolierten Gaumenspalte als auch der Lippen-Gaumen-Spalte darstellt.

RESUMEN

La escisión de la úvula — una microforma de escisión del paladar

L. H. Meskin, R. J. Gorlin, R. J. Isaacson

Fué comprobado un ascenso significativo en la frecuencia del hallazgo de la escisión de la úvula en las familias de los afectados, tanto por la escisión aislada del paladar, como por la escisión del labio y del paladar, en comparación con un grupo de control de familias normales. Estos hallazgos apoyan la hipótesis de que la escisión de la úvula es una microforma tanto de la escisión aislada del paladar, como del segmento palatínico en el complejo de la escisión del labio y del paladar.

REFERENCES

1. **Lucas, R. C.:** Clin. Soc. (London Tr.) 21 : 64—66, 1888.
2. **Lucas, R. C.:** Brit. J. Child. Dis. 1 : 483—489, 1904.
3. **John, A.:** Acta odont. scand. 9 : 41—59, No. 1, 1950—1951.
4. **Meskin, L. H., Gorlin, R. J., Isaacson, R. J.:** Cleft Palate J. 1 : 342—346, 1964.
5. **Meskin, L. H., Gorlin, R. J., Isaacson, R. J.:** Cleft Palate J. 2 : 40—44, 1965.
6. **Calnan, J.:** Brit. J. Plast. Surg. 6 : 264—282, 1954.
7. **Kirkham, H. L. D.:** Intern. J. Orthodont., Oral Surg., Radiog. 17 : 1076—1083, 1931.
8. **Mengele, J.:** Cited in Fogh-Andersen, P.: Opera Ex Domo Biologicae Hereditariae Humane Universitatis Hafniensis. Inheritance of Cleft Lip and Cleft Palate. Kobenhavn. Ejnar Munsgaard; p. 26, 1943.
9. **Fukuhara, T., Siato, S.:** Bull. Tokyo Med. Dent. Univ. 10 : 333—345, 1963.
10. **Berans, C.:** Philadelphia med. Bull. 15 : 177—179, 1893.
11. **McIntosh, R., Merritt, K. K., Richards, M. R., Samuels, M. H., Bellows, M. T.:** Pediatrics 14 : 505—522, 1954.
12. **Fogh-Andersen, P.:** Opera Ex Domo Biologicae Hereditariae Humanae Universitatis Hafniensis. Inheritance of Harelip and Cleft Palate. Kobenhavn, Ejnar Munksgaard 1943.
13. **Pruzansky, S., Mason, B.:** Clinical, Radiographic and Genetic Investigation of 102 Cases of Congenital Palatepharyngeal Incompetence. Abstract, Fifth Annual Meeting of the Teratology Society. May 26, 1965, San Francisco, California.

(L. H. Meskin, M.D.:): Divisions of Oral Pathology and Orthodontics,
University of Minnesota, School of Dentistry,
Minneapolis, Minnesota (U.S.A.)

J. Stadnicki, Z. Barańczak

EXPERIMENTELLE UNTERSUCHUNGEN ÜBER DEN WERT UND DIE ANWENDBARKEIT VERSCHIEDENARTIGER KNOCHEN-TRANSPLANTATE IN DER REKONSTRUKTIVEN KIEFER- UND GESICHTSCHIRURGIE

Abb. 1a. Autogenes Knochenimplantat in der Mandibula des Kaninchens 10 Tage nach Überpflanzung. Die Knochenbälkchen des Implantats weisen gefärbte Knochenzellen auf, in der Nachbarschaft ist kollagenes Bindegewebe sichtbar. Färbung: Hämalaun-Eosin, Vergr.: 120×.

Abb. 1b. Die gleiche Art von Implantat 30 Tage nach der Überpflanzung. Der Zerfall von Knochenbälkchen ist angedeutet, in der unmittelbaren Umgebung sind Osteoklasten sichtbar. Das Implantat ist von Bindegewebe umgeben. Färbung: Hämalaun-Eosin, Vergr.: 120×.

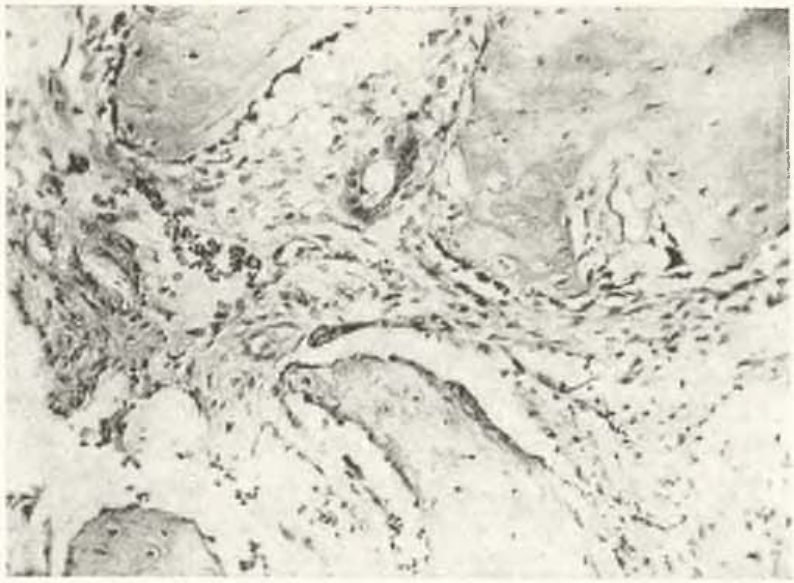

Abb. 2a. Lyophilisiertes homogenes Knochenimplantat in der Mandibula des Kaninchens 20 Tage nach der Überpflanzung. Die Knochenbälkchen sind mit Osteoblasten umsäumt, zwischen diesen befindet sich jugendliches zellreiches Bindegewebe. Färbung: Hämalaun-Eosin, Vergr.: 240×.

Abb. 2b. Die gleiche Art eines Implantates 40 Tage nach der Einpflanzung. Ein Teil der Knochenbälkchen, die in Fragmente aufgeteilt sind, weist eine verschwommene Struktur auf. Die Knochenzellen dieser Fragmente färben sich nicht. Färbung: Hämalaun-Eosin, Vergr.: 240×.

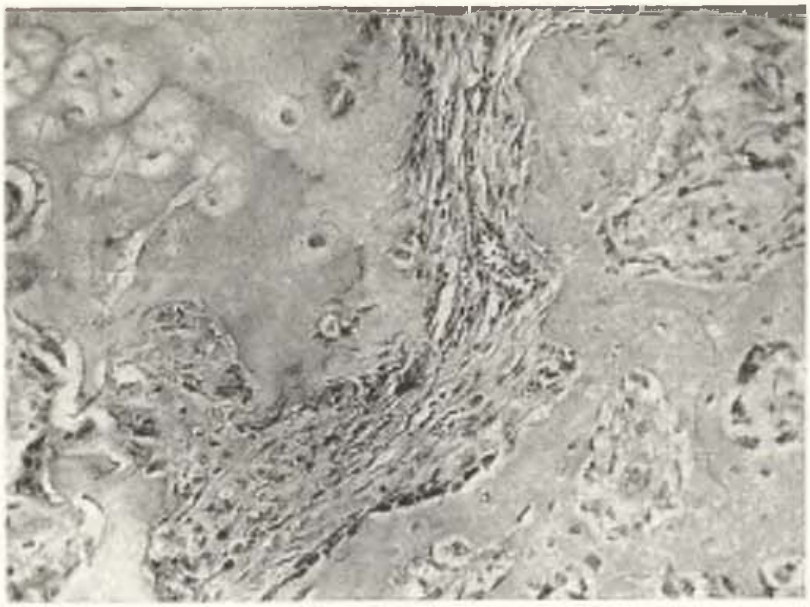

Abb. 3a. Fragment eines lyophilisierten heterogenen Knochenimplantats 20 Tage nach der Einpflanzung. Sichtbar ist Knorpelgewebe mit gut färbbaren Knorpelzellen. Daneben befindet sich jugendliches Bindegewebe. Färbung: Hämalaun-Eosin, Vergr.: 240×.

Abb. 3b. Die gleiche Art von Transplantat 30 Tage nach der Einpflanzung. Fragmente von Knochenbälkchen weisen verwischte Struktur, sowie Hohlräume nach Knochenzellen auf. Färbung: Hämalaun-Eosin, Vergr.: 240×.

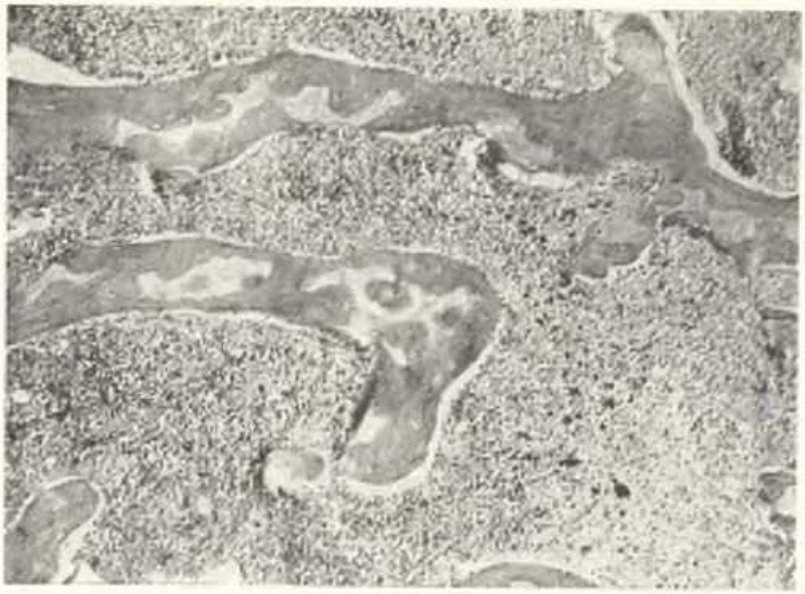

Abb. 4a. Gefrorenes heterogenes Knochenimplantat im Unterkieferknochen des Kaninchens 10 Tage nach der Einpflanzung. Die Struktur der Knochenbälkchen ist verwischt, in dessen Umgebung befinden sich zahlreiche Zellinfiltrationen. Färbung: Hämalaun-Eosin, Vergr.: 120×.

Abb. 4b. Gefrorenes heterogenes Knochenimplantat 30 Tage nach der Implantation. Die Knochenstruktur ist in Fragmente aufgeteilt und weist leere Höhlen nach Knochenzellen auf. Im Bindegewebsgerüst sind Zellinfiltrate sichtbar. Färbung: Hämalaun-Eosin, Vergr.: 120×.

Klinik für Kieferchirurgie der Medizinischen Akademie, Poznań (Polen)
Leiter: Prof. Dr. Jerzy Stadnicki

EXPERIMENTELLE UNTERSUCHUNGEN ÜBER DEN WERT UND DIE ANWENDBARKEIT VERSCHIEDENARTIGER KNOCHENTRANSPLANTATE IN DER REKONSTRUKTIVEN KIEFER- UND GESICHTSCHIRURGIE

J. STADNICKI, Z. BARAŃCZAK

Klinische Versuche über die Anwendbarkeit von Knochentransplantaten in der rekonstruktiven Kiefer- und Gesichtschirurgie stützten sich noch bis vor kurzem hauptsächlich auf experimentellen Untersuchungen und Befunden, die an Röhrenknochen vorgenommen wurden, welche jedoch andere Eigenschaften besitzen, als die flachen Kiefer- und Gesichtsknochen. Die andersartigen und weniger günstigen Verhältnisse für die Knochentransplantate im Kiefer- und Gesichtsbereich sind ausserdem auch durch die Kontaktmöglichkeiten des Knochendefektes mit der Mundhöhle und deren Sekreten bedingt. Aus diesem Grunde ist, unter Berücksichtigung der Spezifität des Operationsfeldes, die Verwendung eines am meisten geeigneten, an Tieren ausprobierten, optimale Ergebnisse liefernden plastischen Materials für die rekonstruktive Kiefer- und Gesichtschirurgie von besonderer Bedeutung. Die Zahl der experimentellen, das Problem von Knochentransplantaten in der rekonstruktiven Kiefer- und Gesichtschirurgie betreffenden Untersuchungen ist verhältnismässig klein, wobei die Untersuchungen vorwiegend autogenes oder gefrorenes homogenes Knochenmaterial betrafen (2, 3, 4, 5, 6, 8, 10, 11, 12, 14, 15).

Das Ziel unserer Arbeit war, vergleichende histologische Untersuchungen über die Einheilung von frisch entnommenen, gefrorenen und lyophilisierten Knochentransplantaten in nichtinfizierte Knochendefekte des Unterkiefers bei Kaninchen durchzuführen.

Die Versuche wurden an Kaninchen ausgeführt, denen in die künstlich angebrachten Unterkieferdefekte die oben erwähnten Knochentransplantate implantiert wurden. Heterogener, einem Kalb entnommener Knochen wurde durch Gefrieren konserviert; ausserdem wurde mittels Lyophilisierung homogener Kaninchen- sowie heterogener Kalbsknochen konserviert. Bevor die Transplantate auf die Versuchstiere überpflanzt wurden, wurde deren histologische Untersuchung vorgenommen. Diese wies sowohl in den gefrorenen, während 10 Tagen bei —35° C aufbewahrten Knochentransplantaten, als auch in den lyophilisierten,

während 5 Monate in hermetisch verschlossenen Glasgefässen bei Zimmertemperatur aufbewahrten Transplantaten deutlich färbbare Zellkerne auf, wie sie in frischen Knochenpräparaten beobachtet werden.

Die Beobachtungszeit der Versuchstiere betrug 50 Tage. Alle 10 Tage wurden makroskopische sowie mikroskopische Untersuchungen durchgeführt. Alle Transplantate heilten ohne Komplikationen ein. Schon nach 20 Tagen konnte makroskopisch festgestellt werden, dass die Transplantate mit dem Empfängerknochen fest verbunden waren, und nach 50 Tagen konnte man sie schwer von der Knochenunterlage des Empfängers unterscheiden.

Zu den histologischen Untersuchungen wurden die das Transplantat enthaltenden Knochengewebsteile entnommen. An Hand der morphologischen Untersuchungen konnte festgestellt werden, dass sich die Knochentransplantate, je nach deren Art, verschieden verhielten und verschiedene Reaktionen in den sie umgebenden Geweben hervorriefen. Im Endeffekt jedoch führten alle zu einer Ausfüllung der künstlich hergestellten Unterkieferknochendefekte bei unseren Versuchstieren, obwohl gewisse zeitliche Unterschiede festzustellen waren.

Genauere histologische Untersuchungen ergaben, dass im Falle eines künstlich hergestellten Mandibuladefektes das allerbeste Material für die Reizung der Knochenunterlage, autogenes, demselben Tier entnommenes Knochengewebe ist (Abb. 1a, 1b), daneben jedoch ebenfalls lyophilisierter homogener Knochen (Abb. 2a, 2b). Erwähnte Implantate führten innerhalb von 50 Tagen zu einer totalen Ausfüllung des Knochendefektes, wobei betont werden muss, dass einige Bälkchen des lyophilisierten homogenen Transplantates die Struktur, sowie herdmässig auffärbbare Knochenzellen bis zum Ende der Beobachtungszeit beibehielten. Gute Ergebnisse wurden ebenfalls durch lyophilisierte heterogene Transplantate erzielt, obwohl deren Umbau etwas verzögert war (Abb. 3a, 3b). Die erwähnten Knochentransplantate riefen keinerlei Reaktionen von Seiten des Wirtsgewebes hervor. Die vierte Art der Knochentransplantate (gefrorenes heterogenes Knochengewebe), rief dagegen in allen Observationsphasen eine Reaktion in Gestalt einer Anhäufung von eosinophilen Granulozyten in dessen nächster Umgebung hervor (Abb. 4a, 4b). Es scheint, dass diese Reaktion nicht die Folge einer Infizierung der Wunde, oder der Fremdkörperwirkung war, da sie mit grosser Regelmässigkeit in allen Observationsphasen und nur in unmittelbarer Umgebung des gefrorenen Transplantats auftrat. Diese Tatsache muss durch die Reaktion des Empfängergewebes auf die im Transplantat anwesenden, durch das zu kurze Gefrieren nicht zerstörten Antigeneigenschaften des Implantats erklärt werden. Nach Ansicht einiger Autoren (7) verlieren gefrorene Knochentransplantate ihre Antigeneigenschaften erst nach 1-monatiger Aufbewahrung im Gefrierschrank. Haas (zit. nach 13) hat dies zwar in seinen Untersuchungen nicht bestätigt, jedoch erlaubten die während aller Beobachtungsphasen auftretenden Reaktionen von Seiten des Empfängergewebes die Vermutung auszusprechen, dass die zu unseren eigenen Untersuchungen vorbereiteten und verwandten Knochentransplantate keineswegs von den spezifischen Eigenschaften des Gewebseiweisses frei waren. Diese Tatsache hatte wahrscheinlich ebenfalls Einfluss auf die Verspätung der Umbauprozesse im erwähnten

Transplantat. Nach Ansicht einiger Autoren (9) weisen gefrorene Knochentransplantate die grösste osteogenetische Aktivität nach 2—3-monatiger Aufbewahrung im Gefrierschrank auf.

Auf Grund beschriebener eigener Untersuchungen scheint es, dass die Rolle sowohl des frisch entnommenen autogenen, als auch des durch Gefrieren oder Lyophilisierung konservierten Knochens, lediglich auf einer induktiven Erregung der knochenbildenden Prozesse von Seiten der Knochenunterlage beruht. Die Anwesenheit von auffärbbaren Knochenzellen in den Knochenbälkchen autogener Transplantate während der ersten Observationsphase, sowie deren, die ganze Versuchszeit über festgestellte Anwesenheit (obgleich in geringerer Anzahl) in lyophilisierten Transplantaten, hat, wie es den Anschein hat, für die Knochenbildung keine grössere Bedeutung. Die knochenbildende Tätigkeit der in den Knochentransplantaten überlebenden Zellen ist, nach einigen Autoren, sehr gering, und hat im Grunde genommen, keinerlei praktische Bedeutung. Es ist jedoch Tatsache, dass die nach einer besonderen Methode konservierten Knochentransplantate, bei denen die Lebensfähigkeit der Knochenzellen keine Beeinträchtigung erlitt, eine grösseren praktischen Wert für den Aufbau des Knochendefektes besitzen, als abgestorbene Transplantate, was schon in zahlreichen experimentellen Arbeiten betont wurde. Während des Absterbens von Knochentransplantaten wird der als Unterlage dienende Empfängerknochen durch die sich freisetzenden Abbauprodukte zur Bildung eines neuen Knochens angeregt. Nach der Ansicht von Nowaczenko (zit. nach 1) soll das Resultat der Knochenplastik von der Zahl der überlebenden Knochenelemente im Transplantat abhängig sein. Auf diese Weise werden auch die überaus guten Resultate nach Anwendung von autogenen, und die fast ebenso guten, nach Anwendung von homo-, und selbst heterogenen, gefrorenen oder lyophilisierten Transplantaten erklärt, da erwähnte Konservierungsmethoden einem Teil der Zellen das Überleben sichern, und ausserdem die spezifischen Antigeneigenschaften der Transplantate schwächen.

FOLGERUNGEN

1. Autogene, gefrorene und lyophilisierte Transplantate wurden von Versuchstieren gut vertragen, und alle heilten ohne Komplikationen ein.

2. Durch histologische Untersuchungen von Gewebsschnitten, die autogene, und lyophilisierte homo- und heterogene Transplantate enthielten, wurden in deren Nachbarschaft keinerlei Zellinfiltrationen festgestellt, die von einer Reaktion des Empfängergewebes auf das implantierte Gewebe zeugen könnten.

3. Eine Reaktion im Wirtsgewebe wurde lediglich durch gefrorene heterogene Transplantate hervorgerufen, wahrscheinlich infolge einer zu kurzen Aufbewahrung des Knochenmaterials im Gefrierschrank.

4. In eigenen Untersuchungen hatten lyophilisierte homogene Knochentransplantate den gleichen Wert wie Transplantate von autogenem Knochengewebe.

5. Lyophilisiertes heterogenes Knochenimplantat wies im Vergleich mit autogenen und homogenen Transplantaten eine Verspätung in den Umbauprozessen auf.

6. Der Wert des gefrorenen heterogenen Knochentransplantates wurde durch den verspäteten Umbau, sowie durch das Auftreten von Gewebsreaktionen im Wirtsgewebe wesentlich beeinträchtigt.

ZUSAMMENFASSUNG

Die Autoren geben eine histologische Bewertung von frisch entnommenen autogenen, lyophilisierten homo- und heterogenen, sowie gefrorenen heterogenen Knochentransplantaten, die zur Füllung von künstlich angelegten Unterkieferknochendefekten bei Kaninchen dienten. Die osteogenetischen Eigenschaften der Knochenunterlage wurden bei Anwendung von autogenen Transplantaten am meisten, und bei Anwendung von lyophilisierten homogenen Transplantaten fast ebenso stark erregt. Bei Anwendung von lyophilisierten oder gefrorenen heterogenen Transplantaten war der Knochenumbau etwas verzögert. Ausserdem riefen gefrorene heterogene Transplantate von Seiten des Empfängerknochens eine Reaktion hervor, die sich mit einer Anhäufung eosinophiler Zellen kennzeichnete.

SUMMARY

Experimental Research in Value and Applicability of Bone Transplants of Various Provenience for Reconstructive Surgery of Jaw and Face

J. Stadnicki, Z. Barańczak

The authors present a histological evaluation of fresh autogenous, lyophilized homogenous and heterogenous as well as frozen heterogenous bone grafts which had been used for bridging artificial bone defects in the mandible of rabbits. The osteogenic capacity of the bony substrate was stimulated most when using autogenous grafts and almost as powerfully when using lyophilized homogenous grafts. After implantation of lyophilized or frozen heterogenous grafts, transformation of bone was slightly retarded. In addition, frozen heterogenous transplants caused a reaction in the recipient bone which was characterized by an accumulation of eosinophil cells.

RÉSUMÉ

Les données expérimentales de la qualité ainsi que de l'utilité des transplant osseux de toute provenance dans la chirurgie réparatrice de la face et des mâchoires

J. Stadnicki, Z. Barańczak

Les auteurs décrivent des données histologiques des transplants osseux fraîs autogènes, homogènes lyophilisés, hétérogènes de même que hétérogènes gelés, tous ayant servi de compléter les défauts artificiels de la mandibule des lapins. Les qualités ostéogénétiques de l'os en question ont été encouragées le plus efficacement au moment de se servir des transplants autogènes et, à peu près le même résultat a été obtenu avec les homotransplants lyophilisés. L'emploie des hétérotransplants lyophilisés ainsi que gelés a retardé la transformation osseuse. En surplus, quand on s'est servi des hétérotransplants gelés, la réaction de l'os du récipient a trouvé place, charactérisée par l'agglomération des cellules éosinophiles.

RESUMEN

Las investigaciones experimentales del valor y de la utilización de varios transplantes óseos en la reconstrucción de la mandíbula y la cara en cirugía

J. Stadnicki, Z. Barańczak

En ese papel los autores presentan una evaluación histológica de los transplantes autógenos, homógenos liofilizados y heterógenos recién tomados tanto como los transplantes óseos heterógenos congelados que sirvieron para completar los defectos óseos artificialmente provocados de las mandíbulas inferiores en los conejos. Las propiedades osteogenéticas de la base ósea fueron estimuladas al máximo al emplear los transplantes autógenos, casi con el mismo resultado al emplear los transplantes homógenos liofilizados. Cuando se empleaban los transplantes liofilizados o los transplantes heterógenos congelados la reconstrucción ósea se atrasó un poco. Además, cuando se empleaban los transplantes heterógenos congelados el hueso del recibidor causó una reacción la que fue caracterizada por una aglomeración de las células eosinofilas.

LITERATUR

1. **Aga, W. W.**: Ortop. Travm. Protez. 2, 28—32, 1958.
2. **Axhausen, W.**: Dtsch. Zahnärztl. Z. 23, 1527, 1961.
3. **Boyne, Ph.**: Oral Surg. 15, 231, 1954.
4. **Boyne, Ph., Kruger, G. O.**: Oral Surg. 15, 3, 1962.
5. **Cross, W. G.**: J. Periodont, 3, 134, 1957.
6. **Egian, G. M.**: Stomatołogia 1, 57—58, 1963.
7. **Elberg, G., Grigoriew, M.**: Vest. Chir. im. Grekova 8, 71, 1962.
8. **Freidel, H.**: Ann. Odont.-Stomatol. 13, 101, 1956.
9. **Gołowin, G. W.**: Vest. Chir. im. Grekova 9, 100—111, 1957.
10. **Górski, M.**: Czas. Stomat. 9, 359—366, 1955.
11. **Górski, M.**: Czas. Stomat. 12, 685—689, 1955.
12. **Płotnikow, I. A.**: Stomatołogia 5, 37—41, 1961.
13. **Serafinowa, R.**: Sympozjum Med. Współczesnej I, 167—192, 1961.
14. **Zemła, J.**: Czas. Stomat. 1, 29—33, 1962.
15. **Zemła, J.**: Czas. Stomat. 2, 109—116, 1962.

(Prof. J. Stadnicki): Ul. Przybyszewskiego 49, Poznań, Poland

Westminster and Stoke Mandeville Hospital, London (Great Britain)

PARTIAL EXCISION OF THE VOMER IN INFANCY

J. P. REIDY

I. In the unilateral complete cleft of lip and palate (Groupe 3. i. Ritchie and Staige Davis) certain secondary deformities appear in later years. These include under-development and collapse of the lateral alveolar arch, displacement of alar base downwards and backwards, drooping of the nostril margin, obliquity of the whole nose and partial nasal obstruction.

Fig. 1. Cleft lip and palate III. i. (L.) (Ritchie & Davis). External nasal obliquity.

The concern of this paper is with nasal deformity wherein the whole nose leans across the face away from the side of the cleft. The bony bridge and the whole nasal septum are chiefly affected. The deformity becomes more apparent about the seventh or eighth year of age (Fig. 1).

II. CLINICAL FINDINGS

Nasal obstruction is the main feature underlying the nasal deformity and the child often presents in these early years with a history of continuous mouth breathing, snoring, frequent colds and on occasion with earache and deafness.

On examination the whole nose is seen to lean across the face away from the side of the cleft. There is nasal obstruction, partial or complete (Fig. 2), on the side of the cleft due to a prominent intranasal horizontal spur. This spur is made up of maxillary ridge projecting into the affected airway and carrying with it the inferior intranasal border of the septal cartilage. In addition, the columella edge of the septal cartilage is seen to be curled into the

Fig. 2. a) Diagram to show intranasal bony spur with displacement of septal cartilage. — b) Diagram to show effect of removal of whole bony spur.

opposite normal nostril and held there by the prominent spinous process of the partly rotated premaxilla.

Reference has been made to the classification. Here the classification of Ritchie and Staige Davis 1922 has been used. This is extremely useful from a clinical point of view, since it gives a simple labelling of a case in telegraphic form. It does not, however, explain how some of the changes and differences have come about and for this one should refer to the work of Stark, Burston, and Kernahan, whose embryological studies show just how the clefts of lip and palate have occurred and how they vary (Fig. 3).

III. THE POSITION OF VOMER AND ORIGIN OF INTRANASAL SPUR

Examination of the normal skull: This shows that the vomer lies vertically (Fig. 4) in the sagittal plane between the base of the skull and the hard palate. In the infant the vomer extends as a straight strut between the base of the skull and the premaxilla. This is very clearly seen in the bilateral cleft of palate where the vomer is exposed for the whole of its length.

Examination in the infant of the unilateral complete cleft: This shows that the position of the vomer differs from the normal. The

posterior vertical part remains unchanged, but the antero-posterior part of the vomer running along the hard palate towards the premaxilla is no longer in the sagittal plane (Fig. 4b) like a keel, but leans sideways into the cleft of the palate and forms a bony spur.

It is evident that, as the child increases in age, the vomer changes (Fig. 5) in shape and from being a straight strut it now becomes angled. There is a ver-

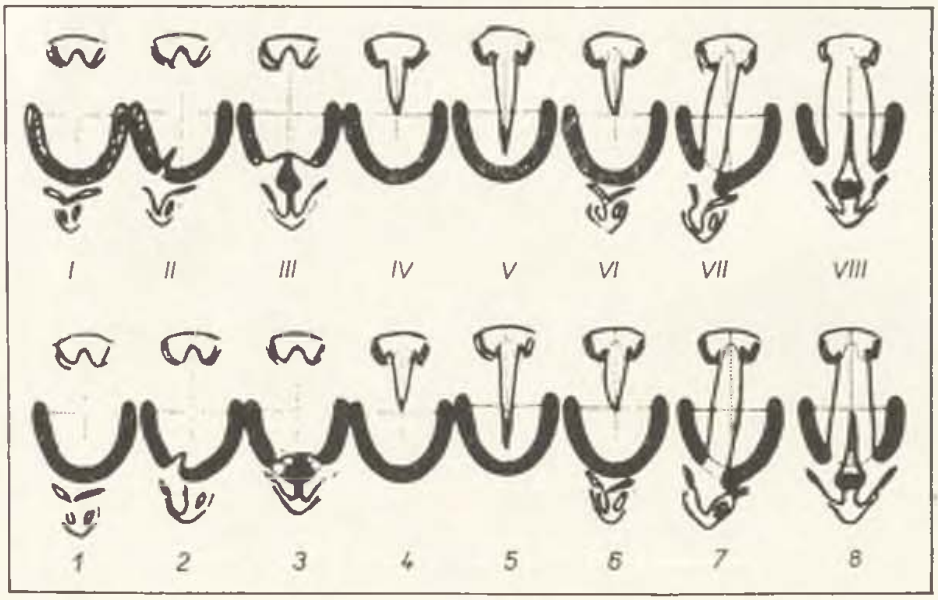

Fig. 3. Cleft Lip and Palate. Classifications. Ritchie & Staige Davis. I — group I.1.; II — group III.1. (without palate); III — group III.3. (without palate); IV — group II. S.P. 3/3; V — group II. S.P. 3/3, H.P. 3/3; VI — group I.1., group II.; VII — group III.1.; VIII — group III.3. — Burston, Kernahan & Stark. 1 — unilateral, subtotal cleft, primary palate; 2 — unilateral, total cleft, primary palate; 3 — bilateral, total cleft, primary palate; 4 — subtotal, secondary palate; 5 — total cleft, secondary palate, 6 — unilateral, subtotal of primary and secondary palate, 7 — unilateral total cleft, primary and secondary, 8 — bilateral total cleft of primary and secondary palate.

tical part extending from the base of the skull to the posterior edge of the hard palate and the horizontal part which runs along the hard palate towards the premaxilla. This change in shape corresponds with the growth of the maxilla downwards and forwards, part of which is due to the thrust of the vomer. The change is well in evidence by the seventh or eighth year, but it is not certain for how many years this vomerine thrust persists.

This part of the vomer is, in the unilateral cleft, attached only to one half of the hard palate, i.e. on the normal side. Further growth of the vomer is not uniform either in itself or in its effect on the premaxilla and the main part of the maxilla. As growth proceeds the vomerine spur projects laterally (Fig. 6) into the airway on the side of the cleft and lies obliquely in the nasal cavity, at the same time carrying the lower edge of the cartilaginous septum with it, thus partially blocking the nasal airway on that side. At the same time the

vomer unattached on the cleft side appears to lift and to push the whole of the nasal bridge across to the opposite side giving the typical nasal deformity associated with this unilateral cleft of lip and palate. This nasal deformity becomes more obvious from the front view of the patient in the 7th and 8th years and at the same time the nasal obstruction on the affected side becomes more marked (Fig. 1).

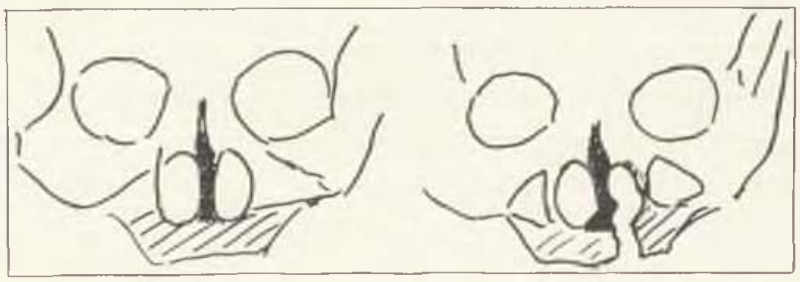

Fig. 4. Tracing of skull X-rays. — a) Normal — showing central septum. — b) Unilateral cleft lip and palate — showing vomerine spur and displaced septum.

IV. SURGICAL TREATMENT OF NASAL OBSTRUCTION IN CHILDREN

It has always been the view of the writer that nasal obstruction is of more importance than the external nasal deformity and that the need for early relief of the obstruction is an essential one. These cases have been subject to lip repair at three months, and V—Y palate repair at the first year.

For many years surgery has been undertaken even at the seventh and eighth year to remove the premaxillary spine and the whole bony spur formed by the vomerine ridge. The intranasal inferior border of the septal cartilage is thus freed to swing back into midline and frequently this border, which is (Fig. 2b)

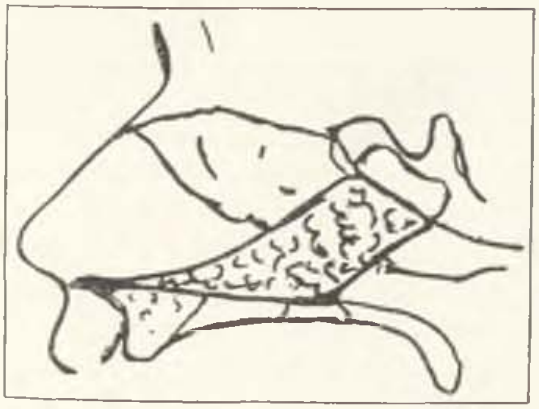

Fig. 5.

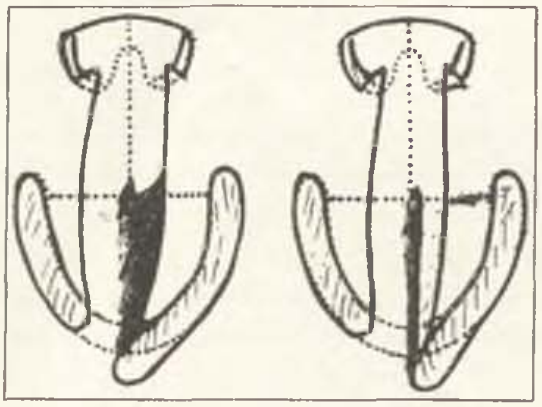

Fig. 6.

Fig. 5. Diagram to show commencing angulation of vomer from vertical to horizontal. — Fig. 6. Diagrams of unilateral clefts of lip and palate (III. i. L.). a) to show septum and vomer in different planes; — b) to show removal of palatal (horizontal) portion of vomer.

thickened and curved, requires either partial excision or thinning of its edge. The blocked nasal airway is thus cleared. In addition, the bony bridge is fractured and straightened. If a through and through excision of the lip scar is undertaken at the beginning of the operation, a truly adequate exposure of the septal elements is obtained.

Fig. 7. Partial Excision of Vomer — Results

	Birth	Vomer excised	External nose	Internal nose	Maxillae
I. M. M.	1947	At 1 yr., at palate repair 1948	Straight	Small spur 1961 No refracture No obstruction	L. Alv. collapse Real prognathism
II. B. T.	1948	At 1 yr., at palate repair 1949	Straight Hump reduced 1961	Small spine No obstruction	Normal limits
III. R. S.	1949	At 1 yr., at palate repair 1950	Straight	Small spur 1962 No obstruction	Recession
IV. J. Q.	1950	At 1 yr., at palate repair 1951	Straight	No spur No obstruction	Slight recession Anodontia
V. J. B.	1955	At 3/12, at lip repair 1955	Straight	No spur Small spine No obstruction	Recession Relative prognathism
VI. R. W.	1959	At 1 yr., at palate repair 1960	Straight	No spur No obstruction	Normal limits
VII. M. B.	1959	At 5/12, at lip repair 1959	Straight	No spur No obstruction	L. Alv. collapse B. G. to notch
VIII. D. A.	1960	At 1 yr., at palate repair 1961	Straight	No spur No obstruction	L. Alv. collapse B. G. to notch failed

There is no evidence of interference with maxillary growth from this age onwards resulting from surgery at this age, although in effect one has removed the spine and maxillary ridge formed by the forward projecting horizontal part of the vomer.

The practice of leaving young children with some nasal obstruction caused by injury or congenital defect until the age of seventeen or eighteen years before treatment is undertaken has nothing to commend it. It appeared to be inspired by the fear that adequate partial resection of the septal cartilage at an early age may result in depression on the lower nasal bridge line or may retard the normal development of the nose as a whole.

As a result the child frequently is allowed to exist in a state of perpetual partial nasal obstruction during his most formative years, that is from eight to eighteen years.

Fig. 8. Partial excision of vomer to show — straight nose — maxillary contour.

Fig. 9. Partial excision of vomer to show — straight nose — maxillary contour.

Fig. 10. Partial excision of vomer to show — straight nose — maxillary contour.

V. PARTIAL REMOVAL OF THE VOMER

Since it was evident that obliquity of the forward antero-posterior portion of the vomer formed the spur and the obstruction, it seemed reasonable to consider that removal of the responsible part of the vomer at an early age would prevent the spur formation and the septal distortion. It was also considered, that since removal of the vomer would be partial and confined to the antero-posterior portion of the vomer, downward and forward maxillary growth due to the vomer might not be affected to any great degree.

Accordingly starting in 1948 part of the vomer has been removed (Fig. 6b) in several of these cases of unilateral cleft of lip and palate. In one case this was done at three months at the time of lip repair, but in the others resection was made at one year at the time of palate repair.

The technique is straight forward. When the vomerine mucosa is turned laterally (to meet and to be sutured to the lateral nasal mucosa to form the nostril floor) the oblique part of the vomer is exposed lying in the cleft of the hard palate. This part of the vomer forms a long narrow triangle with its apex

at the premaxilla. It can easily be divided from the normal half of the hard palate in the midline and removed, thus exposing the inferior border of the septum, which then swings to the midline.

VI. RESULTS (Fig. 7)

Sufficient time has elapsed to report on the eight cases thus treated — the ages range from 5—18 years. Photographs and skull x-rays have been taken to show the external appearance, and development of nose and maxillae.

1. Clinically, in all cases, there is freedom from nasal obstruction. In the untreated cases, nasal obstruction has been the rule.

A small spur has been removed in only two cases (No. 1 & 3 — at 13 years and 14 years).

The spinous process was also removed in one of the above and in two others — only to free the curled inferior border of the septal cartilage.

2. In all cases, the external nasal bridge has been central and symmetrical within normal limits — as opposed to the usual nasal obliquity in those cases where the vomer remains untouched.

Fig. 11. Partial excision of vomer to show — straight nose — maxillary contour.

Fig. 12. Partial excision of vomer to show — straight nose — maxillary contour.

Nasal refracture and straightening have therefore not been required for the external deformity.

3. The effect on the forward and downward growth of the maxillae provides the most important finding.

In three cases (No. 1, 3, 5) there is marked recession of the maxillae. This is as much as occurs in the worst of controls. Maxillary recession does occur in the controls, and must have some genetic origin, but the frequency of occurrence is greater in this small series than in the usual run of cases (Fig. 8, 9, 10, 11, 12).

There is no doubt therefore that partial excision of the vomer at so early an age (1 year) does contribute to maxillary recession.

4. The obvious advantages obtained by excision of the vomer are those of an improved and central nose plus freedom from nasal obstruction. The maxillary recession is too high a price to pay for this, and what has been "gained (Fig. 13, 14) on the swings is lost on the roundabouts".

5. The controls referred to are all those cases similar to that in Fig. 1 — showing nasal obliquity and some degree of nasal obstruction. All of these have required surgery and as far as possible this has been provided from 7 years of age and onward.

VII. DISCUSSION

1. Burston, Kernahan, and Stark discuss the formation of clefts of lip and palate, and observe that maxillary deformity is minimal or absent where the alveolus is not involved. They state that the cartilaginous inter-orbital nasal septum is important in the developing face, and thus is a reason for the facial deformities associated with clefts of lip and palate.

Up to two to three years the nasal septum is enormous, and its growth in this period is responsible for bringing the maxilla downwards and forwards. Failure of attachment of the maxillary segments to the septum robs them of

their growth force, and explains the relative protrusion of the premaxilla in the bilateral cleft of lip and palate, and the deviation in the unilateral case.

Ossification of the septum extends in the first year into the vomer below and the vertical plate of the ethmoid above. Some of the power of growth is thus lost. The anterior cartilaginous portion of the septum grows forward onto the face to form the definitive nose. Subsequent growth of the maxilla is more

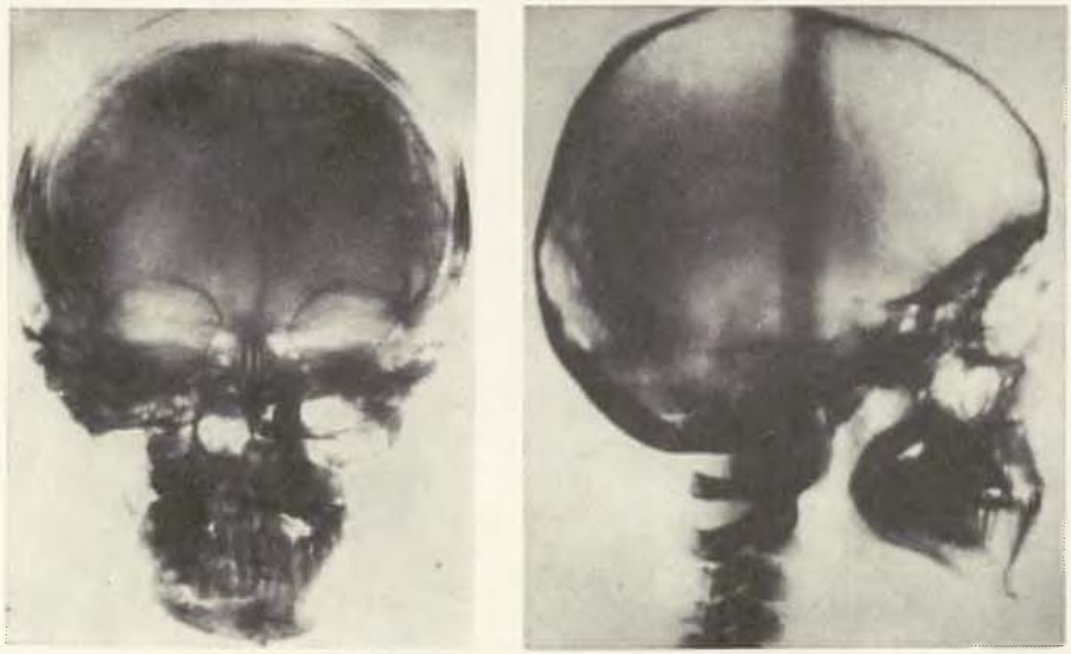

Fig. 13. X-rays B.T. to show maxillae after excision of vomer.

and more by subperiosteal deposition and almost entirely so after seven years of age.

2. There is no doubt that following repair of the unilateral complete cleft of lip and palate, some cases show underdevelopment of maxillae with relative prognathism, and some do not.

Greer Walker and the writer agree that this is a genetic occurrence, and not necessarily the result of surgery. Greer Walker is also of the opinion that while the vomer is important in promoting maxillary growth downwards and forwards, its effect is less marked after the first two years of life.

3. Where the premaxilla and vomer are missing, then maxillary development is deficient, and the palate bones are represented as small ridges in the lateral sides of the nasal cavity close to the base of skull (Fig. 15a).

Underdevelopment of the whole nose is associated with dish face deformity, i.e. agenesis of maxillae (Fig. 15b).

Congenital absence of nose is accompanied by solid maxillae plus dish face deformity (Fig. 15c).

VIII. CONCLUSIONS

The treatment of the secondary deformities (of these cases of unilateral complete cleft of lip and palate) poses certain questions.

1. Since the occurrence of an intranasal spur with nasal obstruction in the unilateral clefts of lip and palate is common, is there any way of preventing it?

Partial removal of the vomer at one year of age does prevent the nasal obstruction, centralises the nose but contributes to the maxillary recession.

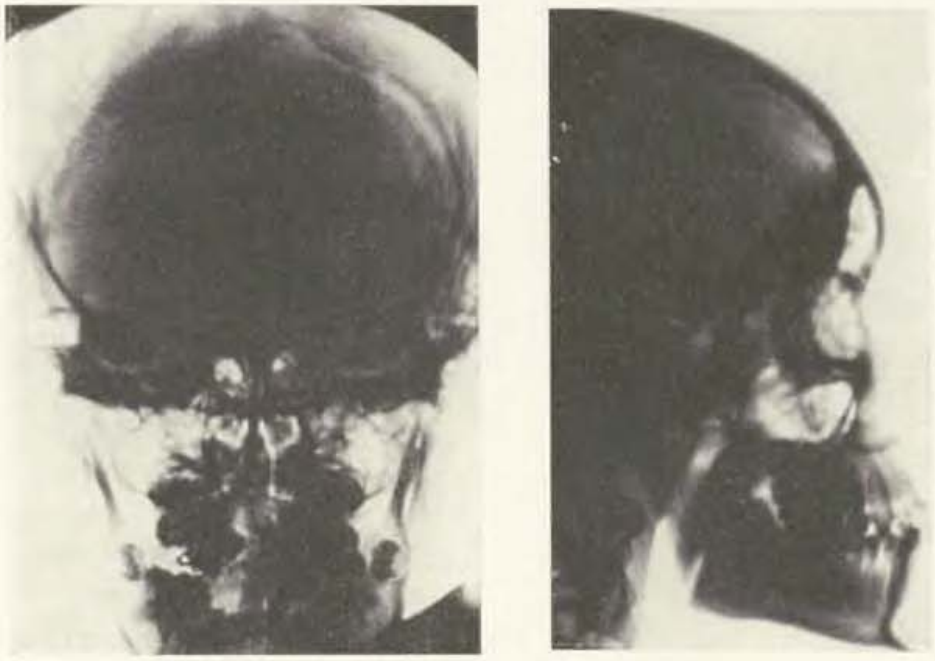

Fig. 14. X-rays J.Q. to show maxillae after excision of vomer.

2. Is there any lack of nasal and/or maxillary development if the intranasal spur is treated (1) in the first year or (2) later at the seventh or eighth years?

a) Treatment in the first year implies partial removal of the vomer as in question 1, and carries with it maxillary recession, but there is no evidence of later nasal underdevelopment.

b) Treatment at the seventh and eighth years is for the purpose of relieving an established (unilateral) nasal obstruction, and of centralising the nose. This requires nasal fracture and straightening plus removal of spinous process and vomerine spur (i.e. maxillary ridge). There is no evidence that additional maxillary under-development follows this.

In some cases, however, the septal cartilage is so distorted that total (rather than partial) S.M.R. is required in order to obtain good nasal airways. This may apply in cases uncomplicated by a cleft of lip and palate.

There is no convincing evidence that there is lack of nasal (Fig. 16, 17) growth, i.e. in the unsupported tip, following this procedure. However, it has

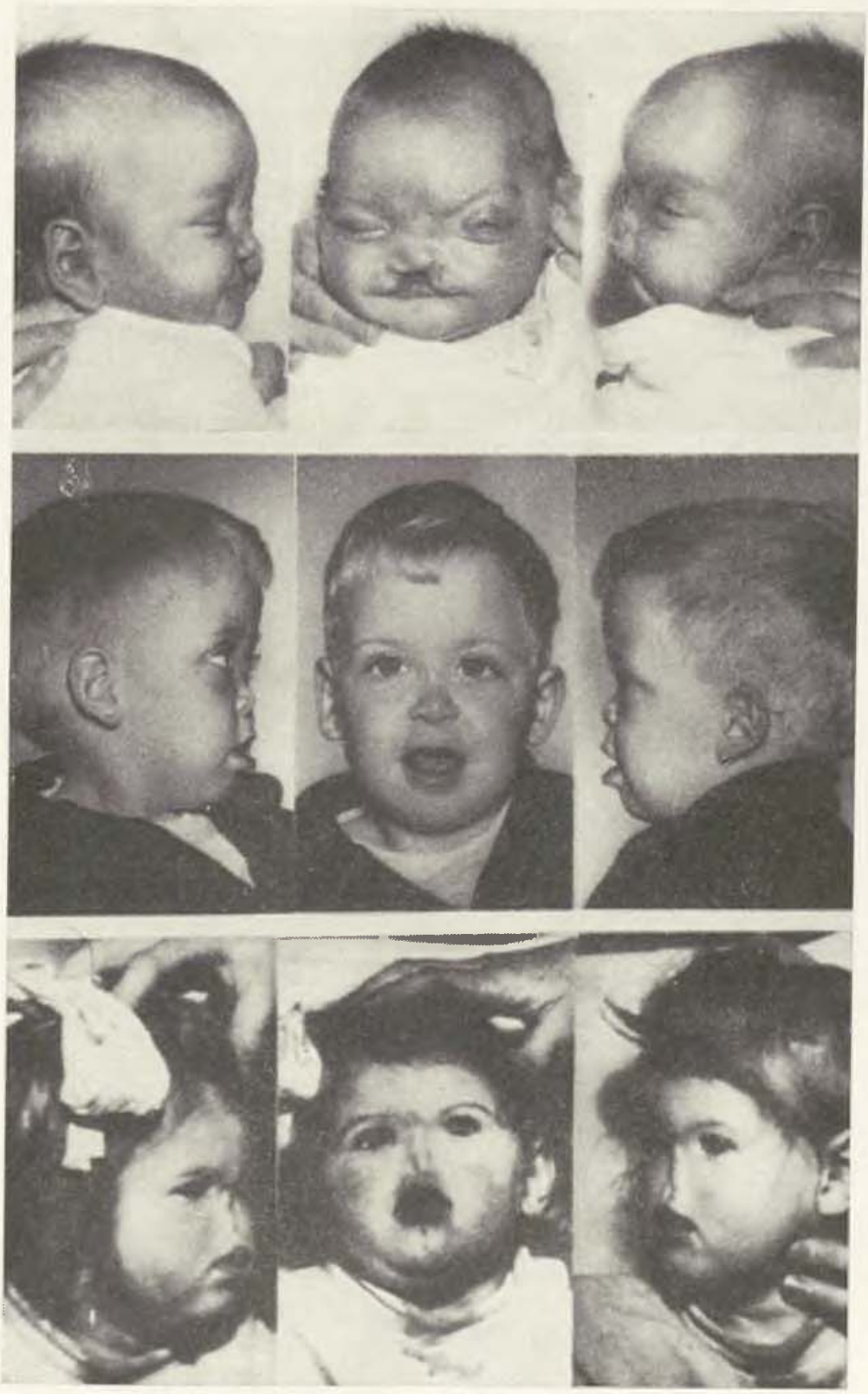

Fig. 15. Congenital nasal deformities and maxillary recession. — a) Absence of premaxilla and septum and vomer + recession. — b) Diminutive nose and recession. — c) Absence of nose — solid maxillae and recession.

been customary to insert temporary intrinsic supports (with the idea of stimulating soft tissue growth) until such time (e.g. at 18 years), when a graft of cartilage or bone is deemed suitable and capable of permanent retention.

The temporary intrinsic supports have included autogenous cartilage or bone dermis; homogenous cartilage or bone, ox cartilage and implants of foreign material, e.g. acridine and teflon.

Fig. 16. X-rays of skull (age 21 years). Total removal of septal cartilage at 8 years.

The writer is not now convinced that a temporary support is necessary for growth of nasal soft tissues, where the septum has been surgically removed from 7—8 years onwards. A support may be indicated from a cosmetic viewpoint, but the number of materials used for this purpose between the ages of 8 and 18 years gives some idea of their unsatisfactory results. The problem of spontaneous absorption of organic materials during adolescence adds to the difficulties.

3. Is there real nasal underdevelopment if the septal cartilage is absent congenitally or removed in very early childhood?

Congenital underdevelopment of the whole median nasal process gives rise to a diminutive nose and recessive middle third of face. This is permanent and may require reconstructive surgery to obtain a balance.

In very young children, two to six years, a septal abscess invariably destroys nearly all the septal cartilage, leaving a thick fibrous septum with depression of the lower bridge and retraction of the columella. The bony bridge is usually broader than normal.

There follows, as a rule, retarded growth of nasal soft tissue, and it is extremely difficult to stimulate growth by inserting an intrinsic support. This may be due to the fact that such cases are usually left for several years before

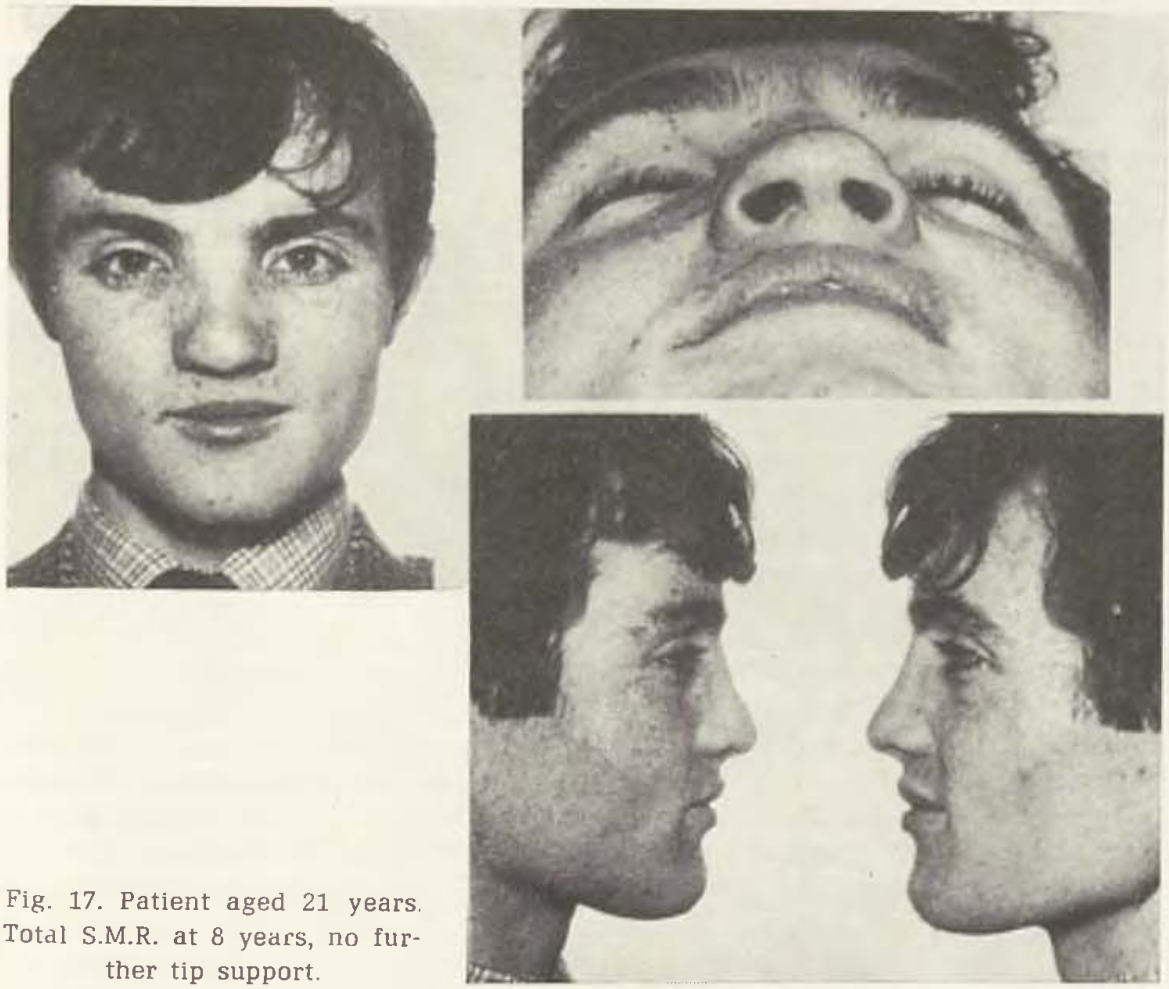

Fig. 17. Patient aged 21 years. Total S.M.R. at 8 years, no further tip support.

treatment is obtained, and due to damage to the whole nasal capsule by the infection.

Finally, it would appear that the vomer is essential for general nasal growth and for downward and forward growth of maxillae up to seven years.

It would also appear that the septal cartilage contributes in the first two to three years to growth of the nasal tip. While early infection and destruction of the septum will retard future growth of the nose, the presence of a grossly distorted but intact septal cartilage appears not to do so, even if left (for 10 years or more) until eighteen years of age. The writer therefore is prepared to apply surgery to the distorted septal cartilage from seven years onwards, in order to obtain good nasal airways, in cases of childhood injury, as well as in those cases of unilateral cleft of lip and palate.

SUMMARY

The typical secondary nasal deformity in the unilateral cleft of lip and palate becomes more apparent at 7—8th year.

There is partial nasal obstruction due to lateral displacement of the inferior border of the nasal septum by the projecting maxillary ridge formed from the

vomer. In the unilateral complete cleft, the forward maxillary part of the vomer is attached to one side only. The abnormal position and the partial maxillary attachment exert abnormal stress on premaxilla and on growth of nasal bony bridge.

Nasal obstruction is frequently present at 7—8 years in cases of repaired unilateral cleft of lip and palate and merits surgery (partial submucous resection and straightening of bony bridge to relieve nasal obstruction).

Since the vomer is responsible for the intranasal obstruction and extranasal deformity, it was considered feasible to attempt "preventive" surgery by partial removal of vomer in the first year.

Six cases have been so treated since 1948; the results and controls are discussed.

RÉSUMÉ

L'excision partiale du vomer à l'âge enfantin

J. P. Reidy

La déformité typique nasale en tant que suite du bec-de-lièvre unilatéral devient la plus apparente à l'âge de 7—8 ans.

Il y a une obstruction partiale due au déplacement latéral du bord inférieur de la cloison nasale tout près de la crête septale. Dans des cas de bec-de-lièvre unilatéral, la partie antérieure maxillaire du vomer ne reste fixé que d'un côté. Grâce à cette position anormale ainsi qu'à la fixation partiale du vomer il y a un stress permanent bien important touchant l'intermaxillaire autant que la formation du pont osseux du nez.

Cette obstruction nasale est très souvent présente à l'âge de 7—8 ans de mêmechez les becs-de-lièvre complèts corrigés et exige l'intervention chirurgicale (résection partiale sous-muqueuse accompagnée de l'écartement du pont osseux pour délivrer l'obstruction). Faute de la responsabilité du vomer en face de l'obstruction et la déformité nasale, l'idée est venue aux auteurs de tâcher «une chirurgie de prévention» tout en supprimant le vomer durant la première année de vie.

Il y a six cas respectifs soignés de sorte depuis 1948; une large discussion des résultats obtenus et des contrôles cliniques vient d'être présentée.

ZUSAMMENFASSUNG

Partielle Exzision des Vomer bei Kleinkindern

J. P. Reidy

Die typische sekundäre Nasendeformität bei einseitiger Lippen- und Gaumenspalte tritt vornehmlich um das 7. bis 8. Lebensjahr in Erscheinung.

Es besteht partielle Obstruktion der Nase infolge der lateralen Verlagerung des unteren Nasenseptumrandes durch einen vorspringenden, vom Vomer gebildeten maxillären Kamm. Bei der einseitigen vollständigen Spaltbildung ist der vordere maxilläre Vomerteil nur an einer Seite fixiert. Die abnormale Lage und die partielle maxilläre Fixierung üben einen abnormalen Einfluss auf die Prämaxilla und das Wachstum der nasalen Knochenbrücke aus.

Nasale Obstruktion besteht häufig um das 7. bis 8. Lebensjahr in Fällen von behandelter einseitiger Lippen- und Gaumenspalte und erfordert einen chirurgischen Ein-

griff (partielle submuköse Resektion und Korrektion der Knochenbrücke zwecks Verminderung der nasalen Obstruktion).

Da das Vomer für die intranasale Obstruktion und die extranasale Deformität verantwortlich ist, hielt der Verfasser den Versuch eines „prophylaktischen" chirurgischen Eingriffs, nämlich der partiellen Entfernung des Vomer im ersten Lebensjahr, für durchführbar.

Seit 1948 wurden auf diese Weise 6 Fälle behandelt; die Ergebnisse und Kontrolluntersuchungen werden erörtert.

RESUMEN

La excisión parcial del vómer en la infancia

J. P. Reidy

La deformidad nasal secundaria típica en la fisura unilateral del labio and paladar se vuelve más prominente en la edad de 7 hasta 8 años.

Hay una obstrucción nasal parcial causada por el desalojamiento del borde inferior del septo nasal por el lomo maxilar saliente desde el vómer. En la fisura completa unilateral, la parte maxilar delantera del vómer está ligada solamente a un lado. La posición anormal y la adhesión maxilar parcial ejercen un esfuerzo anormal sobre el hueso maxilar y sobre el crecimiento del puente osudo nasal.

La obstrucción nasal aparece con frecuencia en la edad de 7 hasta 8 años en los casos de la fisura unilateral reparada del labio y del paladar y merece una intervención quirúrgica (resección submucosa parcial y enderezamiento del puente osudo para aliviar la obstrucción nasal).

Como el vómer está responsable por la obstrucción intranasal y la deformidad extranasal, se consideró posible ensayar una intervención quirúrgica „preventiva" por medio del removimiento del vómer durante el primer año.

Desde hace 1948 seis casos fueron tratados de tal manera; los resultados y controles se discuten en este papel.

REFERENCES

1. **Ritchie, H. B., Staige Davis, J.:** J. Amer. Med. Ass. 2 : 1923, 1922.
2. **Burston, W. R., Kernahan, D. A., Stark, R. B.:** Transactions of International Society of Plastic Surgery. 1959.
3. **Streeter, G. L.:** Contrib. Embryology, Carnegie Institute 31 : 172, 1948.
4. **Keith, A.:** Human Embryology and Morphology (Embryologie a morfologie člověka). Ed. Arnold et Co., London, 6th edition, 1948.
5. **Willis, R. A.:** Borderland of Embryology and Pathology (Hraniční oblasti embryologie a patologie). London 1959.
6. **Greer Walker, D.:** Brit. Dent. J. V 117 : 20, 59, 1964; personal communications 1942—1965.
7. **Littlewood, A. M.:** Plast. reconstr. Surg. May, 27 : 5, 1961.
8. **Stark, R. B.:** Plast. reconstr. Surg. 13 : 20, 1954.
9. **Burston, W. R.:** Ann. roy. Coll. Surg. 25 : 225, 1959.

(J. P. Reidy, F.R.C.S.): 147 Harley St., London W. 1, England

Klinik für Plastische und Wiederherstellende Kiefer- und Gesichtschirurgie Thallwitz, Leipzig (DDR)
Ärztl. Direktor: Prof. Dr. Dr. med. habil. W. Bethmann

BEDEUTUNG UND AUFGABEN DER ANÄSTHESIE IM RAHMEN DER KOMPLEXEN REHABILITATION VON PATIENTEN MIT LIPPEN-KIEFER-GAUMENSEGEL-SPALTEN

W. BETHMANN, H. J. HOCHSTEIN

Die komplexe Rehabilitation der Spaltträger ist bekanntlich nicht die Angelegenheit nur eines bestimmten Lebensalters oder eines bestimmten Fachgebietes allein. Die rehabilitativen Maßnahmen, welche zum Ziele haben, den Patienten optimal in die Gesellschaft einzugliedern und ihn berufsfähig zu machen, müssten zunächst als Grundlage für alle weiteren Maßnahmen die anatomischen Verhältnisse schaffen, auf denen sich die Sprachfunktion, die Kaufunktion usw. aufbauen lässt. Die Eingliederung in die Gesellschaft gelingt umso besser, wenn es möglich ist, die Spalte kosmetisch einwandfrei zu beseitigen, die Ästhetik des Gesichtes durch Wahrung der Harmonie der Gesichtsteile (Entwicklung des Oberkiefermassivs im Vergleich zu den übrigen Gesichtspartien) recht gut wiederherzustellen und den Patienten zu befähigen, sich durch eine Normalsprache mit der Umwelt zu verständigen. Um dies zu erreichen, muss der Spaltträger von der Geburt bis zum Erwachsenenalter medizinisch und pädagogisch behandelt und betreut werden. In medizinischer Hinsicht gehören chirurgische Maßnahmen, Kieferorthopädie, allgemeine Oto-Rhino-Laryngologie, Audiometrie, Phoniatrie, Pädiatrie, Neurologie, evtl. auch Psychiatrie und vor allen Dingen auch die Anästhesiologie zum Gesamtkomplex, während die Pädagogik sich durch die Logopädie einschaltet. Führend in der gesamten Rehabilitation ist die Medizin, weil die Wiederherstellung der normalen Form und Funktion in erster Linie medizinische Probleme sind. Unter den medizinischen Teilgebieten hat der Kiefer- und Gesichtschirurg die Führung, weil er die entsprechenden operativen Maßnahmen durchführen muss, die es erlauben, daß die funktionelle Rehabilitation einsetzen kann.

Der Operateur ist wiederum im besonderen Maße auf die Anästhesiologie angewiesen, denn ohne eine optimale Betäubung, die zugleich Schmerzausschaltung, Senkung des Narkose- und Operationsrisikos und die Möglichkeit des guten und übersichtlichen Arbeitens durch den Operateur gewährleistet, könnte der Letztere sein Können nicht entfalten.

Die Stellung der Anästhesie war auf dem Gebiete der Rehabilitation von Spaltträgern in der Vergangenheit sehr umstritten. Jahrelang hat man über die Vor- und Nachteile der Lokalanästhesie einerseits und der Allgemeinbetäubung andererseits polemisiert. In der Sorge, eine Schädigung des Patienten zu vermeiden, zogen Axhausen, Lindemann, Wassmund und andere die Lokalanästhesie der Narkose in jedem Fall von Operationen bei Lippen-Kiefer-Gaumen-Segel-Spalten vor. Axhausen wurde dadurch auch zu dem vielzitierten Ausspruch veranlasst, „dass eine Lippenplastik unter diesen Umständen zur Nervenstrapaze für den Operateur werden kann, die seine Geduld bis zum Äussersten beansprucht". Andere Autoren operierten Lippenspalten mit Chloroform oder Äther in Form der Tropf- oder Insufflationsnarkose oder auch in Avertin-Rektalnarkose. Rosenthal z. B. hat die Allgemeinbetäubung, soweit es irgend ging, der Lokalanästhesie vorgezogen. Er hat in der von ihm gegründeten Thallwitzer Klinik gern davon berichtet, dass Axhausen anlässlich eines Besuches, den er der Thallwitzer Klinik abstattete, sehr erstaunt darüber war, dass die in Thallwitz operierten Kinder nicht unruhig wurden und schrien, wenn die Ärzte im weissen Mantel kamen. Dies lag nach Rosenthals Berichten vor allen Dingen daran, dass die kleinen Patienten durch die Allgemeinbetäubung vor Schmerzen und vor nachteiligen psychischen Einwirkungen bewahrt geblieben waren.

Die Anwendung von Tropf- oder Insufflationsnarkose oder auch von Rektalnarkosen stellte bei Säuglingen wegen der vielen Nachteile und Gefahren keine ideale Methode dar. Aus diesen Gründen entschieden sich doch wieder viele Chirurgen für die Anwendung der Lokalanästhesie, die sie auch bis heute zum Teil noch pflegen. Die Allgemeinbetäubung kam im grösseren Ausmaße bei Operationen von Gaumenspalten, welche ja erst im etwas vorgerückten Kindesalter durchgeführt werden, zur Anwendung. Dabei war es neben der Rektalnarkose besonders die naso- und oropharyngeale Insufflationsnarkose, die sich jahrelang grosser Beliebtheit erfreute. Dadurch, dass man den Patienten schräg lagerte und am hängenden Kopf operierte, verringerte sich die Gefahr der Aspiration. Trendelenburg hat 1871 zur Verhinderung der Aspiration empfohlen, eine prophylaktische Tracheotomie durchzuführen, wenn man eine Uranoplastik in Narkose vornimmt.

Die Entwicklung der intratrachealen Narkose, die Anwendung neuer Narkosemittel und -techniken und die moderne prä- und postoperative Betreuung und Behandlung eröffnete auch bei Operationen von Lippen-Kiefer-Gaumen-Segel-Spalten eine neue Ära der Anästhesie. Zu diesen Problemen erschienen in den letzten Jahren besonders im anästhesiologischen, chirurgischen und kieferchirurgischen Schrifttum zahlreiche Beiträge nahmhafter Autoren und Kliniken. In der Mehrzahl konnte über gute Erfahrungen bei der Anwendung der intratrachealen Narkose berichtet werden. Diese Narkoseart wird bei Gaumenplastiken auch heute allgemein als die ideale Narkose bezeichnet. Ihre routinemässige Anwendung bei Lippenplastiken jedoch wird von einigen Autoren auch in jüngster Zeit abgelehnt.

Auf Grund der in unserer Klinik gesammelten Erfahrungen bei etwa 8000 Spaltoperationen, davon etwa 3000 Lippenplastiken, sowie auf Grund der Tatsache, dass die Spaltpatienten im Rahmen der komplexen Rehabilitation an unserer Klinik auch kieferorthopädisch, zahnärztlich-konservierend, zahnärztlich-prothetisch, logopädisch und phoniatrisch, pädiatrisch und oto-rhino-laryngologisch behandelt und betreut werden, halten wir es gemäss den eingangs gemachten Darlegungen für angezeigt, die Bedeutung und die Aufgaben der Anästhesie im Rahmen dieser komplexen Rehabilitation zu erörtern. Dabei beschränken sich die Aufgaben der Anästhesie keinesfalls nur auf die Durchführung von Narkosen bei solchen operativen Eingriffen, die dem Verschluss der Lippen-Kiefer-Gaumen-Spalte dienen sollen, sondern es wird unter Umständen auch eine Allgemeinbetäubung in Form einer intratrachealen Narkose für angezeigt gehalten, wenn die „orale Rehabilitation" durchgeführt werden soll. Wir sehen es nämlich immer wieder, dass Spaltträger stomatologisch-konservierend und stomatologisch-prothetisch nur sehr unzureichend versorgt werden, weil der Stomatologe die Behandlung nur zögernd und mit einer gewissen Scheu durchführt, oder weil die Patienten ihr Gebiss aus Angst vor Schmerzen, die bei der stomatologischen Behandlung entstehen könnten, vernachlässigen.

Ein wesentlicher Gesichtspunkt scheint uns die Prämedikation und die Narkoseeinleitung zu sein, obwohl gerade über die Prämedikationen die Diskussionen in Anästhesiologenkreisen noch nicht aufgehört haben, eher in letzter Zeit wieder lauter geworden sind. Wir möchten meinen, dass es notwendig ist, jedes psychische Narkose- und Operationstrauma auszuschalten, um den Kindern die Angst vor der Klinik zu nehmen, denn die Patienten, die schon als Kinder zu uns zur Behandlung und zur Operation kommen, müssen ja auch noch zur kieferorthopädischen oder zahnärztlichen Allgemeinbehandlung, zum Sprachheilunterricht, zu Kontrolluntersuchungen und zu weiteren Operationen in die Klinik kommen. Das psychische Trauma möglichst gering zu halten, ist eine der Aufgaben der Anästhesie. Auch die Nachsorge ist bei den Säuglingen und Kleinkindern mit Lippen-Kiefer-Gaumen-Spalten wegen der erhöhten Gefahr des Auftretens postoperativer und postnarkotischer Komplikationen (Stridor, Pneumonie, Ombrédanne-Syndrom) ein Aufgabenbereich der Anästhesie, der mit besonderer Sorgfalt wahrgenommen werden muss.

Die modernen Narkosetechniken haben es auch ermöglicht, dass die von Säuglingen und Kleinkindern noch tolerierten operativen Eingriffe grösser sein können und mit mehr Zeitaufwand durchgeführt werden können als früher. Es sei hierbei an die primäre und sekundäre Osteoplastik im Bereich der Kieferspalte gedacht, die eine wesentliche Verbesserung der operativen Spaltbehandlung in den letzten Jahren darzustellen scheint. Es scheint so, dass man durch die Osteoplastik eine bessere Stabilität des Kiefers erreicht, und es steht zu erwarten, dass man der so gefürchteten postoperativen Verkrüppelung des Spaltkiefers dadurch bis zu einem gewissen Grade vorbeugen kann. Eine primäre Osteoplastik liesse sich ohne intratracheale Narkose bei einem Säugling kaum durchführen. Erst die Möglichkeit der intratrachealen Narkose hat dazu geführt,

dass sich diese Operationsart, deren Spätergebnisse in kosmetischer, kieferorthopädischer und sprachlicher Hinsicht gut sein dürften, mehr und mehr durchsetzte.

Selbstverständlich gibt es bei der intratrachealen Intubationsnarkose bei Lippen-Kiefer-Gaumen-Segel-Spaltenträgern Probleme, die aus dem Schrifttum bekannt sind und die immer wieder erörtert werden. Es sind dies die besondere anatomische Situation, die Frage, ob man besser pernasal oder peroral intubieren soll, die Lagerung des Patienten, die Tatsache, dass Operateur und Anästhesiologe im gleichen Arbeitsgebiet tätig sein müssen usw.

Mortalität bei Lippen-Kiefer-Gaumen-Spalten-Operationen

Autor	Operationszahl	Mortalität	Zur Anwendung gekommene Anästhesie
Veau — 1931	1 710	2,50 %	Lokalanästhesie, Chloroform, Äther (als Tropf- oder Insufflations-Narkose) Avertin-Rektal-Narkose
Wassmund — 1939	230	3,50 %	
Fogh-Andersen — 1946	1 263	2,70 %	
Ullik/Kölbel — 1946 (1943—1953)	581	3,90 %	
Ullik/Kölbel (1946—1959)	971	1,80	Lokalanästhesie, Äther, Sauerstoff-Lachgas, Relaxation, Intratracheal-Narkose oder Insufflations-Narkose
Burian — 1963	1 752	0,50	
Eigene Ergebnisse (1960 bis Mai 1963)	1 911	0,30 %	Lokalanästhesie, Äther, Sauerstoff-Lachgas, Relaxation, Intratracheal-Narkose oder Insufflations-Narkose
Luhmann — 1956	2 000	0,15 %	
Eigene Ergebnisse (Juni 1963 bis März 1965)	über 1 100	0 %	Lokalanästhesie, Halothan, Intratracheal-Narkose

Zur Frage des anzuwendenden Anästhetikums möchten wir kurz sagen: Wir haben früher in unserer Klinik vorwiegend Äther benutzt. Seit einigen Jahren gebrauchen wir ausschliesslich Halothan AWD bzw. Fluothan in Verbindung mit einem Vaporverdampfer. Dabei intubieren wir im allgemeinen bei erhaltener Spontanatmung oder in kurzfristiger Relaxation. Die Skala der operativen Eingriffe umfasst einfache Lippenplastiken, Lippenplastiken mit primärer Osteoplastik, Veloplastiken nach Veau und nach Schweckendiek, Gaumenplastiken, Uranoplastiken, Hoch- und Rücklagerungen der Gaumenschleimhaut, primäre und sekundäre Gaumen- bzw. Velo-Pharyngoplastiken, sekundäre Osteoplastiken und Korrekturoperationen. Bei Säuglingen und Kleinkindern bedienen wir uns der Nichtrückatmungsventile nach Stephen-Slatter, Leigh und Rubens, bei grösseren Kindern verwenden wir auch das Kreislaufteil nach Oehmig. Bisher haben wir in der Thallwitzer Klinik ca. 900 Narkosen mit Halothan durchgeführt, darunter ca. 750 Halothan-Narkosen bei Spaltoperationen. Diese Narkosen bei Spaltoperationen unterteilen sich 20 % Säuglingsnarkosen (zwischen 4 und 18 Lebensmonaten), 70 % Kindernarkosen (bis zu 12 Lebensjahren) und 10 % Erwachsenennarkosen. Wir werden an anderer Stelle darüber noch ausführlich berichten.

Die wesentlichen Vorteile bei der Anwendung von Halothan sehen wir in seiner sehr guten Steuerbarkeit, d. h. in der Schnelligkeit der Narkoseeinleitung und des Erwachens, in seinem hemmenden Einfluss auf die Speichel- und Bronchialsekretion, in seinem broncho-dilatatorischen Effekt wie auch in der Tatsache, dass das Halothan nicht explosiv und entflammbar ist. Nachteile des Halothans sind in der erhöhten Depression von Atmung und Kreislauf gelegen sowie in der, besonders bei der Operation sehr störenden, Blutungsneigung, zumal eine Anwendung von Adrenalin zur Blutstillung bei Verwendung von Halothan bekanntlich kontraindiziert ist.

Die moderne Narkose hat — wie die bisherigen Ausführungen zeigten — zweifellos ihren festen Platz unter den mannigfaltigen Aufgaben, die bei der komplexen Rehabilitation von Patienten mit Lippen-Kiefer-Gaumen-Segel-Spalten auftreten. Das letzte Kriterium für die Bemühungen der Medizin, besonders auf dem Gebiete der Anästhesiologie und der Operationstechnik usw., ist jedoch die Herabsetzung der Mortalität bei den Operationen. Die sinnvollste Zusammensetzung eines Rehabilitationsteams und die beste Operationsmethodik nützen nichts, wenn eine ungerechtfertigt hohe Mortalität bei oder nach Operationen resultiert. Ein Blick auf die nachstehend angeführte Mortalitätsstatistik der Lippen-Kiefer-Gaumen-Spalten-Operationen zeigt jedoch, dass im allgemeinen trotz einer erheblichen Erweiterung und Vergrösserung der operativen Eingriffe (z. B. primäre Osteoplastik bei Säuglingen oder die in einer Sitzung durchgeführte Velo-Pharyngoplastik mit Bildung beider Nasengänge, Verschluss beider Kieferspalten und sekundäre Osteoplastik vom Beckenkamm) die letalen Ausgänge nach Spaltträgeroperationen oder Narkosen an Zahl erheblich zurückgegangen sind. Der überwiegende Teil aller im Zusammenhang mit einem operativen Eingriff verstorbenen Spaltträger ist wegen Anästhesie-Zwischenfällen ad exitum gekommen. Viele Autoren werten deshalb ihr Krankengut in Abhängigkeit von der jeweiligen Anästhesieform aus.

ZUSAMMENFASSUNG

An der komplexen Rehabilitation von Trägern mit Lippen-Kiefer-Gaumen-Segelspalten hat die moderne Anaesthesie wesentlichen Anteil. Es wird über die Bedeutung und Aufgaben der Anaesthesie, wie sie sich an der Thallwitzer Klinik in den letzten Jahren herausgebildet haben, berichtet. Die Anwendung der intratrachealen Halothan-Narkose und die heutigen prae-, intra- und postoperativen Behandlungsmöglichkeiten brachten eine wesentliche Verbesserung der Operationsbedingungen und ermöglichten eine Erweiterung der operativen Eingriffe bei gleichzeitiger Senkung der intra- und postoperativen Komplikationen, besonders aber der Mortalität, wie ein Vergleich verschiedener Literaturangaben und eine Auswertung des Thallwitzer Patientengutes veranschaulicht.

Abschliessend haben wir den Anästhesiologen der Anästhesie-Abteilung (Leiter: Oberarzt Dr. Hartmann) der Chirurgischen Klinik der Karl-Marx-Universität (Direktor: Prof. Dr. Uebermuth) für ihre gute Zusammenarbeit mit uns zu danken.

SUMMARY

Significance and Role of Anaesthesia in Complex Rehabilitation of Patients with Clefts of Lip, Jaw and Palate

W. Bethmann, H. J. Hochstein

Modern anaesthesia contributes a great deal to the complex rehabilitation of patients with clefts of lip, jaw and soft and hard palate. On the basis of the experience of the Thallwitz University Hospital in recent years, the authors report on the significance and the role of anaesthesia. As can be shown by comparison of the various data in the literature with the evaluation of the Thallwitz group of patients, intratracheal halothane anaesthesia and the modern pre-, intra- and postoperative methods of treatment have brought about considerable improvement of the conditions during operation and made it possible to enlarge the surgery, while intra- and postoperative complications, particularly mortality, decreased at the same time.

RÉSUMÉ

La signification et les devoirs de l'anesthésie en tant que la résuscitation générale des malades soufrants des becs-de-lièvre compliqués

W. Bethmann, H. J. Hochstein

Quand à la résuscitation des malades atteints de bec-de-lièvre compliqué, l'anésthésie moderne en comporte un assez grand partage. Les auteurs décrivent les devoirs et la signification de l'anésthésie dévelopée dans des années dernières à la clinique de Thallwitz. L'ensemble de l'emploi de l'anésthésie endo-trachéale à halothan, des soins augmentés pré, intra et postópératoirs ont fondé des prémisses d'une amélioration fondamentale des résultats opératoirs ainsi que la possibilité d'élargir les interventions chirurgicales avec, en même temps, abaissement du nombre et des sortes diverses des complications, surtout de la mortalité.

Comme preuve, une comparaison entre des diverses données littéraires et l'état général des malades de Thallwitz est présentée.

RESUMEN

El significado y importancia de la anestesia dentro del marco de la rehabilitación compleja de los pacientes con fisuras del labio, mandíbula y paladar

W. Bethmann, H. J. Hochstein

En la rehabilitación compleja de los pacientes con la fisura del labio, mandíbula, del velo y del paladar duro participa considerablemente la anestesia. En este artículo se da cuenta del significado y las tareas de la anestesia, como ésta se ha desarrolado en la clínica de Thallwitz. El empleo de la Halothan-narcosis intra-traqueal y los actuales métodos pre-, intra- y post-operatorios han llevado un mejoramiento esencial de las condiciones y ha hecho posible la extensión las intervenciones operatorias reduciendo al mismo tiempo las complicaciones intra- y post-operatorias, en particular también la mortalidad, lo que muestra la comparación de varios datos en la literatura y los resultados obtenidos a base de la evaluación de los pacientes de Thallwitz.

LITERATUR

1. **Axhausen, G.:** Technik und Ergebnisse der Lippenplastiken. Leipzig 1941.
2. **Axhausen, G.:** Technik und Ergebnisse der Gaumenplastik. Leipzig 1936.
3. **Barth, L.:** Dtsch. Ges. Wes. 19 : 6, 251, 1964.
4. **Barth, L., Meyer, M.:** Moderne Narkose. VEB G. Fischer Verlag, Jena 1962.
5. **Bergmann, H.:** Östr. Z. Stomat. 1 : 3, 113, 1954.
6. **Bergmann, H.:** Anaesthesist 2 : 4, 113, 1953.
7. **Bergmann, H.:** Lehrbuch der Anaesthesiologie. Springer Verlag.
8. **Bertram, H.:** Zbl. Chir. 87 : 7, 291, 1962.
9. **Bethmann, W.:** Dtsch. Stomat. 12 : 5, 341, 1962.
10. **Bethmann, W.:** Dtsch. Stomat. 14 : 9, 645, 1964.
11. **Bethmann, W.:** Dtsch. Stomat. 14 : 794, 1964.
12. **Bethmann, W., Erdenberger, M., Hochstein, H. J., Split, G.:** Zbl. Chir. Im Druck.
13. **Bourne, J.:** Brit. Dent. J. 113 : H 2/54, 1962.
14. **Böckler, H.:** Zbl. Chir. 87 : 1225, 1962.
15. **Bücherl, R.:** Chirurg 33 : 12, 554.
16. **Burian, F.:** Chirurgie der Lippen- und Gaumenspalten. Verlag Volk u. Gesundheit, Berlin 1963.
17. **Czaika, F.:** Zbl. Chir. 86 : 6, 1059, 1961.
18. **Collins, V.:** J. Amer. med. Ass. 172 : 549, 1960 z. n. Musgrave.
19. **Danzinger, A. M.:** Brit. Dent. J. 113 : H/12/426, 1962.
20. **Daplyn, Ph.:** Brit. Med. J. 117 : 1964.
21. **Domaning, E.:** Zbl. Chir. 62 : 2118, 1935.
22. **Drachter, R.:** Zbl. Chir. 41 : 497, 1914.
23. **Ernst, F.:** Kinderärztl. Praxis 5 : 120, 1934.
24. **Evans, F.:** Modern Practice in Anaesthesia. Butterworth und Co. Ltd. London 1949.
25. **Fogh-Andersen, P.:** Acta chir. scand. 94 : 213, 1946.
26. **Forlani, I.:** Dtsch. med. Wschr. 85 : 10, 373, 1960.
27. **Gelbke, H.:** Beitr. klin. Chir. 188 : 406, 1954.
28. **Gelbke, H.:** Med. Klin. 56 : 5, 169, 1961.
29. **Gillespie, N. A.:** Die Endotrachealnarkose. Oppermann Verlag, Hannover.
30. **Gotewood, J. B.:** J. Oral. Surg. 20 : 18, 1962.
31. **Gravenstein, S.:** Anaesthesist 1 : 4, 53, 107, 1952.
32. **Grob, M.:** Lehrbuch der Kinderchirurgie. Stuttgart 1957.
33. **Harder, J.:** Chirurg 29 : 5, 221, 1958.
34. **Hecker, Ch., Henschel, F.:** Chirurg 32 : 500, 1961.
35. **Henschel, W.:** Aesthet. Med. 11 : 236, 1962.
36. **Heiner, H.:** Dtsch. Gesundhws. 12 : 10, 51, 1957.
37. **Hoffer, G.:** Med. Diss. Rostock 1948.
38. **Hochstein, H. J.:** Dtsch. Stomat. Im Druck.
39. **Hunter, H. R.:** Anaesthesist 9 : 5, 62, 1957.
40. **Hutschenreuter, K.:** Dtsch. Stomat. 10 : 12, 912, 1960.
41. **Hutschenreuter, K.:** Anaesthesist 11 : 5, 163, 1962.
42. **Herfert, O.:** Dtsch. Stomat. 4 : 54, 57.
43. **Immenkamp, K.:** Fortschr. d. Kiefer- u. Gesichtschirurgie. Bd. 5, G. Thieme, Stuttgart.
44. **Kirchner, E.:** Anaesthesist 10 : 3, 68, 1961.
45. **Kirschner, M.:** Arch. klin. Chir. 138 : 177, 1925.
46. **Kölbel, H., Ullik, R.:** DZMK 21 : 132, 1954.
47. **Körner, M.:** Anaesthesist 8 : 11, 326, 1959.
48. **Körner, M.:** Anaesthesist 10 : 4, 109, 1961.
49. **Körner, M.:** Chirurg 31 : 131, 1960.
50. **Kronschwitz, H., Mackensen, G.:** Klin. Mbl. Augenheilk. 142 : 4, 681, 1963.
51. **Kronschwitz, H., Passon, V.:** Anaesthesist 11 : 9, 305, 1962.
52. **Kuchner, R.:** Anaesthesist 9 : 3, 96, 1960.

53. **Kuhn, F.**: Zbl. Chir. 28 : 1281, 1901.
54. **Kuhn, F.**: Münch. med. Wschr. 57 : 1948, 1902.
55. **Lange, D.**: DZZ 18 : 22, 1329, 1963.
56. **Lautermann, R.**: Anaesthesist 9 : 3, 100, 1960.
57. **Leigh, M., Kester, H.**: Anaesthesiologie 9 : 33, 1948.
58. **Leigh, M., Belton, M. K.**: Pediatric Anaesthesiology. Macmillen & Co. New York.
59. **Lexer, E.**: Die gesamte Wiederherstellungschirurgie. Leipzig 1931.
60. **Lindemann, A.**: Dtsch. Z. Chir. 68 : 249, 1937.
61. **Loennecken, J.**: Chirurg 24 : 12.
62. **Loskant, G., Hügin, W.**: Anaesthesist 9 : 8, 273.
63. **Lüder, M.**: Dtsch. Gesundhws. 19 : 6, 265, 1964.
64. **Luhmann, K.**: Technik der Operation der Gaumenspalten und Gaumenlippenspalten nebst Ergebnissen. Leipzig 1937.
65. **Luhmann, K.**: Die angeborenen Spaltbildungen des Gesichtes. Leipzig 1956.
66. **Maggio, G.**: Anaesthesist 11 : 3, 75.
67. **Mahaffey, E., Sprous, H.**: Plast. reconstr. Surg. 26 : 596, 1960.
68. **Mayrhofer, O.**: Anaesthesist 9 : 3, 181.
69. **Meissner, F.**: Zbl. Chir. 6 : 1080, 1961.
70. **Meissner, F.**: Persönliche Mitteilung.
71. **Mohr, H.**: Zahnmed. Diss. Greifswald 1925.
72. **Meyer-Burgdorff**: Anaesthesist 2 : 4, 1945.
73. **Mohr, H.**: Med. Diss. Greifswald z. n. Tischer.
74. **Müller, E.**: Dtsch. Stomat. 11 : 13, 841, 1963.
75. **Müller, E., Endres, G.**: Dtsch. Geshws. 19 : 15, 676, 1964.
76. **Musgrave, R., Bremner, C.**: Plast. reconstr. Surg. Vol. 26 : 180, 1960.
77. **Nicole, R.**: Anaesthesist 9 : 3, 183, 1960.
78. **Oech, S.**: Chirurg 25 : 7, 318.
79. **Olfield, M.**: Brit. J. Surg. 46 : 311, 1959.
80. **Pfeifer, H.**: Anaesthesist 6 : 316, 1957.
81. **Pfeifer, H., Schönthal H. u. a.**: Anaesthesist 11 : 5, 160, 1962.
82. **Pfeifer, H.**: Anaesthesist 11 : 5, 160, 1962.
83. **Pfeifer, H.**: Anaesthesist 6 : 5, 317, 1957.
84. **Pflüger, H.**: Anaesthesist 7 : 10, 294; 1958.
85. **Putkonen, T., Pohjola, E.**: Suom hammaslää toim 58 : H 4, 301, 1962.
86. **Rehrmann, A.**: ZR 65 : 2, 27, 1956.
87. **Ressel, G.**: Anaesthesist 5 : 3, 68, 1956.
88. **Ressel, G.**: Lehrbuch der Chirurg. u. Orthop. d. Kindesalters I. B.
89. **Reidy, J.**: Ann. roy. Col. Surg. 23 : 341, 1958.
90. **Ritter, R.**: Allg. u. spezielle chir. Operationslehre. Springer Verlag 1956.
91. **Rose, E.**: Arch. klin. Chir. 17 : 454, 1874.
92. **Rose, E.**: Arch. klin. Chir. 24 : 429, 1879.
93. **Rosenthal, W.**: Kinderärztl. Praxis. Sonderheft 213 : 1933.
94. **Rosenthal, W.**: Spez. Zahn-, Mund- und Kieferchir. Barth Verlag, Leipzig.
95. **Rosenthal, W., Winiker-Blank, E.**: DZZ 11 : 6, 297, 1956.
96. **Salzer, F.**: Zbl. Chir. 13 : 234, 1890.
97. **Scheunemann, H., Stellmach, R.**: Chirurg 29 : 2, 74.
98. **Schmitt, W.**: Allg. Chirurgie. Barth Verlag, Leipzig 1958.
99. **Schmitz, T.**: Anaesthesist 9 : 3, 91, 1960.
100. **Schneider, M., Wiegand, O.**: Dtsch. Geshws. 19 : 27, 1274, 1964.
101. **Schuchardt, K.**: Fortschr. d. Kiefer- u. Gesichtschirurgie. B. 5, G. Thieme Verlag, Stuttgart.
102. **Segmüller, G.**: Anaesthesist 10 : 5, 1922.
103. **Sievers, R.**: Zbl. Chir. 56 : 194, 1929.
104. **Sirekova, H. J.**: Helv. chir. Acta 13 : 397, 1949.
105. **Spiesel, B.**: Fortschr. d. Kiefer- u. Gesichtschirurgie. B. 5, G. Thieme Verlag, Stuttgart.
106. **Stellmach, R.**: DZZ 12 : 274, 1957.
107. **Stellmach, R., Scheunemann, H.**: Fortschr. d. Kiefer- u. Gesichtschirurgie B. 5 G. Thieme Verlag, Stuttgart.

108. **Stein, K., Becker, R.:** Dtsch. Zahnärztbl. 16 : 62, H22, 716.
109. **Stoffregen, J.:** Wiederherstellende plast. Chirurgie B. 1, G. Thieme Verlag, Stuttgart 1963.
110. **Stoffregen, J.:** Anaesthesist 9 : 9, 300.
111. **Stoffregen, J., Buschee, A.:** Anaesthesist 9 : 710.
112. **Struwe, E., Schilli, W.:** Münch. med. Wschr. 105 : 42, 2063, 1963.
113. **Tarrow, B.:** Anaesthesist 10 : 5, 1948.
114. **Thum, H. J.:** Narkosefiebel. G. Thieme Verlag, Stuttgart 1958.
115. **Tischer, W.:** Zbl. Chir. 76 : 3, 508, 1960.
116. **Trauner, R.:** Chir. Operationslehre. Verlag Urban & Schwarzenberg, Wien-Insbruck 1955.
117. **Trauner, R.:** Mund- und Kieferchirurgie. Wien 1948.
118. **Trendelenburg, F.:** Arch. klin. Chir. 12 : 122, 1871.
119. **Trieger, N.:** Oral Surg. 16 : 63, H 1, 31.
120. **Ullik, R.:** Östr. Z. Stomat. 1 : 47, 1950.
121. **Ullik, R.:** Arch. klin. Chir. 285 : 915, 1960.
122. **Veau, V.:** Proc. roy. Soc. Med. (N. Y.) 20 : 1916, 1927, 1926.
123. **Vorphal, H.:** Dtsch. Stomat. 13 : 5, 351, 1963.
124. **Vourrch, G.:** Anaesthesist 7 : 12, 865.
125. **Wagner, A.:** Verhandlungen der Gesellschaft f. Geburtsh. Berlin 1853.
126. **Wassmund, M.:** Lehrbuch der prakt. Chir. d. Mundes u. d. Kiefer. B. 2, Barth Verlag 1939.
127. **Wawersik, J.:** Anaesthesist 13 : 7, 228, 1964.
128. **Weiss, K. H.:** Anaesthesist 11 : 10, 334, 1962.
129. **Wiemers, K.:** Anaesthesist 8 : 6, 167, 1959.
130. **Wiese, H.:** Zbl. Chir. 66 : 1233, 1939.
131. **Wolf, J.:** Hasenscharte R. Anzykl. Leipzig 1896.
132. **Wolfson, R.:** Brit. Dent. J. 112 : H 2, 72, 1962.
133. **Zellner, R.:** DZZ 19 : 1253, 1961.
134. **Zinner, H.:** Östr. Z. Stomat. 58 : 58, 1951.

(Prof. Dr. W. Bethmann): 7251 Thallwitz, Kreis Wurzen, Bezirk Leipzig, DDR

Clinic of Plastic Surgery, Medical Faculty of Hygiene, Charles University, Prague (Czechoslovakia)
Director: Prof. V. Karfík, M. D., D.Sc.

PLASTIC OPERATIONS OF ABDOMINAL WALL

H. PEŠKOVÁ

In most cases it is women who require and request operation on the abdominal wall. The disorder is caused either by slackening of the abdominal wall through repeated pregnancies or the tendency to obesity due to hormonal dysfunction. In men such operations are sometimes indicated after considerable loss of weight.

Less frequently operation of the abdominal wall is required in young women with a thin layer of subcutaneous fat, but whose abdominal wall stretched during pregnancy, particularly if the foetus was large or there were twins or if there was too much amniotic fluid, and no subsequent involution of the skin, fascia and muscle has taken place. The skin stays stretched and puckered around the umbilicus or gathered in the hypogastric region, forming there loose overhanging skin folds. It also does not retract if overstretching has led to striae which represent tears in the connective tissue of the skin while the epidermis has remained intact. These striae are grouped in parallel lines at symmetrical sites, mostly on the sides of the abdomen. They usually run at right angles to the direction of the pull. They are, most probably, caused by tension lasting for a considerable time. According to Trýb, apart from mechanical forces leading to the development of striae, there are also endocrine disorders contributing to fragility of the elastin which, when torn, permits the network of collagenous fibres to be stretched.

Under the puckered skin a dehiscence of various width can be felt between the edges of the loosened recti abdominis and with increased abdominal pressure it becomes visible by the viscera buldging forward through it (Fig. 1, 2). Some women have difficulties in emptying their bowels because they cannot develop enough abdominal pressure. Others complain of unpleasant pressure in the abdomen on wearing a firm suspender belt. Dehiscence of the abdominal muscles has occurred less and less frequently ever since women started to observe a proper regimen of exercises during pregnancy and after delivery, such as was elaborated and introduced to the broad public by modern obstetricians and remedial gymnasts.

Much more often operation is required for deformity and altered contour of the abdominal wall caused by a surplus of subcutaneous fat leading to ptosis.

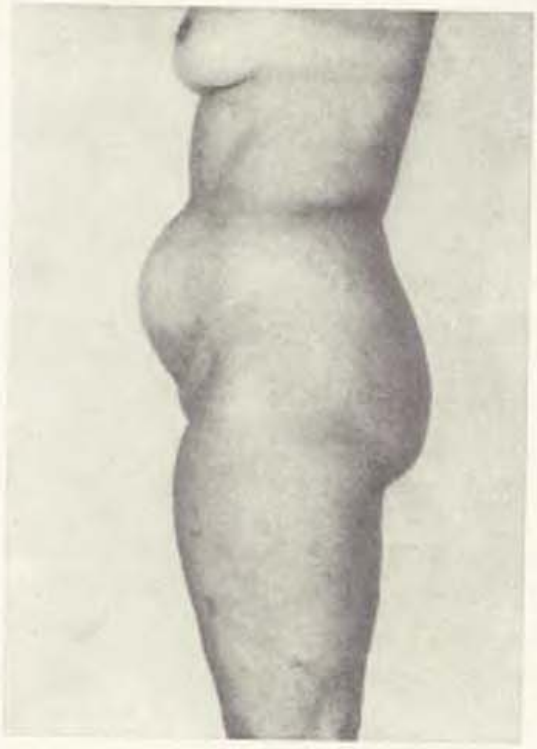

Fig. 1.

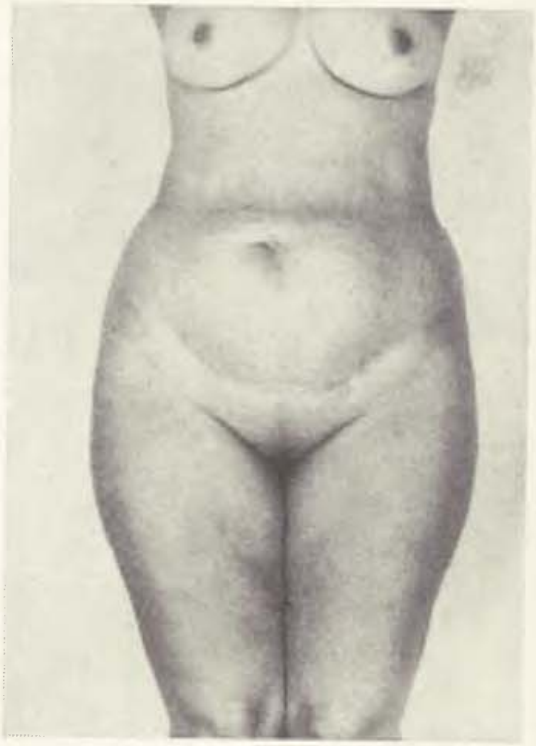

Fig. 2.

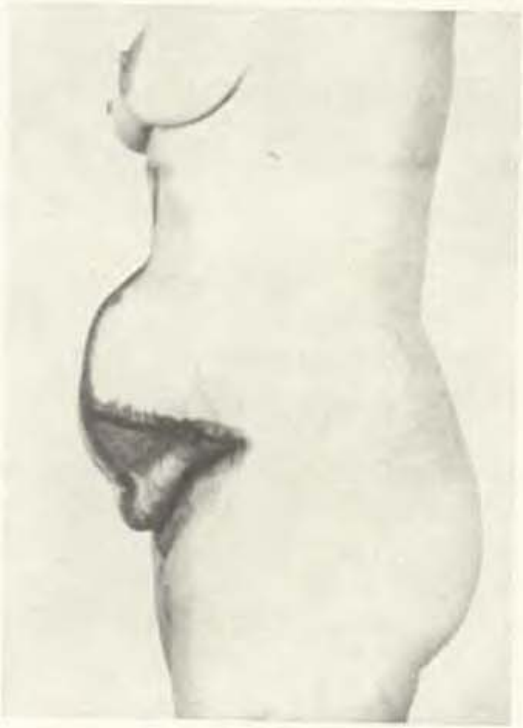

Fig. 3.

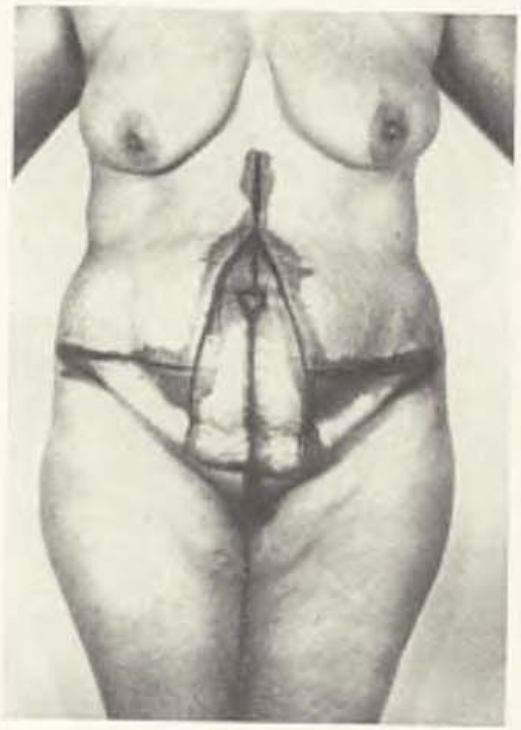

Fig. 4.

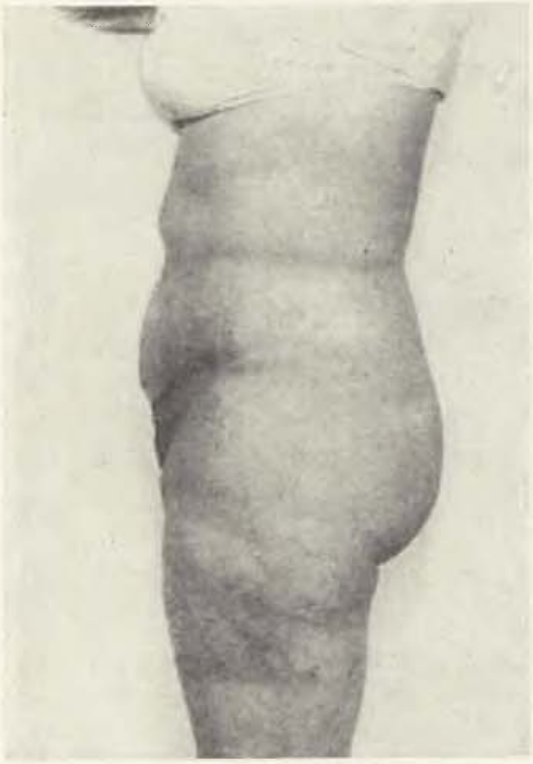

Fig. 5.

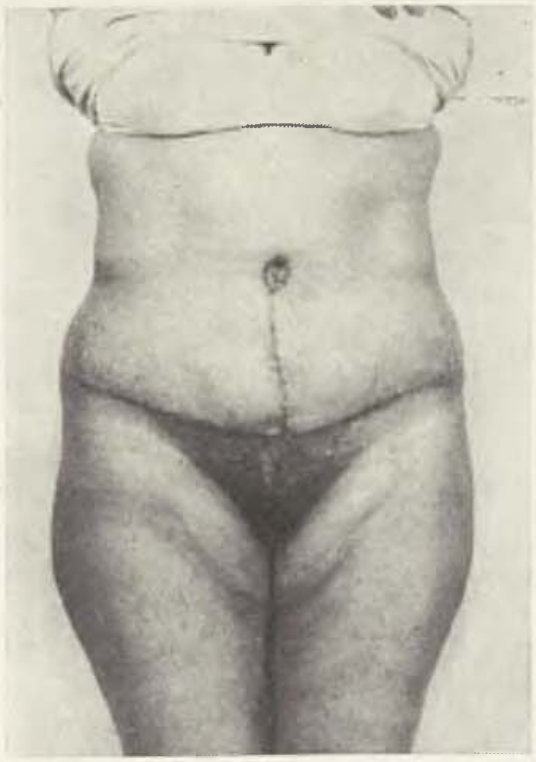

Fig. 6.

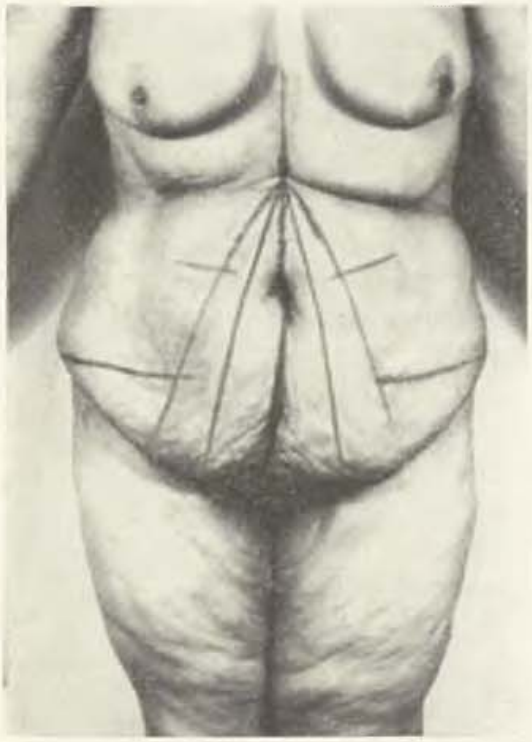

Fig. 7.

Fig. 1 and 2. Protruding abdomen with dehiscence of recti abdominis after three deliveries. — Fig. 3 and 4. Abdomen with wide dehiscence of recti abdominis and ptosis of skin. Preoperative marking. — Fig. 5 and 6. Patient after removal of skin surplus and recti abdominis plasty. — Fig. 7. Preoperative marking with auxilliary lines diverging from xiphoid process downwards.

Hypertrophy of this layer of fatty tissue which, under normal conditions, is symmetrically distributed over the entire body and shapes its contours, develops during pregnancy, but may also be due to endocrine changes, such as take place after the menopause, to some general endocrine and metabolic disorders and frequently also to disproportionate intake of food, particularly too much fat, sugar and other carbohydrates. In these women hypertrophy of fatty tissue is generalized, but fat is deposited most on the abdomen, the breasts, the hips, sometimes the upper parts of the thighs and the gluteal regions. The layer of fatty tissue on the abdomen can reach a depth of six to ten and even more centimetres. It stretches the skin and compresses, stretches and thins out the fascia and muscles. The tissues are pulled down by their weight; in the hypogastric region and on the iliac crests massive folds and mounds are formed. Thus, the clinical picture of venter pendulus develops. In excessive obesity, usually accompanied by large and heavy drooping breasts, transverse mounds are formed over the entire abdomen, the thorax and the thighs thus giving rise to bizarre deformities.

Ptosis of a thick and heavy abdominal wall causes much discomfort and objective disorders. The women suffer from inferiority complexes due to their handicap in leading a normal social and married life, the latter giving rise to deterioration of marriage and psychic alterations. They also have difficulties in maintaining personal hygiene, chosing underwear and clothing, and are excluded from occupations requiring much movement, particularly bending.

The weight of the overhanging abdomen also causes orthostatic syndromes such as low back pain, etc., sometimes accompanied by partial incontinence of urine. Frequently varices develop or get worse and the lower limbs become oedematous. There are respiratory disorders caused by overloading. The skin in the bend of the skin fold becomes intertriginous, the decomposing skin grease gives out a nasty odour and persistent inflammatory changes develop in the leading to eczema and ulcerations. In one of our patients signs of malignancy were found at the site of repeated ulcerations, originating from a constantly irritated pigmented naevus which had become malignant.

In the first group of women with a thin layer of fat and puckering of the loose skin, operation is indicated for cosmetic reasons and also because of the dehiscence caused by parting of the recti abdominis which is a handicap mainly to young sportswomen, gymnasts, dancers, etc. The second group, which is much larger, is comprised of women with ptosis of the heavy abdominal wall who request operation mainly for organic and functional disorders with adverse social and economic effects. In this group there are also surgical indications for the operation, such as removal of surplus fat and skin to facilitate access to herniae, to interabdominal and gynaecological operations, etc.

A properly performed operation of abdominal wall is an exacting surgical procedure which must be carried out with due responsibility. Prior to it the patient must submit to a detailed medical and, if necessary, endocrinological or gynaecological examination. In case of a general disorder, proper therapy must be introduced before operation. In women with general obesity due mainly to

improportionate and incorrect alimentation, it is always advisable to carry out fat reducing treatment under proper medical direction as is done in institutes for human nutrition, by endocrinologists and in some balneotherapeutic establishments. When they have lost weight, these women are not operated on immediately, but after a lapse of a few months when it has become clear that the weight is well stabilized and the patient has got used to the new alimentary regimen. In women thus prepared for operation, surgical treatment proceeds without general or local complications, otherwise so common in cases with a thick layer of fat. These women also have no tendency to recurrence of abdominal ptosis and thus the results achieved by operation are permanent.

Operation is performed under general anaesthesia after proper premedication and emptying of the bowels, and with the strictest observation of asepsis.

Many surgeons are satisfied with excision of the surplus of skin and fat using various incisions the length and direction of which usually being determined by simple lifting up of skin folds between two fingers. The literature refers to several dozens of different types of these excisions.

We do not think this procedure is satisfactory. We consider it necessary to expose the fascia covering the muscles in every case over a large area, to carry out approximation of dehiscent muscles and fasciorraphy, if a hernia is present, to repair and close its ring by plastic operation, and, if need be, to reinforce bulging weak places of the abdominal wall with corium grafts prepared from the excised skin.

Excision of surplus skin must be carried out both in the longitudinal and transverse direction. Only in elderly women, where a large ptosis of the abdominal wall, which has lasted for a considerable period, has led to lengthening of the viscera and an increased intraabdominal pressure, could approximation of the abdominal muscles cause a serious disorder. We, therefore, content ourselves with a horizontal excision of the overhanging parts in the hypogastrium extending to the iliac crest on both sides. This sometimes requires removal of the downward displaced umbilicus. This reduced and less demanding operation is also carried out in patients in whom the physician counterindicated extensive surgical procedure, protracted anaesthesia or postoperative bedrest lasting for several days.

Simple excision of skin plus fat sometimes suffices in young women with a thin layer of fat. The excision is placed at the site where skin folds have developed. Thus puckering of skin round the umbilicus is treated by making one incision round the umbilicus (which is usually not displaced) and then another, long and fusiform in a horizontal direction, widest at the middle and narrowing to both sides of the waist. Meticulous suturing leaves but a thin scar which can well be covered.

If the skin forms folds only in the hypogastrium, a horizontal excision of skin starting just above the mons veneris and extending on both sides to just above the groins, is enough. An inverted T-shaped excision, however, is better in most cases. Prior to the operation a line is drawn with gentian violet on the standing patient precisely in the midline of the hypogastrium and another,

horizontal one just above the mons veneris. It is also advisable to draw a number of auxilliary lines diverging from the umbilicus towards the groins so that they meet the horizontal line below at intervals of 3 to 6 cm. In overstretched, loose and puckered skin this will facilitate symmetrical excision so that the resulting scar will run exactly in the midline of the hypogastrium, where it is least conspicuous. The skin together with the layer of subcutaneous fat is mobilized from the fascia by blunt dissection over the entire extent of the hypogastrium which makes it easy to examine the condition of the recti abdominis. Dehiscent muscles are approximated by firm (but not thick) alternating nylon

Fig. 8.

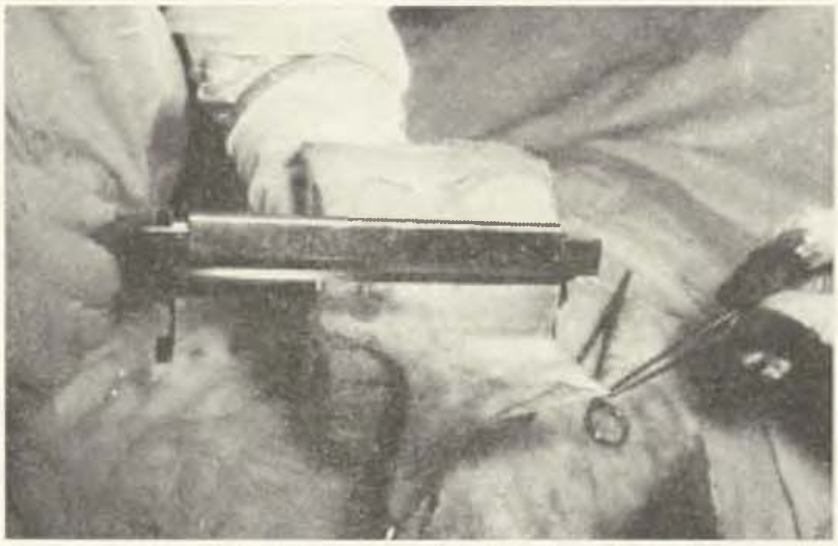

Fig. 9.

Fig. 8 and 9. Lifting of skin graft with dermatome and removal of epidermis on drum of dermatome. The corium graft is used for reinforcement of the weakened fascia.

and catgut sutures, getting their purchase through the covering fascia at the edges of the muscle bellies. The surplus skin is removed vertically from the umbilicus downwards (which also removes the surplus from the sides of the hypogastrium) and horizontally from the incision above the mons veneris (Fig. 3—6). After completion of the suture, the abdomen should be smooth and slightly under the level of the thorax. Usually all, or most of the striae have been removed at the same time.

In the group of patients with a thick layer of fat and a large ptosis, the surgical procedure is similar. It is, however, necessary also to remove the surplus from the epigastrium, otherwise this region protrudes above the diminished hypogastrium. Before the operation, the vertical midline is marked from the xiphoid process down through the umbilicus to the middle of the mons veneris, and a horizontal line just above the hairline of the mons veneris running up in a slight curve towards the iliac spines, but only as far as the end of the overhanging skin folds on both sides. Auxiliary lines facilitating symmetrical excision diverge from the xiphoid process towards the horizontal incision (Fig. 7). A straight horizontal line connecting both iliac crests marks the position to which the umibilicus ought to be replaced.

First the umbilicus is cut around. Then the vertical incision in the middle and the horizontal incision in the groove formed by the overhanging skin fold, are made with a sharp knife right through skin and fat down to the fascia avoiding bruising of the tissues. The skin plus fat is mobilized by blunt dissection in the layer of connective tissue between subcutaneous fat and fascia over the entire front of the abdomen as far as both flanks. During dissection care must be taken to clamp all larger vessels reaching the skin by perforating the fascia, or else they retract under the fascia and may form subfascial or intramuscular haematomas. Haemorrhage is safely controlled by anchored ligatures; only small vessels are coagulated. After folding back the flaps of skin plus fat, the fascia and muscles of the abdominal wall are laid bare over their entire extent (they should be covered with moist towels). In venter pendulus we almost invariably find a wide dehiscence of the recti abdominis along their entire length, from the xiphoid process to the pubic bones. The edges of the muscles are, therefore, brought together by sutures without severing the fascia. If the fascia is stretched and thinned out at the sides, fasciorrhaphy or reinforcement with corium grafts is carried out, the latter being obtained from the excised skin (Fig. 8 and 9). At this stage the patient must be under deep anaesthesia with the abdominal wall well relaxed. After this the skin-plus-fat flaps, which have broad lateral bases, are replaced and shifted medially with a slight pull downwards. Only then is the surplus removed first in a vertical direction starting at the xiphoid process continuing the incisions downwards to the hypogastrium. The excised part on either sides has the shape of a triangle based on the upper edge of the horizontal incision. This completed, horizontal excisions are carried out on either flap to an extent to make the scar, resulting after suture, lie in the flexion groove. This horizontal excision extends laterally, towards the iliac spines, as far as necessary. Making the original horizontal

incision slightly curved upwards prevents gathering of the skin at the sides into ugly cone-shaped protrusions (Fig. 10 to 13). The skin-plus-fat flaps, resulting after these excisions, must be exactly symmetrical and after shifting them to wards the middle and slightly downwards must be anchored to the fascia at exactly symmetrical sites by one or two rows of catgut stitches, or else they tend to slide, pulled by their own weight, towards the sides and put the skin sutures under tension. If they do not lie close to the fascia, cavities form which fill up with serum and tissue fluid. To prevent this a long perforated rubber drain is introduced on either side and led out at the horizontal suture line. Constant suction is applied to these drains for 48 hours following operation. The umbilicus which, at the beginning of the operation, was cut free by a circular incision but left attached to a pedicle of connective tissue and vessels, is raised to a level corresponding to the line connecting both iliac spines and sutured into place by fine, interrupted stitches. A thick layer of fat should be approximated by a few very fine catgut sutures. At the junction of all sutures, just above the centre of the mons veneris, no sutures widely encircling and firmly fastening fatty tissue should be layed, because they may easily lead to necrosis of the tissue, resulting in dehiscence of the skin suture and the development of fat fistulae. After replacement and shifting of the abdominal covers, the wound edges must lie loosely against each other and the suture of fat and skin must be carried out without any tension. The formation of a slight crest at the median suture line is actually of advantage, since it evens out very soon. The transverse suture is started laterally working towards the middle and, at the same time, gathering the tissue of the skin flaps towards the midline. Both the vertical and horizontal skin sutures are carried out with continuous subcutaneous stitches and the edges of epidermis are then exactly approximated by several fine interrupted stitches.

After the completion of the operation and with the patient still under deep anaesthesia the abdominal walls are pulled together by transverse and cross strips of strapping in order to ease the tension which is going to develop in the sutures when the patient comes round from the anaesthesia. For the same purpose a towel is firmly tied around the patient's whole trunk. The operation is performed under antibiotic cover because the fatty tissue, which is — according to Burian — a malicious enemy of the surgeon, is very prone to infection, the more so, since slight bruising cannot be avoided even with the most delicate surgical technique.

After the operation the patient is kept at bed rest for four to five days, but carries out respiratory and limb exercises. The drains are removed after 48 hours and, at that time the skin is inspected for possible irritation caused by the strapping. If this is present, the strapping should be removed immediately. The small approximation stitches are taken out on the fifth day, the subcutaneous stitches on the tenth day. Once the patient gets up, she is advised to wear a firm belt.

Special, rigid belts are considered unnecessary after a properly performed operation.

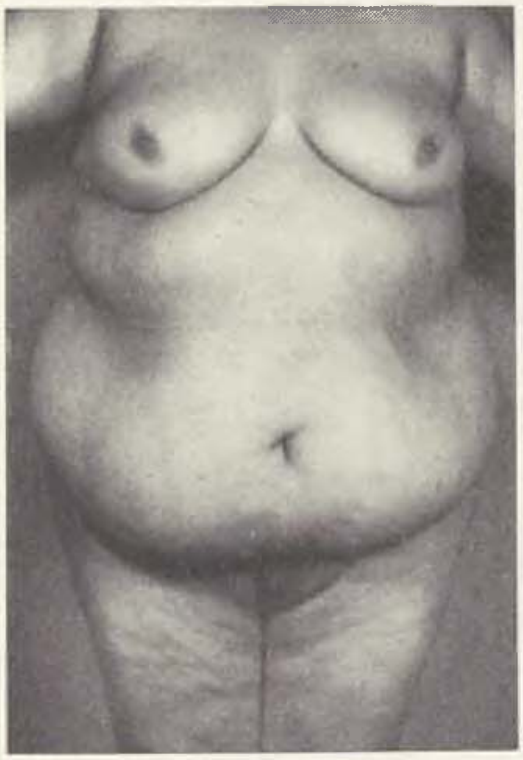

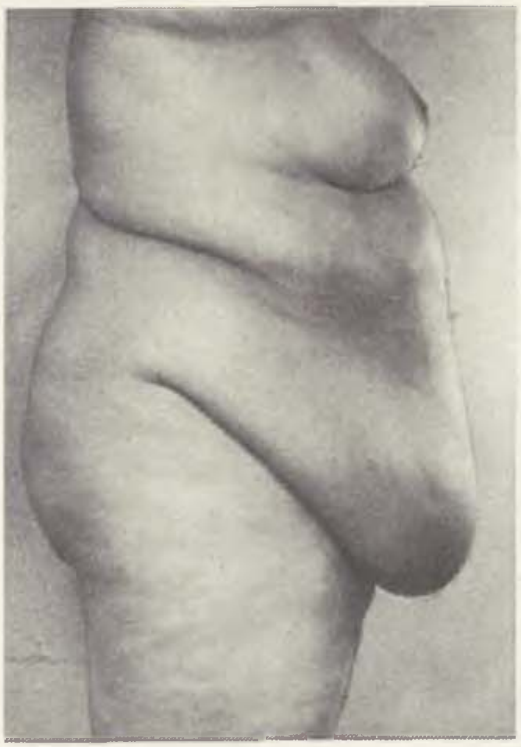

Fig. 10 and 11. Large degree of venter pendulus prior to operation.

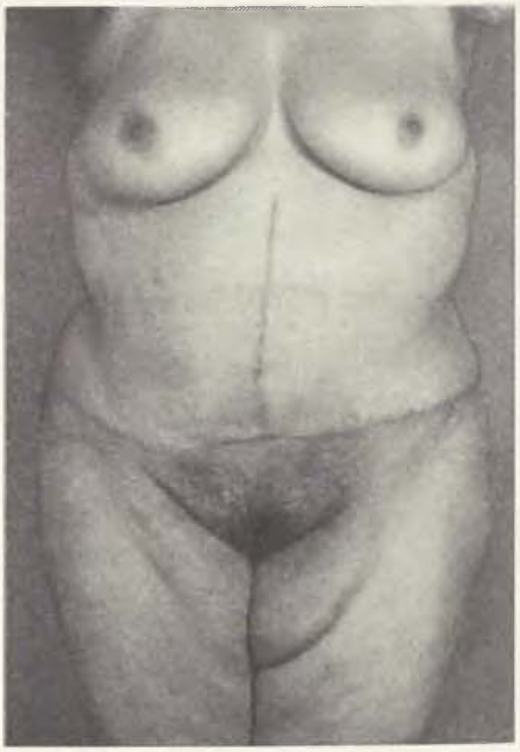

Fig. 12 and 13. Condition after skin-and-fat resection and recti abdominis plasty.

POSTOPERATIVE COMPLICATIONS

General

These are a rare exception provided the patient was properly examined prior to operation, the operation was indicated with due responsibility, and preoperative treatment of the patient and postoperative care were carried out according to all rules and regulations. Since large mobilization of abdominal skin tegumen makes it necessary to keep the patient a few days at bed rest, care must be taken to prevent thrombophlebitis from developing. If varices are present and developed to an extent which would indicate their surgical removal, this should be carried out prior to the abdominal wall operation.

Local

Haematoma of some size may develop, if bleeding has not been controlled meticulously enough, if coming-round from anaesthesia has been violent with vomiting and agitation or if the drains have been removed too early. Dehiscence of the wound is almost invariably caused by tension on the sutures, unless infection is present. The risk of this complication developing can be reduced to a minimum by delicate surgical technique and the strictest observation of asepsis. More often slight and superficial skin dehiscence occurs in the hypogastrium where the three suture lines meet. The skin here has usually been lowered in quality from previous chafing and inflammation. Sloughing of wound edges of the shifted flaps may develop from tension in the suture, from stitches with deep bites and from rough technique and damage to the vessels during operation. Wound dressing must always be carried out under strictest asepsis to avoid contamination of the deeper layers of fat.

An unpleasant complication are fat fistulae which develop after severe bruising of fatty tisue, and may be prevented by careful and delicate surgical technique. If not infected fat fistulae heal quickly.

CONCLUSION

Abdominal wall plasty is a serious operation which must be indicated with due responsibility. Prior to operation the patient must submit to an intensive course of weight reduction treatment, varices should be removed by operation, etc. The plasty should not only consist in the removal of surplus fat and skin, but the recti abdominis should always be approximated and their fascia reinforced. A correctly performed abdominal wall plasty not only brings great relief to the patient, but also satisfaction to the surgeon.

SUMMARY

The surgeon is frequently called upon to perform an abdominal wall plasty. There are two types of disorders which require such operation:

1. Stretching and puckering of skin together with dehiscence of the recti abdominis in young women after twins or a large infant or an excessive amount of amniotic fluid as well as after numerous deliveries.

2. Excessive fat deposits with stretching of muscle and fascia and ptosis of the abdominal wall (venter pendulus).

The author deals with the causes, the clinical picture and the symptoms caused by the disorder which constitute the indication for operation. She stresses the necessity for preoperative treatment of obesity, surgical treatment of varices, the treatment of general, metabolic disorders, etc.

Apart from removal of surplus fat and skin, operation must include repair of the recti abdominis dehiscence and, if necessary, also reinforcement of their fascia. Excision is best performed in the shape of an inverted T. The umbilicus must be transposed to its proper level. In the second group tissue reduction must extend to the epigastrium up to the xiphoid process. Mobilization of the skin-and-fat cover must be carried out over the entire surface of the abdomen and the replaced flaps must be shifted medially and downwards. Then the surplus can be removed and the flaps anchored to the fascia by two rows of stitches through fat. The suture must not show any tension.

The usual complications after abdominal wall plasty are dealt with.

RÉSUMÉ

Les plasties de la paroi abdominale

H. Pešková

Les plasties de la paroi abdominale constituent une partie bien importante de la tâche du chirurgien. Les componentes des défauts à corriger sont surtout:

1. La peau trop étendue et plissée, accompagnée de myocele du muscle grand droit antérieur de l'abdomen, en tant que suite de l'accouchement des jumeaux, d'un foetus beaucoup trop grand, de surplus de liquide amniotique et, finalement, des accouchements répétés;

2. Une couche trop épaisse de la graisse sous-cutanée suivie de l'affaiblissement des muscles et des fascies, dont l'abaissement de la paroi abdominale — le dit ventre en besace — est la suite.

L'auteur présente le tableau des causes, des signes de clinique et des plaintes du malade qui constituent l'indication de l'intervention. Il souligne la nécessité des préparatifs préopératoires au moment où le chirurgien se trouve en face des obésites, varices, des défauts du métabolisme généraux etc.

L'intervention a pour but de corriger non pas seulement la myocèle elle-même, en la fermant à l'aide du dédoublement par la fascie, mais, de même, elle doit débarasser le malade de la graisse et de la peau superflue. La plus efficace, pour ce but, est l'excision du surplus en forme d'un T en revers. Le nombril doit être à tout prix remis à sa place originale, au cas de la couche trop épaisse de la graisse sous-cutanée, il est nécessaire d'entreprendre la réduction tissulaire dans la région épigastrique d'abord, en allant jusqu' au niveau de l'appendice xiphoide. En tout cas, il faut soulever les tissus moux en toute étendue et placer les lambeaux médialement et en bas, les débarasser de tout surplus et les fixer par un à deux rangs des points de la graisse à la fascie, sans que la sutture approuve la moindre traction. Complications.

ZUSAMMENFASSUNG

Plastische Operationen der Bauchwand

H. Pešková

Plastische Operationen der Bauchwand stellen eine häufige Aufgabe des Chirurgen dar. Die zugrunde liegenden Störungen gehören zweierlei Typen an:

1. Erschlaffen und Faltenbildung der Haut mit Diastase der Musculi recti abdominales bei jüngeren Frauen nach der Entbindung von Zwillingen oder grossen Neugeborenen, nach grossen Mengen von Fruchtwasser sowie nach wiederholten Entbindungen.

2. Übermässige Fettablagerung mit Erschlaffen von Muskeln und Faszien und Absinken der Bauchwand (venter pendulus).

Die Verfasserin erörtert Ursache, klinisches Bild und die durch die Störung bedingten Beschwerden, die eine Indikation zur Operation bilden. Ferner wird die Notwendigkeit der präoperativen Vorbereitung bei Fettleibigkeit, Krampfadern, Störungen des Metabolismus und ähnlichem hervorgehoben.

Die operative Behandlung muss stets einerseits die Diastase der Muskeln durch ihr Vernähen, beziehungsweise durch Festigung der Faszie korrigieren, andererseits überflüssige Haut und Fett entfernen. Am vorteilhaftesten ist die Exzision in Form eines umgekehrten T. Der Nabel muss in die richtige Höhe verlagert werden; bei der zweiten Gruppe besteht die Notwendigkeit, das Fettgewebe auch im Oberbauch bis zum Processus xiphoides zu reduzieren. Die Hebung der weichen Gewebe muss im Bereich des ganzen Bauchs durchgeführt werden, die abgehobenen Lappen sind medial und kaudal zu verlagern, wo sie nach entsprechender Reduktion mit 1 bis 2 Stichreihen an die Faszie fixiert werden; die Naht darf nicht unter Zugwirkung stehen.

Sodann werden die Komplikationen besprochen.

RESUMEN

Las operaciones plásticas de la pared abdominal

H. Pešková

Las operaciones plásticas de la pared abdominal son una tarea frecuente del cirujano.

Los defectos son de dos tipos:

1. La tracción y arrugamiento de la piel con la separación de los músculos rectos abdominales en las mujeres jóvenes, después del parto de gemelos, de un gran parto, de gran cantidad de líquido amniótico y después de repetidos partos.

2. Una excesiva acumulación de grasa con una tracción de los músculos y las fascias y con el descenso de la pared abdominal (venter pendulus).

Se explican las causas, el cuadro clínico y las dificultades provocadas por el defecto, las cuales son una indicación para la operación. Se recalca la necesidad de los preparativos pre-operatorios en la obesidad, várices, en los trastornos generales del metabolísmo, etc.

El tratamiento operatorio debe siempre corregir, tanto la separación de los músculos, su costura, respectivamente el fortalecimiento de la fascia, como eliminar el exceso de piel y de grasa. Lo más ventajoso es la excisión en forma de T invertida. Es necesario colocar el ombligo a la altura correcta, en el segundo grupo es necesario

reducir el tejido también en el epigastrio hasta llegar al proc. xifoideos. El levantamiento de los tejidos blandos se debe realizar alcanzando a todo el vientre y los lóbulos separados, llevarlos hacia el centro y hacia abajo, eliminar el exceso y fijarlos en 1—2 filas de puntos de la grasa hacia la fascia, la sutura no debe estar bajo presión Complicaciones.

REFERENCES

1. **Bernson, M. J.**: Atlas of Plastic Surgery. Grune and Stratton, N. Y. 1948.
2. **Burian, F.**: Plastická chirurgie. ČSAV, Prague 1959.
3. **Correa, Iturraspe M.**: Rev. ass. méd. argent. 66 : 340, 1952.
4. **Foget, J.**: Brit. J. Plast. Surg. 1 : 274, 1949.
5. **Fomon, S.**: Cosmetic Surgery, Principles and Practice. Lippincot Comp., USA 1960.
6. **Gillies, H., Millard, R.**: The Principles and Art of Plastic Surgery, Little Brown and Comp., Boston 1957.
7. **Kelly, H. A.**: Surg. Gynec. Obstet. 10 : 229, 1910.
8. **Krenar, J.**: Acta chir. orthop. traum. čechosl. 6 : 498, 1963.
9. **Krenar, J., Havlásek, L.**: Čs. Gynek. 5 : 360, 1964.
10. **Krenar, J.**: Acta chir. orthop. traum. čechosl. 6, , 1965.
11. **Labry, R., Durous, P. E.**: Lyon chir., 46 : 230, 1956.
12. **Malbec, E. F.**: Prensa méd. argent. 35—1251, 1948.
13. **Moor, H. G. Jr., Harkins, H. N.**: Surgery 34—728, 1953.
14. **Talamas Vasquez, J.**: Prensa méd. mex., 11 : 69, 1946.
15. **Thorek, M.**: Plastic Surgery of the Breast and Abdominal Wall. Springfield, Thomas 1942.
16. **Vernon, S.**: Amer. J. Surg. 94 : 490, 1957.
17. **Wells, H. G.**: J. Amer. Med. Ass. 114 : 2177, 1940.

(Doc. H. Pešková, DrSc.): Šrobárova 50, Praha 10, Czechoslovakia

Scientific Research Institute of Traumatology and Orthopaedics of the Ministry of Health of the Georgian Soviet Socialist Republic, Tbilisi (USSR)
Director: B. Sh. Tsereteli, D. M. Sc.

TRANSPLANTATION OF HOMO- AND HETEROGENOUS TENDON STORED IN MEDA SOLUTION*)

M. V. MSHVIDOBADZE

Success in the plastic repair of tendons greatly depends on the kind of plastic material used and its manner of preservation.

For this purpose we made 193 experiments in 100 animals (rabbits and dogs) with bridging a 1 cm. artificial gap in the tendo Achillis with homo- and heterogenous tendon stored in MEDA solution (Mellis — 50.0 g, 0.5% solution of glucose — 40.0 g, 10% calcium chloride solution —9.0 g and sodium chloride — 1.0 g). Autotransplantations served as controls.

Both, catgut and fine thread (No. 1) made of homo- and heterogenous tendon fibres and stored in MEDA solution, were used as suture material.

The observation of the function of the limb and the study of the morphological changes in the transplants and of the processes of regeneration with regard to re-innervation of the regenerated tissue at intervals of between three days and one year after operation, enabled us to detect certain regularities in these processes.

Three days after auto-, homo- or heterotransplantation of tendon, although the skin has almost healed, function of the limb is absent. [The transplants were firmly fixed to the stump ends of the severed tendon with tendon thread and catgut.] Homo- or heterotransplants are of a dull colour, autotransplants show a silvery lustre. Under the microscope, homo- and heterotransplants show homogenization, their collagenous fibres are swollen, the tendon cells disintegrated and the nervous elements destroyed. In the controls, the structure of the autotransplant has been well preserved.

The stump ends of the severed tendon, too, undergo changes; the collagenous fibres become undulated and in some parts homogenized, and the tendon cells do not take the stain. Parallel with the dystrophic and destructive processes, phenomena of regeneration, such as mitotic and amitotic cell division in the endo- and peritendineum and the paratenon, and early invasion of single cells into the transplant, can be observed. Nerve fibres show reactive changes.

*) Paper read at the Fourteenth International Surgical Congress in Bratislava, Czechoslovakia, on June 30, 1965.

Round the tendon threads there is but moderate cell proliferation, but around the catgut stitches an intensive round-cell reaction can be noted.

Seven to ten days after auto-, homo- or heterotransplantation of tendon, function of the limb is limited, but the skin wound has healed by first intention. Both the transplant and the stump ends of the severed tendon, are covered with a layer of granulation tissue rich in newly formed cells and blood vessels. The homo- and heterotransplants are homogenized and void of cells. In the autotransplants the remainig cells still preserve their capacity for being stained.

In the stump ends of the severed tendon the collagenous fibres are swollen having lost their clear contours and the remaining cells do not stain. The cells of the endo- and peritendineum and the paratenon have increased in number together with little differentiated tendon cells. The newly formed cells and blood vessels are invading the transplant from without.

In the proximal stump of the tendo Achillis, thin, naked coils of newly formed nerve fibres can be seen.

In the suture, the knots of both the tendon threads and catgut, hold firm. Granulation tissue has developed around the stitch canal of the tendon thread suture (Fig. 1) and round the catgut stitches, round-cell infiltration.

Twelve to twenty days after auto-, homo- or heterotransplantation of tendon, function of the operated limb has recovered. The newly formed tissue surrounding the transplant consists of fine collagenous fibres running longitudinally and between them there are numerous newly formed cells of a fibroblast character. Here, too, naked, fine axon cylinders are invading the regenerated tissue.

The collagenous fibres of the newly formed tissue around and autogenous tendon graft are distributed quite regularly; in the interstitial spaces cells with elongated fibres predominate. On the twelfth day, fine, non-myelinated nerve fibres make their appearance. The structure of an autogenous tendon graft is better preserved than that of homo- or heterogenous grafts. The latter are homogenized and fragmented and are in the process of being absorbed.

Nerve fibres invade the regenerated tissue 14 to 15 days after homo- or heterotransplantation.

The tendon threads become flayed and their cells disintegrate. The walls of the stitch canal are lined with regenerated tissue of a tendinous character (Fig. 2). The catgut thread is swollen and fragmented and around it granulation tissue has formed (Fig. 3).

Four to six weeks after operation, the greater part of a homo- or heterotransplant has undergone dissolution. The newly formed tendon tissue is rich in cells of a fibroblast character showing mitotic and amitotic division and lying between longitudinally running collagenous fibres. The regenerated structure is richly supplied with vessels of capillary, arteriolar and venular type. Numerous nerve fibres form a network and end both in the collagenous fibres and the cells of the tendon (Fig. 4). In the regenerated tissue the nerve fibres take irregular and undulated courses.

The stump ends of the severed tendon, too, are pervaded by young tendinous tissue and the border between the stumps and the regenerated structure can no longer be distinguished.

In the controls, i.e. after autotransplantation, collagenous bundles of the regenerated structure run in more regular directions and the tendon cells lying in the interstitial spaces have a more mature appearance.

Both the tendon fibre and catgut threads have been absorbed. Young tendinous tissue has developed along the entire tendon fibre thread but the tissue

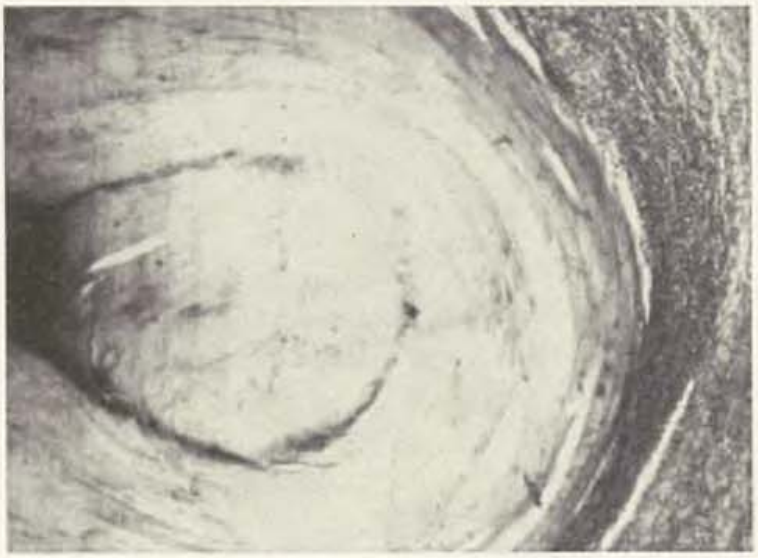

Fig. 1. Ten days after heterotransplantation of tendon: Granulation tissue has developed round the homogenized tendon thread. (Stained with haematoxylin-eosin, magnified 90×.)

Fig. 2. Twenty days after homotransplantation of tendon: The tendon thread is flayed and void of cells. Around it tissue of a tendinous character has developed. (Stained with haematoxylin-eosin, magnified 90×.)

filling the stitch canals of the absorbed catgut sutures differs from the adjacent regenerated structure by its cells being less mature.

Two to three months after auto-, homo- or heterotransplantation a continuous and mobile tendon has formed (Fig. 5), and the defect has been filled with young tendinous tissue. The collagenous fibres form bundles of the first and second order and between them there are regularly distributed tendon cells with rod-shaped nuclei. In most cases of homo- or heterotransplantation the grafts have been replaced by regenerated tendinous tissue. Areas of acellular

Fig. 3. Twenty days after autotransplantation of tendon: The catgut thread is swollen and fragmented and around it granulation tissue has developed. (Stained with haematoxylin-eosin, magnified 90×.)

Fig. 4. Regenerated nerve fibres contact the newly formed tendon cells and collagenous fibres 6 weeks after homotransplantation of tendon. (Impregnated by the method of Bilshovsky and Gross counterstained with haematoxylin-eosin, magnified 240×.)

tissue can particularly be found after autotransplantation and the tissue replacing the autotransplant is slightly more mature than that in place of homo- or heterotransplants. In all these types of tenoplasty the regenerated structures show various stages of maturity; collagenous fibres running parallel with mature tendon cells lying between them alternate with less mature areas showing abundant cell elements and without strictly parallel collagenous fibres.

At that time the number of blood vessels has diminished in the regenerated structures of all types of tenoplasty: Regenerated, richly proliferated nerve fibres form both bundles of tiny nerve trunks and networks. The nerve fibres with simple or complicated, encapsulated endings are regularly distributed along the collagenous fibres, particularly in the endo- and peritendineum.

Later, four to twelve months after operation, further differentiation of the regenerated tendon takes place. At this stage there is no difference between auto-, homo- or heterotransplants. The tendinous tissue filling the defect differs from mature tendon only by the absence of the silvery lustre and the various shapes and sizes of its tendon cells (Fig. 6).

Thus, with the employment of homo- or heterogenous tendon grafts stored in MEDA solution for the bridging of a defect in a tendon — in the same way as in using autotransplants — the continuity of the organ was reconstructed and in this way function of the limb was restored. Then, under the influence of function, further differentiation of the regenerated tendinous structure takes place.

Since 1961, homo- and heterogenous tendon grafts stored in MEDA solution have been used in the hospitals of the Tbilisi Scientific Research Institute of Traumatology and Orthopaedics for tenodesis and the narrowing of the transverse vault of the foot (in foot deformities of various types and origin), the reconstruction of the ligamentous apparatus of the knee joint, the patella and the flexor and extensor tendons of the wrist and fingers. (A total of 29 cases.)

The grafts were stored from 16 days to 18 months.

Check-up of late results (up to 3 years) showed reconstruction of the organ and restoration of its function except in four cases of tenoplasty of finger flexor tendons due to accretion of the transplant with the overlying skin. In these cases function has not improved at all.

Suture material made of homo- and heterogenous tendons stored in MEDA solution was also used in our department for the suture of skin, subcutaneous fascia and muscle (10 cases). All wounds healed by first intention after five to six days. A fine scar developed which after ten days was quite indiscernible.

On the basis of experimental and clinical experience, we assume that with tenoplasty using homo- or heterogenous tendon grafts stored in MEDA solution as well as autotransplants, continuity of the tendons and function of the limb can be restored.

Comparative evaluation of the results of hetero-, homo- (stored in Meda solution) and auto- (fresh) transplantation of tendon grafts showed that the reparative processes proceed in the same manner in all these types of tenoplasty. The transplants undergo disintegration and absorption, and are replaced

by regenerated tendon tissue which is both morphologically and functionally of full value. These processes start in the first days after transplantation and are essentially concluded by the second or third month. Transformation of the regenerated tendon, however, continues even after one year.

After autotransplantation the structure of the graft is preserved for a longer period and the tissue replacing it later, shows a more distinct degree of maturity earlier than after homo- or heterotransplantation.

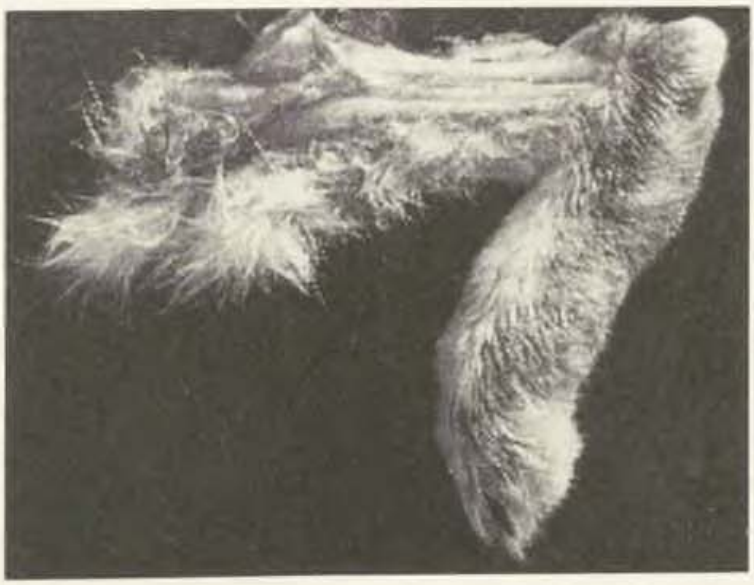

Fig. 5. Three months after heterotransplantation of tendon: A continuous and mobile tendo Achillis has developed.

Fig. 6. Twelve months after homotransplantation of tendon: The regenerated tendinous tissue is rich in various cell elements. (Stained with haematoxylin-eosin, magnified 90×.)

The source of regeneration are the cambium cells of the endo- and peritendineum and the paratenon as well as little differentiated tendon cells (fibroblasts) in the stump ends of the severed tendon.

In the very first days after operation signs of regeneration can be detected in the nerve elements starting in the proximal tendon stump and thence spreading over the entire regenerated part. After hetero- or homotransplantation of tendon, regeneration of nerve elements is well developed by the fifteenth day, after autotransplantation already by the twelfth day.

In all these types of tenoplasty there is a definite correlation between the formation of the regenerated structure and its innervation. In the first two or three months after transplantation, the nerve elements respond to the abundant regeneration of tendinous tissue by massive proliferation. By the third month composition and individual differentiation of nerve elements are, on the whole, completed as seen by their regular distribution and complicated structure (myelinization of nerve fibres, formation of nerve bundles and trunks, complex and encapsulated endings, etc.). Differentiation of nerve elements precedes that of the stroma (collagenous fibres and tendon cells) and promotes further maturation of the tendinous tissue.

Judging by its morphological characteristics, innervation of the regenerated tendon is mature and typical after the transplantation of hetero- or homogenous tendon grafts stored in MEDA solution as well as of fresh autogenous grafts, which seems a reliable proof of the tendinous nature of the regenerated structure in all these types of tenoplasty.

Comparison of the reactive changes and the character of regeneration taking place in tendinous tissue after using catgut or tendon thread stored in MEDA solution as suture material, showed that tendon thread is superior to catgut. It can also be used for suturing skin, fascia or muscle; it is a firm, biological and easily procurable suture material, does not cause much irritation in the tendon and thereby slowing down the formation of mature tendinous tissue in the regenerated part as can be seen on using catgut. Tendon threads stored in MEDA solution are absorbed within four to six weeks.

Analysis of the results of the clinical material has shown that Meda stored heterogenous tendons can be used in the repair of foot deformities of various types and origin, for tenodesis and narrowing of the transverse vault, for plastic reconstruction of the ligamentum patellae and the ligaments of the knee joint and for tenoplasty of the extensor tendons of the wrist and fingers.

SUMMARY

On the basis of the findings of both experimental (193 trials) and clinical (29 cases) observations of the transplantation of homo- and heterogenous tendon grafts stored in a 50% MEDA solution, the author comes to the conclusion that a tendon defect thus bridged is eventually filled with a regenerated structure of complete tendinous character, which is borne out by the fact that a typical and mature nervous system has developed in it.

The author is convinced that autotransplants of tendon can be replaced by homo- or heterogenous tendon stored in MEDA solution even in patients, for tenodesis and narrowing of the transverse vault in foot deformities of various types and origin as well as for the plastic reconstruction of the ligamentous apparatus of the knee joint, the patella and the extensor tendons of the fingers.

The author also suggests the use of homo- and heterogenous tendon thread as suture material for tendon, muscle, fascia and even skin.

RÉSUMÉ

Transplantation des tendons homo- et hétérogènes conservés dans MEDA solution

M. V. Mshvidobadze

Reposant sur les données expérimentales (193 expériments) ainsi que cliniques (29 cas) touchant la transplantation des tendons homo et hétérogènes conservés dans MEDA solution à 50%, l'auteur en fait des conclusions telles que le défait du tendon ainsi complété peut être éventuellement réparé par une structure régénérative au charactère tendineux dont la preuve est le fait de l'apparition du systême nerveux mûr typique.

L'auteur soutient l'avis que les autotransplants tendineux peuvent être remplacés par homo ou, pour combler, par hétérotransplant conservé in MEDA solution même dans la clinique, dans des cas de tenodésie, de remplacement dans les déformités des types divers des pieds et des origines de toute sorte, si bien que dans la reconstruction des appareils ligamenteux du genou, de la patelle et des tendons des extenseurs des doigts.

L'auteur propose de même l'emploie des tendons homo et hétérogènes ainsi conservés en tant que matériel des suttures pour les ruptures des tendons, des muscles, des fascies et, finalement, de la peau.

ZUSAMMENFASSUNG

Transplantation von homo- und heterogenen Sehnen, die in einer Honiglösung konserviert wurden

M. W. Mschwidobadse

Auf Grund seiner experimentellen (193 Versuche) und klinischen Erfahrungen (29 Beobachtungen) mit der Übertragung von in 50%iger Honiglösung konservierten homo- und heterogenen Sehnen kommt der Verfasser zu dem Schluss, dass im Sehnendefekt ein morphologisch und funktionell vollwertiges Sehnenregenerat gebildet wird, wofür auch die Anwesenheit von hier typischen reifen Nervenendorganen spricht.

Der Verfasser halt es für möglich, das Sehnenautotransplantat durch homo- und heterogene Sehnen zu ersetzen, die an der Klinik in einer Honiglösung konserviert wurden, wo sie bei Fussdeformitäten verschiedenen Ursprungs und Grades zur Tenodese und zur Festigung der Querwölbung des Fusses dienen, ebenso wie zur plastischen Rekonstruktion des Bandapparates des Kniegelenks, des Sprunggelenks sowie der Extensoren von Hand und Fingern.

Zum Vernähen von Sehnen, Muskeln, Faszien und Haut schlagt der Verfasser in Honiglösung konservierte homo- und heterogene Sehnenfaden als Nahtmaterial vor.

RESUMEN

La transplantación del homo- y del tendón heterogéneo coservado en una solución MEDA

M. V. Mshvidobadze

Tomando como base los hallazgos en ambas oservaciones experimentales (193 experimentos) y clínicos (29 casos) de las transplantaciones del homo- y del tendón heterogéneo, como injertos conservados en una solución MEDA al 50%, el autor llega a la conclusión de que el defecto tendinoso así reconstruído es eventualmente rellenado por una estructura regenerada de completo carácter tendinoso, lo cual fue demostrado por el hecho de que en ella se dessarrollo un típico y maduro sistema nervioso.

El autor está convencido de que la autotransplantación del tendón puede ser reemplazada por un homo- o un tendón heterogéneo conservado en una solución MEDA precisamente en los pacientes, para la tenodesis y el estrechamiento de la bóveda transversal en las deformaciones del pie de varios tipos y orígenes, tanto como para las reconstrucciones plásticas del aparato ligamentoso de la articulación de la rodilla, de la rótula y del tendón extensor de los dedos.

El autor también sugiere el uso del homo- y del heterogéneo tendón en forma de hilo, como material de sutura para tendones, músculos, fascias e inclusive para la piel.

(Dr. M. Mshvidobadze): ul. Kalinina, 51, NIITO, Tbilisi, USSR

Nous nous permettons d'annoncer

la date du Congres Annuel de la Société Française de Chirurgie Plastique et Reconstructive: Congres Annuel — Paris, Vendredi 23 et Samedi 24 Septembre 1966. Sujet: Paralysie faciale.

Société Française de Chirurgie Plastique et Reconstructive 97 bis, rue Jouffroy — Paris 17e, France. Secrétaire Général: Docteur R. Mouly.

Albert Schweitzer Hospital, Lambaréné (Gabon)

OBSERVATIONS ON THE TREATMENT OF BURNS IN THE TROPICS

J. SEDLÁČEK

This is a report on the treatment of burns at the Albert Schweitzer Hospital in Lambaréné. Burns are treated in the Department of Plastic Surgery on surgical principles by the generally accepted methods of local and general treatment.

Although there is no developed industry, the incidence of burns is high. Twenty-seven patients were treated on one year. Like elsewhere, domestic accidents predominated. They were caused by boiling water, boiling oil or the flames of an open fire. Burns from lighted torches and kindlings or direct burning in tribal dances can also be included among domestic injuries. Petrol and alcohol are still only rare causes of burns.

There are certain differences in the clinical picture, the course of the disease and in the treatment, in the tropics.

The same noxae and the same exposure do not produce a picture identical with that in the European. The injury is milder. The cause can be found in increased skin perspiration in the damp tropical climate and in the coarser nature of the skin cover. The people wear only a minimum of inflammatory clothing and are exposed to intense solar radiation and the influence of the environment. Patients come late for treatment, usually after 24 hours, but also after the lapse of a week, depending on the distance they have to travel. Thus every burn is admitted as infected.

The observation that Africans "heal" far better than Europeans is generally valid. This is conditioned by natural selection and the continuous development of preventive mechanisms of all types. The tremendous environmental dangers only permit the fittest organisms to survive.

We adhere to the Evan's scheme in the general treatment of burns disease and shock, but modified in view of the humidity and temperature by increasing metabolic water requirements by 500 to 1000 ml. Fluid balance is checked and corrected by the haematocrit, following up renal function and by the blood picture.

The open method of treatment cannot be used. This is partly because of the low level of hygiene of the patients, but mainly on account of the high danger of further contamination by microorganisms, parasites and insects. It is interesting that we do not see streptococcal and staphylococcal infection at all. However, abundant mixed infection develops under the bandage

with a predominance of Pseudomonas aeruginosa. Our procedure in treatment is as follows: the wound is washed with soap; all dirt, bullae and loose epithelium removed and the wound dried. It is then washed with saline solution and 3% boracic water and dried again. The Tulle gras used is not too greasy and is placed so that it well overlaps the wound edges. A layer of gauze moistened with mild disinfectant (boracic water, rivanol) is placed over this. Cotton wool is not used at all. Protective boracic powder is sprinkled in the next layer. This produces an acid reaction on dissolving and forms the main barrier to pyocyaneus infection. A bandage made up of only a few layers of gauze is absorptive and airy.

The superficial layers of the bandage are changed when necessary. Treatment is applied over the tulle gras, which is left in situ and the wound then rebandaged as before.

The healing of second degree (superficial and deep) burns is complete two to four days earlier than under European conditions. The relative duration of healing in dependence on the part of the body involved is, in general, preserved.

Deep second degree burns have a better chance of rapid spontaneous epithelization. This is mainly on account of the anatomical and biological properties of black skin. It is approximately twice as "thick" as white skin, according to rough measurement of full-thickness skin grafts taken from different areas. The greatest difference is in the sole of the foot, the least in the palms of the hand. In the latter the thickness of the skin is close to that of the tended European hand. Exact comparative measurements of the layers of the epidermis and dermis would be very interesting.

From the general appearance and from the fact that injection needles get bent and sutures needles break on penetrating the corial layer, we assume that it is this layer which is not only more voluminous but also of different texture and possibly of different histochemical structure. This is also borne out by the great difficulty and sometimes even impossibility of infiltrating local anaesthetic. The requirement that the skin should have a "peau de orange" appearance when collecting dermo-epithelial grafts does not even have to be fulfilled. The ducts of the sebaceous and sweat glands run so deep that sufficient are always left for rapid and complete spontaneous epithelization.

On the other hand, the demarcation and separation of necrotic tissues certainly takes a little longer unless trypsin is used. The average time is 18—22 days. But even here, I have more than once been surprised by unexpected epithelization taking place after necrectomy in the short time the site was being prepared for transplantation.

The newly epithelized areas at first have a lighter shade of pigmentation, but in the course of 2—3 days they acquire the colour of the undamaged surrounding skin. After several more days they develop dark hyperpigmentation with hyperkeratosis. The excessive "overshooting", protective reaction is perhaps the cause of the hypertrophic scars as well as of the deeper colour and hyperkeratosis. True keloids, however, only develop where healing is associated

with persistent infection or excessive pressure or tension. But they do not occur more often than elsewhere in the World.

True keloids are certainly not so common as has been assumed. The people of Gabon are still superstitious and subject their bodies to many and various ritual injuries. The resulting condition is considered as "faro", i.e. adornment. The skin is cut, burned and cauterized at different sites, including sites of predelection, making ingenious patterns, sometimes in really good taste. But keloids only develop in a negligible percentage of cases.

The very good results obtained in the treatment of chronic, tropical, phagedenic, parasitic, tuberculous and leprotic ulcerations with 10% silver nitrate led us recently to even attempting to treat burns by the open method. The wound area is prepared, very carefully dried and gauze soaked in silver nitrate solution applied for one minute. This is allowed to dry and the procedure repeated. Plasma oozing usually stops quite promptly. A film, crust or eschar forms on the wound surface, according to the depth. This then remains uninfected up to healing or to the demarcation of necrosis. Flies and insects avoid this area. The method resembles "tanning" and appears to be more effective in preventing infection. The results so far obtained are very promising for tropical regions.

SUMMARY

The author summarized observations made at the Department of Plastic Surgery at the Albert Schweitzer Hospital in Lambaréné, in treating 27 patients with burns during one year under conditions in tropical Africa.

RÉSUMÉ

Les expériences avec le traitement des brûlures dans les régions tropicales

J. Sedláček

L'auteur nous présente les expériences du service de chirurgie plastique de l'Hôpital Albert Schweitzer à Lambaréné avec le traitement des 27 brûlés soignés dans la période d'une année, sous les conditions de l'Afrique équatoriale.

ZUSAMMENFASSUNG

Erfahrungen mit der Behandlung von Verbrennungen in den Tropen

J. Sedláček

Der Autor fasst die Erfahrungen der plastisch-chirurgischen Abteilung des Albert Schweitzer Krankenhauses in Lambaréné zusammen, die bei der Behandlung von 27 Patienten mit Verbrennungen gewonnen wurden; diese Patienten wurden im Verlauf eines Jahres unter den besonderen Bedingungen Äquatorial-Afrikas behandelt.

RESUMEN

Los conocimientos sobre el tratamiento de las quemaduras en el trópico

J. Sedláček

El autor compendia los conocimientos del Departamento de Cirugía Plástica del Hospital de Schweitzer en Lambaréné, sobre el tratamiento de 27 quemados, tratados durante el período de 1 año, en las condiciones del Africa Ecuatorial.

(Dr. J. Sedláček): Doctor Albert Schweitzer Hospital, Lambaréné, Gabon

ANNOUNCEMENTS

ANNOUNCING THE DATES
of the
Tenth Congress of the Pan-Pacific Surgical Association
Part I — September 20—28, 1966
in Honolulu, Hawaii

*

Second Mobile Educational Seminar
Part II — September 28—October 10, 1966
in Japan and Hong Kong

*

Part III — September 28—November 1, 1966
in Japan, Hong Kong, The Philippines, Thailland, India, Singapore, Australia and New Zealand

The Board of Trustees of the Pan-Pacific Surgical Association announces the dates of the Tenth Congress in Honolulu and the Second Mobile Educational Seminars which travels to countries bordering the Pacific basin.

Part I, the Honolulu portion of the Congress, will convene at the Princess Kaiulani Hotel on September 20, 1966, and continue through September 28.

Part II and III will depart Hawaii on September 28 and travel to Japan and Hong Kong with Part II returning to San Francisco on October 10, in time for the opening of the American College of Surgeons, and Part III continuing on to the Philippines, Thailand, India, Singapore, Australia and New Zealand, returning to Hawaii on November 1, 1966.

The Tenth Congress offers an extensive scientific program presented by more than 450 leading surgeons from the United States and 22 other countries in 12 different specialties: Colon and Anorectal Surgery, General Surgery, Neurosurgery, Obstetrics and Gynaecology, Ophthalmology, Otolaryngology, Orthopaedics, Plastic Surgery, Thoracic-Cardiovascular Surgery, Urology, Anaesthesiology and Radiology. All physicians and surgeons are invited to attend these meetings.

In this space age, diseases are no longer confined to geographical boundaries and it has become essential for the medical profession everywhere, to share its scientific knowledge and efforts. Therefore, Pan-Pacific with its Mobile Seminars, is expanding its activities in teaching, education and dissemination of knowledge to doctors living in the Pacific rim countries who are unable to participate in the Honolulu portion of the Scientific Congresses, in exchange for further education and skill in the diseases unique to the Pacific areas. The Pan-Pacific Surgical Association believes, through the vehicle or medium of medicine and surgery, that our greatest contribution to peace and harmony among all men of all nations can be realized.

For further information, please write: Pan-Pacific Surgical Association, Room 236, Alexander Young Building, Honolulu, Hawaii 96813.