ACTA CHIRURGIAE PLASTICAE

INTERNATIONAL JOURNAL OF PLASTIC SURGERY

VIII · 3

1966

Acta chir. plast. 8 : 3 : 1966

CZECHOSLOVAKIA · PRAGUE · SZDN

Published four times (in 1959: two times) a year by Státní zdravotnické nakladatelství, (Czechoslovak Medical Press), Malostranské nám. 28, Praha 1. — Adress of the editorial office: Acta chirurgiae plasticae (M. Dobrkovský, M. D. — Secretary) Legerova 63, Praha 2, Czechoslovakia. — Orders through ARTIA, Smečky 30, Praha 2. — Press: Středočeské tiskárny, n. p., provoz 101, Hálkova 2, Praha 2. — A-01*61032

TABLE OF CONTENTS

ACTA CHIRURGIAE PLASTICAE — 8, 3, 1966

THE LEGACY OF ACADEMICIAN BURIAN

V. KARFÍK

Academician Burian was a personality who was inseparably linked with the development of our health service and also with the tremendous upsurge of surgery during this century. Czechoslovak surgery was enriched by his life-long effort in developing a new specialized branch, plastic surgery, which by its significance and position in Czechoslovakia's health service in many aspects preceded world development in this discipline. For this reason we are justified in placing Burian side-by-side with the creators of Czechoslovakia's modern surgery Albert, Kukula, Jedlička, Petřivalský and Jirásek, who have greatly influenced the development of surgery in this country.

Academician Burian was not only a great personality of our country but of world plastic surgery, where he is recognized as a co-founder. Together with Ferry-Smith, Davis, Kazanjian, Gillies, Killner, Ombrédanne, Dufourmentel, Sanvenero-Rosselli, Limberg, Rauer and others, he founded the branch of maxillofacial traumatology and reconstructive surgery during the First World War.

In order to understand his development, we must realize that, unlike many others, he was a general surgeon who enriched his experience in both Balkan Wars and in World War I as chief surgeon in large military hospitals both at the front and in the rear. There already, he verified surgical methods and procedures then used. It is no wonder, therefore, that he got into conflict with the official doctrine of war surgery. He introduced treatment of fractures by extension, treated injuries of the upper limb by abduction splints, operated on inguinal hernias by new methods and propagated progressive methods of rehabilitation of the wounded soldiers. Having in mind Austrian-Hungarian surgery, that was rebellious, indeed. However, he also obtained a unique series of results in operations on injured arteries and the heart which later, he submitted for his thesis.

This activity which constitutes the first period of his life-long work is already marked by his profound surgical knowledge, his eagerness for learning, his very critical attitude, his search for the new and better, his constant dissatisfaction with himself and his courage in boldly entering any struggle for the correctness of his ideas. If we realize that he linked all these properties with immense diligence, patience and great manual skill, combined with profound feeling for the tissues, we shall be able to understand his further road to the successes of plastic surgery.

We must, however, realize that in this field Burian was actually a self-taught man. Already in 1912, during the first Balkan War, in a small field hospital in Montenegro, he tried to replace a lost nose with a flap taken from the thoracic wall. This flap he connected with a two-pedicle arm flap in order to obtain sufficient material and then transplanted both into the face. He thus deliberately formed a closed two-pedicle flap completely epithelized on primary surgery and eliminated the shortcomings of the granulating undersurface of the flap which impaired the results of all advocates of Tagliacozzi's method. He thus became the predecessor of the tubed flap which was first consciously used by Filatov in Russia in 1915, and by Gillies, on the Western Front in 1916.

Reconstructive surgery attracted him more and more, and thus we see pictures of his patients in Bulgaria during the second Balkan War, in 1913, who were operated on in the face. In the First World War he then, deliberately collected wounded soldiers of Czech origin and returned with them from the Eastern Front to Prague. He was in charge of the largest military department of reconstructive surgery for war injuries in the countries developed after the disintegration of the Austrian-Hungarian Monarchy. However, in the following period little oficial attention was paid to the care of war invalids and that led to the interruption of his work in 1924. Only in 1929 he was given the first real opportunity to work independently in a department with 35 beds of the hospital of the Jedlička institute. There he also acquired his first permanent coworker.

Yet, this unfavourable period did not prevent Burian from continuing his work of the pioneer of plastic surgery. Publications which testify to the great talent of Burian and which preceded the development of world plastic surgery date back to that period. These include the paper on the treatment of facial paralysis published in 1919. His method of anchorage of eyelids and the corner of the mouth was world priority. He was the first to combine this operation with shifting of the cheek, a method which became the basis for lifting the skin of the face in cases of flabbyness and ptosis. His method of free skin grafting developed in a specific way. He did not further elaborate the method of free transplantation using a Thiersch knife, but that of full-thickness skin grafts in cases where others employed epithelial membranes. He was thus the first to use the so-called "skin inlay" (1926), unlike the epithelial inlay of Esser in the orbit, when reconstructing the oral vestibulum or the vagina, or in syndactyly. In this way he considerably improved the quality of the lining, preventing it from shrinking. The discovery of the dermatome, after the Second World War, induced him to further differentiation of skin grafts, according to the thickness of the skin transplant. Burian was unsurpassable in local skin plasties and in Z-plasty which he employed in a masterly manner, in facial plasties, contractures of the limbs and in straightening of the chordee in hypospadias. He was acquainted with the old publications of Szymanowski and Zeiss and made modifications of plastic operations, particularly on fingers, which had been recommended by them.

The great contribution of Burian was the utilization of the tubed flap for plasties. He gave preference to it over the quicker local plasties which had the disadvantages of creating new scars in the affected region. He, therefore, formed the tubed flaps at covered sites, preferably in the hypogastrium and transferred them via the forearm. With a boldness characteristic for him, Burian was the first surgeon in the world to perform, already in 1921, a closure of a defect in the upper jaw resulting from resection of a tumour, by using a tubed

The golden Medal of the Czechoslovak Academy of Sciences — the highest scientific award, presented to Academician F. Burian in Memoriam.

flap. His method of modelling the transplanted material to fit the defect was original and essentially different from other methods. Meticulous asepsis and careful closure of all raw surfaces was aimed at preventing sclerosis of the flap, whose fatty layer he considered to be the most suitable modelling material. Surgical modelling which in plastic surgery was an unknown feature for a long time and which he patiently tried for many years, enabled him to obtain not only perfect results as to shape but as well as mainly stable results.

Burian soon realized the importance of supporting tissue for the stable condition of reconstruction. That is why already in 1926 he demonstrated the slinging up of the chin and lips reconstructed by a tubed flap by means of fascial bands anchored to the temporal fascia or the zygomatic arch. After transplantation of skin to reconstruct the soft tissues he always replaced the lost skeleton and was the first to use cartilage in the reconstruction of the facial skeleton.

In the flood of new world literature it is difficult to defend the priority of many other operations designed by Burian about which, in all his modesty, he said that he had not been quoted because he had published them so long ago. However, it is necessary to realize his original attitude towards methods of reconstructive surgery which had already been in general use. His physiological

outlook led him to the discussion with Esser in 1923 concerning the conception of the so-called "biological flap". He considered every successful transplantation, complying with all requirements of the repaired region, to be a biological one. From this conception Czechoslovak plastic surgery in which preference is given always to transplantation of autogenous tissue, has taken its origin.

Burian considered the renewal of function to be the main aim. He said literally: "Where function has been renewed successfully the cosmetic result, too, is usually good. It is, therefore, necessary, to analyze carefully the functional significance of a deformity just at its anatomical properties and its extent and depth. Here we realize that only with reservation can we speak of groups of plastic operations. The noxious agent does not choose topographic regions nor does it limit itself to their borders." That is why Burian became the founder of the conception of physiological surgical technique which does not apply "only to the technical aspect of operating but also to the question of the sequelae of physiological processes started by the surgical interference in the organism and also to the physiological, direct, local or remote aims which may thus be attained". His analysis of surgical procedure and of the surgeon's manipulation in the wound, which he described in his brilliant essay, is unique. An operation performed by Burian was guided by a strict order, characteristic for his discipline and undisturbed mental concentration. To him the aesthetics of the surgical performance were the precondition for the physiological performance.

This conception makes us understand his attitude towards cosmetic operations. He always considered cosmetic surgery to be the "logical complement of cosmetic medicine". He postulated highest surgical and moral qualifications of those engaged in this kind of work. It is noteworthy that already in 1930 Burian met with understanding on the part of worker's insurance companies which undertook to cover even the expenses for cosmetic operations performed on their members.

Academician Burian had a great and direct influence on the conception and organization of Czechoslovakia's health service. Already during his life-time, this activity was fully recognized and awarded with highest distinctions. Not only was plastic surgery put on a broad basis, but under his influence adjacent surgical disciplines such as maxillo-facial surgery developed, and the young and vital surgery of the hand and facial traumatology gained ground. The principle of physiological surgical technique entered into all surgical branches. Finally the surgical treatment of burns in our land is the result of Burian's life-long work and one of his great merits.

When evaluating the work of Academician Burian in 1951, on the occasion of his 70th birthday, we visualized two great periods in his life-long work: his activity as a war surgeon and that as a plastic surgeon. We did not anticipate that he would enter a third period, i.e. that of a scientific worker and organizer of research work in the field of plastic surgery. His work as an active surgeon and innovator had often been appreciated on occasions of his anniversaries.

However, now it is necessary to pay tribute to the last of his remarkable periods so that this be fully recorded for the future and appropriately appreciated.

Burian as a clinician furnished with the experience of his long and fruitful life gave thought to the essence of his successes and failures and to the further perspectives of plastic surgery. He dealt profoundly with the question of social consequences of his work and realized the contradiction between the therapeutic success obtained for the individual and its social impact. He considered the increase in the incidence of congenital malformations particularly noticeable in those based on heredity and whose carriers have found their place in society, have been able to marry and produce children. The profoundly humane attitude of this brilliant surgeon confronted him with yet another new task. He started a drive against the harmful increase in the incidence of a defective generation with malformations by putting forward the most important tasks and by elaborating programme for research into congenital malformations that would cover all aspects of this problem. He became the founder of clinical genetics in Czechoslovakia. In his department he established a laboratory for the study of all problems connected with facial clefts, the field to which he had devoted special interest throughout his life. He developed a broad programme of research of etiology, of genetic as well as environmental factors. He proposed registration of congenital malformations on a national scale, advocated a correct classification and biomorphological analysis of these malformations and genealogical research into affected families. He requested this for every group of congenital malformations and asked for the listing of a team of specialists who would be able to deal with all these questions simultaneously. Yet, he never ceased to be a clinician himself with a deep interest in the affected individual for whom he wanted to ensure concentrated care until he had reached maturity.

On the other hand he demanded that clinicians become organizers of research into the external causes and that all who were responsible for healthy environments and the care of women take part in this research. He suggested co-operation of large teams, including agrobiologists, geologists, meteorologists, epidemiologists as well as experimental teratologists, zoologists and veterinary surgeons. He himself gave an example by the way in which the work in his laboratory was organized. This laboratory became part of the Czechoslovak Academy of Sciences.

Burian soon realized that this great battle cannot be fought in one country only. He therefore submitted his view to an international forum. He was the initiator of the first international scheme which in the very near future will have fulfilled its first task, i.e. the classification of cleft deformities so that the results of a world-wide research and also of therapy could be evaluated according to unified criteria.

At the same time Burian was aware that cleft deformity is accompanied by large affections, greatly exceeding the borders of its morphological appearance and necessitating, therefore, profound research in order to evaluate the malformations and its therapy as well as its social impact. He pointed

out that adaptive and compensatory mechanisms have a lesser effect in facial clefts than in other malformations and that responsibility for the therapy of the former is thus greater. He indicated the line along which research should develop, i.e. with the help of biophysical methods and evaluation of the natural and acquired conditions for the further development of the affected region. He showed how many questions of a basic character still remain unsolved which makes it imperative to carry out research into the normal, unaffected population. In this way he opened for Czechoslovakia the road to research in many adjacent branches.

Academician Burian also considered the development of other research tasks in plastic surgery. He started to work on expanding the research into tissue transplantation, employed in plastic surgery. He, therefore, established an immunological laboratory to study the immunological processes in burns as a basis for a better understanding of the processes taking place in skin transplantation in general. Under his guidance, his pupils worked on the problem of cartilage transplantation on which he had published a number of papers.

With his scientific and organizational activities in the field of research work, Burian became an authority and for his scientific work he was awarded the highest distinctions by the Czechoslovak Academy of Sciences.

That was the life of Academician Burian, the surgeon, plastic artist and progressive scientist. His work highly esteemed during his life-time will remain a lasting legacy.

(Prof. Dr. V. Karfík, DrSc.): Šrobárova 50, Praha 10, Czechoslovakia

Just a month after his 84th birthday, on October 15, 1965, Academician Burian was invited to deliver the opening lecture at the meeting of the German Maxillo-Facial Society in Reinhardsbrunn D.D.R. Academician Burian prepared his lecture with care and was looking forward to the trip which he did not live to make. We are presenting our teacher's last work, which radiates profound humanism, deep knowledge and surgical skill, completing the portrait of his many-sided personality.

PLASTIC SURGERY IN RESEARCH ON THE PATHOLOGICAL PROCESS IN THE MAXILLO-FACIAL SPHERE

† ACADEMICIAN F. BURIAN

Mr. President, Ladies and Gentlemen,

The guiding idea of this meeting is the dominant role of aesthetics in plastic surgery.

This takes me a long way back to the period when modern plastic surgery was in its initial stages, after the first world war. At that time, the label of Aesthetic Surgery threatened to disrupt the development of modern plastic surgery. At the end of the war many doctors who were working in departments of reconstructive maxillo-facial surgery (many of them untrained, who had just acquired a smattering of knowledge) were seeking an easy way of earning their living. A welcome opportunity came their way in the cosmetic boom after the war. Social changes emanating from the war were the moving force. During the war, women had been placed in jobs vacated in many branches by recruited men. When the war ended, they were most unwilling to relinquish the positions they had gained. Very soon, they were exposed to mass competition and realised that a fresh and attractive appearance is a highly effective weapon.

After the first world war, women began to be more aware of their physical appearance and the grooming of the body gained general popularity. Increasing numbers of women took up sport and gymnastics, and cosmetics flourished.

This fact was taken advantage of by a number of doctors who had returned from the war and who were thus able to apply what knowledge they had gained in plastic operations during the war. Not a few of them joined forces with cosmetic establishments and carried out cosmetic operations, generally under the most deplorable conditions.

These people did untold harm, for instance, by giving paraffin injections. Phlegmonas and sepsis were the order of the day after such interventions. Claims

for damages and the scandals of "cosmetic surgeons" were favoured topics of conversation.

Enemies of plastic surgery used all this to discredit this speciality.

Many experienced plastic surgeons refused to have anything to do with operations which were purely cosmetic. The International Journal of Plastic Surgery founded by Coelst in Brussels in 1930, changed its name to "Chirurgie Structive" and turned down all further contributions dealing with cosmetic surgery. But this was a mistake because it drove patients into the hands of quacks.

In Prague, we tried to combat these manifestations of disfavour in another way. We gave regular lectures and demonstrations in medical associations and surgical societies. In 1928 I was introduced by professor Leon Ombrédanne to the French Society of Orthopedics. I gave lectures illustrated with films at the Autumn Congresses of the French Society of Surgeons. In this manner, we succeeded, in 1929, in getting permission to hold lectures on plastic surgery at the Faculty of Medicine of Charles University and in 1932 plastic surgery was accorded legal recognition as a special branch, in Czechoslovakia.

The first International Symposium of Plastic Surgery in Prague was held in 1935, sponsored, by the Medical Faculty. It was well attended.

In 1939, the United States of America were next to recognise plastic surgery as a special branch of medicine and plastic surgery is now a highly respected science throughout the world, with an acknowledged aesthetic character.

However, plastic surgery has ceased to be only a clinical and technical sphere. It also has an extensive theoretical-research role, which penetrates deeply into basic research. It is important that every surgeon working in plastic surgery should be aware of this fact.

The task is a far-reaching one in that it involves research into the constitutional basis of man as a patient. The psychological attitude of the afflicted person to his disfiguring deformity and his awareness of it is influenced by his constitution. The psychological phenomena accompanying deformities and disfigurement in children are rarely recognised and taken into consideration. There are children who, up to the age of 5 or 6, are quite unaware even of considerable disfigurement and there are others again who, at the age of 2 or 3, are already highly sensitive and conceal their deformed hands behind their backs and isolate themselves from other children. They are frequently labelled as backward children and as such care for their well-being and education is often inadequate and the harm done to them shows up in later life. When the number of afflicted is great, it constitutes a great social and economic problem.

It goes without saying that constitutional features also influence the biological reaction and healing ability of the patient. A thorough knowledge of his constitution is therefore essential. In order to determine it the prenatal and postnatal history of the patient must be determined. Should the intrauterine part of development be disturbed in any way, be prematurely concluded, or if the weight of the new-born baby or its length be abnormally small, or should

it suffer any damage during birth, then the biological value of the baby's tissues and organs is lower. It adapts itself badly to its new environment. Its resistance to danger is not strong enough and the healing ability of the tissues is poorer.

In the examination of the patient and his medical background his family history is a more important and decisive factor when considering methods of treatment and prognosis than has been admitted up to now.

The worse the health and hereditary index of the family, the more it affects the pathological condition of the patient and his chances of complete recovery. The care of such individuals is a more exacting task.

An exact case history of the patient which takes into consideration all the given circumstances must be drawn up in such a manner as to be lucid and clear at a glance and make a mathematical deduction possible. The plastic surgeon must create a continuity between clinical and basic genetics. The genetic conditions form an extremely important part of etiopathogenesis not only of congenital deformities but also of all other pathological conditions coming within the scope of the plastic surgeon. He must take a precise case history from each patient so as to clarify every single aspect.

The plastic surgeon must be able to make a precise assessment of congenital deformity and operating methods. The surgeon should not be content just to, say, shift a flap a millimetre or two in the operation of cleft lip and then to announce a new and better modification of the operation. The operated child must be kept under observation right up to maturity by which time no significant changes are likely to occur in his development. The resulting condition can then be evaluated. When evaluating each method of operation and method of rehabilitation, the data concerning a large number of adult patients must be collectively assessed. Only then can they be divided into groups and a mathematical-statistical evaluation be deduced.

Thus the plastic surgeon must not only increase and expand his knowledge of mathematics and statistics, but he must also keep in close cooperation with mathematicians and statisticians.

In order that individual clinics and institutions may acquire such considerable data within a short time, plastic surgeons must collaborate, that is, they must all join in this work, and be prepared to meet its specific demands. A plastic surgeon must first of all collaborate with units of plastic surgery in his own country and then cooperate internationally with neighbouring countries. It is increasingly obvious that this work is important not only for plastic surgery but also for all other specialised branches of medicine. We have proposed a simple, internationally acceptable nomenclature, for the time being of clefts, acceptable to all of us who operate on such deformities. Theoretical interest is doubtlessly great but so far there have been only a few applicants for practical cooperation.

Operations and rehabilitation treatment will soon be increasingly frequent. Congenital deformities will increase until a large number of specialists will be able, on the basis of international cooperation, to start effective prevention.

Many plastic surgeons are participating in this field of research and they should begin to collaborate closely as soon as possible.

The second specialised problem in which plastic surgeons have a vital interest is the transplantation of tissues and organs. Traumatic deformities will continue to multiply with motorised transport. Nothing can prevent the growth of this monstrosity which mankind has created to its own disadvantage and continues to boost so enthusiastically.

Injuries sustained in industry are decreasing and with the general introduction of automatization, will be reduced to an insignificant number.

War injuries, however, are on the increase. The most prominent persons in science and arts are devoting their energies to peace. But even, in the time of so-called peace, thousands of people in many parts of the world are daily being wounded and crippled.

The growing task of plastic surgeons is to work for the prevention of these injuries. They must give publicity to the horrors of injuries, demonstrate the difficulties and expense of treatment and contribute to better understanding among nations.

International scientific meetings are of great importance and have the means necessary to produce results. Their activity should lead to increasing international cooperation. International symposia should always tend to be monothematic and should approach the given problem in such a way as to reach agreement concerning future joint research. National research groups with close working contact should be set up.

I beg to submit these proposals to this esteemed gathering for consideration. I regard them as the basis of research in plastic surgery.

(Academician F. Burian): Šrobárova 50, Praha 10, Czechoslovakia

The Laboratory of Plastic Surgery of the Czechoslovak Academy of Sciences,
Prague (Czechoslovakia)
Director: Prof. V. Karfík, M.D., D.Sc.

PROPOSED CLASSIFICATION OF RARE CONGENITAL CLEFT MALFORMATIONS IN THE FACE

V. KARFÍK

The International Subcomittee for Cleft Malformations, founded at ICPS (International Confederation of Plastic Surgery) has been given the task of unifying the classification of malformations of the face. Apart from the most frequent clefts of lip and palate and their combinations, there is a group of rare cleft malformations which essentially differ from the former by their nature, incidence and origin. The constantly improving paediatric care results in an increasing number of children affected with these malformations being referred for operation to the plastic surgeon, and it is, therefore, increasingly necessary to find a unified classification to divide them into groups, make an exact diagnosis and document them precisely. In recent years both foreign and Czechoslovak publications have shown that it is necessary to unify the surgical procedures in these unusual malformations. There must also be a unified classification to permit unified evaluation of the malformation and surgical methods used.

At the Czechoslovak departments of plastic surgery the need for such unification has led us to elaborate the proposal presented here for appraisal. It is based on a number of facts. First of all, it is the analysis of cases which we have operated on and a comparison of them with reports in the literature. We were further guided by the requirement for the simplest possible form of documentation and registration. Finally, we have aimed at the delimitation of regional entities which, at the same time, would define the groups of surgical reconstructions. That is why we have included into the regional groups some syndromes in which only certain details are treated, since they are localized just in these regions.

A number of view points presents itself simultaneously when trying to classify the rare cleft malformations of the face. Most of them have been used in relation to the attempt classify of the common clefts of lip and palate. The morphological characteristics did not get us far and embryological aspects had to be employed, in addition, in the classification of these malformations. The inclusion of a number of aspects contributes not only to the understanding of the genetic relations, but also to the evaluation of the degree

of primary damage and the prognosis of further development of the malformation. In rare malformations it is also necessary to visualize the genetic relations in connection with the morphological picture. Some of them, although their incidence is small, show a clear hereditary taint and familial incidence, and are often combined with other congenital malformations.

Attempts to classify these malformations date back a long way, although the opinion is still widespread that classification is impossible because of their great diversity, and would, in any case, be useless for clinical purposes. Although, on the whole, little is known about the causes of congenital malformations, some of the facts known about teratogenesis may already be used and would be helpful in an attempt to establish a system for these malformations.

With the development of embryological research the old hypothesis of facial processes whose failure to fuse gave rise to the development of the various cleft malformations, has been abandoned. The branchial arches, too, are more of a topographical significance. At present, the dynamic explanation that a disorder in the mesodermization is the cause of congenital malformations in the face, has come to the forefront. It was certainly incorrect to define malformations from a purely local point of view. They should correctly be conceived as a local disturbance resulting from teratogenic factors (depending on their quantity and quality) together with the time factor, both acting upon the hereditary taint at a given moment. For this reason neither exact localization nor the intensity of the malformation can ever be expressed by systematic classification. This can only be approximate and will always meet with opposition. It is, however, most probable that with progressive acquisition of knowledge about genetic laws and embryogenetic processes all forms of malformations will be correctly classified into well defined groups.

SUGGESTED CLASSIFICATION

Group A 1 (Fig. 1).

This group includes changes in the rhinocephalic region, that is axial and paraxial disorders according to their anatomical course. These are primarily disorders in the closure of the anterior neuropore which are characterized by malformations in the region of the olfactory apparatus and are mainly represented by median or closely paramedian clefts. They are often joint with disorders in the closure of the cranial cavity, which lead to prolapses usually combined with a congenital tumour (glioma, hamartoma, dermoid, teratoma).

To this group also belong the clefts of different intensity including doubling of the nose or some of its parts, such as the alae, the septum or the nostrils.

Finally, this group contains defective changes ranging from coloboma of the nostrils and defects in parts of the outer nose and its inner structures to atresia or even total defect of the nose.

This group also includes a very rare malformation which seems to be a continuation of an axial disorder, i.e. the median cleft and defect of the lip and premaxilla.

Arhinencephalic disorders			A 1
Axial Group	Prolapsus	Meningocele Glioma Dermoidal Cyst Teratoma	
	Clefts	Median Nasal Cleft (Double Nose)	
	Defects	Coloboma of Nostril Partial of the Nose Total of the Nose Septal Atresia Nasi	
	Median Cleft of upper Lip and Intermaxilla		

Fig. 1 — A 1

Fig. 2 — A 2

Arhinencephalic disorder composite			A 2
Paraaxial Group	Lateral Cleft	Coloboma Iridal Palpebral Lateral cleft Partial Total Cleft lip lateral Cleft lip typical Lacrimal duct dystopia	

Group A 2 (Fig. 2).

The group includes combined rhinocephalic malformations with paraxial changes represented by the lateral cleft of the cheek, the upper lip, the lower eyelid and the iris. They are always combined with disorders in the develop-

ment of the nose and its parts, and this is the reason why we included them into the rhinocephalic group, although in other classifications they form a special group. This lacral cleft is usually slightly oblique and usually combined with the current type of cleft, of the lip and palate. This is why we consider it incorrect to call this type of lateral cleft "oblique facial cleft", which belongs to the special group. [E]

Group B 1 (Fig. 3, 4).

This group consists of otocephalic malformations with their focus situated around the area of the auricle and inner ear radiating into the adjacent structures to various degrees. The disorder belongs to the group of syndromes of the first and second branchial arch.

The first subgroup consists of transverse clefts of the mouth and the cheek and cervical fistulae running toward the tragus. The second subgroup includes dysostoses which are divided into mandibular and mandibulofacial.

Fig. 3 — B 1

Fig. 4 — B 1

Branchiogenic disorders (1. and 2. Arch)			B 1
Lateral Otocephalic	Clefts	Macrostoma Lateral Fistula of the Neck	
	Dysostosis	Mandibular (Sy Robin) Mandibulo-Facial (Sy Tr. Collins etc)	
	Defect	Auricular Partial - Total Atresia	

Group B 2 (Fig. 5).

Branchiogenic malformations situated in the midline and essentially based on a disorder in fusion form a special group. In extreme cases these disorders lead to a cleft of the tongue, the lower lip, the mandible, the neck and

the sternum. The simple and relatively frequent malformations situated laterally, such as cysts and fistulae of the neck, are purposely not included in this group.

Group C (Fig. 6).

This is the group of orbitopalpebral malformations. They include malformations of the orbit, that is of the eyeball, the eyelids, the orbital walls and clefts of the eyelids.

Fig. 5 — B 2

Fig. 6 — C

Branchiogenic disorders			B 2
Medial Axial	Clefts	Tongue Lower Lip Mandible Fissura Colli Medialis Fissura Thoracis Med.	

Oftalmo-orbital disorders			C
	Malformation	Eyeball: Microbulbia Anophthalmia Lids: Blepharophimosis Epicanthus Ptosis Agenesis	
	Defects	Orbital	
	Clefts	Coloboma Upperlid Commissural	

Craniocephalic disorders			D
	Malformation	Head and Face (Sy Apert, Sy Cruzon etc)	
	Defect	Scalp Scull	
Atypical disorders-embryopathy			E
	Oblique Cleft of Face (see Fig. 2 — A 2) Dysembrioma Parasitic Hemiatrophy Hyperplasy Neoplasma Congenit Teratoma et al.		

Group D.

Another group is made up of craniocephalic malformations including reparable ones such as defects in skin of the skull and the cranial bones, deformations and disorders in the development of the cranium usually greatly affecting the development of the adjacent parts of the face (oxycephaly, acrocephalia, dish-face, etc.). This group, of course, also includes a number of syndromes some signs of which are localized in this region.

Group E.

The last group is made up entirely of atypical malformations most of which are embryopathies proper in origin. To this group belong clefts running obliqely across the cheek and showing no relation to the orbit or the nose. They are usually combined with a certain form of atypical cleft of the lip. We have termed the latter "oblique cleft", because it actually runs in a line lying between the course of the lateral, i.e. paraxial and that of the transverse (marcostoma) cleft. It is evident that this type of cleft forms a special group, and it certainly will be a question of agreement whether it will be called lateral cleft or oblique cleft. There is no uniformity in the literature about it. We, however, maintain that it should be distinguished from the paraxial lateral cleft with its significant relation to the nose and orbit.

This group, of course, also includes the various parasitic formations such as doubling of the upper jaw, teratoma, prosopopage and cengenital tumours causing severe asymmetry of the face, as well as hypertrophy, hemiatrophy, etc.

We present this proposal for systematic classification for discussion as a contribution to the unification of diagnosis, documentation and registration of our working programme.

We are convinced that our classification may be useful to every surgeon who has had the opportunity of operating on congenital defects not mentioned in our scheme. The purpose og this paper is to give examples of placing them into proposed groups of classification.

References with the author.

(Prof. dr. V. Karfík, D.Sc.): Šrobárova 50, Praha 10, Czechoslovakia

Klinik Dr. Schweckendiek für Hals, Nase, Ohren, Lippen, Kiefer, Gaumenspalten
Marburg (Bundesrepublik Deutschland)

DIE BESONDERHEITEN DER GAUMEN- UND LIPPENSPALTENPATIENTEN FÜR DAS HALS-, NASEN-, OHREN-FACHGEBIET

W. SCHWECKENDIEK

Bei Patienten mit Lippen-Kiefer-Gaumenspalten kommen gelegentlich Fehlbildungen des äusseren Ohres, des Mittelohres und des Gehörganges vor. Bei den queren Gesichtsspalten treten Fehlbindungen des Ohres fast ausnahmslos auf.

Die entzündlichen Erkrankungen des Mittelohres und Hörschäden vom Schalleitungstyp spielen bei Gaumenspalten eine grosse Rolle. Die Angaben der Häufigkeit schwanken in der Literatur zwischen 40 u. 90 %. Ursache ist die gestörte Tubenfunktion infolge der mangelnden Vereinigung des Gaumensegels in der Mittellinie. Bei operierten Gaumenspalten können Läsionen in der Gegend des Hamulus pterygoides und Verletzungen der Gaumenmuskeln mit Vernarbungen zusätzlich Mittelohrerkrankungen begünstigen. Am häufigsten werden Trommelfellnarben oder Adhäsiv-Prozesse beobachtet. Seltener sind recidivierende Mittelohrenzündungen mit Dauerperforationen oder chronisch randständige Trommelfelldefekte. Röntgenologisch findet man dabei regelmässig eine herabgesetzte Pneumatisation der Warzenfortsätze oder sekundäre Sklerosierung. Ausser der gestörten Tubenfunktion können auch chronische Entzündungen im Bereich der hinteren Nase und der Rachenmandel eine Ursache für die Mittelohrerkrankungen sein. Wir raten in diesen Fällen zur Adenotomie, evtl. auch zur Tonsillektomie, obwohl wir mit Rücksicht auf die Sprache im allgemeinen mit diesen Eingriffen zurückhaltend sind. Nach der primären Veloplastik ist die Zahl der Mittelohrerkrankungen und Schwerhörigkeiten beträchtlich geringer als nach den Erfahrungen anderer Autoren. Nur in 25 % der im ersten Lebensjahr am weichen Gaumen operierten Patienten leidet an recidivierenden Mittelohrerkrankungen oder Hörstörungen. Wir führen das darauf zurück, dass durch die frühzeitige Vereinigung des Gaumensegels die Tubenfunktion im Wesentlichen normalisiert werden kann.

Von Seiten der Nase sind die äusseren Fehlbildungen und die Asymmetrien das wichtigste Anliegen für den plastischen Chirurgen, da sie ästhetisch unschön wirken. Von Seiten des Hals-Nasen-Ohrenarztes muss aber auch darauf hin-

gewiesen werden, dass häufig, besonders bei den einseitigen Spaltbildungen, erhebliche Septumdeviationen vorhanden sind, die einer operativen Korrektur bedürfen, damit die Nasenatmung frei wird und Nebenhöhlenerkrankungen und Mittelohrentzündungen vermieden werden. Der bei der Nasenscheidewandoperation anfallende Knorpel kann zur Verbesserung der Nasenform wieder plastisch verwendet werden. Um die Septumoperation ausführen zu können, ist eine gesunde Nasenschleimhautbedeckung der Nasenscheidewand erforderlich. Deshalb und um atrophische Schleimhautprozesse nicht zu provozieren, möchte ich vor der grosszügigen Anwendung der Vomerlappen in der Gaumenspaltenchirurgie bei Säuglingen warnen.

Nach Untersuchungen, die wir über die Nasennebenhöhlen bei Spaltträgern angestellt haben, können wir feststellen, dass das Nebenhöhlenwachstum normal verläuft und dass bei erwachsenen Spaltträgern die Nebenhöhlen die gleiche Ausdehnung und Grösse haben wie bei gesunden Vergleichspersonen. Auch bei hochgradiger Kieferdeformierung nach frühzeitigen operativen Massnahmen ist das Wachstum der Nebenhöhlen kaum beeinträchtigt. Etwa 20 % aller erwachsenen Spaltträger haben pathologische Veränderungen der Nasennebenhöhlen-Schleimhaut, obwohl polypöse Sinusitiden seltener sind. Man findet auch häufig Vergrösserungen der unteren Nasenmuscheln, besonders der hinteren Muschelenden. Mit deren Abtragung muss man vorsichtig sein, weil sich häufig danach die Sprache verschlechtert und der Nasaldurchschlag stärker wird, wenn nicht ein genügender Nasenrachenabschluss durch das Velum vorhanden ist.

Auf den Zahndurchbruch an atypischer Stelle im Nasenvorhof oder in der vorderen Nase soll in diesem Zusammenhang ebenfalls hingewiesen werden. Oft unterhalten diese Zähne langdauernde Eiterungen, die in Unkenntnis der Dinge nicht rechtzeitig erkannt werden. Sie können ebenso wie Fisteln im Gaumen die Ursache für Infektionen der Nebenhöhlen oder der Mittelohren sein. In anderen Fällen bilden sich grosse Rhinolithen um die cariösen Nasenzähne.

Zu den sprachlichen Störungen ist folgendes zu bemerken: Nach unserer Erfahrung ist bei der Rhinolalia aperta des operierten Spaltträgers, die gewöhnlich durch ein kurzes oder unbewegliches Gaumensegel hervorgerufen wird, die Velopharyngoplastik mit oben gestieltem Pharynxlappen besonders geeignet, um eine wesentliche Verbesserung der Sprache zu erreichen. Bei sehr kurzem Velum empfiehlt sich die Einbeziehung der hinteren Gaumenbögen in die Plastik.

Aber auch bei gut funktionierendem Gaumensegel oder nach der Velopharyngoplastik kann die Sprache erst dann normalisiert werden, wenn durch einen systematischen Sprachunterricht die Fehlartikulation behoben wird. Die bei erwachsenen Patienten mit Gaumenspalten häufig beobachteten trockenen Rachenkatarrhe werden durch die Velopharyngoplastik ebenfalls günstig beeinflusst.

Auf die Frage der Tonsillektomie wurde schon im Zusammenhang mit den Ohrenkrankungen hingewiesen. Wenn die Tonsillektomie beim Spaltenträger notwendig ist, muss sie besonders schonend und sorgfältig ausgeführt werden, um nicht durch zusätzliche Narbenbildungen die Beweglichkeit des Gaumensegels einzuschränken.

ZUSAMMENFASSUNG

Entzündliche Erkrankungen des Mittelohres und Hörschäden vom Schalleitungstyp spielen bei Gaumenspaltenpatienten eine grosse Rolle. Die Zahl der chronischen Mittelohrentzündungen und der Adhäsivprozesse ist höher als in der Normalbevölkerung. Ursächlich ist dies durch die gestörte Tubenfunktion zu erklären. Die Nase des Spaltpatienten bietet ästhetisch-kosmetische und funktionelle Probleme. Durch hochgradige Septumdeviation und Muschelvergrösserung ist die Luftdurchgängigkeit häufig behindert. Die Nebenhöhlen erreichen eine normale Grösse; in 20 % aller Fälle bestehen aber pathologische Schleimhautveränderungen.

Ein atypischer Zahndurchbruch kann sowohl im Kieferbereich wie am Nasenboden vorkommen. Die Indikation zur Tonsillektomie wird nach gleichen Gesichtspunkten wie bei einem Normalen gestellt. Bei der Adenotomie und bei der Abtragung der hinteren Muschelenden, ist aber eine gewisse Vorsicht geboten. Dieses soll man nur ausführen, wenn die Rachenmandelhyperplasie Ursache einer Schalleitungsschwerhörigkeit ist. Die sprachlichen Störungen erfordern einen systematischen Sprachunterricht. Die nach Gaumenoperation noch bestehende Rhinolalia aperta lässt sich in vielen Fällen durch den obengestielten Pharynx-lappen beseitigen.

SUMMARY

Otolaryngological Features in Patients with Cleft of Lip and Palate

W. Schweckendiek

Inflammatory affection of the middle ear and auditory disorders of a transmission type are common in patients with cleft palate. The incidence of chronic otitis media and adhesive processes is higher than in the normal population. This is probably caused by a disorder in the function of the Eustachian tube. The nose of a patient with a cleft gives rise both to cosmetic and functional problems. Deviation of the nasal septum and enlargement of a nasal concha often blocks the air passages. The nasal sinuses reach normal dimensions. However, in 20% of cases their mucous membrane shows pathological changes.

Atypical eruption of teeth may occur both in the maxillary and the nasal region. Tonsillectomy is indicated from the same point of view as in normal patients, adenotomy and the removal of the posterior poles of the conchae, however, calls for a certain caution. It ought to be carried out only if hyperplasia of the tonsils is the cause of conduction deafness. Disorders in speech call for systematic logopaedic care. Rhinolalia aperta persistent after operation can be cured in many cases by a small pharyngeal flap pointing upwards.

RÉSUMÉ

Les spécialités des malades à bec-de-lièvre en otorhinolaryngologie

W. Schweckendiek

Les inflammations de l'oreille moyenne de même que les défauts de l'ouïe du type de transmission jouent un rôle assez important chez les malades à bec-de-lièvre. Le tout des inflammations chroniques si bien que des adhérences est visiblement élevé que chez la population normale. L'explication la plus simple c'est celle de la fonction

gâchée de la tube acoustique. Le nez du malade a bec-de-lièvre présente des problèmes esthétiques si bien que fonctionnels. La déviation septale au degrès important ainsi que l'aggrandissement du cornet nasal font assez souvent l'obstacle au passage de l'air.

Les cavités annexes sont le plus souvent normales; pourtant dans les vingt pourcents des cas les malformations trouvent lieu quand à la muquese. La sortie des dents atypique peut trouver lieu non pas seulement dans la région de la mâchoire elle-même, mais de même dans celle du nez. Les indications de la tonsilectomie sont pareilles à celles de l'individu normal. Pourtant l'adénotomie ainsi que l'ablation des cornets exigent un traitement à prudence extrême. Elle n'est a conseiller qu'au cas de la sourdité causée par l'hyperplasie des amendes. Les défauts de la parole exigent un traitement systématique. La rhinolalie aperte en suite de l'opération de la division palatine peut être amméliorée par un lambeau pharyngien en direction craniale.

RESUMEN

Las peculiaridades de los pacientes con la escisión de los labios y del paladar, para la otorhinolaringología

W. Schweckendiek

La enfermedad inflamatoria del oído medio y los trastornos auditivos de transmisión juegan un papel meritorio en los pacientes con escisión del paladar. El número de inflamaciones crónicas del oído medio y de los procesos adhesivos es mayor que en los habitantes normales. Causalmente se puede explicar por la función dañada de la trompa. La nariz del paciente con escisión ocasiona estéticamente problemas funcionales y cosméticos. La desviación en alto grado de la pared nasal y el aumento de la cóclea impiden a menudo el paso del aire. Los senos paranasal es alcanzan un tamaño normal pero en un 20% de todos los casos se encuentran cambios patológicos en la mucosa.

La posición atípica del diente se puede encontrar tanto en la región mandibular, como en la región nasal. La indicación de la tonsilectomía se determina según los mismos puntos de vista que en el hombre normal. En la adenotomía y en la eliminación de los extremos traseros de las cócleas es necesario determinada precaución. Esta se debe realizar solamente cuando la hiperplasia de las amígdalas es la causa de la falta de audición transmitiva. Los trastornos de la voz requieren un aprendizaje sistemático del habla. La rhinolalia abierta que queda después de la operación del paladar se puede en muchos casos eliminar hacia arriba en la dirección de la úvula faringeal.

LITERATUR

1. **Schweckendiek, W.**: Gaumen- und Lippenspaltenträger in der Praxis des Hals-Nasen-Ohrenarztes. HNO-Wegweiser 9, 103, 1961.
2. **Schweckendiek, W., Tamba, F.**: Die Nasennebenhöhlen bei Spaltträgern, HNO-Wegweiser 11, 72, 1963.

(Dr. W. Schweckendiek): 355 Marburg, Blitzweg 1, Bundesrepublik Deutschland

Indianapolis, Indiana (U.S.A.)

THE MANAGEMENT OF THE BILATERAL CLEFT LIP DEFORMITY
A Progress Report

J. M. TONDRA, T. B. BAUER, H. M. TRUSLER

In October of 1959, we initially published a description of a new concept in the surgical management of the bilateral cleft lip deformity (1). This paper was prompted by an evaluation of 132 cases of bilateral cleft lips which had been repaired by older technique, as well as 87 additional cases which had been operated by the revised technique published at that time.

It was the purpose of the original paper to present a two-stage technique for the repair of the bilateral cleft lip. This method was evolved because of dissatisfaction with the long term results obtained by a previous one-stage type of operative procedure.

At the time of that publication our experience covered a period of five years. Another five year period has elapsed since our original report. Consequently, we feel that it is time for a progress report to determine the relative difference, if any, or whether or not we have developed a change of attitude regarding this procedure.

There were several major points of reference which were considered in the alteration of management of the bilateral cleft lip which we would like to reiterate. First: was the management of the premaxilla, secondly, the role of the prolabium and third, the question of the technique of lip repair, that is one-stage repair versus the two-stage lip repair.

To reiterate our philosophy, we stated and repeat again, one cannot over emphasize the value of prolonged clinical observation in determining the success of a particular plan of management.

Many of the cases operated by the previous one-stage techniques seemed to have excellent results within the first few years after initial repair, but have later shown severe progressive growth deformities. The previous treatment consisted essentially of an oblique osteotomy of the mid-portion of the vomer, as described by Vaughn (2), in order to retroposition the maxilla, permitting a one-stage repair of the bilateral cleft lip as described by Brown and his Associates (3). However, as the child grew, the developmental deformities and growth disturbances of the lip and upper jaw became progressively more severe. The upper lip was inordinately shortened in its transverse length because of the apposition of the lateral lip flaps under the prolabium and the discarding

of the prolabial mucous membrane. Its vertical length became increasingly long due to the position of the lateral lip flaps under the prolabium.

Prolonged follow up of the cases repaired by this method indicated that a large percentage of the patients developed a middle third maxillary retrusion with progressive growth deformity, inhibition of growth of the middle third of the maxilla, as well as increased disproportion between the upper and lower lip. The upper lip grew progressively tighter, and the lower lip progressively more prominent as the child increased in age. This disproportion between upper and lower lip required, in most instances, an Abbe lip switch procedure to restore some semblance of balance in the soft tissue alone. Deformity of the dental arch and of the maxilla was almost irreparable except with the use of extensive orthodontia, prosthodontia, and in many instances supplemental bone grafts. In more severe instances, a resection of a portion of the mandible in order to better align the upper and lower jaws was required (4).

The current surgical repair of the bilateral cleft lip performed in two stages has offered great promise to date, in view of the fact that growth and development of the soft tissues of the lip, as well as growth and development of the maxillary arch is almost completely uninhibited. There has been no instance in our series where additional soft tissue in the form of an Abbe lip switch has been required to balance the soft tissue defect of the upper lip.

To clarify the method of technique of our surgical management of this problem, we will repeat the technique of the procedure involved. The lip is repaired one side at a time over the protruding premaxilla. Even though the premaxilla is in an abnormal position, we feel that the utilization of unilateral traction on the lip permits a more gradual retropositioning of the premaxilla and to a large extent minimizes the stress on the soft tissues of the upper lip as compared to simultaneous closure of both sides of the lip. As a rule the more extreme cleft is closed initially.

The two points in technique which we feel are of significant interest and importance are that the prolabium is utilized as the total vertical length of the central portion of the lip. Secondly, the prolabium is lined with mucous membrane from the lateral lip flaps in order to partially free the prolabium from its premaxillary attachment thus creating a more normal buccal sulcus upon completion of the surgery. We feel that this permits increased release of the base of the nose and the upper portion of the lip permitting better mobilization of the perinasal structures and permitting more normal forward and upward growth of the nasal tip.

Completion of healing of the primary side of the bilateral cleft thus converts the bilateral cleft, for practical purposes, into a unilateral cleft at the time of the secondary procedure. At the second operation, approximately 2 to 3 months following the initial procedure, a similar operation is carried out permitting the lateral mucous membrane flap to completely line the prolabium, thus creating mobilization of the soft tissue over the premaxilla.

To discuss our major points of differentiation regarding the utilization of this operative procedure over the one-stage bilateral cleft lip repair, we must

Fig. 1. Photographs which illustrate some of the deformities noted with our previous method of management: A. Pre-operative view of bilateral complete cleft lip deformity, B. Early post-operative view following procedure in which a portion of the vomer was resected and a one stage closure of the lip performed over the retro-positioned premaxilla, C. Appearance of profile at 5 years, D. Appearance despite columellar lift prior to Abbe lip switch at age 14.

point out that the management of the premaxilla in our hands, when surgically retropositioned, whether by sliding osteotomy or ostectomy, produced almost universally, a developmental retrusion of the middle third of the face. This problem since the advent of the two-stage procedure has been virtually eliminated.

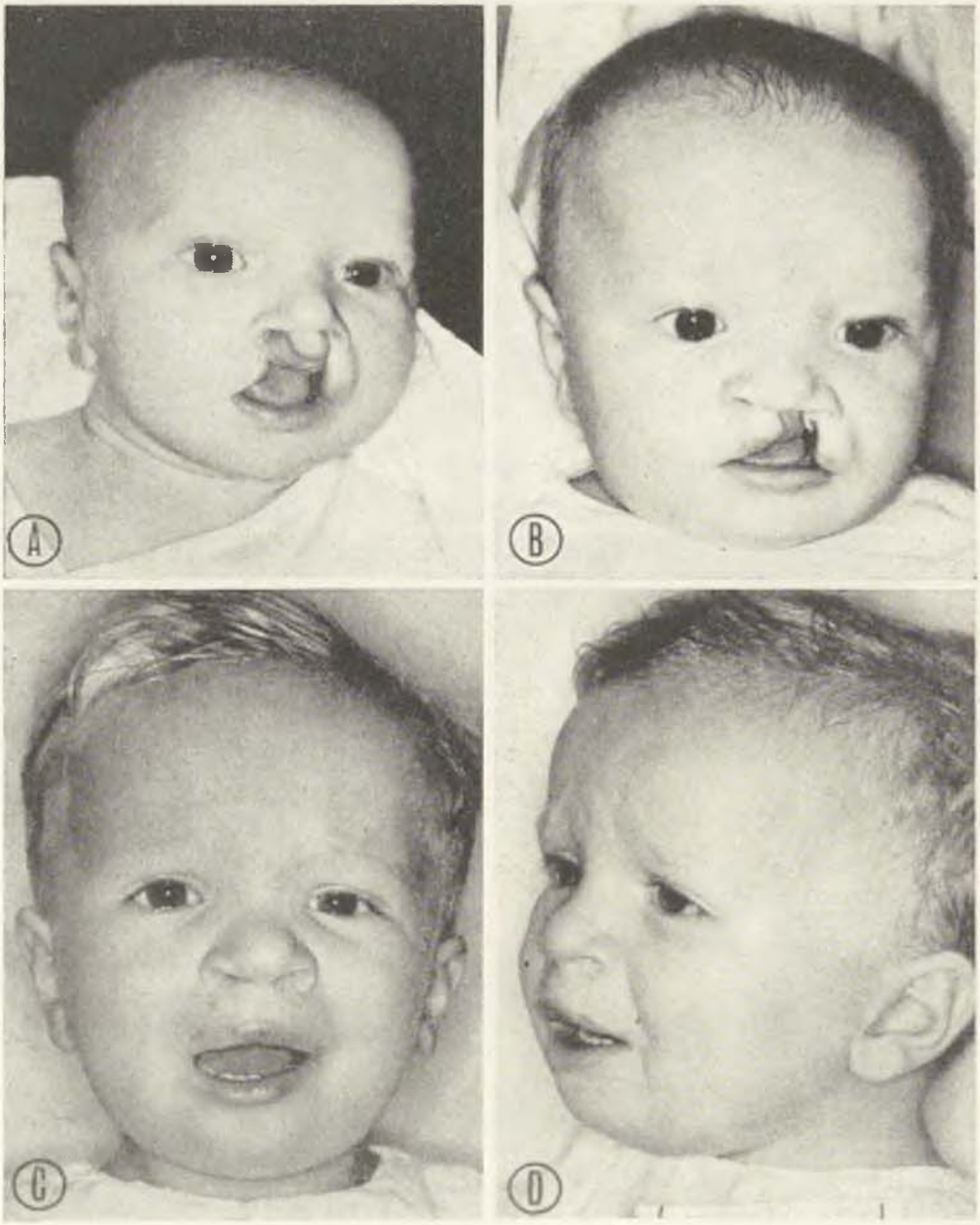

Fig. 2. A. Standard bilateral complete cleft lip deformity, B. Appearance following the repair of the right side of the cleft -- appearance now similar to unilateral complete cleft, C. Appearance following completion of second stage of repair.

The role of the prolabium has been discussed for many years by many authors, and was well being reviewed by Adams (5) in 1956. There is no doubt that Stark (6) and Erhman (7) in their review of the embryology of the upper

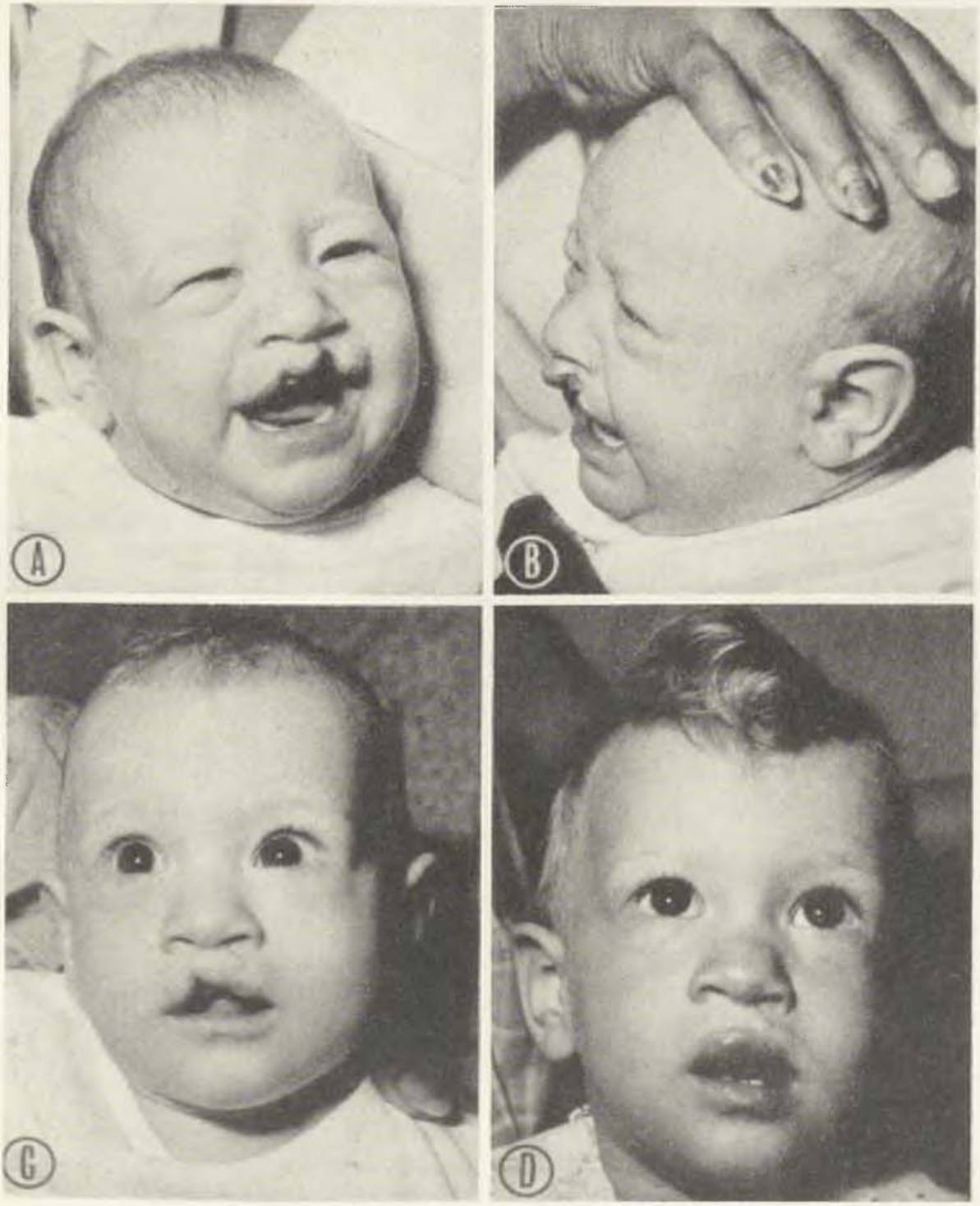

Fig. 3. A. Pre-operative bilateral partial cleft lip, B. Lateral view, C. Post-operative view following repair of left cleft, D. Appearance following repair of both sides.

lip have definitely shown that the prolabium forms the central portion of the upper lip. We have noted in utilizing the prolabium as the entire central portion of the upper lip, regardless of its initial size, that it has shown extremely rapid growth and development and in almost every instance has become more

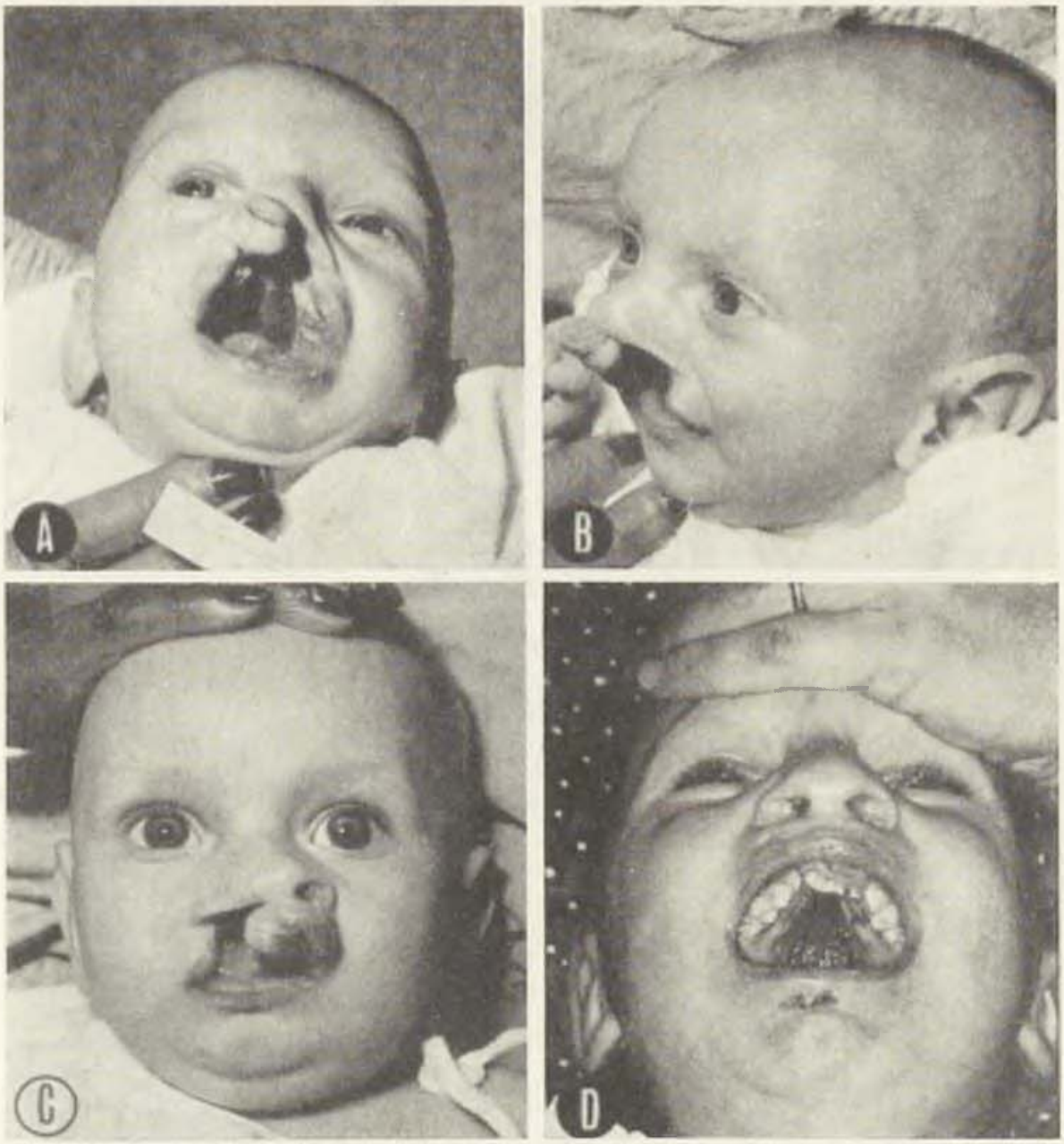

Fig. 4. A. Anterior view of severe bilateral complete cleft with severe protrusion of premaxilla, B. Lateral view, C. Appearance following closure of more severe cleft side, D. Alignment of lip and premaxilla following complete closure.

than adequate to fulfil its initial mission. We also note, in utilizing the mucous membrane of the medial portions of the cleft bilaterally to line the prolabium, that the growth and development of the central portion of the lip and mobilization of the columella and tip of the nose has been markedly improved, minimizing in many instances, the porcine appearance of the bilateral cleft nose.

This method of bilateral cleft lip repair in our hands has demonstrated the opportunity to preserve the maximum amount of soft tissue of the lip and

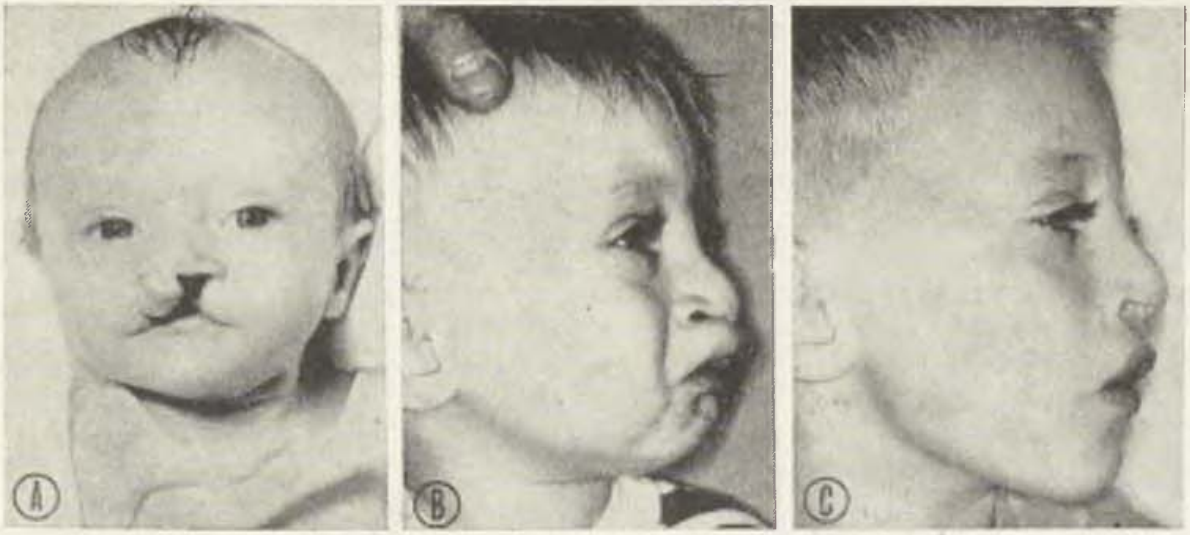

Fig. 5. Serial views of patient demonstrating profile appearance in severe bilateral cleft: A. Pre-operative appearance, B. Appearance at 18 months, C. Appearance at 6 years following columellar lift.

permits the maximum utilization of mucous membrane for lining the buccal side of the lip, thus permitting primary closure with a minimum of tension to the soft tissues and a more gradual retropositioning of the premaxilla due to the reduced tension.

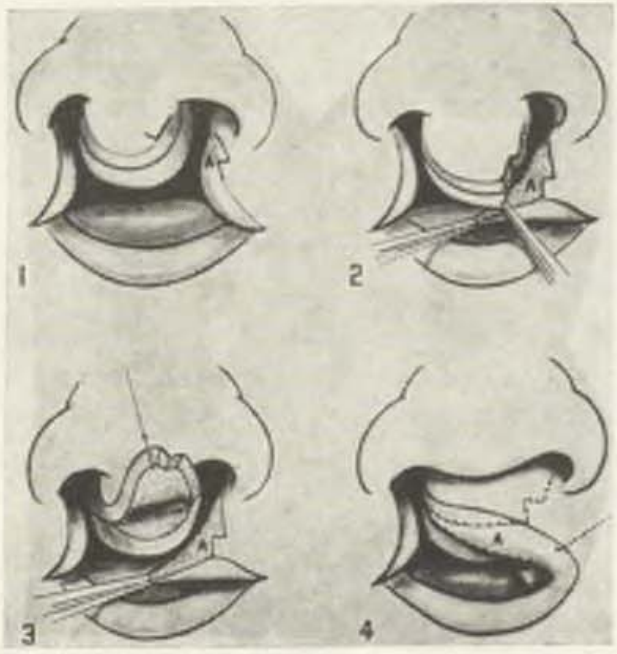

Fig. 6. Diagrams illustrating the technique of the first stage of the bilateral cleft lip repair. 1. Pre-operative view showing outline of incisions, 2. View after completion of incisions demonstrates: A. A submucosal surface of mucous membrane flap based laterally. 3. Dissection of prolabium from portion of premaxilla illustrating surface for approximation of flap A, 4. Closure of first stage.

Since our original report describing this procedure, there have been additional changes brought about due to the development of maxillary orthopedics (8) and early manipulation of the bony components of the maxilla, either prior to, or in conjunction with repair of the cleft lip. There is no doubt in our minds that maxillary orthopedics will play a very prominent role in the further development and progress in the repair of this deformity. However, to date, we

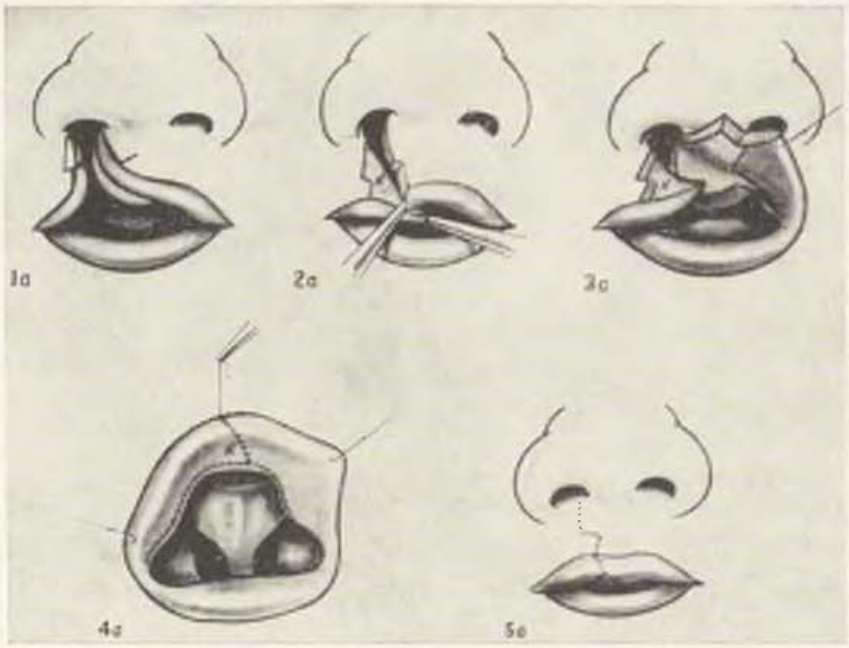

Fig. 7. Diagrams illustrating second stage of bilateral cleft lip repair: 1a. Illustrates outline of incisions on cleft and healed scar on previously repaired side, 2a. Development of flap A and mobilization of lip flaps, 3a. Complete mobilization of prolabium from premaxilla permitting complete lining to the prolabium with mucous membrane flap, 4a. Illustrates continunity of mucous membrane lining of lip and presence of buccal sulcus, 5a. View of bilateral closure.

have found that the management of the severely protruding premaxilla is extremely difficult, even in the face of current developments in maxillary orthopedics, and that ultimately this procedure must be assessed. In the past, as we have previously described, we have usually deferred orthodontia to align the maxillary segments and the premaxilla to approximately 3½ to 4 years of age. To date our planing is still along these lines, with the additional use of stabilizing bone grafts to fix the alignment of the maxillary arch once it has been expanded into proper relationships. We have performed this method of immobilization on a limited number of cases, pending continued observation, on early attempts at maxillary orthopedics.

Skoog's (9—10) excellent treatise on the management of the bilateral cleft lip embraces many of the concepts explained here. However, his primary maneuver stresses direct lengthening of the columellar without detachment of the prolabium. In our procedure, we stress lining of the prolabium with mucous

membrane in the primary procedure and performing the columellar lift as a secondary procedure at age of 5 years (11).

The procedure described, is certainly not to be construed in anyone's mind as being the last word in the treatment of the bilateral cleft. It merely points out that, in our cases, we have found, that the results are far superior to any other method that we have utilized. We would like to feel that the primary

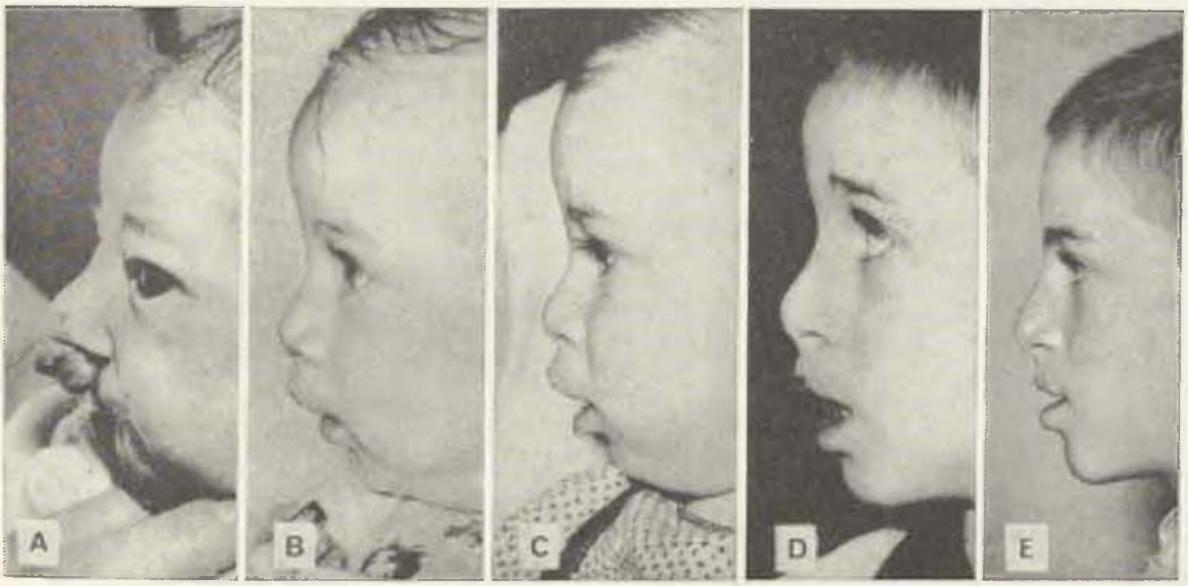

Fig. 8. Serial lateral views of bilateral complete cleft illustrating columellar development without surgical intervention — case initially shown in original paper. A. 2 weeks, B. 9 months, C. 2 years, D. 2 years, D. 5 years, E. 10 years.

repair of these deformities by this method, solves all of the future problems. However, due to the complex growth patterns and intrinsic abnormalities of the various segments of the lip and nose, this is an impossible situation. We do feel, however, that many of the previous complications have been minimized or eliminated as a result of this method of management.

The technique for this operation is demonstrated in the accompanying diagrams. This operation is usually performed under endotracheal anesthesia. The first stage of the operation, that is the first side of the lip, is undertaken between the ages of 2 and 6 weeks. The general anesthesia is supplemented with 1% Xylocaine with 1 to 100,000 Adrenalin. The prolabium and the lip flap on the side to be operated are infiltrated with this solution for the purpose of increased hemastasis and also as supplementary anesthesia to minimize the amount of general anesthetic required.

An incision is made along the lateral border of the prolabium at the mucocutaneous line, beginning at the level of the columella, down to a point where the mucocutaneous line begins to turn medially. This incision is carried down to the premaxilla. At this level, the prolabium is dissected free from the pre-

Fig. 9. Serial views of case illustrated in original article: A. Pre-operative at 2 weeks, B. 2½ months, C. 5 months, D. Anterior view 3 years, E. Lateral view 3 years, F. & G. Present appearance 8 years.

maxilla for approximately 50% of its attachment, just beyond the mid-line. This dissection is carried upward through the base of the columella towards the tip of the nose. The lateral mucous membrane of the prolabium is usually discarded due to the small amount, as well as the inherent abnormality of the tissue, although it may be used to cover the exposed premaxilla.

A lateral flap is then created by freeing the lip from its maxillary attachment. An incision is then made at the infra-alar groove downward along the mucocutaneous line to a point where the vermilion attains normal thickness. This incision does not go through the full thickness of the lip, but down to the level of the submucousa. The mucous membrane must be allowed to remain intact, so that a flap, based laterally, may be developed in order that it may be rotated under the prolabium, to line the subcutaneous surface of the prolabium, which was previously dissected from the premaxilla.

In most instances, it is highly desirable to gain increased length in the area of the lip closure, so that incisions from the infra-alar groove to the mucocutaneous flare on the lateral lip side is fashioned after the Tennison triangular flap (12), and the recipient site is created on the prolabial flap to permit proper closure.

The vermilion line of the prolabium is joined to the vermilion line of the lateral lip flap and the skin edges approximated with interrupted 5—0 black silk. The mucous membrane is closed with interrupted 4—0 Chromic catgut. The repair is carried into the floor of the nostril completing the operation on one side.

During the second stage of this procedure, the unlined portion of the prolabium is elevated and dissection from its premaxillary attachment completed. It will be noted that half of the prolabium is lined with mucous membrane as a result of the initial operation. This allows the prolabium to glide freely over the premaxilla. The gradual method of reducing the premaxilla to its normal position avoids the necessity for resection or osteotomy of the vomer. A Tennison type of closure is accomplished on the second side in a similar fashion to the original operation, since, for practical purposes, the defect is now a unilateral cleft. We recommend the Tennison approach to the closure, not only for gaining additional length to both the prolabium and lateral lip flap, but in order to improve the appearance of the lip by symmetrical philtral scars.

The premaxilla is not joined to the lateral maxillary process at this time. It is joined at the time of the cleft palate repair which in bilateral complete cleft is a two-stage procedure, the first stage enclosing the anterior portion of the defect by the vomer flap technique. The completion of the muscle sling over the premaxilla permits continued retropositioning of the premaxilla. Definitive positioning may require maxillary orthopedics, as well as stabilization by subsequent bone grafts.

The final stage in the repair of the deformity consists of a columellar lift (13) at about 5 years of age. This proceduce affords an opportunity to make any additional corrections or adjustments necessary to obtain the maximum benefits of surgery.

SUMMARY

We present a progress report after ten years of utilizing a two-stage bilateral cleft lip repair technique. Some of the major problems of growth and maldevelopment inherent in a previous technique appear to be eliminated or minimized. We do not propose this current technique as the last word in bilateral cleft lip repair, but we do present its as a considerable improvement over previous methods tried.

The technique may be enhanced by use of maxillary orthopedics and subsequent bone graft stabilization techniques now in vogue. We are employing them in a limited number of cases, but are still primarily following the early orthodontic treatment at 3½ to 4 years of age for definitive maxillary expansion and dental occlusion to be followed by bone grafting.

To reiterate our initial contention, we would like to make the following points:

1. There should be no surgical retropositioning of the premaxilla because of interference with growth and development of the middle third of the face.

2. The lip should be repaired in two stages over the premaxilla to utilize the maximum amount of soft tissue.

3. The prolabium should be utilized as the full length of the lip regardless of its initial size.

4. The prolabium should be released from the premaxilla and lined with mucous membrane.

5. The repaired lip furnishes the most satisfactory dynamic traction for retropositioning of the premaxilla.

6. Early orthodontia should be utilized to prevent or eliminate maxillary collapse, followed by bone grafting for stabilization of the maxillary arch.

RÉSUMÉ

La thérapie de bec-de-lièvre billatéral

J. M. Tondra, T. B. Bauer, H. M. Trusler

Les auteurs présentent les données d'évolution de dix années d'expérience chirurgicale de méthode en deux étapes du traitement du bec-de-lièvre billatéral. Quelques-uns des problèmes, touchant l'évolution normale et anormale que combattaient les méthodes d'autre fois, ont été éliminés ou déprivé de leurs maux. Pourtant les auteurs ne sont point d'avis de posséder le dernier cris quand à la thérapie du bec-de-lièvre, mais croient quand-même leur méthode d'être beaucoup plus efficace quand aux autres méthodes d'autre fois. Cette méthode peut être complétée par l'orthopédie maxillaire et plus tard encore, par la fixation à l'aide des transplants osseux, qu'on vient d'employer de nos jours. Malgré que les auteurs se servent et d'orthopédie et de la plastie osseuse dans certain nombre des cas, ils soulignent surtout la thérapie orthodontique précoce, à l'âge de trois, quatre et cinq ans pour obtenir l'élargissement définitif de l'os maxil-

laire et l'occlusion correcte. Cela une fois réalisé, ils pratiquent en surplus la plastie osseuse. Pour répéter leur conception primaire, les auteurs demandent la permission de conclure:

1⁰ Ils conseillent de ne pas pratiquer la rétroposition de l'os intermaxillaire faute d'intervenir dans le développement du tiercé médian de la figure.

2⁰ La réconstruction de la lèvre supérieurement a l'os intermaxillaire doit être réalisée en deux étapes afin de pouvoir utiliser le plus que possible des tissus moux se trouvant à notre disposition.

3⁰ Le philtrum doit être réalisé dans la pleine largeur de la lèvre sans se rendre compte de sa grandeur originale.

4⁰ Le philtrum doit être libéré de l'os intermaxillaire et doit être couvert par la muqueuse à sa partie orale.

5⁰ La lèvre réconstruite affecte elle-même le mieux la pression dynamique nécessaire à la rétroposition de l'os intermaxillaire.

6⁰ L'orthodontie précore devrait être pratiquée à la perfection afin d'empecher la déformation de maxillaire et en suite, la plastie osseuse pour obtenir la fixation de la courbe maxillaire.

ZUSAMMENFASSUNG

Die Behandlung der beiderseitigen Lippenspalte

J. M. Tondra, T. B. Bauer, H. M. Trusler

In der vorliegenden Arbeit berichten die Verfasser über ihre zehnjährigen Erfahrungen mit der zweizeitigen chirurgischen Behandlung der beiderseitigen Lippenspalte. Frühere Methoden stiessen auf Schwierigkeiten inbezug auf Wachstum und abnormale Entwicklung; diese Probleme konnten entweder zur Ganze oder zum Teil beseitigt werden. Die Verfasser halten ihre Methode nicht für das letzte Wort in der Behandlung der beiderseitigen Lippenspalte, betrachten sie jedoch als wesentlichen Fortschritt gegenüber früheren Behandlungsmethoden.

Die angeführte Methode kann durch Maxilla Orthopädie und spätere Fixierung mit Hilfe von Knochentransplantaten, wie sie gegenwärtig angewendet wird, ergänzt werden. Obwohl die Verfasser in einer beschränkten Anzahl der Fälle sowohl Orthopädie als auch Knochenplastik anwenden, legen sie vor allem auf die rechtzeitige orthodontische Behandlung im Alter von 3 bis 4 Jahren Nachdruck, um die definitive Erweiterung des Oberkiefers und eine richtige Okklusion zu erzielen; erst danach greifen sie zur Knochenplastik.

Ihre Konzeption fassen die Autoren dahingehend zusammen:

1. Die chirurgische Retroponierung des Zwischenkiefers wird nicht empfohlen, da sie ins Wachstum und in die Entwicklung des mittleren Gesichtsdrittels eingreift.

2. Die Rekonstruktion der Lippe über dem Zwischenkiefer soll zweizeitig durchgeführt werden, um das weiche Gewebe, das zur Verfügung steht, weitgehendst auszunützen.

3. Das Philtrum soll in der gesamten Lippenbreite ohne Rücksicht auf seine ursprüngliche Grösse rekonstruiert werden.

4. Das Philtrum ist vom Zwischenkiefer abzulösen und von der oralen Seite mit Schleimhaut zu decken.

5. Die rekonstruierte Lippe selbst ist am besten geeignet, den für die Retroposition des Kiefers notwendigen dynamischen Druck auszuüben.

6. Die Orthodontie ist frühzeitig anzuwenden, um das Zusammensintern des Oberkiefers zu verhindern; erst dann sollten Knochenspäne zur Fixierung des Oberkieferbogens angelegt werden.

RESUMEN

El tratamiento de la escisión bilateral del labio

J. M. Tondra, T. B. Bauer, H. M. Trusler

Damos una información sobre las experiencias de 10 años con el método quirúrgico de dos fases en el tratamiento de la escisión bilateral del labio. Algunos problemas correspondientes al crecimiento y al desarrollo anormal, con los cuales se encontraron los métodos anteriores, fueron eliminados, o si no su gravedad fué disminuída. No consideramos este método como la última palabra, correspondiente al tratamiento de la escisión bilateral, pero lo consideramos como una mejora esencial en comparación con los métodos anteriores.

Este método puede ser completado con la ortopedia maxilar y más tarde con la fijación de los injertos óseos, como los que se usan en la época actual. Aunque usamos tanto la ortopedia, como la plástica ósea en un número limitado de casos, aplicamos en primer lugar un tratamiento ortodóntico a la edad de 3 años y medio a 4 años con el fin de alcanzar una definitiva ampliación del maxilar superior y la correcta oclusión y recientemente después nos extendemos hacia los transplantes óseos.

Con el fin de repetir nuestra concepción original, recordamos esto:

1. No recomendamos la retroposición quirúrgica de la porción intermandibular, porque interviene en el crecimiento y en el desarrollo del tercio medio de la cara.

2. La reconstrucción del labio por encima de la porción intermandibular debe ser realizada en dos fases, para que aprovechemos lo más posible el tejido blando, que tenemos a disposición.

3. El filtro debe ser reconstruído a toda la anchura del labio sin tener en cuenta su tamaño original.

4. El filtro debe estar separado de la porción intermaxilar y en la parte oral, cubierto por la mucosa.

5. En labio reconstruído mejor efectúa la presión dinámica, necesaria para la retroposición mandibular.

6. La ortodoncia inmediata debería ser aplicada, para evitar el arruinamiento del maxilar y recientemente después, se deberían colocar los transplantes para fijar el arco maxilar.

REFERENCES

1. **Bauer, T. B., Trusler, H. M., Tondra, J. M.:** Plast. reconstr. Surg. 24 : 321, 1959.
2. **Vaughn, H. S.:** Plast. reconstr. Surg. 1 : 240, 1946.
3. **Brown, J. B., McDowell, F., Byers, L. T.:** Surg. Gynec. Obstet. 85 : 20, 1947.
4. **Trusler, H. M., Bauer, T. B., Tondra, J. M.:** Plast. reconstr. Surg. 16 : 147, 1955.
5. **Adams, W. M., Adams, L. H.:** Plast. reconstr. Surg. 12 : 225, 1953.
6. **Stark, R. B.:** Plast. reconstr. Surg. 13 : 20, 1954.
7. **Stark, R. B., Ehrmann, N. A.:** Plast. reconstr. Surg. 29 : 625, 1962.
8. **Brauer, R. O., Cronin, T. D., Reaves, E. L.:** Plast. reconstr. Surg. 29 : 13, 1962.
9. **Skoog, T.:** Plast. reconstr. Surg. 35 : 34, 1965.
10. **Skoog, T.:** Plast. reconstr. Surg. 35 : 140, 1965.
11. **Cronin, T. D.:** Plast. reconstr. Surg. 21 : 417, 1958.
12. **Tannison, C. W.:** Plast. reconstr. Surg. 9 : 115, 1952.
13. **Marcks, K., Trevaskis, A., Payne, M.:** Plast. reconstr. Surg. 20 : 466, 1957.

(J. M. Tondra, M. D.): 400 Hume Mansur Building, Indianapolis, USA

Klinik Dr. Schweckendiek für Hals, Nase, Ohren, Lippen, Kiefer, Gaumenspalten
Marburg (Bundesrepublik Deutschland)

DIE TECHNIK DER PRIMÄREN VELOPLASTIK UND IHRE ERGEBNISSE

W. SCHWECKENDIEK

Die klassischen Operationen bei der chirurgischen Behandlung der Gesichtsspalten führten noch vor wenigen Jahrzehnten zu schweren Verstümmelungen des Kiefers und zu Verbildungen des Mittelgesichtes, deren bekannteste Anomalie die hochgradige Pseudoprogenie ist. Bei der Untersuchung der Ursachen dieser postoperativen Kieferverbildungen liess sich nachweisen, dass neben unsachgemässen Lippenplastiken in erster Linie der Uranoplastik eine ursächliche Bedeutung für die sekundären Schäden des Kiefers zukommt. Andererseits war festgestellt worden, dass die frühzeitige Operation des Gaumens zwar mit Kieferdeformierungen einhergeht, dass aber die Sprache bei den Frühoperierten im allgemeinen besser war als bei den später operierten Patienten.

Die primäre Veloplastik, beruhend auf einem Gedanken, den Passavant vor über 100 Jahren geäussert hatte, wurde von H. Schweckendiek systematisch in die Behandlung der Lippen-Kiefer-Gaumenspalten eingeführt. Die frühe Verei-

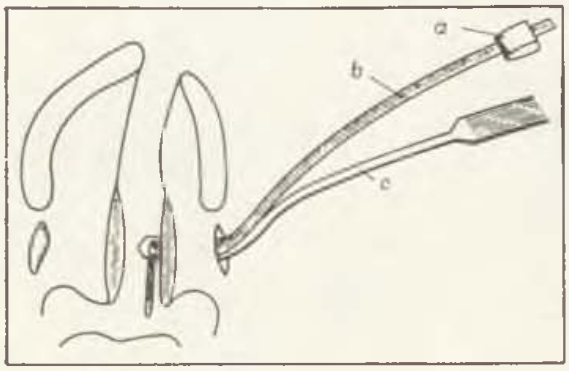

Abb. 1.



Abb. 2.

Abb. 1. Die Spaltkanten des weichen Gaumens sind präpariert und beiderseits die Seitentaschen angelegt. Mit der Führungsnadel I — schwächere Krümmung — wird das Halteband in die linke Seitentasche eingeführt; a) — Schaumgummikeil, b) — Gummihalteband, c) — Führungsnadel I. — Abb. 2. Nach Umfädeln des Haltebandes in die stärker gekrümmte Führungsnadel II wird die rechte Seite des weichen Gaumens von hinten umfasst. Die Spitze der Nadel erscheint in der rechten Seitentasche (*x*); c) — Führungsnadel II).

nigung des Gaumensegels sollte zu Beginn der Sprachentwicklung eine günstige Funktion der Sprechwerkzeuge ermöglichen. Andererseits sollte die Unberührtheit des harten Gaumens die operativ bedingten Kieferdeformierungen vermeiden. Die Technik der Operation ist einfach und stellt bei Säuglingen eine wesentlich geringere Gefährdung dar als die operative Versorgung des gesamten Gaumens.

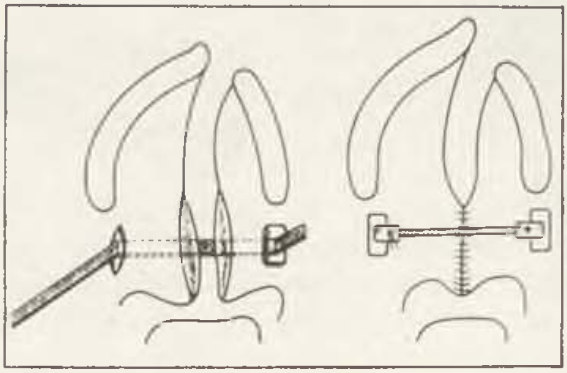

Abb. 3. Abb. 4.

Abb. 3. Halteband eingeführt. Die gestrichelte Linie deutet die Lage des Gummibandes auf der Rückseite des Gaumens an. Es folgt die schichtweise Naht der Spaltränder. — Abb. 4. Veloplastik beendet. Beide Schaumgummikeile liegen in den Seitentaschen. Oral verbindet ein lockerer Sicherungsfaden aus Supramid die beiden freien Enden des Haltebandes.

Als Operationstermin für die Erstoperation wird der 7 bis 8 Lebensmonat gewählt. Die Säuglinge haben dann durchschnittlich ein Gewicht von etwa 7—8 kg.

Entsprechend den beigefügten Abbildungen besteht die Technik in der Darstellung der Schichten der Spaltränder, des weichen Gaumens und der Anlegung von Seitenschnitten, durch die hinter dem Gaumensegel mit speziellen Führungsnadeln ein Gummi-Halteband herumgeführt wird.

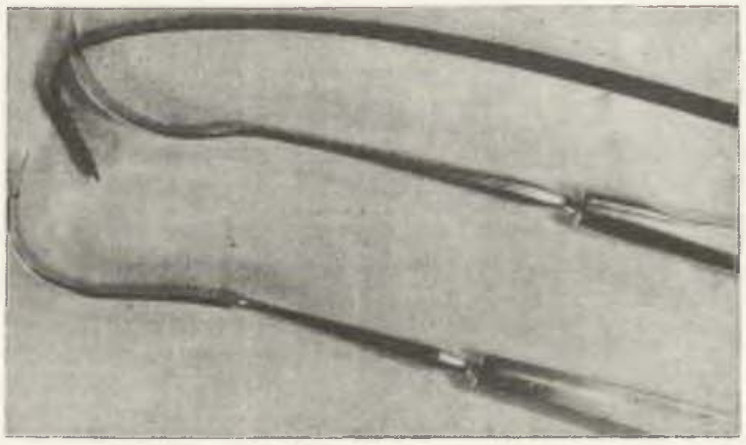

Abb. 5. Führungsnadel I (mit Halteband aus Gummi) und II zur Veloplastik. Gesamtlänge: 20 mm. Breite der Nadel: 6 mm.

Abb. 6.

Abb. 7.

Abb. 6. E. A., 7 Monate. Sehr breite totale Lippen-Kiefer-Gaumenspalte rechts: Kieferspalt 14 mm, Gaumenspalte 16 mm. — Abb. 7. Dasselbe Kind, 9 Monate. Zustand nach primärer Veloplastik und Lippen- und Nasenbodenplastik rechts.

An dem Halteband ist ein Schaumgummi-Keil angebracht, der sich in die linke Seitentasche einfügt. Nach Einführung des Haltebandes wird zunächst die schichtweise Naht des weichen Gaumens in der Mittellinie vorgenommen. Am Schluss der Operation wird in die rechte Seitentasche ein Schaumgummi-Keil auf das Halteband aufgezogen und ein lockerer Sicherungsfaden aus Supramid oral zur Verbindung der beiden Halteband-Enden gelegt. Nur bei sehr breiten Gaumenspalten — über 12 mm Breite — erweist es sich als zweckmässig, die Hamuli beiderseits zu luxieren, um seine spannungsfreie Naht des Gaumensegels zu ermöglichen. Das Halteband wird nach 7 Tagen entfernt. Eine weitere Tamponade der Seitentaschen ist nicht notwendig. Die Fäden der Gaumennaht bleiben etwa 18 Tage liegen. Die Supramid-Fäden werden reizlos in der Schleimhaut vertragen.

Das Halteband, dass in dieser Form seit 1950 regelmässig verwendet wurde, ergibt eine ausgezeichnete Sicherung der Gaumenplastik. Bei unseren Fällen

Abb. 8. Dasselbe Kind, 4 Jahre alt. Schmaler Restspalt im harten Gaumen (4 mm). Recht guter Alveolarbogen, Kieferregulierung im Spaltbereich noch notwendig. Sprache nahezu normal.

liegt die Zahl der Misserfolge unter 1 %. Das Halteband umfasst die Muskulatur so schonend, dass später eine Narbenbildung kaum festgestellt werden kann und dass ein funktionstüchtiges bewegliches Gaumensegel erzielt wird.

Bei den totalen Lippen-Kiefer-Gaumenspalten wird nach der primären Veloplastik nach 3 Wochen die Lippen-Naseneingangsplastik angeschlossen. Bei den doppelseitigen totalen Lippen-Kiefer-Gaumenspalten wird die erste Lippenspalte

Abb. 9.

Abb. 10.

Abb. 11.

Abb. 9., 10., 11. F. J., 11 Jahre. Zustand nach totaler Lippen-Kiefer-Gumenspalte rechts. Im ersten Lebensjahr primäre Veloplastik und Lippen-Nasenbodenplastik rechts. — Abb. 9. Kieferorthopädische Platte zur Regulierung der Zähne im Spaltbereich. — Abb. 10. Restspalt im harten Gaumen. — Abb. 11. Zustand nach Uranoplastik im Alter von 16 Jahren.

3 Wochen v o r der Veloplastik, die zweite Lippenspalte 3 Wochen n a c h der Veloplastik operativ versorgt. Die Spalten des weichen Gaumens werden vollständig geschlossen. Bei den Spalten des harten und weichen Gaumens bleibt ebenfalls ein Restspalt im harten Gaumen bestehen.

Der Restspalt im harten Gaumen macht den Patienten kaum Beschwerden. Nur bei 3 % der nachuntersuchten Patienten wurde über geringe Beschwerden geklagt. Im allgemeinen tritt Gewöhnung ein. Einige Kinder tragen temporär eine flache Gaumenplatte, die den Restspalt abdeckt und eine noch günstigere Sprachentwicklung ermöglicht. Bei den totalen Lippen-Kiefer-Gaumenspalten wird gleichzeitig die notwendige kieferorthopädische Behandlung durchgeführt.

Die Sprachentwicklung nach der primären Veloplastik ist recht günstig, insbesondere können die tiefen Artikulationsstellen bei der Sprachbildung vermieden werden, d. h. die Zahl der Ersatzlaute ist wesentlich geringer als bei nicht operierten Gaumen. Spalten des weichen Gaumens allein bekommen spontan in über 90 % eine normale Sprache. Alle übrigen Spaltbildungen haben in über 70 % eine gute Umgangssprache. Bei 20 % bestehen stärkere Sprachfehler, während in höchstens 8 % ein ungenügendes Sprechergebnis vorliegt. Diese Ergebnisse decken sich durchaus mit denen anderer Operateure, bei denen der gesamte Gaumen verschlossen wird.

Sehr viel günstiger liegen aber die Ergebnisse der Kieferbildung. Kieferdeformierungen im Sinne von Pseudoprogenien und stärkeren Kieferkompressionen kommen praktisch nicht vor. Die Patienten zeigen eine Grössenentwicklung des Alveolarbogens, die den Messwerten normaler Kinder entspricht, wie unsere Nachuntersuchungen bei ein- und doppelseitigen totalen Spaltbildungen gezeigt haben. Daneben können wir feststellen, dass sich eine Verschmälerung des Spaltes im harten Gaumen in fast allen Fällen ergibt. Vor allem gestaltet sich die relative Gewebszunahme der seitlichen Gaumenanteile im Verhältnis zu dem Spaltbereich so günstig, dass später ohne Schwierigkeit ein Verschluss des Spaltes im harten Gaumen möglich ist. Den Verschluss des Restspaltes im harten Gaumen führt man zweckmässigerweise erst nach Abschluss des Kieferwachstums, im Alter von 12 bis 14 Jahren aus, da dann die Gefahr einer sekundären Kieferverbildung nicht mehr gegeben ist. Entschliesst man sich früher zur Uranoplastik, so ist eine weitere kieferorthopädische Überwachung und Behandlung unbedingt notwendig.

Das von uns ausgeübte Verfahren bringt für den Patienten nur ein geringes Operationsrisiko. Es ermöglicht eine gute Sprachentwicklung und gibt ein optimales Wachstumsergebnis des Kiefers. Seitdem wir das Verfahren seit über 15 Jahren systematisch verwenden und feststellen können, dass die Sprache ebenso wie die Kieferentwicklung den an die Spaltenchirurgie gestellten Anforderungen vollauf genügen, werden wir das Verfahren auch in Zukunft weiter verwenden und können es mit gutem Gewissen zur Nachahmung empfehlen.

ZUSAMMENFASSUNG

Die Fehlbildungen des Kiefers bei Patienten mit Lippen-Kiefer-Gaumenspalten sind teilweise anlagebedingt und betreffen in erster Linie den Spaltbereich. Der grössere Teil der schweren Fehlbildungen ist aber häufig operationsbedingt. Nach der primären Veloplastik mit nachfolgender Lippen- und Naseneingangsplastik besteht dagegen ein ungestörtes Kieferwachstum. Die Operationstechnik ist einfach und kann im Alter von 7 bis 8 Monaten ohne Schwierigkeiten ausgeführt werden.

Die Kieferentwicklung verläuft nach dieser Operation regelrecht. Die noch bestehenden anlagebedingten Kieferdeformierungen sind einer orthodontischen Behandlung leicht zugängig. Die Sprachentwicklung ist bei langem und gut beweglichem Gaumensegel trotz des Restspaltes im harten Gaumen günstig. Der Verschluss des Restspaltes wird zweckmässigerweise erst nach Abschluss des Kieferwachstums im Alter von 12 bis 14 Jahren ausgeführt. Der Restspalt kann temporär durch eine Gaumenplatte abgedeckt werden. Wird der Restspalt früher verschlossen, so ist eine kieferorthopädische Überwachung notwendig, um eine Kieferkompression zu vermeiden.

SUMMARY

Surgical Technique of Primary Veloplasty and its Results

W. Schweckendiek

Malformations of the jaws in patients with clefts of lip, jaw and palate are partly based on genetic factors mainly affecting the region of the cleft. A large percentage of malformations, however, develop as a result of surgery. After primary veloplasty with subsequent reconstruction of the lip and the nostril threshold, growth of the maxillae usually remains unaffected. Surgical technique of this operation is simple and may be carried out without any difficulty at the age of seven to eight months.

After this operation, the maxillae develop normally and any deformity based on genetic factors is easily accessible to orthodontic treatment. With a long and well mobile soft palate, speech develops favourably despite some remnants of the cleft in the hard palate, whose closure is best deferred to the age between 12 and 14, because at that period the maxillae have ceased to grow. In the meantime the residual openings in the hard palate can be covered by a palatine plate. If surgical closure of these remnants of the palatine cleft are undertakten earlier, maxillo-orthopaedic supervision in order to prevent maxillary compression, is imperative.

RÉSUMÉ

La technique de la véloplastie précoce et ces résultats

W. Schweckendiek

Les malformations des mâchoires chez les malades souffrant de bec-de-lièvre complèt sont partiellement innées et comportent le plus souvent la région de la division. Mais, malheureusement, une partie bien importante de ces malformations est une séquelle postopératoire. Ceci, au contraire, n'est jamais à trouver chez ceux des malades, qui ont passé à la véloplastie précoce accompagnée par la plastie narinaire. La technique opératoire est facile et c'est pourquoi elle peut être réalisée sans difficulté respective déjà à l'âge de 7—8 mois.

Le développement des mâchoires continue tout à fait normalement après cette opération. Les éventuelles malformations en suite de celle primaire répondent facilement au traitement orthodontique. Le développement de la parole est favorable en mépris de la division persistante de la voûte palatine osseuse, à condition que la voile du palais est assez longue et mobile. Le fermeture du palais osseux ne trouve lieu qu'après l'achèvement du développement des mâchoires, c'est — à dire à l'age de 12—14 ans. Si nécessaire, la division peut être couverte par un plat. Au cas de la fermeture précoce, de la division, un traitement orthodontique devient nécessaire faute d'empêcher une compression des mâchoirs.

RESUMEN

La técnica primaria de la veloplástica y sus resultados

W. Schweckendiek

Las malformaciones de las mandíbulas en los pacientes que padecen de escisión de los labios, de las mandíbulas y de los paladares están en parte condicionadas por la disposición y se tratan primeramente de las de la zona de las escisiones. La mayor parte de las malformaciones más graves es producto de las operaciones. Después de

la veloplástica primaria seguida de la plástica de los labios y de la entrada nasal, al centrario es frecuente el crecimiento inalterable de la mandíbula. La técnica operatoria es sencilla y puede ser realizada sin dificultados a la edad de 7 a 8 meses.

El desarrollo de la mandíbula después de la operación transcurre normalmente. Las deformaciones perdurables de la mandíbula, condicionadas por la disposición, son fácilmente asequibles al tratamiento ortodóntico. El desarrollo del lenguaje es favorable, cuando existe un paladar blando, largo con buena movilidad, aún en presencia de un residuo de la escisión en el paladar duro. El cierre del residuo de la escisión se puede realizar efectivamente recién terminado el crecimiento de la mandíbula a la edad de 12 a 14 años. El residuo de la escisión se puede temporalmente cubrir con un disco del paladar. Si se cierra antes el residuo de la escisión, es necesaria una atención de tipo mandíbulo-ortopédica con el fin de evitar la compresión de la mandíbula.

LITERATUR

1. **v. Hinüber, E.:** Sprachergebnisse nach Operation von Gaumenspalten bei der Primären Veloplastik. Dissertation, Marburg 1963.
2. **v. Hinüber, E.:** Die Kieferbildung nach der Primären Veloplastik (unter besonderer Berücksichtigung der einseitigen totalen Lippen-Kiefer-Gaumenspalten). Dissertation, Marburg 1964.
3. **Lattermann, J. P.:** Die Behandlung der doppelseitig-totalen Lippen-Kiefer-Gaumenspalte nach dem Vorgehen von Schweckendiek. Dissertation, Marburg 1964.
4. **Schweckendiek, H.:** Z. Laryng. (Stuttgart) 30, 51, 1951.
5. **Schweckendiek, H.:** Fortschr. Kiefer-Ges.-Chir. I, 73, 1955. Thieme-Verlag, Stuttgart.
6. **Schweckendiek, W.:** Die Spaltbildungen der Lippe, des Kiefers und des Gaumens. In HNO-Heilkunde. Herausgegeben von Berendes, Link, Zöllner. Bd. II, 1, Thieme-Verlag, Stuttgart 1963.
7. **Schweckendiek, W.:** Arch. Ohr-Nas.-Kehlk.-HK 180, 541, 1962.
8. **Schweckendiek, W.:** Chirurg 34, 277, 1963.

(Dr. W. Schweckendiek): Blitzweg 1, 355 Marburg/Lahn, Bundesrepublik Deutschland

Klinik und Poliklinik für Mund-, Zahn, Kieferkranke der Universität Heidelberg,
Heidelberg (Bundesrepublik Deutschland)
Direktor: Prof. Dr. Dr. R. Ritter

FUNKTIONELLE GESICHTSPUNKTE BEI DER SPALTOPERATION OHNE KNOCHENPLASTIK

R. RITTER

Unter den Spaltchirurgen besteht Einigkeit darüber, dass die Lippenspalte im ersten Lebensjahr, etwa mit sechs Monaten, operiert werden soll, wenn das Kind gut entwickelt ist. Dagegen gibt es, was die Operation der Kiefergaumenspalte anbetrifft, zwei Gruppen von Operateuren: 1. die Vertreter der Frühoperation im Alter von 1—3 Jahren und 2. diejenigen, welche die Operation später, etwa im Alter von fünf Jahren vornehmen. Beide Gruppen haben das Ziel, die chirurgische Behandlung bis zum Schulbeginn zu beenden und den Sprachunterricht so zeitig wie möglich unter Berücksichtigung der Intelligenz beginnen zu lassen. Die Befürworter der Frühoperation behaupten, dass das Kind früher und besser sprechen lerne. Es ist aber andererseits bekannt, dass der Kieferknochen in den ersten Lebensjahren sehr weich ist und dass durch Ablösung der Gaumenschleimhaut und die nachfolgenden Narbenplatten starke Deformierungen des Oberkiefers und des Mittelgesichtes sich ergeben. Diese Oberkieferdeformierung führt zu einer Verschlechterung der Sprache bereits bei Schulbeginn, die Kaufunktion ist behindert, Oberkiefer und Mittelgesicht bleiben im Wachstum zurück. Es entsteht das typische Bild der Progenie oder Retrognathie. Das Kind ist körperlich geschädigt, es ist dem Spott der anderen Kinder ausgesetzt. Zu dem körperlichen kommt der seelische Schaden, der oft noch schwerer zu werten ist. Durch die Frühoperation wird also nichts gewonnen. In Erkenntnis dieser Nachteile ist nun in den letzten Jahren versucht worden, mit Hilfe eines in die Spalte eingesetzten Knochenspans die Deformation des Oberkiefers zu verhindern. Inzwischen hat sich aber gezeigt, dass durch die Knochenplastik allein die Deformation des Oberkiefers nicht aufzuhalten ist, die Kompression der Narbenplatten ist am weichen Oberkieferknochen stärker. Nur eine sofort nach der Operation folgende intensive orthopädische Kieferdehnung vermag die Kieferkompression und Gesichtsentstellung zu verhindern. Die orthopädische Kieferbehandlung des Kleinkindes und des Vorschulkindes ist schwierig, oft fehlt die Einsicht und die Gedult der Eltern zu Mitarbeit. Die jahrelange Behandlung zermürbt den vielleicht zuerst vorhandenen guten Willen. Die komplizierte orthopädische Behandlung kann nicht von jedem Zahnarzt ausgeführt

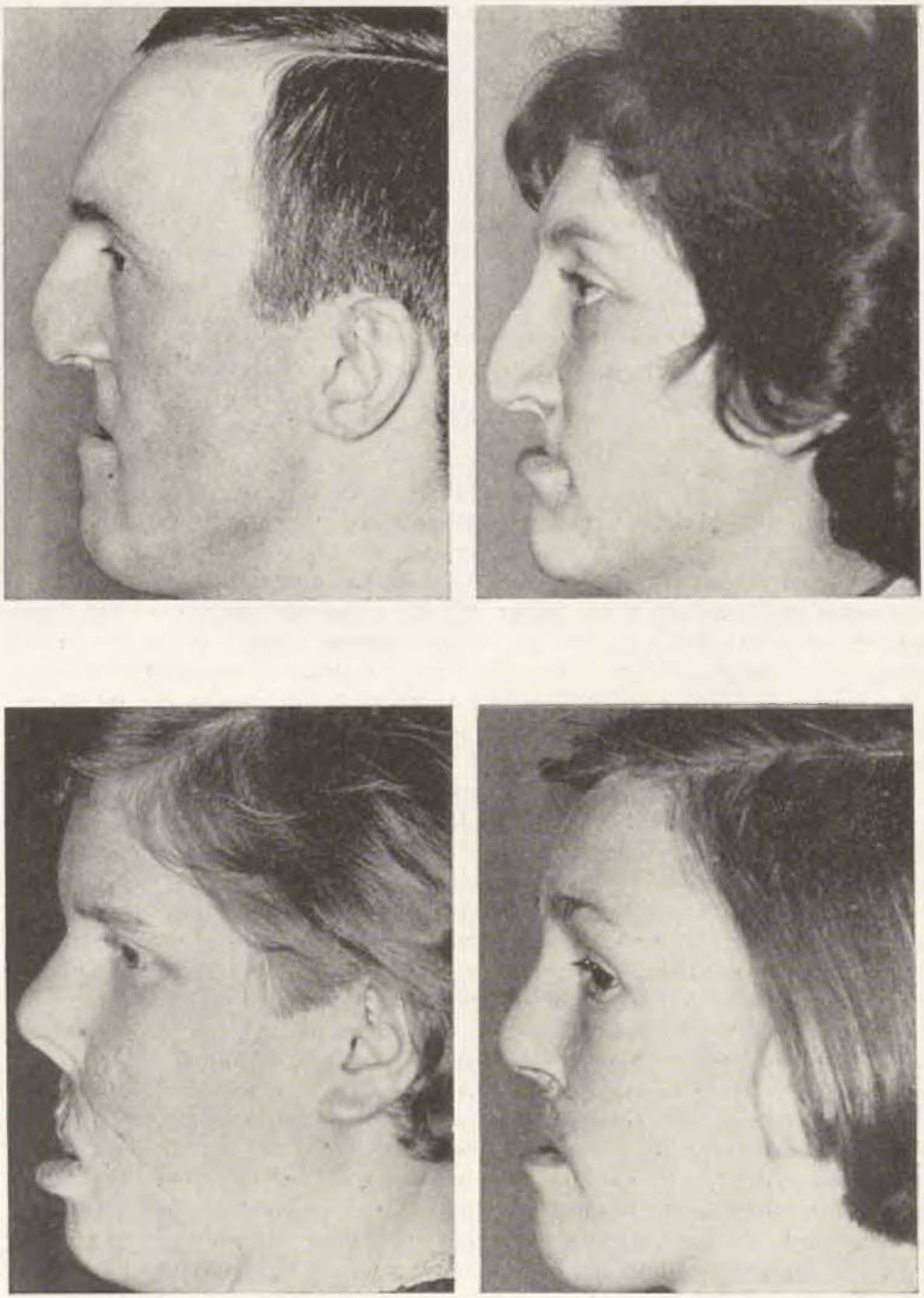

Abb. 1. Iatrogene Oberkiefer- und Mittelgesichtsdeformation durch Frühoperation der Kiefer-Gaumenspalte im 1.—2. Lebensjahr.

Abb. 2. Pat. Fi. 5 Jahre alt, normales Profil nach Lippen-Kiefer-Gaumenspaltoperation. Normale Okklusion im Seitenzahnbereich, Kopfbiss im Frontzahnbereich. I und II im Zahnwechsel. Keine orthodontische Behandlung.

werden, spezielle kieferorthopädische Fachkenntnisse sind notwendig. Nicht jedem Kieferchirurg steht ein Kieferorthopäde für die Fortführung der Behandlung nach den Operationen zur Verfügung. Die Kosten der Behandlung sind hoch, manche Kinder wohnen weit entfernt. Auch aus diesen Gründen scheitert die so notwendige orthopädische Nachbehandlung oft, zurück bleibt das körperlich und seelisch geschädigte Kind. Der Tatbestand der fahrlässigen Körperverletzung aus verschiedener Ursache wird offenbar, keiner will nun die Verant-

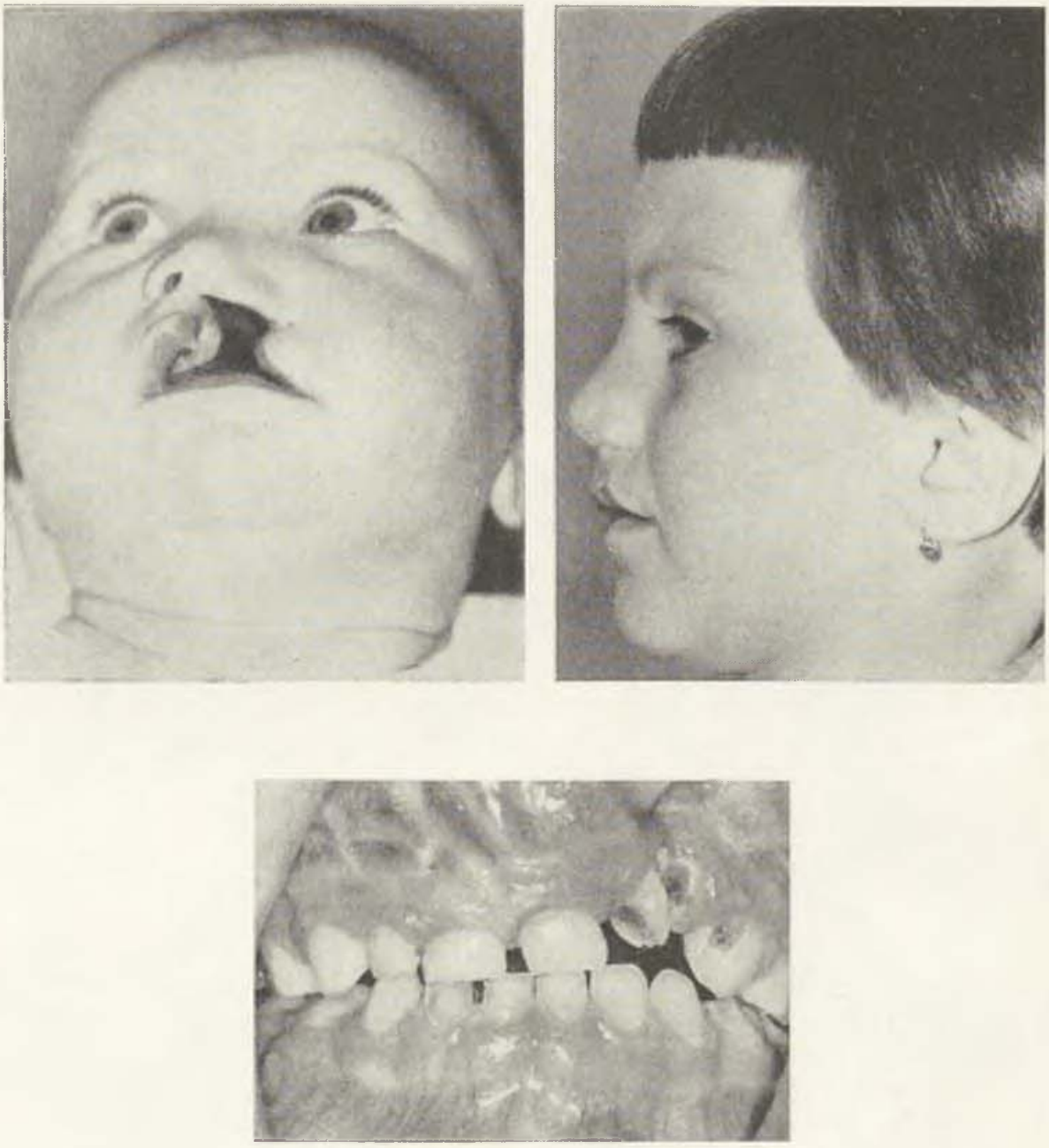

Abb. 3. Pat. He. 5 Jahre alt, normales Profil nach Lippen-Kiefer-Gaumenspaltoperation. Normale Okklusion im Seitenzahnbereich, Kopfbiss im Frontzahnbereich. Doppelanlage von II. Keine orthodontische Behandlung.

wortung dafür tragen, weder der Chirurg noch der Kieferorthopäde. Der Chirurg sagt, er habe lege artis operiert, die Nachbehandlung ist Sache des Kieferorthopäden, der aber oft nicht erfolgreich behandeln kann, weil die Behandlung wegen der oben erwähnten Gründe nicht möglich ist.

Abb. 1. Infolge der Oberkieferkompression mit seitlichem Kreuzbiss oder Nonocclusion sowie progen offenem Biss, ist die Aussprache der Lippen- und Gutturallaute schlecht, die Kinder scheuen sich zu sprechen. Neueste Unter-

suchungen aus der Hamburger Klinik von G. Lieb, und G. Mühlhausen beweisen, dass bereits bei Kindern ohne Gaumenspalte, die nur Gebissanomalien haben, starke Sprachfehler vorhanden sind. Um wieviel mehr sind diese Sprachfehler erst bei Kiefer- und Gesichtsdeformationen der Spaltkinder festzustellen!

Wegen dieser Nachteile der Frühoperation der Kiefergaumenspalten operieren wir deshalb die Kiefer-Gaumenspalten erst mit fünf Jahren. In diesem Alter ist der Kieferknochen viel fester als im Alter von 1—3 Jahren. Der Oberkiefer ist fast oder schon so breit wie später im Erwachsenenalter. Die Milchmolaren stehen miteinander in guter Okklusion, das ist ein ganz wesentlicher Gesichtspunkt, denn eine gute Kaufunktion verhindert nach der Operation die Kompression des Oberkiefers besser als ein orthopädischer Apparat. Wir betreiben also eine chirurgisch-funktionelle Therapie ohne Knochenplastik mit anschliessender Sprachschulung, so dass das Spaltkind bei Schuleintritt den gesunden Kindern gegenüber fast als gleichwertig beurteilt werden kann. Zur Operationstechnik ist nicht viel zu sagen: Zuerst wird der weiche Gaumen und der hintere Teil des harten Gaumens geschlossen, die Arteria palatina wird möglichst geschont. Das verbleibende Restloch im harten Gaumen wird 3—6 Monate später mit einem Türflügellappen gedeckt.

Es folgen nun der Sprachunterricht, Intelligenz- und Hörproben. Das Kind lernt ständig besser sprechen, weil ein normal geformter Oberkiefer die Lautbildung nicht behindert. Intelligenz, Sprachinteresse und normales Hörvermögen natürlich vorausgesetzt!

Wir haben viele Beweise dafür, daß mit dieser Operations- und Behandlungsmethode keine Kiefer- und Gesichtsentstellung hervorgerufen wird und daß die Spaltkinder zu vollwertigen Mitgliedern der menschlichen Gesellschaft heranwachsen.

Abb. 2, 3. Die chirurgisch funktionelle Behandlung ist einfach, sie beschränkt sich auf wenige Wochen Krankenhausaufenthalt. Jedes Spaltkind, auch das entfernt wohnende, kann mit dieser Methode erfolgreich behandelt werden.

ZUSAMMENFASSUNG

Es wird empfohlen, die Kiefer- Gaumenspalte erst im Alter von 5 Jahren zu operieren. In diesem Alter ist das Kieferbreitenwachstum fast beendet, der Kieferknochen ist fest und kann durch Narbenzüge nicht mehr so stark deformiert werden. Die weitere ungünstige Folge der Frühoperation im Alter von 1—3 Jahren sind Kieferanomalien, welche später die Sprache nachteilig beeinflussen.

SUMMARY

Functional Viewpoints in Operations for Cleft Without Bone Plasty

R. Ritter

The author does not recommend operating on cleft of jaw and palate before the age of five. At this age the jaw has ceased to grow in width and the maxilla is firm and cannot be deformed to any degree by the pull of scars. Maxillary anomalies which later affect speech, are another unfavourable effect of operations carried out at the age between one and three years.

RÉSUMÉ

Les raisons fonctionelles de l'opération des becs-de-lièvre sans l'usage de la plastie osseuse

R. Ritter

L'auteur conseille d'entreprendre les corrections des becs-de-lièvre et des fissures palatinales pas moins qu'à l'âge de cinq ans. A cette époque le développement de l'os maxillaire est accompli en toute largeur, l'os maxillaire est compacte si bien que la déformation par la traction des cicatrices ne peut plus être tellement exprimée. Une autre suite très défavorable des opération précoces à l'âge d'une à trois années sont de nombreuses anomalies des maxillaires, lesquelles, plus tard, causent des troubles de la parole.

RESUMEN

El punto de vista funcional en la operación de las escisiones sin la plástica ósea

R. Ritter

Se recomienda operar las escisiones de la mandíbula y de los paladares hasta que se tenga 5 años de edad.

En esta edad el crecimiento de la mandíbula, en anchura, está casi terminado, el hueso mandibular está firme y no puede ser tan fuertemente deformado por la tracción de las cicatrices. Otra consecuencia desfavorable de las operaciones anticipadas en las edades de 1 a 3 años, son las anomalías mandibulares, que más tarde influyen desfavorablemente sobre el lenguaje.

LITERATUR

1. **Burian, F.**: Chirurgie der Lippen-Kiefer-Gaumenspalten. VEB-Verlag- Volk und Gesundheit, Berlin 1959.
2. **Gabka, J.**: Hasenscharten und Wolfsrachen. Verlag Walter de Gruyter, Berlin 1964.
3. **Ritter, R.**: Langenbecks Arch. klin. Chir. 311, 1965.
4. **Ritter, R.**: Beurteilung des Zwischenkiefers bei Spaltkindern. Fortschritte der Kiefer- und Gesichtschirurgie. V, 1959, Thieme-Verlag, Stuttgart.
5. **Ritter, R.**: Kritische Betrachtungen zur Stimulationsplatte nach Mc Neil für die Behandlung von Spaltkindern. D. Z. Z. 7, 1961.

(Prof Dr. R. Ritter): Wielandstr. 29, 69 Heidelberg, Bundesrepublik Deutschland

CLINICAL OBSERVATION ON THE SPONTANEOUS REGENERATION OF THE MANDIBLE

Fig. 1. January 21st, 1954. Tumor of mandible with appearance of typical dentigenous cyst.

Fig. 2. October 7th, 1954. Eight months later defect is filled with bone.

Fig. 4.

Fig. 5.

Figs. 4, 5. March 10th, 1955. Antero-posterior and bas al views showing the extend of multicystic tumor and destruction of mandible.

Fig. 6.

Fig. 7.

Fig. 8.

Fig. 6. August 26th, 1955. Early stage of regeneration of the mandible from periosteal wall of cavity. — Fig. 7. December 11th, 1955. Further stage of regeneration and moulding. — Fig. 8. November 21st, 1958. Regeneration of mandible completed. Note presence of "new" wisdom tooth.

Fig. 9.
Extent of recurrent adamantinoma of left mandible.

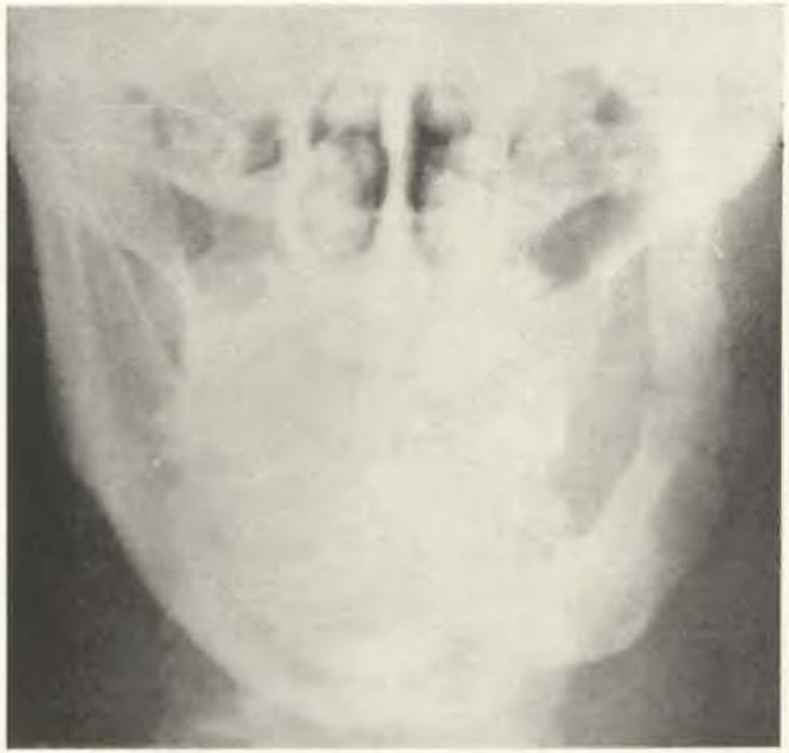

Fig. 10.
Bone graft in place of resected tumor

Medical Arts Clinic, Regina-Saskatchewan (Canada)

CLINICAL OBSERVATION ON THE SPONTANEOUS REGENERATION OF THE MANDIBLE

J.P. SZLAZAK

It is a well recognized fact that bone healing takes place by regeneration of osseous tissue or from periosteum. It is of clinical and prognostic interest, however, to determine what quantitive regeneration will occur under specified circumstances. Three patients, each with a previous diagnosis of adamantinoma of the mandible, treated more than ten years ago without recurrence and without residual defect or reduced function, are presented.

Fig. 3.

Patient 1. A 13-year-old boy developed a tumour, 5 centimeters long involving the antero-lateral portion of the mandible within a period of two months. Radiological interpretation of the lesion suggested the diagnosis of dentigerous cyst but histological examination revealed the lesion to be adamantinoma. The tumour was removed by enucleation only. Within a period of eight months the continuity of the bone was restored and the mandible present-

Figs. 11, 12. Functional result.

ed a normal appearance with the exception that a tooth socket, displaced originally by tumour pressure, remained (Fig. 1, 2).

The normal bone structure in this patient was restored by osseous regeneration.

Patient 2. Was also a boy of 13 years of age. A rapidly growing tumour involving the left transverse and ascending rami of his mandible and occupying the pterygomandibular fossa caused marked deformity of his face (Fig. 3, 4, 5). Radiological examination revealed a multi-cystic tumour totally destroying the bone. Surgical exploration revealed that the periosteum was intact. The large lesion, consisting of four separate but contiguous cysts, was enucleated subperiosteally. This procedure was considered to be the only justifiable one.

The residual cavity was partially filled with two blocks of autogenous bone and multiple bone chips. The mandible was immobilized for a period of two months by inderdental wiring. Within three months the bone introduced into the cavity was extruded through a sinus opening into the mouth.

Despite the apparent lack of support, the function of the jaw was excellent. Over a period of 3½ years complete regeneration of bone and moulding to normal contour occurred (Figs. 6, 7, 8).

The indications are that the regeneration of bone in this patient was mainly periosteal in origin.

Patient 3. A woman, aged 23 years, had a cystic adamantinoma of the transverse ramus of the left mandible treated by currettage. Four years later she demonstrated clinical and radiological evidence of recurrence with swelling of the face caused by a multi-cystic lesion involving the transverse and

ascending rami. Multiple intra-oral fistulae and alveolar adhesions were present (Fig. 9).

Because of the factors of recurrence and of the complications, radical surgical resection was performed as the procedure of choice.

A direct autogenous bone graft was applied and fixation obtained by interdental and interosseous wiring. Within three months the function of the mandible was normal and satisfactory bone union obtained (Figs. 10, 11).

SUMMARY

These three patients demonstrate that the treatment of adamantinoma of the mandible may be dictated by factors, such as age, the extent of the bone destruction by tumour and the complications arising from inadequate surgery. The successful end result following the management of the first two patients indicates the value of complete eradication of the tumour by enucleation, together with the recognition of the potential regenerative ability of the bone tissue, and/or the periosteum.

In adult patients in which bone and periosteal regeneration is less active and especially in those in whom there are other complicating factors, comparable results will be obtained, both anatomically and functionally, by wide resection of the tumour and the application of a direct bone graft.

RÉSUMÉ

Les observations cliniques touchant la régénération spontanée des mâchoires

J. P. Szlazak

L'exemple des trois malades observés fait preuve du fait que le traitement chirurgical respectif de l'adamantinome des mâchoires peut être réalisé à l'égard des divers données, telles que l'âge du malade, l'étendue de la destruction osseuse, causée par la tumeur, de même que les complications en tant que suites d'une opération mal fondée. Les bons résultats obtenus dans les premiers deux cas soulignent non pas seulement la nécessité d'une exstirpation précise et absolue de la tumeur à l'aide de l'énucléation, mais de même le fait de la mise en évidence de l'aptitude de l'os lui-même et de son périoste quand à la régénération.

Chez les adultes, où la régénération osseuse de même que périostale se trouve dans un état moins actif ou que pire en surplus, il y en a d'autres facteurs comme complications, on peut tout de même obtenir un résultat rélativement favorable quand à l'anatomie et la fonction en entreprenant une résection large de la tumeur suivie d'une implantation de la greffe osseuse directe dans le défait en question.

ZUSAMMENFASSUNG

Klinische Beobachtungen von spontaner Unterkieferregeneration

J. P. Szlazak

Die drei beschriebenen Patienten zeigen, dass die chirurgische Behandlung des Adamantinoms des Unterkiefers sich nach verschiedenen Faktoren richten kann, wie z. B. Alter des Patienten, Ausdehnung der tumorbedingten Knochendestruktion und Komplika-

tionen infolge unrichtigen operativen Vorgehens. Die guten Ergebnisse in den beiden ersten Fällen weisen darauf hin, wie wichtig die vollständige Entfernung der Geschwulst durch Enukleation ist, zugleich jedoch auch darauf, dass das Regenerationspotential von Knochengewebe und Periost stets im Auge zu behalten ist.

Bei Erwachsenen, bei denen die Knochen- und Periostregeneration weniger aktiv ist, besonders aber dann, wenn weitere komplizierende Umstände bestehen, können relativ gute anatomische und funktionelle Resultate durch breite Tumorresektion und Implantation eines direkten Knochenspans in den so entstandenen Defekt erzielt werden.

RESUMEN

Las observaciones clínicas de los casos de regeneración spontánea de la mandíbula

J. P. Szlazak

Estos tres enfermos demuestran que el tratamiento quirúrgico del adamantinoma de la mandíbula se puede regir por diferentes factores como la edad del enfermo, el alcance de la destrucción ósea ocasionada por el tumor y la complicación producida por un procedimiento quirúrgico incorrecto. Los buenos resultados en los dos primeros casos demuestran la importancia de la eliminación completa del tumor por medio de la enucleación y al mismo tiempo la necesidad de tener completamente en cuenta el potencial regenerativo del tejido óseo y del periostio.

En los adultos donde la regeneración ósea y periostal es menos activa y principalmente donde están presentes otros factores complicativos, es posible alcanzar resultados anatómicos y fisiológicos relativamente buenos con la resección amplia del tumor y con la implantación de un injerto óseo directo en el correspondiente defecto.

(J. P. Szlazak, M. D.): Box 557, Medical Arts Clinic,
Regina-Saskatchewan, (Canada)

King George's Medical College, Unit of Plastic Surgery, Lucknow (India)
Head: Prof. R. N. Sharma, M.S., F.R.C.S.

ELEVEN YEARS IMPRESSION OF SURGERY OF CLEFT PALATE

R. N. SHARMA

Cleft palate and its surgery seems to be undergoing a change in the modern era, but its essentials remain basically firmly ingrained in the planning and timing of every procedure. A sample survey was carried out recently on our series of eleven years, to be presented at a symposium that was held at the annual meeting of the section of plastic surgery, Association of Surgeons of India, in December 1964. Certain conclusions were drawn. In our repairs Veau-

Fig. 1 A.

Kilner and Wardill procedures have been followed with an addition to the traditional Veau flap (Fig. 1A). A standard modified Reidys classification has been followed in assessing speech results. Orthodontic assessment was done between the ages of six and eight years. 41% our series were repaired within two years of age. A few selected patients will be presented here.

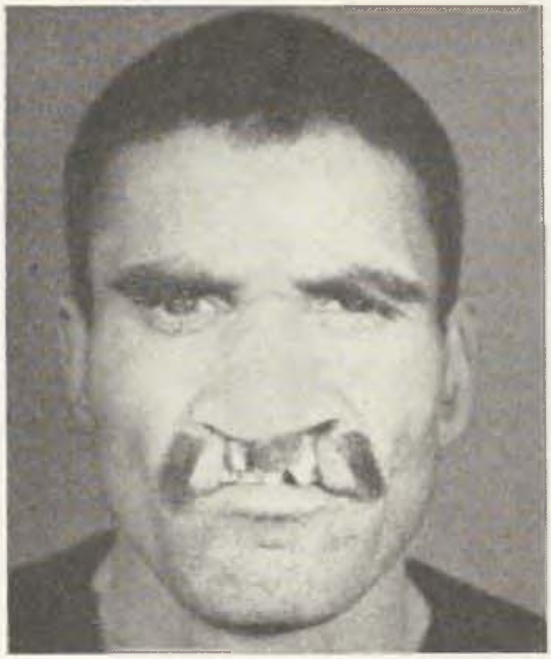

Fig. 1.

Fig. 2.

It is becoming uncommon to get adult patients but in this intelligent patient (M. 25 years, Fig. 1, 2) the face components are in complete harmony. But for the protrusion of loose premaxilla (Fig. 3) that can be corrected, the maxilla is well developed with a "V" shaped arch (Fig. 4, 5) and the arch of the mandible is parabolic. The passavant prominence is well marked (Fig. 6) as confirmed by the histogram (Fig. 7), the gap is too wide and it may be difficult to attain intelligible speech even with pharyngoplasty.

Another adult patient (A. B. 20 years) had a superiorly based flap pharyngoplasty (Fig. 8) along with the repair of his palate for a perforated submucus cleft. Analysis after six months revealed persistence of nasality with a positive mirror test. The histogram (Fig. 9) shows that the palate does not rise above the hard palate despite the flap. Further improvements in speech is not predictable.

A female child (M. L. 7 years) was repaired at two years for group III unilateral cleft (Fig. 10, 11). She still has nasality, with grimmace. For the

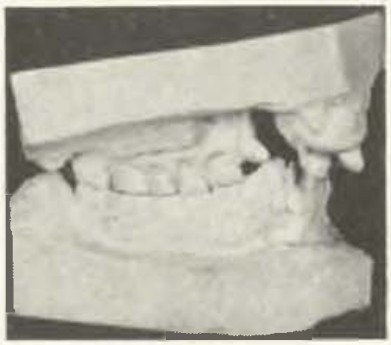

Fig. 3.

Fig. 4.

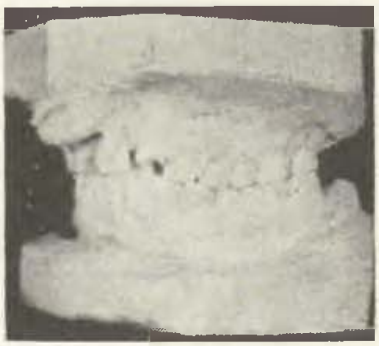

Fig. 5.

labials and alveolars she brings her tongue between her teeth. The histogram reveals deficiency (Fig. 12) but speech therapy may improve her. Failure will lead to pharyngoplasty. Dental models reveal, that the left side with a small fragment is in crossbite (Fig. 13, 14, 15). The orthodontist will only correct her when she has incisors.

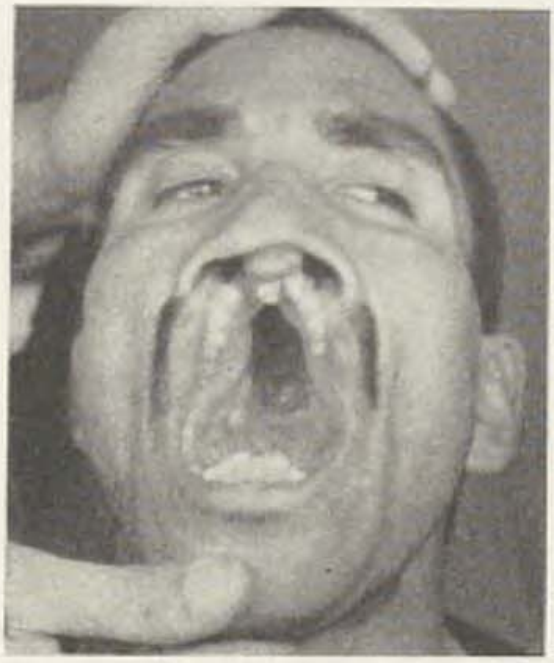

Fig. 6.

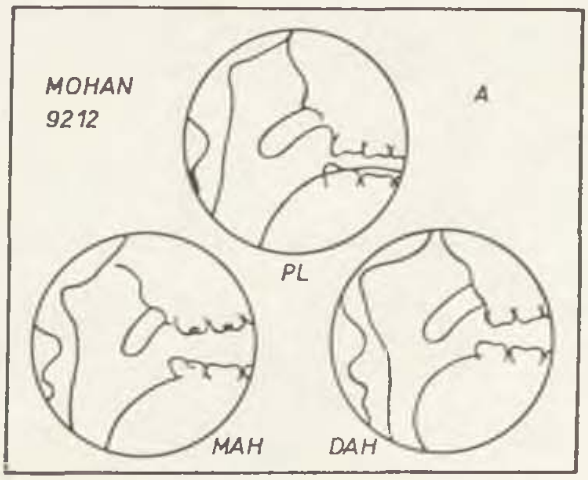

Fig. 7. A — Bilateral complete cleft lip and palate.

Another female child (I. 7 years) of group III bilateral cleft which was repaired between 3½ to 5 years (Fig. 16, 17). Unlike the preceding she wears a plate for a small alveolar fistula (Fig. 18, 19). Lips and palate are supple and mobile. She has good speech though repaired at 5 years. The histogram

shows good palatal function (Fig. 20). Dental models reveal a well moulded premaxilla with well balanced occlusion (Fig. 21, 22, 23).

Surgeons like myself who are addicted to the Kilner Wardill flap procedures, will agree with me that there is considerable lengthening with mobilisation, leading to narrowing of the Isthmus. Calnan has shown radiographi-

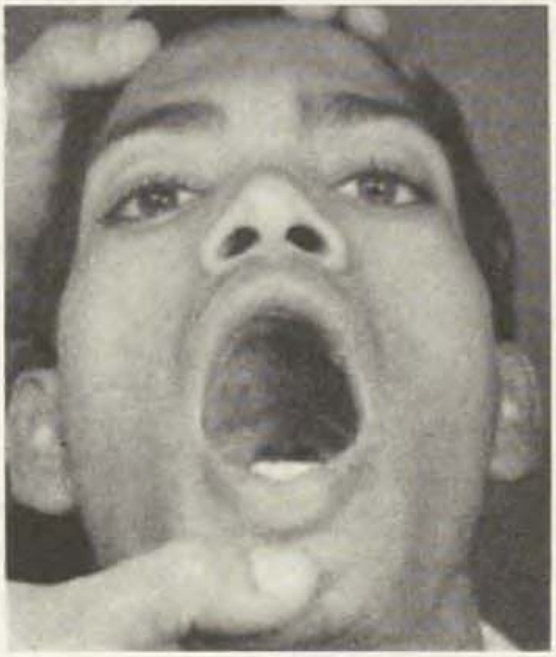

Fig. 8.

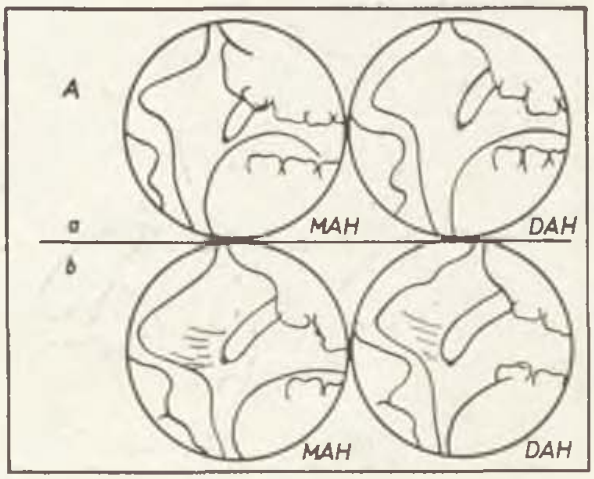

Fig. 9. Sub-mucous cleft palate with perforation: a — pre-operative, b — post-operative.

cally that the shorter the effective length of the soft palate, the greater its lengthening after operation. Reidy and others have pointed out that when the nasal mucosa breaks healing by fibrosis undoes the lengthening. It is our feeling that this occurs commonly in group III unilateral and very wide group II clefts.

Fig. 10.

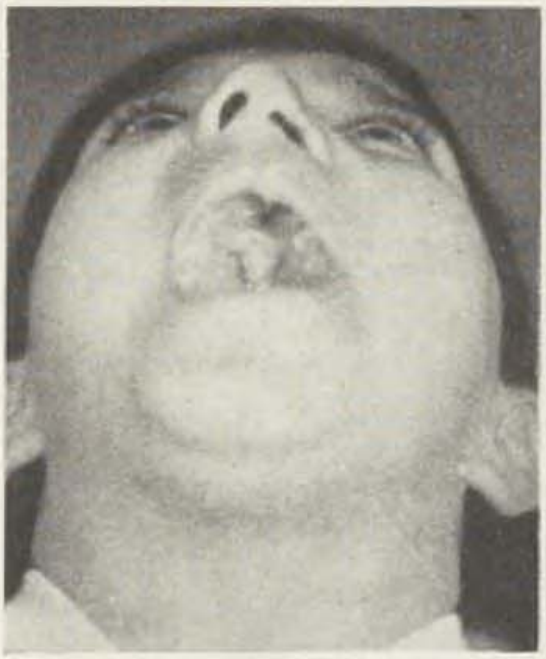

Fig. 11.

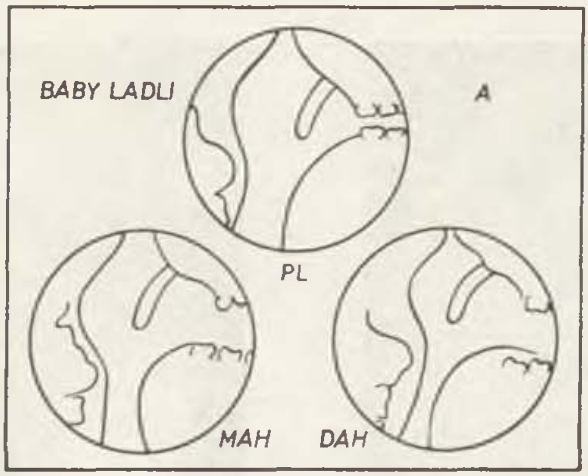

Fig. 12. A — Unilateral complete cleft lip and palate.

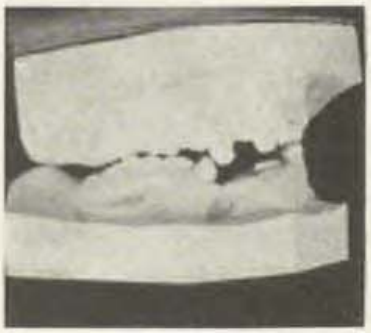

Fig. 13.

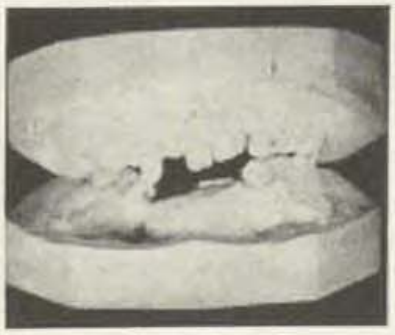

Fig. 14.

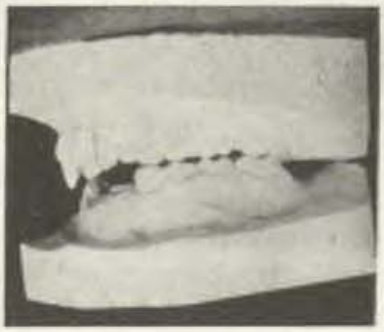

Fig. 15.

Fig. 16.

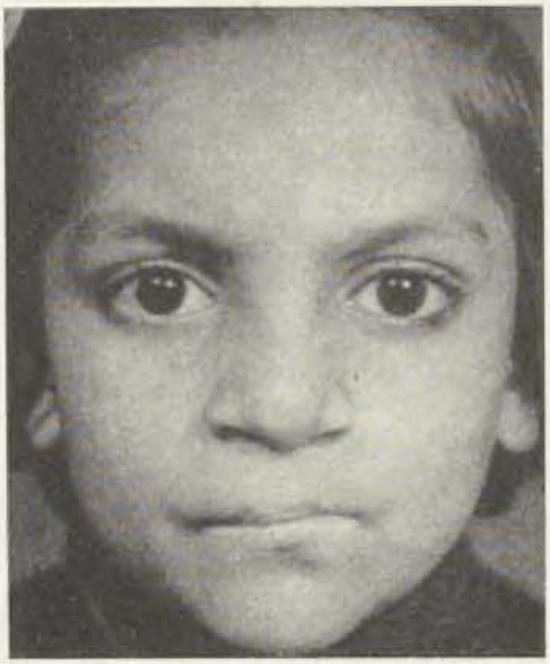

Fig. 17.

Fig. 18.

Fig. 19.

A triangular flap of Thomas Gibson or a fourth flap may be added at this stage, but I have no personal experience of this. I also doubt the necessity of breaking every hamulus as we have done so far. The effect of healing by fibrosis in the cavities that we pack is open to question. I am unable to predict anything at this stage due to lack of investigatory facilities. Even Calnan with all his in-

genuity stated that if one could predict the exact amount of lengthening obtained then it could be of some practical applicability. Fracture of the hamulus does take away the tension in wide clefts.

An important question is the stage at which pharyngoplasty comes in question. Many Americans and Canadians felt that a V-Y repair minimises its

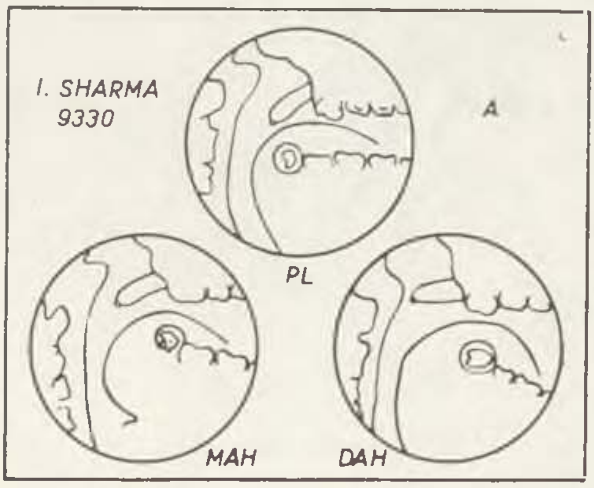

Fig. 20. A — Bilateral complete cleft lip and palate.

need, but 40% mainly relied on flap pharyngoplasty of which 64.3% were superiorly based and only 5 performed Hyne pharyngoplastyes. Calnan's histographic studies show that Passavant's prominence may be minimal in normal people (Fig. 24). In speech there are rapid tonic contractions and the soft palate meets at a higher site. The palate meets the eminence when clonic contractions occur during blowing and deglutition. The blowing and manometric tests may be falacious. The adenoid pad and Passavant's eminence both help in combating the deficiency. Like Calnan, Reidy and others, I believe that pharyngoplasty as a primary procedure is not needed in early age groups. It may be done as a secondary procedure or added in very wide clefts, if primary repairs are undertaken after the age of five or six years. Thus far, I have done only four pharyngoplasties in eleven years.

Fig. 21.



Fig. 22.

Fig. 23.

The raising of mucoperiosteal flaps at an early age is the next question. That ligation of posterior palatine artery disturbs the growth has been proved by Oskar Herfert. Professor Burian alongwith Herfert now advocate closure of soft palate at 14 to 16 months, which reduces the gap in the hard palate that is repaired at the age of six. Our children do not come to us so often although

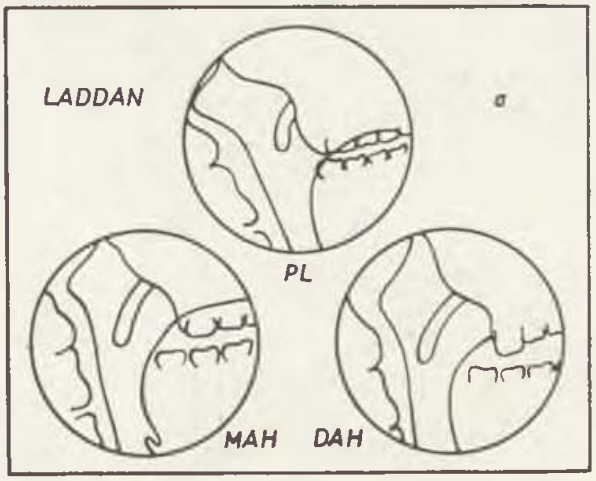

Fig. 24. a — Normal.

the orthodontist agrees with this. In our series our dental colleague cannot recollect any patient whose growth may have been disturbed due to early repairs.

Anthony Wallace has discussed the problem of the premaxilla and the dental arch. In none of our series except in one adult did we have to resect prevomerine bone; nor did we ever have to excise it. On the other hand, we had two patients with tight lips due to its excision elsewhere. In the opinion of our dental colleague, however small the premaxilla may be, the prosthesis fitted will not be bulky and can easily be moulded to small premaxilla. In his opinion the best time for orthodontia is nine to ten years because the pattern of dentition is established and the child is old enough to cooperate. The treatment of deciduous dentition will not automatically take care of the permanent teeth. A child with repeated surgery is in no mood to cooperate early. We have no experience of early bone grafting as advocated by Johanson and Ohlson.

In conclusion, we would like to say that whenever the nasal mucosa breaks it undoes the effect of mobilisation. The routine breaking of the hamulus may not be necessary in every case. Pharyngoplasty, as a primary procedure in older age groups, may be combined with primary repair. In our series early repair has retarted growth. We accept the procedure advocated by Schweckendick as practiced now by Professor Burian in cases over 4—5 years of age. Resection of premaxilla is hardly ever needed. Our method of speech therapy is of value in the absence of regular speech training.

I cannot give a statistical data of analysis of my series on account of lack of facilities. I must, however, emphasize the old teaching of my Guru late

Professor Kilner that stands true even today, that a patient should look well, eat well and speak well; but what one calls a good speaker may revert to unintelligible speech when excited. For this I now advise the parents to teach patients classical Indian music on the Harmonium, with excellent results.

SUMMARY

1. This paper gives an Eleven Years sample survey of the Surgery of the Cleft Palate.

2. All the repairs were based on Killner Wardill flap procedures and a Veau flap was used for supplementing the repair of anterior 3rd of the Clefts.

3. The need for fracturing the hamulus has been doubtful in every patient, where as addition of a fourth flap to avoid healing by fibrosis where the nasal mucosa breaks at the junction of soft and hard palate, has been justified.

4. Pharyngoplasty as a primary procedure in early age groups is not justifiable but it may be combined if repair is undertaken after five years of age.

5. In our series, the growth of the maxillary complex is not disturbed if

6. Removal of the premaxilla had not been necessary in any instance.

the mucoperiosteum is raised in repairs during infancy.

7. We accept the procedure advocated by Schweckendik as practiced now by Professor Burian.

8. Any easy method of speech correction by learning classical Indian music on the harmonium has been advocated.

RÉSUMÉ

Les résultats des onzes années de la thérapie chirurgicale de bec-de-lièvre

R. N. Sharma

1⁰ L'article présente l'ensemble des expériences des onzes années consacrées à la thérapie chirurgicale de bec-de-lièvre.

2⁰ Dans tous les cas, principalement, la méthode du lambeau de Kilner-Wardille fut celle du choix. Le lambeau de Veau n'a été employé que pour compléter la reconstruction de la première tiercée de la fissure.

3⁰ L'ablation de hamulus lacriminalis n'a pas été considérée en tant que nécessaire dans aucun des cas ou l'emploie d'un quatrième lambeau a été jugé raisonnable pour empêcher la guérison par fibrose dans la zône de transit de la voûte palatine osseuse dans la voile du palais, où, bien souvent, la muqueuse nasale se déchire.

4⁰ Pharyngoplastie en tant qu'intervention précoce chez nourisson n'est point la plus désirée, mais elle peut être associée à la réconstruction tardive mis en oeuvre chez les enfants âgés de plus de cinq ans.

5⁰ Notre série n'a pas montré des troubles de développement du complexe maxillaire grâce au soulevement du mucopérioste à l'âge précoce.

6⁰ Dans aucun des cas la nécessité d'enlever l'os intermaxillaire n'a pas été signalée.

7⁰ Nous sommes d'accord avec la méthode proclamée par Schweckendiek et pratiquée nouvellement par prof. Burian.

8⁰ Nous récommandons l'enseignement de la musique classique des Indes à l'aide d'harmonium comme méthode bien facile de la correction des défauts de la parole.

ZUSAMMENFASSUNG

Elfjährige Erfahrungen mit der chirurgischen Behandlung der Gaumenspalte

R. N. Sharma

1. Der vorliegende Artikel bringt die elfjährigen Erfahrungen mit der chirurgischen Behandlung der Gaumenspalte.

2. In allen Fällen wurde grundsätzlich die Methode des Kilner-Wardillschen Lappens angewendet, der Veausche Lappen wurde zur Ergänzung der Rekonstruktion des vorderen Spaltdrittels gebildet.

3. Das Abbrechen des Hamulus wurde in keinem der Fälle für nötig erachtet, wo die Verwendung eines vierten Lappens voll begründet war, um eine Heilung durch Fibrose am Übergang des weichen in den harten Gaumen zu vermeiden; an dieser Stelle kann es nämlich zum Einreissen der Nasenschleimhaut kommen.

4. Die Pharyngoplastik als primärer Eingriff ist im zarten Kindesalter nicht indiziert, kann jedoch bei Kindern über 5 Jahren mit der Rekonstruktion kombiniert werden.

5. In seiner Aufstellung beobachtete der Verfasser keine Wachstumsstörung des Maxilla-Komplexes, da er bei Rekonstruktionen im zarten Kindesalter das Mukoperiost abgehoben hatte.

6. In keinem Falle war es notwendig, den Zwischenkiefer zu entfernen.

7. Der Verfasser stimmt mit der von Schweckendiek empfohlenen und von Professor Burian nunmehr angewendeten Methode überein.

8. Der Verfasser empfiehlt den Unterricht im der klassischen indischen Musik unter Verwendung eines Harmoniums als geeignete Methode zur Sprachkorrektion.

RESUMEN

Las experiencias de once años con el tratamiento quirúrgico de la escisión del paladar

R. N. Sharma

1. El artículo dá una idea de las experiencias de once años con el tratamiento quirúrgico de la escisión del paladar.

2. En todos los casos se utilizó fundamentalmente el método de Kilner-Wardill del lóbulo, y este lóbulo fué formado según Veau par a completar la reconstrucción del tercio anterior de la escisión.

3. El desprendimiento del hamulus no fué considerado como necesario en ningúno de los casos, donde el uso del cuarto lóbulo fué completamente realizado con el fin de detener la curación con fibrosis en el lugar de transición del paladar blando con el paladar duro, que conduce a la desgarradura de la mucosa nasal.

4. La faringoplástica como primer paso en la edad temprana no está justificada, pero puede ser combinada con la reconstrucción, realizada en los niños mayores de 5 años.

5. En nuestra serie nos hemos encontrado con la perturbación del crecimiento del complejo maxilar, porque hemos levantado el mucoperiostio durante las reconstrucciones en la edad temprana.

6. En ninguno de los casos fué necesario eliminar la porción intermandibular.

7. Estamos de acuerdo con el método recomendado por Schweckendiek y ahora completado por el profesor Burian.

8. Recomendamos la enseñanza de la música clásica india por medio del acordeon como un método fácil para reparar el lenguaje.

REFERENCES

1. **Calnan, J.:** Brit. J. Plast. Surg. 13 : 340, 1960—61.
2. **Calnan, J.:** Brit. J. Plast. Surg. 13 : 340, 1960—61.
3. **Calnan, J.:** Brit. J. Plast. Surg. 14 : 39, 1961.
4. **Farina, M.:** Brit. J. Plast. Surg. Vol. X, 14 : 89, 1957—58.
5. **Foster Greene:** Brit. J. Plast. Surg. 12, 1959—60.
6. **Holdsworth:** Brit. J. Plast. Surg. 16 : 144, 1963.
7. **Herfert:** Brit. J. Plast. Surg. 16 : 32, 1963.
8. **Calnan, J.:** Brit. J. Plast. Surg. Vol. X, 14 : 89, 1957—58.
9. **Wilde, J.:** Brit. J. Plast. Surg. 13 : 28, 1960—61.
10. **Reidy, J. P.:** Brit. J. Plast Surg. 15 : 261, 1962.
11. **Kahn, Winstein:** Brit. J. Plast. Surg. 13 : 13, 1960—61.
12. **Lewin, M. L.:** Plast. reconstr. Surg. April 1964.
13. **Reidy, J. P.:** Brit. J. Plast. Surg. 13 : 340, 1960—61.
14. **Reidy, J. P.:** Brit. J. Plast. Surg. 12 : 208, 1959—60.
15. **Sten, J., Stenstron:** Plast. reconstr. Surg. Vol. 32 : 353, 1963.
16. **Wallace:** Brit. J. Plast. Surg. 16 : 37, 1963.

(Prof. R. N. Sharma): King George's Medicall College, Lucknow, India

CONGENITALLY SHORT URETHRA

G. S. PAP, T. D. CRONIN

Congenitally short urethra is rare, although probably more common than recognized. In the international literature for the past 15 years a number of reports were found, by McIndoe, Bergerhof and Gelbke, and Fogh-Andersen, reporting on a limited number of cases. The largest series is that of Fogh-Andersen who operated on 10 patients with a short congenital urethra in a series of 275 consecutive cases operated for a hypospadias deformity.

It seemed, therefore, useful to report on our personal experience each of us having seen two cases requiring more understanding and attempting to recommend methods of management with observance of general principles of plastic surgery.

McIndoe described congenitally short urethra in the same precise style as he used in surgery, saying that at first sight it resembles hypospadias: The penis is short, ventrally curved, normal erection is impossible and the distinguishing feature is that the urethra emerges from the meatal dimple in the normal way and not on the ventral surface of the penis as in hypospadias.

In the number of cases described by the authors whose experience I am quoting, various degrees of this deformity are seen. In particular, the degrees of curvature in a flaccid penis with a urethral opening at the tip of the penis and the deformity becoming more obvious only on erection.

There seems to be agreement on the developmental cause of this malformation. It is thought to be a lack of differentiation of the corpus spongiosum in its distal portion. The degree of the deformity is then caused by a disproportionate growth of the corpus spongiosum as compared with corpora cavernosa. In cases where the corpus spongiosum is absent and the anterior urethra is formed only by a skin tube, the fibrous bands replacing the corpus spongiosum are the cause of ventral curvature of the organ.

As far as management is concerned all authors quoted stress the importance of correction of the chordee in the first instance, followed by reconstruction of the resulting gap in the urethra along the lines of a conventional hypospadias repair.

All of them agree in 2 recommendations:

A) To split the urethra and corpus spongiosum at the level of the corona for purpose of release of the ventral curvature.

B) To preserve the anterior urethra tranversing the glans only if it is of good caliber.

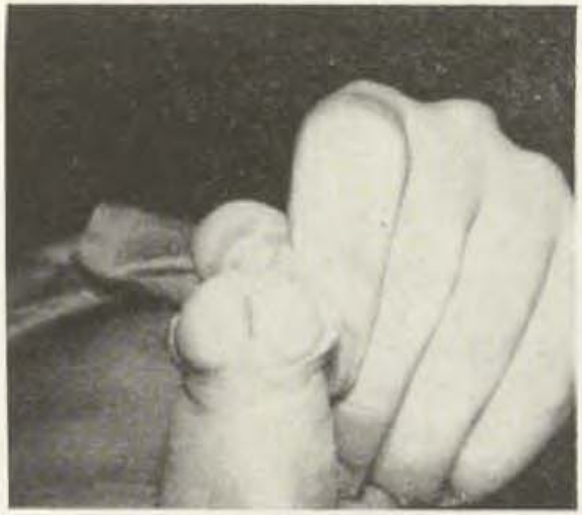

Fig. 1.

Fig. 2.

Fig. 3.

Fig. 4.

Fig. 5.

Fig. 6.

Individual considerations on various types of deformity are given by Fogh-Andersen who recommends:

1. A transverse division of the urethra at the corona for the type of deformity where he decided to preserve the anterior urethra.
2. Splitting the urethral tube backwards and excision of the urethral mucous membrane together with fibrous tissue in the rest of the cases thus producing a hypospadias condition without chordee.

Bergerhof and Gelbke reflect their clinical differential diagnosis in their recommendations for treatment. They recommend division of the urethra at the level of the corona in cases where the corpus spongiosum is present anteriorly. Whereas, when the anterior urethra is formed only by a skin tube excision of that part of the urethra is recommended. All of these authors used Denis Browne's technique for the repair.

CASE REPORTS

Case 1 (Fig. 1). A boy was seen by G.S.P. while in the hospital for a Thorek procedure for an undescended testicle at the age of 12. The penis appeared to be almost of normal appearance with a urethra of good caliber and size of a No. 14 French catheter. A moderate pull on the glans was present which became more obvious when the penis was stretched dorsally. I did not operate on this patient for lack of information at that time. Today I would classify this case as one falling into the category of disproportionate growth of the corpus spongiosum and corpora cavernosa.

Case 2 (Fig. 2). This patient was seen by G.S.P. when he was 5 years old with a tentative diagnosis of hypospadias. The mother reported that at birth and during the first two weeks of life urine escaped from the tip of the penis. At two weeks and from then on she noticed an additional opening on the undersurface of the penis, through which part of the urinary stream escaped on voiding. I initially thought that this is a case of an urethral fistula similar to the one reported by Gupta, without cordee.

My patient was examined under an anesthetic prior to a decision on definite treatment. I found that I could pass a sound in both directions through the hypospadiac opening. Distally into the bladder and anteriorly through the glans and normally located meatus. In my case a marked degree of ventral curvature could be observed.

At the time of his first operation the distal urethra was released and permitted to fall back almost to the penoscrotal junction. (Fig. 3.) I preserved the anterior urethra traversing the glans since it appeared to be of good caliber and repaired the tissue defect by means of preputial flaps according to Byars. This case is still unfinished and it is planned to reconstruct the gap in the urethra according to Byars' technique.

Case 3. Seen at the age of 10 by T.D.C. He had had an operation on the penis at an early age.

The penis showed a marked chordee (Fig. 4). The meatus was at the tip of the glans. There was some scarring on the ventral surface. The urethra admitted a F-20 sound.

Fig. 7.

Fig. 8.

Fig. 9.

Fig. 10.

Fig. 11.

At the time of the first operation it was noted that the urethra was very thin over the ventral surface distally (Fig. 5). This very thin portion of the urethra from the frenulum proximally to almost ½ the length of the penis was excised. A great deal of scar tissue was encountered, this was removed with proximal displacement of the meatus and the ventral curvature corrected. Preputial flaps were developed and swung to the ventral surface. They were joined to a small portion of the urethral channel remaining distally in the glans and proximally to the new urethral meatus which was located at the penoscrotal junction.

In the second stage, a flap was outlined on the ventral surface in width 20 mm. Just before the frenular artery, the flap bifurcated laterally and dorsally in a Y fashion the upper arms being 10 mm. in width. The length of these arms was adequate to reach the end of the glans (Fig. 6).

Incisions were made along the lines as drawn and the central island flap was undermined lightly on all margins. The crura of the flap were undermined back to the junction and were kept rather thin. A midline ventral incision was then made in the glans and carried down to the bifurcation of the flap. Flaps were then elevated so as to create a raw area to lay the other flaps in to form the urethra. Laterally, along the shaft of the penis the skin was undermined for considerable margin to allow for mobilization to the ventral surface. A catheter was placed in the meatus and the island flap tubed over this catheter. The two crura distally, was sutured into the raw area of the glans, the dorsal junction of those flaps was not sutured. The ventral junction of these flaps were sutured together and this was continued with the suture which tubed the proximal portion of the urethral flap. The lateral flaps of the glans were then crossed over the distal portion of the tubed urethra and sutured with fine catgut.

The lateral flaps of the glans were then crossed over the distal portion of the urethra and the lateral flaps along the shaft were brought over the new urethra, resulting in what was thought adequate coverage without tension.

The postoperative course of this patient was complicated by postoperative bleeding which occurred on the fifth postoperative day and was ascribed to an erection. This resulted in partial break down of the repair. The distal one-half to ¾ of an inch of the urethra had not separated nor had the proximal 1 cm. Hemorrhage was controlled and the wound resutured.

Two additional operations were necessary for closure of fistulas resulting in a satisfactory functional result (Fig. 7). When realing had taken place the reconstructed urethra permitted the passage of a F-18 sound in its whole length (Fig. 8).

Case 4. Seen initially at the age of 12 by T.D.C. He had had one operation previously at the age of 6. Mother reported that he was born with a curvature of the penis, but urine has always come out from an opening at the tip of the glans. At this time the curvature was accentuated with erection.

The penis was rather short and stout, with ventral curvature, the meatus was at the tip and admitted a F-18 sound (Fig. 9).

At the first operation an incision was made in the middle of the ventral surface of the penis distally towards the glans. The incision was then extended around the glans about 3—4 mm. from the groove. The skin flaps thus outlined were dissected from the shaft. The urethra was severed transversely at about the middle of the penis and all fibrous and connective tissue dissected off the undersurface, allowing the penis to be extended. As this occurred the cut ends of the urethra were separated about 1—1¼ inch.

Then a free skin graft of preputial skin was taken from the prepuce, wrapped around a No. 20 catheter and sutured with a continuous 5—0 catgut suture. This was then laid into the defect of the urethra on the ventral surface of the penis, the suture line being against the body of the penis (Fig. 10).

The ends of the graft were sutured to the urethra at each end. Then the skin flaps were mobilized after making a dorsal slit in the distal part of the prepuce and laterally to cover this grafted area. The flaps were sutured together with mattress sutures tied over a continuous bolster of cotton (Fig. 11).

In the postoperative course unfortunately the skin flaps sloughed, apparently due to the mattress sutures having been tied too tightly over the bolsters, with loss of the flaps, there was loss of the skin graft, except where it was in contact with the shaft of the penis.

Five months later the urethra was reconstructed in the following fashion: Parallel incisions 20 mm. apart were made and extended around each meatus. The flap thus outlined was formed into a tube by suturing its edges together with a continuous inverting 5—0 catgut suture. The lateral skin margins were undermined and closed with mattress sutures tied over cotton bolsters with moderate tension.

This patient underwent 3 consecutive operations for closure of fistulas, the largest of which measured 3 mm. in diameter leading eventually to a successful repair resulting in a straight penis and urethra of satisfactory caliber.

SUMMARY

I would like to say that Fogh-Andersen and others have presented enough evidence that the congenitally short urethra is a clinical entity per se.

We think that Byars' technique for the first stage hypospadias repair with a foreskin available is superior to other methods for release of chordee.

We would like to stress that these cases should be operated on early rather than wait until puberty to see whether a ventral curvature will occur with erection. Surgery on the urethra in adolescence carries a high rate of complications. These are due to the more pronounced vascularity of the organ and uncontrollable erections which may ruin the most satisfactory repair.

We also propose that a more aggressive attitude be adopted for the case of the congenital short urethra and there should be no hesitation in dividing a urethra which appears normal, and is at the same time cause of sexual incompetence.

RÉSUMÉ

L'uretre trop courte innée

G. S. Pap, T. D. Cronin

L'auteur est d'accord avec Fogh-Andersen et all. trouvant assez efficace leur preuve en ce qui concerne la classe clinique du phenomène de l'urètre trop courte innée.

Quand à la thérapie: l'auteur suppose la méthode de Byars de l'emploie de la peau préputiale dans la première etape de la réparation d'hypospadie étant supérieure à toutes autres méthodes quand à la libération de la verge courbée.

Il est à souligner que ces malades devraient être opérés précocement sans attendre la puberté venir pour constater la courbe ventrale de la verge suivant l'érection. L'opération de l'urètre chez l'adulte présente toute une série des complications, ceux-ci étant causées non pas seulement par la vascularization beaucoup plus élévée chez l'adulte, mais de même par des érections sans contrôle, capables de détruire la plus parfaite opération.

Nos projets pour l'avenir sont ceux de faire comprendre à tous la nécessité d'examiner minutieusement les malades à l'urètre trop courte innée faute d'éliminer les inconvénients de l'urètre discidé d'aspect normal, mais qui, pourtant, présente la cause respective de l'impuissance de la vie sexuelle.

ZUSAMMENFASSUNG

Die kongenital kurze Urethra

G. S. Pap, T. D. Cronin

Nach Ansicht der Verfasser haben Fogh-Andersen und andere Forscher hinreichende Beweise dafür erbracht, dass die kongenital kurze Urethra eine selbständige klinische Einheit ist.

Hinsichtlich der Behandlung vermuten die Autoren, dass die Byarsche Methode — die Verwendung des Praeputiums in der ersten Etappe der Reparation der Hypospadie — vorteilhafter ist als die anderen Methoden zum Freimachen des gekrümmten Penis.

Die Verfasser betonen, dass diese Fälle im frühen Kindesalter und nicht erst in der Pubertät zu operieren sind, denn in der Pubertat soll man sich bereits davon überzeugen, ob es bei der Errektion zur ventralen Krümmung des Penis kommt. Eine Urethra-Operation beim Erwachsenen bringt eine ganze Reihe von Komplikationen mit sich, die einerseits durch den markanteren Gefässreichtum des Penis bedingt sind, andererseits mit unkontrollierbaren Errektionen zusammenhängen, die auch eine tadellos ausgeführte Reparation zunichte machen können.

Zugleich schlagen die Verfasser vor, der kongenital kurzen Urethra erhöhte Aufmerksammkeit zu widmen; so könnte die Verlegenheit bezüglich der Durchschneidung der Urethra — die zwar normal aussieht, jedoch Ursache der geschlechtlichen Impotenz ist — beseitigt werden.

RESUMEN

La uretra corta congenital

G. S. Pap, T. D. Cronin

Nosotros creemos que Fogh-Andersen y otros dieron una muestra suficiente de que la uretra congenital es una unidad clínica independiente.

En cuanto al tratamiento: Pensamos que el método de Byars con el uso del prepucio en la primera etapa de la reparación de la hipospadia es más perfecto que los otros métodos de la liberación del pene doblado.

Queremos reafirmar, que estos casos deberían operarse en la edad temprana, nunca en la pubertad, cuando quisiéramos convencernos, si se producirá un encorvamiento ventral durante la ereccion. La operación de la uretra en la adultez trae consigo toda serie de complicaciones. Éstas son ocasionadas, una por la vascularización acentuada del pene y otra por las erecciones incontrolables, que pueden destruir y la reparación mejor realizada.

Proponemos al mismo tiempo, que sea dedicada una atención aumentada en los casos de uretra corta congenital, y con eso desaparecerían las confusiones por la sección de la uretra, la cual es verdad que parece como normal, pero sin embargo es la causa de la impotencia sexual.

REFERENCES

1. **Fogh-Andersen, P.:** Excerpta med. International Congress Series No. 66, 1964.
2. **Bergerhof, H. D., Gelbke, H.:** Chirurg 33, 114, 1962.
3. **McIndoe, A. H.:** Brit. J. Plast. Surg. 1, 36, 1948.
4. **Byars, L. T.:** Surg. Gynec. Obstet. 184, 100, 1955.
5. **Gupta, S. C.:** Brit. J. Plast. Surg. 15, 194, 1962.

(G. Pap, M. D.): 2500 N. Rockton Avenue, Rockford, Illinois, U.S.A.

Department of Plastic Surgery, Comenius University, Bratislava (Czechoslovakia)
Director: Prof. Š. Demjén, M. D.
Second Gynaecological Department, Comenius University, Bratislava
Director: Prof. A. Hudcovič
First Gynaecological Department, Comenius University, Bratislava
Director: Prof. Štefánik, M. D.

APLASIA OF THE VAGINA. RECONSTRUCTION BY A FREE SKIN GRAFT

Š. DEMJÉN, A. A. HUDCOVIČ, A. PONŤUCH

Patients with aplasia of the vagina are willing to undergo any operation if the surgeon promises success.

From the time of Dupuytren (2) many surgeons and gynaecologists have tried their luck with this condition. Many different methods have been used, sometimes quite illogically.

In 1950 we decided to reconstruct the vagina by means of a skin graft and in the course of the past 15 years we have operated on 38 patients using this method.

All this time we adhered to the original surgical tactics which one of us saw at the department of McIndoe. A cavity 12—14 cm. long and two fingers broad is created in the rectovesicle connective tissue, and an already prepared acrylic mould 12—14 cm. long and 4 cm. in diameter, covered with a thin skin graft, is inserted into this cavity and the vulvae sutured together.

If the suture of the vulvae holds, the prosthesis is left in situ for several months. If the suture gives way and the mould falls out, the graft is immediately inspected.

The graft took in 75% of the patients, either completely or with only small defects which healed spontaneously in a short time during the course of dilatation. In about 25% of the cases the defects were larger and if not regrafted in time, healed with scarring which marred the final result. The graft was never completely lost and in no case was there infection of the surrounding tissues.

At the beginning, when we inserted an indwelling catheter, we had three cases of pressure ulceration of the urethra. In one case, perforation of the rectovaginal wall occurred a month after the operation, with fistula formation.

No other complications were met with in this series. The following conclusions were drawn from our experiences:

1. A ready prepared, hard, acrylic mould is not good because:
   a) It does not go into all the folds formed in the cavity so that the close contact of the graft with its bed is not ensured everywhere;
   b) the movements of the patients, which are transmitted through the rigid mould to the graft, act as a disturbing factor in healing;
   c) the hard mould may cause abrasions and compression of the graft and urethra or cause perforation with resulting rectal or vesico-vaginal fistula.

2. It is simple but not correct to leave the mould sutured in for a long time. The graft should be inspected 10—12 days after the operation, evacuated and any defects developing early regrafted. Spontaneous epithelization from the edges must not be permitted, since such an area without corium is particularly liable to contract and lead to deformation of the vagina.

3. After a number of years, a thick graft forms a rigid, poorly elastic wall, extruding abundant white, unpleasant smelling sebaceous secretions, and hair-growth is longer and thicker than at the donor site. For these reasons a thin graft is better, since it contains fewer hair follicles, sebaceous and sweat glands and its properties resemble more closely those of mucosa.

After making an evaluation of these basic considerations and experiences from the follow-up of our patients we decided upon the following changes in surgical tactics:

A. If the bed is not completely dry, the cavity is packed and grafting postponed for 24 hours.

B. The graft should be thin, in one piece and, where possible, taken from the gluteal region. It is applied according to the principles of Polycratic (7). Wool soaked in paraffin oil and flavine is used for packing. The edge of the graft is sutured by knotted stitches of the edge of the vulva and long ends left and tied over the pack. In this way the graft is held in close contact following all the folds in the bed of the graft by the elastic pressure of a sufficiently large pack of flavine wool. There is no danger of pressure ulceration and an indwelling catheter can be introduced without fear. The patient is kept in bed for 6—8 days. The first dressing is made 8—10 days after operation, under general anaesthesia. If the graft is found to be in good condition on inspection, treatment is continued as described below. If, however a large haematoma is found an attempt is made to save the graft over it by evacuating the haematoma and packing its cavity. If this is not successful early retransplantation should be carried out. Epithelization from the edges is only permissible when the defect is small.

C. As is the case with every soft bed, after the first dressing active steps must be taken against secondary contraction, the duration of which must be directly proportional to the thinness of the graft. Dilatation must be continuous and not intermittent. The duration necessary varies with the thickness of the graft and the manner of healing, and in married women is 4—6 months. In

unmarried women dilatation for 6 months is recommended, at least at night. This was solved by Castanares (1) by means of a polyethylene bag filled with glass wool. This should have a diameter 4 cm. and its length can be adjusted according to requirements. It is also possible to make a model of given size from Silastica, Polystan or any other nonirritating elastic plastic substance.

DISCUSION

Very good anatomical results were obtained in 75% of our 38 patients operated on by the method of McIndoe. Complications occurred in the rest in the form of partial loss of the graft or pressure ulcers. Loss of the graft can be attributed to failure to treat delimited haematomas at the right time and to unfavourable healing conditions caused by the hard mould. We encountered more serious complications in the form of pressure ulceration of the urethra (3 cases) and in one case, rupture of the posterior vaginal wall with subsequent development of a rectovaginal fistula.

For these reasons we have given up the use of a hard acrylic mould.

It is clear that the percentage of failures will be directly related to the experience of the surgeon doing the operation and carrying out after-treatment in the taking, application and after-treatment of skin grafts.

However, the basic requirement remains that the new vagina must be lined by a resistant, elastic layer of skin, and any method permitting "epithelization" without corium is at variance with the basic principles.

We have no personal experience with the reconstruction of the vagina by means of intestinal grafts. In the modifications suggested at the present time, these operations will hardly ever be recommended as methods of choice as compared with the results attained with free skin grafts.

SUMMARY

A report is given of the results obtained in 38 operations for aplasia of the vagina carried out by the method of McIndoe during the past 15 years in collaboration between plastic surgeons and gynaecologists. In 75% of the patients the operations were successful. An analysis is given of the remaining 25% in whom complications were encountered and it was decided to make certain changes in surgical tactics, which are described.

RÉSUMÉ

La réconstruction de l'aplasie vaginale au transplant cutané libre

Š. Demjén, A. Hudcovič, A. Ponťuch

Les auteurs présentent leur expérience avec 38 des opérations de l'aplasie vaginale d'après la méthode de McIndoe, qui ont été faites durant les dernières 15 années en collaboration d'un chirurgien esthétique et d'un gynécologue. 75 % des opérations ont été favorables. L'analyse des 25 % des malades qui présentaient des complications importantes parvint à obliger les auteurs de modifier la technique opératoire. Cette nouvelle technique fait l'objet de l'article présenté ci-dessus.

ZUSAMMENFASSUNG

Rekonstruktion bei Aplasie der Vagina durch ein freies Hauttransplantat

Š. Demjén, A. Hudcovič, A. Ponťuch

Die vorliegende Arbeit bringt die Erfahrungen mit 38 Operationen wegen Vagina-Aplasie; die Operationen wurden nach McIndoe in den letzten 15 Jahren in enger Zusammenarbeit des plastischen Chirurgen mit dem Gynäkologen ausgeführt. 75 % der Operationen waren erfolgreich. Die Verfasser analysierten die übrigen 25 % der Fälle, bei denen Komplikationen zu verzeichnen waren, und entschlossen sich, die Operationstaktik zu ändern, worüber sie in der vorliegenden Arbeit berichten.

RESUMEN

La reconstrucción de la aplasia de la vagina por un transplante cutáneo libre

Š. Demjén, A. Hudcovič, A. Ponťuch

Los autores informan sobre sus experiencias con 38 pacientes operados de aplasia vaginal, según el método o procedimiento de McIndoe, realizadas en el transcurso de los últimos años con la colaboración del cirujano plástico y del ginecólogo.

El 75 % de las operaciones se efectuaron exitosamente. Los' autores analizaron el 25 % restante donde registraron las complicaciones y se decidieron modificar el método operatorio, el cual describen en este trabajo.

REFERENCES

1. **Castanares, S.:** Plast. reconstr. Surg. 32 : 368, 1963.
2. **Dupuytren, G.:** Cl. d'Hosp. (Paris) I, 3, 1827.
3. **Hudcovič, A., Demjén, Š.:** Čs. Gynek. 17/32, 117, 1953.
4. **McIndoe, A. H.:** Personal communication, 1947.
5. **McIndoe, A. H.:** Brit. J. Plast. Surg. 2, 254, 1950.
6. **O'Conor, C. M.:** Brit. J. Plast. Surg. 15, 13, 1962.
7. **Pylocratis, G. S.:** A Safer Technique for Vaginal Construction by Free Skin Graft. Transactions of the First Congress, International Society of Plastic Surgery 1957.

(Prof. dr. Š. Demjén): Partizánska 2, Bratislava

Second Gynaecological Department, Comenius University, Bratislava (Czechoslovakia)
Director: Prof. A. Hudcovič, M. D.
First Gynaecological Department, Comenius University, Bratislava
Director: Prof. Štefánik, M. D.
Department of Plastic Surgery, Comenius University, Bratislava
Director: Prof. Š. Demjén, M. D.

THE LONGTERM RESULT OF OPERATIONS FOR APLASIA OF THE VAGINA

A. HUDCOVIČ, A. PONŤUCH, Š. DEMJÉN

Aplasia of the vagina always has a decisive effect on the happiness of the women affected. It is a defect which prevents marriage and normal sexual life. It is clear that it provides the basis for many psychological conflicts.

The fact that the patient has not started to menstruate has a depressive effect but the realisation that her desire to become pregnant and have children will never be satisfied acts as a stress which increases with age. An artificial vagina shoud at least parthy fulfil its function in coitus. Successful reconstructive surgery has a favourable effect on anxiety states arising from the consciousness of the defect.

From the year 1943 we have operated on 38 patients with this defect at the Bratislava University Department using the method of a skin graft. Only 32 of these women responded to our request to attend a follow-up examination.

We shall direct our attention to the longterm results of the operation. It is generally known that a vagina constructed by a skin graft has a great tendency to retract. In the patients we followed up the vagina was not usually shortened, but it was narrowed conically in a proximal direction. Ring constrictions had developed which led to pain on coitus from blunt impact.

The lining was pale, dry and only slightly moistened from without. It was covered with a layer a yellow sebaceous material which tended to accumulate in the conus. It was composed histologically of stratified pavement, cornified epithelium, that is, a type only found in the vagina under pathological conditions (prolapse and so on).

In the vaginal smears disintegrating acidophil cells were predominant. The pH ranged from slightly acid to neutral. The vaginal biocenosis was one of a mixed bacterial flora with epithelial cells and leucocytes. On cultivation there was a predominance of non-specific aerobic bacterial flora (pseudodiphtheritic

bacilli, white micrococci and micotic organisms). The Döderlein bacillus did not remain there even after implantation.

In 75% there was a satisfactory organ 8—11 cm. long, sufficiently spacious for the function of coitus. A deeper analysis led us to the conclusion that subjective factors played a certain role. Some patients with a relatively poorer result were more satisfied with it than others with a much better result. That this organ is satisfactory in practice is shown by the fact that the 14 patients married before operation were able to maintain their marriages and of the 32 patients who were single, 20 subsequently married.

At follow-up only one patient was divorced, one was not living with her husband and one remained a widow after the death of her husband. Six were not followed up because they did not respond to our letter. At the time of follow up, 69.2% had been married more than 10 years. Their marriage had passed the test stage and was now stable. It can be assumed that if the husband had not been satisfied he would probably have solved the matter by divorce. In two cases where the husband got to know about the defect in his wife, he began to be dissatisfied and sought the company of other women.

In our patients libido was usually quite well developed. Only 65.6% experienced orgasm. They complained that the pleasant feeling of satisfaction very quickly disappeared.

From the above it can be assumed that a vagina reconstructed by the non-deleterious method of a skin graft can alleviate the severe psychological conflicts of the patient. It is, however, only a partial help, because the impossibility of having her own children continues to act as a stress, at the very thought of this the patients eyes may fill with tears. In many there is the additional fear of divorce if the husband should get to know of the defect. One must agree with A. Mayer who contended that in people with faulty sexual differentiation in the development of the vagina or in the formation of the external genitals, it is not possible to create a full-value sexual partner or the essentials for a sexually harmonious marriage. On the other hand, most patients when asked if they would recommend others to undergo the operation replied that they would.

Only five patients admitted that the operation did not solve any of their problems. The others justified their positive answer by saying that the operation made sexual life possible and their union with a person who was a continuous support in every day life.

What would happen if every patient told her future husband about her defect and operation in addition to warning him that she should not have children, remains unknown. In addition to the men referred to above who started to go with other women, one couple parted after a long period of sexual relations before marriage when the man got to know the truth and another man divorced his wife after five years of married life.

It must be admitted in conclusion that the surgical solution of the problem is only partial. The operation is only justified when using simple minimally dangerous methods.

SUMMARY

The authors point out that a long term follow up of the effects of operations is necessary in addition to the follow up of the actual surgery. Out of 38 patients operated on for aplasia of the vagina by the method of skin grafting, 32 attended follow up examination. 69.2% of these patients had already been married more than 10 years, that is the marriage was over the period of trial and had become stabilized. In 75% of these an organ had been constructed whose size and quality was suitable for coital function. Only one patient was divorced and one was not living with her husband. Five remained unmarried. The operation was of some help in resolving psychological conflicts. But the longing for children remained unfulfilled in all and in many became intensified. Some patients were frightened of divorce if their husband should learn about their defect.

RÉSUMÉ

Les résultats à la longue des opérations d'aplasie vaginale

A. Hudcovič, A. Pontuch, Š. Demjén

Les auteurs soulignent la nécessité du contrôle des résultats postopératoires définitifs et non pas seulement de la technique opératoire elle-même. Des 38 cas des malades ayant subi une intervention au transplants libres 32 sont venues se présenter au contrôle. Dans 69,2 pour cent des cas le mariage des malades persistent de plus de 10 années, c'est-à-dire la crise originale vient d'être supprimée. 75 % des malades présentent une formation d'un organ à qualité et grandeur convenable à la fonction de cohabitation. Une des malades est divorcée, une vit en séparation de son mari, 5 malades sont restées célibataires. L'intervention nous aide à résoudre les problèmes psychiques, mais pas à la perfection. Toutes ces malades présentent un désir ardent des enfants qui reste à jamais insatisfait. Quelques-unes des mariées vivent en peur continue du divorce au cas de la vérité de leur malformation apparue à leur mari.

ZUSAMMENFASSUNG

Spätergebnisse der Operation bei Vagina-Aplasie

A. Hudcovič, A. Pontuch, Š. Demjén

Die Verfasser weisen darauf hin, dass ausser der Technik auch die Spätergebnisse der Operation zu verfolgen sind. Von 38 Patientinnen, die nach der Methode der freien Hauttransplantate operiert wurden, kamen 32 zur Kontrolluntersuchung. Bei 69,2 % dieser Patientinnen dauert die Ehe im Durchschnitt mehr als 10 Jahre, sie ist also nach den ersten Krisen nunmehr gefestigt. Bei 75 % dieser Patientinnen kam es zur Bildung eines Organs, das hinsichtlich Qualität und Grösse die Kohabitation ermöglicht. Nur eine Patientin war geschieden, eine andere lebt vom Gatten getrennt, 5 Patientinnen blieben ledig. Die Operation hilft, wenn auch nur teilweise, die psychischen Konflikte überbrücken. Bei allen Patientinnen bleibt die immer stärker werdende Sehnsucht nach Kindern unerfüllt. Bei manchen verheirateten Patientinnen tritt noch die Angst vor der Scheidung hinzu, falls der Gatte Kenntnis von ihrem Defekt erhielte.

RESUMEN

Los resultados por largo tiempo en la operación de la aplasia vaginal

A. Hudcovič, A. Ponťuch, Š. Demjén

Los autores hacen énfasis en que además de la operación técnica, es necesario observar los efectos duraderos de las operaciones. De 38 métodos operativos de libres transplantes fueron controlados 32. De ellas el 69,2 % son pacientes cuyo matrimonio dura como promedio 10 años, es decir, está fortalecido después de las primeras crisis. En ellas, en el 75 % se formó un órgano cuya cualidad y tamaño convienen a la función de cohabitación. Solamente una paciente se divorció, otra no vive con el marido y 5 permanecieron solteras. La operación ayuda a resolver los conflictos psíquicos, pero solo parcialmente. En todas permanece incompleta y todavía más, aumentada la ansiedad por tener niños. En algunas significativamente aparece el miedo al divorcio, si el marido se entera de sus defectos.

REFERENCES

1. **Hudcovič, A., Demjén, Š.:** Čs. Gynek. 17, 32, 117, 1953.
2. **Hudcovič, A., Zachar, Vl.:** Čs. Gynek. 26, 766, 1961.
3. **Hudcovič, A.:** Collection of Papers from the National Conference, Olomouc 1963.
4. **Mayer, A.:** Zbl. Gynaek. 78, 1956, 1889—1892.

(Prof. dr. A. Hudcovič): II. gynekologická klinika, Bratislava, Czechoslovakia

Institute of Sexuology, Medical Faculty of Charles University, Prague (Czechoslovakia)
Director: Prof. J. Hynie, DrSc.

THE SEXUOLOGICAL ASPECTS OF HYPOSPADIAS

J. HYNIE

An analysis was made of 600 cases of malformations of the male genital organs, treated in cooperation with the surgeons, from the sexuological point of view. 314 of these were hypospadiacs. The main point of the evaluation was to assess sexual function and fecondation.

In this series 81.5% had distal hypospadias which did not prevent the sperms from reaching the vagina. The urethral orifice was on the ventral aspect of the penis in 30.5%, on the ventral aspect of the glans in 31% and at the border between them in 20%. Penoscrotal hypospadias (10.5%), scrotal (6%) and perineal (2%) hypospadias were less common. In these proximal forms the sperms do not enter the female genital tract at coitus.

Of even greater importance for sexual function is chordee which may make coitus impossible. It was present in 30% of glandular and 60% of penile forms of hypospadias. Straightening of the penis was usually essential to make coitus possible. This was sometimes at the cost of shifting the opening of less elastic urethra further from the apex of the glans, sometimes even to the peno-scrotal angle. Later the absent part of the urethra must be constructed when penis reaches an adequate size at puberty. In scrotal and perineal hypospadias, the penis is sometimes so fixed down that it resembles an enlarged clitoris and coitus is impossibles without surgery.

Constriction of the orifice of the urethra or canal may impede ejaculation. This was found in about 30% of cases with glandular and penile hypospadias. In some cases this formed an obstruction to urine flow, not to speak of the more viscous seminal fluid. But such difficulties with micturition are mainly of importance because they make the child nervous and attract too much attention to the genitals.

The production of spermatozoa is usually prevented by incomplete descent of the testicles which was found in 15% of cases of glandular hypospadias, in more than 30% of penile and penoscrotal hypospadias, in 50% of scrotal and in an even higher percentage of the perineal form. This is unfavourable for fertility, but the question must be posed of whether it is desirable at all to assist patients with disturbances of sexual development to acquire fertility, especially in families where anomalies have a relatively high incidence.

The passage of spermatozoa from the testicles may be hindered by inade-

quate development of the epididymis and of the vas deferens, and possibly also of the seminal vesicles and the ejaculatory ducts. The surgeons found disorders of this type in 6% of cases of infertility when performing biopsy or attempting to make a vasoepididymo-anastomosis. They were not, of course, all associated with hypospadias, but they are also manifestations of inadequate urogenital differentiation.

The manner of micturition in our patients was to a certain extent connected with the position of the urethral orifice. The male manner of micturition was possible in about 14% of cases with scrotal hypospadias, whereas in 4% of glandopenile and 11% of penile hypospadias, the female mode of micturition was necessicated by the chordee of the penis. This often has an unfavourable psychological effect on the boys. Marked forms of hypospadias and pseudo-hermaphroditism of the genitals with a deep cleft are not male in appearance and micturition is only possible in the female manner. It is not surprising that such children have doubts as to whether they are really boys. This is associated with loss of self-confidence, and with interests and behaviour which are not characteristic for boys. Such boys are not so assertive as normal boys, although we have met with one who became the leader of a gang despite the malformation of his genitals.

In proximal types of hypospadias, we therefore recommend early correction of the chordee and lengthening of the urethra, at least to the penoscrotal angle, if the construction of a complete urethra is impossible on account of the hypoplasia of the penis.

If the hypospadias is only a symptom of true or false hermaphroditism, a vagina is usually also present, even if rudimentary. In these cases the name and genitals must be modified to conform with either male or female sexual life, according to the general and psychological disposition of the patient. It is necessary to free the penis, straighten the chordee and construct the anterior part of the urethra and anastomose it with the original urethral orifice, if male sex is selected. In the case of female sex, it is necessary to enlarge or construct an artificial vagina, amputate the penis, and in some cases put the feminizing testicles in the inguinal canals or back in the abdomen, so that the genitals can serve the purpose of female sex life.

SUMMARY

It is important that a child with hypospadias should not lose his male self-confidence and as an adult he should be capable of sexual life. A free and straight penis, which is capable of erection is essential for coitus. The site of the urethral orifice is not so important providing it is not too far from the apex of the glans. It is important for the self-confidence of a boy that he should be able to micturate in the same position as other boys. The author, therefore, advises the lengthening of the urethra to the penoscrotal angle, at least until the final construction of the anterior urethra can be carried out. In cases of hermaphroditism, it is often necessary to adjust the genitals to play a male or female role in accordance with the general and psycho-sexual disposition of the patient.

RÉSUMÉ

Les questions sexuologiques des hypospadias

J. Hynie

Quand au jeune mâle atteint d'hypospadias, nous soulignons la nécessité de son bien-être de mâle et, chez les adultes en surplus, la possibilité de cohabitation. La copulation elle-même exige une verge libre et droite, prête à l'érection. La position de l'aperture uréthrale elle-même n'est point si importante, à moins qu'elle n'est pas située trop loin du sommet du gland. Pour le bien-être du garçon il est surtout nécessaire de pouvoir uriner debout comme les autres garçons. Voilà pourquoi nous exigeons, en face de l'hypospadias, scrotale ou périnéale, la prolongation de l'urètre dans la flexion péno-scrotale au moins jusqu' à la période de la plastie définive de l'urètre. Dans des cas d'hermaphrodisme, la nécessité de préparer les organes génitaux pour le rôle masculin ou féminin est soutenue par les dispositions psycho-sexuelles en combination avec l'état général du sujet en question.

ZUSAMMENFASSUNG

Sexuologische Gesichtspunkte bei Hypospadie

J. Hynie

Der Verfasser hebt hervor, wie wichtig es ist, dass der jugendliche Patient mit Hypospadie nicht sein männliches Selbstbewusstsein einbüsst und der Erwachsene fähig ist, den Geschlechtsverkehr auszuüben. Zur Kopulation benötigt er ein frei bewegliches und gerades Glied, das zur Errektion befähigt ist; weniger wichtig ist die Stelle der Urethra-Mündung, wenn sie nur nicht allzu weit von der Eichelspitze entfernt ist. Für das Selbstbewusstsein des Jungen ist es jedoch von einschneidender Bedeutung, dass er nicht im Stehen urinieren kann wie die anderen. Deshalb empfiehlt der Verfasser, in Fällen von skrotaler oder perinealer Hypospadie die Urethra bis in den Penis-Skrotum-Winkel zu verlängern, wenigstens bis zum Zeitpunkt der definitiven Plastik der vorderen Urethra. In Fällen von Hermaphroditismus ist es gewöhnlich notwendig, die Genitalien für die männliche oder die weibliche Rolle zu adaptieren je nach der psychosexuellen und der Gesamtdisposition.

RESUMEN

Los puntos de vista sexológicos en la hipospadia

J. Hynie

A nosotros nos interesa que el joven hipospádico no pierda su confianza masculina en si mismo y como adulto que sea capaz de tener vida matrimonial. Para la copulación es necesario un miembro sexual, recto y libre, con buena capacidad de erección; no es tan importante el lugar de la desembocadura uretral, si no está demasiado lejos del extremo del glande. Pero para la confianza del muchacho es significativo si este no puede orinar parado como los demás. Por eso estamos de acuerdo, en los casos de hipospadia escrotal o perineal con la prolongación de la uretra hasta el ángulo entre el pene y el escroto, por lo menos hasta el tiempo de la plástica definitiva de la parte de alante de la uretra. En los casos de hermafroditismo es necesario a veces adaptar los genitales para un papel feminino o masculino, según las disposiciones en total o psicosexológicas.

(Prof. J. Hynie, DrSc.): Karlovo nám. 32, Praha 2, Czechoslovakia

PRELIMINARY INFORMATION FOR CONTRIBUTORS

Original papers on all aspects of plastic surgery can be accepted for publication in Acta chirurgiae plasticae in Russian, English, German, French and Spanish. Two clearly legible copies of the manuscript are required. Each article must be procided with an adequate resumé in at least three copies. The heading should include the name of the institution at which the work dealt with has been carried out, i.e. name of institution, name of the head of the institution with full academic title, in the case of a university clinic the name and place of the university. References should be listed in the internationally accepted manner. Illustrations: photographic documentation — black and white, not retouched, glossy. Drawings and graphs must be clear and suitable for reproduction. In the case of all illustrations a vertical arrangement is welcome. Illusrations must be clearly marked, with the lower edge indicated on the reverse side. Similarly the annotation of photographs and graphs on the reverse side must include their number and the author's name together with the title of the article. The proper position of each illustration should be clearly indicated in the manuscript so that it may be correctly placed in the text. The editorial board relies on authors to limit their articles to a reasonable length.

VORLÄUFIGE INFORMATIONEN FÜR UNSERE MITARBEITER

Zwecks Publikation in der Zeitschrift Acta chirurgiae plasticae werden Originalarbeiten, die sämtliche Probleme der plastischen Chirurgie betreffen, in russischer, englischer, deutscher, französischer und spanischer Sprache angenommen und in den angeführten Sprachen publiziert. Die Arbeiten müssen in 2, gut leserlichen Exemplaren, angefertigt sein. Jeder Artikel muss ein genügend langes Resumé, wenigstens in 3 Exemplaren enthalten. In dem Titel ist der Arbeitsplatz, dem die Arbeit entstammt, d. i. der Leiter des Arbeitsplatzes mit vollem akademischen Titel, und soweit es sich um eine Universitätsklinik handelt, ebenfalls deren Sitz und Bezeichnung anzuführen. Literaturangaben sind nach den interationale Gebräuchen anzuführen. Bildbeilagen: photographische Dokumentation schwarz-weiss, unretouchiert, auf Glanzpapier. Zeichnungen und Graphe sollen klar und reproduktionsfähig sein. Bei allen Bildbeilagen ist eine vertikale Anordnung erwünscht. Die Bezeichnung der Bilder muss deutlich, der Unterrand auf der Rückseite bezeichnet sein. Die Bezeichnung der Photographien und der Graphe muss auf der Rückseite ebenfalls eine Ordnungsnummer, Namen des Autors und Titel der Arbeit enthalten. In der Handschrift muss annähernd die Stelle bezeichnet sein, wohin die Abbildung logisch gehört, um sie im Text richtig einordnen zu können. Die Redaktion erwartet, dass sich die Autoren mit Ihren Beiträgen auf einen entsprechenden Umfang beschränken werden.

INFORMATIONS PRÉLIMINAIRES AUX AUTEURS

Pour la publication dans la revue Acta chirurgiae plasticae seront acceptées les oeuvres originales concernant tous les problèmes de la chirurgie plastique en langues russe, anglaise, allemande, française et espagnole et seront publiées dans ces langues. Les oeuvres doivent être rédigées en 2 exemplaires très lisibles. Chaque article doit contenir un résumé suffisamment long, au moins en trois exemplaires. Dans l'en-texte doit être indiqué le lieu de travail duquel l'ouvrage provient, c'est-à dire le titre du lieu du travail, le nom du travail dirigeant avec les titres académiques en entier. Dans le cas où il s'agit d'une clinique universitaire, le nom et le siège de l'université doivent être également indiqués. La littérature doit être intitulée d'après les usages internacionaux. Annexes illustrées: documentation à photographies noir sur blanc, non retouchées, brillantes. Les dessins et graphiques doivent être clairs et aptes à la reproduction. Pour toutes annexes illustrées le rendement vertical est recommandé. La description des illustrations doit être bien distincte, la limite inférieure doit être marquée au verso. De même la descriptions des photographies et graphiques au verso doit contenir le numéro d'ordre et le nome de l'auteur avec le titre de l'article. Dans le manuscrit doit être indiqué d'une façon très visible l'endroit où la reproduction doit figurer, afin qu'il soit possible de la placer exactement dans le texte. La rédaction serait reconnaissante aux auteurs de limiter leurs contributions à une longueur normale.

INFORMACIÓN PRELIMINAR PARA LOS COLABORADORES

Los artículos originales sobre todos los aspectos de la cirugía plástica pueden ser aceptados para su publicación en „Acta chirurgiae plasticae", en ruso, inglés, alemán, francés y español. Son requeridas dos copias del manuscrito claramente legibles. Cada artículo debe estar provisto de un adecuado resume, por lo menos en tres copias. En el encabezamiento se incluirá el nombre de la institución en la cual el trabajo tomado se ha realizado, eventualmente, el nombre de la institución, el nombre de la cabeza de la institución completamente con el título académico, en el caso de un clínico universitario, el nombre y lugar de la universidad. Las referencias serán anotadas en las formas internacionalmente aceptadas. Ilustraciones: la documentación fotográfica — en blanco y negro, no retocadas, con brillo. Los dibujos y los gráficos deben ser claros y apropriados para la reproducción. En el caso de todas las ilustraciones es bienvenido un ordenamiento vertical. Las ilustraciones deben estar claramente marcadas con el borde inferior indicado en el lado reverso. En forma similar la anotación de las fotografías y los gráficos en el lado reverso debe incluir su número y el nombre del autor junto con el título del artículo. La propia posición de cada ilustración debe estar claramente indicada en el manuscrito, ya que ésta debe estar correctamente situada en el texto. El comité editorial confía en que los autores limiten sus artículos a un largo razonable.