ACTA CHIRURGIAE PLASTICAE

INTERNATIONAL JOURNAL
OF PLASTIC SURGERY

23 · 4

1981

CS ISSN—0001—5423

AVICENUM · CZECHOSLOVAK MEDICAL PRESS
PRAGUE

Exclusive Distributors for all Western Countries
KARGER-LIBRI AG, Petersgraben 31, CH-4000 Basel 11 (Switzerland)

Published four times (in 1959: two times) a year by Avicenum - Czechoslovak Medical Press, Malostranské nám. 28, Praha 1. Editor in Chief Prof. H. Pešková, M. D. — Address of the Editorial Office: Acta Chirurgiae Plasticae, 120 00 Praha 2, Lidových milicí 63, Czechoslovakia. — Press: Tiskařské závody, n. p., Praha, závod 1 — provoz 11, Praha 2, Hálkova 2.

Subscription rate: sFr 109,— plus postage Exclusive distributors for all countries with the exception of Albania, Bulgaria, China, Cuba, Czechoslovakia, German Democratic Republic, Hungary, North Korea, Vietnam, Mongolia, Poland, Rumania, Union of Soviet Socialist Republics and Yougoslavia:

KARGER LIBRI AG, Petersgraben 31, CH-4000 BASEL 11 (Switzerland)

PHYSICIANS AGAINST THE NUCLEAR WAR

The Czechoslovak Medical Society J. E. Purkyně, the Scientific Council of the Ministry of Health of the Czech Socialist Republic and the Scientific Council of the Ministry of Health of the Slovak Socialist Republic fully support the appeal "To the Scientists of the World" signed by leading Soviet scientists as well as the resolutions of the First International Congress of Physicians which in March this year discussed in the USA the necessity to prevent a nuclear war.

In particular we, doctors and scientists, are fully aware of the mortal danger which a possible nuclear war entails for mankind and of how many chances are wasted for solving urgent medical problems in this world by attempts to bring about a new feverish arms race. We are no less disturbed by efforts to justify the permissibility or even expedience of a "limited" nuclear war and by the exertion of certain groups to increase the potential of nuclear and other deadly weapons.

Already the first nuclear attack in a modern war would cause the death of at least 200 million people and serious injuries and suffering to further 60 million. More than 80 % of hospital beds would be destroyed, food and water contaminated, transportation and communication systems put out of action. There would be severe changes in the weather giving rise to serious shortages in animal and plant production. Those who would survive, and especially children. would be afflicted in great numbers by malignant tumours and leukemia.

Being aware of this horrible danger we appeal to all our colleagues and members of national and international medical organizations and to their international central office CIOMS to fight against further rearmaments and for averting the nuclear war at congresses and symposia of scientific institutions. We are calling on the Director General of the World Health Organization, Dr. G. Mahler, to establish, according to the resolution of the 34th General Meeting of WHO, in cooperation with the Secretary General of the United Nations an international committee of scientists who would objectively make clear to the world public the threat and fatal consequences of a nuclear war for the life and health of the world population.

The present-day situation cannot leave us indifferent. In contributing to the fight against further arms race and against abuses of the fruits of science we feel to be fulfilling our duty to present and future generations of all continents and all nations.

Czechoslovak Medical Society J. E. Purkyně

Prof. B. Špaček, M. D., DSc.
Chairman
Czech Medical Society

Prof. T. R. Niederland
Chairman
Slovak Medical Society

Prof. P. Pudlák, M. D., DSc.
Chairman of Scientific Council
Ministry of Health of CSR

Prof. J. Rusnák, M. D., DSc.
Chairman of Scientific Council
Ministry of Health of SSR

N. A. Semashko's Moscow Medical Institute of Stomatology, Moscow (USSR)
Department of Paediatric Stomatology
Director professor A. A. Kolesov

TREATMENT OF MANDIBULAR BONE HAEMANGIOMA BY BIOLOGICAL PLASTIC TAMPONADE IN CHILDREN

A. A. Kolesov, N. N. Kasparov, S. V. Dyakov, M. A. Pershin

A bonne haemangioma of jaws, localized strictly in a bone tissue, has been seen extremely rarely (Kholdin 1935, Nesvizhskii 1955, Kondrashin 1963, Krivolutskaya 1963, Gorbushina 1978).

More than 400 children suffering from facial haemangiomas of varied localizations have been treated in our Department during last 17 years. The neoplasm was localized solely in the jaw bones only by 7 children: by 2 patients in the left part of maxilla and by 5 patients in mandibula. The diagnosis of maxillar haemangioma was quite easy, as the tumour markedly pulsated.

In this paper, the clinical and roentgenological features, diagnostic and treatment of 5 children affected with mandibular haemangioma will be dealt with in detail. The patients were 4 girls and 1 boy in the age from 8 to 13 years.

It is agreed by all the surgeons treating haemangiomas that diagnosis of mandibular haemangioma is difficult. The roentgenological features were thoroughly described by Vorobyev et al. (1963).

The diagnosis of 3 patients was established from findings obtained by X-ray examination and puncture of the neoplasm. By a girl, 8 years old, an open surgical biopsy was required, in order to settle the diagnosis of the capillary type of the haemangioma (Fig. 1a). A girl, 9 years old, was brought to our Clinic by the Emergence Service, because of a profuse bleeding from the tooth bed 6, which started during extraction of the tooth (Fig. 2a).

The intraosseal cavernous type of haemangioma occurred by 4 children, the capillary type by 1 child.

Clinically, an insignificant deformation of mandibula (a moderate bulging) was observed by all the children. Byl 4 children, a slightly visible vascular net was noted in the skin and mucosa of the alveolar process. This sign was absent by a patient with the capillary form.

Roentgenologically, regions of osteoporosis appeared in the corpus of the mandibular bone in cases of the cavernous haemangioma. They were encountered as circular holes (Fig. 2a) or as a large singular cavity surrounded by several smaller eliptical or circular cavities (Fig. 3a).

A fresh blood was easily sucked into the syringe during the puncture of the cavities.

The clinical and roentgenological features of the capillary form of haemangioma (Fig. 3a) had to be differentiated from a fibrotic dysplasia; the final diagnosis was settled following and open surgical biopsy.

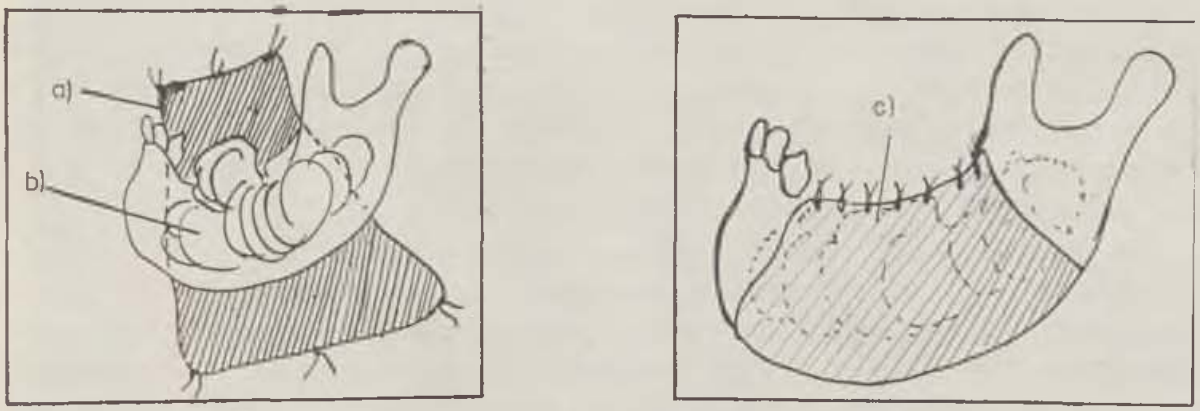

Fig. 4. A diagramm of the operation

Since 1965, a biological plastic tamponade of bone cavities has been used for treatment of the mandibular haemangiomas. A similar technique used for tamponade of bleeding wound cavities formed by excision of haemangiomas on extremities was suggested by other surgeons (Krakovskii and Taranovitch, 1965, 1974).

The course of the operation will be described. The external temporal artery is temporarily ligated. An incision is led in the submandibular region. The soft tissues are carefully liberated from the mandibular surface along the pathological focus. The oral mucosa is incised along the transitional fold and further along the lingual surface of the corpus mandibulae. A preserved flap of fascia or cerebral dura mater (frozen or lyophilized) was introduced into the wound (Fig. 4a). Then, 1—2 teeth had to be exstirpated and a gauze wad soaked in iodoform was quickly pulled through the alveolus into the bone cavity. All the teeth occuring in the region of the pathological mandibular focus had to be removed. The gingival and alveolar mucosa was excised in the limits of the exstirpated teeth. Then, the tampon soaked in iodoform was taken off and quickly and cautiously replaced by the second flap of the preserved tissue (Fig. 4b), which was inserted into the bone cavity as firmly as possible. The corpus mandibulae was tightly covered by a previously prepared flap (Fig. 4c). In this way, the fascial flap inserted into the bone cavity was kept in place and the bleeding was stopped.

In the case of the capillary type of haemangioma, the altered bone was partially removed and the mandibular corpus was covered by the lyophilized fascia.

In the oral vestibulum, one or two subsidiary incisions of mucosa were led as prolongation of the original incision or oriented to a transitional fold in a straight or obtuse angle. By the end of the operation, the oral mucosa and the submandibular soft tissues were sewn in layers.

The results of treatment were reexamined 5 to 14 years later. The following conclusions could be drawn from the obtained data.

During 2—3 years after the operation, a rebuilding of the bone resulting in normal structure (Fig. 3b) or sclerosis (Figs. 1b, 2b) took place in the region of mandibula, where the tamponade was applied and the mandibular corpus was covered by the flap. It is very important to make a copy showing size of the surgery in the chin region of the mandibular corpus. As the child grows, the haemangioma may also develop further and secondary treatment may be required. It happened by a girl, who was operated by us.

Patient Ya., 9 years old (Fig. 2) was operated on in 1965, as it was described. About 3—4 years later, some osteoporotic foci appeared in the region of preserved premolars, which continued to enlarge. Five years later, the premolars became pathologically mobilized. Following three attempts of the intraosseal sclerosing treatment by a solution of urethane and chinin, the premolars were exstirpated. However, new osteoporotic foci appeared again in the alveolar process of the chin part of mandibula by the girl in the age of 16 years. A vascular net was distinctly visible on several sites of gingival and sublingual mucosa.

A X-ray irradiation was applied in the total dose of 1200 R. The patient has remained under observation till this time. She became pregnant and delivered a normal child.

Based on our experience, the described technique is recommended as treatment of the bone cavernous haemangiomas that do not penetrate cortical layer of the bone. Using the method of the biological plastic tamponade, the resection of the mandibula is unnecessary, integrity of the mandibular bone is preserved and a final rebuilding of the bone tissue, i. e. healing of the patient, is achieved.

M. T.

SUMMARY

A method of biological plastic tamponade was described. It was applied in treatment of the mandibular bone haemangiomas. The results of treatment were followed for 5—14 years. It is recommended by the authors to utilize this technique in practice, as a bone integrity is preserved and a resection of mandibula is unnecessary.

RESUME

Le traitement du hémangiome osseux de la mandibule aux enfants en appliquant la méthode du tamponnement biologique plastique

Koléssove A. A., Kasparova N. N., Diakova S. V., Perchina M. A.

Les auteurs décrivent la méthode du tamponnement biologique plastique. Celle-ci fut appliquée pendant le traitement du hémangiome de la mandibule. On a étudié les

résultats du traitement au cours de 5 et 14 années. Les auteurs recommandent application de cette méthode grâce à laquelle l'intégrité des os reste conservée et il n'est pas indispensable de se réfugier à la résection de la mandibule.

ZUSAMMENFASSUNG

Behandlung des Knochenhämangioms des Unterkiefers bei Kindern durch die Methode der biologischen plastischen Tamponade

Kolesow A. A., Kasparowa N. N., Djakowa S. V., Perschina M. A.

Es wurde eine Methode der biologischen plastischen Tamponade beschrieben. Diese Methode wurde bei der Behandlung des Unterkieferhämangioms benutzt. Die Behandlungsergebnisse wurden 5—14 Jahre lang verfolgt. Die Autoren empfehlen die Anwendung dieser Methode, da die Integrität des Knochens erhalten bleibt und die Resektion der Mandibula nicht unvermeidlich ist.

RESUMEN

Tratamiento del hemangioma óseo de la mandíbula inferior de los niños por método de taponamiento plástico biológico

Kolesov A. A., Kasparova N. N., Diakova S. V., Perschina M. A.

Se describe el método de taponamiento plástico biológico. Este método fue utilizado en el tratamiento del hemangioma de la mandíbula inferior. Los resultados del tratamiento fueron estudiados durante un período de 5 a 14 años. Los autores recomiendan utilizar dicho método puesto que así se conserva la integridad del hueso, no resultando indispensable la resección de la mandíbula.

REFERENCES

1. **Vorobyev, Yu. I., Gorbushina, P. M., Kritskii, A. A.:** Roentgenological Features of Mandibular Haemangiomas. (In Russian.) Stomatologija, 3: 50, 1963.

2. **Gorbushina, P. M.:** Vascular Neoplasm of Face, Jaws and Organs in Oral Cavity. (In Russian.) Meditsina, 151 p., Moscow 1978.

3. **Kondrashin, N. I.:** Clinical Characteristics and Treatment of Haemangiomas by Children. (In Russian.) Meditsina, 106 p., Moscow 1963.

4. **Krakovskii, N. I., Taranovitch, V. A.:** New Developments in Diagnostics and Surgical Treatment of Large Haemangiomas on Extremities. (In Russian.) Zh. Eksp. Khir. 4: 62, 1965.

5. **Krakovskii, N. I., Taranovitch, V. A.:** Haemangiomas. (In Russian.) Meditsina, 176 p., Moscow 1974.

6. **Krivolutskaya, E. G.:** A Case of the Central Cavernous Haemangioma of Mandibula. (In Russian.) Stomatologija, 4: 87, 1963.

7. **Nesvizhskii, S. O.:** To the Problem of Mandibular Haemangiomas. (In Russian.) Stomatologija, 4: 30, 1955.

8. **Kholdin, S. A.:** Haemangiomas and their Treatment. (In Russian.) 150 p., Leningrad 1935.

Prof. A. A. Kolesov, N. A. Semashko's Moscow Medical Institute of Stomatology, Delegatskaya 20/1, 103473 Moscow, USSR

Comenius University Medical Faculty, Bratislava (Czechoslovakia)
Department of Plastic Surgery
Head As. Prof. F. Mariš, M. D., CSc.

ARTERIAL FOREHEAD FLAPS IN RECONSTRUCTIVE SURGERY OF THE FACE

F. Mariš

Arterial flaps taken from the forehead and used in reconstructive surgery of the face take advantage of the blood supply from the following arteries and their venous systems: a. supratrochlearis, a. supraorbitalis, a. temporalis superficialis.

The ramifications and mutual anastomoses of the aboved described three principal sources of blood supply permit the construction of different types of forehead flaps. These can be used for the covering of defects, for the restoration

Fig. 1.

Fig. 2.

of skin cover in different areas of the face, or for the reconstruction of its organs. They are also useful for the reconstruction of oral cavity floor and buccal wall lining, the tongue or palate. Arterial forehead flaps are used in the classical form of simple full-thickness flaps, i. e. cutis and subcutis, or as combined musculocutaneous flaps, possibly with the simultaneous transfer of other tissue structures.

Fig. 3.

Fig. 4.

In the construction of arterial forehead flaps it is not necessary to keep to the empirically established width-length ration to ensure adequate blood supply as in skin flaps; the length of an arterial flap is, as a rule, a multiple of the supplying pedicle width.

An arterial flap may be given the shape of a peninsula. The connection to the donor site is provided by the pedicle complete with the supplying and draining vessels or neurovascular bundle.

M. L., 37 years (clin. n. No. 18094) had the left wing of the nose resected in 1977 for epidermoid carcinoma (Fig. 1). The wing was reconstructed in 1978 using a forehead flap supplied from the a. supratrochlearis; the flap was lined with a free skin graft taken from the shoulder with a view to reconstructing the vestibular lining (Fig. 2). The state at check-up 3 years after is shown in Fig. 3.

P. J., b. 1930 (clin. n. No. 321) suffered loss of nose as a result of electric contact injury (Fig. 4, 5). A forehead flap according to Converse was used for reconstruction (Fig. 6).

Fig. 5.

Fig. 6.

Fig. 7.

Fig. 8.

M., 70-year old female patient (clin. n. No. 19639). Tumour of the right wing of nose extirpated in 1975. Readmission to the clinic for basocellular carcinoma relapse in 1980. Fig. 7 shows extent of tumour, planned excision, and forehead flap, part of which was used for lining and reconstruction of wing (A), buccal part (B) and lateral part of nose (C). Donor site was closed by suture, and the flap was sutured to the nasal wing (Fig. 8). Cut off, the flap pedicle was sutured back to the forehead (Fig. 9).

Fig. 9.

Fig. 10.

The flap pedicle, particularly if it is relatively broad, may restrain flap transfer to a new position, and the pressure of its tissue may reduce or even block blood flow through the nutrient and, especially, draining vessels in cases where the pedicle is bent at more than 90^0. For that reason it is advisable to use an island flap with a pedicle made up of only nutrient vessels or a neuro-vascular bundle (Fig. 13—16). An island flap of this type is easier to transfer to the recipient site either straight or through a tunnel created by surrounding tissue mobilization.

B. S., 56 years (clin. n. No. 18121) had basalioma of the nose removed in 1977; the defect was covered with free skin graft. In 1980, relapsing basalioma had to be resected wide and deep in healthy tissue (Fig. 10) involving the removal of part of the lateral and apical cartilages. The defect was covered using an arterial island forehead flap supplied from the supratrochlear artery (Fig. 11). With the flap sutured into the defect, the donor site was covered with

Obr. 11.

Obr. 12.

Obr. 13.

a free full-thickness graft taken from the retroauricular region (Fig. 12). State at check-up 8 months after surgery is shown in Fig. 13.

Another technique involves the transfer of free arterial flaps where the main supplying and draining vessels are cut off and, using immediate anasto-

Obr. 14.

mosis, connected to the vascular system of the recipient site. Smaller vessel anastomoses require the use of microsurgical techniques, and are found useful especially in free flap transfer from the more remote regions of the body.

The use of arterial flaps from the forehead in reconstructive surgery of the face offers two salient advantages.

First, the advantage of immediate primary provision of skin cover on the face, reconstruction of the relief of the face, albeit not always absolutely perfectly accomplished, or else reconstruction of facial organs or just the beginning of such reconstruction in that biological material is brought to the damage site. This means doing without preparatory operations involved in transferring biological material to the face through the conventional techniques the way it used to be done or still is when the need arises to transfer tube or island flaps from some of the more remote regions of the body. The significance of this is underlined when reconstruction is necessary after radical resection for malignant tumours or for injuries involving facial tissue loss.

The primary application of skin flaps makes redundant secondary healing of the defect or the need to use free skin grafts for temporary wound cover before some more appropriate biological material in the form of skin flap is made available, e. g. a tube flap.

M. Z., 68 years (clin. n. No. 19802) was first operated on for basocellular carcinoma near the outer corner of the left eye. He received three operations and radiotherapy. In 1978, exenteration of the left eye had to be resorted to for another relapse. In 1979, the patient was referred to our clinical department with a new relapse (Fig. 14). Radical resection was made of the soft parts,

lower orbital wall and anterior maxillary cavity wall complete with evacuation of ethmoidal and maxillary cavities. A forehead flap used for covering the defect, and the donor site was covered with a free skin graft (Fig. 15). Following flap disconnection (Fig. 16) an epithesis was made and fixed to the frames of the patient's glasses (Fig. 17).

Obr. 15.

Obr. 16.

Obr. 17.

The other major advantage of arterial forehead flaps is the provision of biological material, the texture, coloration and composition of which is identical with or very similar to that which is being replaced at the site of the defect. The price to pay for this advantage is the appearance of scarring along the sutured donor site, or the need to use a free skin graft in case the defect on the donor site is too large to be closed by simple suture. Well healed, however, the forehead scar will after some time become fairly inconspicuous, and even a large free skin graft is hardly noticeable on the forehead. It seems a fair assumption then that this disadvantage is more than adequately made up for by the speedy reconstruction of the affected part of the face with suitable material, and by the avoidance of too many operations. J. H.

SUMMARY

The use of arterial forehead flaps in reconstructive surgery of the face offers two advantages. It permits the primary closure of major defects, restoration of the relief and reconstruction of the organs of the face. The flaps can also be used for oral cavity lining, tongue and palate reconstruction. Thus, material biologically very like that which originally covered the damaged site is made available for facial surface reconstruction.

Island flaps taken from the forehead are increasingly significant for oncosurgical reconstruction and in cases of tissue loss facial injuries. The arterial flaps may take the form of a peninsula, an island or a free transfer flap using microsurgically established vascular anastomoses of the nutrient arteries and veins.

The forehead region yields either simple skin flaps or combined, particularly musculocutaneous flaps supplied from the a. supratrochlearis, a. supraorbitalis and a. temporalis superficialis. Case reports are included on some of the patients who received arterial forehead flaps for reconstructive surgery of the face performed at the Bratislava Department of Plastic Surgery.

RESUME

Lambeaux artériels provenant du front dans la chirurgie reconstructive de la face

Mariš F.

L'application des lambeaux artériels provenant du front dans la chirurgie reconstructive de la face présente deux avantages. Elle permet de couvrir primairement de gros défauts, de reconstruire le relief de même que les organes de la face. Les lambeaux peuvent être appliqués également pour reconstruire l'épithélium de la cavité buccale, de la langue et du palais. Pour reconstruire la surface de la face on obtient le matériel qui ressemble du point de vue biologique à celui qui se trouvait dans les parties endommagées de la face.

Les lambeaux artériels provenant du front jouent un rôle important aux cas des reconstructions oncochirurgicales ainsi qu'aux cas des blessures de perte de la face.

Les lambeaux artériels provenant du front peuvent être appliqués en forme d'une île, d'une présqu'île ou d'un lambeau transposé librement sur la base de l'anatomose vasculaire des artères et des veines approvisionneurs, par la technique microchirurgicale.

On se sert surtout des lambeaux cutanés simples ou combinés, le plus souvent les lambeaux cutano-masculaires approvisionnés par a. supratrochlearis, a. supraorbitalis et a. temporalis superficialis. On montre quelques cas des patients chez qui on a appliqué les lambeaux artériels provanant du front en cas de la chirurgie reconstructive de la face à la clinique de la chirurgie plastique de Bratislava.

ZUSAMMENFASSUNG

Arterielle Lappen aus der Stirn in der Wiederherstellungschirurgie des Gesichtes

Mariš F.

Die Anwendung der arteriellen Lappen aus der Stirn in der Wiederherstellungschirurgie des Gesichtes bietet zwei Vorteile. Sie ermöglicht die primäre Schliessung umfangreicher Defekte, die Erneuerung des Reliefs und die Wiederherstellung der Gesichtsorgane. Ebenfalls kann man sie zur Wiederherstellung des Epithels der Mundhöhle, der Zunge und des Gaumens benutzen. Für die Wiederherstellung an der Gesichtsoberfläche wird ein Material gewonnen, das biologisch sehr ähnlich jenem ist, das an der Stelle der Gesichtsschädigung war.

Arterielle Lappen aus der Stirn gewinnen ihre Bedeutung in der onkochirurgischen Wiederherstellung und bei Verlustverletzungen des Gesichtes.

Arterielle Lappen aus der Stirn kann man in Form einer Halbinsel, eines inselförmigen Lappens oder eines frei übertragenen Lappens auf der Basis der Arterienanastomose der versorgenden Arterien und Venen auf dem Wege der mikrochirurgischen Technik benutzen.

Aus der Stirn benutzt man einfache Hautlappen, oder kombinierte Lappen, vor allem Muskelhautlappen, die durch a. supraorbitalis und a. temporalis superficialis versorgt sind. In der Arbeit werden einige Patienten demonstriert, bei denen arterielle Lappen aus der Stirn in der Wiederherstellungschirurgie des Gesichtes an der Klinik der plastischen Chirurgie in Bratislava benutzt wurden.

RESUMEN

Lóbulos arteriales de la frente en la quirurgía de reconstrucción de la mejilla

Mariš F.

La utilización de lóbulos arteriales de la frente en la quirurgía de reconstrucción de la mejilla brinda dos ventajas. Posibilita un cubrimiento primario de los defectos, la renovación del relieve y la reconstrucción de los órganos faciales. Asimismo puede ser utilizado para la reconstrucción de la mucosa de la cavidad bocal, de la lengua y el paladar. Para reconstrucciones en la superficie de la faz se emplea un material muy similar al que se encontraba en el lugar del defecto.

Los lóbulos arteriales de la frente adquieren importancia en la reconstrucción oncoquirúrgica y en las heridas faciales de estrato. Los lóbulos arteriales de la frente pueden ser utilizados en forma peninsular, insular o lóbulo libremente transferido a base de anastomosis vascular de las arterias y venas por medi de la técnica de microquirurgía.

Utilízanse de la frente lóbulos cutáneos simples o combinados cutáneo-musculares alimentados por la a. supratrochlearis, la a. supraorbitalis y la a. temporalis superficialis. En el trabajo se mencionan algunos pacientes de la Clínica de cirugía plástica de Bratislava en quienes se han utilizado lóbulos arteriales de la frente para la reconstrucción facial quirúrgica.

REFERENCES

1. **Barbosa, J. F.**: Surgical Treatment of Head and Neck Tumours. Grune, Straton, New York, London, 1974, p. 311.

2. **Converse, J. M.**: Reconstr. plast. Surg., 2nd ed., Vol. I, W. B. Saunders Co., Philadelphia, 1977.

3. **Grabb, W. C., Myers, M. B.**: Skin Flaps, Little, Brown Co., Boston 1975, p. 548.

4. **Grabb, W. C., Smith, J. W.**: Plastic Surgery. A Concise Guide to Clinical Practice. Little, Brown Co., Boston 1973, p. 1085.

5. **Naumann, H. H.**: Head and Neck Surgery, Vol. 1. Georg Thieme, Stuttgart 1980 p. 473.

6. **Pfeifer, P.**: Wiederherstellung der Naseform bei partiellen und totalen Defekten. Fortschritte der Kiefer und Gesichtschirurgie, XXIII, p. 125—129. Georg Thieme Verlag, Stuttgart 1978.

7. **Shah, J. P.**: Folded Forehead Flap for Reconstruction of fullthickness Defects of the cheek. Head and Neck Surgery, 2, 3: 248, 1980.

Dr. F. Mariš, Clinic of Plastic Surgery, 800 00 Bratislava, Czechoslovakia

Prague Municipal Institute of Cosmetic Care, Prague (Czechoslovakia)
Director O. Feřtek, M. D., CSc.
Department of Plastic Surgery
Head K. Fahoun, M. D.

A FEW COMMENTS ON OSTEOTOMY IN RHINOPLASTY

K. Fahoun

Resection of nasal protuberance breaks all continuity between the upper lateral cartilage and the septum, thus leaving the lateral connection with the nasal bone as the only one to support the upper lateral cartilage and to form a smooth lateral line. Discontinuity there gives the patient a nose which looks like broken on that particular side. Also the nasal axis in its lower part becomes deviated towards the affected side. Moreover, the inner nasal valve becomes narrowed and its movement limited. While expiration is normal, inspiration is impaired owing to the loose upper lateral cartilage collapsing against the septum. In cases of bilateral discontinuity, the medial third of the nose is narrowed, and the point of junction between the bone and the upper lateral cartilages is made conspicuous due to bilateral compression. The functional capacity of the nose is thus impaired, and the patient may suffer from olfactory disorder since the air flow is channeled straight in without having to pass through the upper recess of the nasal cavity so important for olfaction. This may easily be the result of the technically wrong use of raspatory in rhinoplasty (see diagram 1). The instrument should be applied obliquely to the axis of the nose, and solely to its bony part.

The upper lateral cartilage is triangular, its lower edge forming an angle of about 120 degrees with the upper edge of the septum. Excessive resection of the caudal end of the upper lateral cartilage should be avoided in any operation designed to shorten the nose, and so should an excessive narrowing of the lower lateral cartilage, The resulting retraction would mean too much exposure for the mucosa making it protrude into the nasal vestibule and possibly giving rise to vestibular atresia as a result of adhesions. Inadequate postoperative tamponage may prove to be another contributory factor. According to my own experience, at least 80 % rhinoplasty patients suffer from a certain degree of nasal vestibule reduction caused by adhesions.

Caution is also advised in lower lateral cartilage resection if apex nasi collapse is to be avoided. Correction here poses a great deal of difficulty. If

the apex is too blunt, techniques other than radical or even total removal of the lower lateral cartilages ought to be used. While collapse of the tip will be achieved, the whole front vault will be left without support. Sufficient support

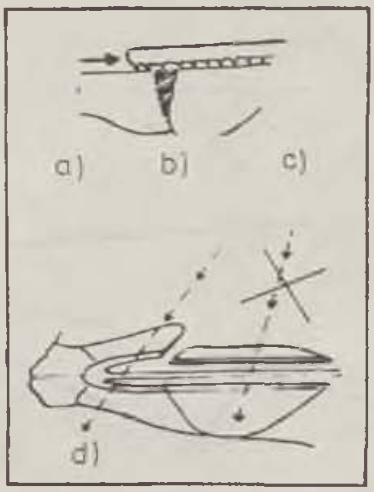

Diagram 1 — Raspatory used in rhinoplasty

a) bone
b) junction
c) upper lateral cartilage
d) correct application of raspatory

for the front vault and tip of nose can only be provided by cartilaginous edge 3 to 4 mm wide (diagram 2). It is only then that the tip can be shaped by working the edges.

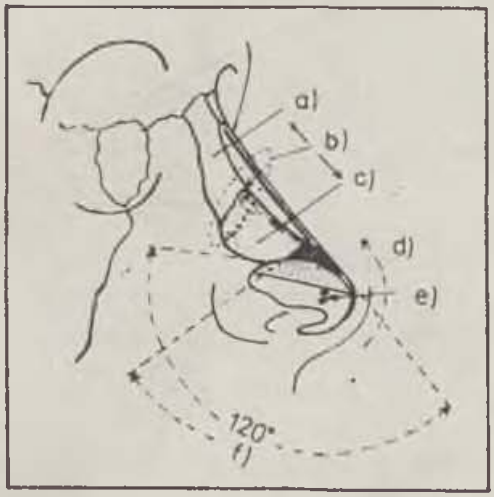

Diagram 2 — Recommended maximum reduction in rhinoplasty

a) bone
b) junction
c) upper lateral cartilage
d) nose shortening
e) 3—4 mm edge
f) after resection

Osteotomy is used for reducing the width and the height of the nose. Bridge reduction makes lateral osteotomy essential as the pyramid of the nose has to be closed again. A diagram showing post-osteotomy changes in the shape of the pyramid will give a clearer idea of the mechanism of nasal bones mobilization (diagram 3).

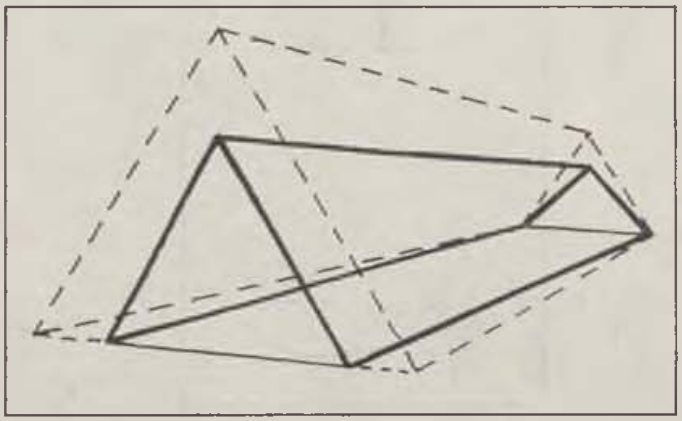

Diagram 3 — nasal bone structure pyramids

The pyramid of the nasal bone structure is really made up of a series of traingles growing in size from the smallest at the root to the largest at the caudal end of the nasal bones. In order to close the top left open by the resection and to reconstruct a new, smaller pyramid, the lateral osteotomy line should

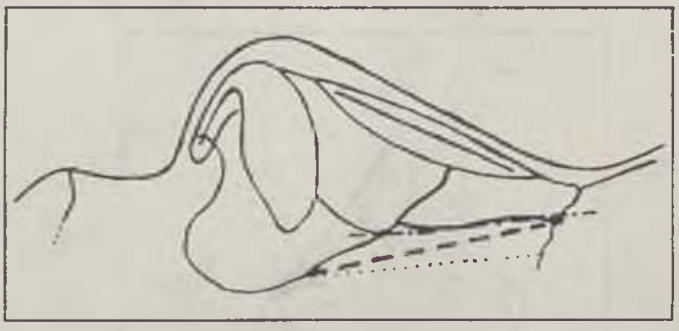

Diagram 4 — Types of osteotomy

follow the lateral edge of the pyramid as shown in diagram 4 (dashed line — LOW TO HIGH osteotomy). After osteotomy, the greatest medial shift is in the caudal direction, the least at the root (diagram 4).

HIGH TO HIGH osteotomy (dash-and-dot line) will result in a caudal depression and in the shaping of a new, smaller pyramid. This only shows the importance of starting osteotomy as low as possible at the piriform aperture.

LOW TO LOW osteotomy (dotted line) is often recommended. In this type of osteotomy the beginning is correct enough. However, the osteotomy line which runs roughly parallel to the bridge line is bound to result in a very wide cranial part of the nasal bone. Medial osteotomy and infraction are inevitable here in order to mobilize the bones medially, thus often giving rise to a depression at the root of the nose. In LOW TO HIGH osteotomy it is seldom necessary to resort to medial osteotomy.

By way of conclusion, attention ought to be drawn to variability in the nasal bone length. The bone usually ends half way between the root and the nasal septum angle. But it may reach as far as the edge of the piriform aperture, or it may be abnormally short or missing altogether. The nasal bone structural difference are of considerable aesthetic or even functional significance for the outcome of the operation. I should like to warn against osteotomy in cases of short nasal bone as the lateral wall of the medial vault of the nose is liable to collapse towards the septum. For that reason the actual length of the nasal bone should first be palpated using the thumb and the index in opposition. If it is found too short, the middle third of the nose will collapse between the fingers as it is made up of nothing but cartilage and soft tissues.

J. H.

SUMMARY

The Low to High technique of osteotomy is recommended for use in rhinoplasty. A list is presented of some of the mistakes likely to be made by the surgeon performing an osteotomy. The author warns against osteotomy in too short nasal bones, stressing the need for careful preoperative examination of the nasal bone structure.

RESUME

Quelques remarques sur l'osteotomie en cas d'une rhinoplastie

Fahoun K.

Dans l'article on recommende la méthode Low to High de l'osteotomie en cas d'une rhinoplastie. On note aussi plusieurs fautes que l'opérateur pourrait soumettre quant à la technique de l'osteotomie. L'auteur montre le danger de l'osteotomie en cas de l'os nasal court et il souligne la nécessité de l'examen préopératoire du squelette nasale.

ZUSAMMENFASSUNG

Einige Bemerkungen zur Osteotomie bei der Rhinoplastik

Fahoun K.

Im Artikel wird das Low-to-High-Verfahren der Osteotomie bei der Rhinoplastik empfohlen. Es werden auch einige Fehler angeführt, die der Operateur in der Technik der Osteotomie begeht. Der Autor warnt vor der Osteotomie bei kurzem Nasenknochen und hebt die Notwendigkeit der präoperativen Untersuchung des Nasenskelletts hervor.

RESUMEN

Algunas sugerencia sobre la osteotomie en la rinoplastia

Fahoun K.

En el artículo se recomienda el método de la osteotomia Low to High empleada en la rinoplastia. Se mencionan asimismo algunos de los errores que el operador puede cometer en la técnica de osteotomia. El autor advierte contra la osteotomia en el corto hueso nasal subra yando la necesidad de un examen preoperatorio del esqueleto nasal.

REFERENCES

1. **Fomon, S. et al.**: Physiological Principles in Rhinoplasty. Arch. Otolaryn., 53: 256, 1951.

2. **Millard, R. D., jr.**: Symposium on Corrective Rhinoplasty. Vol. 13, St. Louis, 1976, The C. V. Mosby Co.

3. **O'Connor, G. B., McGregor, M. W.**: Secondary Rhinoplasty. Plast. reconstr. Surg., 15: 404, 1955.

4. **Sheen, J. H.**: Secondary Rhinoplasty. Plast. reconstr. Surg., 56: 135, 1975.

5. **Sheen, J. H.**: Esthetic Rhinoplasty. St. Louis, 1978, The C. V. Mosby Co.

Dr. K. Fahoun, Institute of Cosmetic Care,
Jungmannova 31, 110 00 Prague 1, Czechoslovakia

Prague Municipal Cosmetic Institute, Prague (Czechoslovakia)
Director O. Feřtek, M. D., CSc.
Department of Plastic Surgery
Head K. Fahoun, M. D.

SECONDARY CORRECTION OF TIP OF NOSE

K. Fahoun

Drooping or sunken tip of the nose is very often a telling sign of unsuccessful rhinoplasty. An aesthetic line of the ridge-tip junction and its continuation in the tip-columella-lip line are among the most important features of an aesthetically shaped nose. Consequently, reconstruction of this line constitutes the most delicate and complex part of the whole rhinoplasty. This particular problem is often encountered in primary rhinoplasty but far more often in corrective secondary plastic operation of the nose. A drooping tip of the nose may be due to quite a few causes: too radical a reduction of the ridge (here I should always recommend a conservative approach to reduction), a wrong angle of the line of ridge resection, insufficient support for the apex nasi caused by excessive or complete removal of the apical cartilages, or by excessive shortening of the septum. Augmentation and transposition of the supportive structures of the tip are inevitable here. This has been well known for more than half a century, and it is exactly the multitude of proposed approaches that suggest how complicated the problem is. Yet we keep coming across drooping tips of the nose all the same.

One of the techniques we use in coping with such cases involves the use of apical implant augmentation. To do so we use auto- or homomartilage which makes success and easy healing the most likely. Resected parts of the lower lateral cartilage, septum, ridge, or concha auriculae are used as reconstruction material to be given the required shape and size as shown in Fig. 1.

The operation is performed in local anaesthesia from the side of the columella, never from the midline. The bed for the implant is prepared with scissors. It should be large enough but not too large. The quality of the implant has to guarantee sufficient strength. A folded implant may be used, too.

Position of the implant: the lower portion rests on the columella at the site of the columello-lobular junction (CLJ) to form an aesthetic curve, the upper part of the implant fills the forms the tip. The angle of the implant is roughly 35 degree from the vertical line. The shape of the apical implant is determined by a broader upper portion with lateral bulges to form a relief corresponding to the apex of the structure on both sides. This shape fits in where the cutis and

subcutis are not very strong and where there are no scars resulting from previous operations. Sometimes, a narrower and rounded shape has to be chosen as a compromise to give some prominence to the tip of nose as the dominant projection point. The lower part of the implant is narrower with a cut necessary for fixation of the position.

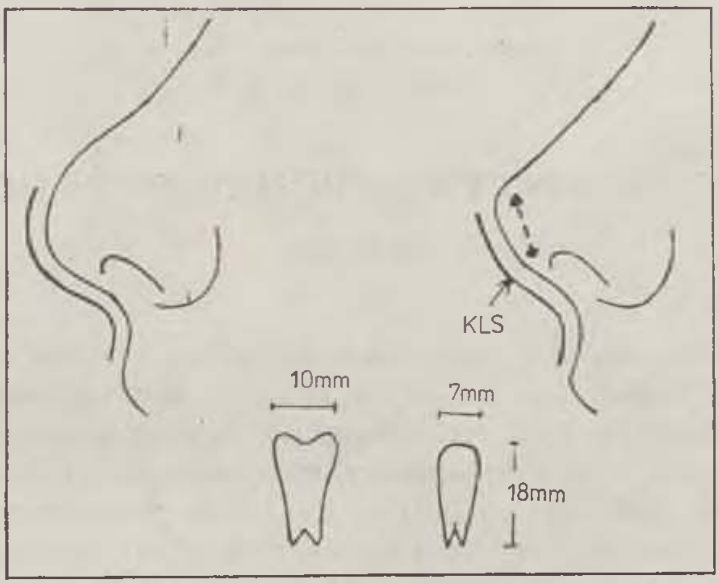

Fig. 1 — Apical implant augmentation

Possible complications:

a) incorrect position of the implant

b) skin reaction caused by pressure from an inadequately work implant, or by too thin tissues (bed insufficiently soft)

c) necrosis caused by excessively large implant

d) subsequent absorption of implant

The rate of complications depends on the surgeon's skills as well as on the quality of tissues. Nevertheless, only perforation poses a serious problem, the other complications are all reparable. J. H.

SUMMARY

The author recommends augmentation of cartilaginous implant as a means for the correction of sunken apex nasi resulting from inadequately performed rhinoplasty.

RESUME

La correction secondaire de la pointe du nez

Fahoun K.

L'auteur recommande la correction de la pointe descendente du nez par l'augmentation de la greffe cartilagineuse ce qui peut corriger l'état après une rhinoplastie mal faite.

ZUSAMMENFASSUNG

Sekundäre Korrektur der Nasenspitze

Fahoun K.

Der Autor empfiehlt die Korrektur der herabfallenden Nasenspitze nach schlecht durchgeführter Rhinoplastik durch eine Vergrösserung des Knorpelimplantates.

RESUMEN

Corrección secundaria de la punta de la nariz

Fahoun K.

Recomienda el autor la corrección de la punta descendida de la nariz, producto de una rinoplástica malograda, por aumentación del implante cartilaginoso.

REFERENCES

1. **Fomon, S. et al.:** Physiological Principles in Rhinoplasty. Arch. Otolaryngol., 53, 256, 1951.

2. **Millard, R. D., jr.:** Symposium on Corrective Rhinoplasty. Vol. 13, St. Louis, 1976, The C. V. Mosby Co.

3. **O'Connor, G. B., McGregor, M. W.:** Secondary Rhinoplasty. Plast. reconstr. Surg., 15, 404, 1955.

4. **Sheen, J. H.:** Secondary Rhinoplasty. Plast. reconstr. Surg., 56, 135, 1975.

5. **Sheen, J. H.:** Esthetic Rhinoplasty. St. Louis, 1978, The C. V. Mosby Co.

Dr. K. Fahoun, Prague Municipal Cosmetic Inst.,
Jungmannova 31, 110 00 Prague, Czechoslovakia

Faculty Hospital, P. J. Šafárik University, Košice (Czechoslovakia)
Department of Plastic and Reconstructive Surgery, Regional
Institute of National Health
Head As. Prof. A. Kipikaša, M. D., CSc.

MARJOLIN'S MALIGNANT ULCERS IN CICATRICAL TISSUE

A. Kipikaša, Š. Guzanin

Marjolin's malignant ulcers are a fairly frequent affection involving the malignant degeneration of skin scars of different origin, most frequently burn scars, anywhere on the human body surface. This malignization of chronic scars was first observed and described in 1828 by Jean-Nicola Marjolin, a surgeon working for baron G. Dupuytren at the Hotel Dieu in Paris, as malignant ulcertaion seeen in areas of chronic scars (1). Later on, sporadic references to such malignant tumours appeared, some of them underrating the hazards of malignancy, no doubt also due to the fact that slow growth and a state of latency lasting almost invariably for years up to decades are characteristic features of such tumours. In the past 15 years or so, attention has again been focused on this type of so far inadequately explored malignant neoplasia (2, 3, 4, 5), mainly because of its high degree of lethality which is likely to be triggered off by surgical intervention.

MATERIAL

In order to verify the rate of occurrence and clinical course of malignant ulceration we examined the clinical notes of 659 patients who had been treated at our department for large hypertrophic scars (275 patients), for skin defects (260 patients), and for flat scars resulting from burns (124 patients).

Among all those patients, malignant ulceration was found in 5 patients in burns scars, in 1 patient's scar resulting from a war wound caused by an explosive bullet, i. e. in a total of 6 patients. The incidence of malignant melanoma in scars and spinocellular carcinoma in chronic radiodermatitis were not included in our study as these will be examined in separate communications.

CASE REPORTS

1. Patient D. A., cl. n. No. 1096, a female born in 1895; as a two-year old girl she fell on a hot stove and suffered burns in the gluteal regions. The defect healed to form a flat, fine, almost hypertrophic scar. 58 years after the injury

a skin ulcer developed in the left gluteal region above the ischium; the ulcer kept growing and being filled with cauliflower-like hypertrophic tissue reminiscent of granulations. Radical surgery in 1955 removed the tumorous tissue, and

Tab. 1. Patients under observation

Condition after skin damage	Number	Spinocellular carcinoma
Hypertrophic burn scars	275	4
Burn defects	260	—
Flat burn scars	124	1
Trophic defects	79	—
Post-injury defects	77	1
X-ray ulcers	42	—
Total	857	6

the resulting defect was covered by means of local plastic surgery. A histological examination revealed the presence of spinocellular carcinoma. Owing to local relapses, the patient had to be reoperated on, using skin grafts to cover the

Tab. 2. Malignant ulceration in scar tissue

Patient	Cause	Born	Age	Anamnesis	Localization	Tumour type
1. D. A.	Burn	1895	2	58	gluteal	Ca spinocel.
2. G. A.	Scald	1914	3	50	popliteal	Ca spinocel.
3. J. K.	Scald	1897	15	45	cubital	Ca spinocel.
4. P. A.	War wound	1920	24	35	crural	Ca spinocel.
5. K. M.	Scald	1930	2	23	femoral	Ca spinocel.
6. T. E.	Scald, acid contact	1955	3 24	21 1	malleolar	Ca spinocel.

defects as they appeared after each new operation. Death occurred 6 months after the first operation owing to extensive metastases and to the generalization of the malignant process.

Fig. 1. Pat. D. A. — malignant ulceration in scar tissue — gluteal region on the left. — Fig. 2. Pat. G. A. — malignant ulceration in popliteal region

2. Patient G. A., cl. n. No. 4857, born 1914, suffered a scald at the age of 3 years. Healing was by spontaneous epithelization whereafter hypertrophic scars developed in the lower extremities, particularly in the left popliteal region. 45 years after the injury, the patient was hospitalized at our department for ulceration in the popliteal area; defects resulting from radical surgery were covered with skin transplants in 1962. Five years later, i. e. 50 years after the injury, a new ulcer developed in the left popliteal region filled with tumorous exulcerated tissue. The ulcer complete with the tumorous tissue was removed in what had to be a total excision, and the defect was covered with a skin graft. Histology identified spinocellular carcinoma. 2 years later, another operation had to be performed for continued ulcerative process in the popiteal region, though no more malignancy was noted, nor was there any evidence of metastases in the regional nodes. From that time on, the patient failed to present for check-up, but there is information that he is no longer alive.

3. Patient J. K., cl. n. No. 2036, born 1897; as a young girl of 15 she suffered a scald in the left forearm and in the cubital region. Healing resulted in a hypertrophic scar in the cubital region where tiny ruptures developed fre-

Fig. 3. Pat. K. M. — malignant ulceration in the femoral region and below costal arch. — Fig. 4. Pat. T. E. — malignant ulceration in the heel

quently. The patient was given conservative treatment dispensed by her family doctor and, in 1952, at a skin department, too. In 1957, as a 60-year old woman, 45 years after injury, she presented at our department for unhealing ulceration in the cubital region on the left extending into the upper third of the forearm. On admission, she was found to have a cauliflower-like exulcerated tumour the size of an adult man's fist, of little mobility against the base but with no bone involvement. The tumour was removed by surgery, the resulting defect was covered with a skin transplant. Histology identified the presence of spinocellular carcinoma. Reoperation was called for owing to local relapse. One year after surgery, metastases were extirpated from the left axilla, and local relapse had to be coped with. In spite of the effort, the malignant process progressed rapidly until, towards the end of 1958, the left arm had to be amputated by exarticulation in the art. humeri. Owing to the malignant process progression in the scapular and clavicular regions, the patient had to be referred to an oncological ward where she died in 1959 at the age of 62.

4. Patient P. A., cl. n. No. 12451, born 1920. As a young man of 24, he suffered an explosive bullet injury during the Dukla Pass military operation,

resulting in a large soft tissue defect throughout the entire calf. Treatment at different health institutes ensued. Years after healing the defect began to give trouble. In spite of all intensive conservative treatment at other health institutes the ulcer in the middle portion of the calf showed no tendency to heal. The patient turned down proposed amputation of the leg, and was consequently admitted at our department for the purpose of radical local surgery. The ulcer complete with the tumorous tissue was excised right down to healthy tissue, and the resulting defect was covered with skin transplants. Histology identified the presence of spinocellular carcinoma. After the defect had healed in the calf, a metastasis the size of a chicken egg was discovered in the right inguinal region. The patient rejected the idea of another operation, and was released from hospital at his own request. 4 weeks later he had to be readmitted for a huge colliquated and infected metastasis in the right inguinal region. Owing to inoperability at that stage, he was referred to an oncological ward where he died 10 months after the first surgical operation.

5. Patient K. M., cl. n. No. 1112, born 1930. As a two-year old girl, she suffered a hot water scald leaving flat or almost hypertrophic scars. On admission in 1955, 23 years after the accident, a hypertrophic scar 3 to 5 cm broad was found extending from the right axilla down to the right knee, the cause of limited movement in the art. coxae. In the lower and medium portions of the right thigh there was a chronic ulcer 15×10 cm in size with hypergranulation tissue at the base and solid protuberating edges. A similar ulcer 8×5 cm in size was found above the right trochanter, and yet another one beneath the costal arch. The ulcers were removed by surgery, and the resulting defects were covered with skin transplants. Bioptic material taken from the thigh was examined and found to contain spinocellular carcinoma. Three more operations for local relapses of the malignant process failed to arrest the rapid progression. 6 months after the first operation the patient was referred to an oncological ward. This year she was invited for a check-up but the letter of invitation was "returned to sender".

6. Patient T. E., cl. n. No. 12 819, born 1955. As a boy of 3 suffered burns in both lower extremities, little toes on both feet had to be amputated for necrosis. Soft, pliable flat scars remained after spontaneous epithelization. In 1979, while serving a prison sentence, he suffered a chemical burn resulting from contact with acid, though that may well have been self-inflicted. He had to undergo three operations for skin defects in the region of the heel. Readmitted at our clinical department in 1980, 21 years after the first accident, and 1 year after the acid burn. On admission, he was found to have a tumour 11×8 cm in size in the region of the heel and the external malleolus of the right foot, oval in shape, pink-reddish, with lumpy surface full of tumorous formations rising 1 to 2 cm above the surroundings, with exulcerations and haemorrhages in places. Enlarged nodes were palpable in both groins. The tumour in the foot was removed by surgery, the defect covered with a skin graft. The enlarged inguinal nodes were both extirpated. Histology identified spinocellular carcinoma in the foot, and metastases in both inguina. Amputation had to be performed in the

upper third of the leg below the knee for reasons of malignant process relapse and general deterioration. Towards the end of 1980, following amputation stump healing and improvement of general condition, the patient was released and recommended to report for regular check-ups at our department.

DISCUSSION

Marjolin's ulcers often go under the name of burn scar carcinoma, though, in fact, the aetiology of the scar does not make much difference.

Histologically speaking, this is a well differentiated spinocellular carcinoma primarily metastasizing through the lymphatic system. Clinical observations so far corroborate the still unelucidated problem of the often extremely long-term developpment and growth of the tumour on the one hand, and its extreme agressivity on the other hand with the development of metastases and local relapses following surgical treatment, both invariably lethal in a short period of time.

Arons et al. (3), having operated on 15 patients, report 11 of them (75 %) to have aggressive local relapses and metastases in regional lymph nodes, and to have died soon. Not even radical excision of the tumour going sufficiently deep into healthy tissue was able to save the victims from lethal end. Similar experience is reported by Bostwick et al. (6). 6 of their patients underwent adequate radical excision with subsequent coverage of the defect with dermo-epidermal grafts (and extirpation of regional lymph nodes) only to develop early local relapses with metastases into regional lymph nodes within 6 months of the first surgery. All of their patients died within 3 to 11 months after surgery with generalized metastases in the chest, bones and brain.

Almost invariably, surgical operation is the critical breaking point where what has been a strikingly protracted course suddenly takes a turn for a rapidly approaching lethal end.

Treves and Pack (1) in what we consider a classical treatment of the problem believe the avascular tissue of the scar acts as a protective barrier against metastasizing. Their view is shared by Futrell et al. (2) who see the scar as an immunologically privileged site. Encircling and oppressing lymph vessels, the scar acts as a barrier preventing tumour cells in malignant ulceration which represent a specific antigen from making their way into the regional lymph nodes. In this way the lymphatic system cannot react to the specific antigen of the tumour, as a result of which the primary tumour has all the conditions for growth un-impeded by the usual immunological mechanisms. This is also how the authors account for the rapid post-operative expansion of the tumour where the scar, representing an immunological barrier, is broken open thus allowing tumour cells to pass along the lymph nodes into regional nodes.

Bostwick et al. (6) describe the above theory as interesting albeit it as yet uncorroborated. Much in the same vein, Castillo and Goldschmidth (4) believe the scar enveloping malignant ulceration from all sides to act upon the body's immunological reaction as a sort of barrier. Delon et al. (5) found two of their

patients with malignant ulceration to have a low level of T-cells; this made them suspect that malignant ulcerations were most likely the develop in patients with impaired cellular immunity.

There is little to be said about the clinical picture of malignant ulcers as these develop in sites of scars resulting from burns, scalds, exposure to radiation, mechanical injuries, especially war wounds, after a lapse of time running into decades. The most frequently affected parts are the extremities and those portions of scars which are exposed to chronic traumatization, particularly mechanical traumatization. The growth and development of ulcerations is slow and inconspicuous. For that reason, the point of degeneration of a benign chronic ulcer into a malignant tumour is difficult to discern. Patients present at our department often with diagnoses of chronic trophic ulceration, or pseudo-epitheliomatous hyperplasia, sometimes — as a result of unskilled but also skilled intervention — already with metastases in the regional lymph nodes.

The primary therapeutical principle is that all chronic ulcers arising from scars ought to be regarded as malignancies until histological examination confirms the opposite. This principle should also govern our practical procedure. In practical terms this means that we do our best to avoid any mechanical intervention which might cause bleeding in the defect. Mechanical irritation of the defect also means running the risk of washing tumour celles out into the blood and lymph vessels. Surgical intervention is resorted to only after local management of the infection (so long as this is at all possible) and after the patient's general preparation for the process.

If our own experience is anything to go by, the principles of therapy could be summed up as follows: 1. Malignant ulcers in the extremities ought to be operated on in avascular surroundings. 2. Radical excision (going deep and wide) should be performed with the aid of electric cautery as this may prevent tumour cells being washed out into the lymphatic and blood vascular beds. 3. If facilities for cryosurgery are available the whole focus complete with the borderline healthy tissue should be frozen. 4. Following radical extirpation and refreshment with cryocautery and prior to covering with full-thickness skin grafts the defect ought to be washed with physiological saline solution to remove any possible tumour cells retained in the defect. 5. The surgeon will make no mistake if he decides in favour of packs or lavage of the defect following the surgical extirpation of the tumour for a period of 24 to 48 hours prior to the application of the dermo-epidermal graft. 6. This is then followed by the application of the skin transplant. 7. Regional lymph nodes are removed either simultaneously with the malignant ulcer extirpation, or else 2 to 4 weeks after extirpation.

For Marjolin's ulcer prevention the following principles ought to be observed: 1. As a matter of principle skin defects should never be allowed to epithelize spontaneously, instead, they should be covered with a high-quality skin transplant as a primary or secondary measure. 2. In cases of large defects where for technical reasons it is impossible to cover the whole area with skin transplants (burns), preferential treatment is given to the most exposed sites. 3. Skin contractures, particularly those with a tendency to repeated exulceration over

a period of a few years, as well as scars exposed to systematic mechanical irritation, ought to be removed in good time. 4. As part of follow-up care for patients with World War 2 wounds we take note of all scar tissue, and give those patients preferential surgical treatment before the ulcers have time to degenerate into malignant tumours.

Bostwick et al. (6) call on all researchers to examine the possibilities of increasing the body's immunological response in patients with Marjolin's ulcers even before surgical excision in order to increase the chances of longer-term survival of those unfortunate patients. However, intensive research is going on in this field in relation to all malignant neoplasms. So far, however, we have little reason for optimism in view of the experience of the treatment of malignant melanomas.

Even though prognosis in malignant ulcerations is almost hopeless, we believe that given a correct and timely therapeutical procedure, more improvement can be achieved in post-operative results although, for the time being, it is prevention that requires most of our interest.

CONCLUSION

Taking into account the aetiological conditions listed in the discussion section as well as the fate of patients suffering from Marjolin's malignant ulcers, our conclusions are as follows:

Immunological reaction is one of the biological adaptation processes of the organism whereby the body responds to the antigen in action by producing antibodies. Malignant ulcers in the scar, the cells of which represent an antigen in the organism, are isolated by the scar to such an extent that their tissues and, consequently, their cells, too, as the specific antigen, have no chance to come into contact with blood or lymph circulation. The lymphatic system, i. e. tissues responsible for the production of antibodies, is thus deprived of the opportunity to register the presence of a specific antigen in the body — cells of malignant ulceration — and, consequently, also of the opportunity to produce specific antibodies. Once, however, under specific conditions, the cells of malignant ulceration do make their way into circulation and, through it, into contact with the lymphatic system, they "catch" the body unprepared for fight with the new antigen since no antibodies have yet been developed against malignant ulceration. The triggering mechanism which allows tumour cells to break the isolation in the scar and to invade the whole of the body may be exactly a surgical or other mechanical intervention in the malignant ulcer region, but also the spontaneous growth of the tumour itself after it has overcome the isolating barrier of the scar. In a massive invasion of the tumour cells the organism, unprepared for the attack, is destroyed by the unimpeded growth of the tumour at its original site as well as by disseminated metastases before is can respond by starting to produce antibodies. This is how our team account for the rapid progression after surgery culminating almost invariably in death in a short period of time. Consequently, malignant ulceration has to be des-

troyed before it has time to destroy the organism as outlined in the above principles. Since it is practically imposible to tell exactly when a benign ulcer starts degenerating into malignant ulceration, prevention is obviously the only way. This in practical terms means organizing follow-up care for the endangered part of the population, i. e. all large scars resulting from burns and other major traumas, inviting all the patients involved for regular check-ups and, in cases of suspicion, removing all foci suspected of possible malignant degeneration as an act of prevention in line with the generally valid principles of plastic surgery. J. H.

SUMMARY

Proceeding from literary data and their own experience of 6 cases of Marjolin's ulcers the authors warn of the dangers posed by burn scar carcinoma consisting in inconspicuous prodromal period, lasting as long as decades, and rapid postoperative malignant degeneration resulting in early death due to local relapses and generalized metastasizing.

The authors contemplate the causes of the virulent aggressivity of malignant ulceration occurring as a result of surgical operation or some other mechanical irritation. In their view, though not yet confirmed by laboratory test results, the cells of malignant ulceration as a specific antigen are isolated during their growth in the scar from organs responsible for immunological protection of the organism. Once invaded by a mass of tumour cells at the time of surgical operation or some other mechanical intervention, the organism with no stock of antibodies against the cancer cells as a specific antigen is bound to succumb as a result of local relapses and metastatic dissemination.

Provided certain therapeutical principles listed by the authors are observed there may be hope for partial improvement; the bulk of all medical and surgical care, however, is in preventive measures.

RESUME

Les ulcérations malignes de Marjoline dans les cicatrices

Kipikaša A., Guzanin Š.

Sur la base des connaissances litéraires et de leurs propres expériences obtenues par le traitement de 6 malades, les auteurs avertissent le danger des ulcérations malignes de Marjoline, danger qui consiste à une longue maladie latente. Celle-ci peut bien durer une dizaine d'années suivie d'une rapide conversion maligne post-opératoire qui est terminée par la mort en consequence des récidives locales et des métastases généralisées, dans quelques mois.

Les auteurs cherchent les raisons de la virulence progressive des ulcérations malignes qui est conséquence d'une intervention ou d'une excitation méchanique des ulcères. Les auteurs nous offrent une explication qui n'est pas attesté par des examens laboratoires.

Les cellules d'ulcération maligne, en grandissant dans la cicatrice, sont isolées des organes responsables de l'immunité de l'organisme. Au moment de l'intervention, l'or-

ganisme qui n'est pas armé contre les cellules tumureuses succombe à la suite des récidives locales et des métastases disséminées.

En se conformant au xprincipes du traitement recommandé par les auteurs, il existe une possibilité d'amélioration partiale des résultats. Les médecins doivent concentrer leurs efforts surtout à prévenir la maladie.

ZUSAMMENFASSUNG

Maligne Marjolinsche Ulzerationen in den Narben

Kipikaša A., Guzanin Š.

Aufgrund einer Literaturübersicht und anhand eigener Erfahrungen, die mit der Behandlung von 6 Fällen maligner Marjolinscher Ulzerationen gewonnen wurden, dokumentieren die Autoren die Gefahr dieser Ulzerationen, die in einem unauffälligen, bis Jahrzehnte lang dauernden Vorkrankheitsbild und einem schnellen bösartigen Umsturz nach der Operation beruht, der infolge lokaler Rezidiven und generalisierter Metastasen binner einiger Monate lethal endet.

Die Autoren analysieren ferner die Ursache der hohen Virulenz der malignen Ulzerationen, die nach der Operation oder als Folge einer anderen mechanischen Reizung auftritt. Die Erklärung dafür, die durch Laboratoriumsuntersuchungen nicht bestätigt wurde, sehen sie darin, dass die Zellen der malignen Ulzeration als Antigen, solange sie in der Narbe wachsen, von den für den immunologischen Schutz des Organismus verantwortlichen Organen isoliert sind. Bei massiver Überschwemmung mit Tumorzellen während der Operation oder eines anderen mechanischen Eingriffes, als der Organismus noch keine Antikörper gegen Tumorzellen als spezifisches Antigen besitzt, erliegt er den Folgen der lokalen Rezidiven und an Folgen der Dissemination der Metastasen.

Bei der Einhaltung der von den Autoren festgesetzten Therapieregeln besteht eine gewisse Hoffnung auf eine partielle Verbesserung der Ergebnisse, der Schwerpunkt des Intresses der Ärzte muss jedoch bis auf weiteres in der Prophylaxe liegen.

RESUMEN

Ulceraciones malignas Marjolin en las cicatrices

Kipikaša A., Guzanin Š.

Partiendo de un resumen de la literatura al respecto así como sus propias experiencias ad uiridas durante el tratamiento de 6 casos de ulceraciones malignas Marjolin, los autores señalan el peligro resultante de dichas ulceraciones que consiste en un discreto estadio de predisposición a la enfermedad, de hasta decenas de años de duración, y un rápido cambio maligno después de la operación que, en consecuencia de recidivas locales y metástasis generalizadas termina letalmente al cabo de unos meses.

A continuación, los autores analizan las causas de la alta virulencia propia de las ulceraciones malignas que sucede después de la operación o en consecuencia de otras irritaciones mecánicas de la ulceración.

Los autores suponen que la aclaración, que todavía no se ha probado laboratoriamente, consiste en que las células de la ulceración maligna, como antígeno, mientras crecen en la cicatriz están aisladas de los órganos responsables de la protección imunológica del organismo. Durante la operación u otra irritación mecánica, ante una afluencia de células tumorosas, el organismo que no se ha creado ningunos antídotos contra

las células de tumor como antígeno específico, sucumbe en consecuencia de recidivas locales y diseminación de la metástasis.

Al observar los principios terapéuticos definidos por los autores, hay cierta esperanza de un mejoramiento parcial de los resultados, siendo, sin embargo, hasta ahora de mayor importancia la prevención.

REFERENCES

1. **Treves, N., Pack, G. T.**: The Development of Cancer in Burn Scar. Analysis and Report of 34 Cases. Surg. Gynec. Obstet., 51: 749, 1930.
2. **Futrell, J. W., Myers, G. H.**: The Burn Scar as an Immunologically Privileged Site. Surg. Forum, 23: 129, 1972.
3. **Arons, M. S. et al.**: Scar Tissue Carcinoma. I. Clinical study with special reference to burn scar carcinoma. Ann. Surg., 163: 445, 1966.
4. **Castillo, J. L., Goldschmidth, M. S.**: Burn Malignancy in a Possible Depressed Immunologic Setting. Surg. Forum, 19: 511, 1968.
5. **Dellon, A. L. et al.**: The Immunobiology of Skin Cancer. Plast. reconstr. Surg., 55: 341, 1975.
6. **Bostwick, J., Pendergrast, J., Vasconez, L.**: Marjolin's Ulcer: an Immunologically Privileged Tumour? Plast. reconstr. Surg., 57: 66, 1976.

As. Prof. A. Kipikaša, M. D., CSc., Olivova 7, 040 00 Košice, Czechoslovakia

Bulgarian Medical Academy, Medical Faculty, Varna (Bulgaria)
Department of Surgery
Head Prof. A. Stoichev, M. D.

FREE SKIN GRAFT IN THE TREATMENT OF PENILE SKIN DEFECTS

K. Troshev

Penile skin defects are rather a rare occurrence, and problems involved in their treatment arise from the anatomical and functional specifities of the male genitalia. There are but sporadic descriptions of such cases in general surgical literature, all of them solely in plastic surgery journals. There are obviously some specificities of the surgical treatment involved, too. Detailed knowledge of the relevant surgical techniques is essential if complications are to be avoided. The following is a summing up of literary data over the past ten years, and of the author's own experience of this field of plastic surgery.

Injuries of male external genitalia involving genital skin avulsion are not quite so rare as we might think. Yet there is a scarcity of literary data on the number of such injuries. The extent of penile injury depends on the mobility of the male sex organs, particularly the skin which is well fixed to the pubis and to the perineum. The skin may become detached from the penile fascia and from the tunica dartos on the scrotum. A pedicled scrotal skin flap remains usually in the direction of the acting force.

Another type of injury may involve the skin being caught at the edge of a moving hard object or a stationary object if the body itself moves at great speed, i. e. in fall.

Rarer cases involve intentional self-inflicted injuries in attempts to cut off the penis which is not in erection; most of these end up in the skin cover being cut with the penile body and head remaining intact.

Penile skin and subcutis are removed by surgical means in the treatment of elephantiasis regardless of the aetiology (8). Partial defects may result from ritual circumcision of the prepuce.

The clinical picture is characterized by burning pain of medium intensity at the time of the injury, a condition manageable with the aid of analgetics. Patients invariably report vague discomfort at the site of injury. Provided there is no other injury the accident may pass without shock. However, shock may arrive if penile vessels are affected or in some other associated injury, which is a characteristic feature of occupational accidents.

The extent of the skin defect depends on the mechanism of injury. The most serious injuries are caused by machines. A stripe of skin only 5 mm to 1 cm

broad remains in an uncircumcised penis. Injuries caused by other mechanisms usually result in lesser skin loss. In surgical operations for elephantiasis all penile skin has to be ablated. Ritual circumcision, if poorly planned, may result in circular defects and, later on, in cicatrical deformation of the penis.

Fig. 1.

Emergency measure to be effected immediately include arresting haemorrhage and the application of sterile dressing. The aim of systemic treatment is to manage shock and to prevent infection. This is where infusion of glucose and electrolytic solutions, plasma and blood are in place; so is the use of analgetics, broad-spectrum antibiotics, antitetanus and anti-gangrenous sera. The patient should then be transported to the nearest plastic surgery ward without delay. Avulsed or cut off skin, provided it has been found, should be transported along with the patient, wrapped in moist sterile mull. Before it is prepared for use, it should be preserved in a refrigerator at +4 ^{0}C steeped in a solution of broad-spectrum antibiotics.

The penis ought to be definitively covered with skin as soon as possible within the first few hours of injury, within 24 hours at the latest. General narcosis, depilation, and correct desinfection of the wound and the skin of the whole damaged area are essential.

The use of skin flaps from the abdomen or thighs is, in my opinion, to be dispensed with so long as the penis alone is to be covered, as there are a number of inadequacies involved such as deformation of the penis by a thick layer of subcutaneous fat and diminished skin mobility, or the need for several surgical operations.

In view of the above listed facts and in accordance with literary data [1, 4, 5, 6, 7, 8] we regard the use of a free dermal graft as a method of choice. The damaged skin is usually torn thus making its use precarious because its surface area is invariably inadequate following pre-treatment and removal of devitalized

parts. The graft 0.35—0.40 mm thick is taken from the underbelly (9) or from the anterior surface of the thigh. An indwelling catheter is introduced into the urinary bladder (2) and used as a splint for the penis maximally stretched. The graft is fixed in this position. The graft edges enveloping the root of the penis and the corona glandis as well as the edges of the wound are excised in a W-fashion. The edges of the graft running along the penile body are prepared likewise. The planned longitudinal scar runs alons the lower surface of the penis or a little obliquely (3). The undulating line of the suture eliminates the possibility of cicatrical narrowing or other functional consequences. The transplant is pressed to the surface of the wound on the penile body using a gauze bolus soaked in antibiotic ointment. Correct dressing and immobilization are essential for a period of 8 to 10 days. If necessary, anti-erection drugs are administered in the post-operative period. Erection may result from irritation of the glans or in excessive compression caused by the dressing and involving vascular supply disorders. Antibiotics are applied to manage any possible infection. The dressing has to be frequently checked for the condition of the glans and the graft to make sure no haematoma can develop. Analgetics are given throughout.

After the graft has taken and the catheter and bandage have been removed, we continue taking care of the graft where restoration of the functional capacity and adaptation to the anatomical and physiological characteristics are essential. The transplanted skin is kept elastic nd moist with the aid of oily cream at least twice daily. The authors has had years of experience treating these and other scars withHeparoid Spofa. It can well be used with success after this kind of surgery as well.

It is advisable to refrain from sexual intercourse for a period of 3 to 4 weeks, although it is obviously impossible to give any hard and fast rules here. Erection and sexual intercourse ought to be regulated according to the condition of the graft, its functional capacities and the patient's psychic preparedness. The first attempts at coitus ought to be as sparing as possible as regards the mechanism, intensity and the female partner's reactions if complications are to be avoided — local (haematoma, injury, dehiscence) or general sexuological ones.

Our experience is based on the results of treatment accorded to 7 patients with complete loss of penile skin. Five of the men had sustained machine injury (71.42 %), one was a case of elephantiasis of the genitalia, and the remaining one was the victim of his partner's attempted amputation of the penis. The patients age ranged from 24 to 66 years, most of them (57.1 %) belonging in the 20—30 year group.

All of them were successfully operated on within the first 24 hours. One had a flap plastic operation from the scrotum performed in three stages. In the rest, coverage with free skin grafts proved to be without any major complications. The post-operative period was uneventful with good functional and aesthetic results, except in one patient with straight linear suture around the glans where correction of contracture was called for (1). Four of the men experienced erection within 10 to 20 days of the removal of stitches and dressing with initial feelings of mild pain and contraction. Later on, however, the complaints

abated. The first erections were accompanied by apprehension, but these feelings, too, subsequently passed. Four of the men had their first sexual intercourse 3 weeks after being released from hospital. This proved to be a smooth affair as did all subsequent regular sexual intercourse. None of them complained of diminished sensitivity. Three of the men continue to rub the transplant with Heparoid Spofa twice daily for a total of six weeks, thus attaining normal elasticity.

CONCLUSIONS

1. The use of a free dermal transplant is a method of choice for covering penile skin defects caused by injury or surgical operation.
2. A surgical operation is essential in the very first few hours, within 24 hours at the latest.
3. To ensure good therapeutical results the patient ought to be operated on and treated at a plastic surgery ward. J. H.

SUMMARY

The author sums up literary data and his own experience of treatment for penile skin defects, analyzing the therapeutical results in his seven patients and explaining the strategy of treatment, preparation, operative and post-operative care. The skin defects should be covered with free dermal autografts sutured to the edges of the wound in the W-plasty fashion. All therapy should take place at departments of plastic surgery.

RESUME

La greffe cutanée libre dans le traitement des défauts de la peau du pénis

Trochev K.

L'auteur assemble les donnés litéraires ainsi que ses expériences pendant le traitement des défauts cutanés du corps du pénis. Il analyse les résultats du traitement de ses 7 malades. Il explique plan du traitement, préparation, soins avant et après l'opération.

Il recommande recouvrir les surfaces des lésions par une autogreffe cutanée libre. Dans ce cas, le greffon est suturé aux lèvres de la plaie d'après la méthode de la plastie en W.

Il est nécessaire que le traitement soit réalisé à la clinique de la chirurgie plastique.

ZUSAMMENFASSUNG

Freies Hauttransplantat in der Behandlung der ePnishautdefekte

Troschew K.

Der Autor behandelt Angaben aus der Literatur und seine Erfahrungen bei der Behandlung der Hautdefekte des Peniskörpers. Er analysiert die Behandlungsergebnisse von sieben seiner Patienten. Er beschreibt den Therapieplan, die Vorbereitung und die operative und postoperative Betreuung. Er emfiehlt die Defekte mit einem freien Dermatomhautautotransplantat zu decken, das zu den Wundenrändern nach dem Verfahren der W-Plastik genäht wird. iDe Behandlung muss in der Abteilung der plastischen Chirurgie durchgeführt werden.

RESUMEN

Transplante de piel libre en el tratamiento de los defectos dérmicos de los penes

Troshev K.

El autor resume datos de la literatura así como sus propias experiencias adquiridas en el tratamiento de los defectos dérmicos del cuerpo del pene. Analiza los resultados logrados durante el tratamiento de sus siete pacientes. Explica el plan de la terapia, la preparación, la asistencia operatoria y postoperatoria. Recomienda cubrir los defectos con un autotransplante dérmico libre que se sujeta cíon costura a los bordes de la cortadura a modo de la plástica W. El tratamiento debe tener lugar en la sección de cirugía plástica.

REFERENCES

1. **Whorton, C. E., McCraw, J. B., Devine, C. Jr., Devine, P. C.**: Secondary Reconstruction of the Genital Area. Urol. Clin. North Am., 4, 1: 133, 1977.

2. **Jones, H. W., Kahn, R. A.**: Surgical Treatment of Elephantiasis of the Male Genitalia. Plast. reconstr. Surg., 46, 1: 8, 1970.

3. **Khanna, N. N.**: Surgical Treatment of Elephantiasis of Male Genitalia. Plast. reconstr. Surg., 46, 5: 481, 1970.

4. **Lapidus, S. M., Graham, W. P.**: Complete Avulsion of the Genital Skin. Pann. Med., 76, 8: 38, 1973.

5. **Levitt, S. B., Smith, R. B., Ship, A. G.**: Iatrogenic Microphallus Secondary to Circumcision. Urology, 8, 5: 472, 1976.

6. **Marini, F., Perego, S.**: Lo scalpo dei genitali maschili. A proposito di un caso. Urologia (Treviso), 41, 2: 210, 1974.

7. **Taguchi, H.**: More than 10 Years of Experience with Reconstructed Scrotums. J. Urol. (Balt), 116, 4: 469, 1976.

8. **Vaught, S. K., Litvak, A. S., McRoberts, J. W.**: Surgical Management of Scrotal and Penile Lymphadema. J. Urol. (Balt)., 113, 2: 201, 1975.

9. **Wild, R. M., Devine, C. J., Horton, C. E.**: Dermal Graft Repair of Payronie's Disease: Surgery of 50 Patients. J. Urol., 121, 1: 47, 1979.

Dr. K. Troshev, Khristo Kabachiev St. 44, 9000 Varna, Bulgaria

Burn Center of the Clinic of Plastic Surgery, University Hospital, Prague (Czechoslovakia)
Head Prof. M. Fára, M. D., DSc.

CONTEMPORARY ORGANIZATION OF BURN CARE

R. Königová

An extensive burn is a catastrophic injury — catastrophic in the overwhelming insult to the patient, catastrophic in its psychological aspects and suffering of the family involved (Artz, 1979).

It represents an immense burden for the society, because the cost of the burn treatment is much higher than in any other speciality (Tab. 1). The question who should treat the burn injury was decided by a special committee of the ISBI in 1974, which established that the concentration of critically ill patients within a given area allows centralization of facilities, coordination of medical effort and thereby improved patient care. As the burns are concerned, there should be in every major population area a burn center at which specialized care is available. Although the per diem cost in the burn center may be greater — the equipping and staffing being expensive — these specialized arrangements afford the most economic and efficient method of taking care of severe burns.

The exact type of burn facility desirable for a specific region depends upon the situation of that region. It should be planned by members of the team that is to staff it. It should be attached to a general hospital to ensure cooperation with the other specialities. New construction is recommended over reconstruction of an existing facility. It should be larger than required by the immediate need and be of modular construction with movable walls to adjust it quickly to disaster situation.

The equipment and staffing should correspond with the up-to-date requirements:

1. beds with monitoring equipment for insufficiency of the vital functions (ventilators, defibrilator, haemoperfusion aparatus)
2. beds for longlasting intensive care — including an air-fluidized bed isolated in boxing system
3. beds for reconstructive surgery and physiotherapy
4. operating facilities
5. dressing stations areas, tanking with possibility of complex hydrotherapy
6. admission and out-patient clinic area
7. emergency laboratories (biochemistry, bacteriology)
8. skin bank, immunological laboratory
9. conference and educational rooms

Tab. 1. Cost of severe burn treatment

Example: 39-year old man, 2nd – 3rd degree burn, 70% explosion of petrol in making fire in stove

Total Kčs 110,121.–
+ £ 220.–

Solutions: Kčs 23,000		= 43,000 Kčs	
Hartmann sol.	10000 ml	whole blood	6500 ml
sacch. sol.	985000 ml	packed erythr.	4500 ml
aminosolutions	38000 ml	plasma	17250 ml
fat emulsions	28000 ml	albumin	1100 ml
		gamma-globulin	530 amp.
Hydrocortison Roussel		3200 g = 9,600 Kčs	
Heparin		24000 u. × 50	
Vivasorb		10 packets	
Vitamins A, B, C, E, D, B_{12}		daily to schedule, in infusions or i. m.	
Superanabolon			
Calcium gluconicum		160 amp.	
Cardilan		16 amp.	
Digoxin		10 amp.	
Oxyphyllin		36 amp.	
Anacid		4 pack.	
Reparil		12 amp.	
Antibiotics: = 12,618 Kčs		+ £ 220	
Septrin		30 ml for 13 days	
Colimycin		4 g for 9 days	
Ticarcilin		224 g for 19 days	
Anaesthetics: = 13,094 Kčs			
Ketamine		5370 mg	
Thalamonal		20 ml	
Droperidol		115 mg	
Fentanyl		28 mg	
Faustan		250 mg	
Diazepam		250 mg	
Atropin		11.5 mg	
Dolsin		500 mg	

Numerous auxiliary spaces are desirable.

Finally, the committee emphasized, that the single most important factor in operation of a burn center is the organization of a highly trained, dedicated and tireless team. An intensive in — service educational program for all members of the team is essential to prevent the stress of unsureness.

27 years ago, the surgical approach in burns — started by professor Burian — was a great progress. Till then the treatment was utterly in the dermatological sphere.

Contemporary development and knowledge prove the multidisciplinary approach. Above all, the most important aspect in the development in any type

of burn facility is the burn-surgeon coordinating all the other specialists concerned (Tab. 2).

All the international congresses during the last 15 years have been encouraging the multidisciplinary team approach and the national burn societies have been formed, where associate the specialists of various disciplines helping to resolve the burn problems. The principle aims of these national societies is

Scheme 1. Burns team co-operation structure

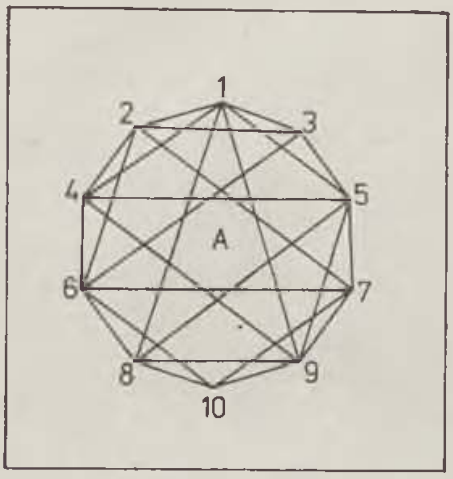

1 surgeon
2 anaesthesiologist
3 medical specialist
4 psychologist
5 biochemist
A burned patiet
6 epidemiologist
7 bacteriologist
8 neurologist
9 ophthalmologist
10 rehabilitation specialist

to work out an organization of burn care ensuring complex and continual treatment for all severe burns in specialized centers. In 1970 A. B. Wallace stressed the significance of international cooperation to resolve many challenging problems, not only medical ones. He said "the peoples of the world should aknowledge that all mankind is one and societies like our own — ISBI — could by example lead the way in application of the concept of international cooperation".

Tab. 2. Increased ethical requirements in severe burns care are in connection with

1. specificity of the mechanism of injury and burn shock
2. prognosis-related decision making on therapeutical strategy
3. long-term treatment depression in patients
   depression in medical and nursing staff
4. surgeon-coordinated interdisciplinary team work
5. strictly individual approach to each patient
6. differences of approach — in childhood
   — in adulthood
   — in old age

According to our long experience we find vitally important, that the same staff treats the severe burns from the shock period till the convalescence, which is from the psychological point of view essential in preventing suicides in the disfigured patients who require complicated and repeated reconstructive procedures (Tab. 3).

SUMMARY

Concentration of critically ill patients within a given area allows centralization of facilities, coordination of medical effort and thereby improved patient care. As the burns are concerned, there should be in every major area a burn center at which specialized care is available. It should be larger than required by immediate need. The personnel staffing the center should have specialists in all disciplines readily available for consultation. Adequate nursing is the key to successful work. The team approach must be coordinated by those with broadest perspective, highly skilled and dedicated to burn care, throughout the longlasting treatment. According to our experience the same staff must treat the severely burned patient from the shock period to the convalescence, which is from the psychological point of view essentiel in preventing suicides in the disfigured patients.

RESUME

L'organisation contemporaire des soins médicaux des brûlés

Königová R.

La concentration des malades en état critique au centre spécialisé permet d'agglomérer dans une certaine région plusieurs établissements médicaux, coordonner les efforts des médecins. A cette manière, on peut augmenter le niveau des soins des malades brûlés. L'auteur recommande installer un centre spécialisé des soins des brûlés dans toutes les régions assez étendues. Il faudrait que la capacité de ce centre soit un peu plus grande que la nécessité instantanée exige. Le personnel du centre devrait avoir toujours la possibilité de consulter les spécialistes de tous les domaines. Il faut une équipe entraînée, des infirmières dévouées, rompues aux soins incessants et délicats que réclament les brûlés. Cette immense organisation exige des services hospitaliers hautement spécialisés, coordonnés par les spécialistes possédants une vaste expérience.

D'après l'expérience de l'auteur il est indispensable, du point de vue psychologique, que les soins du malade brûlé soient procurés par une équipe invariable pendant tout le longtemps du traitement, c'est à dire depuis l'état initial du choc jusqu'à la convalescence. La grande importance de cela consiste en prévention des tentatives de suicide chez les malades gravement défigurés.

ZUSAMMENFASSUNG

Gegenwärtige Organisation der Betreuung von Verbrennungen

Königová R.

Die Konzentrierung kritisch kranker Patienten macht es auf dem gegebenen Gebiet möglich, die Behandlungseinrichtungen zu zentralisieren, die Anstrengungen des medizinischen Personals zu koordinieren und somit das Niveau der Betreuung des Patienten zu erhöhen. Deshalb sollte jedes grössere Gebiet auch seine eigene Zentralstelle für Verbrennungen haben, die fähig wäre fachliche Betreuung zu leisten. Sie sollte grösser sein, als der augenblickliche Bedarf erfordert. Das medizinische Personal des Zentrums sollte jederzeit die Möglichkeit haben, Spezialisten aller Fächer zu konsultieren. Den Schlüssel zur erfolgreichen Arbeit bildet das entsprechende Niveau der Betreuungspflege. Die Arbeit des Gesundheitsteams müssen während der ganzen langen Behandlungs-

zeit hochqualifizierte und der Sache hingegebene Spezialisten mit breitem Umsichtsvermögen koordinieren. Den verbrannten Patienten muss nach den Erfahrungen der Autorin vom Zeitpunkt des Schocks bis zur Rekonvaleszenz eine und dieselbe Gruppe von Gesundheitsarbeitern betreuen, was vom psychologischen Gesichtspunkt notwendig ist, wenn Selbstmordversuche bei entstellten Patienten vermieden werden sollen.

RESUMEN

Organización actual de la asistencia a los quemados

Königová R.

La concentración de los pacientes en estado crítico posibilita centralizar los distintos centros de tratamiento en una zona dada, coordinar los esfuerzos del personal sanitario mejorando así el nivel de la asistencia a los pacientes. Por consiguiente, cada zona de mayor importancia debería contar con su propio centro de tratamiento de quemaduras capaz de prestar una asistencia especializada y de un tamaño superior a la necesidad momentánea, el respectivo personal sanitario debe tener la posibilidad de consultar, en cualquier momento necesario, a los médicos especialistas de todas las ramas. El adecuado nivel de asistencia requerida es el punto cardinal de todo tratamiento exitoso. El trabajo del equipo sanitario debe ser coordinado, durante todo el tratamiento, por especialistas altamente calificados, apegados a la causa y con amplios conocimientos generales. Conforme a la adquirida experiencia de la autora, debe atender al paciente quemado, desde el momento del choque hasta el período de convalescencia, el mismo equipo de personal sanitario. Es una condición sicológica necesaria para prevenir que los pacientes mutilados intenten cometer suicidios.

REFERENCES

1. **Artz, C. P., Moncrief, J. A., Pruitt, B. A.**: Burns-A Team Approach W. B. Sounders Company, Philadelphia, 1979.
2. **Feller, I., Crane, K. H.**: Planning and Designing a Burn Care Facility. Ann Arbor, Michigan, Institute for Burn Medicine 1971.
3. **Holubec, K., Karfík, V.**: Chirurgické léčení popálenin (in Czech) Státní zdravotnické nakladatelství, Praha, 1956.
4. **Skoog, T.**: The Surgical Treatment of Burns. Almquist and Wiksells, Stockholm, 1963.

Dr. R. Königová, Veleslavínova 10, 110 00 Praha 1, Czechoslovakia

Semmelweis Medical University School, Budapest (Hungary)
Central Hospital, I. Neurological Clinic

STUDIES ON METABOLIC DISTURBANCES IN BURN SHOCK

K. Szabó, I. Tulok, J. Novák

The lack of substrates and disturbances in the metabolism following the thermal injury is a wellknown fact (1, 4). However there has been little or no knowledge of the possibilities to inhibit the consequences of the catabolism already during the shock period.

In present paper metabolic changes observed during shock in patients healthy before injury have been summarised. They were treated according to one of the customed fluid replacement formulas (2, 5, 6) with good clinical results.

METHODS

We studied alterations of glycolysis (Pyruvate, Lactate Test Combinations UV Method, Boehringer) and of some intermediary metabolits of Krebs' cycle (3) in venous blood samples of patients with burn injuries (Fig. 1). Simultaneously ketone bodies (8) and serum ammonia level (7) changes were determined. Moreover high energy adenosine phosphate content of erytrocytes has been studied (ATP, ADP/AMP Test Combinations UV Method, Boehringer). Calculation of the various metabolit values were expressed in SI, the adenosine phosphate values referred to hemoglobin SI units. Concentration ratio changes of several metabolits have been also examined.

We have given the measured values in the per cent of normal controls and have been represented on normal log scales so that normal controls approximate a straight line. Deviations refer to severity degree of the disturbance.

Elevated lactate/pyruvate ratio shows increase of anaerobe glycolysis, as well as of sympathoadrenergic activity. Decrease of citrate/pyruvate and citrate/total ketone bodies ratio suggest inhibited entry of pyruvate and acetoacetate in tricarboxylic acid cycle. Reduced ATP/ADP ratio indicates both, the increase of ATP utilization and the insufficient ATP synthesis. AMP increase is an indirect sign of raised adenylcyclase activity.

RESULTS. COMMENTS

Fig. 2 shows data of patients with burns of small extent requiring, according to clinical practice, no fluid replacement for shock treatment. It may be seen that besides normal laboratory findings severe disturbances of intermediary metabolism are present.

During the first few days after burn increase of lactate and ketone bodies, as well as decrease of total adenosine phosphate and ATP can be observed. Hypoglykemia and low pyruvate and citrate concentrations in one patient suggests starvation. In the other patient utilization of ketone bodies is insufficient

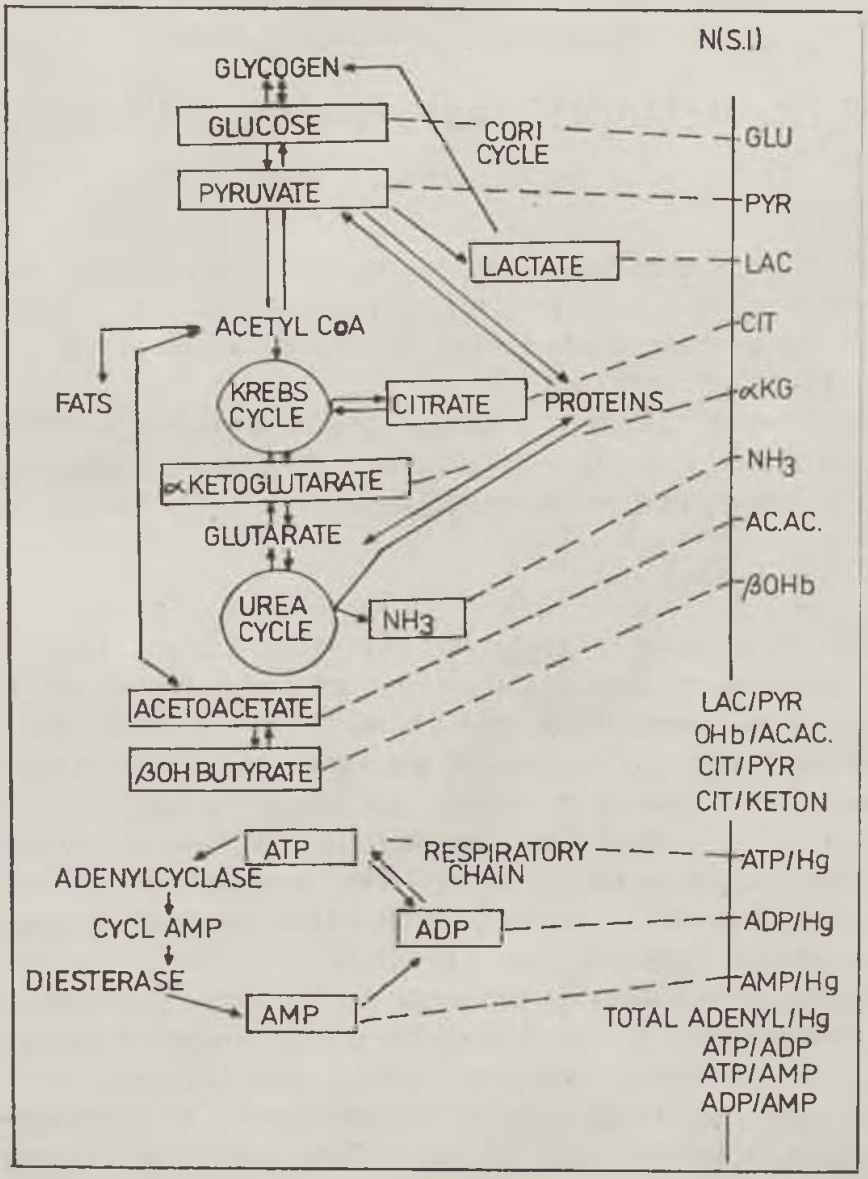

Fig. 1. The places of the investigated substrates in the chief biochemical pathways. The ratios of substrates might indicate the disturbed metabolic steps. The values of normal controls approximate a straight line if they have been expressed as 100 per cent and ordinata indicates our schematic biochemical series

despite the high pyruvate and citrate concentration. Ketone bodies accumulate in a minor degree in serum. The increasing AMP level and decreasing ATP/AMP ratio suggest raised adenylcyclase activity. Primary necretomy and skin transplantation did only partly influence trends of the process.

Fig. 3 shows data of patients with burns up to 20 per cent of the body surface. In these metabolic disturbances similar to the aforementioned, though much more severe have been found in two patients. Clinical findings showed normal values. In these cases shock treatment according to Evans (5) has been

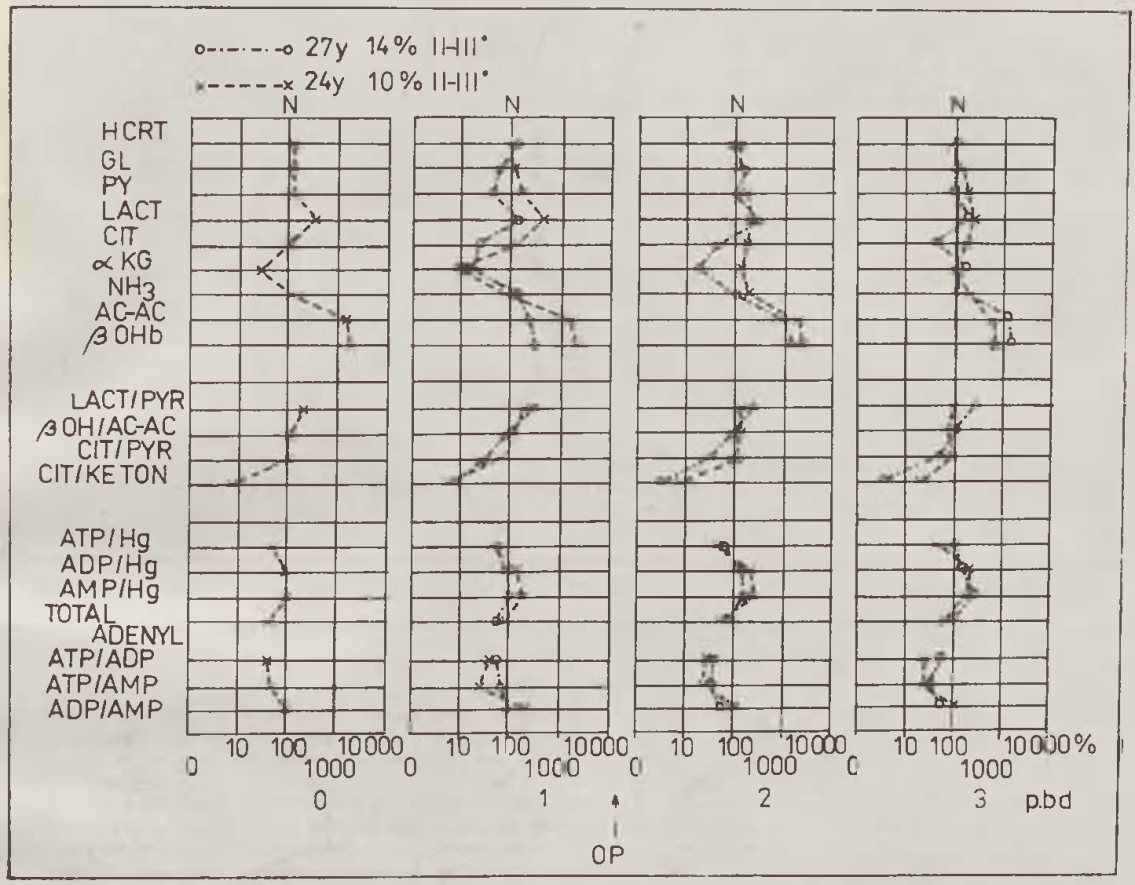

Graphs 2—5. The measured values in the per cent of normal control have been given on the abscissa. Each patient have been represented day by day with the same dotted line. The drawn lines indicate those patients who were treated with insulin (+ high CH intake) right from admission too

applied, Monafo's (6) shock treatment was used in the third patient and was supplemented right from admission —16 hours after the injury — with 40 IU insulin and 50 to 100 mEq potassium phosphate buffer.

Despite the large pool of substrates originating from glyconeogenesis and increased glycolysis, lypolytic end products could enter the tricarboxylic acid cycle. Elevation of lypolysis might have been reduced by insulin. Anyway, value of ketone bodies remained normal. The lower ATP and total adenosine phosphate levels observed on admission, together with measured diphosphoglycerate level, not having been displayed here, promptly normalized or exceeded normal values, respectively. Increase of AMP level suggest adenylcyclase activity increase.

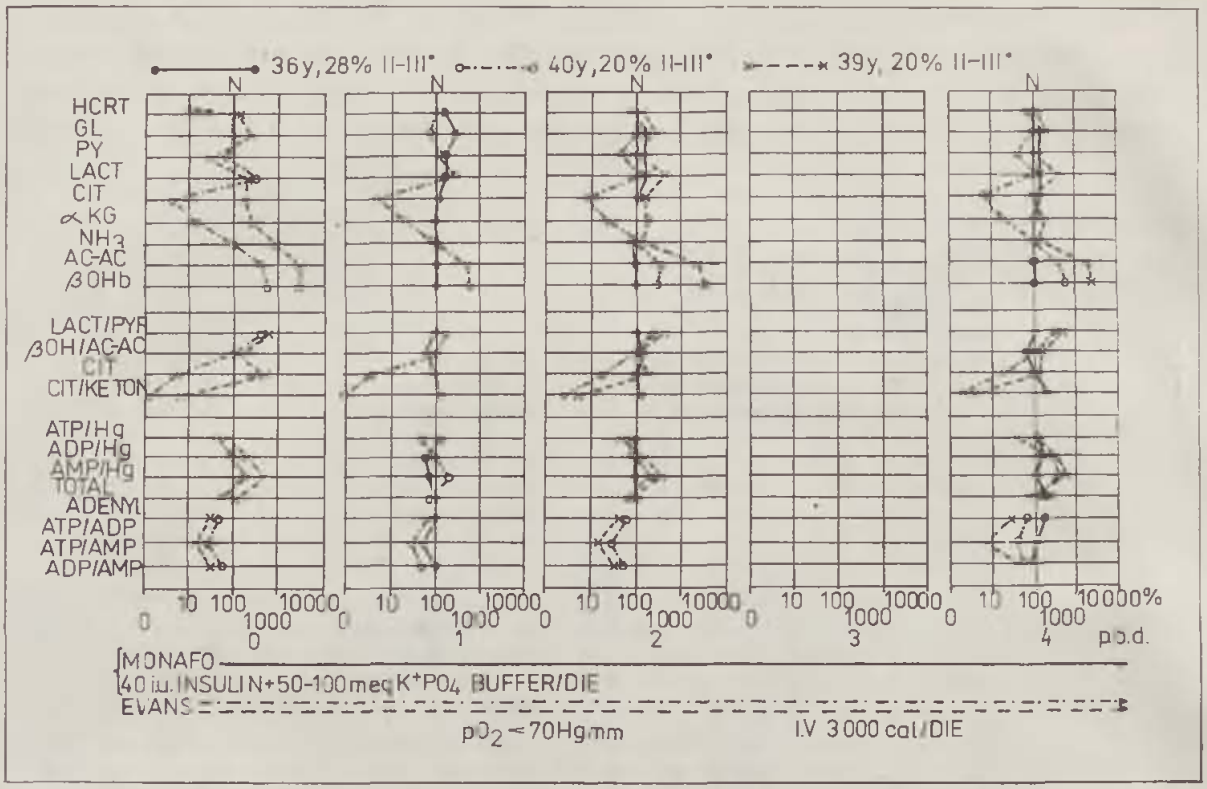

Graph 3.

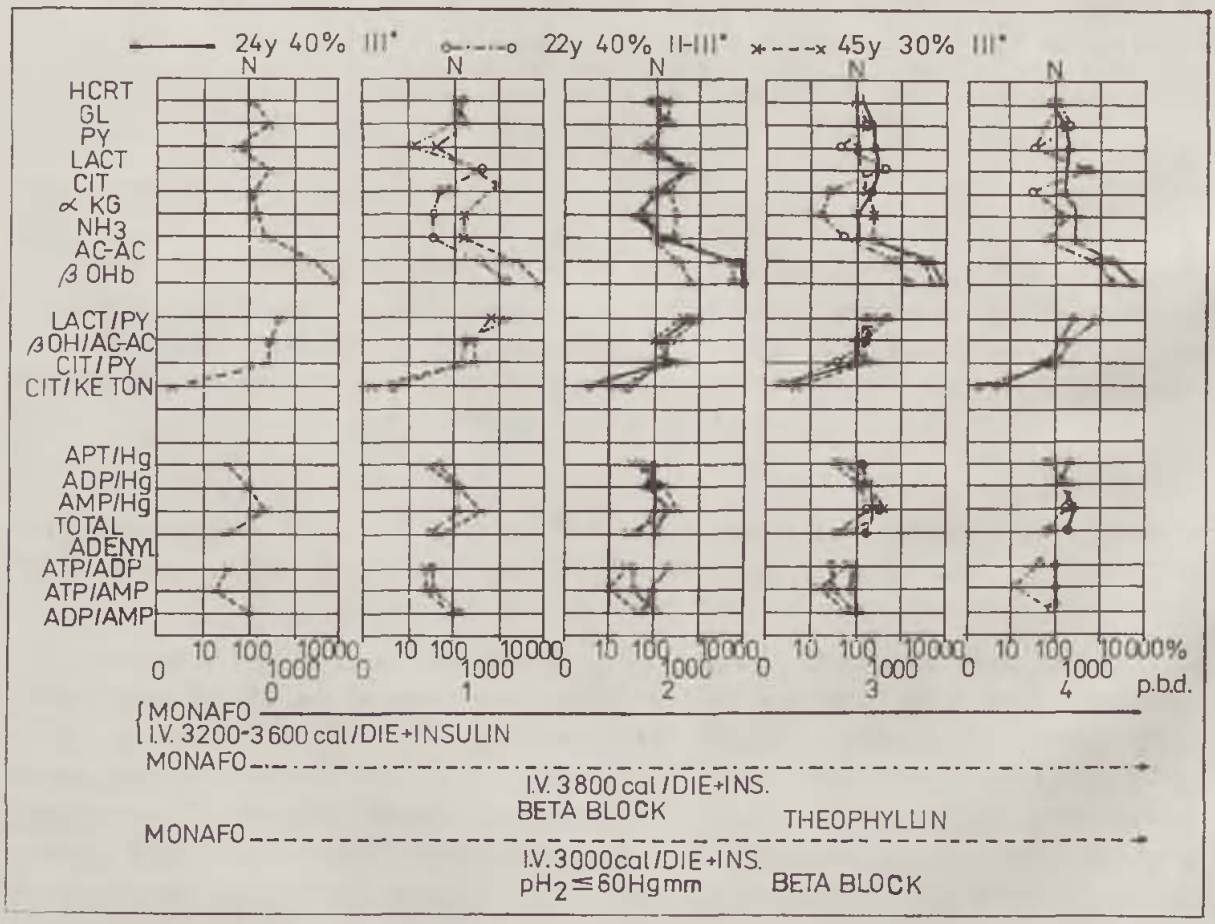

Graph 4.

The next three patients have been admitted with 40 per cent body surface burns and were given shock treatment with hypertonic sodium chloride lactate solution (Fig. 4). After 24 hours intravenous invertose corresponding 3000 calories, 50 g aminoacid solution and 200 to 300 IU insulin were given to two of

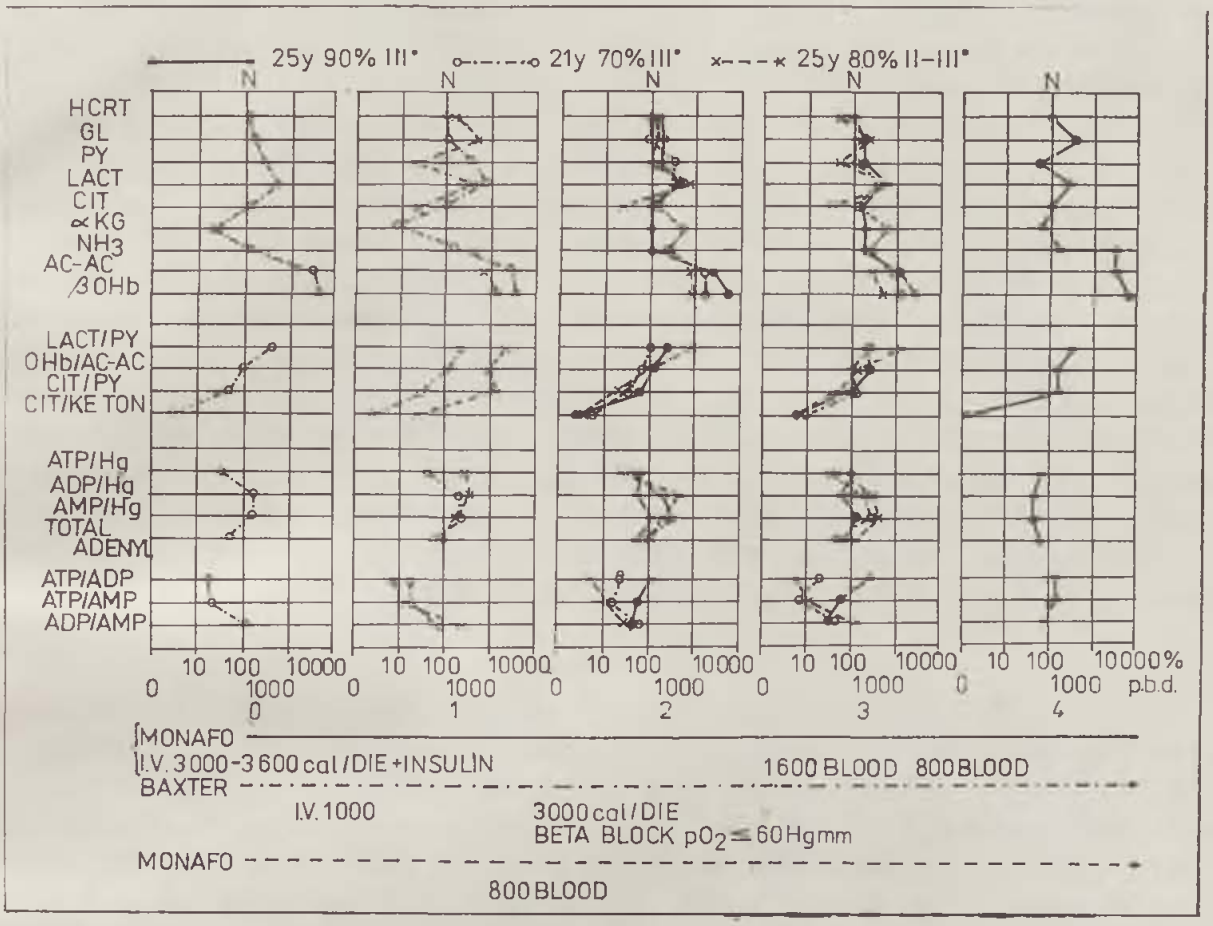

Graph 5.

these patients. The high blood sugar content in both patients was accompanied by low pyruvate level, in one of them also low citrate and ketoglutaric acid concentration has been found. Caloric supply led to the increase of the citrate values and blood sugar level approximated normal value. By day 4 ketoglutaric acid level also showed substantial increase effectuated, presumably, by aminoacid infusion. Concentration of lactate and ketone bodies, and within latter accumulation of hydroxybutiric acid, have been essential. The extremely low citrate/ketone bodies ratio suggests that lipolytic products were not utilized in shock since acetoacetate did not enter the tricarboxylic acid cycle. The low ATP and total adenyl concentrations on admission showed no noteworthy improvement, ADP and AMP showed extreme increase. In one of the patients Trasicor had to be given due to supraventricular tachycardia. At that time a certain improvement of ATP and AMP was found. Because of bronchial spasm Trasicor

had to be discontinued on day 2 and was replaced by Diaphyllin involving an essential fall of the ATP/AMP ratio. Fluid substitution was supplemented from admission by intravenous 3000 calories plus insulin therapy in one patient. Here ATP and total adenyl content normalized on day 2 and showed further increase thereafter, despite severe general condition and hypoxia. In spite of high glycolytic substrate levels and high citrate value, utilization of acetoacetate was inhibited, total ketone bodies concentration decreased on day 4. Increase of lactate/pyruvate ratio did not reach the high level observed in patients with similar severe burn injuries.

Finally, data of three patients with extremely severe burns — 70 to 90 per cent of the body surface — have been summed up (Fig. 5). In one of them intravenous invertose administration exceeded 3000 calories right from admission and was combined with an adequate quantity of aminoacid and insulin. Despite serum metabolic changes adenosine phosphate levels remained almost normal and ATP/ADP ratio suggested that ATP synthesis meets requirements. In the otherpatients insufficient parenteral nutrition on the first two days was hightened from the third day. However the severe metabolic changes decreased only partly despite the apparently succesful hypertonic (6) and isotonic saline solution (2) shock treatment. Adenosine phosphate concentration has neither been influenced. Alike in other patients, it was found remarkable here too, that serum ammonia content was often substantially increased and was accompanied by normal urea nitrogen and creatinine levels.

SUMMARY

On the basis of the mentioned results, which partly coincide with findings reported previously by some (1, 4) authors permitted following conclusions. Severe changes of intermediary metabolism will be found which — ever shock treatment method has been used, even its apparent efficiency on circulatory and laboratory findings. Disturbances are prolonged and will not or almost not be influenced by parenteral caloric administration — insulin-started on day 2 or 3. In addition to hyperglykemia extreme accumulation of lactate and ketone bodies, occasionally low citrate and ketoglutaric acid levels, as well as varying pyruvic acid values are characteristic features.

The measured contraction ratios suggests that entry into Krebs' cycle of glycosis and of lypolysis end products is inhibited. The frequently high ammonia concentration suggests insufficiency of the urea cycle as compared to increased glyconeogenesis. ADP and AMP accumulation in red cells points to increased ATP utilization. At the same time ATP synthesis does not meet requirements. Exogenous insulin and sugar administration started on admission might result in improvement of these disorders.

RESUME

L'études des troubles métaboliques au cours du choc chez les brûlés

Szabó K., Tulok I., Novák J.

Les résultats décrits qui correspondent en partie aux observations de certains auteurs (1, 4) publiées plus tôt, permettent de prononcer les conclusions suivantes. On a

observé les changements graves du métabolisme intermédiaire quelque soient les méthodes appliquées contre le choc, y compris celles qui, d'une façon efficace, améliorent la circulation sanguine et les résultats laboratoires. Les troubles ont duré longtemps et n'étaient pas du tout ou presque influencés par la médication calorique perentérale + l'insuline qui a été entamée le 2e et le 3e jour.

Excepté l'hyperglycémie, la spécialité caractéristique était l'accumulation extrême du lactate et des matières cétoniques, parfois le niveau bas des citrates et de l'acide cétoglutarique de même que l'instabilité des niveaux de l'acide pyruvique. Les rapports de concentration remarqués montrent que l'entrée des produits résultants de glycolyse et de lipolyse dans le cycle de Krebs est diminuée. Dans la plupart des cas, la haute concentration de l'ammonium révèle l'insuffisance du cycle uréique à la différence de la glyconéogenèse. L'accumulation ADP et AMP dans les hématies prouve que l'utilisation de ATP s'augmente. Simultanément, la synthèse de ATP ne correspond pas aux exigences.

L'administration exogène des sucres et de l'insuline commencée immédiatement après l'hospitalisation du malade, pourrait corriger les troubles précités.

ZUSAMMENFASSUNG

Untersuchungen über Stoffwechselstörungen bei dem Verbrennungsschock

Szabó K., Tulok I., Novák J.

Die beschriebenen Ergebnisse, die zum Teil den früher veröffentlichten Beobachtungen anderen Autoren (1, 4) entsprechen, ermöglichen folgende Schlüsse zu ziehen. Schwere Veränderungen des intermediären Stoffwechsels wurden beobachtet, auch wenn verschiedenste Methoden der Schockbekämpfung benutzt wurden, sogar auch jene, die im Hinblick auf den Blutkreislauf und die Laboratoriumsbefunde offensichtlich effektiv waren. Die Störungen dauerten lange und wurden nicht beeinflusst — oder fast nicht beeinflusst — doch die parentelae kalorische Medikation + Insulin, mit der man am 2. oder 3. Tag begonnen hatte. Ausser der Hyperglykämie bildeten ein charakteristisches Sondermerkmal die extreme Akkumulation von Laktat und Ketonkörpern, manchmal niedrige Spiegel der Zitrate und der Ketoglutarsäure sowie die Schwankung der Werte der Brenztraubensäure. Die beobachteten Konzentrationsverhältnisse weisen darauf hin, dass der Eintritt der resultierenden Glykolyse- und Lipolyseprodukte in den Krebsschen Zyklus unterdückt ist. Die häufig hohe Ammoniumkonzentration verrät die Insuffizienz des Harnstoffzyklus im Gegenteil zu der Glykoneogenese. Die Akkumulation von ADP und AMP in den roten Blutkörperchen ist ein Beweis für die steigende Utilisierung von ATP. Gleichzeitig entspricht die ATP-Synthese keinesfalls den Bedürfnissen. Die exogene Verabreichung von Sacchariden und Insulin, eingeleitet unmittelbar nach der Ankunft des Patienten, könnte zur Korrektur dieser Störungen führen.

RESUMEN

Estudio de perturbaciones del metabolismo en el choque por quemadura

Szabó K., Tulok I., Novák J.

Los resultados descritos que en parte coinciden con las preinsertas (1, 4) comprobaciones hechas por algunos autores permiten sacar las siguientes conclusiones. Fueron observadas graves mutaciones del metabolismo intermediario, cualesquiera métodos de tratamiento del choque se hubiesen aplicado, incluyendo los de evidente

eficiencia respecto a la circulación de la sangre y los resultados de laboratorio. Las turbaciones persitieron mucho tiempo sin ser paliadas o sin serlo casi — ni siquiera por la medicación calórica parenteral más insulina, iniciada el segundo o el tercer día. Además de la hiperglicemia el fenómeno se caracterizaba por extremadas acumulaciones de lactato y cuerpos de cetona y a veces también por niveles bajos de citratos y de ácido cetoglutárico así como oscilacones de cantidades de ácido pirúvico. Proporciones de contracción observadas atestiguan de que se encuentra suprimida la entrada de productos resultantes de la glicolisis y lipolisis, en el ciclo de Krebs. La frecuente concentración alta de amonio revela una insuficiencia de ciclo ureico a diferencia de la glucineogénesis. La acumulación del ADP y AMP en los glóbulos rojos testimonia de la creciente utilización del ATP. Al mismo tiempo, la síntesis del ATP no corresponde a los requisitos. Una administración exógena de azúcar e insulina, si se inicia inmediatamente después de ser ingresado el paciente puede conducir a eliminar estas pertubaciones.

REFERENCES

1. **Batstone, G. F. et al.**: Burns 2: 206, 1976.
2. **Baxter, C. R.**: Clin. Plast. Surg., 1: 693, 1974.
3. **Camp, B. J., Farmer, L.**: Clin. Chem., 13: 501, 1967.
4. **Doleček, R.**: Metabolic Response of the Burned Organism. Thomas, 1969, Springfield (III).
5. **Evans, E. I. et al.**: Ann. Surg., 135: 804, 1952.
6. **Monafo, W. W. et al.**: Amer. J. Surg., 126: 778, 1973.
7. **Müting, D. et al.**: Dtsch. Med. Wschr., 95: 1390, 1970.
8. **Williamson, D. H. et al.**: Biochem. J., 82:, 90, 1962.

K. Szabó, M. D., Budapest, P.O.B. 1., 1553 Hungary

Komenský University Medical Faculty, Bratislava (Czechoslovakia)
Department of Plastic Surgery
Head As. Prof. František Mariš, M. D., CSc.

A NEW METHOD OF LOCAL APPLICATION OF GENTAMYCIN

F. Mariš, J. Novák

If an antibiotic is administered systemically its action in the locality concerned will depend on its ability to penetrate the barrier of morphological structures and to reach the concentrated focus of the given pathological bacterial agent.

The use of polymethylmetacrylates saturated with a suitable antibiotic is one of the forms of local and highly effective application of antibiotics. It also conforms to the requirements of specific antibacterial therapy since the technique permits the development and maintenance at the site of infection of an adequately high level of the antibiotic and allows it to be maintained long enough to ensure pronounced antibacterial efficacy. Moreover, the organism as a whole can avoid the stress of being flooded with large quantities of the active principle.

Quantitatively oriented long-term research provides enough evidence to show that water-soluble antibiotics are released from the polymethylmetacrylate by way of diffusion which is made possible by the absorption of 1.5 to 2 % water in cured Palacos at 37 ^{0}C. At first, a larger amount of the substance is released before the diffusion and elution of the antibiotic begin to slow down over a long period of time.

Gentamycin is released from Palacos in sufficient quantities per unit of time. This is the most suitable combination; the preparation is made by the pharmaceutical firm Merck under the trade name of Septopal. It has a broad spectrum of antibacterial effect, a low degree of resistance and allergy development, and has considerable physical-chemical stability particularly in relation to heat.

Antibiotic-saturated polymethylmetacrylate is manufactured in the form of pellets 7 mm in diamater, weighing 0.2 g each, with 4.5 mg gentamycin base and 20 mg zirconium dioxide as X-ray contrast medium. The drug is commercially supplied in packages of 10 pellets each, more, however, in the form of strings of beads 30 cm long with 30 pellets fixed to a polyfilamentous wire. For long bones strings of 60 pellets each are available. For application in smaller pellets are manufactured.

The local application of pellets inserted in infected soft tissues was marked by low antibiotic concentrations in the serum and urine, and by the simultaneous high concentration of gentamycin in the wound secreta.

Fig. 1.

The concentration of antibiotic necessary to produce a sufficient antibacterial effect at the site of infection is exceeded over a period of many weeks. It follows then that as regards profuse and protracted release of antibiotics, these active principle carriers are particularly well suited for antibacterial therapy of soft tissue infection.

However, even in cases of long bone chronic osteomyelitis the application of pellets proves useful as the outflow of secreta remains unimpeded, and the introduction as well as the removal of the pellets is technically quite feasible.

The following procedure was observed in the application of Septopal.

A sample of secretion from the infected site was taken for bacteriography. The point to be borne in mind here is that the bacterial flora in the opening of the fistula may differ from that deep inside the infected space. Another such important point is that in the application of Septopal the local concentrations of the antibiotic are ten to a hundred times higher that the minimum concentrations with sufficient effect on the most important strains of bacteria. Consequently, the bacterial strain resistance ascertained in routine antibiograms for serum concentrations of the antibiotic in the systemic mode of administration is of no relevance. Since the local concentration of gentamycin prominently exceeds the minimum bacteriostatic concentration of gentamycin, the clinical course of the treatment may prove a success despite evident gentamycin resistance ascertained by routine bacteriography.

Following the removal of necrotic tissue, sequestra, and the introduction of the pellets, the skin cover has to be closed to prevent the released antibiotic from escaping with the secretion, and to keep it at maximum concentration at

the site of infection. Only in cases of excessively voluminous and purulent secretion was it necessary, for the first two days, to wash out two extensive decubital ulcers. Another possibility is the use of drain without negative pressure in order to relive the skin suture. Haematoma permits the release of antibiotics.

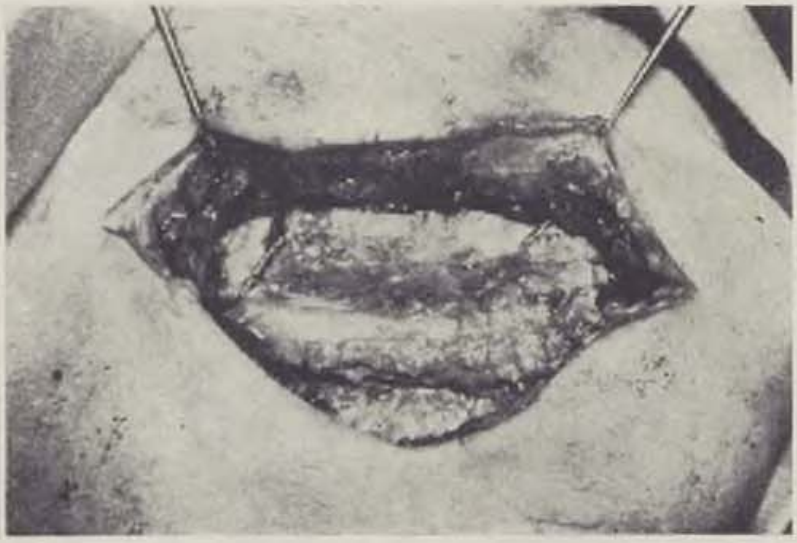

Fig. 4.

The drain can be removed in one to three days after the secretion has been reduced. The last pellet or the end of the string left to stick out of the wound are easy to pull out. Septopal is left in place for 10 to 14 days. The subsequently organized granulation tissue is bound to fix the string which can only be removed by surgical means. Where the defect cannot be closed by suture, it should by covered with Synkrit (Epigard, Syspurderm). After debridement or the development of granulation tissue the wound is closed by means of suture, free graft or skin flap.

The main indications for the use of Septopal in our patients were infection of soft tissues or combined infection of bone and soft tissue. The following strains of bacteria were found the most frequently: Staphylococcus pyogenes aureus, Staphylococcus epidermoides, Escherichia coli, Streptococcus pyogenes, Streptococcus viridans, Proteus mirabilis and Pseudomonas aeruginosa.

The following are a few case reports on patients treated with Septopal:

Patient G. C. (clin. n. No. 20 463), aged 40, irradiated for laryngeal carcinoma in 1974. Admitted at our clinical department with the diagnosis of: state after radiotherapy for laryngeal carcinoma, osteomyelitis mandibulae 1. dx., osteoradionecrosis, pathological fracture of the mandible.Biopsy from the affected area proved negative. At the time of admission, the fistula led right up to the bone, however, without entering the oral cavity. Bacteriogram: Staphylococcus epidermoides, Streptococcus viridans, resistant to PNC and ERY.

The first surgical operation involved the excision of soft tissue, and resection of the necrotizing portion of the mandible at a length of 6 cm. A string of

6 beads of Septopal were implanted along a piece of Kirschner wire which fixed fragments of the mandible. Healing after skin suture was by first intention (Fig. 3).

After 3 and a half months, both Septopal and Kirschner's wire were removed, and the defect in the mandible (Fig. 4) was filled with a bone graft from

Fig. 5.

the hip bone. The skin was closed with V-Y-plasty (Fig. 5). The tissue from the vicinity of Septopal was used for biopsy: signs of chronic inflammation, giant cells surrounding foreign material. Bacteriography proved negative. The postoperative course was without complications.

Patient M. H. (cl. n. No. 20 440) suffered an open comminuted fracture of the right foreknee. In the subsequent years, she had several sequestromies performed.

On admission in 1979, the anterior portion of the right leg showed the presence of an inflamed scarry cover extending from the tuberositas tibiae up to the distal third of the leg and fixed to the bone. In the proximal part, there was the wound area and osteomyelitis tibiae. Bacteriography proved the presence of Staphylococcus aureus sensitive to all antibiotics (Fig. 6).

A tube flap 27×16 cm was lifted from the abdominal wall to cover the defect. Sequestrotomy was performed, and a string of 27 Septopal beads was implanted from the proximal and distal directions into the tibia (Fig. 7, 8). The defect was covered with Syspurderm. After 10 days, Septopal was removed from the soft tissue but left in intramedullarly. The upper third of the scar was excised, and part of the tube flap transferred with the aid of a temporary carrier was sutured into the defect (Fig. 9).

After 4 weeks, the flap was cut off the carrier and, following the excision of the remaining part of the scar, sutured into the defect. The flap transfer and healing occurred without inflammatory complications (Fig. 10).

Fig. 6.

Fig. 7.

Fig. 8.

Fig. 9.

Our patients showed no signs of ototoxic or nephrotoxic affection or any allergic response to polymethylmetacrylate.

Synkrit Syspurderm as well as Epigard proved useful as temporary cover for open wound areas following the application of Septopal.

Fig. 10.

The granulation tissue which developed while Septopal was used provided a suitable wound area for direct skin flap application. There was no need to remove this granulation tissue, nor were there any post-operative complications as a result of infection from the granulation tissue.

In irradiated areas, too, the effect of Septopal was sufficient as a means of preparation for bone transplant surgery.

Septopal proved extremely efficacious in the treatment of large decubital ulcers in paraplegic patients. If there was conspicuous secretion, the decubital pockets were washed twice daily during the first two days after the drug was started. Consequently, the amount of secretion diminished, so the lavage was discontinued in order to maintain a high enough concentration of antibiotics in the pockets. These were cleaned with a curette 10 days after the application of Septopal, the edges were excised, and the wound was subsequently sutured.

If our experience so far is anything to go by, Septopal can be regarded as well suited for the local application of antibiotics, and as a useful component of comprehensive surgical treatment of infections. The main advantages of Septo-

pal are as follows: fewer redressings, less treatment time, no need to administer antibiotics daily per os or parenterally, no need for time-consuming lavage and perfusions; moreover, the use of Septopal is more economical than the systemic administration of antibiotics.

The above listed advantages help to shorten and intensify the treatment of surgical infections, and make the process easier for both patients and the nursing staff. Septopal in smaller beads and in smaller, economical packages is being developed for use in plastic surgery. J. H.

SUMMARY

Septopal, manufactured by the Merck company, is recommended as useful for the local treatment of surgical infections on the basis of the author's own clinical experience. Septopal is polymethylmetacrylate saturated with gentamycin base. The antibiotic is released in sufficient concentrations for long periods of time, thus accounting for the great antibacterial effect. At the Bratislava department of plastic surgery, the drug was used for the treatment of soft tissue infections or also for the treatment of combined infections of soft tissue and bone. Several case reports are included to demonstrate the practical uses of Septopal.

RESUME

La nouvelle méthode d'application locale de Gentamycine

Mariš F., Novák J.

On recommande, à la base des examens cliniques, un remède convenable pour le traitement locale des infections chirurgicales — SEPTOPAL, produit de la firme MERCK. Il s'agit de polymethylmétacrylate saturé par la base de Gentamycine. L'antibiotique agit dans la concentration suffisante pendant longtemps alors que l'effet antibactériel est très efficace.

A la clinique de la chirurgie plastique à Bratislava on l'a utilisé pour le traitement des infections des tissus moux et des infections des os.

Les auteurs décrivent le traitement de ses quelquesmalades avec SEPTOPAL.

ZUSAMMENFASSUNG

Eine neue Methode der lokalen Applikation von Gentamycin

Mariš F., Novák J.

Als ein geeignetes Medikament zur lokalen Behandlung der chirurgischen Infektionen wird aufgrund klinischer Erfahrungen das von der Firma Merck hergestellte Präparat Septopal empfohlen. Es handelt sich um ein mit Gentamycinbase gesättigtes Polymethylmetakrylat. Das Antibioticum wird in genügender Konzentration und während eines langen Zeitraums freigesetzt, so dass seine antibakterielle Wirkung sehr effektiv ist. An der Klinik der plastischen Chirurgie in Bratislava benutzten wir es bei der Behandlung von Infektionen der weichen Gewebe oder bei kombinierter Infektion des weichen Gewebes und des Knochens. In der Arbeit wurden einige Patienten demonstriert, bei denen Septopal eingesetzt wurde.

RESUMEN

Nuevo método de aplicación local de Gentamycin

Mariš F., Novák J.

Como medicamento conveniente para tratamiento local de las infecciones quirúrgicas se recomienda, a base de la experiencia clínica, el Sestopal fabricado por la firma Merck. Es un polimetilmetacrilato saturado con la base gentamicina. El antibiótico se viene generando por mucho tiempo y en concentraciones suficientes, por cuánto el efecto antibacterial resulta muy fuerte. En la Clínica de Cirurgía Plástica en Bratislava lo hemos utilizado al curar infecciones del tejido blando o infecciones combinadas del tejido blando y el hueso.

REFERENCES

1. **Asche, G.**: Die Verwendung von Gentamycin PMMA Miniketten in der septischen Chirurgie der Hand. Aktuelle Probleme der Chirurgie und Orthopädie, 12, 103—112, Hans Huber Verlag, Bern, Stuttgart, Wien, 1979.

2. **Dingeldein, E.**: Spektrum und Empfindlichkeit bakterieller Erreger unter der Behandlung von Knocheninfektionen mit Gentamycin Polymetylmetacrylat. Aktuelle Probleme der Chirurgie und Orthopädie, 12, 113—120. Hans Huber Verlag, Bern, Stuttgart, Wien, 1979.

3. **Klemm, K., Contzen, H., Lennert, K. H.**: Gentamycin PMMA Kugeln bei Knochen und Weichteilinfektionen — Ergebnisse aus der Berufsgenossenschaftlichen Unfallklinik, Frankfurt/Main. Aktuelle Probleme der Chirurgie und Orthopädie, 12, 128—132. Hans Huber Verlag, Bern, Stuttgart, Wien, 1979.

4. **Wahlig, H.**: Experimentelle Grundlagen für die Anwendung von antibiotikahaltigem Polymethylmetacrylat. Aktuelle Probleme der Chirurgie und Orthopädie, 12, 103—112, Hans Huber Verlag, Bern, Stuttgart, Wien, 1979.

Dr. F. Mariš, Dept. of Plastic Surgery KUMF, 800 00 Bratislava, Czechoslovakia

NEW BOOKS

L. Šimun: **Atlas of Surgery of the Hand**

The author gives a brief summing up of the essentials of surgical anatomy in order to outline the correct principles of making simple knot skin suture, the basic methods of opening the skin cover for good access to deep structure revision. For tendon suture he describes the technique of starting simple buried cross suture, for nerves — the classical epineural suture. The general section ends up with a list of the basic principles of the methods of skin plastic operations.

In the special section chapter on flexor injuries the author gives advice on the treatment of the flexion mechanism in the osteofibrous capsule, and on treatment at the distal section, and in injuries of the long flexor of the thumb. A similar situation is described in injuries of the extensors of the digits and their ruptures with examples of the conservative and surgical methods of treatment. The chapter on bone injuries deals with some of the frequent and typical fractures of phalanges and metacarpal bones. Skin defect management involves plastic operations using skin from the immediate or near vicinity, or even from distant sites. Also included are methods for thumb skin avulsion, from whole hand skin avlusion, and for roller compression hand injuries. For cases of sharp amputation of fingers the author outlines a technique of reimplantation in what is a classical modification of Gillies' method.

More chapters are devoted to methods of post-injury treatment such as the management of contracting scars on the fingers, in the commisure, and in the palm of the hand — using local plastic surgery as well as skin transplants. Reconstruction of flexor tendons is discussed in another chapter. Detailed drawings are given to show tendon transplant operations in injuries affecting the "danger zone", the techniques of lifting the transplants, and the determination of their length. Also included is reconstruction of the expansion apparatus using a method according to Fowler.

For grip reconstruction the author presents the cocket hatflap method and the bone transplant techniýue, as well as a surgical operation according to Hilgenfeldt (involving the use of the 2nd metacarpal for making the thumb longer). Secondary reconstruction of injured nerves (n. medianus, n. ulnaris, n. digitalis) is represented in pictures showing the successive stages of operation.

Special chapters are devoted to the therapy of Dupuytren's contracture. The operation technique and methods of general procedure are represented according to the particular degrees and forms of the contracture. The book ends up with a chapter on the management of some of the congenital malformations of the hand such as syndactyly, acrosyndactyly, double thumb, clinodactyly, and strangulation.

The usefulness of a book of this kind is in a wealth of drawings showing different phases of surgical operations with

all the necessary technicalities, which any surgeon should appreciate. The book is consistent in its view of the methods which have been found the most useful. The drawings are comprehensive and easy to understand thanks to a uniform style. In what is a most fortunate coincidence, the author as a plastic surgeon is very good at drawing, too. The pictures are accompaneid by brief, succint explanations devoid of convoluted descriptions as befits the practical nature of the volume.

Atlas of Surgery of the Hand — selected chapters on surgical techniques — is a practical book intended mainly for general surgeons, traumatologists and orthopedic surgeons, but — in matters of superspecialization — for plastic surgeons, too.

Published by Osveta Publishing House, national enterprise, Martin (Czechoslovakia), 1980, 145 pages, 335 illustrations.

R. Vrabec, M. D.,

Příčná 1, 110 00 Praha 1, Czechoslovakia

NEWS

During the General Assembly of the XV. Conference of the Section of Plastic and Reconstructive Surgery of the Society Polish Surgeons the following officers were elected for 1981—1982:

President: Zygmut Kratochwil M. D. — Wrocław
Vice-president: Michał Krauss Assoc. Prof. M. D. — Warszawa
Members: Jan Goldstein Prof. M. D. — Łódź
Kazimierz Kobus Assoc. Prof. M. D. — Polanica
Wanda Kondrat Prof. M. D. — Gdańsk
Jerzy Potocki M. D. — Warszawa
Antoni Trybus M. D. — Kraków
Secretary: Tadeusz Myczkowski M. D. — Wrocław

The next Conference of our Section will be held in Wrocław of 1982.

For further information please write to Dr Zygmunt Kratochwil, ul. Wiśniowa 36a, 53-137 Wrocław, Poland.

INSTRUCTIONS TO AUTHORS

Acta Chirurgiae Plasticae, the international journal of plastic surgery, is issued in two versions four times a year. One version is in English (or, as requested by the author, in French or German) and the other in Russian. The aim of the Journal is to make specialists acquainted with the work of authors of the socialist countries, but studies from other countries are also published and welcomed.

Articles are accepted for publication which deal with the problems of plastic surgery and allied branches (clinical, laboratory, experimental studies); they must be original and not yet been published elsewhere. Articles written by authors of the countries which are represented in the editorial board of the Journal, must be given their imprimatur by the respective members.

Kindly send your manuscripts to the following address: Acta Chirurgiae Plasticae, c/o R. Vrabec, M. D., the secretary, tř. Lidových milicí 63, Praha 2, Czechoslovakia.

The manuscript must be typewritten in two copies (1 original plus 1 carbon-copy), one page per sheet, with doublespacing between the lines, 60 types per line and no more than 30 lines per page. There must not be more than five corrections by handwriting per manuscript. The manuscript should not exceed egiht pages and contain no more than 10—12 illustrations. The institute the author works at, its director, the title of the article and the full name of the author (or authors), must be stated on the first page. All other pages should be numbered consecutively. Every paper must have a summary which is then translated into French, German and Spanish. The summary, the references and the captions to the figures are to be written each on a separate page and added to both copies of the manuscript. The address of the main author should be given at the bottom of the references. The place where the tables are to be inserted, must be marked in ink on the margin of the text. Figures are to be separate and not affixed in the text. On the back of each figure, the author is requested to write his name, the short title of the paper and the consecutive number of the illustration which must tally with the number marked on the margin of the text. An arrow indicates the way the figure should be set. Photographs must be clear, with good contrast and of the same size (best 6×9 cm.). The tables and graphs should be lined with Indian ink on white paper so as to make them well readable.

References should be limited, quoted from internationally accessible sources and not older than five years. It the number of references exceed ten, the editors are

Quotations should be adjusted according to Czechoslovak norm as follows: Articles in journals — author's surname and initials, title of the article (may be left our), international abbreviation of the journal, volume, number, page and year of issue. For instance: Frazer F. C., Warburton D.: Plast. reconstr. Surg., 33, 4 : 395, 1964.

Books and monographs — name of author, title of publication, place of issue, publisher, year of issue and — maybe — also page from which quotations has been taken. For instance: Burian F.: Surgery of Cleft, Praha, SZdN 1954.

Manuscripts which do not comply with these requirements, cannot be published.

The editorial board reserves the right to suggest to the author publication of his article in the form of an annotation, shorten the original manuscript, make corrections or, an account of comments made by the reviewers, return the manuscript to the author for redrafting. The papers must be sent to the editor in their final formulation. The galley proofs are done by the author, but no essential changes are permitted. The authors of original papers receive 50 reprints free of charge and without special order.

A. A. Kolesov, N. N. Kasparov, S. V. Dyakov, M. A. Pershin

TREATMENT OF MANDIBULAR BONE HAEMANGIOMA BY BIOLOGICAL PLASTIC TAMPONADE IN CHILDREN

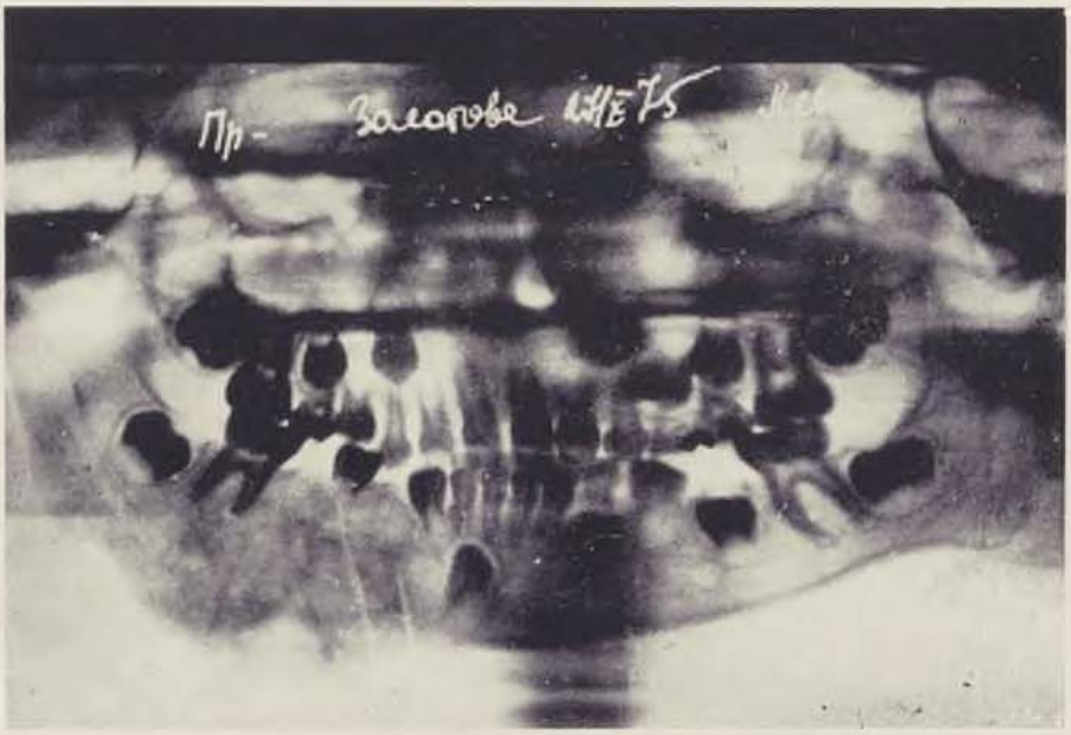

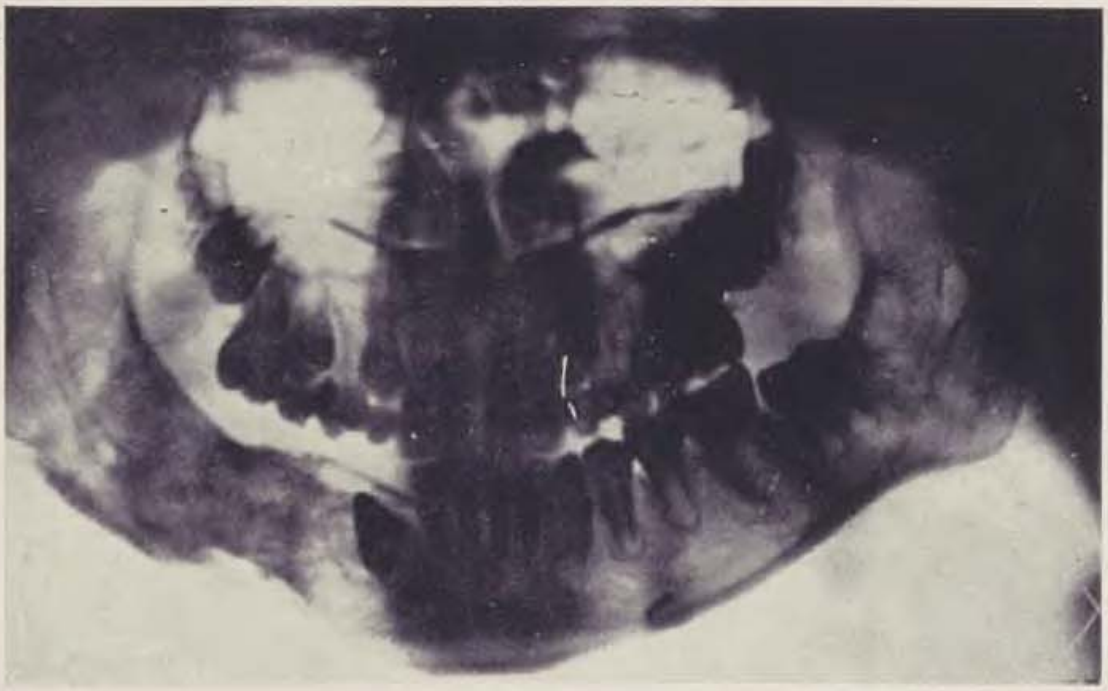

Fig. 1. Capillary haemangioma of mandibula, patient Z. (9. years).
a — an orthopantomogramm taken before the operation; an osteoporotic region visible on the lower margin of the neoplasm was caused by an open surgical biopsy
b — the same region examined 2 years after the operation

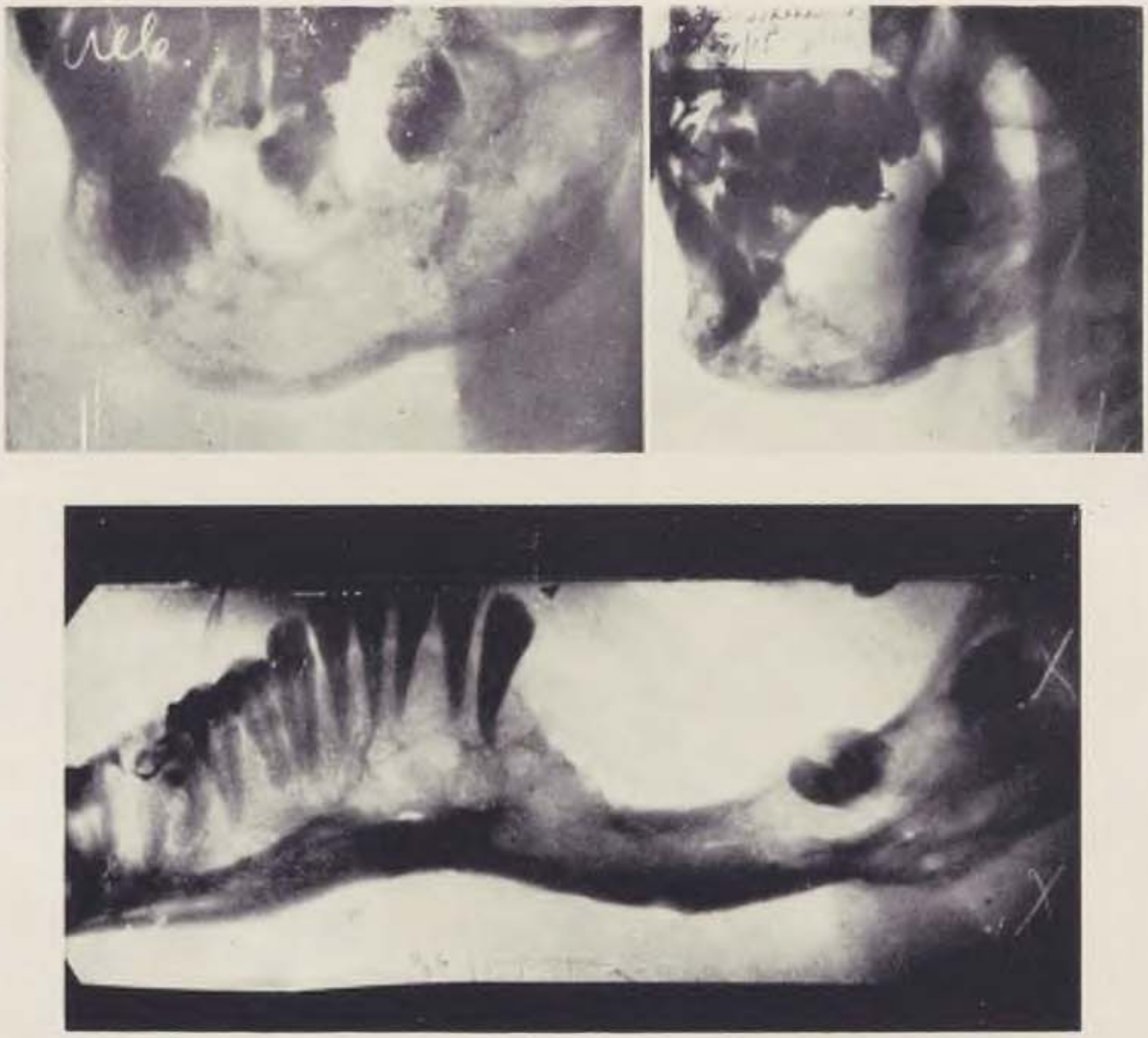

Fig. 2. Cavernous bone haemangioma of mandibula, patient Ya. (9 years)

a — a roentgenogramm taken before the operation

b — a roentgenogramm taken 6 months after the operation

c — an orthopantomogramm of the jaws, which was taken 14 years after the operation and 7 years following the X-ray therapy

Fig. 3. Cavernous bone haemangioma of mandibula, patient S. (12 years)
a — a roentgenogramm before the operation
b — a roentgenogramm 4 years after the operation

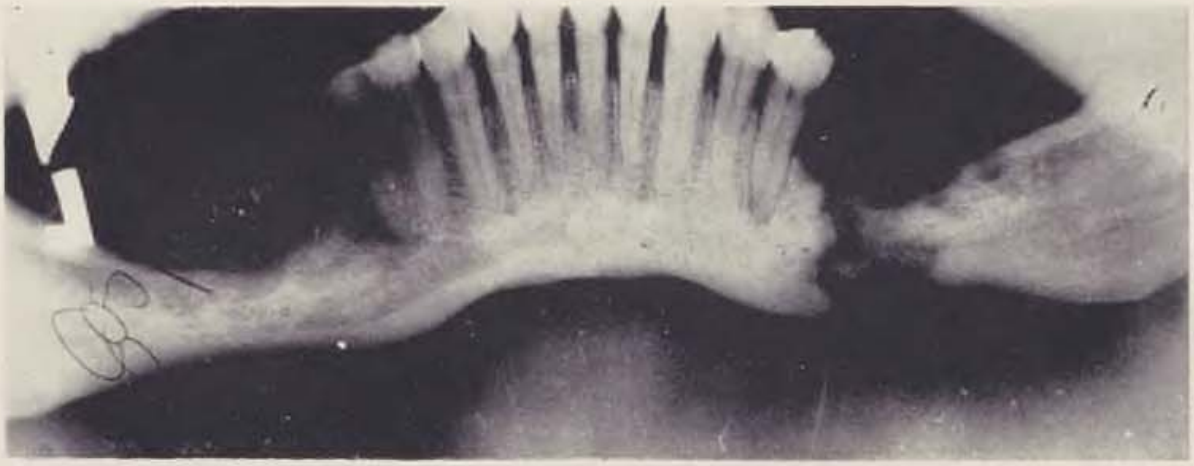

Fig. 2.

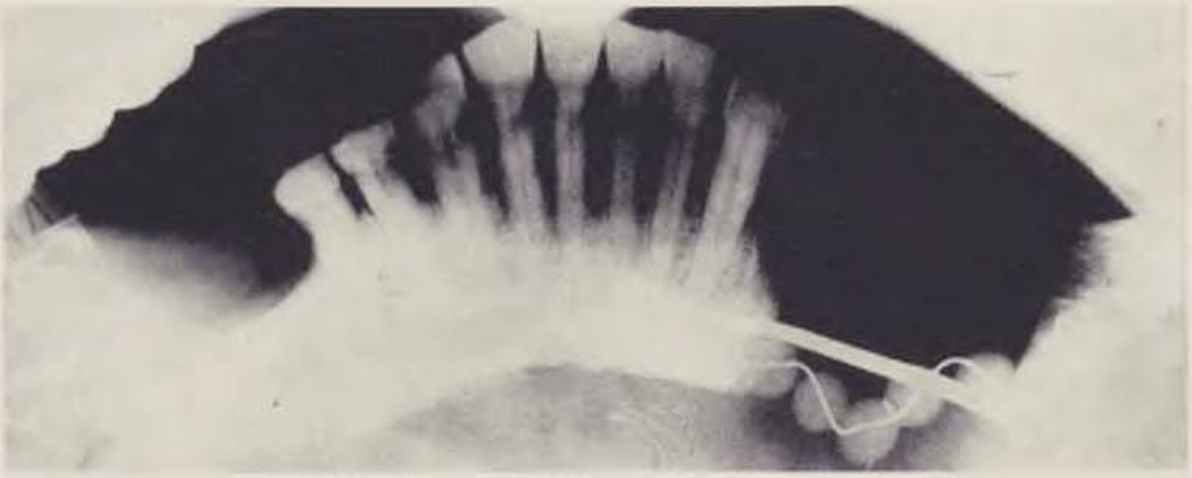

Fig. 3.

CONTENTS