ACTA CHIRURGIAE PLASTICAE

INTERNATIONAL JOURNAL
OF PLASTIC SURGERY

25 · 2

1983

CS ISSN—0001—5423

AVICENUM · CZECHOSLOVAK MEDICAL PRESS
PRAGUE

Exclusive Distributors for all Western Countries
KARGER-LIBRI AG, Petersgraben 31, CH-4000 Basel 11 (Switzerland)

Distributed by PNS. Information on subscription can be obtained from and orders are accepted by every administration of PNS, post-office, postman and PNS Central Expedition Prague. Orders for abroad are accepted by PNS Central Expedition and Press Import, administration of press export Kafkova 19, 160 00 Praha 6.

Published four times (in 1959: two times) a year by Avicenum - Czechoslovak Medical Press, Malostranské nám. 28, Praha 1. Editor in Chief Prof. H. Pešková, M. D. — Address of the Editorial Office: Acta Chirurgiae Plasticae, 120 00 Praha 2, Lidových milicí 63, Czechoslovakia. — Press: Tiskařské závody, n. p., Praha, závod 1 — provoz 11, Praha 2, Hálkova 2.

Subscription rate: Sfr 109,— plus postage, Exclusive distributors for all countries with the exception of Albania, Bulgaria, China, Cuba, Czechoslovakia, German Democratic Republic, Hungary, North Korea, Vietnam, Mongolia, Poland, Roumania, the Union of Soviet Socialist Republics and Yugoslavia:

KARGER LIBRI AG, Petersgraben 31, CH-4000 BASEL 11 (Switzerland)

EPIGLOTTOPEXIA AND LARYNGOPEXIA
INDICATIONS, METHOD AND RESULTS OF THE OPERATIONS

A. I. Yunina

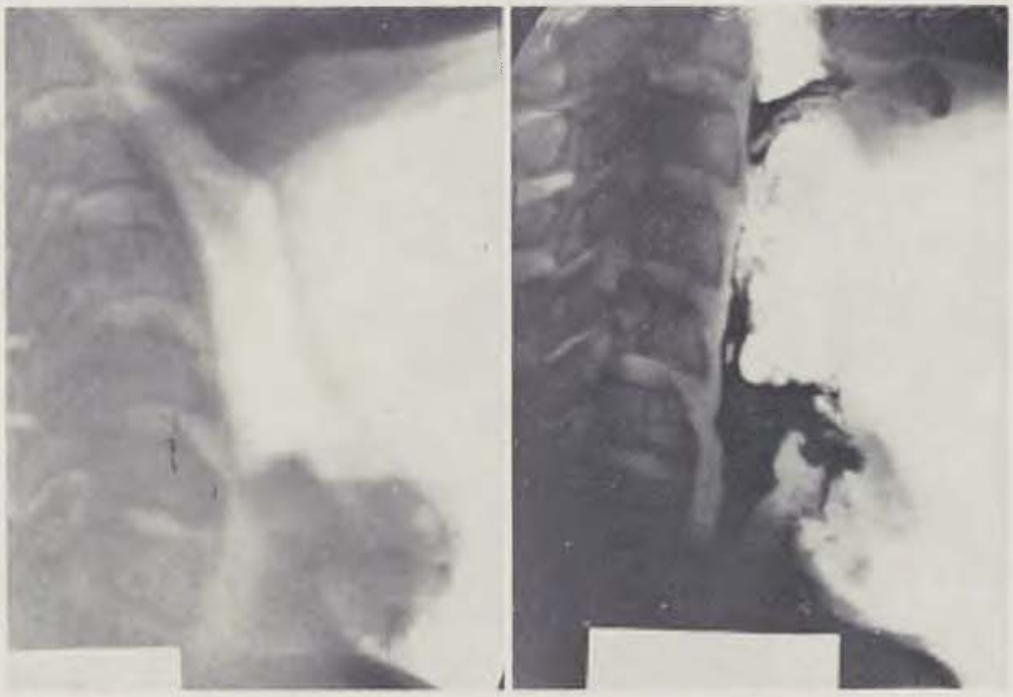

Fig. 1. X-ray photographs of patient S. Consequences of a neck injury (pharyngotomia subhyoidea). A diastasis is seen between the hyoid bone and the larynx. The baryum suspension gets into the respiratory pathways, when swallowed

Fig. 2. X-ray photographs of patient B. Consequences of a burn injury of larynx and pharynx caused by an acid. The horizontally situated epiglottis is fixed to posterio-lateral pharyngeal walls by scars. The swallowed barium suspension mostly gets into the respiratory pathways

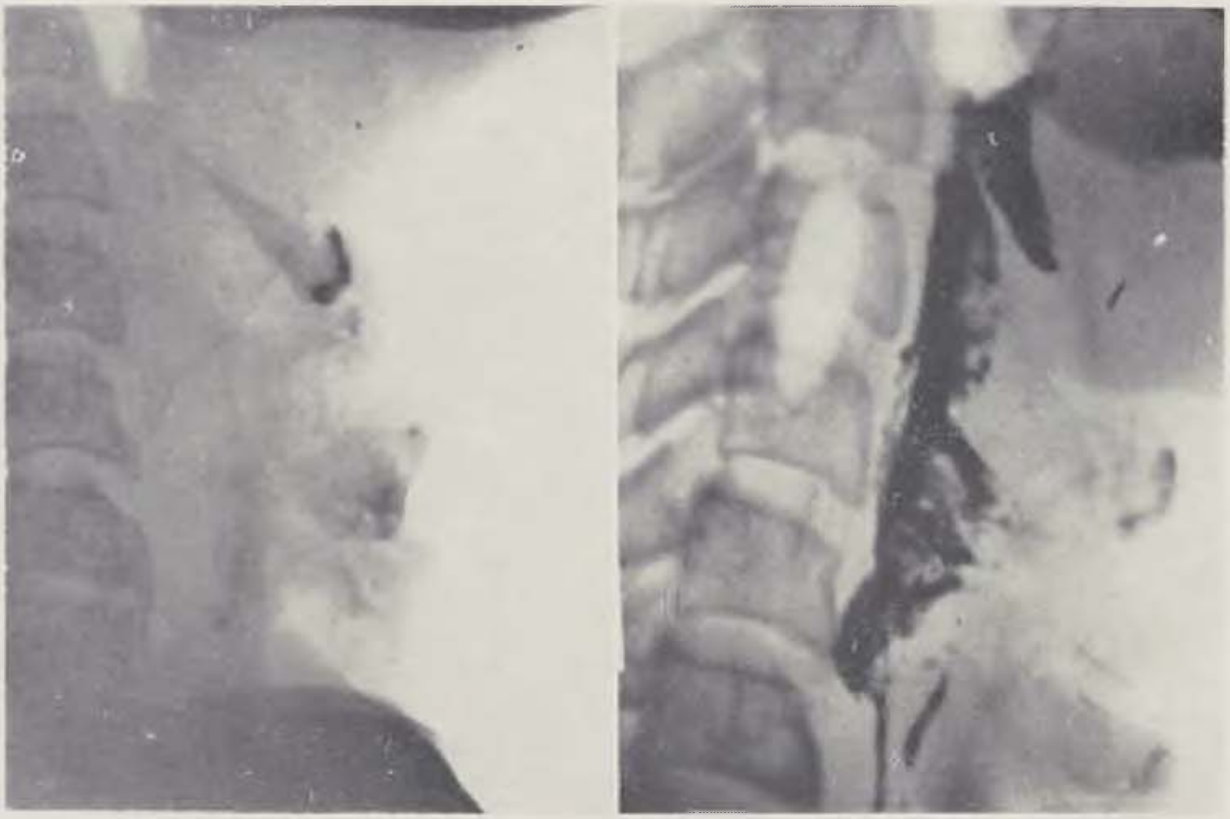

Fig. 5. Results of laryngopexia and epiglottopexia by patient S. The larynx was shifted nearer to the hyoid bone. The distributing function and swallowing were restored (the barium suspension did not get into the respiratory pathways)

Fig. 6. Results of epiglotopexia and reconstruction of pharyngeal relief by patient B. The distributing role and swallowing were restored (the barium suspension was prevented from getting into the respiratory pathways)

Medical Faculty of Hygiene, Charles University, Prague (Czechoslovakia)
Department of Plastic Surgery Burns Unit
Head Prof. MUDr. M. Fára, DrSc.
2nd Department, Institute of Experimental Medicine,
Czechoslovak Academy of Sciences, Prague
Head Prof. MUDr. V. Kusák, CSc.

MAXILLARY DEVELOPMENT IN FACIAL CLEFTS AFTER PRIMARY BONE IMPLANTATION AND AFTER BRIDGING THE GAP WITH A PERIOSTEAL FLAP – A COMPARISON

J. HRIVNÁKOVÁ, M. FÁRA, Ž. MÜLLEROVÁ, J. MĚŠŤÁK

A facial cleft is not just two or more different structures standing apart; there is a real defect of the tissues affected. The most serious manifestations of this inadequacy can be seen in the bones of the maxilla and the palate. In terms of therapeutical results, the gravest bone defect is that in the maxilla or the alveolar process. This is where the gap between the maxillary segments has to be filled — either by the bone growing from their edges or by bone transplantation. However, the gap must never be allowed to be closed as a result of post-operative collapse of the maxilla.

The construction of a free lip with physiologically reconstructed orbicular muscle of the mouth combined with mechanical prevention of the two maxillary segments coming together are important factors for the prevention of maxillary segments compression. There is a variety of orthodontic devices and a number of surgical techniques to serve this purpose. The most significant of these include primary osteoplasty whereby bone from the rib or tibia is implanted while the lip is sutured into the maxillary cleft, or bridging the gap with a periosteal flap taken from the anterior surface of the maxilla.

In an effort to weigh the advantages and disadvantages of the relevant surgical procedures, particularly with a view to the growth and development of the upper jaw, we decided to compare the results of the two methods. Our patients were followed up by means of clinical investigations, X-ray pictures and dental impressions.

A. For bone implants we use full-thickness rib segments about 3 cm long to be inserted into the lower edge of the piriform aperture, i. e. above the alveolar process. The reasons why we choose not to place the implant lower — as other units of plastic surgery do — are as follows:

1. Subperiosteal preparation in the region of the cleft poles may damage rudimentary dentition or else interfere with the growth potentialities of the alveolus,
2. wedging the bone implant between the two alveolar poles may prevent their spontaneous growth which, to a greater or lesser degree, takes place in most cases anyway,

Fig. 1, a, b: Patient I. H., complete right-sided cleft before and after operation with primary bone implantation

3. an implant positioned higher up serves as a supply of bone material for the growth of the hypoplastic cleft poles, thus continuously stimulating their natural growth potential. The alveolar process becomes round-shaped, the teeth cutting along the cleft gap are prevented from turning cranially,
4. an implant positioned in the region of the piriform aperture provides support for the nostril while, at the same time, stimulating the development of the nose. The cover for the bone implant is created with the aid of the rotated mucoperiosteum of the vomer.

The results of primary bone implantation were monitored in 245 patients with the more severe forms of unilateral cleft. In bilateral clefts we refrained from performing this operation for fear that wedging the intermaxilla firmly it might complicate the orthodontic positioning of the bone later on. All the implants were found to have healed in amply with not a single case of rejection.

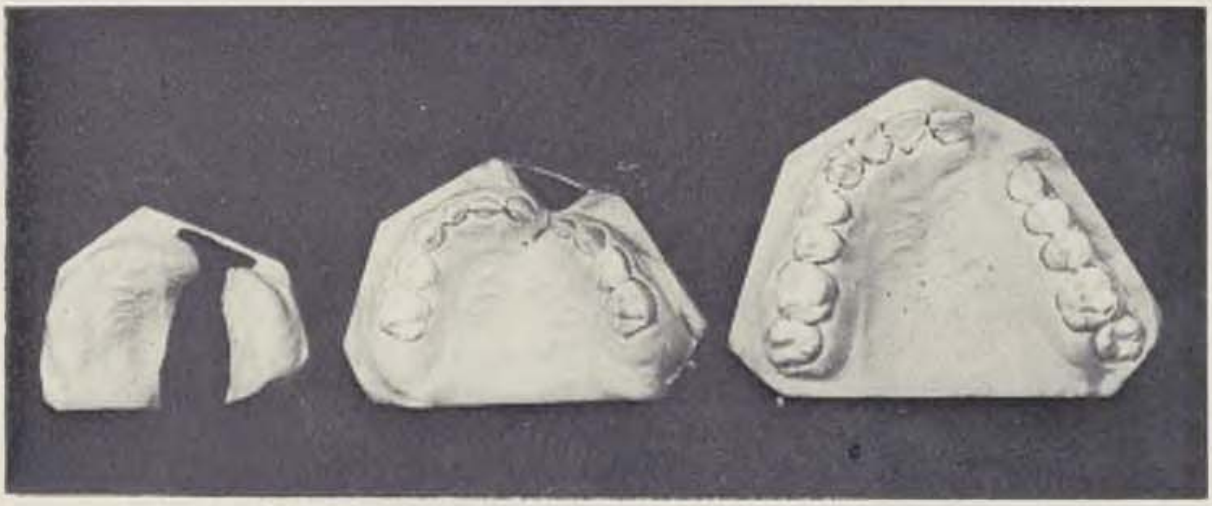

Fig. 2: Patient P. H., complete left-sided cleft with soft bridging. Dental impressions made at 6 months, 5 and half years and 14 years. Orthodontic treatment from the age of 5 years. Bone implantation

This stomatological regard for the effect of primary bone implant on the development of the upper jaw in unilateral clefts yields the following results: there is satisfactory retrusion of the outer cleft pole in the premaxillary region, a factor of favourable influence on the shaping of the alveolar arch. While both poles of the cleft come closer together, the width of the alveolar process at the sites of primary canines becomes somewhat diminished. The width of the alveolar arch at the level of the second deciduous molars remains almost unaltered.

During the primary dentition period, lateral displacement of the external segment persists in a number of cases, a situation often resulting in the buccal non-occlusion of the first and second primary molars on the unaffected side. On the affected side there is defectless occlusion. In a few sporadic cases there is cross bite in the anterior and lateral regions of the primary dentition. The mutual relationship between the two jaws is seldom affected.

Primary suture of the palate results in the shortening and narrowing of the dental and alveolar arches of the maxilla in the overwhelming majority of the patients. Slow, spontaneous normalization is invariably seen in those cases where the lateral displacement of the outer segment persisted prior to surgical operation on the palate. In other words, buccal non. occlusion is a favourable factor as it helps to maintain — until the time of the primary

operation on the palate — the space necessary for the satisfactory arrangement of the width of the upper dental arch and the alveolar process.

To sum up, the use of primary bone implants in patients with unilateral clefts of the lip, maxilla and palate reduces the risk of secondary deformations developing in association with the cleft, mainly in the regions of the upper dental and alveolar arches. Just as in other surgical methods for the recon-

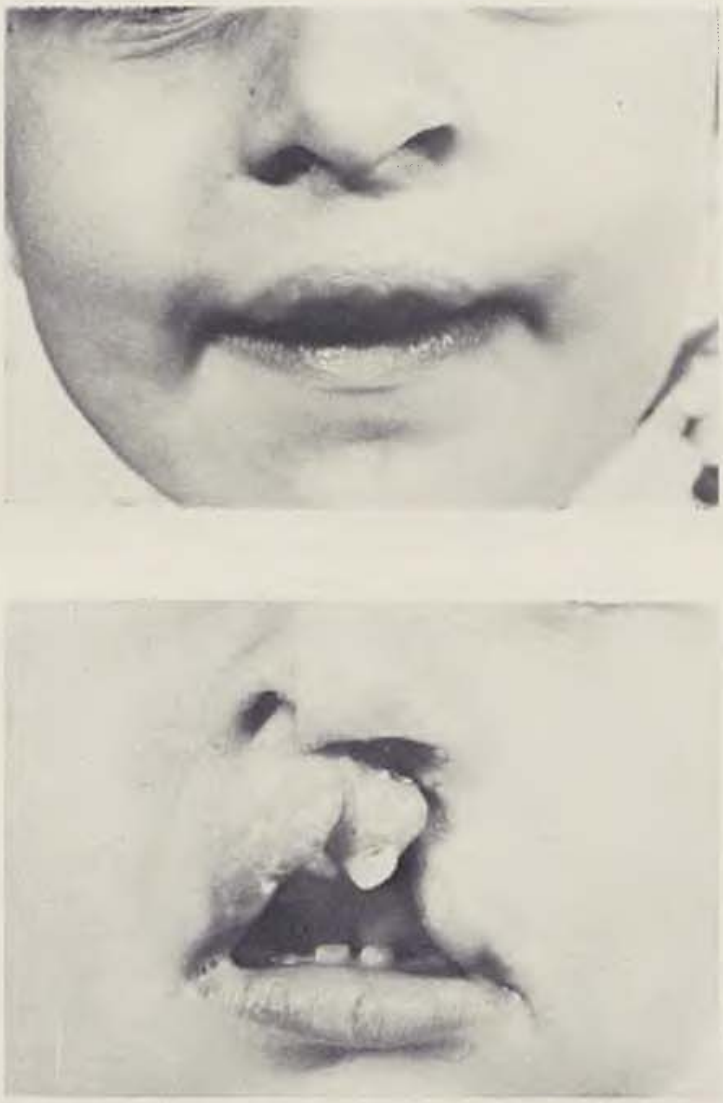

Fig. 3, a, b: Patient J. T., complete left-sided cleft before and after operation using periosteal flap

struction of facial clefts, the dental defect, as a rule, does not start developing until the period of early mixed dentition. Nevertheless, the mutual position of the two jaws usually remains unaffected, and whatever orthodontic anomalies may have developed in the dentoalveolar region are much less severe than those found in cleft-affected patients with no primary bone implant and, in any case, can be eliminated by a course of orthodontic treatment.

B. The technique of bridging the maxillary gap with a periosteal flap raised from the anterior surface of the maxilla as introduced by Skoog is based on the following four conditions:

1. the periosteum covering the maxillary segments is endowed with normal growth potential,
2. the denuded maxillary bone can regenerated normal periosteum like any other bone,



Fig. 4: Patient P. K., complete left-sided cleft. Dental impressions at 7 months, 2 and a half, and 5 years. No orthodontic treatment. Periosteal flap

3. the interaction thus induced between the growth centres of the medial and lateral sides and the biomechanics of the whole region are then co-responsible for a more advantageous growth and development of the united maxilla,
4. ample osteogenic capacity of the periosteum continues until the age of five years; from then on it begins to decline.

The periosteal flap is created substantially narrower since we could see no evidence of the reported regeneration of the periosteum at the site of its raising. The flap is 5 to 7 mm broad and 15 to 2 mm long to reach across the cleft gap. Following its circumcision along the sides and at both ends the flap is rotated by more than 90° round its pedicle situated at the edge of the piriform aperture across the cleft, and then sutured to the premaxillary periosteum. Its size proved sufficient to allow the bridging of the bone cleft along its sides in a matter of several months. The newly formed bone obviously cannot fill all of the gap between the maxillary segments. In our opinion, however, it does have a favourable influence on the maxillary development dynamics in that it ensures a union between the divided maxillary segments — at first elastic, subsequently in the form of a narrow bone lamella. In unilateral clefts there is consequently a more favourable and rapid rounding of the maxillary arch, while bilateral clefts are, as a result, noted for a more

rapid normalization of the interrelationships between the intermaxilla and the lateral maxillary segments.

The results of this technique were followed up in a group of 183 children with facial clefts (140 with unilateral defects — lip, maxilla or lip, maxilla and palate, 43 with bilateral defects) after an elapse of 5 to 7 years from the primary lip suture when the gap was bridged with a periosteal flap.

Fig. 5, a, b: Patient I. H., complete bilateral cleft soft bridged on the right before and after operation using periosteal flap bilaterally

The results appear to warrant the following conclusions: compared with the control group there is a more prominent [illegible]g of the alveolus, no protrusion of the intermaxilla, and the lateral cleft segment is not turned oralward.

There was no evidence of the maxillary growth potential being impaired as a result of raising the periosteal flap.

New bone formation in the region of the inserted periosteal flap was found (by means of X-ray) in 75 % of the cases examined. The thickness of the bone bridge, however, differed from case to case.

Intensive growth of the anterior region of the lateral segment was seen in patients with unilateral clefts. The cleft pole grows to reach its full

size with contact being established between the two segments in most cases, thus permitting mesial migration of teeth of the lateral segment. No new bone formation was demonstrated on the cleft pole of the premaxilla.

From the stomatological point of view, there was no evidence of compression of the upper jaw, in particular of its alveolar process and dental arch. As distinct from the control group, the children's deciduous teeth — even at the beginning of mixed dentition — were noted for a markedly reduced proportion of orthodontic anomalies. If they did occur, they were localized mostly in the dento-alveolar region.

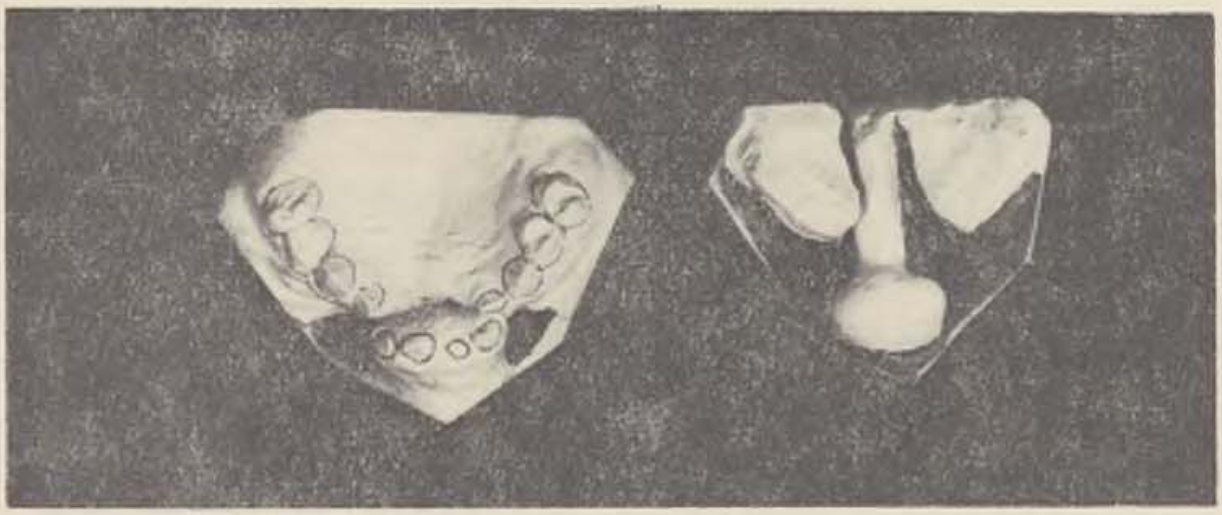

Fig. 6: Patient J. E., complete bilateral cleft. Dental impressions at 8 months and 6 and a half years, no orthodontic treatment. Periosteal flap

In patients with bilateral clefts involving the lip, maxilla and palate, the periosteal flap technique contributes to improving the unfavourable relationships between the three segments of the anomalous maxilla. It has a particularly favourable effect on the intermaxilla where protrusion is gradually eliminated. There is also spontaneous correction of premaxillary asymmetry with regard to the mediosagittal plane of the face.

Bridging facial clefts with periosteal flaps is a simple operation adding only about 5 minutes to the duration of the primary lip suture. Another point: the periosteal flap improves the appearance of both the lip and nose by providing a solid foundation for both structures.

To conclude, our experience stands as evidence that bridging the gap in a cleft maxilla with a periosteal flap produces better overall results than those seen after primary bone implantation or in patients where no bone graft has been used.

J. H.

SUMMARY

In order to compare the relative advantages and disadvantages of primary bone implantation and bridging facial clefts with periosteal flaps, patients of

the two groups were followed up by means of clinical tests, X-ray pictures and dental impressions. Group I consisted of 245 patients with the more severe forms of unilateral facial cleft, group II was formed by 140 patients with unilateral clefts and 43 patients with bilateral clefts. Distinctly better overall results were obtained with the periosteal flap technique than in patients after primary bone implantation or in those where no bone graft had been used.

RESUME

Les divisions au visage traitées par l'implantation osseuse primaire ou voûtées par une lobule périostée. Comparaison du développement du maxilaire supérieur.

Hrivnáková, J., Fára, M., Müllerová, Ž., Měšťák, J.

Les auteurs ont comparé des avantages et des inconvénients du traitement qui consistait soit en implantation osseuse primaire, soit en voûter la division par une lobule périostée. On a profité de plusieurs méthodes d'examens cliniques, de la radiographie et des modèles de la denture.

Premier groupe examiné comptait 245 malades avec de graves divisions unilatérales, le second groupe 140 malades avec la division unilatérale et 43 malades avec la division bilatérale. L'utilisation d'une lobule périostée a apporté, en somme, les résultats considérablement meilleurs que la méthode de l'implantation osseuse primaire ou que le traitement sans greffe osseuse.

ZUSAMMENFASSUNG

Ein Vergleich der Entwicklung des Oberkiefers bei Gesichtsspaltungen nach primärer Knochenimplantation und nach Überbrücken der Spalte durch ein Periostalläppchen

Hrivnáková, J., Fára, M., Müllerová, Ž., Měšťák, J.

Zwecks eines Vergleichs der Vor- und Nachteile einer primären Knochenimplantation und einem Überbrücken der Spalte durch ein Periostalläppchen wurden die Patienten beider dieser Gruppen mittels klinischer Untersuchungen, Roentgenaufnahmen und Gebissmodellen beobachtet. Die erste Gruppe bestand aus 245 Patienten mit schwerwiegenderen Formen einer einseitigen Spaltung, die zweite Gruppe aus 140 Patienten mit einseitiger und 43 Patienten mit doppelseitiger Spaltung. Deutlich bessere komplexe Ergebnisse zeitigte die Anwendung des Periostalläppchens als die primäre Knochenimplantation oder als die Patienten ohne Knochentransplantat.

RESUMEN

Comparación de la evolución de la mandíbula superior en las fisuras faciales después de la implantación óstea primaria y la cobertura de la fisión con lobulito periostal.

Hrivnáková, J., Fára, M., Müllerová, Ž., Měšťák, J.

Para poder comparar las ventajas y desventajas de la implantación ostea primaria de un lado y de la cobertura de la fisura por un lobulito periostal del otro, pacientes en ambos grupos fueron sometidos a exámenes clínicos con ayuda de rayos X y modelos de dentaduras. El primer grupo fue integrado por 245 pacientes con fisura uni-

lateral de formas más bien graves, el segundo por 140 pacientes con fisura unilateral y 43 pacientes con fisura bilateral. Se pudo observar resultados complejos obviamente mejores en el uso del lobulito periostal que en consecuencia de la implantación ostea primaria o en los pacientes sin implante ósteo.

REFERENCES

1. **Fára, M.**: Principles of Physiological Approach to Comprehensive Treatment in Facial Clefts (in Czech). Rozhl. Chir., 52, 7 : 439, 1973.
2. **Fára, M.**: Functional Anatomy of Lip and Palate and Its Application to Cleft Lip and Palate Surgery. Recent Advances in Plastic Surgery. Churchill Livingstone, Edinburgh, 1981, p. 145.
3. **Hrivnáková, J., Fára, M., Müllerová, Ž.**: The Use of Periosteal Flaps for Bridging Maxillary Defects in Facial Clefts. Acta Chir. plast., 23, 3, 130, 1981.
4. **Skoog, T.**: Skoog's Methods of Repair of Unilateral and Bilateral Cleft Lip. Cleft Lip and Palate, Ed. W. C. Crabb, S. W. Rosenstein and R. R. Bzoch. Little, Brown and Co., Boston, 1971, p. 288.

Dr. J. Hrivnáková, Šrobárova 50, 100 00 Prague 10, Czechoslovakia

Bulgarian Medical Academy — Medical Faculty, Varna (Bulgaria)
Chair of Surgical Propedeutics
Head As. Prof. M. Genova, M. D., CSc.

SKIN PLASTIC OPERATION FOR SPINA BIFIDA

K. TROSHEV

Spina bifida is rather rarely encountered by the plastic surgeon. Children with this type of congenital defect are hospitalized at departments of neurosurgery (3). The plastic surgeon has no major say in rating the degree of operability but it is up to him to decide the problem of plastic operation for large skin defects (3, 9).

There are a number of moot points as regards therapy for spina bifida (9): whether or not every case calls for surgery, the timing of the operation, and the type of surgical technique to be chosen. Regardless of size, a skin defect is no surgical contraindication. Thanks to progress in neurosurgery and rehabilitation care, there is no such thing as contraindication for surgical operation in uncomplicated meningomeylocele. For that reason, from the point of view of present-day human medicine, we regard as unsubstantiated any disputes concerning the operability of uncomplicated cases of spina bifida.

An early operation has its reasons and advantages as it reduces the number of cases involving meningitis, helps to preserve muscular strength and protects the nervous tissue against drying out in cases of sac perforation. An early removal of the congenital defect is of great importance for the psychic state of the parents and the rest of the family who then go on looking after the child with increased élan and hope. Early operation is taken to mean surgery performed within two days of birth, which is hardly any problem now with a view to the potentialities of present-day anaesthesiology.

Then there is the problem of choosing the appropriate surgical technique. The opening moves are essentially standard (9) — with excision of the sac and skin edges, and with the open spinal canal being covered by means of fascial plastic operation from the neighbourhood using two juxtaposed flaps to give shape to a new spinal canal. Additional strength can be given by overlapping with the adjacent dorsal muscles (8).

The skin cover can be constructed in several ways. The simplest and the most frequently used is the direct suture of the edges of the elliptic skin wound previously widely mobilized sideways to reduce skin tension. The neurosurgeon himself will decide whether or not the myelomeningocele size pre-

cludes the use of direct suture. In cases like those the plastic surgeon's co-operation is not called for (1, 3, 9).

In an effort to use homogeneous neighbouring tissues, relief incisions are made running parallel to the wound to help construct bipedicled vertical (9, 10, 11) or horizontal (5) skin flaps. In some cases the length of the flaps may reach from the shoulder blade down to the gluteal sulcus (3). The donor wound thus made lateral to the flap is wide and requires autologous skin mesh-graft for covering (3). Some authors include dorsal muscles in the flap. The lateral defect sites are subject to considerable deformation even if they are covered with skin.

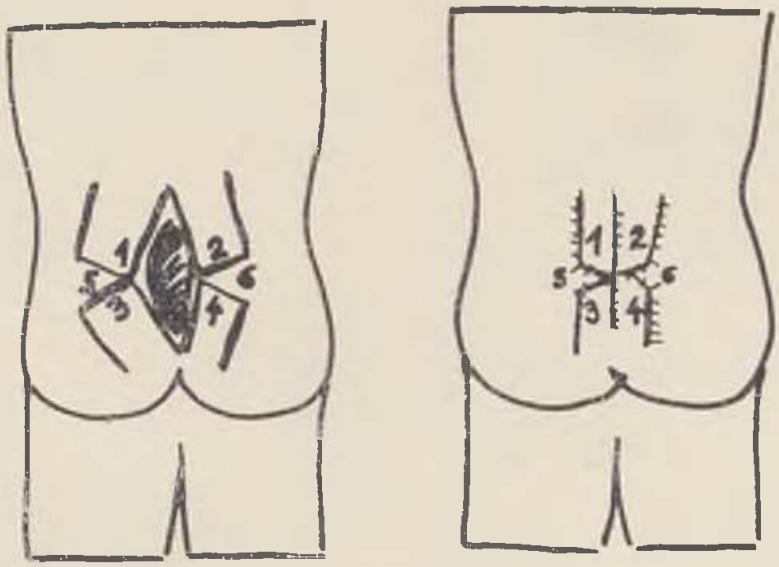

Fig. 1. Scheme of operation

A free skin autograft can be used independently for the direct coverage of the central skin defect (7). This, however, is not safe enough as the donor site open wound represents another surgical trauma for the neonate.

A pedicle flap mobilized from the neighbourhood is a convenient method though not particularly well suited for large skin defects where, in turn, the donor site has to be covered with a free skin autograft in spite of all its disadvantages.

The use of a double L-shaped flap is no longer recommended either (9).

The above described circumstances made it necessary to devise a surgical technique whereby the skin defect could be covered with good-quality skin complete with the subcutis from the surrounding area regardless of the size of the skin defect.

Surgical technique. To remove meningomyelocele we perform a lozenge-shaped excizion bordering on intact skin. Four rectangular and two triangular pedicle flaps are then created in the adjacent region with each side of the

lozenge forming the side of the adjacent rectangular flap. Then we measure the distance between the extreme points of the lozenge and its centre to be projected perpendicularly to each side of the lozenge. The resulting rectangular flaps have proximal or distal pedicles. In creating them we observe the basic rule which lays down that their width-to-length ratio should be 1:2 (Fig 1). The rectangular flaps and the skin neighbouring on them are mobilized widely sideways with efforts being made to arrest bleeding. The flaps are then transferred to cover the skin defect, and their edges are sutured. In the neighbourhood, rubber drains are left in position for up to 48 hours.

Fig. 2. State before operation. — Fig. 3. Flaps drawn prior to surgery

In our opinion, it is not necessary for the child to be kept in a special position during the post-operative period as recommended by some authors (9).

So long as there is uncomplicated wound healing, the stitches can be removed after 10 to 11 days.

Marginal necrosis may develop in cases of imprecise flap delineation and dehiscence. if the process of healing is complicated by liquorrhoea, or in cases of insufficient closure of the spinal cord canal during the first stage of the operation.

During the past period, we were able to use the above described method of skin plastic operation in 9 neonates, all of them with good results (Fig. 1, 2, 3).

Fig. 4. Resultant state at the end of operation

Our experience seems to justify our preference for the above described surgical method (patented as invention N 28089/March 14, 1980), and warrant its recommendation for routine skin plastic operations in the treatment of spina bifida.

J. H.

SUMMARY

The author analyzes moot points in the treatment of spina bifida and method of plastic operation for skin defect coverage with references to the inadequacies of the conventional methods.

He describes a method of his own involving skin plastic operation whereby four rectangular and two triangular pedicle flaps from the adjacent area can cover any skin defect in spina bifida regardless of its size.

In the past few years, the author used this method to operate on 9 neonates in the first few postnatal days with the skin plastic operations bringing satisfactory results. He, therefore, recommends his method for routine use in skin plastic operations for the treatment of spina bifida.

RESUME

La plastie cutanée après l'opération du spina-bifida

Trochev, K.

L'auteur analyse des questions litigieuses du traitement du spina-bifida aussi que

de la méthode du recouvrement plastique d'un défaut cutané. Il avertit aux indigences des méthodes fréquemment utilisées.

L'auteur décrit la méthode* d'une opération plastique cutanée qui permet recouvrir des défauts cutanés du spina-bifida quoi qu'ils soient vastes par six lambeaux pédiculés de voisinage: 4 lambeaux rectangulaires et 2 lambeaux triangulaires.

Pendant les dernières années, l'auteur a utilisé la méthode chez 9 enfants, opérés dans les premiers jours de vie, avec de très bons résultats des plasties cutanées. Il recommende utiliser couramment sa méthode des plasties cutanées en traitement opératoire du spina-bifida.

ZUSAMMENFASSUNG

Eine plastische Hautoperation der Spina bifida

Troschev, K.

Der Autor analysiert strittige Fragen bei der Behandlung einer Spina bifida sowie die Methoden einer plastischen Deckung des Hautdefekts. Er verweist auf die Mängel der angewendeten Methoden.

Ferner beschreibt er die Methode* einer plastischen Hautoperation, mit deren Hilfe man mit vier rechteckigen und zwei dreieckigen Lappen am Stiel aus der Umgebung jeden Hautdefekt bei der Spina bifida unabhängig von seiner Grösse decken kann.

In den letzten Jahren hat der Autor mit Hilfe dieser Methode 9 Kinder in den ersten Tagen nach der Geburt mit guten Ergebnissen der plastischen Hautoperationen operiert. Er empfiehlt daher seine Methode zur laufenden Anwendung in der plastischen Hautoperationstechnik bei der Behandlung einer Spina bifida.

RESUMEN

Operación plástica dérmica de la espina bífida

Troshev, K.

El autor analiza los puntos problemáticos en el tratamiento de la espina bífida así como métodos de cobertura plástica del defecto dérmico. Señala las deficiencias de los métodos utilizados.

Describe el método* de operación plástica dérmica que posibilita que sea cubierto, independientemente de su tamaño, cada defecto dérmico en la espina bífida utilizándose cuatro lóbulos rectangulares y dos triangulares sobre pecíolo.

En los últimos años el autor ha implementado este método en las operaciones de 9 niños en los primeros días después del parto logrando buenos resultados. Por tanto recomienda que su método sea utilizado corrientemente en la práctica operacional dermoplástica en el tratamiento de la espina bífida.

REFERENCES

1. **Boitchev**, B.: Operative Surgery, t. VI, 1965, 546—547, MF — Sofia (in Bulgarian).

2. **Blaiklock, C. R., Demetrion, E. L., Reyner, C. R. W.**: The Use of a Latissimus Dorsi Myocutaneous Flap in the Repair of Spinal Defects in Spina Bifida. Brit. J. plast. Surg., 34 : 358, 1981.

3. **Deprez, J. D., Kiehn, C. L., Eckstein, W.**: Closure of Large Meningomyelocele Defects by Composite Skin-Muscle Flaps. Plast, reconstr. Surg., 47, 3 : 234, 1971.

4. **Davies, D., Adendorf, D.**: A Large Rotational Flap Raised Across the Midline to Close Lumbosacral Defects. Brit J. plast. Surg., 30, 1663, 1977.

5. **Hill, M. L. et al.**: The Transverse Lumbosacral Back Flap. Plast. reconstr. Surg., 62,2 : 177, 1978.

6. **Madzidov, N. M., Dusmuratov, M., Kurbanov, N. M.**: Congenital Meningocele. Tashkent, Medicine, 1981 (in Russian).

7. **Mustardé, J. C.**: Meningomyelocele — the Problem of Skin Coverage. Brit. J. Surg., 53 : 36, 1966.

8. **Mustardé, J. C.**: Reconstruction of the Spinal Canal in Severe Spina Bifida. Plast. reconstr. Surg., 42, 2 : 109, 1968.

9. **Pap, G. S., Grulee, C. G.**: Repair of Dorsal Myelomeningocele. Acta Chir. plast., 21, 1 : 28, 1979.

10. **Salasin, R. I., Briggs, R. M.**: Closure of a Large Myelomeningocele. Plast reconstr. Surg., 51, 4 : 464, 1973.

11. **Zook, E. G., Dzenitis, A. J., Bennett, J. E.**: Repair of Large Myelomeningoceles. Arch. Surg., 98, 41, 1969.

Dr. K. Troshev, Bulgarian Medical Academy, Medical Faculty, Varna, Bulgaria

Petényi Sándor Hospital, Budapest (Hungary)
Department of Plastic Surgery

LATISSIMUS DORSI MUSCULOCUTANEOUS ISLAND FLAP FOR THE RECONSTRUCTION OF SOFT TISSUE DEFECTS OF THE UPPER ARM

G. GULYÁS, I. KARTIK, L. TAKÁCS

Different methods can be used for the reconstruction of large and deep soft tissue defects of the upper arm, ranging from local flap rotation to microvascular free flap transplantation. A well chosen flap saves the deep structures, is large enough, adequate in skin colour and sensibility and technically safe, and provides better blood supply.

The latissimus dorsi muscle or musclulocutaneous flap has recently been developed into a most versatile flap for the reconstruction of the chest, neck and arms, and it is available as one of the most useful free flaps. It was first used for breast reconstruction following mastectomy by Iginio Tansisi in 1896 (6). Reports describing its anatomy and blood supply have been published by many authors (1, 2, 3, 4, 5). We obtained the best functional and aesthetic results with the latissimus dorsi musculocutaneous island flap for the reconstruction of the dorsal surface of the upper arm.

Fig. 1a. The design of the latissimus dorsi musculocutaneous island flap

CASE REPORT

A 42-year old women presented with an unstable scar on the left upper arm following a lacerated injury and radial nerve damage. The skin loss had been repaired with split-skin grafts but the nerve had not been reconstructed.

Fig. 1b. Elevation of the flap

Fig. 1c. Flap in position. — Fig. 1d. Flap and donor site 10 days post-operatively

The scar adhered to the dorsal surface of the humerus. The area of total destruction was 29×6—9 cm. An innervated latissimus dorsi musculocutaneous island flap was designed (Fig. 1a) and an island flap strip 26 cm long and 9 cm broad was created (Fig. 1b). After identifying the vessels and nerve (thoracodorsal artery, vein and nerve) the flap was passed through a tunnel to the upper arm (Fig. 1c). Circulation in the flap was excellent. The previously grafted skin was removed, and fascicular radial nerve repair performed under microscope. The flap was sutured in position, and the donor site was closed immediately.

The post-operative course was uneventful (Fig. 1d). During the six-month follow-up period, the patient was able to use her arm well, and regeneration of the radial nerved (checked by EMG) was progressing well.

DISCUSSION

Local flaps will rarely do for the adequate treatment of large and deep soft tissue defects in the upper arm.

The axial pattern flaps — pedicled or of the island type — provide satisfactory functional and aesthetic results. If the surrounding tissues do not fit, we prefer island flaps from distant areas or microvascular free flap transplantation. The latissimus dorsi musculocutaneous island flap has excellent blood supply, it is large enough to reach the distal part of the upper arm, technically simple and safe. For those reasons, we propose its use for the reconstruction of upper arm defects.

J. H.

SUMMARY

The latissimus dorsi musculocutaneous island flap is recommended for reconstruction of the dorsal surface of the upper arm.

RESUME

Lobe libre dermo-musculaire du muscle latissimus dorsi comme matériel reconstructif des défauts du tissu mou au membre supérieur

Gulyás, G., Kartik, I., Takács, L.

Les auteurs recommendent l'utilisation d'un lobe libre dermo-musculaire latissimus dorsi pour les reconstructions des téguments dorsals au membre supérieur.

ZUSAMMENFASSUNG

Der freie Hautmuskellappen des M. latissimus dorsi für eine Rekonstruktion der Defekte der Weichteile des oberen Gliedmasses

Gulyás, G., Kartik, I., Takács, L.

Zur Rekonstruktion der dorsalen Oberfläche des oberen Teils des Oberarms wird empfohlen, den freien Hautmuskellappen des M. latissimus dorsi zu verwenden.

RESUMEN

Lóbulo libre dermomuscular m. latissimus dorsi para la reconstrucción de defectos de tejidos blandos de la extremidad superior

Gulyás, G., Kartik, I., Takács, L.

Se recomienda utilizar un lóbulo libre dermomuscular latissimus dorsi para la reconstrucción de la superficie dorsal de la parte superior del brazo.

REFERENCES

1. **Daniel, R. K., Terzis, J. K.:** Reconstructive Microsurgery. Little, Brown and Company, Boston, 1977.

2. **Daniller, A. I., Strauch, B.:** Symposium on Microsurgery. The C. V. Mosby Co. St. Louis 1976.

3. **Mathes, S. J., Nahai, F.:** Clinical Atlas of Muscle and Musculocutaneous Flaps. The C. V. Mosby Co., St. Louis, 1976.

4. **Tansisi, I.:** Nuovo processo per l'amputazione della mammaella per cancere. Reforma méd., 12 : 3, 1896.

5. **Olivari, N.:** The Latissimus Flap. Brit. J. plast. Surg., 29 : 126, 1976.

6. **Maxwell, G. P., Manson, P. N., Holpes, J. E.:** Experience with Thirteen Latissimus Dorsi Myocutaneous Free Flaps. Plast. reconstr. Surg., 64 : 1, 1979.

G. Gulyás, M. D., Gellérthegy u. 23, Budapest, 1016, Hungary

Toho University School of Medicine, Tokyo (Japan)
Department of Plastic and Reconstructive Surgery
Head Y. Maruyama, M. D.
Second Department of Surgery
Chairman S. Takeuchi, M. D.

FUNCTIONAL RECONSTRUCTION OF ANAL CONSTRICTION USING A GRACILIS MUSCULOCUTANEOUS FLAP

Y. MARUYAMA, K. OHNISHI, C. HASHIMURA

Anal constriction and incontinence resulting from surgical treatment for haemorrhoids or anal fistulae are rare but distressing complications.

The following is a report on the use of gracilis musculocutaneous island flap for the repair of anal constriction and for improving rectal sphincter action.

Pickrell (1954) described the reconstruction of rectal sphincter using a gracilis muscle transplant. Several authors have reported the use of gracilis myocutaneous flap for the reconstruction of the penis (Orticochea 1972), for the repair of ischial pressure sores (Wingate 1978), for vaginal reconstruction (McCraw 1976), and as a free flap (Harii et al. 1976). Of late, the myocutaneous flap has also added new dimensions to the field of functional reconstruction (6—9).

CASE REPORT

A 68-year woman had had several surgical operations for haemorrhoids and anal fistulae, the tretment resulting in severe anal constriction.

She had also undergone a reconstructive operation with a sliding graft but without much success. Finally, she had permanent colostomy constructed due to obstructive ileus 2 years ago.

We felt we should provide adequate coverage and try and improve her rectal sphincter action by repairing her anal constriction (it was difficult to pass a 5-mm-diameter dilator through the constriction).

To meet all the requirements, we decided to use a gracilis myocutaneous flap. Under general anaesthesia, an incision was made towards the constriction creating a 4 by 5 cm defect. The gracilis myocutaneous flap was then elevated from its distal end.

The small vascular branches from the femoral vessels were ligated. The main supplying vessels originating from the deep femoral artery were identified between the adductor longus and adductor brevis muscles, and traced proximally. The proximal attachment was left intact.

The viability of the flap was tested with fluorescein intravenously.

A subcutaneous tunnel was made under the skin bridge to the anal defect. Then the flap was trimmed to the size of the defect, and all excess skin was removed. The distal muscle portion was sutured to the opposite levator muscle to provide sphincter action. The donor site defect was closed by means of primary suture. Post-operatively, there was a slight wound infection, but on the whole the flap healed in well with any necrosis. The patient's colostomy was closed three months after this surgery, and now she has no inconvenience in her daily life, and feels satisfied with the result.

Fig. 1a. Ano-perineal defect after a 7-o'clock icision

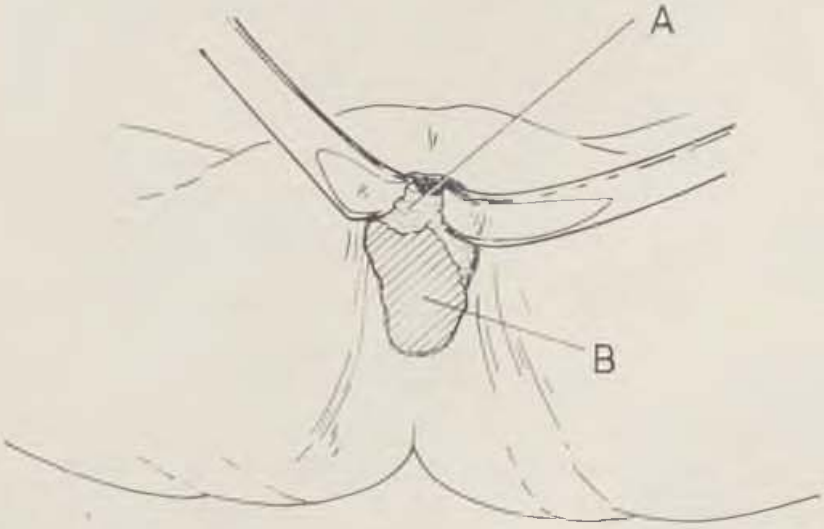

Fig. 1b. Scheme: A — rectal mucosa, B — ano-perineal defect

DISCUSSION

Though rare, anal constriction and incontinence following surgical treatment for haemorrhoids or fistulae can cause considerable d stress to the victim.

Fig. 2a. Design and elevation of the gracilis myocutaneous flap

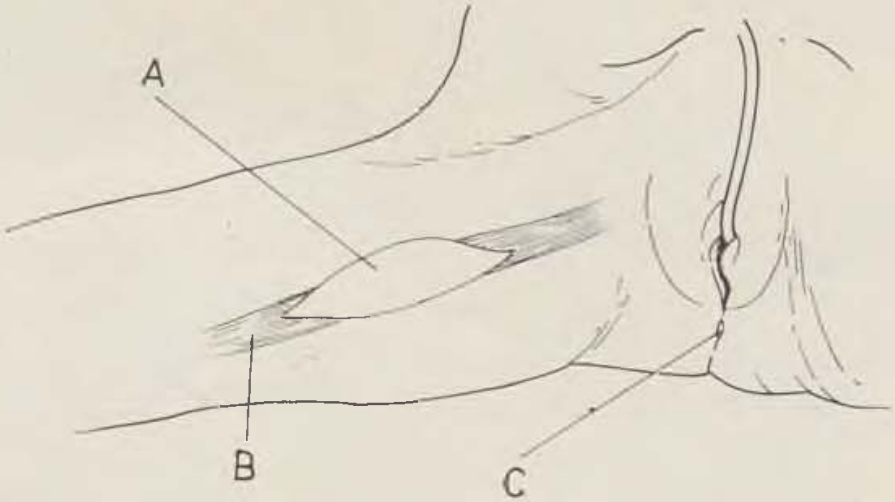

Fig. 2b. Scheme: gracilis myocutaneous flap is elevated from the distal end vascula pedicles, and proximal attachement is left intact. A — gracilis musculocutaneous skin flap, B — gracilis muscle, C — constricted anus

While it has a firm position in the field of anal reconstructive surgery, Whitehead's operation may sometimes develop into anal constriction or the so called Whitehead deformity. In 1937, Milligan and Morgan described the detailed surgical anatomy of the anal canal as well as their surgical treatment for haemorrhoids. This ligation excision technique is now widely used by many surgeons, and the rate of complications has decreased.

However, the complication does occur still. In fact, many procedures for the repair of constrictions have been developed and described, such as the sliding graft, the pedicle skin graft, and S-plasty.

Pickrell reported good results with the construction of the rectal sphincter using gracilis muscle transplants. The gracilis myocutaneous flap is now well established as a reliable and versatile flap in its rotation arch.

With these myocutaneous flaps, functional reconstruction is now feasible.

We had a case, in which the gracilis myocutaneous flap was used with good results for the repair of anal constriction, for covering the defect and for improving rectal sphincter action.

J. H.

Fig. 3a. The flap is trimmed to size, and introduced to the defect through a subcutaneous tunnel

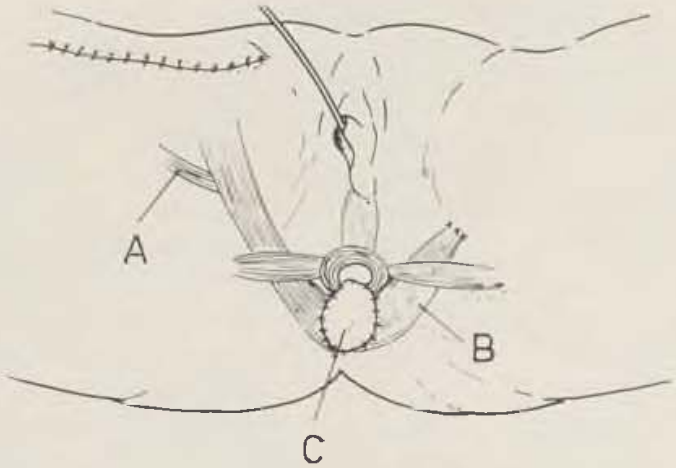

Fig. 3b. Scheme: The distal muscle portion is sutured to the opposite levator muscle. A — vascular pedicle, B — gracilis muscle, C — gracilis musculocutaneous flap

SUMMARY

A case is reported, in which a gracilis musculocutaneous flap was used for the reconstruction of anal constriction and for the restoration of rectal sphincter action. The patient now enjoys fuctionally satisfactory results while the functional loss of part of the gracilis muscle goes unnoticed in her daily life.

RESUME

La reconstruction fonctionnelle de la constriction anale en utilisant un lobe dermo-musculaire du muscle gracilis

Maruyama, Y., Ohnishi, K., Hashimura, C.

On a décrit l'utilisation du lobe dermo-musculaire du muscle gracilis pour reconstruire la constriction anale et pour rétablir la fonction du sphincter rectal chez une malade. Celle-là est complètement contente des résultats fonctionnels; elle ne souffre point par l'absence fonctionnelle du muscle gracilis.

ZUSAMMENFASSUNG

Die Funktionsrekonstruktion einer Analkonstriktion unter Anwendung eines Hautmuskellappens des M. gracilis

Maruyama, Y., Ohnishi, K., Hashimura, C.

Es wird die Anwendung eines Hautmuskellappens des M. gracilis zur Rekonstruktion einer Analkonstriktion und zur Erneuerung der Funktion des Rektalsphinkters beschrieben. Die Patientin ist mit den funktionsmässig zufriedenstellenden Ergebnissen zufrieden, und der Funktionsverlust des M. gracilis wirkt sich in ihrem täglichen Leben überhaupt nicht aus.

RESUMEN

Reconstrucción funcional de la constricción anal con la utilización del lóbulo dermomuscular m. gracilis

Maruyama, Y., Ohnishi, K., Hashimura, C.

Se describe la utilización del lóbulo dermomuscular m. gracilis para la reconstrucción de la constricción anal y para la renovación de la función faltante del esfínter rectal; la paciente se siente satisfecha con los resultados funcionalmente satisfactorios mientras que la pérdida funcional del m. gracilis no tiene consecuencias negativas en su vida diaria.

REFERENCES

1. **Pickrell, K., Masters, F., Georgiade, N., Norton, C.**: Rectal Sphincter Reconstruction Using a Gracilis Muscle Trans plant. Plast. reconstr. Surg., 13 : 46, 1956.

2. **Orticochea, M.**: A New Method for Total Reconstruction of the Penis. Brit. J. plast. Surg., 25 : 347, 1972.

3. **McCraw, J. B., Massey, F. M., Shanklin, K. D., Horton, C. E.**: Vaginal Reconstruction with Gracilis Myocutaneous Flaps. Plast. reconstr. Surg., 58 : 176, 1976.

4. **Wingate, G. B., Friedlond, J. A.**: Repair of Ischial Pressure Sores with Gracilis Myocutaneous Island Flaps. Plast. reconstr. Surg., 62 : 245, 1978.

5. **Harii, K., Ohmori, K.**: The Free Musculocutaneous Flap. Plast. reconstr. Surg., 57 : 294, 1976.

6. **Maruyama, Y., Nakajima, H., Fossati, E., Fujino, T.**: Free Latissimus Dorsi Myocutaneous Flaps in the Dynamic Reconstruction of Cheek Defects. Journal of Microsurgery, Nov./Dec. 231, 1979.

7. **Maruyama, Y., Nakajima, H., Fujino, T.**: A Dynamic Reconstruction of a Facial Defect with a Pectoralis Major Myocutaneous Flap. Brit. J. plast. Surg., 33 : 145, 1980.

8. **Maruyama, Y., Yoshimura, Y., Sawada, Y., Fujino, T.**: A Lower Trapezius Myocutaneous Free Flap in Facial Reconstruction. Journal of Microsurgery, Mar. 214, 1981.

9. **Fujino, T., Maruyama, Y., Yoshimura, Y.**: Primary Functional Cheek Reconstruction. Brit. J. plast. Surg., 34 : 136, 1981.

Y. Maruyama, M. D., Dept. of Plast. nad Reconstr. Surgery, Toho University School of Medicine, 6-11-1 Ohta-ku, Ohmorinishi Tokyo 143, Japan

The 1st Regional Clinic of Kursk, Kursk (USSR)
Director L. I. Beschodarnyj
Department of Maxillofacial Surgery
Head S. D. Sidorov

THE TUBED FLAP IN PLASTY OF EXTENDED RESECTIONS OF THE LOWER PART OF THE FACE

S. D. SIDOROV

Improved techniques of surgical removal of affected tissues and improvement of the methods used for reconstruction of organs injured by surgical interventions are two basic requirements for successful treatment of spread malignant lesions of the oral cavity, face and neck (Chitrov, 1954; Jevdokimov and Lanjuk, 1962; Sidorov, 1970, 1971, 1978, 1980; Patches, 1971; Dunajevskij, 1976; Vonemoto et al., 1972; Jakobson et al., 1973; Harrold, 1971; Karrolli, 1952 and others).

MATERIAL AND METHODS

Our conclusions are based on observation of 31 patients with penetrating defects of the lower part of the face. The defects originated from wide resections of spread carcinomas of the oral cavity and tongue and of carcinomas of the lower lip metastasing into the mandibular body and cervical lymph nodes. The patients (22 males, 9 females) were aged from 20 to 61 years. In 23 cases the surgery was combined with radiotherapy and chemotherapy.

Radical surgical interventions, performed under endotracheal anaesthesia (in 88 % of cases via the tracheostomy), aimed at complete or partial removing of all the affected tissues and of cervical lymph nodes as well.

Postoperative penetrating defects arose from total or partial loss of: the floor of the mouth and tongue (2 cases); the floor of the mouth, tongue and mandible (5 cases); the floor of the mouth, mandible and cheek (3 cases); the floor of the mouth, tongue, mandible and cheek (3 cases); the floor of the mouth, lateral wall of the pharynx, mandible and cheek (6 cases).

Pedicle flaps were used for reconstruction of the oral cavity walls. A single-pedicle flap was used in 12 cases, a double-pedicle flap in 17 cases and a trilobed pedicle flap in 2 cases. The flaps were formed 3 to 5 weeks after radical interventions, depending on the postoperative conditions of individual patients.

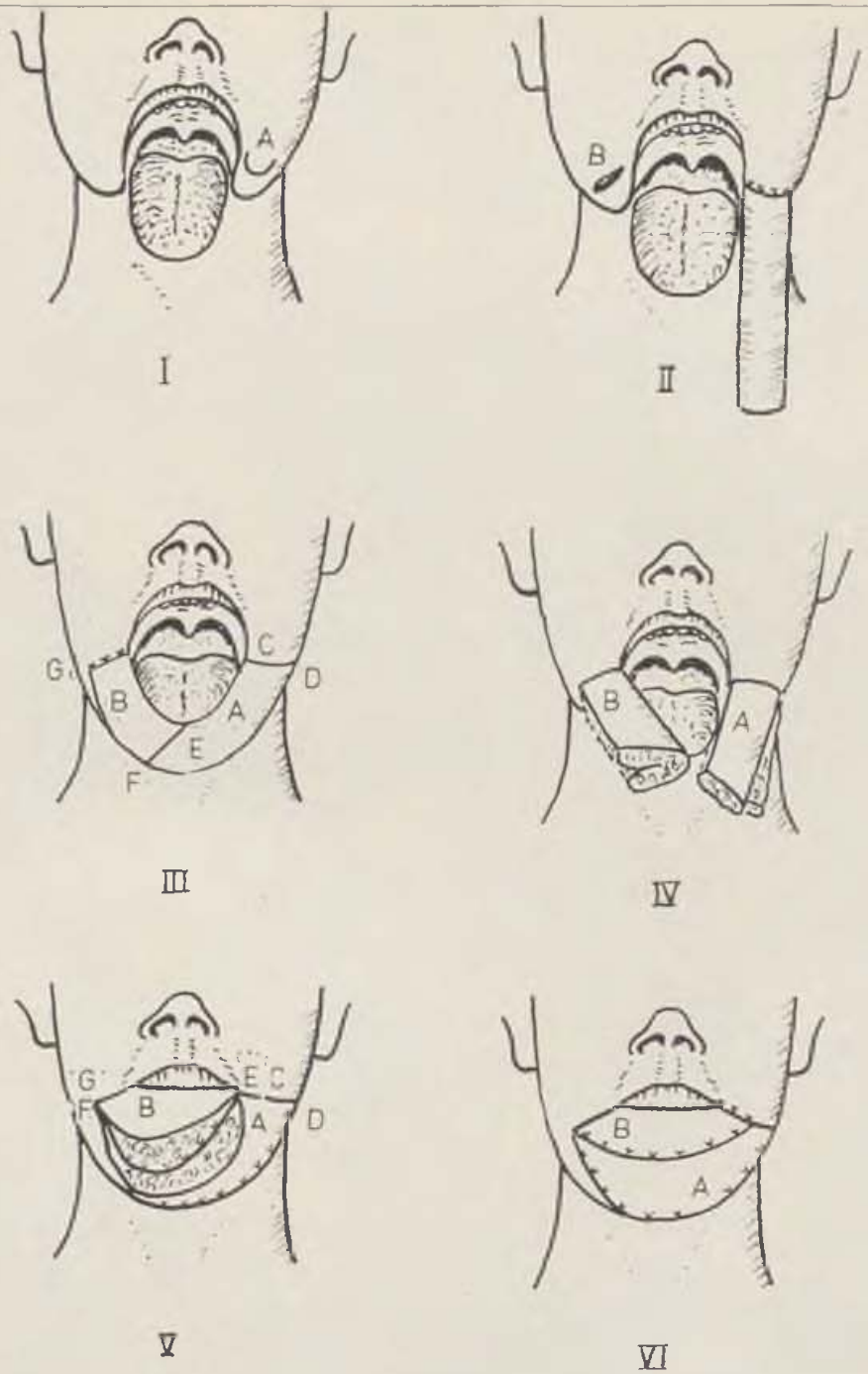

Figure 1. Reconstruction of the lower part of the face using the tubed flap. I. The line of insertion (A) of the distal part of the flap. II. The distal part of the pedicle is inserted into posterior buccal margin of the defect (B-outlines of the area to be covered by the medial pedicle). III. The flap is completely transferred to the margins of the defect. E, F — the line of oblique transection dividing the flap into two parts. C, E and D, F — lengthwise division of the distal part (A) of the flap, F, G— lengthwise dissection for removing of excessive material from the medial part (B) of the flap. IV. Both parts of the flap (A and B) are transformed into two strips. V. The manner in which both strips are opposed side to side (lines G, F and C, E) and used for epithelial lining of the floor of the mouth, lower lip and part of the cheek. The superficial flaps are slightly lifted. VI. Formation of the outer covering of the mouth floor, chin, lower lip and part of the cheek

The method of closing the defects of the lower part of the face is based on wide spreading of one or two pedicles inserted into the opposite margins of the defects. All defects of the oral cavity, mandible, chin and cheeks were closed in one step. With regard to specific circumstances of each plasty, the flap was divided by an oblique or stepwise transection into two parts. The two resulting flap strips were used simultaneously for both internal and external epithelial lining of the oral cavity walls (Fig. 1). Later on, if necessary, the treatment continued with mandible plasty using an autograft from the rib (11 cases) or an implant (2 cases) and with corrective surgical interventions.

RESULTS AND DISCUSSION

Six patients (out of 31) with penetrating defects of the lower part of the face died during the period of the reconstructive surgery (i. e., 6 to 12 months after the radical intervention) because of the recurrence of the malignant tumours of former chronic diseases.

The best therapeutical results were achieved in the group of 12 patients treated also by combined radiotherapy and local chemotherapy. In this group an increased occurrence of complications at the stage of the flap implanta-

Figure 2. Patient K., postoperative penetrating defect of the lower part of the face. The flap implanted into posterior buccal margin of the defect. — Figure 3. The same patient. The flap pedicle implanted into the opposite margin of the defect

tion was observed. In 4 cases the pedicle tore off, in 3 cases the sutures cut through and in 2 cases the spreading of the flap resulted in partial necrosis. Such complications occurred only in 2, 2 and 1 case, respectively, in the group of 13 patients without radiotherapy and chemotherapy.

In some cases, reconstructions of the oral cavity walls (the floor of the mouth, mandible, cheeks) resulted in anatomical and functional distrubances (unfavourable cosmetic results, poor speech, feeding difficulties, decreased saliva sectretion, etc) which at the beginning of the treatment had unfavourable psychoemotional influences o nthe patients. Later on, as the result of compensatory adaptations, the patients were able to restore oral feeding and to use oesophageal and pharyngeal muscles for speaking. Thus, reconstructed organs become more acceptable both from aesthetic and functional point of view.

Eleven patients (35.5 %) had been alive after the surgical intervention for 5 and more years. Three of them continued their work (2 accountants, 1 journalist) 2 women were housekeepers, 4 patients retired, two of them due to their age and the two others because of illness.

Figure 4. The same patient. The tubed flap divided by oblique transection into two parts. Inner and outer flap strips were formed. — Figure 5. The same patient. The two parts of the flap are opposed side to side and the inner flap strips are sutured, so that the epithelial lining of the oral cavity is formed. The outer flaps are slightly lifted

Case report

Patient K., female aged 52, was admitted on November 10, 1958. Diagnosis: recurrence of the carcinoma of the lower lip with metastases in the mandible and cervical lymph nodes. On November 16, under the endotracheal anaesthesia via the tracheostomy, a wide resection of the lower jaw, tissues of the floor of the mouth, lower lip, cheek and lateral pharyngeal wall, simultaneously with the one step operation according Crail, were performed. An extensive defect of the lower part of the face was closed using the tubed flap (size 32×16 cm) formed on the anterolateral abdominal wall on December 14. The flap was transferred to the dorsal aspect of the hand on January 12, 1959, implanted in the posterior buccal margin of the defect on February 10 (Fig. 2) and into the opposite margin of the defect on March 4 (Fig. 3).

On March 12, under a local anaesthesia, the tubed flap was cut transversely and divided into distal and medial parts (Fig. 4). The distal part was spread into the inner and outer flap strip. The medial part of the flap was incised along its inner margin and surpluses of the flap material were removed. Both parts of the flap were opposed side to side. The floor of the mouth and cheeks were formed from the material of the distal part, the lower jaw, chin and anterior parts of the cheeks from the medial part of the flap (Fig. 5, 6). After six months mandible plasty was performed using AKR-7 implant (Fig. 7).

Fig. 6. The same patient after surgery. Formation of the outer skin cover. — Fig. 7. The same patient after mandible plasty

The above described plasty of the lower part of the face with a single-tubed flap enabled us to reconstruct the floor of the mouth, the lower lip, chin, cheek and oral cavity. The oral cavity was deep enough to receive the tongue (diminished by resection) and to serve as the saliva receptacle. The oral feeding was restored and the speech improved sufficiently. The patient was quite content with the results of the surgery and did not require suggested corrective interventions.

CONCLUSIONS

1. The penetrating defects resulting from radical surgery should be closed as soon as possible.

2. To close the combined postoperative defects of the lower part of the face by the tubed flap, widely spread in the final step of the plasty, can be used.

3. The tubed flap in reconstructive surgery of the lower part of the face is fully justifiable from anatomical, functional and aesthetical points of view.

M. D.

SUMMARY

Postoperative penetrating defects of the lower part of the face were closed using the tubed flap. In 11 out of 31 patients surviving for five and more years satisfactory anatomical and functional results were obtained. It is recommended to perform reconstructive surgery of the lower part of the face as soon as possible after radical interventions.

RESUME

La plastie par lambeau tubulé après de vastes résections à la partie inférieure du visage

Sidorov, S. D.

Les défauts de la partie inférieure du visage, conséquences des opérations radicales, ont été recouverts par des lambeaux tubulés. 11 malades sur 31 survenaient plus de 5 années après l'opération avec de bons résultats anatomiques.

D'après nos expériences, nous recommendons exécuter une plastie du visage inférieur le plus tôt possible après l'intervention radicale.

ZUSAMMENFASSUNG

Die Plastik mittels tubuliertem Lappen nach ausgedehnten Resektionen des Unterteils des Gesichts

Sidorov, S. D.

Bei radikalen Operationen wurden die entstandenen Defekte des Unterteils des Gesichts mittels einer Plastik mit Hilfe eines tubulierten Lappens verdeckt. Bei 11 von 31 Patienten wurde eine Überlebenszeit von 5 und mehr Jahren nach der Operation sowie befriedigende anatomische Ergebnisse erzielt. Auf Grund unserer Erfahrungen empfehlen wir, die Plastik des Unterteils des Gesichts so bald wie möglich nach dem radikalen operativen Eingriff vorzunehmen.

RESUMEN

Plástica mediante lóbulo tubulado después de amplias resecciones de partes inferiores de la cara

Sidorov, S. D.

Por operaciones radicales se cubrieron los defectos originados en la parte facial inferior utilizándose plástica por lóbulo tubulado. En 11 de 31 pacientes se pudo lograr una supervivencia de 5 y más años después de la operación así como resultados anatómicos satisfactorios. A base de nuestras experiencias recomendamos sea efectuada la plástica de la parte inferior del semblante a la mayor brevedad posible después de la intervención operativa radical.

REFERENCES

1. **Dunajevskij, V. A.**: Plastic Operations Used for Surgical Treatment of Tumours of the Face and Jaws (in Russian). L., 1976.

2. **Jevdokimov, A. I., Lanjuk, C. V.**: Operatability of Carcinomas of the Mandible. Stomatologija (Mosk.), (in Russian). 1 : 11, 1962.

3. **Patches, A. I.**: Tumours of the Head and Neck (in Russian). M., 167, 1971.

4. **Sidorov, S. D.**: Plasty Closing Defects of the Oral Region (in Russian), Ph. D. Thesis, M., 1970.

5. **Sidorov, S. D.**: Plasty of the Oral Region Using the Tubed Flap (in Russian). Kursk Scientific Medical Conference, No. I., 1971.

6. **Sidorov, S. D.**: The Method for Prevention of the Secondary Hemorrhage from the Carotid Arteries after Neck Surgery (in Russian). Vest. Chir., 10 : 108, 1978.

7. **Sidorov, S. D.**: The Tubed Flap Used for Closing of Postoperative Total Defects of the Floor of the Mouth, the Chin and the Lover Lip (in Russian). Vest. Chir., 5 : 121, 1979.

8. **Sidorov, S. D.**: The Tubed Flap Used for Closing of Postoperative Total Defects of the Floor of the Mouth (in Russian), Stomatologija (Mosk.), 4 : 38, 1980.

9. **Chitrov, F. M.**: The Tubed Flap for Closing Defects of the Face and Neck (in Russian). M., 183, 1954.

10. **Vonemoto, R. H., Ching, P. T., Byron, R. Z., Kiihimaki, D. S.**: The Composite Operation in Cancer of the Head and Neck (commando procedure). Arch. Surg., 104, 6 : 809, 1972.

11. **Jakobsson, P. A., Körlof, B., Nylen, B., Medez, B., Wezsall, I.**: Repair of the Oral Carcinoma. Acta oto-laryng., 75, 4 : 304, 1973.

12. **Harrold, C. C.**: Management of Cancer of the Floor of the Mouth. Amer. J. Surg., 122, 4 : 487, 1971.

13. **Karrolli, W. W.**: Combined Neck and Jaw Resection for Intraoral Carcinoma. Surg. Gynec. Obstet., 94, 1 : 1, 1952.

Dr. S. D. Sidorov, Lenina 31, 305000 Kursk, USSR

Vitebsk Institute of Medicine, Vitebsk (USSR)
Department of General Surgery
Director Prof. V. M. Velitchenko

RESECTION OF THE BIFURCATION OF THE TRACHEA. AN EXPERIMENTAL STUDY.

V. V. ANITCHKIN, M. G. SATCHEK

Operations on the bifurcation of the trachea constitue a unique group of surgical interventions with regard to anatomical features of the area and technical difficulties of reconstructing the airways and maintaining the ventilation. Resections of the bifurcation of the trachea are classified (Petrovskij et al., 1978) as follows: complete resection, resection of the lateral wall including the carina tracheae and the main-stem bronchus, circular resection of the bifurcation with or without pulmectomy (leaving the atelectatic lung in situ), and circular resection of the bifurcation with preservation of the lung function. The latter as well as the complete resection are the most physiological approaches preserving both lungs.

Literature reports on 100 cases of operations on the bifurcation of the trachea (Perelman and Koroleva, 1977). Only few of them, however, were performed using the circular resection preserving the lung. In most cases, resection of the intrathoriacic part of the trachea extends from 4 to 5 trachea rings (Carrera et al., 1975), exceptionally to 16 rings (Eterija, 1974), and distally it is limited to 2—4 rings of the main stem bronchi.

However, the most common reasons for resection of the bifurcation of the trachea — malignant tumours — very often require a more extensive resection of the bronchi. Consequently, it is rather difficult to restore the tracheobronchial tree and new techniques of the intrathoriacic airways reconstruction should be looked for. Obviously, a wide resection of the bifurcation of the trachea preserving fully the function of both lungs would be preferred, and, in this direction, further research is desirable.

The paper presents results of our experiments, in which we attempted to improve the techniques of the reconstruction of the intrathoracic airways following their extended resections.

35 sexually mature randombred dogs of both sexes, weighing between 13 and 35 kilograms, were used. Surgery was performed under intravenous anaesthesia (Nembutal, 30 mg/kg) with a forced ventilation. When the tracheobronchial tree was transected, the orotracheal intubation was replaced by intubation of distal airways and the system of "shunt-ventilation" was used.

A right thoracotomy was performed through the fifth intercostal space. After incision of the mediastinal pleura and ligamentum pulmonale, the vena azygos was transected and the distal trachea, bifurcation and both main-stem bronchi were exposed.

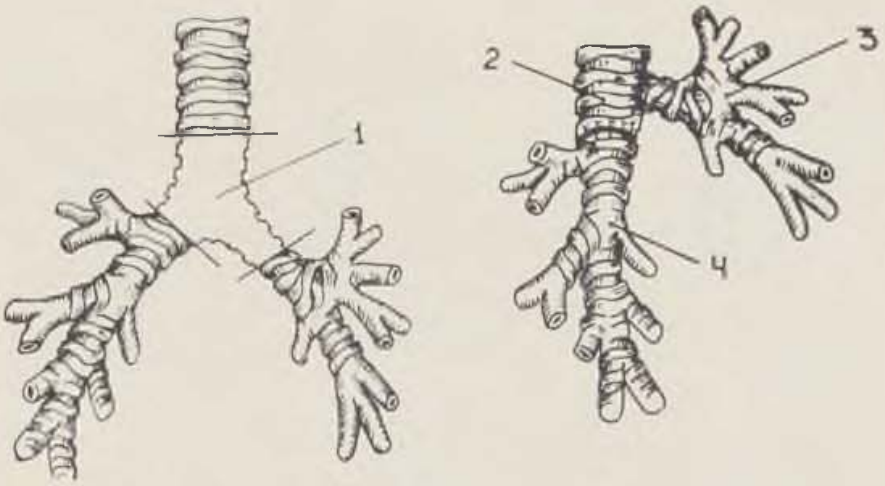

Fig. 1. The scheme of resection of the bifurcation of the trachea and reconstruction of the tracheobronchial tree in the 1st group of dogs. 1 — the segment to be removed, 2 — the trachea, 3 — the left main-stem bronchus, 4 — the right main-stem bronchus

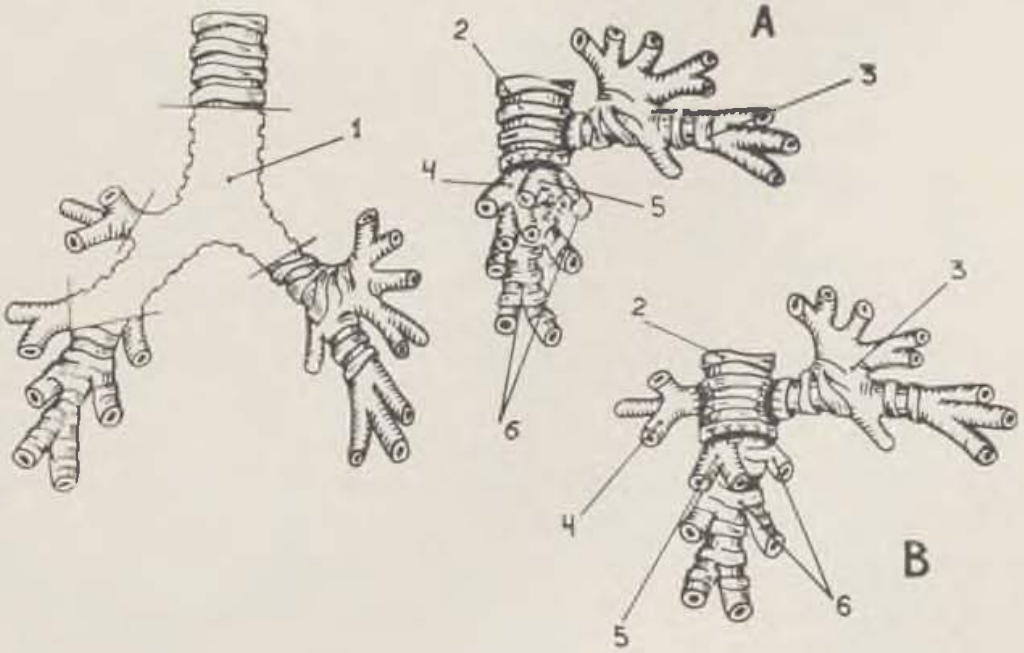

Fig. 2. The scheme of resection of the bifurcation of the trachea and reconstruction of the tracheobronchial tree in the 2nd (A) 3rd (B) group of dogs. 1 — the segment to be removed, 2 — the trachea, 3 — the left main-stem bronchus, 4 — the cranial lobe bronchus, 5 — the cardiac lobe bronchus, 6 — the diaphragmatic and intermediate lobe bronchi

In all the experiments the resected segment of the airways consisted of 5, 6 or 7 rings of the trachea, the bifurcation, and from 2 to 4 rings of the left main-stem bronchus. According to the extent of the resection of the right main-stem bronchus and the technique used for the reconstruction of the tracheobronchial tree, four experimental groups were distinguished.

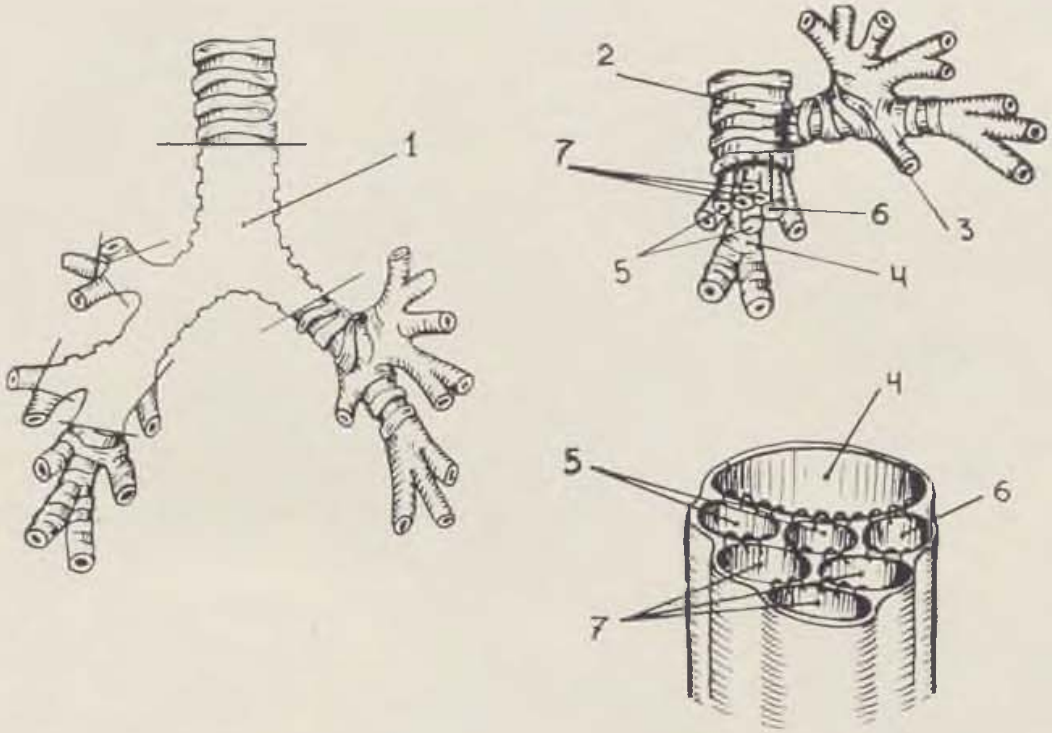

Fig. 3. The scheme of resection of the bifurcation of the trachea, reconstruction of the tracheobronchial tree and formation of the polybronchial anastomosis in the 4th group of dogs. 1 — the segment to be removed, 2 — the trachea, 3 — the left main-stem bronchus, 4 — the diaphragmatic lobe bronchus, 5 — the segmental bronchi of the cardiac lobe, 6 — the intermediate lobe bronchus, 7 — the segmental bronchi of the cranial lobe

In 10 animals in the 1st (control) experimental group 2 rings of the right main-stem bronchus were resected and the airways were reconstructed by the direct connection of the right bronchus and the trachea. The left main-stem bronchus was inserted into the lateral wall of the trachea (Fig. 1).

In 10 animals in the 2nd experimental group the resection of the right main-stem bronchus was extended distally so that the orifices of the lobe bronchi were exposed and transected. The stumps of the diaphragmatic, cardiac and cranial lobe bronchi were sutured into a trifurcation and anastomosed to the proximal part of the trachea (Fig. 2, A). In 3 animals the anastomosis resulted in changed coarse of the cranial lobe bronchus, its bendings and lumen deformation.

In the 3rd experimental group (5 animals) we tried to avoid this complication using another technique of reconstruction. The extent of resection was the same as in the 2nd group, and the diaphragmatic and cardiac lobe bronchi were sutured together by their membranous walls and connected with the proximal part of the trachea. However, the cranial lobe bronchus was inserted into the right lateral wall of the trachea (Fig. 2, B). Thus we managed to prevent any deformation of its lumen.

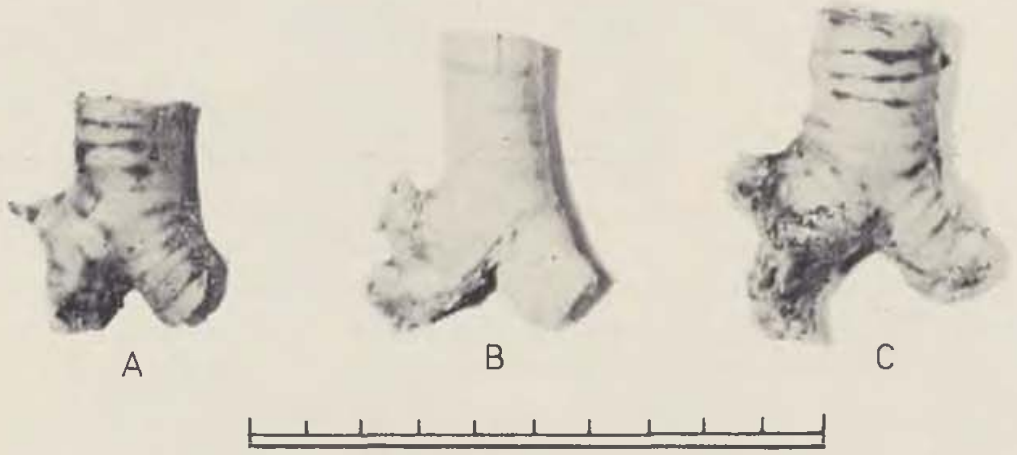

Fig. 4. Specimens of the resected airway segments in dogs of the 1st (A), 2nd and 3rd (B) and 4th (C) group

In 10 animals of the 4th group the resected segment was extended distally up to the level of the segmental bronchi of the cardiac and diaphragmatic lobe (Fig. 3). The first step of the reconstruction was to form a polybronchal anastomosis using the group method (Avilova, 1971). The stumps of the transected bronchi (with the diameter from 4 to 6 mm) were successively sutured in the following manner. Using one suture on an atraumatic needle, three segmentad bronchi of the cranial lobe were sutured. The two segmental bronchi of the cardiac lobe were added and together with the intermediate lobe bronchus sutured to the wide stump of the diaphragmatic lobe (transected at the level of the 7th and 8th segmental bronchi). Polybronchial anastomosis, formed in the way described and having the form of "bundle of tubings", was connected with the proximal part of the trachea in a usual manner.

During the reconstructive period of all the experiments the left lung was ventilated using the system of "shunt-ventilation". Then the right lung was used for the ventilation and the left main-stem bronchus was transected and removed in one block with the resected parts of the trachea and the right bronchus (Fig. 4). The stump of the left main-stem bronchus was connected end to side to the trachea below the level of the left tracheobronchal anastomosis. The anastomosis were performed with the sutures Supramid 3-0, 4-0 on atraumatic needles Medicor (Hungary).

12 out of 35 dogs died of complications of the surgical intervention (3 in the 1st and 2nd group, 6 in the 4th group). 23 dogs that survived had been followed for 24 months, the most common lethal complications being pneumonia (6 cases) and cardiac or breathing failure (4 cases). One dog died of pneumothorax and another one of empyema of the thorax.

The postoperative coarse of all the experimental dogs was rather difficult: they had been adynamic and refusing food for 2 or 3 days. Within two weeks postoperatively the dogs suffered from pneumonia and within the next 10 days from intensive tracheobronchitis. Such a difficult postoperative coarse was caused by traumatising surgery, disturbances of the blood supply and the vagus nerve transection, which undoubtedly contributed to the development of lung complications.

Antibiotics were necessary component of the early postoperative period management. Clinical conditions and laboratory values were stabilised and the decrease in body weight stopped after one and a half month; after two months the preoperative status was reached. The four experimental groups were compared as to clinical conditions and complications within the early postoperative period. The most difficult postoperative coarse was observed with animals of the 4th group, a better one with animals of the 1st and 3rd groups. Later postoperatively (8—24 months) there were no differences in clinical conditions between the four experimental groups. When examining the lung function by chest roentgenograms, in 3 dogs of the 2nd group we found a hypoventilation of the right cranial lobe as a result of deformation of the upper bronchus during formation of the anastomosis. Chronic pneumonia and minor disturbances of the capillary flow in the right lung were diagnosed in the surviving dogs of the 4th experimental group. In dogs of the 1st and 3rd group no pathological changes were found.

At macroscopic examination the lung tissue was elastic, pinkish-white and evenly distributed at both sides. The mucous membrane of the region of the polybronchial nad tracheobronchial anastomoses healed by primary adhesion with a fine scar. Histological changes of the lung tissue of the animals of the 1st, 2nd and 3rd group were of the same type: areas with changes in alveolar lumina, periodic occurrence of the emphysematic alveoli with desquamating epithelium, narrowing of the bronchi and peribronchial leucocytic infiltration. Blood vessels were dilated and there were single leucocytes in the perivascular spaces. Grave sclerotic changes of the lung parenchyma were not observed. Histological findings in animals of the 4th experimental group corresponded to the chronic pneumonia.

CONCLUSIONS

1. Experimentally developed techniques of extended resection of the bifurcation of the trachea enable us to resect the airway segment consisting of: 5—7 rings of the trachea, the bifurcation, 2—4 rings of the left main-stem

bronchus and the right main-stem bronchus including the orifices of the lobe and segmental bronchi.

2. The reconstruction of the tracheobronchial airways after extended resection of the bifurcation is performed by anastomosing the bronchi to the trachea, so that the function of both the right and left lung is preserved.

M. D.

SUMMARY

A technique for extended resection of the bifurcation of the trachea was developed in experiments with 35 dogs. Using the technique it is possible to resect the airway segment of 5—7 rings of the trachea, 2—4 rings of the left main-stem bronchus and entire right main-stem bronchus, including orifices of the lobe and segmental bronchi. The airways are reconstructed by forming tracheopolybronchial anastomosis, which preserves the function of both lungs.

RESUME

La résection de la bifurcation trachéale.
Travail expérimental.

Anitchkin, V. V., Satchek, M. G.

On a élaboré une technique de la résection élargie de la bifurcation trachéale, en expérimentation sur les chiens. La technique permet éliminer 5 ou 7 anneaux trachéales en un seul bloc au dessus de la bifurcation, 2—4 anneaux de la bronche souche gauche et toute la bronche souche droite avec les bouches des bronches lobaires supérieures et inférieures. Des voies aériennes sont reconstruites par l'anastomose trachéopolybronchiale de sorte que la fonction de les deux poumons reste conservée.

ZUSAMMENFASSUNG

Die Resektion einer Gabelung der Luftröhre.
Experimentalarbeit.

Anitshkin, V. V., Satshek, M. G.

An Hand von Versuchen an 35 Hunden wurde die Technik einer erweiterten Resektion einer Gabelung der Luftröhre ausgearbeitet. Diese Technik gestattet, in einem Block 5—7 Luftröhrenringe oberhalb der Gabelung, 2—4 Ringe der linken Hauptbronchie sowie die ganze rechte Bronchie einschliesslich der Bronchieneinmündungen der einzelnen Lappen und Segmente zu beseitigen. Die Atemwege werden durch Bildung einer tracheopolybronchialen Anastomosis rekonstruiert, sodass die Funktion beider Lungenflügel erhalten bleibt.

RESUMEN

Resección de la bifurcación de la tráquea.
Trabajo experimental.

Anitchkin, V. V., Satchek, M. G.

A base de experimentos con 35 perros se ha elaborado una técnica de resección ampliada de la bifurcación de la tráquea. Esta técnica posibilita quitar, en un bloque, 5 a 7 anillos de la tráquea encima de la bifurcación, 2 a 4 anillos del bronquio

principal izquierdo y todo el bronqui derecho, incluyendo las bocas de bronquios de los diferentes lóbulos y segmentos. Por la creación de anastomosis traqueopolibronquial se reconstruyen las vías respiratorias manteniéndose así ambos pulmones funcionales.

REFERENCES

1. **Avilova, O. M.:** Resection and Plasty of the Bronchi and Mediastinal Trachea (in Russian). Ph. D. Thesis, Kiev, 1971.

2. **Petrovskij, B. V., Perelman, M. I., Korolove, N. S.:** The Tracheobronchal Surgery (in Russian). M., 1978.

3. **Perelman, M. I., Koroleva, N. C.:** Resection of the Bifurcation of the Trachea (in Russian). Grudnaja Chir., 5 : 86, 1977.

4. **Eterija, G. P.:** The Plastic Operations on the Trachea and Bronchi (in Russian). Ph. D. Thesis, Tbilisi, 1974.

5. **Carrera, C., Gastambide, C., Delgado, F., Rubi, F., Crustanello, F.:** Reseccion y reconstruccion de la carina traqueal. Cirug. Uruguay, 45, 3, 275, 1975.

Dr. V. V. Anitchkin, Vitebskij Medicinskij Institute,
pr. Frunze 27, 210023, Vitebsk, SSSR

Moscow Research Institute of Otolaryngology, Moscow (USSR)
Director Prof. D. I. Tarasov
Department of Reconstructive Surgery
Director Prof. A. I. Yunina

EPIGLOTTOPEXIA AND LARYNGOPEXIA. INDICATIONS, METHODS AND RESULTS OF THE OPERATIONS.

A. I. YUNINA

Epiglottis is situated in a crossing of respiratory and digestive pathways. Therefore, changes of its form, localization, inclination and motility cause disturbances of breathing, or swallowing, or both.

Structure and function of the epiglottis may be altered by variety of factors. Usually, clinical features are closely related to the responsible etiological factors (Yunina 1973).

A stretched, perpendicularly situated epiglottis, shifted towards bottom of the oral cavity and sometimes rotated to one side occurs by patients suffering from consequences of subcutaneous ruptures (blunt injuries, strangulations), injuries of thyreo-hyoid membrane, or partial resection of the larynx (a horizontal, frontal or fronto-lateral one). A diastasis is usually formed between the epiglottis and the vestibular part of the larynx. It is especially expressed in the case of laryngeal prolaps (Fig. 1). A distributing role of epiglottis is disturbed: saliva, liquids and food get into respiratory pathways. Neck configuration is changed by such patients. The larynx is in low position and a thyreo-hyoid distance exceedes the normal condition two times or even more. The tissues are thinner in this region and often float off, when the patients talk or during their forced breathing. Aspection of the larynx reveals high position of a free margin of the epiglottis and its perpendicularly elongated, sometimes deformed, pedicle (petiolus). The laryngeal constituents are shifted downwards ,the vocal part usually remains unaffected.

An X-ray examination performed from a lateral view reveals a high position of the hyoid bone. The thyreoideal cartilage is situated 1—2 vertebrae lower, the tissues are thinned out in the thyreo-hyoid space. A swallowed barium suspension gets into larynx. The pharynx is stretched perpendicularly.

A horizontal, arched epiglottis (Fig. 2) develops usually as a consequence of burns acused by acids or hydroxides. A degree of stenosis depends on length of the scars fixing epiglottis to lateral walls of the pharynx. Sometimes, the nasal and oral breathing ih thoroughly impossible. Saliva, liquids and food

often get into respiratory pathways. The symptomatology is different. Neck configuration is almost unchanged, the thyreoid cartilage is shifted nearer to a body of the hyoid bone, the thyreo-hyoid distance is shorter and sometimes totally disappears. Laryngoscopically, a horizontally situated epiglottis is observed; valleculae and pyriform sinuses are often missing. A free margin and lateral parts of the epiglottis are usually fixed by scars to a posterio-lateral side of the pharynx. An orifice many remain between the conglomerated scars, through which larynx and pharynx communicate. Unaffected vocal folds can sometimes be seen through this opening. In the most serious cases, the larynx becomes united with the pharynx and a retrocricoideal region and pyriform sinuses disappear. When examining a X-ray photographs taken from a lateral view, a horizontal position of the epiglottis is seen, major horns of the hyoid bone may run obliquely and a posterior pharyngeal wall may be deformed. If swallowing is followed, an altered relief of the pharynx is noted and a great part of the suspension goes down the oesophagus as a thin stream. If the oesophagus is totally obliterated, no barium suspension can enter.

Different types of the correcting surgical methods can be chosen in relation to features of the structurally altered epiglottis. However, a fixation of the epiglottis in normal position (epiglottopexia) is a constant part of each technique. In cases of laryngoptosis, the larynx is fixed to the hyoid bone (laryngopexia).

In patients suffering from consequences of a subcutaneous rupture or injury of the thyreo-hyoid membrane in combination with laryngoptosis, the normal topographic relationships of larynx and pharynx are restored by bringing the larynx nearer to the hyoid bone and by fixation of the epiglottis in a plane, which is more inclined to the horizontal one. In contrary, in patients suffering from consequences of burns, a relief of the laryngo-pharyngeal complex is restored by reconstruction of pyriform sinuses and of retrocricoid space, and by fixation of the epiglottis in a more vertical position (Yunina 1972, 1973, 1978).

Now, a technique of the epiglottopexia will be described (Fig. 3). The skin and subcutaneous connective tissue are incised in the middle line. A layer of long neck muscles is liberated along a white line and turned sideways. The hyoid bone and larynx are cleaned. The larynx is fully mobilized by removing the scars. A pair of holding ligatures is drawn behind both major horns of the hyoid bone, another pair of ligatures is lead behind inferior horns of the thyreoid cartilage. A middle third of the thyreo-hyoid membrane and pharyngeal mucosa are cut in a distance of 0,5 cm from an upper margin of the thyreoid cartilage. Then, the larynx is inspected. If additional interventions are not required, the remaining scars are excised together with a part of pedicle of the epiglottis, along the upper margin of the incision. It can be determined, to what extent the tissues should be excised, when the larynx and the hyoid bone are brought together so much as their normal distance is regained (1.5—2.00 cm). Before suturing of the laryngeal wound, two complementary fan-shaped incisions are lead along sides of the epiglottis, which

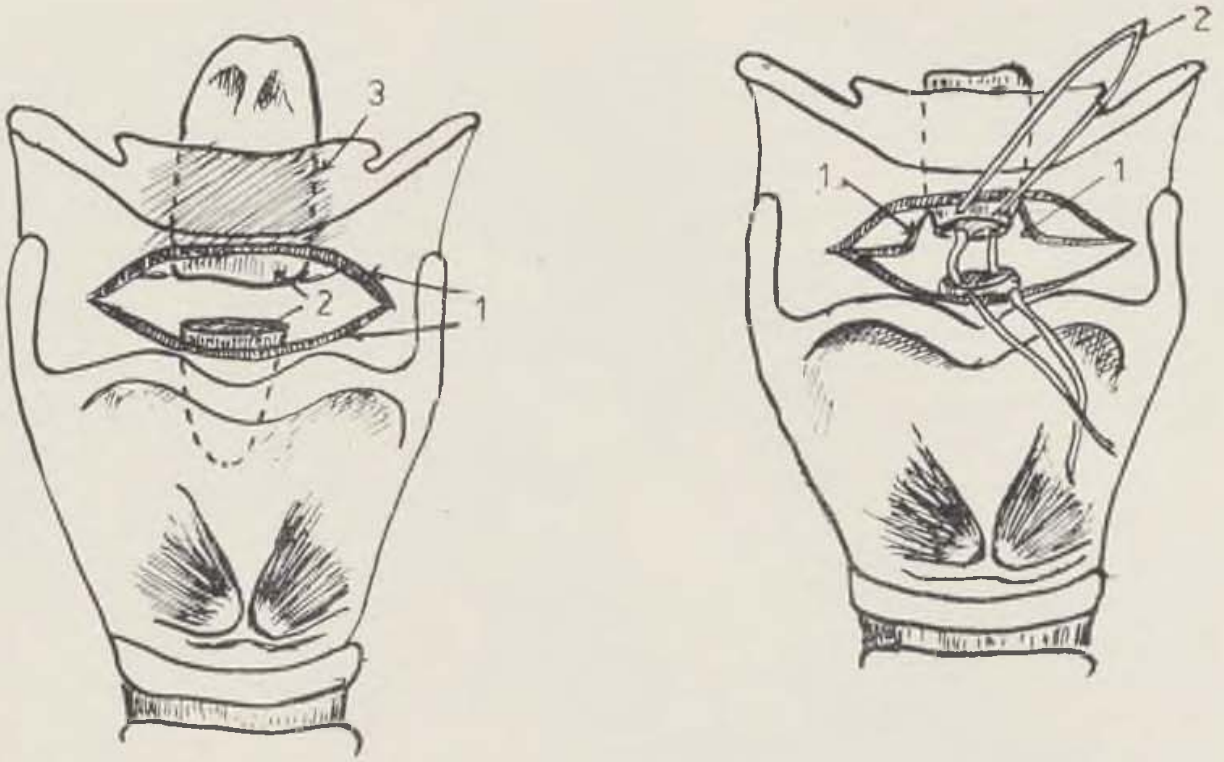

Fig. 3. Stages of the epiglottopexia. a — subhyoid pharyngotomia (1), liberation of the upper part of the epiglottis (2) from scars (3), b — the anterior pharyngeal wall was mobilized and incised (1) along the sides of the epiglottis; a thread (2) was drawn through forming an U-shaped suture

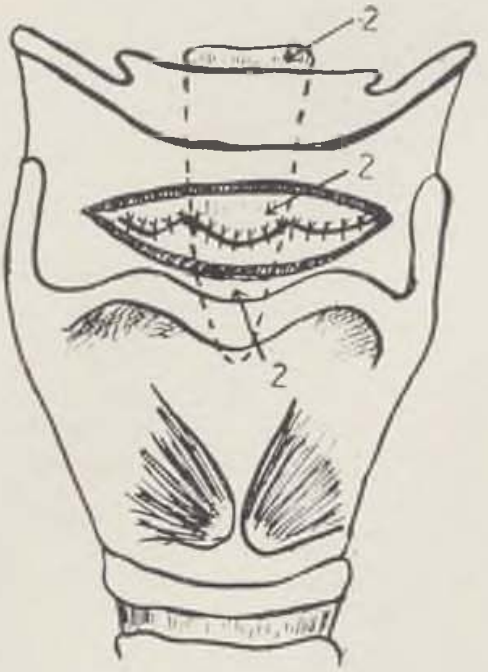

Fig. 3. c — the pharyngostomy was sutured, the epiglottis was shifted downwards and connected with its pedicle (2)

has been mobilized through the preepiglottical space. It is done, in order to reposition the epiglottis as low as possible. Then, margins of the epiglottis are united by a U-shaped suture. Starting from this point, knotted sutures are applied on both sides towards periphery. It should be checked that the free margin of the epiglottis and its pedicle are sufficiently inclined to form and 45^0—60^0 angle with a horizontal plane. After suturing of the pharyngostoma, the sutures are irregularly aligned. The holding ligatures, which have been drawn behind horns of the hyoid bone and behind inferior horns of the thyreoid cartilage, are tied together on both sides.

A plan of the operation is more complicated, if burn consequences of the laryngo-pharyngeal complex and horizontally situated epiglottis are to be repaired. An approach to pharynx is the same as has been already described. Following its incision, the epiglottis is made free of scars that have fixed it to the posterio-lateral walls of the pharynx. The wounded margins of the epiglottis are covered by strenched margins of the wounded lingual and laryngeal surfaces. The scars that have caused deformation of the pharynx, are loosened. The larynx is liberated from the scars that have fixed it to the posterior wall and pyriform sinuses are reconstructed. The wounded surfaces are covered by shifted mucosal flaps, by skin or by an enteral graft in cases of total oesophagoplasty. All methodological details of such an operation were described by Khitrov (1963) and by us later on (Yunina 1978). A renewal of horizontal fixation of the epiglottis that would again interfere with breathing should be prevented. It has to be positioned more perpendicularly. It is achieved by the epiglottopexia. U-shaped sutures are drawn through the preepiglottical space, ends of the threads are brought out and knotted above a gauze pad in a submandibular region. In addtition to it, a tube is introduced into a laryngeal lumen, which pushes the epiglottis anteriorly.

If the disturbed position and function of the epiglottis have been combined with a marked laryngoptosis, the sutures may become loose after the operation and the larynx could move to the original place, i. e. a failure of its distributing role would result again. In order to prevent aspiration and to normalize swallowing, Meuerman (1957) suggested "Aufhängung" of the larynx. This operation was modified by us. The larynx is lifted using fascial bands that are not fixed to the cricoid cartilage, but to inferior horns of the thyreoid cartilage (Figs. 4a, b). In this way, a necessary downward and forward inclination of the larynx is achieved.

A thick part of the fascia lata femoris is utilized for the laryngopexia. It is obtained from the same patient during the operation, or from the "tissue bank".

The technique of the laryngopexia: The hyoid bone and the larynx are exposed. They are liberated from scars and brought together as much as the normal position is restored (a distance between lower border of the hyoid bone and upper border of the thyreoid cartilage should be 1.5—2.0 cm). Two guiding silk threads are drawn behind a body of the hyoid bone in the place, where its major horns originate, using de Champs' or a circular enteral needle. Then, ane end of the thread is drawn also behind a base of the inferior horn of the

thyreoid cartilage, pricking out the needle anteriorly. The fascial band is connected with this end of the thread. Pulling by the other, free end of the thread, the fascia is drawn through along the pathway predetermined by the course of the thread. In this way, the silk threads are replaced by bands of the fascia lata. The ends of both bands are simultaneously knotted by the surgeon and his assistant, as soon as the appropriate distance between the larynx and

Fig. 4. Diagrammatical representation of the laryngopexia. b — the larynx is "suspended" by fascial bands (6) fastened to inferior horns of the thyreoid cartilage (5) and to the hyoid bone (4)

the hyoid bone has been adjusted. The ends of the tied fascial bands are additionally fastened to neck muscles by catgut, in order to prevent weakening of the stretching force and relapse of the laryngoptosis. The wound is sewn in layers.

The laryngopexia restores normal topographical relationships of larynx and pharynx. The epiglottopexia renews correct position of epiglottis. By both operations, that may also be combined with other interventions if necessary, the structure and the relief of the laryngo-pharyngeal complex are recovered, as well as the distributing role and breathing (originally mechanically disturbed by a horizontally situated epiglottis) are normalized. The results of the operations are illustrated by X-ray photographs of the patients (Figs. 5 and 6).

The epiglottopexia and the laryngopexia may be carried out as autonomous operations, or as stages of more complicated surgical reconstructions of larynx and pharynx.

The epiglottopexia was performed by 42 patients in the age ranging from 14 to 15 years. Consequences of subcutaneous ruptures occurred in 14 patients, injuries and operations of larynx due to neoplasma — in 9 patients, chemical burns — in 5 patients, irradiation — in 4 patients, wolf's bite — in 1 patient, contusion and canullation — in 1 patient, consequences of diphteria — in 3 patients, consequences of paratonsillitis and phlegmonous laryngitis — in 2 patients, consequences of syphillis — in 2 patients. The laryngopexia was performed simultaneously in 7 patients. The good results were obtained in 37 patients. In 2 patients, the distributing function did not fully recover due to complications that appeared after the operation. Further treatment was refused by one patient, because a total oesophagoplasty would have to be done (a thoracal part of the oesophagus was obliterated as a consequence of a chemical burn injury). One patient died due to abscessing pneumonia following knife injury of the torax. A carcinoma relapsed in one patient.

CONCLUSIONS

1. By means of epiglottopexia and laryngopexia, the distributing role, swallowing and adequate breathing can be restored, if disturbances have been caused by abnormal position of epiglottis and by laryngoptosis.

2. The appropriate way of the epiglottopexia is chosen in respect to the type of pathological alternations in the crossing of the respiratory and digestive pathways.

3. Epiglottopexia and laryngopexia can be carried out as autonomous operations or as complementary stages of other operations.

M. T.

SUMMARY

The methods of epiglottopexia and laryngopexia were worked out by the author and applied in 42 patients suffering from disturbances of the distributing function, swallowing and breathing due to consequences of various injuries and diseases of the larynx and the pharynx. Indications of the operations, their methods and modifications were described. The results of treatment were documented. Clinical features, surgical techniques and results were illustrated by diagramms and figures.

RESUME

La fixation de l'épiglotte et du larynx.
Indications, méthodes, résultats opératoires.

Yunina, A. I.

Les techniques opératoires de la fixation de l'épiglotte et du larynx, élaborées par l'auteur, ont été utilisées pour le traitement des troubles laryngaux, Il s'agissait des troubles de la fonction de division, d'avalement, de respiration, consequences des traumas ou maladies pharyngo-laryngiennes, chez 42 malades.

L'auteur enumère les indications, méthodes et variantes des opérations. Les résultats du traitement sont aussi décrits. Le procès clinique est documenté sur les images, les types des interventions et leurs résultats sont démontrés aux schémas.

ZUSAMMENFASSUNG

Fixation der Epiglottis und des Larynx. Indikationen, Methodik und Operationsergebnisse

Yunina, A. I.

Operationstechniken zur Fixation der Epiglottis und des Larynx, die von der Autorin erarbeitet wurden, benutzte man bei Störungen der Verteilungsfunktion, bei Schluck- und Schlingstörungen und bei Atmungsstörungen bei 42 Patienten mit Folgen verschiedener Verletzungen und Erkrankungen des Larynx und Pharynx. Es wurden die Operationsindikationen, ihre Methoden und Varianten angeführt. Die Behandlungsergebnisse wurden wiedergegeben. Der klinische Verlauf wurde mit Abbildungen dokumentiert und die Operationsverfahren sowie ihre Ergebnisse an Schemen dargestellt.

RESUMEN

Fijación de epiglotis y laringe. Indicación, metodología y resultados de operaciones

Yunina, A. I.

Las técnica operatorias de fijacón de la epiglotis y la laringe, elaboradas por la autora, fueron empleadas para tratar defectos de la junta divisoria, la deglución l respiración en 42 pacientes afectados en consecuencia de diferentes lesiones y enfermedades de la faringe y laringe. Se plantean indicaciones de las operaciones, sus metodologías y variantes. Se describe los resultados del tratamiento. El desarrollo clínico se documenta con imágenes, los métodos de las operaciones y sus resultados vienen ilustrados en esquemas.

REFERENCES

1. **Khitrov, F. M.**: Defects and Scar Obliterations of Pharynx, Neck Part of Oesophagus, Larynx and Trachea, and Methods of Their Treatment. Medgiz, Moscow 1963 (In Russian.)

2. **Yunina, A. I.**: Injuries of Neck Organs and Their Complications. Meditsina, Moscow 1972 (In Russian.)

3. **Yunina, A. I.**: Epiglottopexia. (In Russian.) Problems of Pathology of the Upper Respiratory Pathways. Collected Works of Moscow Research Institute of Otolaryngology, Vol XIX, Moscow 1973.

4. **Yunina, A. I.**: Plastic Treatment of Scar Atresias of Larynx and Pharynx. (In Russian.) Discoveries, Improvements, Industrial Standards, Trade Marks, Bulletin 35, 1978.

5. **Meuerman, J.**: Aufhängung des Larynx mit Fascienstreifen am Zungenbein zur Beseitigung von Schluck-Störungen nach Trauma. Arch. Ohr.-, Nas.- u., Kehlk.-Heilk. 172 : 96, 1957.

Prof. A. I. Yunina, Moscow Research Institute of Otolaryngology,
2nd Botkin Avenue 5/8, Moscow, USSR

Medical Faculty of Hygiene, Charles University, Prague (Czechoslovakia)
Department of Plastic Surgery Burns Unit
Head Prof. MUDr. M. Fára, DrSc.

ACUPUNCTURE IN PATIENTS WITH THERMAL INJURIES

E. JÍCHOVÁ, R. KŌNIGOVÁ, K. PRUSÍK

Pain has been man's companion throughout his existence. Since time immemorial, people have been trying to give relief to pain sufferers. In the countries of East Asia, acupuncture has, since Stone Age, been in use for a wide variety of diseases and their adverse concomitant phenomena. Over the centuries, people there have built up considerable knowledge of points situated along certain pathways.

In today's world where we have too much chemistry as it is we cannot but welcome the return and spread of acupuncture, not only the classical, somatic type but also auricular acupuncture. In 1956, Nogier et al. developed a French type of auriculotherapy independently of the Chinese classical somatic methods. According to the French authors, under pathological circumstances the ear alone permits the differentiation of 110 points, thereof 37 with powerful analgetic effects, and 19 more are likely to be added before long. A combination of somatic and auricular acupuncture leads to the potentiation and thereby to the amplification of the therapeutic effect, and that not only in the treatment but also in the prevention of pain.

Since in the course of their treatment burned patients have to undergo repeated, often daily exchanges of dressing or even reoperations involving repeated anaesthesia, we found it particularly tempting to try out this method after Dr. Prusík's report in the journal Praktický lékař (General Practitioner) had drawn our attention to it.

Now, only a few months after using acupuncture for burns of a variety of stages and extent, several indubitable facts seem to stand out:

— Following its application in patients with fresh burns of up to 20—30 % and up to the 2nd b degree, we were able to observe distinct possibilities of influencing the dynamics of post-injury changes, the disappearance of visible signs of neurogenic shock within 10 to 15 minutes, and extinction of the sensation of burning and pain within 25 to 30 minutes. In some cases, we chose to repeate acupuncture treatment daily or every other day.

— In cases of visible reddening in the surrounding of the burned area treated with daily acupuncture at preselected points there were signs of infection regressing (e. g. point LI 4 where, within 3 minutes of passing the needle, there is leucocytosis, proliferation and increased activity of macrophages).

— Regular exchanges of dressing in patients with extensive burns at different stages of the disease constitute yet another indication. This is a case of acupuncture used in patients receiving intensive care at burn units, mostly with a view to the abatement of pain resulting from surgical operations or from adverse forced positions (instead of analgetics).

Adding various other sensitive points we can exert influence on a number of pathological conditions occurring in the course of treatment. Last but not least, we use acupuncture 30 minutes prior to any major dressing exchange or operation in the operating theatre, premedicating the patients at the same time, as a rule with NLA+atropine or with dolsin+atropine (dosage to be determined by the patient's weight and individual tolerance). Patients thus prepared were found to need less than a half the usual dose of anaesthesiological agents. Individual approach and inadvisability in certain age groups (children, people over 60 years of age) have to be borne in mind in all indications for acupuncture. The usual though rare contraindications pertain mainly to certain specific points. Should such a point be situated beneath the wound area, the needles are passed through the damaged skin observing all the rules of sterility.

Technique of application, basic points for the burned

Filiform needles are introduced into the points of our selection at right angles or, at the beginning, at a more acute angle. Since only passage through the skin is painful, quick penetration may alleviate pain. All other manipulation is painless; all the patient can feel provided the needle has been lodged correctly is a little pressure or numbness. For acupuncture on the ear we use short needles inserted until cartilage is reached.

Points:

1. Situated on the pulmonary pathway is point P 7, LIEQUE at the medial edge of the radius, 1.5 cun (cun = width of patient's thumb) above the wrist fold. Auxiliary palpation is used there (Fig. 1). The needle is inserted obliquely upwards, depth 5 to 10 mm, minimum application time being 5 to 10 minutes

Fig. 1. Mode of palpation for finding point P 7 LIEQUE

(Fig. 2). There are several indications for this particular point; in our practical work it was used as a basic point in fresh burns since it removes the sensation of burning.

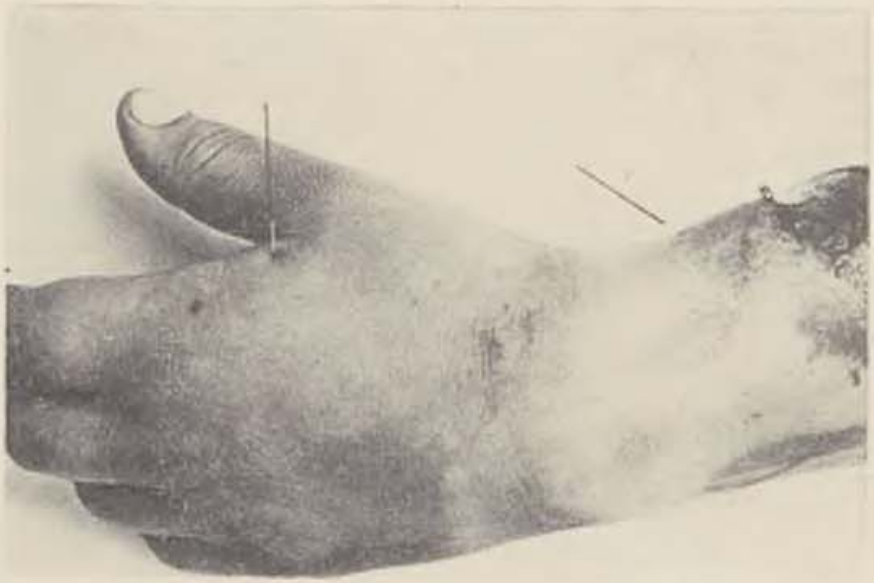

Fig. 2. Needle introduced into points LIEQUE and HEGU

2. Situated on the large intestine pathway is point LI 4, HEGU,

a) it is found in the middle of the 2nd metacarpus, on its radial edge,
b) at the top of the muscle provided the thumb and index are held closely together (Fig. 3).

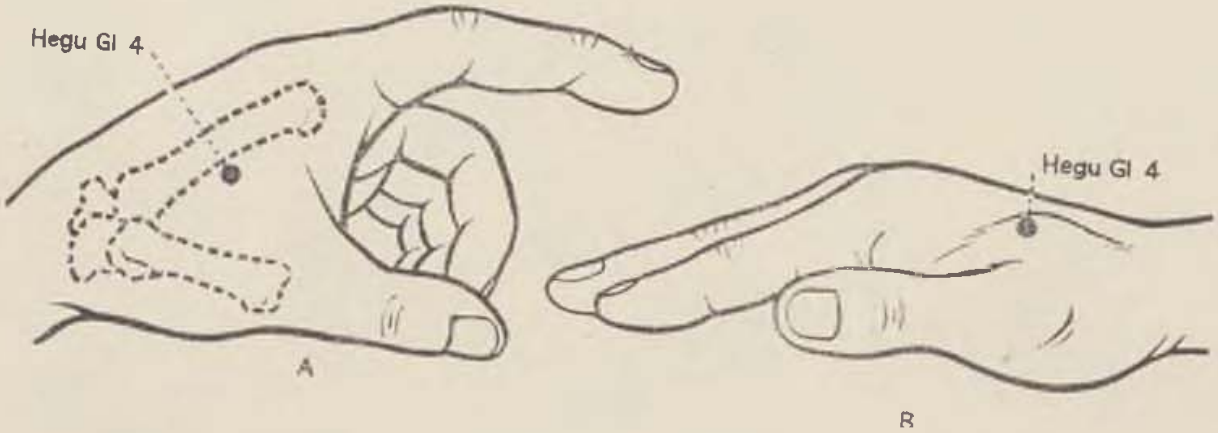

Fig. 3. Scheme of point LI 4 HEGU localization (marked as GI according to French authors)

The needle is introduced at right angles, 12—15 mm, and left in position for 10 to 15 minutes (Fig. 4). This point is noted for powerful analgetic and anti-inflammatory effects.

3. Situated along the gastric line is point St 36, ZU-SAN-LI, 3 cun below the edge of the patella, a finger-breadth lateral to the tibial crista, i. e. between the m. tibialis anterior and the m. extensor digorum longus (Fig. 5).

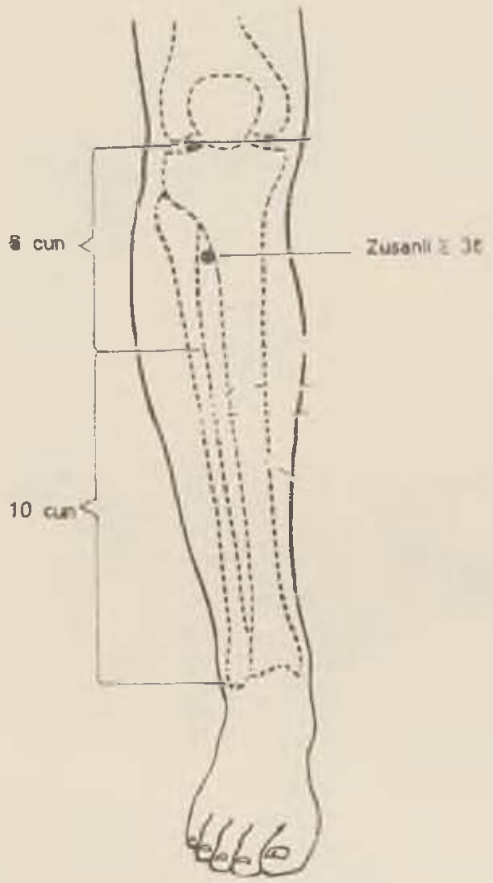

Fig. 4. Scheme of point St 36 ZUSANLI localization (marked as E 36 according to French authors)

Fig. 5. Needles introduced bilaterally into point ZU ANLI

The needle is introduced at right angles 25—40 mm and left in position for 10 to 15 minutes (Fig. 6). There is a wide range of indications for this particular point, too. Apart from its generally invigorating effects, it is also noted

Fig. 6. Scheme of auricular points — SHENMEN and thalamic projection point
Fig. 7. Needles introduced into both auricular points

for its analgetic and anti-inflammatory effects and for overall tranquilization The auricular points are used preoperatively: SHENMEN is localized on the dorsal angle of the fossa triangularis, and noted for powerful anti-inflammatory, analgetic and sedative effects. A shorter needle is introduced at right angles or obliquely as far as the cartilage and left in position for 20 to 30 minutes (Fig. 7).

The thalamic projection point is situated on the inside of the upper part of the antitragus. It inhibits pain transmission. The technique is the same as in the previous point (Fig. 7). However, there are likely to be a number of more points capable of bringing relief to burned patients as follows from literary reports.

Once the needle is in position, the following stimulation can be performed:

a) manual — by twirling the needle (the analgetic effects comes on earlier but is of shorter duration),

b) electric — the effect takes longer to be felt but persists longer, too. Electric stimulation makes use of apparatus generating rectangular or variously modulated currents at frequencies ranging from 0.5 to 2 000 Hz. The stimulation should be above threshold but short of causing pain to the patient. With the apparatus switched on, the intensity of the current is increased very slowly until the limits of tolerance are reached, maintaining permanent contact with the patient.

Lately, there have been a growing number of reports on the use of acupuncture in anaesthesiology at European and American clinics. In 1974, Benzer et al. of Vienna published the results of 69 different surgical operations using analgesia with classical and auricular acupuncture at a 64 % rate of effect. Nguyen Van Nghi (1972) reported on 875 diverse surgical operations performed in France, mainly abdominal operations, with very good effects reached in 72 %, and partially good results in 22.29 % of the cases concerned.

Similarly, Tsung O. Chang (1974) reported favourable results achieved with auriculotherapy in cardiosurgical operations at a teaching hospital in Washington. Satisfactory outcome of a variety of operations was achieved by Bischko (1973) of the Ludwig Boltzmann Research Institute, Vienna. Niboyet (1973) presented detailed results of 20 different surgical operations (strumectomy, tonsillectomy, appendicectomy, cholecystectomy, herniotomy) and 30 cases of stomatological operations, all with relatively good results. König and Wancura (1973) define auricular acupuncture analgesia as a selective elimination of pain corresponding to local anaesthesia. The patient remains fully conscious, his blood pressure and pulse rate values are stabilized. All he is free from his pain, or at least pain is greatly subdued, while sensation of pressure and touch remain preserved. Apart from successful anaesthesia induced by acupuncture, most authors reporting their clinical experience noted reduced bleeding in the operating field, favourable effects on blood pressure, respiration and pulse, and, last but not least, more rapid wound healing in patients operated on in acupuncture.

Proceeding from our, for the time being, brief but effective experience, we should like to draw attention to what is an easy and practically harmless operation in burned patients, whose organs have been damaged by the burn itself as it is. Our practical experience stands to show that unless it has brought improvement, acupuncture has certainly never caused distress to our patients.

J. H.

SUMMARY

The authors discuss the potential uses of classical as well as auricular acupuncture in patients with thermal trauma reviewing the points used for pain mitigation as well as for the primary management of the manifestations of burn injuries. These are somatic points Lu 7, LI 4, St 36, and auricular points Shenmen and the thalamic projection point. Apart from other characteristics, all those points are used for pain and inflammation management. The authors also refer to some of the latest experience of acupuncture as used at different world clinics.

RESUME

L'acupuncture des malades avec les traumas thermiques

Jíchová, E., Königová, R., Prusík, K.

Les auteurs avertissent aux possibilités qui sont offertes par l'acupuncture classique ou d'oreille, au traitement des malades avec les traumas thermiques. Ils apportent une liste synoptique des points qui sont importants pour le traitement des symptômes primaires de brûlure et pour l'analgésie. Les points du corps sont suivants: Lu 7, LI 4, St 36, parmi les points d'oreille c'est Shenmen et le point de projection du thalamus. Tous ces points peuvent influencer la douleur et l'inflammation, outre ses autres aptitudes.

Le traité rapporte des nouvelles de l'acupuncture aussi que des expériences des acupuncteurs du monde entier.

ZUSAMMENFASSUNG

Die Akupunktur bei Patienten mit thermischen Verletzungen

Jíchová, E., Königová, R., Prusík, K.

In ihrer Arbeit weisen die Autoren auf die Möglichkeiten einer Anwendung einserseits der klassischen und andererseits der Ohrenakupunktur bei Patienten mit einem thermischen Trauma hin. Anschaulich bieten sie seine Übersicht über die benutzten Punkte zur Schmerzverminderung sowie zum primären Beeinflussen der Auswirkungen einer solchen Verletzung. Es sind dies die Körperpunkte Lu 7, LI 4, St 36, ferner von den Ohrenpunkten Shenmen und der Punkt der Thalamusprojektion. Alle diese Punkte besitzen u. a. die Fähigkeit, Schmerzen und Entzündungen zu beeinflussen. Der Artikel erwähnt ferner die neusten Erfahrungen mit der Anwendung der Akupunktur an den verschiedensten Arbeitsstätten in der Welt.

RESUMEN

Implementación de acupuntura en pacientes con lesiones térmicas

Jíchová, E., Königová, R., Prusík, K.

Los autores en su trabajo hacen observar las posibilidades que ofrece el aprovechamiento de la acupuntura tanto clásica como la de la oreja en pacientes afectados por traumas térmicos. Brindan una relación sinóptica de puntos utilizados para aliviar el dolor así como para influir primariamente en los efectos de las heridas térmicas. Los puntos señalados en el cuerpo son Lu 7, LI 4, St 36, en la oreja es el Shenmen y el punto de la proyección del tálamo. Dichos puntos, aparte de otras capacidades, mitigan el dolor e influyen benéficamente en las inflamaciones. El artículo menciona, además, las más recientes experiencias en la utilización de acuputura en el mundo.

REFERENCES

1. **Académie de médecine traditionnelle chinoise (Péking) 1975:** PRECIS D'ACUPUNCTURE CHINOISE

2. **Niboyet, J. E. H.:** L'Anesthesie par acupuncture Saint-Ruffine, Maisonneuve 1973, p. 433.

3. **Šmirala, J.:** Auricular Acupuncture and Its Uses in Anaesthesiology (in Slovak). Bratisl. lek. Listy, 69, 5, 513, 1978.

Dr. E. Jíchová, Lidových milicí 63, 120 00 Prague 2, Czechoslovakia

Medical Faculty of Hygiene, Charles University, Prague (Czechoslovakia)
Department of Plastic Surgery Burns Unit
Head Prof. MUDr. M. Fára, DrSc.

GERONTOLOGICAL PROBLEMS IN BURNS

V. ŽELÍZKOVÁ

The World Health Organization declared 1982 the International Year of the Elderly, and in August 1982, a UN World Assembly on Ageing took place in Vienna, Austria. Ageing and old age are fast becoming one of major medical problems.

At the 9th Gerontological Congress in Grenoble, Heikinnen of Finland referred to a far higher death rate among old people compared with the average figures at intensive care units.

This particular problem was dealt with at our burns intensive care unit during the last ten years. Patients over 65 years of age with 2nd- to 3rd-degree burns involving 15 % and more of the body surface were selected for the study.

During the 1970—1979 period, a total of 1102 patients were treated at the intensive care unit, thereof 163 old people (14.8 %). 242 of them died, thereof 106 over the age of 65 (43.8 %).

In the 1980—1981 period, 31 out of the 146 admitted were old people, (21.2 %). A total of 36 of them died, thereof 27 over the age of 65 (75 %).

	I: 1970—1979		
admitted	1102	died	242
old people	163	died	106
	II: 1980—1981		
admitted	146	died	36
old people	31	died	27

Group II: 15 men, 16 women, thereof 7 aged 65—70 years
7 aged 71—75 years
8 aged 75—80 years
9 aged 81—88 years

17 patients had burns covering 15—20 %, 14 more than 20 % total body area. The causes included 25 cases of fire burns, 4 cases of contact thermal injury, and only 4 cases of scalding. The causes of death were shock (12 cases), bronchopneumonia (5), sepsis (4), embolism (3), acute myocardial infarction

(2), cardiac failure with pulmonary oedema (1 case), all verified at post mortem examination. The shortest period of survival was 1 day, the longest 23 days.

In order to better understand the problem of therapy in old people, some of the facts recently revealed by gerontology have to be borne in mind:

It is difficult to determine the physiological dividing line between longevity and pathological old age with a view to singling out at-risk patients. Functional age does not coincide with calendar age. Ageing appears to be more of a problem in women: there are 212 eighty-year-old women per only 100 men of equal age. Susceptibility to disease rises with age, the syndromes are often atypical (e. g. absence of temperature or leucocytosis in inflammations, or the absence of stenocardia in myocardial infarction, etc.). Besides, old people tend to interpret the symptoms differently — dyspnoea and cardiac embarrassment are often dismissed as just part of old age trouble and never reported to the clinician.

The clinical picture is marked by a tendency to complications, to chronicity, polymorbidity, microsymptomatology, and there is often exacerbation of some other concomitant complaint in what is known as the acceleration phenomenon. Old people's social situation has an increasingly greater role to play.

The following are the most frequent complicating factors: impaired quality of consciousness, breakdown of acid-base balance, metabolism and water economy, susceptibility to trophic defects, micturition disorders, "acute immobilization syndrome".

Ageing in the clinical sense of the word means qualitative and irreversible changes in essential physiological functions. This should be borne in mind in the assessment of alterations arising from burns in old people as well as in devising therapeutical strategy such as the number of operations and narcoses, dosage of infusion solutions and drugs.

As for the circulatory system, cardiac output and stroke volume are often as much as halved in those over 70 years. There are frequent arrhythmias, especially ventricular extrasystoles, fibrillation, various forms of heart block, bradycardia. About 69 % of those over 70 exhibit pathological changes in the ECG. There are frequent sclerotic vascular changes, particularly in the aorta. Peripheral resistance increases, hypertension is a frequent occurrence. Microcirculation, too, so important in burned patients, becomes impaired.

CNS disorders, which had better be referred to as organic psychosyndrome, are due to cerebrovascular sclerosis in only about 40 % of the cases. Most of them are cases of functional deficiency with the changes taking place at the level of metabolic disturbances, particularly glycoregulation impairment (glucose has a key role to play as a source of energy for brain cells).

Renal functions deteriorate, there is a drop in the amount of glomerular filtration, obviously because of decreased blood flow through the kidneys as a result of vascular changes. The concentration capacity grows less with the distal tubules unable to step up sodium ion absorption during dehydration. The dilution capacity is on the decline, too, as a result of decreased renal reactivity to the action of the antidiuretic hormone. Where the intake of water

is excessive the old patient cannot eliminate the extra water load quickly enough. Similarly, renal drug clearance shows signs of slowing down. For that reason, special care should be taken in determining the doses of infusion and drugs, particularly cardiotonics, antibiotics, diuretics, etc.

Since old people tend to lose the sensation of thirst, they may sometimes become dehydrated. Hence the need to check serum and urine osmolality.

Gastrointestinal disorders are also frequent, apparently in connection with disordered blood supply arising from vascular sclerosis in the mesenterial region. Gastric ulcers are a more frequent occurrence than duodenal ulcers, they tend to be larger and bleed. Intestinal peristalsis is also often disordered. The liver tends to have lower and slower detoxication capacity.

Diabetes mellitus is a frequent companion in old age. There are 6 % diabetics in the population of the 60- to 70-years-olds, after the age of 70 the figure is 10 %.

Anaemia and hypovitaminosis are also signs of old age. Last but not least, there is an equally important factor: the old people's social situation. Here we refer to what is known as the asylum syndrome on placing the patient in an old people's home. Similar syndromes can be seen in our department, too, where no visitors are allowed. The patient feels isolated, abandoned.

The burn disease is, as we know, accompanied by metabolic, water economy and circulatory disorders (shock, shock kidney), toxo-infectious liver damage, stress ulcerations of the gastrointestinal tract, altered haematopoiesis and haemocoagulation, vitamin deficiency. In other words, damage is caused to systems and functions which in old people have already undergone premorbid impairment and other changes. Hence why they are threatened far more than younger individual with equal burns. A thoughtful approach to therapy and the creation of a favourable atmosphere around the elderly may perhaps help us reach better results at intensive care units than in the past.

J. H.

SUMMARY

The mortality of old people treated at the intensive care unit of a burns department is examined. The authoress stresses physiological functional changes in the elderly and the need for bearing those alterations in mind in diagnosing organ function disorders concomitant to the burn disease and in choosing appropriate therapeutical strategy.

RESUME

Problématique des vieillards brûlés

Želízková, V.

L'auteur apporte les donnés de la mortalité des vieillards, hospitalisés au Centre des brûlures, dans le département des soins intensifs.

La connaissance des changements physiologiques fonctionnels des vieillards a l'importance pour le diagnostic des troubles fonctionnels des organes chez les brûles autant que pour le choix de la meilleure thérapie.

ZUSAMMENFASSUNG

Gerontologische Problematik bei der Verbrennungskrankheit

Želízková, V.

Die Arbeit berichtet über die Mortalität der Geronten in der Einheit für Intensivbetreung der Abteilung für Verbrennungen. Hervorgehoben wurden die physiologischen Funktionsveränderungen bei den Geronten sowie die Notwendigkeit ihrer Kenntnis bei der Beurteilung der als Folge der Verbrennungskrankheit auftretenden Störungen der Organfunktionen bei der Wahl der entsprechenden Therapie.

RESUMEN

Problemática gerontológica en las enfermedades por quemaduras

Želízková, V.

Se informa sobre la mortalidad de los gerontes trasladados a la unidad de tratamiento intensivo de la sección de quemaduras. Se subrayan las alteraciones fisiológicas de las funciones en los gerontes y la necesidad de que se conozcan y tomen en cuenta al evaluar los defectos en las funciones de órganos como consecuencia de las enfermedades por quemaduras al elegir la adecuada terapia.

REFERENCES

1. **Pacovský, V.:** Pathological Specificities of Ageing and Old Age (in Czech). Vnitřní Lék., 9, 918, 1981.

2. **Osten, A. et al.:** Problems of Renal Dilution Capacity in Old Age (in Czech). Vnitřní Lék., 11, 1098, 1981.

3. **Spáčil, J., Kolbel, M.:** Syncope in the Elderly (in Czech), Prakt. Lék., 61, 1981.

4. **Pacovský, V.:** Symptoms and Syndromes of Old Age and in Old Age (in Czech). Prakt. Lék., 61, 1981.

5. **Reban, O.:** 9th European Congress of Clinical Gerontology. Čas. Lék. čes., 7, 200, 1981.

6. **Reban, O.:** 12th International Gerontological Congress. Čas. Lék. čes., 5, 155, 1982.

Dr. V. Želízková, Lidových milicí 63, 120 00 Prague 2, Czechoslovakia

CONTENTS

Hrivňáková J., Fára M., Mullerová Ž., Měšťák J.: Maxillary Development in Facial Clefts after Primary Bone Implantation and after Bridging the Gap with a Periosteal Flap — a Comparison 57

Troshev K.: Skin Plastic Operation for Spina bifida 66

Gulyás G., Kartik I., Takács L.: Latissimus Dorsi Musculocutaneous Island Flap for the Reconstruction of Soft Tissue Defects of the Upper Arm 72

Maruyama Y., Ohnishi K., Hashimura C.: Functional Reconstruction of Anal Constriction Using a Gracilis Musculotaneous Flap 76

Sidorov S. D.: The Tubed Flap in Plasty of Extended Resections of the Lower Part of the Face 81

Anitchkin V. V., Satchek M. G.: Resection of the Bifurcation of the Trachea. An Experimental Study 88

Yunina A. I.: Epiglottopexia and Laryngopexia. Indications, Methods and Results of the Operations 95

Jíchová E, Königová R., Prusík K.: Acupuncture in Patients with Thermal Injuries 102

Želízková V.: Gerontological Problems in Burn 109