ACTA CHIRURGIAE PLASTICAE

INTERNATIONAL JOURNAL
OF PLASTIC SURGERY

28 · 1

1986

CS ISSN—0001—5423

AVICENUM - CZECHOSLOVAK MEDICAL PRESS
PRAGUE

Exclusive Distributors for all Western Countries
KARGER-LIBRI AG, Petersgraben 31, CH-4000 Basel 11 (Switzerland)

Distributed by PNS. Information on subscription can be obtained from and orders are accepted by every administration of PNS, post-office, postman and PNS Central Expedition Prague. Orders for abroad are accepted by PNS Central Expedition and Press Import, administration of press export Kafkova 19, 160 00 Praha 6.

Published four times (in 1959: two times) a year by Avicenum - Czechoslovak Medical Press, Malostranské nám. 28, Praha 1. Editor in Chief Prof. H. Pešková, M. D. — Address of the Editorial Office: Acta Chirurgicae Plasticae, 120 00 Praha 2, Lidových milicí 63, Czechoslovakia. — Press: Tiskařské závody, n. p., Praha, závod 3 — provoz 33, Praha 2, Hálkova 2.
Subscription rate: Sfr 143 — plus postage, Exclusive distributors for all countries with the exception of Albania, Bulgaria, China, Cuba, Czechoslovakia, German Democratic Republic, Hungary, North Korea, Vietnam, Mongolia, Poland, Romania, the Union of Soviet Socialist Republics and Yugoslavia:
KARGER LIBRI AG, Petersgraben 31, CH-4000 BASEL 11 (Switzerland)

Comenius University Medical Faculty, Bratislava (Czechoslovakia)
Chair of Reconstructive Surgery
Head Prof. E. Huraj, M. D., Dr. h. c., DrSc.
Department of Plastic Surgery
Head Prof. F. Mariš, M. D., CSc.

EFFECT OF LASER RAYS ON THE SKIN AND LASER FOR PLASTIC SURGERY USES

V. Sekan, M. Brozman, Š. Zboja, J. Janovič

Skin damage resulting from exposure to laser rays depends on the energy and duration of the flash, on skin pigmentation, and on the wave length of the radiation. It is manifested as a burn of various degrees. The exposed site is sharply delineated from intact tissue.

In his experiments of 1967 Goldman ascertained the following postulates:

1. The effect on the skin of laser radiation depends on pigmentation and vascularization
2. Hyperkeratotic skin is resistant to the effect of laser rays
3. The use of artificial dark pigments on the skin surface has an adjuvant effect
4. The resulting effect depends on the type of the laser radiation source, on the duration of exposure, on optical factors (focus ray), on the amount ef energy per 1 cm^2

In 1981, Plenk jr. and co-workers made experimental morphological assessments of white rat skin sections following incision with a classical scalpels, CO_2 laser, and electrocautery. A fresh laser scalpel incision produced a carbonization zone merely 30 micrometres thick, a necrotic zone 300 micrometres thick with the zone of temporary damage reaching 500 to 700 micrometres. In the transiet damage zone there was hyperaemia and oedema with open blood and lymphatic vessels (Fig. 1, 2). Manifest granulocytic demarkation started within 24 hours.

A fresh electrocautery incision is noted for its broader necrotic as well as demarkation zones. With a scalpel the zone of necrotic is the narrowest and wound edge damage the least.

After seven days, laser-incised skin is devoid of necrosis, the surface is pre-epithelialized, and the tissue loss made up for by granulation tissue. The scalpel incision is healed, with the electrocautery incision superficial epithelization is still missing. In other words, the healing process following incision with laser and the conventional scalpel is comparable and only slightly prolonged in the former.

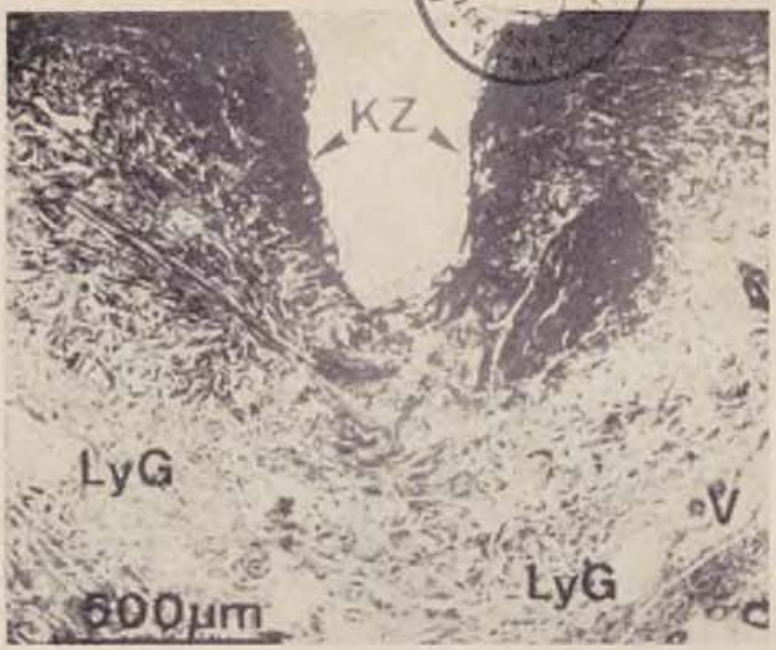

Fig. 1 — Fresh incision of human skin with CO_2 laser (KZ — zone of carbonization, V — open vein, LyG — open lymphatic vessel), Plenk H. jr. (1981)



Fig. 2 — Fresh incision of rat skin with CO_2 laser (KZ — zone of carbonization, NZ — necrotic zone, SF — subcutaneous fat, SM — skeletal muscle). Skeletal muscle damage is discernible underneath vacuolized fat. Plenk H. jr. (1981)

Kaplan (1975) used laser rays to treat superficial teleangiectasis as well as onychogryphosis with excellent results.

Tatto removal using laser dermabrasion was reported by Goldman (1967) as being free from hypertrophic scarring production or from secondary infection. At that time, laser dermabrasion was not routinely recommended for inadequate cytological and cytogenetic knowledge though the author never saw any signs of local or general damage in his patients within 3 years of the operation. Reid (1980) reported his 304-member group of patients with laser dermabrasion to display excellent cosmetic results.

Gamaleya (1974) in his Kiev institute treated over 500 dermatological patients. It seems worth mentioning that in using lower-energy laser rays he operates on his patients without anaesthesia, many of them on an outpatient basis.

The removal of tattoo and keloid scars has become the domain of argon laser surgery. The technique leaves no secondary skin deformities. Rhinophyma, too, is a regarding field of application.

Plenk jr. (1981) examined an interesting prerequisite of the effect of the laser scalpel. One of the generally accepted postulates is its effect on the blood and lymphatic vessels which obliterate after the application of CO_2 laser. This in practical terms means preventing tumour cells from metastatic spreading via the lymphatic and blood passages. For that reason, the extirpation of malignant skin growths is so often indicated for laser. Plenk compared Indian ink migration from incisions made with a scalpel, a laser scalpel and an electroscalpel. He made dorsal incisions on rats, contaminated the wound with Indian ink, and made histological examination of the regional lymph nodes. One point to be stressed, though, is that he used 6 to 10 W CO_2 laser. His experiments supplied unambiguous evidence to show that a laser incision is no guarantee for the prevention of cancer cells spreading metastatically through blood and lymphatic vessels as he found the presence of Indian ink elements in regional lymph nodes.

A special chapter deserves to be devoted to the stimulating effects of low doses of helium-neon laser and their favourable influence over the healing of defects of diverse aetiology and localization. Those observations were confirmed experimentally and successfully translated into clinical practice. Mester is a pioneer of the stimulation therapy with his wealth of studies and reports published over the past 15 years. The favourable healing effects are utilized in crural ulcers of any aetiology, in all types of decubitus ulcers, vascular skin necrosis, infectious inflammatory skin processes, in X-radiation injuries and capillary haemangiomas.

Following up those clinical experiments he used the same techniques in an effort to stimulate the healing of wounds caused mechanically or by electrocoagulation. Consequently, low, stimulating doses can activate the process of healing through accelerated granulation and epithelialization of wounds.

Stellar (1971) used carbon dioxide laser for the excision of burn eschars. In an experiment, he produced a 3rd-degree contact burn covering 20 % of the body surface. 24 hours afterwards he used laser to excise the eschars and

immediately covered the defect with a skin transplant. Union developed soon and remained intact throughout the 2-month post-operative follow-up period. Similarly, the laser rays produced no general or systemic complaints although a whole fifth of the experimental animal's body surface had been exposed to the radiation.

Stellar (1974) reported the use of continual-radiation CO_2 laser for the debridement of decubitus ulcers. He treated with very good results 5 bedsores in 4 patients in general anaesthesia. Laser debridement of large, infected decubitus ulcers with necrotic tissues is a rapid, effective and complete process. Subsequently, the defect was covered with a rotation flap or a skin transplant. 100% sterility was noted after the application. Using this process all the patients were healed.

Levine (1974) performed clinical escharectomy from an area of 15 % without any signs of local or general toxicity.

Madden (1970) compared resistance to the infection of wounds caused by the conventional scalpel, electrocautery and laser scalpel. Within five minutes of the incision he infected the wounds with a culture of Staphylococcus aureus and, in another five minutes, he closed the wounds with adhesive tape. The wounds caused by the classical scalpel were significantly more resistant to bacterial infection than those caused by the electrocautery or laser. The author puts this down to the presence of devitalized tissue, avascular or necrotic issue as this is more susceptible to infection in the contaminated wound.

Udod (1982) of Leningrad reports on 32 patients with soft tissue suppuration of various aetiology where a Skalpel-1 CO_2 laser with focussed radiation was used with a view to an early application of secondary suture. Following the laser operation the wound was sutured and the stitches were removed on the 9th post-operative day. The technique proved a success in 94 % of the patients.

A similar study was published by Korolenko (1982) of Kiev who, over a period of 2 years, had treated 81 patients with soft tissue suppuration (suppurative cysts, carbuncles and furuncles, post-injection abscesses, post-operative wounds, acute paraproctisis, phlegmons of lower extremities) using also a Skalpel-1 CO_2 laser without focussed and non-focussed radiation. He drained the secondary suture and washed it with antibiotics and 10% NaCl. He reports healing in 10 to 12 days.

The use of laser guarantees haemostasis and sterility, facilitates suture and cuts down the period of treatment.

Experimental wound healing (Piel in 1981 operated on monkeys of the Macaca mulatta species) is complete within 10 days of the operation. The author also operated on children with cleft palate aged two years with good results. The process of healing proved to be an uncomplicated affair.

Cochrane (1980) studies wound healing following incisions with scalpels, laser scalpels and electrocautery from a special aspect, namely testing 12-cm long incisions of 35-kg experimental pigs for strength. Scars resulting from conventional scalpel incisions proved to be the strongest. Using the same experimental animals he also studied free skin grafts healing in after scalpel

excision. This proved to be 81 %, following excision with CO_2 laser — 78 %, with electrocautery — 75 %. However, the uses of laser in plastic surgery are much wider, let us just recall Slutzki's study of 1977 — use of CO_2 laser for large excision with minimal blood loss. The main uses are the treatment of inveterate large squamocellular carcinomas of the face and nose with deep infiltration, or large vulvular haemangiomas. Laser also permits operating on patients with impaired haemocoagulation and facilitates approach to otherwise inoperable lesions.

The following are some of the advantages of the laser scalpel compared with the other techniques

1. Well delineated incision with fine edges requiring no direct cutting tool contact with the tissue surface. The cellular layers destroyed as a result of thermocoagulation necrosis are very thin.
2. Capillary bleeding is totally suppressed in the small vessels thanks to the microtrombosing effect; arterial bleeding, if present, can be arrested by repeated coagulation using the laser ray.
3. The wounds heal very well and soon without producing any major fibrosis in the vicinity; they are a good match for the conventional scalpel with good resistance to common infection.
4. Absolute sterility of the incision is another advantage.
5. Wound resistance to secondary infection is poorer only in cases of massive inoculation of the fresh wound. In infected wounds laser exhibits a sterilizing effect.

SUMMARY

More types of laser radiation are of use in plastic surgery — argon, crypton, helium-neon and carbon dioxide laser scalpels. The first two are used in dermatological indications and for tattoo removal, helium-neon laser stimulates wound healing (defects of diverse aetiology). Carbon dioxide laser can be put to the same uses as the conventional scalpel with many advantages over the latter but also some specific shortcomings of technical rather than medical nature. The uses of laser for oncological purposes is referred to in another study.

RESUME

L'effet du rayonnement laser exercé sur la derme et l'application des lasers dans la chirurgie plastique

Sekan, V., Brozman, M., Zboja, Š., Janovič, J.

Dans la chirurgie plastique, plusieurs sortes du rayonnement laser peuvent être utilisées. Ce sont: laser à argon, laser à krypton, laser à hélium-néon, bistouri-laser à gaz carbonique. Deux premiers sont utilisés aux indications dermatologiques et dans le traitement du tatouage. Le laser à hélium-néon stimule la guérison des plaies (défauts d'étiologie variée). Le laser à gaz carbonique est utilisé comme bistouri avec de multiples avantages sur le bistouri classique bien que son utilisation ait quelques insuffisances du genre plutôt technique que medical. L'application du laser dans la pratique cancérologique est traitée dans un autre travail.

ZUSAMMENFASSUNG

Die Wirkung von Laserbestrahlungen auf die Haut und die Verwendung von Laserstrahlen in der plastischen Chirurgie

Sekan, V., Brozman, M., Zboja, Š., Janovič, J.

In der plastischen Chirurgie kann man mehrere Arten Laserbestrahlungen verwenden. Es sind dies: Argon-, Krypton-, Helium-Neon- und Kohlendioxid-Laserskalpelle. Die ersten beiden werden bei dermatologischen Indikationen sowie bei der Behandlung von Tätowierungen verwendet, Helium-Neon-Laser stimulieren die Heilung von Wunden (Defekten verschiedener Ätiologie), und Kohlendioxid-Laser wird als Skalpell verwendet, das gegenüber den klassischen Skalpellen viele Vorteile hat, jedoch auch spezifische Mängel eher technischer als medizinischer Art. Über die Ausnutzung von Lasern in der onkologischen Praxis wird in einer anderen Arbeit gesprochen.

RESUMEN

Efecto de la radiación de rayos laser sobre la piel así como la utilización del laser en la cirugía plástica

Sekan, V., Brozman, M., Zboja, Š., Janovič, J.

En la cirugía plástica podemos utilizar varios tipos de radiación laser, a saber: el bisturí de argón, criptón, helio-neón y CO_2. Los dos primeros los utilizamos por indicaciones dermatológicas y en el tratamiento de los tatuajes. El de helio-neón estimula la cicatrización de la llagas (defectos de diferente etiología). El laser CO_2 se aplica como bisturí con muchas ventajas frente al bisturí clásico, sin embargo su utilización tiene también varios defectos específicos más bien de carácter técnico que de medicina. Sobre la implementación del laser en la práctica oncología nos ampliamos en otro trabajo.

REFERENCES

1. **Cochrane, J. et al.**: Wound healing after laser surgery — an experimental study. Brit. J. Surg., 67, 10 : 740, 1980.
2. **Cotterill, J.**: Laser treatment of port-wine stains. Brit. Med. J., 284, 6, 318 : 766, 1982.
3. **Finsterbusch, A. et al.**: Healing and tensile strength of CO_2 laser incisions and scalpel wounds in rabbits. Plast. reconstr. Surg., 70, 3 : 360, 1982.
4. **Fry, T. et al.**: Effects of laser, scalpel and electrosurgical excision on wound contracture and graft "take". Plast. reconstr. Surg., 65, 6 : 729, 1980.
5. **Kaplan, I.**: Current CO_2 laser surgery. Plast. reconstr. Surg., 69, 3 : 552, 1982.
6. **Korolenko, V.**: Laser scalpel treatment of suppurative soft tissue diseases. Klin. Chir., 1 : 41, 1982.
7. **Mester, E. et al.**: Biostimulating effect of laser beams. Z. exp. Chir., 15, 42 : 67, 1982.
8. **Piel, H. et al.**: Animal experiment and clinical studies on the use of the laser in the plastic repair of cleft palate. Dtsch. zahnärtzl. Z., 36, 3 : 175, 1981.
9. **Udod, V. et al.**: Use of Scalpel-1 apparatus in treating suppurative soft tissue wounds. Klin. Chir., 40, 1, 1982.
10 **Vojtenjuk, N. et al.**: Effect of laser radiation on wound microflora. Vest. Chir., 126, 4 : 76, 1981.

For other references contact the author

Dr. V. Sekan,
Dept. of Plastic Surgery,
Partizánska 2, 813 26 Bratislava,
Czechoslovakia

Teaching Hospital in Motol, Prague (Czechoslovakia)
Department of Neurosurgery
Head As. Prof. V. Beneš, M. D., CSc.
Central Military Hospital, Prague
Department of Stomatic and Facial Surgery
Chief As. Prof. T. Németh, M. D., DrSc.

SURGICAL TREATMENT OF CRANIOSYNOSTOSIS IN CHILDREN

I. Škodová, J. Kozák

The first reports on the surgical treatment of craniosynostosis date back to Langelongue writing in 1890. He and his followers tried to devise a surgical operation to prevent the build-up of intracranial pressure in cases of premature closure of the cranial sutures. Their approach was one of linear discision of the sutures concerned, later on morcellation (mosaic-like osteotomy of the calvaria) or the ablation of the whole skullcap. Most of those operations were only partially successful, and nearly all produced but poor cosmetic results.

Tessier, Converse and others making use of their experience with shifting the medial portions of the face and orbits proposed, for severe craniofacial deformities of the Crouzon's and Apert's syndrome type, the advancement of the supraorbital bones and an extension of the anterior cranial fossa as part of the remodelling operation. The favourable results of those operations as a prevention of the intracranial hypertension syndrome and an improvement on the victim's appearance prompted the establishment throughout the world of centres for the treatment of craniosynostosis as well as the development of a new surgical specialty — craniofacial surgery.

Since in this country the children thus affected had not always been treated comprehensively, our effort was to develop a team capable of dealing with those anomalies. All the children are now hospitalized at the Department of Neurosurgery of the Teaching Hospital in Prague-Motol where optimum conditions are available for the surgery proper and for post-operative care.

Our own experience

We operated on a total of 21 children with simple craniosynostosis (premature closure of one or more sutures of the skullcap without any major facial deformation) and 17 children with complex craniosynostosis (affecting one or more calvarial sutures with facial deformation).

In operations for scaphocephaly at any age we discise a free bony flap over the sagittal sinus and create one to three free bony flaps parietooccipitally

from either side. Of late, we have been trying to operate on both sides simultaneously from an extended bicoronal incision using a modification of our own. Its principle consists in that we fix the entirely mobilized insertion of the temporal muscle with a few silon sutures to the upper edge of the mobilized temporal bone. The muscle function then helps to press the fragments sideways and, consequently, to remodel the shape of the head sooner (Fig. 1).

To treat simple synostosis of the coronary suture in young children we now prefer using McCarthy's modification incising the coronal suture as far down as the inferior orbital fissure. The bicoronal incision must be sufficiently long for precise and safe mobilization in the temporal fossa region. In older children we proceed as in cases of complex synostosis.

All patients with complex craniosynostosis (craniofacial malformations) had the frontal region remodelled using the rotation and exchange of 2 to 4 bony flaps and the supraorbital bones advanced 1 to 1.5 cm involving the creation of a peg-and-socket joint. Of late, wherever possible, we have been trying to create the peg more cranialward (Fig. 2) to avoid unnecessary blind operation deep in the middle cranial fossa. The new position of the advanced supraorbital arch in young children is fixed with absorbable suturing material. We have found PDS and Vicryl made by the Ethicon company quite useful. This permits more movement of the mobilized portion under the pressure of the growing frontal lobes. In some cases we choose to prevent the peg-and-socket joint from relapsing by using small bony grafts from the skullcap according to Hoffman.

Fig. 1a A three-month old girl with scaphocephaly. Condition prior to surgery. — Fig. 1b 3 week after bony flap release in the authors' own modification

Most of our patients suffered from cranial deformities of such a degree that a complete remodelling of the anterior half or most of the calvaria was necessary (Fig. 4, 5). The correction involved the exchange and rotation of bony flaps as proposed by Marchac. In cases of severe and asymmetrical deformations we model and plan the surgical strategy on a plaster-of-Paris cast

Fig 2 Released supraorbital bones with a "peg" created in the temporal bone — photographed during operation

of the head. In some children we had to adapt the shape of the bone segments to avoid the development of irregularly prominent edges. The technique involves a fine incision of the lamina interna and gentle bending of the bone (Fig. 5). As a result, none of our patients developed any major deformities requiring surgical removal at any time later on.

At first, we used grafts from the hip bone for the correction of hypertelorism in two children to make the mobilized segments safely blocked against any possible relapse. Now we can do with grafts from the skullcap which we either excise and use as a full-thickness piece or split, if the bone is thick enough, using only the inside portion as a graft.

Several children had homologous deproteinized bone grafts implanted the way they are used, invariably with good results, in neurosurgery. Smaller grafts took without complications. In one patient with a craniofacial cleft and a huge encephalocele where a larger number of grafts had been used these had to be removed after a few weeks for osteomyelitis. We are beginning to use demineralized bone grafts as recommended by Mulliken. We are still building up sufficient experience but the results so far seem to be encouraging.

Fig. 3a A 7-month old boy with premature closure of the coronal suture on the left. Condition prior to surgery — Fig. 3b One year after the left supraorbital margin advancement with forehead remodelling

Fig. 4a 2.5 year old girl with Apert's syndrome. Condition prior to surgery — Fig. 4b One year after supraorbital bones advancement with forehead remodelling

RESULTS

Using these techniques we operated on 21 cases of simple craniosynostosis in six years and on 17 cases of complex craniosynostosis over a period of 4 years (we have been using Tessier's method only since 1981). These were 18 cases of scaphocephaly, 3 cases of brachycephaly. 5 children had Crouzon's syndrome, 6 had Apert's syndrome, 1 girl had Cohen's syndrome (turricephaly

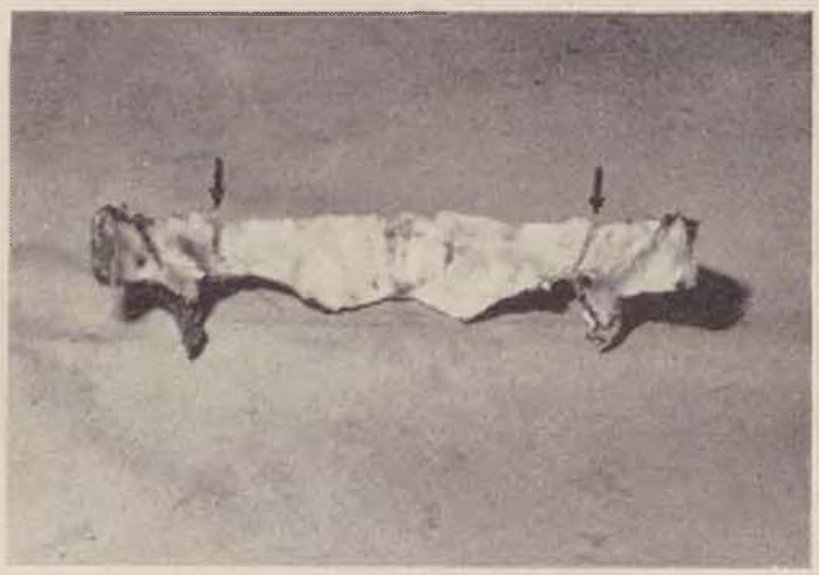

Fig. 5 Supraorbital bones remodelled at two points by incision of the lamina interna (arrows) — photographed at the time of operation

with hypertelorism and nasal cleft). 2 children were found to have synostosis of all the sutures, 2 had anterior plagiocephaly (closure of one half of the coronal suture) and 2 patients had craniofacial malformations with clefts. The children's age at operation was 3 months up to 12 years.

One girl with Apert's syndrome died post-operatively due to acute cardio-respiratory insufficiency because of undiagnosed associated malformation of the upper respiratory tract. In one case we had to resort to reoperation for suppurative complications in the patient with the huge encephalocele and craniofacial cleft. In two cases transient rhinorrohoea was noted in the post-operative course, and there was one case of major bleeding in the gastroin-testinal tract. Administering mannitol and corticoids during and on the first day after operation we could see no neurological complaints nor any complica-tions with the extended epidural space which results from the advancement of the supraorbital bones.

The cosmetic effect in all the surgical patients is satisfactory, none of them has had to be reoperated on either for the intracranial hypertension syn-drome or for cosmetic reasons.

CONCLUSION

We have been treating craniosynostosis surgically for 6 years now, and four years ago we formed a craniofacial team for the treatment of children with craniofacial malformations. Concurrently with a whole number of authors we believe that the children thus affected ought to be operated on at the tender age of several months prior to the development of irreversible brain damage and severe craniofacial deformities. Patients with simple synostosis are referred to surgical treatment in good time, most of them were operated on before reaching the age of one year, and without any complications. The rest of them vere indicated for surgery with severe deformities, often with the intracranial hypertension syndrome and mental involvement.

We are convinced that even better short- and long-term results can be achieved through early indication, improvements in the surgical technique and shorter operating time. For those reasons, paediatricians should be continually made aware of the opportunities for operating on the children thus affected at a specialized unit.

SUMMARY

Some encouraging results have been achieved in the surgical treatment of simple craniosynostosis and craniofacial malformations in childhood. The authors present the results with the surgical technique in 38 children. Scaphocephaly was successfully treated in a single-time operation involving the mobilization of bony flaps in the authors' own modification. Complex synostosis (craniofacial malformation) was dealt with by supraorbital bones advancement with remodelling the anterior half of the skullcap. To do so the authors use partial incisions of the bone with osteoplasty using demineralized bone grafts.

RESUME

Le traitement opératoire des craniosynostoses chez des enfants

Škodová, I., Kozák, J.

Les résultats du traitement opératoire des simples synostoses ou des malformations craniofaciales à l'âge enfantin sont encourageants. Les auteurs allèguent leurs résultats et leur technique opératoire du traitement de 38 enfants. Chez les scaphocéphalies, l'opération a un temps avec le dégagement des lobes osseux, dans une propre modification des auteurs, a fait ses preuves. Les synostoses complexes (malformations craniofaciales) sont résolues par l'avancement du squelette d'arcade orbiculaire avec le remodelage de la moitié antérieure de la calve. Comme méthode de modelage les auteurs ont choisi les entailes des os avec une ostéoplastie par des greffes osseuses démineralisées.

ZUSAMMENFASSUNG

Operative Behandlung von Kraniosynostosen bei Kindern

Škodová, I., Kozák, J.

Die Ergebnisse operativer Behandlungen einfacher Kraniosynostosen sowie kraniofacialer Deformierungen im Kindesalter sind ermunternd. Die Autoren führen Er-

gebnisse sowie die Operationstechnik von Operationen bei 38 Kindern an. Bei einer Skaphozephalie hat sich eine einmalige Operation mit Lockerung der Knochenlappen in eigener Modifizierung bewährt. Komplexe Synostosen (kraniofaciale Deformierungen) werden durch Herausschieben des Skeletts über den Augen und Remodellierung der vorderen Hälfte der Schädelwölbung behandelt. Die Autoren verwenden zur Modellierung teilweise Knochenschnitte sowie Osteoplastik mit demineralisierten Knochenpfropfen.

RESUMEN

Tratamiento aperativo de las craniosinostosis en los niños

Škodová, I., Kozák, J.

Las soluciones de malformaciones craniofaciales y craniosinostosis no complicadas en la edad infantil resultan alentadoras. Los autores publican los resultados y la técnica de operación en 38 niños. En el caso de las escafocefalías dió buenos resultados el procedimiento a base de una sola operación con la soltura de lóbulos óseos en la modificación propia. Sinostosis complicadas (las malformaciones craniofaciales) se resuelven mediante un desplazamiento hacia afuera del esqueleto supraorbital junto con la remodelación de la parte frontal de la calva. Los autores utilizan para la modelación cortes parciales de los huesos y la osteoplástica mediante injertos óseos desmineralizados.

REFERENCES

1. **Hoffman, H. J., Hendrick, E. B.:** Early neurosurgical repair in craniofacial dysmorphism. J. Neurosurg., 51 : 796, 1979.

2. **Hoffman, H. J., Mohr, G.:** Lateral canthal advancement of the supraorbital margin. A new corrective technique in the treatment of coronal synostisis. J. Neurosurg., 46 : 376, 1976.

3. **Kozák, J., Škodová, I. et al.:** More scope for the surgical treatment of craniofacial malformations (in Czech). Čs. Pediat., 39 : 468, 1984.

4. **Kozák, J., Škodová, I. et al.:** Current scope for surgery in craniofacial malformations (in Czech). Rozhl. Chir., in press.

5. **Kozák, J., Škodová, I. et al.:** Stomatosurgical and neurosurgical co-operation in the treatment of craniofacial malformations (in Czech). National Symposium of Plastic Surgery, Žinkovy, Dec. 5—7, 1984.

6. **Marchac, D.:** Radical forehead remodelling for craniostenosis. Plast. reconstr. Surg., 61 : 823, 1978.

7. **McCarthy, J. et al.:** Early skeleton release in the infant with craniofacial dysostosis. Plast. reconstr. Surg., 62 : 335, 1978.

8. **Mulliken, J. B., Glowacki, J.:** Induced osteogenesis for repair and construction in the craniofacial region. Plast. reconstr. Surg., 65 : 553, 1980.

9. **Shillito, J., Matson, D. D.:** Craniosynostosis: a review of 819 surgical patients. Pediatrics, 41 : 829, 1968.

10. **Tessier, P.:** Ostéotomie totale de la face: syndrome de Crouzon, syndrome d'Apert: oxycéphalie, saphocéphalie, turicéphalie. Ann. Chir. plast., 12 : 273, 1967.

For other references contact the authoress.

Dr. I. Škodová,
Teaching Hospital Prague-Motol,
Dept. of Neurosurgery,
V úvalu 84, 150 18 Prague 5,
Czechoslovakia

Czechoslovak Academy of Sciences, Prague (Czechoslovakia)
Institute of Experimental Medicine
Director As. Prof. J. Elis, M. D., DrSc.

CRANIOFACIAL DEVIATIONS IN BILATERAL COMPLETE CLEFT LIP AND PALATE AFTER EARLIER PRECEEDING OSTEOTOMY

Z. Šmahel

In our previous study were described craniofacial changes in adult males with bilateral complete cleft lip and palate (Šmahel, 1984). The main deviations consisted of retrusions of the upper and lower jaws with a particularly marked retroinclination of incisors and of the maxillar alveolar process. The face was prolonged and showed posterior rotation. During our studies we have seen eight individuals with this type of cleft subjected previously to Le Fort I osteotomy with displacement of individual segments of the maxilla forwards. The present communication analyses craniofacial changes in these individuals and their comparison with the findings in patients without previous maxillofacial surgery.

MATERIAL AND METHODS

The series examined included Czech adult males ranging in age from 22 to 28 years (mean age 25.1 years) who were subjected three to twelve (on the average 7.5) years ago to Le Fort I osteotomy. All patients had bilateral complete cleft lip and palate ($BCLP_c$) without any associated malformations. Primary cheiloplasty according to Tennison or Veau was carried out, on the average, at age of 9.0 months on the right and 11.9 months on the left. Palatoplasty consisting of retroposition and pharyngeal fixation was performed at the mean age of 5.8 years (between 4.7 and 7.4 years). These data were consistent with those in the compared series of individuals with $BCLP_c$ without osteotomy, with the exception of the age at the time of lip suture on the left which was higher (contrary to 7.3 months). One patient was during childhood subjected to premaxillary setback (as compared to 35 % in individuals without osteotomy) and five had a surgically enlarged vestibular sulcus (similarly as 46 % in $BCLP_c$ without osteotomy). All affected individuals had a surgical prolongation of the columella and in the region of the lip and nose were performed on the average 2.8 repairs per patient (as compared to 2.0 in $BCLP_c$ without osteotomy). Three individuals were subjected to closures of palatal perforations (similarly as 42 % of individuals with $BCLP_c$ without osteotomy). The primary surgical repairs were carried out between 1952 and 1963 incl.

The roentgenographic method and the interpretation of X-ray films were described in one of our previous reports (Šmahel and Brejcha, 1983). The craniometric points used in our studies are presented on Fig. 1. In order to exclude the effect of premaxillar position on the depth of the upper jaw we have de-

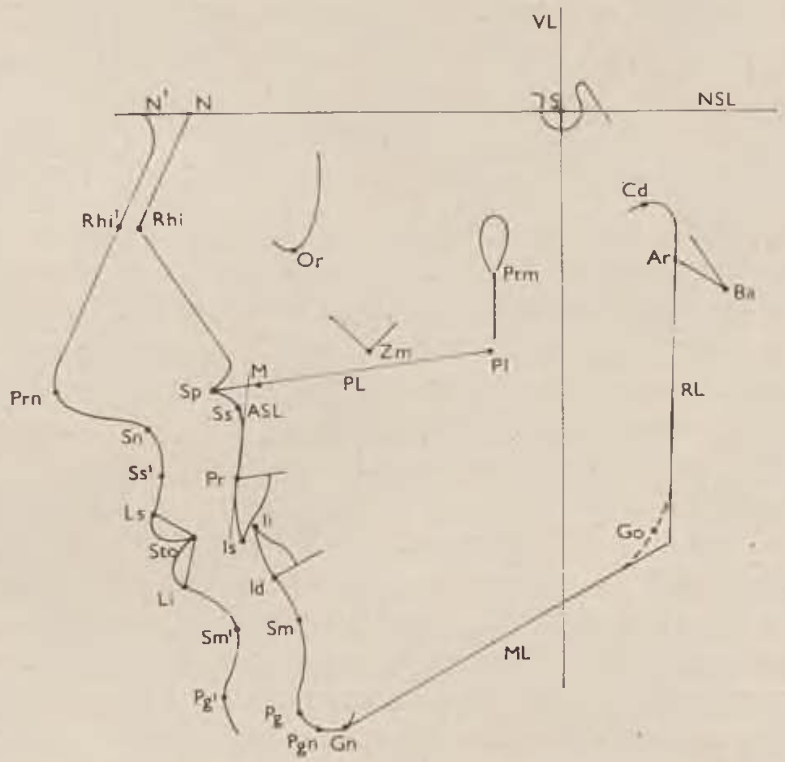

Fig. 1. Cephalometric points used in the study (reference lines: PL = palate line through Sp and Pl, ASL = tangent to the maxillar alveolar process through Pr)

termined, in addition, point M representing the point of intersection of the palatal plane with the perpendicular line dropped from the anterior wall of the canine at the site of its penetration into the alveolus. The results obtained were compared with the situation in individuals with the same type of cleft without any kind of maxillofacial surgery inclusive of premaxillary setback. These individuals were analysed in detail in the above mentioned study (Šmahel, 1984). The results were tested with the F-test and with the t-test. In tabellar form are presented only characteristics which showed some differences between the compared series. For a more precise illustration the craniograms obtained include also those in controls (the upper incisors are not plotted in individuals subjected to osteotomy since they were missing in all cases).

Since the Le Fort type of osteotomy was not carried out in close co-operation with plastic surgeons from the Department for Plastic Surgery in Prague, who did not advocate the use of such extensive maxillar surgery in patients with clefts, we have had neither preoperative nor immediately postoperative X-ray films which would have allowed an assessment of the original condition. This resulted in limitations during the interpretation of the findings. The

patients had a mean body height 175.5 cm which was similar to that recorded in patients with $BCLP_c$ without osteotomy (175.2 cm) as well as in controls (176.8 cm). With the exception of the maxilla, all roentgencephalometric characteristics were identical with the corresponding characteristics in individuals without maxillofacial surgical interventions and thus confirmed that the investigated series of patients was not influenced by any accidental factors which could be due to small number of cases.

RESULTS

The results disclosed (Tab. 1, Fig. 2) that the upper jaw, or more precisely the premaxilla showed a somewhat more marked retrusion in patients subjected to an osteotomy than in patients without this surgical procedure (S-N-Sp, S-N-Ss). In spite of the marked retrognathia of the mandible the sagittal maxillomandibular relations were disturbed (Ss-N-Sm) while in individuals without osteotomy they were similar to those in controls. There was only a small difference in the position of lateral maxillar segments (S-N-M). However, individuals subjected to osteotomy had a slighter retroinclination of the dentoalveolar process, and thus of the premaxilla (ASL/PL). The depth of the upper jaw as a whole (Ss-Pl, Sp-Pl) was also somewhat greater in patients without osteotomy. This dimension was influenced by the degree of protrusion of the premaxilla (Sp-M and M-Pl). However, none of the described differences attained the significance level, which was in many cases due to the small number of patients subjected to osteotomy. There were no differences in the configuration of the soft profile between the compared series (Fig. 2). Significant differences were recorded in two characteristics concerning simultaneously the soft tissue and the skeletal profile. The distance between the anterior spina and the tip of the nose (Prn-Sp) and the "thickness" of the upper lip (Ss_t') represent two characteristics which due to the more marked retrusion of the premaxilla are larger in individuals subjected to osteotomy than in the other affected patients.

Tab. 1. Mean values in patients with complete bilateral cleft lip and palate subjected previously to facial osteotomy (ost.) and in patients without any maxillofacial surgery (nonost.)

Linear	Ost.	Nonost.	Control	Angles	Ost.	Nonost.	Control
Ss-Pl	52.38	54.00	52.40	S-N-Sp	77.38	80.59	85.22
Sp-Pl	57.25	59.47	56.70	S-N-Ss	73.25	75.24	80.68
Sp-M	16.75	20.00	8.78	S-N-M	62.12	62.53	76.42
M-Pl	40.25	39.65	47.72	Ss-N-Sm	−0.12	1.95	2.48
Prn-Sp**	32.25	26.65	32.30	ASL/PL	91.38	87.38	107.60
Ss_t'*	15.25	12.53	14.80	S-N-Zm	48.00	48.47	53.44

* significant differences between patients with and without osteotomy at $p<0.05$ (** $p<0.01$)

During an individual assessment the angle of sagittal maxillomandibular relations (Ss-N-Sm) was highly negative in three patients treated by osteotomy (—3° or more) and in four patients it was below the average observed in patients without osteotomy (1°). Though in the four latter patients this angle

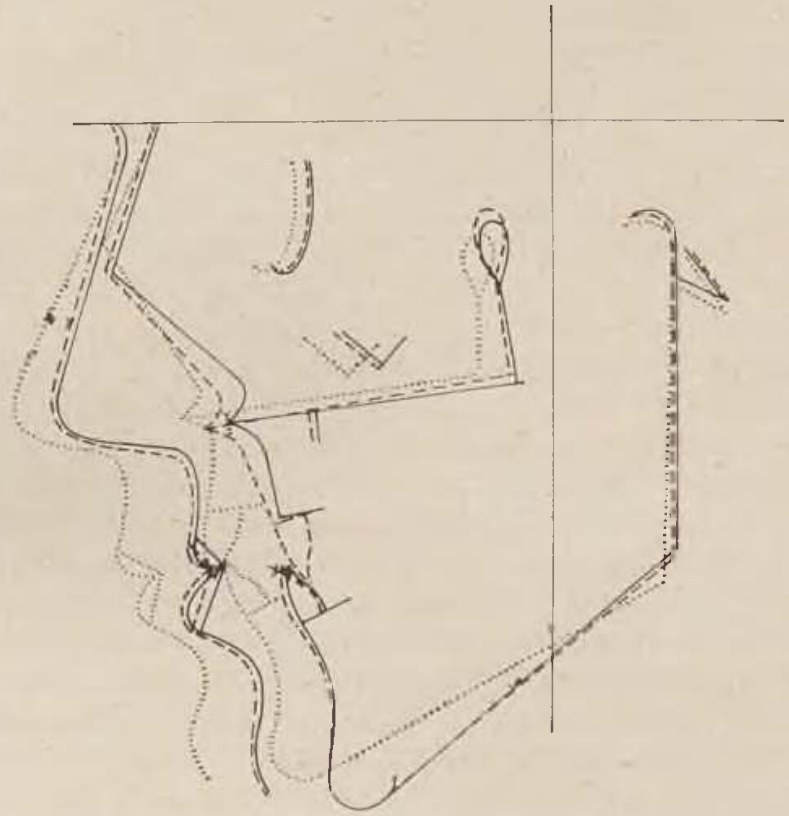

Fig. 2. Craniograms in patients with complete bilateral cleft lip and palate with Le Fort I osteotomy (solid line) and without any maxillofacial surgery (dashed line) as compared to controls (dotted line). In individuals with prosthetic repair the apex of the upper incisors is marked by plus (+) in patients with osteotomy and by x in those without maxillofacial surgery

did not show any substantial deviation, this was caused mainly by the anterior position of the premaxilla. The retrusion of the lateral maxillar segments (S-N-M) was much more marked. One patient whose ANB angle was above the average had also a retrusion of lateral maxillar segments. The use of a prosthesis resulted in individuals after previous osteotomy in an edge to edge occlusion, while in patients without osteotomy the use of prosthesis resulted in a slight overbite (marked by crosses in the craniogram).

DISCUSSION

Preoperative roentgenograms are not available and therefore the assessment of the results of osteotomy is associated with difficulties. It is not possible

to rely fully on the comparison with the findings in individuals without osteotomy since it can be assumed that this surgical procedure was carried out in patients with a more severe skeletal dysbalance. Yet some circumstances indicate that the differences were not marked. This is suggested by the identical retrusion of zygomatic bones (S-N-Zm) in both subgroups, which is closely correlated with the retrusion of the maxilla (S-N-M, $r = 0.670$ in $BCLP_c$ without osteotomy, i. e. $p < 0.001$) and the similar configuration of the soft profile which shows slighter changes after osteotomy than the skeletal profile. Secondary surgical procedures were not carried out frequently as well, with the exception of nose repair. Our findings provided definite evidence that the applied surgical procedure failed to attain a normal anteroposterior relation between the two jaws. It could be possible that the preoperative situation was worse than in average cases, but the final results of this treatment were equally less favourable.

Maxillofacial surgery is aimed at an improvement which would then allow an adequate prosthetic treatment. However even with this view in mind the results can not be considered as satisfactory. The treatment attained, on the average, an edge to edge bite, as compared to overbite in patients treated by a prosthetic appliance alone, without osteotomy. Anterior crossbite persisted in three patients (an overbite in three cases, edge to edge bite in one and in one no prosthesis was applied). The unfavourable findings were due obviously to the draught exerted by the sutures of the palate which hindered the anterior shift of the maxilla and of its segments. Thus it can reduce the value of an immediately postoperatively satisfactory result of osteotomy and interferes with an adequate prosthetic treatment. These draughts represented also the cause of the development of retrusions in clefts during the period of growth. In addition osteotomy leads to velopharyngeal insufficiency which exerts adverse effects on speech as reported by Sano and Kondo (1983).

In view of the above described findings it is not possible to advocate a widespread use of Le Fort I osteotomy for the repair of the disturbed sagittal maxillomandibular relations in clefts. Since it represents a major surgical procedure its use should be always in advance carefully weighed and to give preference to minor surgical procedures (alveotomy and similar), or to compensatory mandibular surgical procedures. Further improvement of therapeutic results requires comprehensive objective investigations, carried out in departments specialized in maxillofacial surgery, with a systemic follow up of patients for long periods of time after osteotomy.

SUMMARY

Roentgenocephalometric studies were carried out in eight adult males with bilateral complete cleft lip and palate. All of them were subjected at least three years ago to Le Fort I osteotomy. They were compared with individuals with the same type of clefts without any maxillofacial surgical procedures. The results obtained are not suggestive of the usefulness of the applied surgical procedure since it failed to attain a normal anteroposterior relation between both jaws.

RESUME

Les anomalies crâniofaciales chez la division de la lèvre et du palais bilatérale totale après une ostéotomie effectuée auparavant

Šmahel, Z.

Par les examens radiocéphalométriques on a examiné 8 hommes avec la division de la lèvre et du palais bilatérale totale, chez lesquels une ostéotomie Le Fort I a été effectuée il y a au moins 3 ans auparavant. Ce groupe a été comparé avec un autre, composé des sujets atteints de la même façon, mais sans aucune intervention de la chirurgie maxillo-faciale. Les résultats ne témoignent pas au profit du procédé décrit ci-dessus qui s'est montré insuffisant pour l'égalisation des relations réciproques des deux maxillaires, dans la direction antériopostérieur.

ZUSAMMENFASSUNG

Kraniofaciale Abweichungen bei vellkommener beiderseitiger Spaltung der Lippe und des Gaumens nach früher ausgeführter Osteotomie

Šmahel, Z.

Röntgenkephalometrisch wurden 8 Männer mit vollkommener Lippen- und Gaumenspaltung untersucht, bei denen vor mindestens drei Jahren eine Osteotomie laut Le Fort I ausgeführt worden war. Sie wurden mit ebenso betroffenen Personen ohne jedwede maxillofaciale chirurgische Behandlung verglichen. Die Befunde sprechen keineswegs zum Vorteil des angeführten Vorgehens, bei dem es nicht gelungen war, die Stellung der beiden Kiefer in der Richtung von vorn nach hinten auszugleichen.

RESUMEN

Desviaciones craniofaciales en caso de una escisión labial y palatal como producto de una osteotomia anterior

Šmahel, Z.

Por cefalometría mediante los rayos x se examinaron 8 hombres con escisión labial y palatal bilateral completa, en los que, por lo menos 3 años atrás, se había efectuado la osteotomía según Le Fort I. Se los comparó con individuos afectados por los mismos defectos que no se habían sometido a ninguna intervención maxilofacial quirúrgica. La condición resultante no es favorable al procedimiento indicado ya que con él no se ha logrado equiparar la relación de ambas partes — mandíbula y la maxilar — en la dirección horizontal.

REFERENCES

1. **Sano, S., Kondo, T.:** Maxillofacial osteotomy in patients with cleft lip and palate. Jap. J. Soc. Plast. Reconstr. Surg., 3 : 324, 1983.
2. **Šmahel, Z.:** Craniofacial morphology in adults with bilateral complete cleft lip and palate. Cleft Palate J., 21 : 159, 1984.
3. **Šmahel, Z., Brejcha, M.:** Differences in craniofacial morphology between complete and incomplete unilateral cleft lip and palate in adults. Cleft Palate J., 20 : 113, 1983.

Dr. Z. Šmahel,
Šrobárova 50, 100 34 Prague 10,
Czechoslovakia

Institute of Surgery, Medical Academy, Lublin (Poland)
Head Prof. M. Jesipowicz
Clinic of Traumatology
Head As. Prof. T. Jastrzębski

CLOSURE OF SHOTGUN DEFECT OF POPLITEAL FOSSA USING A LATERAL GASTROCNEMIUS MUSCLE FLAP

Case report

J. Podlewski, G. Olszewski

The use of muscle and musculocutaneous flaps as a singlestage reconstructive technique has evolved from an operation on the lower extremity to one applicable to all body regions. The gastrocnemius muscle flap can provide local coverage for most skin defects between the lower leg and the lower thigh, and it can reduce the need for cross-leg flaps. Each head of the gastrocnemius has a dominant vascular pedicle, the sural branches of the popliteal artery. These are large vessels entering each head proximally close to the origin of

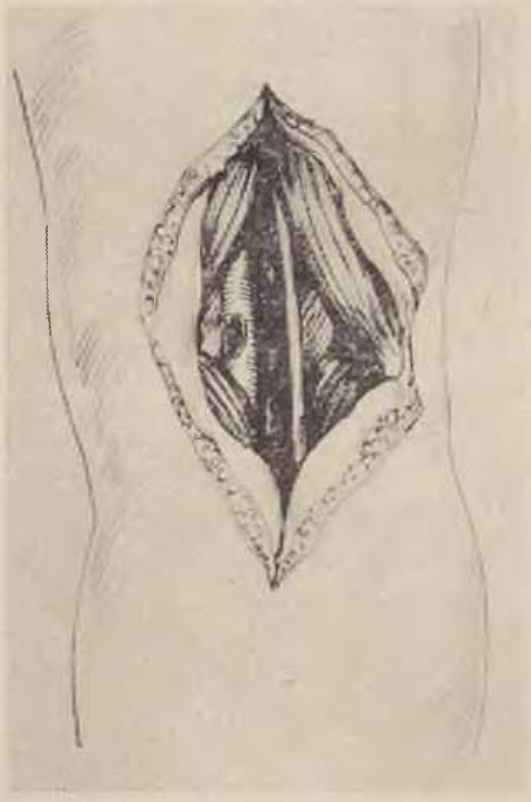

Fig. 1 — A schematic diagram of the outlet wound in the popliteal fossa

the muscle at the femoral condyles. The abundant blood supply to both heads of the muscle produces rapid and sure healing even under adverse circumstances, e. g., local infection or osteomyelitis.

Case report. A 32-year old male was admitted with a shotgun wound of the distal end of the left thigh. The inlet wound of 3 cm in diameter was localized medial to the patella. The outlet wound of 8 cm in diameter was localized in the popliteal fossa. Inside the wound, moderate bleeding and muscle tear were found (Fig. 1). The ipsilateral foot was warm, however, no pulse was noted on the dorsal artery. X-ray examination revealed fractures of the medial and lateral femoral condyles (Fig. 2). Surgery under general anaesthesia was performed forthwith. During the operation, major debridement of both wounds proved necessary, the bone fractures were fixed (Fig. 3), and arterioplasty of the popliteal artery was performed subsequently. Furthermore, a popliteal vein tear was sutured. The soft tissue defect of approximately 8 cm in diameter as well as the popliteal artery, popliteal vein and sciatic nerve remained exposed. To cover this defect, a muscle flap was elevated from the lateral head of the gastrocnemius muscle, rotated superiorly by 180 degrees, and placed into the defect. The tip of the flap was folded to fit the contour of the defect. This muscle flap was immediately covered with a split-thick-

Fig. 2a, b — X-ray of fractures of medial and lateral femoral condyles

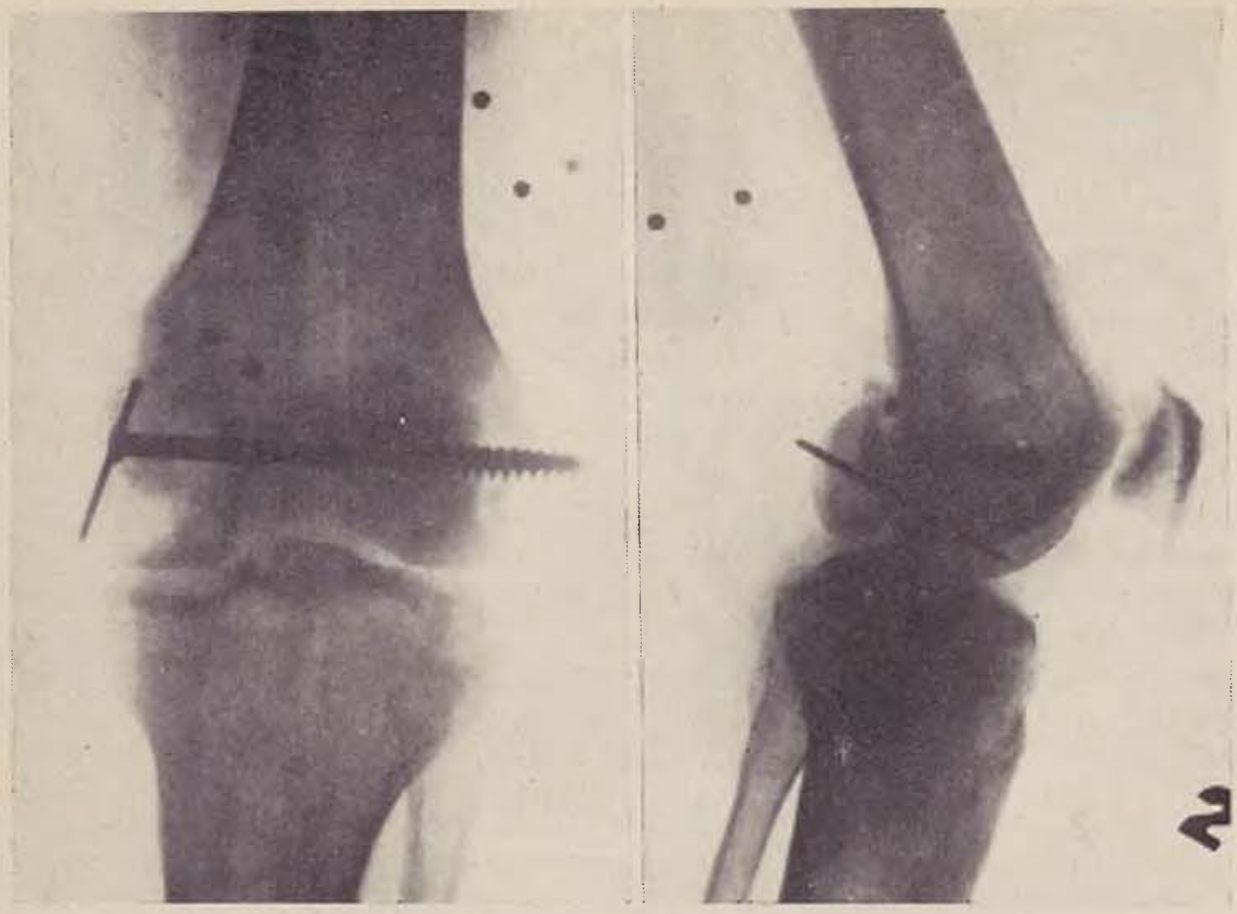

Fig. 3a, b X-ray of fractures after fixation

Fig. 4 — Eventual result of treatment

ness skin graft. Suction drainage was placed into the donor site wound. The extremity was immobilized in a posterior plaster splint. The flap, skin graft and donor wound healed by first intention. The post-operative course was uneventful, and on the 18th day the patient could be discharged. The popliteal area has remained stable postoperatively (Fig. 4).

DISCUSSION

The use of a gastrocnemius muscle flap obviated the need for a cross-leg flap in this patient. This muscle flap technique allowed not only for skin defect resurfacing; it also provided a protective pad over the important anatomical structures of the popliteal cavity (popliteal artery and sciatic nerve). The ample blood supply to the flap permits rapid and sure healing even under adverse circumstances, e. g., contaminated wound, local infection, osteomyelitis, infected foreign bodies, etc., and in this respect the gastrocnemius flap must obviously be seen as a therapeutic flap. The gastrocnemius flap proves to be a reliable and useful alternative to all other methods of repair in the lower extremity, including free microvascular flaps. It is much easier, quicker and safer to perform than most of the other flaps, especially the free flap. The amount of skin which can be transferred is somewhat limited but the range is greater than in any local or cross-leg flap.

SUMMARY

A 32-year old male patient was admitted with a shotgun wound defect of the popliteal fossa to be treated by means of gastrocnemius muscle flap transposition. The therapeutical result proved good.

RESUME

Défaut d'arme à feu dans la région du creux poplité, recouvert par une greffe latérale de musculus gastrocnemius.
Description d'un cas.

Podlewski, J., Olszewski, G.

Un malade de 32 ans, atteint d'un défaut d'arme à feu au creux poplité. Le défaut a été guéri avec de bons résultats, en exécutant une transposition d'une greffe latérale prise de musculus gastrocnemius.

ZUSAMMENFASSUNG

Das Schliessen eines Schussdefekts in der Kniekehle durch Seitenpropfen aus dem Zwillingsmuskel
(Beschreibung eines Falls)

Podlewski, J., Olszewski, G.

Es wird ein 32-jähriger Patient mit Schussdefekt in der Kniekehle beschrieben. Der Defekt wurde erfolgreich durch eine Transposition des seitlichen Pfropfens des Zwillingsmuskels behandelt.

RESUMEN

Cerradura del defecto causado por arma de fuego en la fossa poplitealis mediante un injerto lateral del músculus gastrocnemius (descripción de un caso)

Podlewski, J., Olszewski, G.

Se describe un paciente de 32 años de edad con defecto causado por una arma de fuego en la fosa popliteal. El defecto pudo ser curado con buenos resultados mediante la transposicion de injerto lateral del músculus gastrocnemius.

REFERENCES

1. **Kobus, K., Stępniewski, J.**: Muscular, musculo-cutaneous and skin island flaps in the treatment of compound fractures weight-bearing areas. Chir. Narzad. Ruchu, 48 : 315, 1983.

2. **Mathes, S. J., Nahai, F.**: Clinical atlas of muscle and musculocutaneous flaps. The C. V. Mosby Company. St. Louis, Toronto, London 1979.

3. **McCraw, J. B., et al.**: The versatile gastrocnemius myocutaneous flap. Plast. reconstr. Surg., 62 : 15, 1978.

4. **Podlewski, J.**: Clinical applications of muscle and musculocutaneous flaps of gastrocnemius muscle. Chir. Narzad. Ruchu, 48 : 431, 1983.

5. **Salimbeni-Ughi, G. et al.**: The gastrocnemius myocutaneous flap (GMF): an alternative method to repair severe lesions of the legs. Arch. orthop. traumat. Surg., 98 : 195, 1981.

6. **Smith, D. J. et al.**: Surgical options in the repair of lower extremity soft-tissue wounds. J. Trauma, 22 : 374, 1982.

Dr. J. Podlewski,
ul. Wajdeloty 3 m. 46,
20 — 604 Lublin, Poland

Central Institute of Postgradual Medicine, Moscow (USSR)
Rector M. D. Kovrigina
Department of Surgical Stomatology
Head Dr. V. A. Sukatchev

RECONSTRUCTION OF THE CHIN IN MALE PATIENTS

A. I. Nerobyeyev

Total defects of the chin including surrounding soft tissues and the lower lip arise either from surgical removal of broad disintegrated malignant tumours, or from fire-arm wounds of the face. Patients suffering from almost total absence of the lower part of the face are unable to communicate as well as to be fed orally.

Techniques of the reconstruction of the chin using two tubed flaps consist of many stages (Rauer and Michelson 1954, Chitrov 1984). In such cases the average length of hospitalization amounts to 230 days, and the total length of treatment — including intervals between individual hospitalizations — reaches up to 2 years (Matjakin and Nerobyeyev 1977).

In circumstances of preparatory irradiation the ability of tubed flaps to accommodate decreases considerably (Kabakov et al. 1978), the percentage of failures being higher. The application of the visor-like method of Lexer, using the advancement of occipital adipo-cutaneous flap on two pedicles simultaneously with two superficial temporal arteries (Burian 1967) is, at the present time, rather seldom owing to the difficulties in formation of the inner lining. A suggestion to form the inner lining from the skin of the anterior surface of the neck has proved to be incorrect, for the skin is too thin and when a large flap on a rather narrow pedicle is cut out its necrosis is imminent. Moreover, the front surface of the neck is deformed frequently by scars resulting from the trauma; similarly this procedure is quite out of question with patients suffering from malignant tumours whose treatment involved resection of the cervical lymph nodes.

Equally important is also the fact that the overturn of the skin flap into the mouth cavity results in broad defect at the neck.

Since 1980 we have been using our own technique of chin reconstruction to close the defects described above (application No. 3434727 of October 27th, 1983). It consists in using an adipo-cutaneous flap including m. pectoralis major for the inner lining and a flap from the scalp for the external lining (Fig. 1).

Basic features of the technique are the following. Oval or rectangular flap consisting of the skin and subcutaneous fat of required size (8×10, 12×14 cm) is cut out at the anterior surface of the chest so that its centre is at the level

Fig. 1 — A scheme showing the formation of the head and chest flaps. — Fig. 2 — Patient B. before the operation. Planning of the flap for the inner lining

of the 5th rib. The flap is lifted from below, the m. pectoralis being transected using the well known method of Ariyan (1979). At carefully checking of the a. and v. thoracoacromialis, the myocutaneous plate, except for its upper part, is incised by cuts through all the tissues. Also the skin of the anterior surface of the chest is cut from the clavicle to the upper border of the flap. The anterior surface of the muscle is exposed and incised along the vascular bundle to form a muscular pedicle. From a horizontal incision above the upper margin of the ipsilateral clavicle a tunnel is formed leading, under the skin of the neck, to the anterior margin of the defect in the suprahyoideal region. The adipo-cutaneous flap with the underlying parts of the muscle is lifted on the vasculo-muscular pedicle over the clavicle into the cervical tunnel. The skin part of the flap is sutured to the rest of the lining of the floor of the mouth cavity (with skin toward the interior), the muscular pedicle is placed along the cervical vascular bundle. After that the wound at the chest is closed. A skin flap 10 cm wide, with pedicles situated along the superficial temporal arteries, is cut out from the scalp over the aponeurosis. It is lifted and transferred to the chin. There, it is sutured to the surface of the chest flap, forming thus the external lining. The individual layers of both the flaps are sutured together. After 4—5 weeks the pedicles are separated and placed back to the occipito-temporal regions.

This technique has been used to reconstruct the chin in 5 men aged from 21 to 44 years. The defect of the chin was caused by the fire-arm wound in 1 patient, in 4 patients by the surgical treatment of a malignant tumour of the floor of the mouth cavity and mandible.

Case report.

Patient B., aged 27, hospitalized on October 16th, 1980. Diagnosis: A total defect of the chin and lower lip due to resection of recidiving squamous-cell carcinoma of the lip (operation according Crail on the left side and incision of the cervical aponeurosis on the right side). The patient had already been irradiated before (40 Gr). On his admission, the chin, body of the mandible, anterior part of the floor of the oral cavity and lower lip were completely

missing. The scarry skin was tightly grown together with the underlying tissues. The tongue was fixed to the skin of the anterior surface of the neck, the saliva flowing out, speach and oral feeding were quite impossible (Fig. 2).

On October 23rd, 1980 a surgical intervention was performed consisting in the excision of the scars under the tongue. On the anterior surface of the chest is using the operative technique described, a composite skin flap of the size 9×12 cm was advanced to the defect and then bent rectangularly to form the outlines of the chin. An adipo-cutaneous flap (12 cm wide in the central part) on two pedicles was cut out from the scalp and transferred to the wound surface of the chin and lower lip. The pedicles were tubed, the defect on the head closed using the split skin. The primary healing took place. The chin thus formed was compact with properly shaped outlines. After 45 days the pedicles of the external flap were separated. Now, the patients is able to eat independently and also the speech has been reconstituted (Fig. 3).

On examination after 3 years the chin was symmetrical, without any deformations.

Fig. 3 — Patient B. after the operation

Though the operative results were successful, one disadvantage was observed — the growing hairs in the region of the mouth had prevented formation of the vermilion. In the following operations we succeeded in removing this disadvantage by formation of a longer myocutaneous flap from the chest to cover the external surface of the reconstructed lower lip.

In the following surgical reconstructions we abandoned also the one-stage plasty of the scalp defect using the split-skin flap. First, to put the skin back it is necessary to excise the surplasses of the accomodated skin, second, the tissues are fixed to the skin and its lifting is difficult. Absence of hairs in the central part of the scalp forms a cosmetic defect.

Case report.

Patient M., aged 22, hospitalized on October 7th, 1982. Diagnosis: A total defect of the chin caused by the fire-arm wound six months before the admission. The absence of soft tissues of the chin, lower lip as well as mandibular body from 7 to 7, the saliva flowing out. The patient cannot be fed orally and speak clearly (Fig. 4).

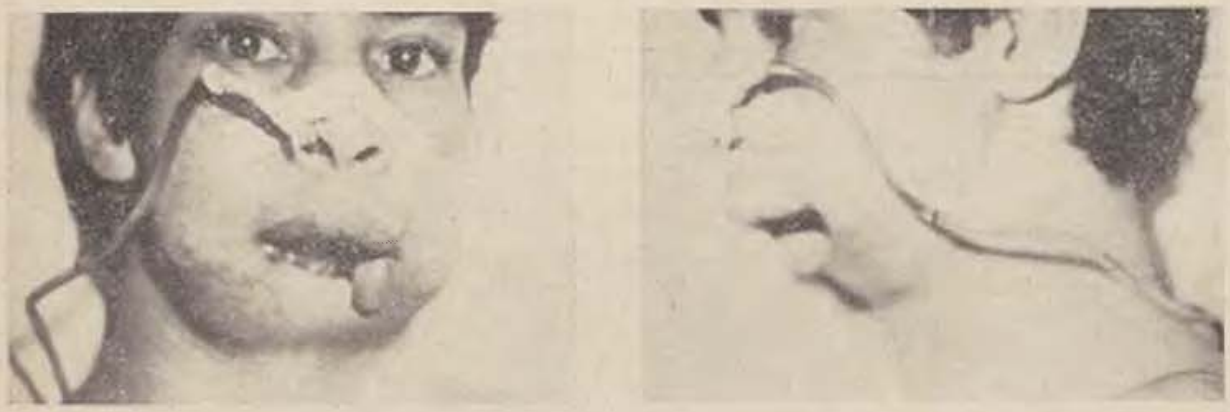

Fig. 4a, b — Patient M. before the operation. a — en face, b — the side view

On October 16th, 1982 the first stage of the surgery was performed, i. e., the reconstruction of the chin using two flaps (as described above). The upper part of the myocutaneous flap from the chest was, unlike in the previous case, brought to the defect anteriorly (Fig. 5).

The defect on the head was covered by an artificial skin. After 5 weeks the pedicles of the flap were separated and placed back to the occipito-temporal region. The excision, granulation and shift of the tissues made it possible to cover completely the defect of the scalp using local tissues. Lateral parts of the chin flaps were sutured to the rest of the inner lining and the skin of the cheeks (Fig. 6).

After three weeks the vermilion was reconstructed. The flap according to Abbe from the upper lip was sutured to the deepidermalized lower lip. Its pedicle was separated after 21 days. The vermilion was fully restored.

Figures 7 and 8 show the appearance of the patient 2 months after the operation. According to the patient's wish the osseous plasty was postponed to the next year.

The extensive uses of composite skin flaps with vascular axis — i. e., of the deltopectoralis flap (Clouet et al. 1980), adipo-cutaneous flaps including m. pectoralis major, m. trapezius and m. latissimus dorsi — as well as of free grafting with one-stage revascularization by means of microvascular anastomoses, have in a decisive manner changed our approach to plastic reconstruction within the past ten years. At the present time it is possible to cover extensive defects in one or two stages. Bell and Barron (1980), Tamai (1980), Colen et al. (1983) reported on exceptional cases of one-stage plasty of extensive penetrating defects of the lower third of the face using composite flaps and microvascular anastomoses. Though this procedure is advantageous in

Fig. 5 — Patient M. 5 weeks after the first stage of the operation

Fig. 6 — Patient M. before the plasty of the vermilion of the lower lip

many respects, it exhibits also some significant disadvantages; namely extraordinary difficulties of the intervention and a high probability of failures, especially with the patients treated by irradiation. To reconstruct the chin properly two massive flaps have to be transferred to the defect. Moreover in case of necrosis of one of the flaps neither the other one can be used due to considerable scarring and changes after inflammation. However, the probability of successful treatment and its minimum possible duration are most important factors. The flaps we use are characterized by high vitality given by centrally located blood vessels. Simultaneously, they are not endangered

Fig. 7a, b — Patient M. after the operation. a — en face, b — the side view

by necrosis, for the vascular pedicle is safe deep in transferred tissues. The flaps are formed in a sufficient distance from the defect so that an autonomous blood supply is maintained even in circumstances of therapeutic irradiation of the floor of the mouth cavity and lateral parts of the neck. The reconstructed chin is compact and stable, even without osseous plasty, which is refused by some patients in the first year. However, there is sufficient amount of soft tissues for additionally performed osseous support. The plasty does not require special equipment and can be performed at any surgical department performing plastic operations.

SUMMARY

The paper describes a technique of rapid reconstruction of the chin by means of two pedicle flaps with axial nourishing vessels. The inner lining is formed using composite skin flap including m. pectoralis major; the flap is brought to the facial defect through a subcutaneous channel in the cervical

Fig. 8 — The floor of the mouth cavity and the lower lip of patient M.

region. For the external lining of the defect a visor-like shaped skin flap from the scalp is used. After severing off the nourishing pedicles the chin, formed by several tissue layers, remains compact and holds its shape; postoperative scars are covered by growing hairs. This technique was used to reconstruct the chin in 5 patients aged from 21 to 44 years. Results were satisfactory in functional as well as cosmetic aspects.

RESUME

La reconstruction d'une partie du menton chez les hommes

Nerobyeyev, A. I.

Le travail apporte la description d'un procédé rapide de la reconstruction du menton. La méthode consiste en deux lobes cutanés pliés, à pédicule, dont modelage accentue la conduite axiale des artères d'alimentation. Comme matériau du gonflement interne on a choisi un lobe cutané contenant musculus pectoralis major. Le lobe est déplacé par un tunnel sous-cutané de la région de gorge vers le défaut du visage. Le recouvrement extérieur est créé à l'aide d'un lobe cutané triangulaire, pris dans la région chevelue de la tête. Le menton, composé de plusieurs couches de tissus différents, reste compacte et garde bien sa forme, après la section des pédicules nourrissants. Les cheveux poussants recouvrent les cicatrices postopératoires. De cette manière, on a effectué les opérations de 5 malades âgés entre 21 à 44 ans. On a obtenu de bons résultats fonctionnels et cosmétiques.

ZUSAMMENFASSUNG

Die Rekonstruktion der Kinnpartie bei Männern

Nerobjejew, A. I.

In der Arbeit wird eine schnelle Art der Rekonstruktion des Kinns mittels zweier zusammengelegter Hautlappen am Stiel beschrieben, die mit Nachdruck auf den axialen Verlauf der ernährenden Gefässe gebildet werden. Zur inneren Ausbettung wird ein Knochenlappen verwendet, der den m. peetoralis major enthält. Der Lappen wird durch den Unterhauttunnel in der Halsregion zum Gesichtsdefekt gebracht. Die äussere Bedeckung wird mittels eines schildähnlichen Hautlappens des behaarten Kopfteils gebildet. Das Kinn, das aus mehreren Schichten verschiedener Gewebe besteht, bleibt nach Abtrennung der ernährenden Stiele fest und behält seine Form; die wachsenden Haare bedecken die Operationsnarben. Auf diese Weise wurden Operationen bei 5 Patienten im Alter von 21 bis 44 Jahren ausgeführt, und es wurden gute Funktions- und kosmetische Ergebnisse erzielt.

RESUMEN

Reconstrucción de la parte de mentón en la cara de los hombres

Nerobyeyev, A. I.

En el estudio se describe una rápida reconstrucción del mentón con ayuda de dos lóbulos dérmicos plegados, colocados sobre pecíolos, conformados poniéndose énfasis en la dirección axial de los vasos de alimentación. Para el epitelio interior se utilizó un lóbulo dérmico que incluye el m. pectoralis major. A través de un túnel subcutáneo en la parte del cuello el lóbulo es transladado hacia el defecto de la cara. La cobertura exterior la constituye un lóbulo de escudetes de la piel tomada desde la cabeza cubierta con cabello. El mentón integrado por varias capas de diferentes

tejidos, después de separarse los pecíolos de alimentación, se queda firme y mantiene la forma adecuada; al crecer, el cabello va cubriendo las cicatrices postoperativas. De tal forma se efectuó la operación en 5 pacientes de 21 a 44 años de edad. Se consiguieron buenos resultados funcionales y cosméticos.

REFERENCES

1. **Burian, F.**: The Plastic Surgery Atlas. Czechoslovak Medical Press Prague, Butterworths London, 1967.
2. **Kabakov, B. D., Iermolaiev, I. I., Vorobiev, IU. I., Alexandrov, N. M.**: Treatment of the malignant tumours of the maxillofacial region. Medicine, M., 1978.
3. **Matjakin, E. G., Nerobyeyev, A. I.**: Evaluation of the results of plastic reconstructions of defects arising from treatment of malignant tumours of maxillo-facial and cervical regions. Experimental and Clinical Stomatology, 8 : 76—77, 1977.
4. **Rauer, A. E., Michelson, N. M.**: Plastic Surgery of the Face. Medgiz., M., 1954.
5. **Chitrov, F. M.**: Atlas of the Plastic Surgery of the Face and Neck. Medicine, M., 1984.
6. **Ariyan, S.**: The pectoralis major myocutaneous flap. Plast. reconstr. Surg., 63 : 73, 1979.
7. **Bell, M., Barron, P.**: A new method of oral reconstruction using a free composite foot flap. Ann. plast. Surg., 5 : 281, 1980.
8. **Clouet, M., Cadenat, H., Combeless, R.**: Reconstruction de l'etage inferieur de la face. Ann. Chir. plast., 25 : 383, 1980.
9. **Colen, S., Bacer, D., Shaw, W.**: Microvascular flap reconstruction of the head and neck. Clin. Plast. Surg., 10 : 73, 1983.
10. **Tamai, S.**: Microsurgery in Japan. Clin. plast. Surg., 7 : 475, 1980.

Dr. A. I. Nerobyeyev,
Central Institute
of Postgradual Medicine,
Vosstaniya 1/2, 123242 Moscow, USSR

During the IV National Congress of Orthopaedics and Traumatology, held in Etropole October 1984, the foundation of the Bulgarian Society for Surgery of the Hand was approved and Prof. Ivan B. Matev, D. Sc., was elected as the first president.

Charles University Medical Faculty of Hygiene, Prague (Czechoslovakia)
Department of Plastic Surgery Burn Center
Head Prof. M. Fára, M. D., DrSc.
1st Medical Department
Head As. Prof. J. Strejček, M. D., CSc.

ALTERED LYMPHOCYTE RESPONSIVENESS IN EXTENSIVELY BURNED PATIENTS

V. Poláček, M. Jíra, J. Strejček, R. Königová, L. Brož, M. Fára

INTRODUCTION

Many immunological aberrations were noted in burn patients, including changes in serum immunoglobulins, complement levels, impaired neutrophil function, decreased opsonic activity, impaired lymphocyte responsiveness, disturbances in lymphocyte subpopulations, etc. These alterations related to lymphocyte functions are listed in Table 1.

Tab. 1. Immune system changes in relation to lymphocyte functions in burned patients

Type of change	Authors
Skin tests for hypersensitivity tests	Hergers et al., 1984 Brown et al., 1982
Changes in lyphocyte response	Keane et al., 1983 Collins et al., 1982 Munster et al., 1980 Miller et al., 1979 Alexander et al., 1979
Suppressor cell production	Ninnemann et al., 1984 Keane et al., 1982
Changes in lymphocyte subgroups	Antonacci et al., 1984 Mc Irvine et al., 1982
Morphological changes	Koníčková et al., 1983
B-lymphocyte part in suppression	Ninnemann et al., 1980
in vitro production of immunoglobulins	Shorr et al., 1984
PGE_2 part in suppression	Ninnemann et al., 1983
Thromboxane B_2 part in suppression	Herndon et al., 1984
Effect of temperature	Hanson et al., 1984
Effect of transfusions	Collins et al., 1982
Effect of plasma exchange	Ninnemann et al., 1984
Reduced IL-2 production	Wood et al., 1984
NK cell activity changes	Stein et al., 1984 Poláček et al., 1984

Furthermore, a measure of immunodeficiency induced by thermal injury is seen as the hypothetical cause of an increased rate of infection. The present report is part of a comprehensive prospective study of immune parameters in severely burned patients. It describes changes in lymphocyte responsiveness to non-specific mitogens in those patients.

CLINICAL MATERIAL

A group of 29 patients (17 men, 12 women) with extensive burns (20—79 % BSA, average 39.8 %) were studied. The patients' mean age was 40.5 years (19—66). The essential clinical data are summed up in Table 2. 7 patients

Tab. 2. Clinical data on burned patients

Clinical course of burn illness		Number of patients	Mean age	BSA (%)	Index of gravity
Septic patients	surviving	7	33.7	47.1	80.8
	dead	3	39.0	34.4	74.4
Non-septic patients	surviving	16	41.3	33.9	74.2
	dead	3	46.0	46.0	92.0

had septic episodes in the late phase of the burn illness. 3 of them died due to septicaemia and decompensated burn illness. Another 3 patients were non-septic, and died subsequently for other reasons (one of cardiac failure, two of pulmonary embolism). All received standard individual treatment at an intensive care unit during the emergency and acute phases of their illness. Blood samples were taken each week until the convalescence period. The control group consisted of 47 healthy subjects matched for age and sex.

Lymphocyte cultures

The proliferative response of mononuclear cells from the patients and controls was investigated using a previously described standard technique. Briefly, though, mononuclear cells were isolated from heparinized venous blood by centrifugation on a density gradient. Purified mononuclear cells were washed in Eagle's minimal essential medium (E-MEM, ÚSOL, Prague, Czechoslovakia) and then resuspended in E-MEM supplemented with glutamine, penicillin, streptomycin and 10% foetal calf serum (FCS; VŠV, Brno, Czechoslovakia) to obtain a final concentration of 1×10^6 cells/ml. Eventually, triplicate cultures were placed on microtitre plates (Dynatech M29ARTL, FRG) containing 100 μl cells and 100 μl diverse mitogens or medium alone. In previous experiments, the following concentrations of mitogens were found optimal for the study of lymphocyte functions in human diseases: 20 μg PHA (Phytohaemagglutinin Wellcome, Beckenham, Great Britain), 5 μg ConA/ml medium (Concanavalin A, Pharmacia Fine Chemicals, Uppsala, Sweden) and 2 μg PWM (Poke-

weed mitogen, Flow Labs. Ltd., Irvine, Great Britain). The plates were sealed with the adhesive tape and incubated for 48 hours at 37 °C. Then the cultures were treated with 40 kBq tritiated thymidine in 5 μl (^{3}H-TdR, ÚVVVR, Czechoslovakia). After 18 more hours in the culture medium the cells were harvested on glass fibre paper using an automatic cell harvester (Dynatech, AM 78, FRG). The filters were then transferred into vials with scintillation fluid (SLT-41, Spolana Neratovice, Czechoslovakia) and counted on a Berthold scintillation counter. The results were expressed in c.p.m. as the mean of triplicates, and compared with Student's t-test.

RESULTS

Spontaneous cultures

All patients exhibited increased lymphocyte uptake of thymidine in the acute phase of the illness, often repeatedly. Mean spontaneous incorporation was 5.11 ± 3.96 taking into account the highest values within 21 days of the acute phase. Nevertheless, the results showed no significant difference from the controls (1.83 ± 1.42). There were no differences between the septic and non-septic groups provided the highest values were compared (Table 3). Interestingly, the fatal outcome papients exhibited, in general, lower spontaneous incorporation values than the survivors.

Response to PHA

The PHA-stimulated lymphocyte cultures of the burn patients were usually above the control values. In terms of the highest values during the first 21 days of the acute phase, the burn victims exhibited increased lymphocyte response to PHA (150.0 ± 53.7) compared with the controls (124.9 ± 32.8), however, without reaching statistical significance. The highest values were found in the subgroup of surviving non-septic patients (162.4 ± 48.1). During the convalescence phase, the lymphocyte response usually returned to normal values (Table 4). Prominently inhibited lymphocyte response to PHA was found

Tab. 3. Tritiated thymidine incorporation in burned patients' spontaneous lymphocyte cultures (in i. m. p./min × 10^{-3} ± 1 SD)

Subgroup			Emergency phase		Acute phase (maximum values within 21 days)		Convalescence	
Septic	surviving	(n = 7)	3.16 ± 2.99		6.30	4.74	2.11	2.01
	dead	(n = 3)	1.99 ± 2.05		4.00	4.08	—	
Non-septic	surviving	(n = 16)	2.96	2.67	5.05	3.67	1.96	1.83
	dead	(n = 3)	1.76	1.05	3.67	3.57	—	
Controls		(n = 47)	1.83 ± 1.42					

Tab. 4. Lymphocyte response to PHA in burned patients (in i. m. p./ /min × 10^{-3} ± 1 SD)

Subgroup		Emergency phase		Acute phase (max. values in 21 days)		Convalescence	
Septic	surviving (n = 7)	133.5	41.5	143.0	52.8	108.6	39.1
	dead (n = 3)	126.5	53.5	147.1	43.6	—	
Non-septic	surviving (n = 16)	137.5	40.2	162.4	48.1	116.5	41.4
	dead (n = 3)	130.9	66.1	128.3	79.3	—	
Burned patients total (n = 29)		134.7	37.7	150.0	53.7	114.1	40.5
Controls (n = 47)		124 ± 32.8					

Tab. 5. Individual results of lymposyte respornse to PHA in patients who subsequently developed sepsis in the course of 3 to 7 days

Patient	Age Sex	BSA %	Clinical course of disease	Post-injury examination			
				Day	Value	Day	Value
P. L.	20/M	45	mitigated sepsis due to Staphyloc. aur. starting on day 45	31st	96.3	38th	17.5
Z. L.	30/F	20	severe sepsis due to Enterobact. starting on day 28	15th	143.0	22nd	56.9
B. Š.	45/F	38	mitigated sepsis due to Staphyloc. aur. starting on day 22	8th	132.4	15th	116.4
T. K.	19/M	33	mitigated sepsis due to Pseudomona aer. starting on day 17	7th	138.9	14th	125.7
M. K.	32/M	51	mitigated sepsis due to Staphyloc. aur. starting on day 14	3rd	104.9	10th	69.5
				$p < 0,05$			

in 5 patients continually studied for 3 to 7 days prior to the onset of sepsis (89.8 ± 51.8). Compared with the results from the same individuals one week before, the decrease was statistically significant (Table 5). However, no statistically significant departures were found from the rest of the values in the other subgroups.

Tab. 6. Lymphocyte response to Con A in burned patients (in i. m. p.)/min × 10^{-3} ± SD)

Subgroup			Emergency phase		Acute phase (max. values in 21 days)		Convalescence	
Septic	surviving	(n = 7)	73.5	±47.5	70.9	44.1	66.5	31.8
	dead	(n = 3)	83.5	±66.8	99.7	78.0	—	
Non-septic	surviving	(n = 16)	84.5	40.8	91.7	51.1	66.6	31.8
	dead	(n = 3)	66.9	57.7	77.0	50.5	—	
Burned patients total		(n = 29)	79.9	46.9	84.2	43.7	67.2	29.4
Controls		(n = 47)	69.5 ±22.5					

Response to Con A

The lymphocyte response to Con A was increased in the burned (Table 6). The highest values were recorded in the non-septic patients' group (91.7 ± 51.1). However, in relation to the controls, none of the subgroups of patients exhibited an increase in Con A response big enough to reach statistical significance. During convalescence, the lymphocyte response values were gradually returning to normal.

The lymphocyte response to Con A estimated 3 to 7 days before sepsis had dropped, too, to reach statistical significance when compared with the results of the same individuals during the previous week (Table 7).

Response to PWM

The burn patients' lymphocyte response to PWM was also increased (Table

Tab. 7. Individual results of lymphocyte response to Con A in patients who subsequently developed sepsis in the course of 3 to 7 days

Patient	Age Sex	BSA %	Post-injury examination				Sepsis starting on day
			Day	Value	Day	Value	
P. L.	20/M	45	31	48.2	38	10.9	45
Z. L.	30/F	20	15	16.5	22	10.3	28
B. Š.	45/F	38	8	116.7	15	70.4	22
T. K.	19/M	33	7	81.5	14	44.0	17
M. K.	32/M	51	3	111.6	10	89.6	14
					$p<0.05$		

8). The highest values were seen initially in the group of patients who subsequently developed sepsis. A decline in the lymphocyte responsiveness to PWM was found 3—7 days before the development of sepsis (30.3 ± 22.1). Comparing the results from those patients with the values obtained one week before we can once again note a highly significant drop. During the phase of convalescence the lymphocyte response to PWM was slightly below that of the control value (35.6 ± 26.6).

Individual laboratory approach to burn patients

Fig. 1 demonstrates the lymphocyte response to different mitogens in different periods of the burn illness. A decrease in lymphocyte responsiveness can be seen prior to the development of fatal sepsis.

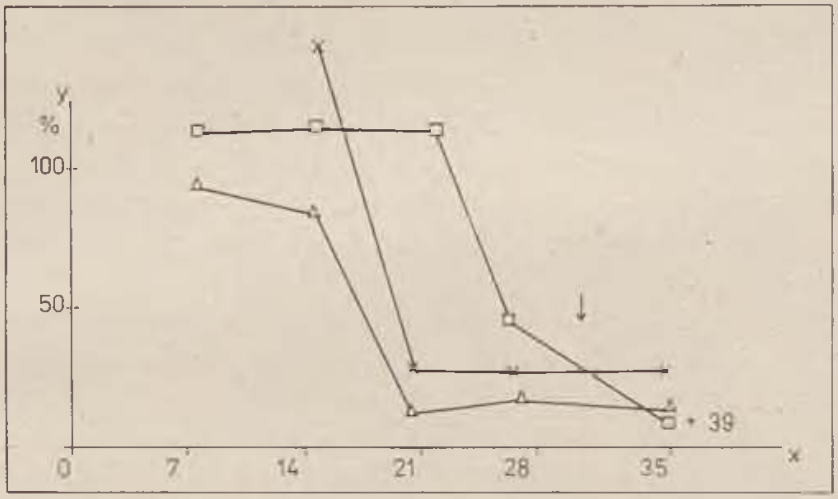

Fig. 1 Lymphocyte response to diverse mitogens in patient L. Z. (20 %, 3rd-degree) who developed fatal sepsis (results are given in % of stimulated control values) x — post injury day, y — %, ■ — PHA, △ — Con A, × — PWM, ↓ —sepsis

DISCUSSION

Opinion varies as to the lymphocyte response to various mitogens in burn patients. Some seem to believe that the decline in this response signifies impaired immunocompetence in those patients. Others, however, are apparently unable to endorse such conclusions reporting, on the contrary, a rise in lymphocyte responsiveness throughout the acute phase of burn injury. Our own study lends supports to the latter finding as we, too, were able to see the response increasing during the acute phase. According to Ninnemann, B-lymphocytes, too, have a role to play in the production of suppressor cells. Conceivably, the B-cells are, at least in some phases of the burn trauma, easier to activate. The initial rise in lymphocyte responsiveness followed by a rapid decline lasting 3 to 7 days in those patients who subsequently developed sepsis. Possibly then, this technique could be used for the detection of high-risk patients susceptible to septic complications. The period of cultivation (3 days) may limit the clinic-

al value of this assay as the decline in lymphocyte responsiveness cannot be demonstrated until a week before the appearance of sepsis.

We considered also the possibility that our results may have been influenced by some specific therapeutical procedures affecting the immune system. In our group of patients, however, we were unable to find any relationship to the number of transfusions used, skin grafting, fever or BSA. Moreover, lymphocytes placed in a different medium (foetal calf serum used in our own and some other studies) may display different reactivity and support the importance of circulating immunosuppressive substances in the burn patients' plasma. Obviously, increased lymphocyte responsiveness to mitogens as demonstrated in our study represents only one in vitro parameter of cell-mediated immunity. We presume, however, that this parameter can be of clinical use for predicting septic complications in burn patients.

Tab. 8. Lymphocyte response to PWM in burned patients (in i. m.p./min y $10^{-3} \pm 1$ SD)

Subgroup			Emergency phase		Acute phase (max. values in 21 days)		Convalescence	
Septic	surviving	(n = 7)	53.2±41.6		77.9	77.0	41.5	30.4
	dead	(n = 3)	46.8±30.0		85.2	24.8	—	
Non-septic	surviving	(n = 16)	58.8	32.8	69.3	37.6	33.0	28.3
	dead	(n = 3)	50.6	44.1	63.3	28.2	—	
Burned patients total		(n = 29)	55.4	35.8	73.4	47.7	35.6	28.9
Controls		(n = 47)	42.8±19.7					

Tab. 9. Individual results of lymphocyte response to PWM in patients who subsequently developed sepsis in the course of 3 to 7 days

Patient	Age Sex	BSA %	Post-injury examination				Sepsis starting on day
			day	value	day	value	
P. L.	20/M	45	31	30.8	38	5.1	45
Z. L.	30/F	20	15	86.2	22	13.0	28
B. Š.	45/F	38	8	45.4	15	41.2	22
T. K.	19/M	33	7	111.9	14	31.8	17
M. K.	32/M	51	3	86.9	10	60.3	14
					$p<0.05$		

The cell-mediated immunity regulating system in burn patients appears to be more intricate than was initially suggested. Different subsets of cells may perform different functions at different times of the burn illness. Our current research work aims at: 1. demonstrating the clinical value and reliability of the above test in a subgroup of patients susceptible to infection, and 2. investigating the mechanism of call-mediated immune response with special regard to immunomodulation treatment of those patients.

SUMMARY

29 severely burned patients were repeatedly tested for their lymphocyte response to different non-specific mitogens in vitro. The general conclusion is that the burn trauma was accompanied by increased lymphocyte responsiveness to PHA, Con A, and PWM during the emergency and acute phases of the illness. A rapid decline in lymphocyte response was noted in patients who developed septic episodes during the following week. Patients with the highest spontaneous and mitogen-induced lymphocyte transformation had the lowest mortality. The clinical value of immunological changes taking place in thermal injury is discussed.

RESUME

Les changements de la réponse lymphocytaire des grand-brûlés

Poláček, V., Jíra, M., Strejček, J., Königová, R., Brož, L., Fára, M.

29 malades gravement brûlés ont été examinés en plusieurs répétitions sur le plan de leur réponse lymphocytaire à l'application in vitro des mitogènes non-spécifiques. En général, on a pu constaté que le trauma thermique a été accompagné par l'augmentation de la réaction à PHA, Con A et PWM, au cours d'une période immédiate et acute du trauma thermique.

L'abaissement rapide de la réponse lymphocytaire a été remarqué chez les malades avec une complication septique qui était survenue dans la semaine suivante. La plus haute transformation lymphocytaire spontanée, par l'intermédiaire des mitogènes, est apparue chez les sujets de la plus basse mortalité. La valeur clinique de cette exploration est discutée dans le cadre des changements immunologiques chez les malades atteints d'un grand trauma thermique.

ZUSAMMENFASSUNG

Veränderungen in der lymphozytären Reaktion bei ausgedehnten Verbrennungen

Poláček, V., Jíra, M., Strejček, J., Königová, R., Brož, L., Fára, M.

Bei 29 schwer verbrannten Personen wurde ihre lymphozytäre Reaktion auf die Verabreichung nichtspezifischer Mitogene in vitro wiederholt untersucht. Allgemein konnte festgestellt werden, dass das Verbrennungstrauma mit einem Anstieg der Reaktion auf PHA, Con A und PWM während der unmittelbaren und der akuten Periode des Verbrennungstraumas verbunden war.

Ein rapider Abfall der Reaktion der Lymphozyten wurde bei solchen Patienten festgestellt, die in der folgenden Woche eine septische Komplikation durchmachten. Die Patienten mit der höchsten spontanen und durch Mitrogene vermittelten lymphozytären Transformation weisen die geringste Mortalität auf. Es wird der klinische Wert

dieser Untersuchung im Rahmen immunologischer Veränderungen bei Patienten mit ausgedehnten thermischen Verwundungen diskutiert.

RESUMEN

Cambios de respuesta linfocitaria en personas ampliamente quemadas

Poláček, V., Jíra, M., Strejček, J., Königová, R., Brož, L., Fára, M.

En 29 personas gravemente quemadas se hizo prueba, reiteradas veces, de su respuesto linfocitaria a la toma de mitogenos no específicos in vitro. Generalmente se pudo constatar que el trauma producto de las quemaduras fue acompañado de un incremento de la respuesta a PHA, Con A y PWM, durante el período agudo y de urgencia del trauma causado por quemaduras.

Se detectó una fuerte disminución en la respuesta de linfócitos en tales pacientes, que, a la semana siguiente, pasaron por una complicación sética. Los pacientes con la mayor transformación linfocitaria espontánea y causada por intermedio de mitógenos, arrojan la mortalidad más baja. Se discute el valor clínico de similares exámenes en relación con los cambios imunológicos en los pacientes afectados por amplias heridas térmicas.

REFERENCES

1. **Antonacci, A. C., Reaves, L. E., Calvano, S. E., Amand, R., De Riesthal, H. F., Shires, T.**: Flow cytometric analysis of lymphocyte subpopulations after thermal injury in human beings. Surg. Gynec. Obstet., 159, 1 : 1, 1984.
2. **Heggers, J. P., Robson, M. C., Kucan, J. O., Jellema, A., Osborne, J.**: Skin testing. A valuable predictor in thermal injury? Arch. Surg., 119, 1 : 49, 1984.
3. **Herndon, D. N., Abston, S., Stein, M. D.**: Increased thromboxane B_2 levels in the plasma of burned and septic burned patients. Surg. Gynec. Obstet., 200, 3 : 210, 1984.
4. **Jíra, M., Strejček, J., Horký, J., Písa, P., Šuhajová, E.**: Effect of alpha-interferon on peripheral human lymphocytes (in Czech). Čas. Lék. čes., 123, 48 : 1470, 1984.
5. **Munster, A. M.**: Immunologic response of trauma and burns. An Overview. Am. J. Med., 76, 3 : 142, 1984.
6. **Ninnemann, J. L., Stratta, R. J., Warden, G. D., Saffle, J. R., Weber, M. E.**: The effect of plasma exchange on lymphocyte suppression after burn. Ann. Surg., 119, 1 : 33, 1984.
7. **Poláček, V., Jíra, M., Fára, M., Strejček, J., Königová, R., Brož, L.**: NK activity and lymphocyte transformation in severe burn injury. Presented at the 16th Annual Meeting of ABA, April 21—24, 1984, San Francisco.
8. **Shorr, R. M., Ershler, W. B., Gamelli, R. L.**: Immunoglobulin production in burned patients. J. Trauma, 24, 4 : 319, 1984.
9. **Stein, M. D., Gamble, D. N., Klimper, K. D., Herndon, D. N., Klimper, G. R.**: Natural killer cell defects resulting from thermal injury. Cell. Immunol., 86, 2 : 551, 1984.
10. **Strejček, J., Šuhajová, E., Jíra, M., Písa, P.**: Further evidence of immunoregulatory effects of cimetidine. Allerg. Immunol., 30, 2 : 117, 1984.
11. **Wood, J. J., Rodrick, M. L., O'Mahony, J. B., Palder, S. B., Saporoschetz, I., D'Eon, P., Mannick, J. A.**: Inadequate interleukin 2 production. A fundamental immunological deficiency in patients with major burns. Ann. Surg., 200, 3 : 311, 1984.

For other references contact the author.

Dr. V. Poláček,
Department of Plastic Surgery,
Šrobárova 50, 100 34 Prague 10,
Czechoslovakia

Moscow Medical Institute of Stomatology of N. A. Semaschko, Moscow (USSR)
Faculty of Postgradual Education
Department of Psychiatry
Head prof. A. A. Portnov

SPECIAL FEATURES OF DELAYED PSYCHOGENIC DISORDERS AND THERAPEUTIC-PREVENTIVE MEASURES IN ADULT PATIENTS WITH ACQUIRED FACIAL DEFECTS

S. A. Schamov, A. A. Sergeiev, M. M. Rakitin

In our as well as in foreign literature an increasing attention is paid to complex problem of the psychology of people under the conditions of severe psychic isolation caused by physical inadequacy (Korkina 1973, Matveiev and Sergeiev 1967, Kurindina 1979, Easson 1957 and others).

A complex approach solving this interdisciplinary problem of psychiatry and cosmetology involves the study of special features of psychology of the patients looking for cosmetic help. Its results enable us to discover a close connection of emotional, typological and behavioral reactions with one's appearance (Achabadze 1977, Belenkaia 1980, Peskova 1971). The patients are inclined, not infrequently, to attribute the worsening of their social, professional and often also family conditions to their cosmetic defects and with time they are becoming oversensitive, suspicious, breaking their former social relations.

Up to now, many questions related to the general laws of the origin, course and consequences of psychologic disorders ensuing from cosmetic defects of the face in adulthood still remain open.

This paper is based on the experience with dynamic clinical observations on 62 patients (44 females, 18 males) that had been asking for surgical correction of cosmetic defects at the Moscow Research Scientific Institute of Cosmetology from 1979 to 1983. The patients were aged from 36 to 57, they differred in the level of education acquired (the minimum being 8 school years).

Etiology of cosmetic defects varied considerably: in 16 patients the defects originated acutely from traumas of the nose and earlobes, in 46 patients the causes were of chronic nature. They consisted of skin surplasses due to abrupt changes of the body weight, trophic disorders of the skin of the face, endocrinologic disorders, insufficient hygiene and care for the skin, and, finally, the changes due to aging that appear after the age of 43. They require special surgical treatment for they do not respond satisfactorily to the conventional therapy (massages, creams, unquenta, etc.).

Neurotic reactions in patients suffering from cosmetic defects were preceded by psychologically justifiable and adequate reactions to psychogenic situations connected usually directly with cosmetic defects. Psychological traumas began in the period of excessive fixation to the defect, which proved to be an important factor in all the stages of origination and development of psychogenic disorders. Uniform psychologic traumas affecting the patients under the conditions of daily traumatization caused gradual changes of psychologically adequate reactions into inadequate neurotic ones.

The analysis of clinical and anamnestical data enabled us to differentiate between 3 groups of patients with the following premorbid accentuations of asthenic (26), psychasthenic (22) and hysterical features (14). The individual accentuations, (even those exhibiting sufficient stability) did not affect the normal way of living and social adaptability of the patients — up to the period of the pathological fixation to the cosmetic defect. Neurotic reactions were experienced on the background created by one's own psychologic features. With the asthenics they were expressed as tiredness, decreased capability of working, the absence of usual needs, decreased ability of concentration, increased suspectibility to sensoric stimuli and, also, as transient unpleasant sensations on the skin of the face, where the patients localized the defect.

Also the occurrence of neurotic reactions in patients with psychasthenic features of the premorbid personality was connected with morbid reactions to cosmetic defect of the face. In these patients indecisiveness, permanent uncertainty, troublesome persistent doubts as far as correctness of their behaviour is concerned, anxiety about the people close to them, and, above all, fears concerning the correctibility of the cosmetic defect were observed. In the preoperative period they even expressed doubts about the necessity of cosmetic surgery, although the fixation on surgical correction was rather rare. Discussions about it intensified the strain and weak attitudes occurred. The patients concealed their doubts carefully from their relatives. Only the analysis of their condition and confidential talks enabled us to identify the fabic syndrome, usually only rudimentary and poorly realized by the patient himself.

The analysis of patients with hysterical features in the premorbid period has revealed some typical reactions to cosmetic defects. A psychogenic reaction consisted of the signs of "the escape into the illness". The patients were loosing their old friends together with the interest in new friendship, they stop visiting regular parties as well as the theatres and tried to spend their leisure time at home. They were abnormally sensitive to meaningless family situations, egocentric and hypochondric; their asthenic reactions were elective. Characteristically, the used various tricks to reach their purpose (surgical correction of the defect): for instance, in the out-patient department they tried to register more than once and to contact different surgeons.

With all the patients examined, the origination of the cosmetic defect, impossibility of its removing by means of cosmetics, as well as morbid fixation to the defect played substantial role in pathogenesis of delayed psychogenic disorders. All these factors resulted in constant and intensive complex state

of excitement which in circumstances of relative psychologic isolation lead to a psychogenic state.

The patients were treated with regard to special features of their clinical picture and to generally recognized principles of therapy of neuropsychological disorders (Alexandrovskii 1976, Avruckii and Neduva 1981, Rozhnov 1978 and others). The treatment consisted of the following steps:

— the removal of a psychical trauma (surgical correction, in most cases representing by itself a very successful component of psychotherapy),
— the psychopharmacological therapy combined with psychotherapy,
— the general prophylactic and therapeutic measures.

Due to specificity of psychogenic disorders, both the pharmacologic and psychotherapeutic interventions were performed only along the axis: patient—doctor, or doctor—medical staff—patient, without any additional social and psychologic support from near relatives and fellow-patients. Only certain portion of patients (23 patients) treated at Moscow Institute of Cosmetology shared their problems and intentions with their relatives or friends, who frequently accompanied them to examinations. The treatment of these patients was more successful — both in the preoperative and postoperative period. They had the advantage of sufficient psychological support from the part of the people who were — together with the patient — anxious about the results of the forthcoming surgery. In some cases we had discussions with relatives or frieds of our patients in order to explain to them the strategy of the preparation of the patient to the surgery, as well as their treatment in the postoperative period — especially after the removal of the dressing. The results were very good, irrespective of the clinical form of the neuropsychological disorder and type of personality.

Simultaneously we performed psychopharmacologic therapy and general somatic treatment. However, not all the patients adopt a positive attitude to psychopharmacologic and psychotherapeutic methods. This concerns, first of all, the patients with asthenic features. Prolonged psychotherapeutic discussions and procedures were often too tiring to them to bring the effect required. In psychotherapeutic discussions we tried to fill our patient with hope and confidence in the future, by giving real examples that surgical correction of cosmetic defects will, apart from a good result itself, change some aspects of their life, and that their adaptation to a new situation will require some time (the readaptation of a man personality is considered quite normal because the operation will change his usual appearance, even if hardly bearable before). At first the patient's as well as that of other people reaction tu surgical correction of the defect can be negative ("it was better before the surgery", "what have they done to you?" etc.). In such cases we tried to explain the temporary character of these feelings and we used psychopharmacologic treatment. This period extended usually from 10 to 15 days after the removal of the dressing. The convincing method resulted in the patient's gradual participation in the treatment, he took it more easily and became gradually used to it.

It is extremely difficult to assess the effectiveness of drugs used for phar-

macopsychotherapy, for very seldom tranquilizers, antidepressants and psychostimulants were used without simultaneous psychotherapy. Phenozepam, tazepam, rudotel, teralene, azaphene, pyrazidol and amytriptylin were used to abase emotional tension, anxiety and fears. In 19 patients with strong neurotic reactions as a result of the climax the best results were obtained by the combination of ambosex, belloid, seduxene and phenozepam. New drugs were included consecutively, starting from the minimum dose.

According to our observation the rational psychotherapy is the most effective in patients suffering from psychogenic disorders with prevailing asthenohysterical syndrome. Suggestion and hypnosuggestion were used mainly for psychotherapy of patients with asthenic disorders. At a particular stage of the treatment (after disappearance of asthenic disorders) a formula of obligatory transition to active autogenic training was applied. For instance: "Your status will improve if you manage to relax and concentrate." We tried to include into each psychotherapeutic group the patients who underwent surgical corrections successfully. They took part in the discussions and oriented other patients for successful results.

The analysis of our results shows that the success of therapeutic measures is determined first of all by surgical correction, prolongation and intensity of clinical symptoms, premorbid type of personality, and also by the "microenvironment". The most effective was the complex treatment with clinically dominant asthenohysterical disorders; the patients most resistant to the treatment were those with asthenoobscessive symptoms. The success of the treatment was dependent on the stage of the development of psychogenic disorder at which the complex treatment began. An earlier request for surgical correction of the defect and — with regard to neurotic reactions to the cosmetic defect — also for specialized psychoneurologic help would be very important factor of prophylaxis of the above mentioned disorders.

In conclusion we should state that the aim of psychotherapeutic and pharmacologic treatment is a short-termed and full-valued rehabilitation of the patients suffering from cosmetic defects of the face. The complex of measures demonstrated above was considerably useful in speeding up the physical as well as psychical compensation of the treated patients. Therefore we feel qualified to recommend the inclusion of the units for psychical rehabilitation of patients with cosmetic defects of the face into cosmetologic institutes.

SUMMARY

The paper concerns some aspects of intensive psychogenic reactions in adult patients suffering from acquired cosmetic defects of the face. It demonstrates that the development of a neurotic state is related to premorbid personality (asthenic, psychoasthenic and hysterical radical). Psychopharmacologic and psychotherapeutic treatment, including the symptomatic therapy, was designed with taking regard to clinical picture and personality into account. The therapeutic measures were aimed at a more rapid reconvalescence and social adaptation of these patients. The treatment used in individual groups of patients is specified.

RESUME

Quelques spécialités et mesures prophylactiques dans le traitement des troubles psychogènes chez les malades entre deux âges avec des défauts acquis sur le visage

Chamov, S. A., Sergeïeff, A. A., Rakitine, M. M.

Le travail porte sur quelques aspects de l'origine des états psychogènes tardifs chez le malade entre deux âges avec les défauts traumatiques acquis sur le visage. La relation de la genèse des états névrotiques entre le type de personnalité prémorbide (asthénique, psychoasthénique ou radical hystérique) est prouvée. En dépendance du tableau clinique et du type de personnalité, on a effectué le traitement psychopharmacologique et la psychothérapie, en profitant d'une thérapie symptomatique. Les mesures thérapeutiques sont orientées vers une convalescence plus rapide et vers l'adaptation sociale de ce groupe des malades. On allègue des résultats du traitement du groupe.

ZUSAMMENFASSUNG

Besondere Züge und profylaktische Massnahmen bei psychogenen Störungen bei Patienten mittleren Alters mit Gesichtsdefekten

Schamow, S. A., Sergejew, A. A., Rakitin, M. M.

In der Arbeit werden einige Aspekte der Entstehung später psychogener Zustände bei Patienten im reifen Alter mit erworbenen traumatischen Gesichtsdefekten beurteilt. Die Beziehung der Entstehung neurotischer Zustände bei dem prämorbiden Typ der Persönlichkeit (asthenisch, psychoasthenisch und hysterisch) ist erwiesen. In Abhängigkeit von dem klinischen Bild und dem Typ der Persönlichkeit wurde eine psychopharmakologische und psychotherapeutische Behandlung unter Einbeziehung symptomatischer Therapie durchgeführt. Die Heilmassnahmen sind auf eine raschere Rekonvaleszenz und eine soziale Adaptierung dieser Patientengruppe gerichtet. Es wird die Gruppenanalyse der therapeutischen Ergebnisse beschrieben.

RESUMEN

Rasgos específicos así como medidas profilácticas en caso de pertubaciones sicógenas en pacientes de edad madura con defectos adquiridos de la cara

Shamov, S. A., Sergeyev, A. A., Rakitin, M. M.

En el trabajo se analizan algunos aspectos del origen de tardíos estados sicógenos en los enfermos de edad madura que tienen defectos traumáticos adquiridos de la cara. Está demostrado el acondicionado surgimiento de los estados neuróticos en un tipo premórbido de la personalidad (radical asténico, sicoasténico e histérico). En dependencia del diagnóstico clínico y el tipo de la personalidad se procedió a un tratamiento sicoterápico con inclusión de la terapia sintomática. Las medidas de terapia tienen el objetivo de acelerar la convalescencia y la adaptación social de este grupo de enfermos. Se describe un análisis por grupos de los resultados de la terapia.

REFERENCES

1. **Avrutzkii, G. Ia., Neduva, A. A.:** Treatment of psychic disorders. M. Medicine, p. 495, 1981.

7. **Matveiev, V. F., Sergeiev, A. A.:** Type of psychic reactions to trauma of the face. In: Therapy and Practice in Stomatology,

2. **Alexandrovskii, Iu. A.**: Psychical desadaptation and compensation. M., Medicine, p. 272, 1976.

3. **Achabadze, A. F.**: Planning and prognosing of cosmetologic care. In: Current Problems of Cosmetology, M., Scientific Reports of MNII of Cosmetology, p. 7, 1977.

4. **Belenkaia, M. Ia.**: Psychiatric diagnosis in cosmetologic treatment. In: Problems of Cosmetologic Rehabilitation. M., Scientific Reports of Beauty Institute, M., p. 38, 1980.

5. **Korkina, M. V.**: Clinical meaning of the dysmorphophobic syndrome. M., Medicine, p. 46, 1973.

6. **Kurindina, L. I.**: Psychical Changes in Physically Inadequate People. Thesis, M., 1979.

Scientific reports of the Institute of Medical Stomatology, M., p. 186, 1967.

8. Handbook af Psychotherapy. Ed. V. E. Rozhnov, Tashkent, p. 639, 1979.

9. **Peskova, H.**: Plastic Surgery of Cosmetic Defects. State Medical Press, Praha, pp. 33—41, 126—131, 1971 (in Czech).

10. **Easson, W. M.**: Psychopathological environment reaction to congenital defect. L. News Ment. Dis., 142 : 453, 1967.

Dr. S. L. Shamov,
Moscow Medical Institute
of Stomatology,
Delegatskaia 20/1, 103473 Moscow,
USSR

FIRST EUROPEAN FLAP DISSECTION WORKSHOP

Hannover, Germany, May 12—15, 1986

This workshop will be based on its American counterpart which has been held in Norfolk Virginia for 9 years. The accent will be on practical cadaver dissections but a panel of well-known European and American surgeons will give tutorials and assist with dissections.

Fees for the 4 day course will be D. M. 900 for surgeons and D. M. 600 for junior staff in training.

Course organisers: Prof. Alfred Berger
Dr. David Tolhurst

For further details and application from please apply to:

Prof. Dr. med. A. Berger
M. H. H.
Klinik für Plastische, Hand- und Wiederherstellungschirurgie
Podbielskistr. 380
D-3000 Hannover 51

J. E. Purkyně University, Brno (Czechoslovakia)
Department of Plastic Surgery
Head Prof. V. Kubáček, M. D., DrSc.
Research Institute of Clinical and Experimental Oncology, Brno
Head Prof. J. Švejda, M. D., DrSc.

NOTES ON THE SURGICAL TREATMENT OF RADIATION INJURIES

V. Riebelová, L. Bařinka, Z. Pačovský, F. Strnad

Local post-radiation lesions — dermatitis, ulceration, malignantly degenerated post-radiation scars — continue to stand out in many respects an open therapeutical problem. This applies primarily to extensive deep therapeutical post-radiation ulceration. The purpose of the present report is to give general guidelines for the treatment of radiation injuries as well as the results seen in four women who had been treated accordingly.

Review of current knowledge and therapeutical principles in post-radiation injuries

A study of the causes of local radiation changes has revealed the fact that chronic radiation dermatitis is essentially a progressive ischaemic vascular disease — sclerosis of the intima — affecting irradiated tissue, combined with atrophy of the skin.

Years of empirical experience and the results of our study have led to the establishment of the following basic, generally recognized principles of radiation lesion treatment:

The only permanently effective and short-term intervention is surgical treatment. This consists of:

1. radical excision of irradiated tissues, if possible, well before the onset of ulceration and other related complications,
2. defect cover replacement by good-quality material amply supplied with blood.

Both principles involve a number of difficult problems concerning both the radicality of excision or the choice of the type and technique of covering the defects.

Excision of irradiated tissues

In the case of therapeutical post-radiation lesions, the planning of the excision as well as the covering of the defects are made much easier by the radiologists' information on the probable area and depth of the injury (result-

ing from fields overlapping, irradiation at an angle, voltage, etc.). This gives the surgeon advance information as to the gravity of the changes he can expect in the region affected, as well as a chance to prepare alternative approaches even in the most adverse situation.

Excision of all the radiation injured tissues is an ideal that cannot always be achieved because of the involvement of vital organs or other important functional structures localized in the affected region. For those reasons, there are problems when dealing with, e. g., full-thickness chest wall defects, defects in the cranial region with bone and brain denudation, necrosis of parts of whole vertebrae complete with adjacent muscle, etc. In such cases there is no other option but a compromise where we leave on the base weakly bleeding sclerotic tissues or even, according to some authors, even noninfected bone that has given way to radionecrosis. Another thing to be borne in mind are the effects of diffuse radiation which are difficult to identify before or even during surgery. These may become manifest in the form of slowed-down postoperative healing, thrombotization of vessels, wound susceptibility to infection, etc. Hence the importance of another need: to excise around the lesion proper a 2, 3 or even more cm broad stripe of intact skin and subcutis to create a broader with a healthy base, and thus to provide suitable ground for the new cover to heal in to. If residual damaged tissue has remained in the middle of the excision, the border should be particularly broad to prevent the development of another radiation injury on the periphery of the wound or in its vicinity.

Covering the defects

In post-radiation defects any replacement of the original cover must meet certain specific requirements and correspond to special principles.

A free graft can be used for a definitive cover only in the mildest and most superficial lesions with the base bleeding freely on excision.

In the case of deep damage, the defect requires the transfer of well-supplied skin complete with the subcutis or even with the fascia and muscle. The tissue thus transferred should have its own permanent pedicle to provide the poorly supplied region with a permanently profuse supply of blood.

Another major principle of post-radiation defect coverage is for the transferred material to cover, if possible at a time, the whole of the damaged region complete with the strip of healthy base. This is to mitigate the danger of infection, provided there is a residual focus of irradiated tissue, and, in this way, to ensure an early union at the edges of the flap. Slow healing in the middle of the defect taking the form of prolonged serous secretion can be managed by continuous suction using suction drainage.

For defect coverage, many authors dealing with radiation injuries seem to prefer large rotation or transposition flaps often prepared with the method of delayed-transfer flaps. On the other hand, they tend to take a reserved if not skeptical view of tube flaps, avoiding their use for chronic radiation injury repair. Mendelson goes as far as talking of "parasitic" flaps likely to cause more damage to the anaemic bed.

Since 1963, Kiricuta and subsequently Dupont, Menard and others have been using for post-radiation chest wall defects coverage the greater omentum covering it with dermoepithelial grafts after it has developed granulations. This method has proved advantageous and useful in many cases. But there are some drawbacks, too — the danger of infection developing in the abdominal cavity, impaired post-operative ventilation, problems involved in the full-thickness coverage of chest wall defects, and, eventually, the impossibility of using it in patients after abdominal operations. However, the method does appear to be able to hold its own as one of the options in dealing with some types of chronic radiation injuries.

The new types of flaps — fasciocutaneous, musculocutaneous and muscular — have made a fine contribution to radiation injury treatment of late, as in many respects they do meet the above listed requirements. However, peripheral necrosis has been reported to have developed even there provided they were planned to maximum extent. In those particular zones there is blood supply both from the main pedicle and from the adjacent areas. The only option in such cases is the use of the delayed transfer flap method.

One more comment on this. Supply pedicles of the planned myocutaneous flaps may have been damaged or destroyed during previous operations or by radiation — even diffuse radiation. It is imperative, therefore, that the existence and intactness of the pedicle should be ascertained pre-operatively, either by ultrasound, arteriography or, eventually, direct visual or manual revision of the pedicle at the start of the operation.

For its safety, large amount of material and range of transfer the musculocutaneous flap from the latissimus dorsi muscle is by far the most widely used transplant well suited for covering defects on the chest, back, upper extremities, neck and nape of the neck. It was described as early as the end of the last century by Iginio Tansini of Italy for breast reconstruction following radical mastectomy. It had a brief period of popularity and than a period of oblivion until D'Este used it for chest wall defect coverage in 1912, and then Davis and Campbell in 1949 and in 1950. In 1955 and 1973 Schottstaedt and Zancolli used it for the elbow region. In 1971, Des Prez used it to cover meningocele. In 1976, Olivari described it again in a case of chest wall defect. In 1979, Bostwick was already able to write a report on 60 surgical operations involving the use of the latissimus dorsi muscle musculocutaneous flap. In Czechoslovakia, Bařinka, Riebelová, Stockarová and Janovič used it for reconstructions of different defects in 1980 to 1983.

Anatomy of the latissimus dorsi myocutaneous flap

The latissimus dorsi is a flat, fan-shaped muscle taking its origin from the lumbodorsal fascia dorsally, from the posterior part of the iliac crest distally, and, in a serrated fashion, from the last three ribs anteriorly. Its narrowed part is inserted in the crista tuberculi minoris humeri. The insertion serves as a support for the posterior axillary fold. The free lateral edge of the muscle follows appproximately the posterior axillary line. The proximal free edge extends across the shoulder blade at Th8 level. At the spinal column it sub-

merges under the trapezius muscle. Its innervation comes from the thoracodorsal nerve, a branch of the dorsal fasciculus of the infraclavicular part of the brachial plexus. Loss of its function — medial adduction of the humerus — is negligible as it is soon compensated by the synergists. The vascular pedicle is made up of the subscapular artery, the terminal branch of the thoracodorsal artery though not until it has given off a branch for the anterior serrated muscle. The vascular bundle enters the muscle about half way up the posterior axillary fold, and it consists of one artery and two veins. Inside the muscle it ramifies into a larger number of branches. The skin and subcutis over the muscle are supplied from perforants arising from the muscle and related to the subcutaneous plexuses. That is why only a part of the skin cover in the shape of an island can be used with the muscle. In the marginal zones, the intercostal arteries participate in keeping the flap supplied.

Surgical strategies

The surgical strategies in the lifting and shifting of the latissimus dorsi musculocutaneous flap depend on which form of transfer is used and on whether the whole flap or only part of it is needed. The latissimus dorsi musculocutaneous flap may take the form of a transposition, rotation or island flap, or it may be used as a free flap transferred microsurgically. We can transfer the whole material of the flap or only part of it.

Transposition, rotation or total island flaps can start being lifted from an incision along the posterior axillary line over the free lateral edge of the latissimus dorsi muscle. This is also where it is easy to penetrate between the muscle and the base and to separate the former from the latter with practically no bleeding at all. Or we can start lifting the flap from an incision over the vertebral spines bounded by Th8—12, or, within the same range, from a paramedial incision. With the lumbodorsal fascia cut open we can see the longitudinally running fibres of the paraspinal muscle fasciae. Entry into the intermuscular space is between them and the lumbodorsal fascia. From there, the isolation of the latissimus dorsi from the base takes much the same course as from the front. The circumcision of the distal part of the flap or also the lifting of its proximal part is then a very easy affair ranging, in accordance with the local situation, from mobilization of just part of the flap up to the total circumcision of the whole circumference of the flap including transsection of the latissimus dorsi insertion with the whole mass of the flap hanging on the vascular pedicle. In minor shifts the secondary defect can be closed by primary suture, in major ones the only way is to cover the secondary defect with dermoepithelial grafts.

The operation strategy is a little more complicated if we have to transfer the whole of the latissimus dorsi muscle with only part of the skin cover in the shape of an island. First, it is necessary to mark the skin cover planned for the transfer over the territory of the latissimus dorsi myocutaneous flap. As a rule, it is spindle-shaped with dimensions of up to 23 cm in length and 12 cm in width.

It runs from the vertebral spine of Th8 at an angle caudalward beneath

the angulus inferior scapulae down to the posterior axillary line. First, we cut open the skin along the circumference of the island down to the muscle tissue, thus creating an island skin flap. Proceeding from a caudal incision we mobilize the skin with the subcutis as far as the lumbodorsal fascia, from which we cut off a branch of the latissimus dorsi. From there we penetrate beneath the muscle, proceeding with the mobilization proximalward complete with the separated skin island. Information about the right layer of muscle of the latissimus dorsi is given by the lower edge of the shoulder blade over which the muscle extends and become narrower in the lateral direction. At the posterior axillary fold level we can easily identify the upper edge of the muscle tissue aiming at the axilla. Mobilization of the skin and subcutis over the proximal part of the latissimus dorsi muscle is then an easy affair performed over a varying distance and in different directions depending on where the flap is to be transferred.

The vascular bundle can be tested by palpation. Using fingers we can feel the pulsation of the thoracodorsal and subscapular arteries.

CASE REPORTS

The following are four cases of deep chronic radiation injuries regarded for many years as inoperable and intractable lesions. We shall then report on a case of therapeutic postradiation dermatitis treated early with the transfer of a myocutaneous island flap from the latissimus dorsi muscle.

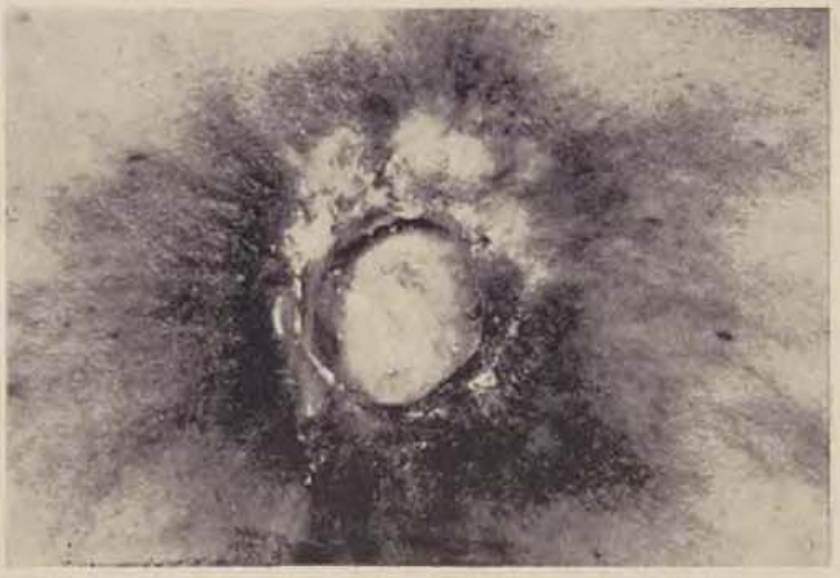

Fig. 1 Therapeutical injury persisting for 5 years following irradiation of malignant melanoma in a 52-year old woman. Situated at the base of the injury are necrotic spinal processes of the 4th and 5th thoratic vertebrae. The neighbouring muscle tissue is also necrotic. State prior to radical surgery

Case 1

Patient H. L., 52 years old, a housewife, clin. notes No. 1625/76. Malignant melanoma on the back found in 1976. Owing to cardiac decompensation radiation treatment was indicated. The patient was given a total of 9,300 rad of

Fig. 2 State 2 years after radical excision including necrotic muscle and spinal processes with the defect covered with trapezius muscle myocutaneous flap prepared beforehand

Fig. 3 Therapeutic radiation injury persisting for 7 years after thoracic and lumbar spine irradiation for metastases from the 72-year old patient's right breast carcinoma. Injury is situated over Th10. Its margin, however, is widely undermined. Part of the spinal processes had succumbed to necrosis as had the neighbouring muscle tissue

Fig. 4, 5 Extent of tissues excised — skin, subcutis, paraspinal muscle

Fig. 6 State 4 weeks after radical surgery. Healed in flap on the thoracic spinal surface. New radiation injury in the lower suture. Despite its enormous extent, the excision proved inadequate. Prior to removal of spinal processes L1 and L2 and of necroses in the vicinity, and prior to more local transposition

Fig. 7 State 2 years after healing

betatron radiation. A year later, a radiation injury 2 cm in diameter and 2 mm deep appeared in the irradiated region. Conservative treatment was unsuccessful. Three years afterwards, the ulcer had grown to 7 cm in diameter and 2.5 cm in depth. Neither laser treatment nor cryalization proved of any help. Within five years of irradiation the injury had deepened to involve two of the vertebral spines (Th4—5). In 1981, 5 years after the radiation therapy, the patient's general condition had improved to a point where we were able to venture surgical treatment. Using radical surgery, we removed the necrotic soft tissues including muscle and excised the necrotic spines of the 4th and 5th thoracic vertebrae. The resulting circular defect, 15 cm in diameter, was covered with a transposition trapezius myocutaneous flap prepared in advance. The wound healed within three weeks. At a check-up three years after the operation the patient was free of any tumour relapse and the irradiated region was covered with good-quality skin with subcutis. The dermoepithelial graft in the secondary defect had become consolidated giving the patient no trouble.

Case 2

Patient P. M., 72 year old pensioner, clin. n. No. 628/72, had her right breast amputated in 1972 with exenteration of the axilla for a solid dissociated carcinoma with metastases in the axilla. After healing, cobalt irradiation was added for safety reasons. A year later, metastases in the thoracic and lumbar regions appeared on X-ray pictures. The spinal column was irradiated with ortho-

Fig. 8 Huge subacute therapeutical radiation injury penetrating into the thoracic cavity resulting from preventive irradiation following left-sided mastectomy for carcinoma in a 52-year old patient

Fig. 9 State after excision of lesion and anterior parts of 3 ribs. Chest opened up. Lungs and pericardium are visible at wound base

X-ray (Th-3 600 rad, L 3600 rad). By the end of the next three months a superficial radiation ulcer had developed over Th10 and kept growing in spite of intensive conservative treatment. By 1977, the patient had developed spastic paraparesis and yet, despite necrectomy, laser and cryalization therapy, the injury went on growing, deepening and giving the victim excruciating pain. In 1981, seven years after irradiation, we removed the radiation-injured soft tissues from Th1 to Th12 including the vertebral spines of Th8—Th12 as well as the adjacent necrotic muscle riddled with suppurative fistulae. The resulting huge defect was covered in the distal portion with a latissimus dorsi musculocutaneous flap (the rotation form), in the proximal portion with mobilization from the sides. The wound became healed in three weeks except for a small defect in the lower pole of the wound which started growing again assumming the character of radiation injury. For that reason we excised this new ulcer 2 and a half months after the operation ablating two more vertebral spines L1 and L2 and covering the soft tissue defect by an exchange of wedge-shaped flaps. The wound healed in 3 weeks. Now, three years later, the operated region is perfectly healed with good-quality material.

Case 3

Patient K. M., a 52 year old teacher, clin. n. No. 423/82, had in March 1982 left-sided mastectomy performed with exenteration of the axilla for an

Fig. 10 Latissimus dorsi myocutaneous flap ready to be transposed into the chest wall defect

Fig. 11 One year atfer flap union. Left upper extremity is without oedema, shoulder joint movement is unimpaired. Patient has no respiratory complaints and no tumour relapses

infiltrating carcinoma. The nodes were negative. Preventive betatron irradiation was started one month post-operatively. After a dose of 3,600 rad, dehiscence developed in the middle of the operation scar slowly assuming the nature of radiation injury. In spite of that irradiation was completed at 5,000 rad. With the course of radiotherapy over, the patient was given four series of chemotherapy (CMF). 6 months post-operatively, the chest featured a large and deep defect 8 by 7 cm in size resisting repeated necrectomy and cryosurgery and showing persistenly infaust progression. For those reasons, on Feb. 1,

Fig. 12 Chronic radiation dermatitis in the right axillary region 18 years after irradiation for right breast carcinoma in a 64-year old patient

1983, we made a radical extensive excision of the injury complete with the resection of the chest wall including the anterior portions of the 2nd, 4th and 5th ribs and the chest wall pleura adhering at one site to the lungs. The resulting defect was covered with a musculocutaneous flap using the latissimus dorsi muscle. All that remained in the posterior axillary fold was a 5 cm wide skin pedicle designed to prevent the development of axillary skin contracture. The secondary defect was covered with dermoepithelial grafts.

Free from complications, the flap healed in within three weeks. Owing to pyocyanic infection, however, protracted healing was noted in the secondary defect which we had to retransplant. In spite of that the patient was healed in less than two months and allowed to return home. One year post-operatively there were no signs of the tumour relapsing. The left upper extremity, prior to operation showing signs of elephantiasis and a major adduction contracture, is free from oedema, movement in the shoulder is entirely unimpaired. The secondary defect transplants are well consolidated with no functional impairment. The post-operative paradoxical deflation of the chest wall at the site of the original defect has been reduced to a minimum. The patient is free from respiratory complaints, and is already able to sign effortlessly.

Fig. 13 Sketch for a latissimus dorsi myocutaneous island flap with the whole muscle planned for transposition but only part of the skin cover

Fig. 14 Flap lifted according to previous sketch diagram, ready for transposition into the axillary region defect

Case 4

Patient L. J., a 64 year old pensioner, clin. n. No. 61412, had her right breast amputated 18 years ago with exenteration of the axilla for carcinoma. Radiation therapy followed, and in the course of years a zone of radiation

Fig. 15 State at a year after the healing in of the flap. Extremity is free of oedema. Shoulder joint movement is free

dermatitis had developed in the right axillary region with threatened ulceration and signs of elephantiasis of the right upper extremity. For those reasons, early total excision of the altered skin and subcutis was performed and the defect covered by sliding in a latissimus dorsi musculocutaneous island flap. The secondary defect could be closed with simple suture. Subsequent healing was free from complications. The right upper extremity shows no oedema, movement in the shoulder joint is free.

Case No. 4 is an example of early indication for surgical treatment permitting transfer of smaller extent, lower risk, and rapid lasting union. In patients No. 3 and 4, an initial stage of upper extremity lymphoedema was noted prior to the operation. This, however, disappeared completely in both cases postoperatively, thus improving extremity function.

RESULTS

In our small series of four therapeutical radiation injuries regarded as inoperable for their localization, depth and extent we tried our treatment using recent technical strategies — radical excision and myocutaneous flap transfer. The results proved highly encouraging. All the three surgical patients were permanently healed within a short period of time (the flaps themselves within three weeks). Operation stress was well tolerated despite advanced age. There were minimal complications.

DISCUSSION AND CONCLUSIONS

The favourable results obtained in our patients fully confirm the validity of the therapeutical principles and technical approaches listed at the beginning of the present report. In our opinion, the indications for early surgical treatment can with justification be extended to cover also radiation injuries regarded until recently as inoperable, provided the neighbourhood offers enough good-quality material with ample blood supply (musculocutaneous, muscular, fasciocutaneous flaps, or the greater omentum). It appears that added to this list of indications should be also certain lymphoedemas of the upper extremities resulting from axillary irradiation as suggested by the results achieved in two of our patients. In any case, however, surgical treatment should be started as soon as possible well before the appearance of all sorts of complications. There remains still the problem of radiation injuries in the lower extremities as not material suitable for transfer is available there. This is apparently where the microsurgical transfer of free flaps should be considered. However, to go by literary reports, the results there do not appear to be unambiguously favourable yet.

SUMMARY

The authors present the results of operations on four patients with therapeutical irradiation injuries long regarded as inoperable. Using radical excision going 2 to 3 cm deep into healthy tissue, and covering the defects with

flaps to provide the damaged site with a lasting ample supply of blood, they were able to achieve early union in a short period of time (the flap transferred — in three weeks). In their opinion, indications for surgical treatment should be broadened to cover all local radiation injuries with enough suitable transferrable material within easy reach, and that well before the development of ulceration (case 4).

RESUME

A propos du traitement chirurgical des ulcérations résultantes de l'irradiation

Riebelová, V., Bařinka, L., Pačovský, Z., Strnad, F.

Le travail apporte des résultats du traitement opératoire de 4 malades avec des ulcérations résultantes de l'irradiation, jusqu'à présent considérées comme incurables. En effectuant des excisions radicales, atteignantes de 2—3 cm au tissu sain, avec le recouvrement des défauts engendrés par des lobes qui assurent une riche alimentation sanguine de la région endommagée, les auteurs ont aquéri la guérison chez tous les 3 cas dans un temps court (lobes de transposition guéris dans 3 semaines). Les auteurs présument qu'il soit possible étendre des indications au traitement opératoire à tous les lésions locales résultantes de l'irradiation, qui sont entourées du matériau convenable aux transpositions, même dans la période de préulcération (4ème cas).

ZUSAMMENFASSUNG

Bemerkungen zur chirurgischen Behandlung von Postradiationsgeschwüren

Riebelová, V., Bařinka, L., Pačovský, Z., Strnad, F.

In der Arbeit werden die Operationsergebnisse bei 4 Patienten mit therapeutischen Postradiationsgeschwüren angeführt, die bisher als unheilbar angesehen wurden. Durch radikale Exzisionen, die 2—3 cm tief in das gesunde Gewebe eingriffen, und durch Bedeckung der so entstandenen Defekte mit Lappen, die eine stetige und reichhaltige Blutzufuhr in die beschädigte Region gewährleisteten, erzielten die Autoren in allen Fällen eine Heilung in sehr kurzer Zeit (drei Wochen). Sie nehmen daher an, dass die Indikationen zur operativen Behandlung auf alle lokalen Postradiationslasionen erweitert werden können, bei denen genügend geeignetes Material zur Überführung zur Verfügung steht und zwar noch vor der Bildung von Ulzerationen (4. Fall).

RESUMEN

Notas sobre el tratamiento quirúrgico de úlceras productos de rayos x

Riebelová, V., Bařinka, L., Pačovský, Z., Strnad, F.

En el estudio se indican resultados operativos en 4 pacientes afectados por úlceras causadas por la terapía de radiación que hasta ahora fueron consideradas incurables. Con excisiones radicales de hasta 2 a 3 cms. efectuadas en los tejidos sanos y cubriéndose los defectos así producidos con lóbulos que posibilitan una afluencia permanente a la zona afectada de cantidades de sangre, los autores han podido conseguir la cicatrizacion en todos los casos y a la mayor brevedad (un lóbulo trasplantado en tres semanas). Opinan pues que nada impide implementar esta indicacion para cualquier zona local con lesión postradial en cuya proximidad se encuentre la suficiente cantidad de material adecuado para el transplante todavía antes de que se vayan produciendo las ulceraciones. (Como en el caso 4.)

/

REFERENCES

1. **Bařinka, L.**: The use of latissimus dorsi musculocutaneous island flap for breast reconstruction (in Czech). Personal communication, 1981.

2. **Bařinka, L.**: Correction following incorrectly performed cosmetic operations on the breasts (in Czech). Symposion plast. surg. ČSSR, October 1982.

3. **Hodgkindson, D. J., Arnold, P. G.**: Chest wall reconstruction using the external oblique muscle. Brit. J. plast. Surg., 33 : 216, 1980.

4. **Janovič, J., Brozman, M., Fedeleš, J.**: Breast reconstruction using myocutaneous flaps (in Slovak). National scientific conference of plastic surgery, April 1983.

5. **Leonard, A. G.**: Reconstruction of the chest wall using a deepithelialized "turnover" deltopectoral flap. Brit. J. plast. Surg., 33 : 187, 1980.

6. **May, J. W., Toth, B. A., Cohen, A. M.**: Three major latissimus dorsi skin island flaps for chest wall reconstruction. Plast. reconstr. Surg., 69 : 326, 1982.

7. **Riebelová, V.**: Operative counselling in plastic surgery (in Czech). National scientific symposium of plastic surgery, April 1982.

8. **Riebelová, V.**: Reconstruction of post-radiation defect in the chest wall using a latissimus dorsi myocutaneous flap (in Czech). National scientific conference of plastic surgery, April 1983.

9. **Schrude, J., Petrovici, V.**: The use of sliding-swing plasty in closing skin defects: a clinical study based on 1,308 cases. Plast. reconstr. Surg., 67 : 467, 1981.

10. **Stockarová, D.**: Breast replacement following mastectomy using latissimus dorsi myocutaneous island flap (in Czech). National scientific conference of plastic surgery, April 1982.

For other references contact the authoress.

Dr. V. Riebelová,
Dept. of Plastic Surgery,
Berkova 34, 612 00 Brno,
Czechoslovakia

9th Meeting of the International Society of Microsurgery will be held in Brescia (University Medical School) from 27th July to 1st August, 1986.

Further information can be obtained from Organizing Secretariat — Masson Italia Congressi, Via Baldissera 4, 20129 Milan, Italy.

BOOK REVIEW

Principles and Practice of Surgery. A Surgical Supplement to Davidson's PRINCIPLES AND PRACTICE OF MEDICINE.

A. P. M. Forrest, D. C. Carter, I. M. Macleod. Churchill Livingstone. Edinburgh, London, Melbourne and New York. 1st edition 1985.

This is a 672-page publication by three prominent professors of surgery at medical faculties in Scotland, the result of years of planning by the last of the three, and the accomplishment of the idea of a standardized one-volume work designed to comprise all the essential knowledge necessary for post-graduate qualification in surgery and for medical students in Great Britain in an integrated, easy-to-survey and factual way. Besides the editors, nine more professors specializing in the field had each a share in compiling the special surgery part.

Following the introductory part the book is divided into 41 chapters, the first 15 of which discuss on 167 pages the problems of general surgery, the next 25 deal with problems of special surgery, and the 41st together with appendices covers general surgical operations and the administrative and juridical problems of surgical patients in Britain. The whole work is devised very comprehensively and, as regards the division into chapters, similarly as in most textbooks of surgery though in some chapters, particularly those on general surgery, more concisely than in our textbooks for 1st-degree post-graduate qualification exams. The opening chapter "Examination and diagnosis of surgical problems" presents modern methods of investigation. Oddly, the traumatology of the extremities has been omitted. In contrast, the chapter on shock is compiled in a very good, modern way. The advantage of the publication is in the integrated manner of planning designed to include the latest achievements of science and, at the same time, to respond to research and its practical uses. An example of modern approach, the textbook is supplemented with a multitude of objective illustrations, diagrams, graphs and tables. Of particular value is the close touch with the latest scientific achievements and their undelayed inclusion in the publication.

Dr. O. Schütz,
Department of Surgery,
Charles University Paediatric Faculty,
Prague, Czechoslovakia

J. Zoltán: **Atlas of Skin Repair.** Akadémiai Kiadó, 1984, Budapest, Hungary, ISBN 963 05 3244 1.

Following his classical monograph "Cicatrix Optima", this well-known Hungarian plastic surgeon has published another monograph, this time on the principles of skin repair. On 304 pages of glossy paper his atlas contains illustrative photographs, drawings and sketches, each with a brief text explaining the approaches to and principles of surgical repair. The opening general part consists of descriptions and illustrations of the general technical procedures of plastic surgery: local shifts, tubed flaps, arterial flaps and also the latest techniques such as myocutaneous flaps and the microsurgical essentials of tissue transfer, as well as types of skin transplantation. The other, special part also gives illustrated applications of those techniques in diverse regions of the body. All the techniques are accompanied by objective illustrations of a whole number of variations devised by world famous clas-

sics of plastic surgery, mostly with the authors' names. More instruction is to be found in an extensive bibliography. The monograph is the result of the author's extremely hard work and years of purpose-oriented gathering of the most suitable clinical cases. This book definitely serves as a source of instruction on the principles of plastic surgery and its techniques not only for beginners in the specialty but also for seasoned workers in traumatology, orthopaedic and general surgery.

Dr. R. Vrabec,
Příčná 1, 110 00 Prague,
Czechoslovakia

"Plastic Surgery", a book written in the Bulgarian language was published in 1984 in the Medicine and Physical Culture publishing house in Sofia with professors Shindarski, Chervenkov and Matev as editors. Beside them, 6 experienced plastic surgeons took part in compiling the book.

The publication has 286 pages, including extensive domestic and foreign references, and is abundantly documented with easy-to-survey drawings as well as a large number of photographs some of them in colour. It discusses the scope for reconstructive and plastic operations anywhere on the body surface. The text is divided into the general and special parts with brief summaries in English attached.

This book compiled by experienced plastic surgeons is bound to add a great deal to Bulgarian medical literature. It will be found useful not only by prospective and beginning plastic surgeons but, thanks to some of the original surgical approaches, by experienced adepts in the field as well. I am sure it would be greatly appreciated by the founder of Czechoslovak plastic surgery and teacher of many Bulgarian specialists — Academician František Burian, whose pioneering work is rightly commemorated by the book's authors.

Dr. H. Pešková, DrSc.,
Husinecká 3, 130 00 Prague 3,
Czechoslovakia

CONTENTS

STOP FOR A MOMENT AND CONSIDER YOUR HEALTH



DAY AFTER DAY AND YEAR AFTER YEAR YOU ARE CONSTANTLY CHASING SOME AIM OR ANOTHER, YOU STRETCH THE MAINSPRING OF YOUR HEALTH TO THE VERY MAXIMUM. AND HOW LONG DO YOU THING YOU CAN CONTINUE TO DO SO? REMEMBER THAT YOU HAVE ONLY ONE HEALTH AND FINALLY MAKE UP YOUR MIND TO GRANT IT, AT A VERY REASONABLE PRICE, WHAT IT DESERVES: COMPLEX TREATMENT AT ONE OF THE OLDEST AND THE MOST WIDELY RECOGNIZED SPAS IN EUROPE.

CZECHOSLOVAK SPAS — OASES OF HEALTH,
QUIET AND INSPIRATION

KARLOVY VARY — FRANTIŠKOVY LÁZNĚ — MARIÁNSKÉ LÁZNĚ — JÁCHYMOV — TEPLICE V ČECHÁCH — PODĚBRADY — JANSKÉ LÁZNĚ — TREBOŇ — JESENÍK LUHAČOVICE — TEPLICE NAD BEČVOU

BALNEA
PRAHA

BALNEA PRAHA - REPRESENTATION OF CZECHOSLOVAK SPAS AND MINERAL SPRINGS
110 01 PRAHA 1, PAŘÍŽSKÁ 11 — TELEX, 122 215 - CZECHOSLOVAKIA