ACTA CHIRURGIAE PLASTICAE

INTERNATIONAL JOURNAL
OF PLASTIC SURGERY

34·1

1992

CS ISSN - 0323-0414

AVICENUM — CZECHOSLOVAK MEDICAL PRESS
PRAGUE

Exclusive Distributors for all Western Countries
KARGER - LIBRI AG, Peteergraben 31, CH-4000 Basel 11 (Switzerland)

Distributed by PNS. Information on subscription can be obtained from and orders are accepted by every administration of PNS, post-office, postman and PNS Central Expedition Prague. Orders for abroad are accepted by PNS Central Expedition and Press Import, administration of press export, H. Píky 26, 160 00 Praha 6.

Published four times (in 1959: two times) a year by Avicenum — Czechoslovak Medical Press, Malostranské nám. 28, Praha 1. Editor in Chief prof. M. Fára, M. D. DrSc. — Adress of the Editorial Office: Acta Chirurgiae Plasticae, 100 34 Praha 10, Šrobárova 50, Czechoslovakia — Press: Tiskařské závody, provoz 33, Praha 2, Hálkova 2. Exclusive distributors for all countries with the exception of Albania, Bulgaria, China, Cuba, Czechoslovakia, Hungary, North Korea, Vietnam, Mongolia, Poland, Romania, the Commonwealth of Independent States and Yugoslavia:
KARGER LIBRI AG, Petersgraben 31, CH-4000 BASEL 11 (Switzerland)

Department of Plastic Surgery
Královské Vinohrady Teaching Hospital
Director: Prof. MUDr. M. Fára, DrSc.

BREAST RECONSTRUCTION FOLLOWING MASTECTOMY WITH PEDICLED AND FREE TRAM FLAPS

A. NEJEDLÝ, M. TVRDEK

INTRODUCTION

At present, mastectomy can be regarded as one of the mainstays in the treatment of breast cancer. However, besides its therapeutic effect, the method has also considerable adverse effects on the woman involved. Women undergoing the procedure have to cope with substantial psychic stress, in addition to functional limitations. The status after mastectomy gives rise to a feeling of deformity, the women lose their feeling of feminity, their sexual gratification is reduced and, last but not least, the loss of a breast serves as a constant reminder of the presence of a neoplasm. The choice of attire is rather limited, and the women are faced with problems due to wearing an ectoprosthesis. The contracting scar reduces the extent of the upper limb's mobility, and the hypersensitivity present around the scar is just another source of complaints reported by women following mastectomy. Having considered all the above mentioned negative effects, it is appropriate to regard a correctly indicated breast reconstruction as part of comprehensive treatment of breast cancer.

INDICATIONS

Those eligible for breast reconstruction using a transposed or free TRAM flap include all young or middle-aged women free of any disease other than carcinoma and, also, those willing to undergo one-stage breast reconstruction using autologous tissue, who are, at the same time, reluctant tohave a plastic implant. The procedure is indicated in women with stage I or II tumour and treatment (radiotherapy in particular) completed at least a year before the reconstruction. Provided a higher stage tumour is involved, the reconstruction is performed at a five-year interval since mastectomy. A conditio sine qua non is the absence of metastases. It is our policy to indicate the patient for the procedure in collaboration with an oncologist.

A scheduled breast reconstruction using a TRAM flap requires sufficient excess of skin cover and subcutis in the regions of the meso- and hypogastrium. Another precondition is an intact abdominal wall, without previous laparotomies that may have injured m. rectus abdominus and epigastric vessels.

PATIENTS AND METHOD

Beginning November 1990, a total of 9 breast reconstructions using a TRAM flap have been performed in patients aged 34 to 49 years. Eight of them underwent mastectomy for stage I and II carcinoma. The interval between mastectomy and reconstruction was up to three years. In one patient with a stage III carcinoma, mastectomy was undertaken five years ago.

The first three breast reconstructions were carried out using TRAM flap transposition (Fig. 1). To perform the procedure, the ipsilateral m. abdominus rectus was transposed (Fig. 2).

Fig. 1. Patient No. 1. before reconstruction using TRAM flap transposition

In one patient, a secondary defect of the anterior leaf of m. abdominus rectus was successfully closed by direct suture. In other two patients, the defect was closed using a mobilised segment of the contralateral anterior leaf of m. abdominus rectus (Fig. 3).

The pedicled TRAM flap was invariably long enough to allow free placement of the flap into the reconstruction site (Figs. 4, 5).

Fig. 2. Harvested flap with a rectus muscle pedicle

Fig. 3. Closure of the contralateral rectus muscle sheath defect

Fig. 4 and 5. Patient No. 2 after reconstruction by means of pedicled TRAM

In other six patients, breast reconstruction using a free TRAM flap was performed (Fig. 6). On the homolateral side inferior epigastric vessels were adopted as flap's pedicle (Fig. 7).

Fig. 6. Patient No. 2 before reconstruction using a free TRAM flap

In all cases, the internal thoracic vessels were used as recipient ones after anastomoses, a sufficiently long flap pedicle was created and enabled fully free position of the flap (Fig. 8).

The defect of the anterior leaf of rectus muscle following free flap transfer was minimal and direct suture was possible (Fig. 9).

In our patients, the postoperative course was mostly uncomplicated. In transposed flaps there always occurred a small ischaemic defect in contralateral pole of the flap. However, it could be healed by excision and suture.

In the abdominal wall suture, no hernia was observed even in a long term follow up (Figs. 10, 11).

A pedicled or a free TRAM transfer allows breast reconstruction using autologous well perfused tissue.

This procedure ensures a sufficient amount of tissue, and the reconstruction can be performed even in cases where mastectomy had caused an extensive defect of the chest wall. Using this technique, a satisfactory contour and suitable consistency of the breast can be obtained. There is no atrophy of the flap tissue. In opposite, there is no need to augment reconstructed breast by

Fig. 7. The mobilised free flap before transfer. The pedicle is formed by inferior epigastric vessels.

Fig. 8. Free flap after perfusion has been restored, arrow indicates side of anastomosis.

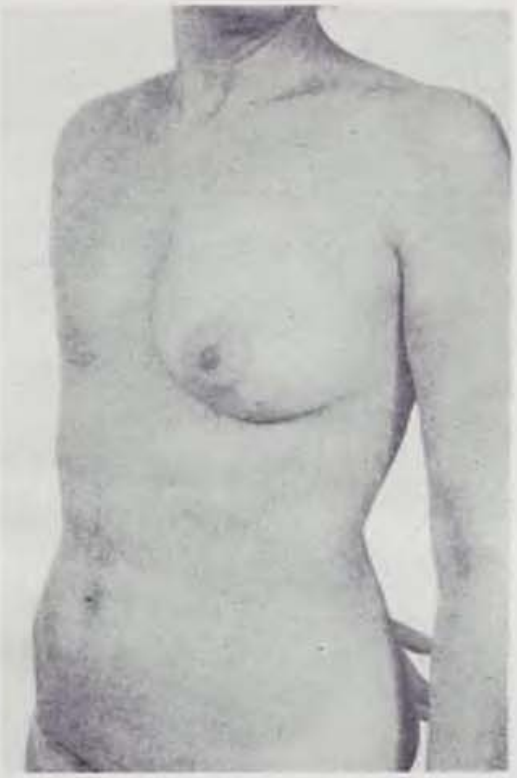

Fig. 9. Patient No. 2 after breast reconstruction using a free TRAM flap

Fig. 10. Patient No. 3 before reconstruction using a free TRAM flap

means of prostheses. If the patient is able to undergo a free TRAM transfer, we prefer this procedure to the pedicled TRAM because of the following reasons: Perforators insuring perfusion of the flap tissue are direct branches of epigastric vessels and the flap is thoroughly and well perfused at all times. There is no excessive tissue in the subcutis at the side of pedicle rotation, with the pedicle made up of the rectus muscle in the transposed flap. The small defect of the rectus muscle sheet following free flap transfer enables reliable direct suture minimising the risk of hernia.

Fig. 11. Patient No. 3 after breast reconstruction

SUMMARY

The authors present a group of nine patients after mastectomy. Breast reconstruction was performed by transposition (3) or by free transplantation (6) of a TRAM flap. Based on a review of literary reports, and on their own experience, the authors consider this procedure to be a reliable and effective method of breast reconstruction.

Key words: Breast reconstruction; transposed TRAM flap; free TRAM flap.

RÉSUMÉ

Reconstruction mammaire après mastectomie par lobe transposé et lobe libre — TRAM

Nejedlý, A., Tvrdek, M.

Les auteurs présentent un groupe de neuf patientes après mastectomie. La reconstruction du sein était effectuée par transposition (3) ou par transfert libre (6) du TRAM-lobe. Selon les données littéraires ainsi que selon leurs propres expériences, les auteurs considèrent ce procédé opératoire comme une méthode fiable et efficace de la reconstruction mammaire.

ZUSAMMENFASSUNG

Die Rekonstruktion der Brust nach einer Mastektomie durch einen transponierten und einem freien TRAM-Lappen

Nejedlý, A., Tvrdek, M.

Die Autoren stellen eine Gruppe von neuen Patientinnen nach einer Mastektomie vor. Die Rekonstruktion der Brust wurde durch eine Transposition (in drei Fällen) oder freie Übertragung (in sechs Fällen) eines TRAM-Lappens ausgeführt. Der Literatur nach sowie auch auf Grund eigener Erfahrungen erachten sie diesen operativen Vorgang als zuverlässig und als effektive Methode einer Rekonstruktion der Brust.

REFERENCES

1. **Stephen J. Mathes, Foad Nahai:** Clinical applications for muscle and musculocutaneous flaps, The C. V. Mosby Company, St. Louis, Toronto, London, 1982.
2. **Herman T. Smet:** Tissue transfers in reconstructive surgery, Raven Press, New York, 1989.
3. **W. W. Shaw:** Microsurgery in trauma. Futura Publ. Comp., Mount Kisco, New York, 1987.
4. **W. W. Shaw:** Free tissue transplantation to the breast (presented at 59th Annual Scientific Meeting, Boston, 1990).
5. **Carl R. Hartrampf, Jr.:** The transverse abdominal island flap for breast reconstruction, Plastic and Reconstr. Breast Surgery, 15, 4, Oct. 1988.

MUDr. A. Nejedlý
Department of Plastic Surgery
Královské Vinohrady Teaching Hospital
Šrobárova 50
100 34 Prague 10
Czechoslovakia

Sverdlovsk Branch (Director — S. M. Kutepov) of the All-Union Kurgan Scientific Centre for Reconstructive Traumatology and Orthopedics, Ministry of Health, Yekaterinoburg, Russia

EXPERIMENTAL SUBSTANTIATION OF ALLOGENIC TENDON TISSUE TRANSPLANTATION

V. A. PLOTNIKOVA, I. A. STAKHEYEV, V. P. SHTIN

The selection of plastic material for the treatment of patients with defects of tendons and ligaments of varying origin has always caused difficulties (1—3). Experience gained in the treatment of 418 patients of the Sverdlovsk Research Institute of Traumatology and Orthopedics during the period 1982 to 1986 proved preserved allogenic tendons to be the best plastic material at present. This, however, requires a preservative maintaining the biological and mechanical properties of the transplant at their best. The present paper is devoted to this problem.

There are various methods of sterilization and preservation of biological tissues. Among them, liquid preservative media are quite important. From the sixties, weak (0.5 and 0.25 %) formaldehyde solutions, exhibiting simultaneously sterilizing and preservatory effects, started to be increasingly used for the preservation of biological tissues. The studies of V. P. Parfent'eva et al. have pointed out (5) that formaldehyde as a preservative should be paid more attention. However, further investigations have revealed toxic effects of 0.5 % and 0.25 % formaldehyde solutions on the tissues of the transplant and its bed (4); in these solutions the elasticity of the preserved tissues decreases (6, 8).

That is why we set the task to develop a new solution preserving the biological properties of tissues to the utmost.

MATERIAL AND METHOD

Taking into account the known properties of the medicinal preparations, we experimentally used 0.1 % formaldehyde solution (F) and added dimethyl sulfoxide (D) — a cellular protector (0.5 ml/l, monomycin (M) — an antibacterial preparation (0.5 g/l), prednisolone (P) — a preparation with anti-inflammatory and immunodepressive effects (60 mg/l): the obtained solution = FDMP. The solution was made up by V. I. Savel'yev et al. (6).

We examined the behaviour of the chemical ingredients in the solution since the sterilizing complex was a mixture of active substances. The chemical interaction was studied spectrophotometrically in the UV portion of the spectrum

Cadaver skin served as the test object for the study of the sterilizing properties of the solution. Reproductivity of microbial flora was examined before and after sterilization using solution of the above mentioned components taken separately, in various combinations and as a complex. In addition, the sterilizing effect of the solution was tested on museum strains of microorganisms (Staphylococcus aureus, Proteus vulgaris, Streptococcus faecalis, Klebsiella, Escherichia coli). The concentration of microbial cells corresponded to the size of the suppurative wound. The intervals of sterilization ranged from 1 to 7 days.

Two series of experiments concerned with comparative investigation into the structural changes in tendons preserved in 0.5 % formaldehyde solution and in the FDMP solution were set up. The periods of preservation ranged from 15 to 180 days. The integrity of colagen was studied by test-tube determination of the sped of resorption of preserved tendon tissue using bacterial collagenase. The speed of resorption was assessed according to the quantity of oxyproline in the solution.

Comparative studies of the effect of 0.25 % and 0.5 % of formaldehyde solution and the FDMP solution, respectively, on the tensile strength and elasticity of tendon tissue were carried out. The results were compared with the indices of mechanical properties of native tendons. The periods of preservation ranged from 3 to 180 days. Changes in the mechanical properties were assessed according to the limits of tensile strength and elasticity on stretching the samples.

In order to explore the processes of reconstruction of the tendon transplants preserved by various methods, a total of 84 dogs (three series of experiments) were operated on. Series I consisted of 26 dogs with re-implantation of the middle third of Achilles tendon (control); series II of 26 dogs with transplanted allogenic tendon fragments preserved in 0.5 % formalin solution; series III of 32 dogs with transplanted allogenic tendon grafts preserved in the FDMP solution.

The periods of observation of the animals were 14, 21, 45, 180 and 365 days.

The operation was caried out under general anesthesia by thiopental-sodium solution (0.5 ml 5 % solution per 1 kg body mass of the animal) administered intravenously until deep sleep set in. Upon that, the skin and subcutaneous cellular connective tissue were incised on the posterior surface of the leg. The loose connective tissue was bluntly drawn apart and the Achilles tendon laid bare. The middle portion of the Achilles tendon from 2 to 4.5 cm long (in most cases 3.5—4 cm) was excised by means of a razor and removed. Autotransplant or preserved allotransplant was inserted into the defect. The ends of the tendon were sutured with a kapron thread ac-

cording to Cuneo. The extremity operated on was immobilized with plaster-of-Paris bandage for 3 weeks.

The animals were sacrified by intravenous or intrapulmonary administration of lethal doses of 10 % thiopental-sodium solution. To study revascularization of the transplanted graft on sacrificing the animals the operated and intact limbs were infused with the red mass of Gerrot through the femoral arteries in part of the cases.

RESULTS

The obtained results have shown that the proposed solution FDMP for the preservation of tissues keeps up their biological properties to the utmost; sterility remains unimpaired during a year (Fig. 1). It has been established

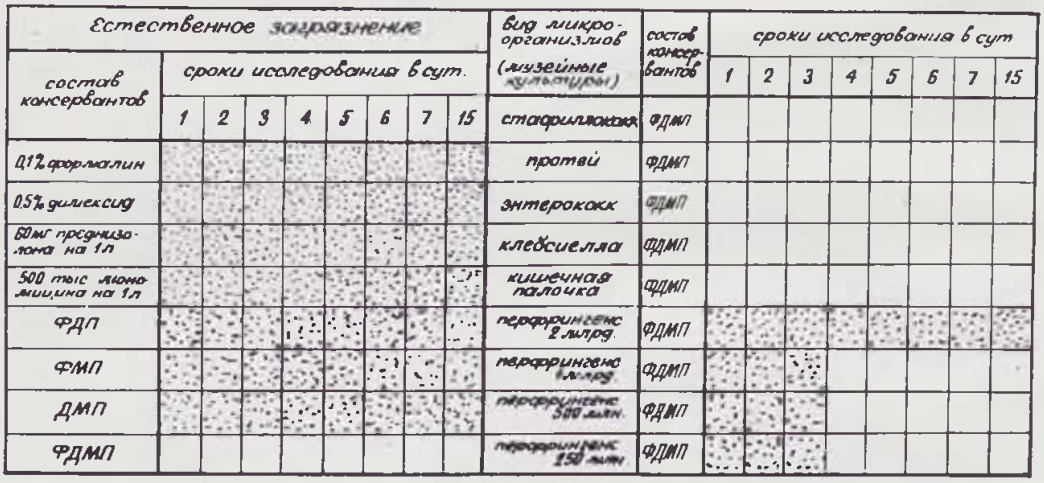

Fig. 1. Results of examination of sterilizing properties of various solutions. (Empty squares — sterile, dotted squares — unsterile.)

by spectrophotometric investigations that the components of the solution do not lose their individual properties when mixed, they complement each other and thus enhance the sterilizing effect. Histological examination by means of a light microscope virtually did not reveal any morphological changes in the structure of the preserved allotransplants, the tissue maintained its typical texture. Biological studies of the tendon tissue using bacterial collagenase have demonstrated that transplants preserved in the FDMP solution were resorbed more slowly than frozen transplants, but more quickly than those preserved in 0.5 % formaldehyde solution. This testifies to the fact that the processes of resorption and replacement of the transplants preserved in the FDMP solution were synchronous.

Biological properties of the tendons changed starting from the first

month of preservation. The tendons acquired great toughness, the limit of tensile strength increased. Changes in mechanical properties of the tendons could be observed in all concentrations of formaldehyde (0.5 %, 0.25 %, 0.1 %), and the higher the concentration, the more pronounced were the changes.

The same dependence was found in the study of the elastic properties. The tendons were more elastic when preserved in the FDMP solution; out of the three preservatives under study, we therefore gave preference to 0.1% formaldehyde solution with the addition of dimethyl sulfoxide (dimexide), monomycin and prednisolone (FDMP).

In the experimental studies carried out on 84 dogs, certain differences were established in the process of reconstruction of transplants preserved in different ways (in the FDMP solution, in 0.5 % formaldehyde solution), and of autotransplants.

On the 14th postoperative day, no essential differences were revealed in the 3 series on macroscopic examination. The tendons operated on formed a loose connective-tissue band united with the surrounding tissues and enlarged 2—3 times in diameter as compared with the tendon in the control limb. Histological examination showed the tissues of the autotransplant to be homogenized, partly fragmentated, devoid of vessels and cell elements. After autoplasty and alloplasty using a transplant preserved in the FDMP solution, an increased number of fibroblasts and vessels oriented towards the junction could be observed at the ends of the maternal tendon. Migration of fibroblasts could be noticed in the tissue of the transplant. In the experiments where tendon allotransplants preserved in 0.5 % formaldehyde solution were used, no signs ever of even beginning reconstruction could be traced.

By the 21st day following operation, the tendons operated on remained macroscopically enlarged in all the 3 series. There was a difference in cases of autoplasty using grafts preserved in the FDMP solution: the loose connective tissue surrounding the transplant stuck closely to it. In histological examinations of all series at this interval, the transplant presented homogenized vessel-free tissue with reconstruction close to the junction and in the superficial portions of the transplant. When using autotransplants and allotransplants preserved in the FDMP solution, fibroblasts and vessels of the capillary type penetrated the tissue of the transplant to a depth of 1—2 mm; there were no vessels in transplants preserved in 0.5 % formaldehyde solution.

By the 45th day in the first 2 series, the operated tendon presented a solid connective-tissue band; in experiments where 0.5 % formaldehyde solution was used, the connective-tissue band in the place of the tendon operated on was loose and enlarged in diameter.

Histological examination revealed unreconstructed sections with homogeneous structure in the central portions of the transplant. In autotransplants, these sections were smaller in size.

Replacement of the transplants by young connective tissue proceeded from the recipient bed as well as from the junctions: in the latter case, it was more active (Fig. 2, a). Unlike other series, the experiments using 0.5 % solution

showed dystrophic changes in the form of basophilic foci and pronounced swelling at the ends of the maternal tendon.

By the 90th postoperative day, histological examination revealed signs of active reconstruction in all parts of the transplant. The fibroblasts were large, with hyperchromic nuclei. They penetrated into the transplant both from the surrounding tissues and from the junctions. Vessels of the capillary type became visible in these parts. However, even after autoplasty, there were areas of unreconstructed homogenized tissue in the very central parts of the transplant, and in experiments using 0.5 % solution, such areas were found even in the region of the junctions. In autotransplants and allotransplants preserved in the FDMP solution, collagen fibres were oriented longitudinally,

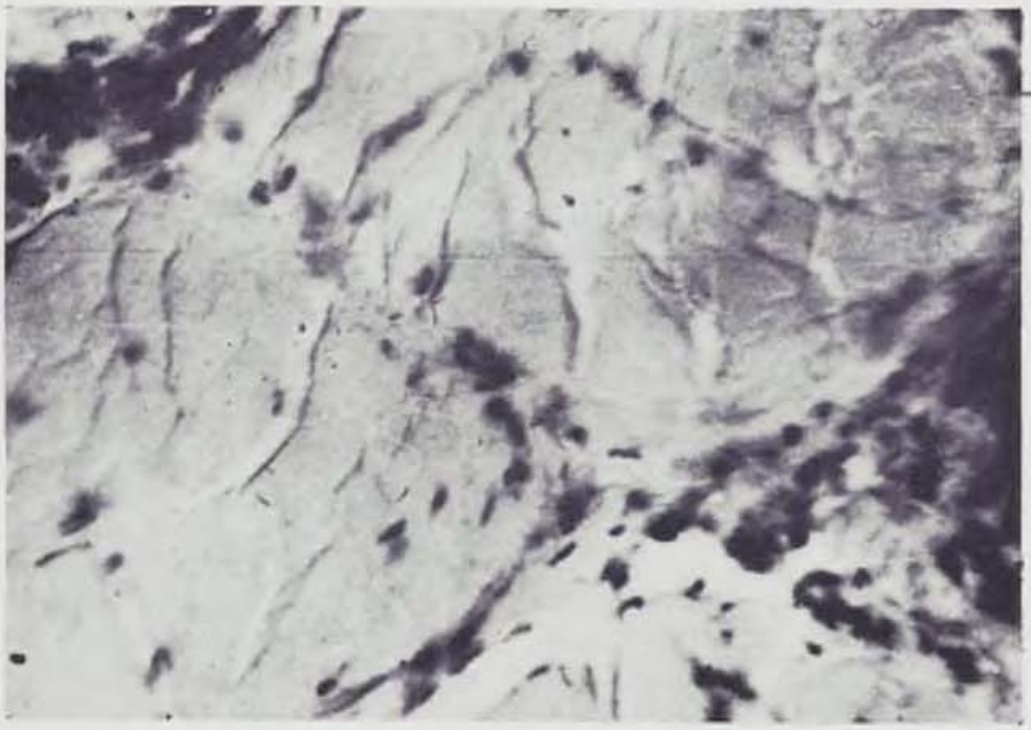

Fig. 2. Histological picture of reconstruction of a tendon transplant at various intervals following operation.
a — 45 days after operation. Penetration of cellular elements into the transplant. Staining hematoxylin-eosin. Magn. 140×;

whereas in transplants preserved in 0.5 % solution, the fibres just only started taking the longitudinal course even at the proximal junction.

By the 180th day after operation in the series with 0.5 % formaldehyde solution, the regenerate was considerably thicker (4—5 times) than the control tendon. Poor tensile strength of the tendon operated on was established. The function of the operated limb was imperfect, the animals spared the limb

pulling it up during examination. In the two other series, the function of the operated limb was fully developed.

On histological examination in the series with autoplasty and transplants preserved in the FDMP solution, the transplant presented young tendinous tissue (Fig. 2, b). Fibroblasts showed a more oblong shape, the outlines of collagen fibres became more distinct.

In the series with 0.5 % formaldehyde solution, multiple nucleus-free areas of homognized tissue were encountered in the visual field. Longitudinal orientation of collagen fibres and fibroblasts was not established. Complete disorientation of the fibres could be observed in some of the sections. Their arrangement was loose, they failed to become compact.

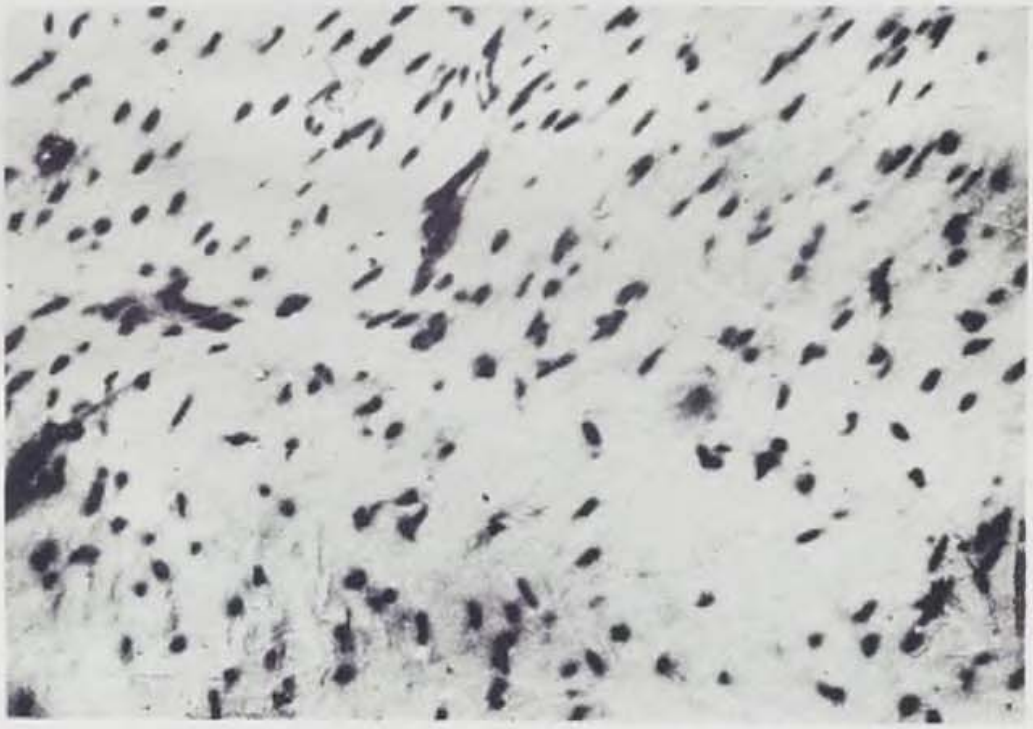

b — 180 days after operation. Young tendon tissue with a large number of cellular elements. Magn. 140×;

A year postoperatively, the animals in all series of experiments put full weight on the operated limb and jumped on the hind paws. However, on histological examination, the regenerate did not show the structure of a native tendon. In the series with autoplasty and the FDMP solution, the structure of the young tendinous tissue was more mature: most fibroblasts had assumed oblong shape, collagen fibres were clearly outlined, thin layers corresponding to endotenon and peritenon could be well distinguished; vessels of the capillary type were present in the layers (Fig. 2, c).

Impaired architecture in the central sections and in the region of the distal suture was observed in the series with 0.5 % formaldehyde solution. In the middle of mature tissue, there were areas with hyperchromic nuclei, this testifying to retarded reconstruction of these sections.

The results of the experimental investigation have shown that the process of reconstruction in the experiments using allotransplants preserved in the FDMP solution was very similar to that in autotransplants at the intervals under study. In the experiments with 0.5 % formaldehyde solution, reconstruction of the tissue of the transplant was found to be retarded and complete replacement of the latter by newly formed tissue failed to take place even by the 180th day. Compact state and orientation of the fibres in experiments with 0.5 % formaldehyde solution were not achieved even after a year of observation after operation.

c — 360 days after operation. Bundles of collagen fibres of 1st and 2nd order, endotendineum with undifferentiated cell elements in between (a), staining hematoxylin-eosin. Magn. 140×.

Good results of tendon transplantation thus depend on a number of conditions among which the methods of preservation of tissues are of great importance. The proposed solution FDMP for the preservation of tendons meets all the necessary requirements, it maintains the biological properties of the tendons to a maximum and, in addition, has an adequate sterilizing effect.

In the period from 1982 to 1986, tendons preserved in the FDMP solution were used in the clinics of the Sverdlovsk Research Institute of Traumatology and Orthopedics, in the health service establishments of Sverdlovsk and the region in treating 418 patiens with chronic damage to ligaments of the knee joint and the ankle joint, injuries to the Achilles tendon and the acromio-clavicular joint. The remoteness of injury ranged from 6 months to 6 years. Allografts of tendons of the muscles of the leg and ligaments of the knee cap served as plastic material. In all cases, the wounds healed by first intention in the postoperative period. No deviations whatever, connected with the use of preserved allotransplants, from the usual clinical picture following intra-articular operations, were observed. Examination of the functional results in the operated patients after periods up to 2 years showed an improvement of function in the joints operated on after a year in all cases, and full restoration of the function occurred in the subsequent periods.

From the complications, we can mention defibering of the allotransplant in an operation using the cruciate ligament of the knee in a woman patient, due to wrong disposition of the points of fixation of the allotransplant. The operation was repeated with a good result.

The present analysis of experimental and clinical data therefore testifies to the fact that tendon allografts preserved in the FDMP solution can be successfully used in broad clinical practice in various plastic operations on tendons.

SUMMARY

Substantiation of transplantation of tendon allografts treated with a new solution showing both sterilizing and preservatory effects was provided in experiments on 84 dogs. The solution prepared on the basis of 0.1 % formaldehyde with the addition of dimethyl sulphoxide, monomycin and prednisolone (FDMP) shows a high antimicrobial activity, preserves the structure of the tendons and their elasticity. In their duration, the processes of reconstruction of allografts preserved in FDMP are very similar to autotransplants. Clinical application of preserved tendons on repairing defects in 418 patients proved the method to be highly effective.

Key words: transplantation; tendons; preservation; regeneration

RÉSUMÉ

Justification expérimentale de greffes allogènes du tissu tendineux

Plotnikova, V. A., Stachejev, I. A., Stin, V. P.

Dans une expérimentation sur 84 chiens on a vérifié la raison d'être des greffes allogènes tendineuses, préparées par une nouvelle solution produisant les effets stérilisateurs et conservateurs. La solution obtenue, à la base de 0,1 % d'aldéhyde formique, à l'addition de diméthylsulfoxyde, de monomycine et de prednisolone, (FDMP) montre une haute activité antimicrobienne, conserve la structure des tendons et leurs qualités d'élasticité. La durée des processus de transformation des greffes allogènes,

conservées par FDMP, est proche à celle des autogreffes. L'application clinique des tendons préparés par cette conservation, effectuée chez 418 patients, a confirmé une haute efficacité de la méthode.

ZUSAMMENFASSUNG

Experimentale Begründung einer Transplantation des allogenen Sehnengewebes

Plotnikova, V. A., Stachejev, I. A., Stin, V. P.

Bei einem Experiment mit 84 Hunden wurde die Möglichkeit einer Transplantation von Sehnen-Allotransplantaten bestätigt, diemit einer neuen Lösung bearbeitet wurden, die gleichzeitig auch sterilisierend und konservierend wirkt. Die auf Grund von 0,1 % Formaldehyd gewonnene Lösung unter Zusetzung von Dimethylsulphoxid, Monomycin, Prednisolon (FDMP) weist eine hohe antimikrobiale Aktivität auf, erhält die Struktur der Sehnen sowie ihre elastische Eigenschaften. Die Prozesse des Umbaus der Allotransplantate, die im FDMP konserviert sind, befinden sich zeitlich sehr nahe den Autotransplantaten. Die klinische Anwendung der konservierten Sehnen bei 418 Patienten hat die große Effektivität der Methode erwiesen.

RESUMEN

Motivación experimental de transplantates de tejido ligamentoso

Plotnikova, V. A., Stachejev, I. A., Stin, V. P.

En experimentos realizados en 84 peros fue confirmada la posibilidad de ejecutar transplantes de tendones alógenos, preparados con una nueva solución que actúa a la vez como esterilizante y conservante. La solución lograda en base a un 0,1 % de formaldehído, al que se le añade dimetilsulfóxido, monomicina, prednisolona (FDMP), acusa una alta actividad antimicrobial, manteniendo la estructura de los tendones y su propiedades elásticas. Los procesos de transformación de los transplantes alógenos conservados en FDMP, temporalmente son muy cercanos a los autotransplantes. La aplicación clínica de los tendones conservados en 418 pacientes confirmó la alta eficacia del metodo.

REFERENCES

1. **Beringer, Yu. V., Roskov, R. V.:** Application of liquid media for the preservaion of tendons. In: Preparation, preservation and sterilization of biological tissues (in Russian). Moscow, 33, 1970.

2. **Guliada, Yu. A.:** Plastic surgery of the ligamentous apparatus of the knee joint. In: Sterilization, preservation and transplantation of tissues (in Russian). Volgo-Nizhnevolzhskoye knizhnoye izdatel'stvo, 159, 1975.

3. **Demichev, N. P.:** Reconstructive-restorative operations on tendons and the tendinoligamentous apparatus (in Russian). Acta Chir. Plast., 21, 3 : 137, 1979.

4. **Pan'shin, A. G., Sokolova, L. I., Frinlyandskii, I. I., Blinova, G. I., Ivankin, D. E.:** Cytotoxic properties of weak formaldehyde solutions. Transplantation of biological tissues sterilized and preserved with formalin (in Russian). Leningrad, 26, 1980.

5. **Parfent'eva, V. F., Rozvadovskii, V. D., Dmitriyenko, V. I.:** Preservation of homologous bone transplants (in Russian). Kishinev, Kartya Molodovenyaske, 113, 1969.

6. **Plotnikova, V. A., Stakheyev, I. A., Pashkevich, M. Yu.:** Biomechanical characteristic of the regenerate on repairing a defect of the Achilles tendon. Medical

biomechanics. In: Abstracts of papers presented at the International conference "Achievements of biomechanics in medicine" (in Russian). Riga, vol. 1, 304, 1986.

7. **Savel'ev, V. I., Plotnikova, V. A., Ivankin, D. E., Kravtsov, V. A.:** A method of sterilization of biologcial transplants with simultaneous preservation. Author's report No. 1061783, USSR, MKI[3] A 011/02 — 33633802/28-13 (in Russian). Notified 25. 12. 81. Published 23. 12. 83. Byul. izobret., 47, 1983.

8. **Stakheyev, I. A., Plotnikova, V. A., Pashkevich, M. Yu.:** Biomechanical characteristic of tendinous tissue preserved in varying solutions of formalin. In: Abstracts of papers presented at the 3rd All-Union Conference on the problems of biomechanics (in Russian). Riga, vol. 1, 117, 1983.

Author's address:
V. A. Plotnikova,
Sen. Scient. Coworker, Sverdlovsk Branch of the All-Union Kurgan Scientific Centre
"Reconstructive Traumatology and Orthopedics",
Ministry of Health
Yekaterinoburg, Russia, Bankovskii per., 7

Toho University School of Medicine, Tokyo (Japan)
Department of Plastic and Reconstructive Surgery
Head Y. Maruyama M.D.
Department of Orthopedic Surgery
Director M. Motegi M.D.

THE ANTECUBITO-RADIAL FLAP FOR THE REPAIR OF FOREARM DEFECT

M. YOSHITAKE, Y. MARUYAMA, Y. OKAJIMA, M. MOTEGI

The radial forarm flap based on he radial artery, has been used in various reconstructions and results in good such as in facial, intraoral, penile, and hand (1, 2, 3, 4).

The antecubital fasciocutaneous flap based on the inferior cubital artery, is also the alternative in the repair in its arc of rotation, or as a free flap (5).

There have been no report that antecubital flap was carried to the forearm or hand defects based on the inferior cubito-radial vessels.

We present a case in which the antecubital forearm flap based on the radial artery had been transported to the forearm full thickness defect with good results.

PATIENT'S HISTORY

A 52-year-old man presented with an ulcer measuring 3.5×4.5 cm over the dorsum of his right forearm as a result of leakage of adriamycin given for malignant lymphoma (Fig. 1a). The scars surrounding the ulcer were excised down to healthy tissue, producing a 5.5×6.5 cm defect over the distal third of the forearm.

A anticubito-radial flap was designed in the lowermost part of the antecubital fossa over the course of the inferior cubital artery (Fig. 1b), which was the first perforator arising from the radial artery.

The incision was started on the lateral side of the flap and carried down through subcutaneous fat and deep fascia. The inferior cubital vessels and the radial vessels were identified lying deeply in the fascial septum separating the brachioradialis and the pronator teres and were included in the flap (Fig. 1c). The radial artery and venae comitantes were ligated at the level of the proximal side of the vessels which divided to the inferior cubital vessels. The flap was transported easily into the defect of the distal third of the forearm.

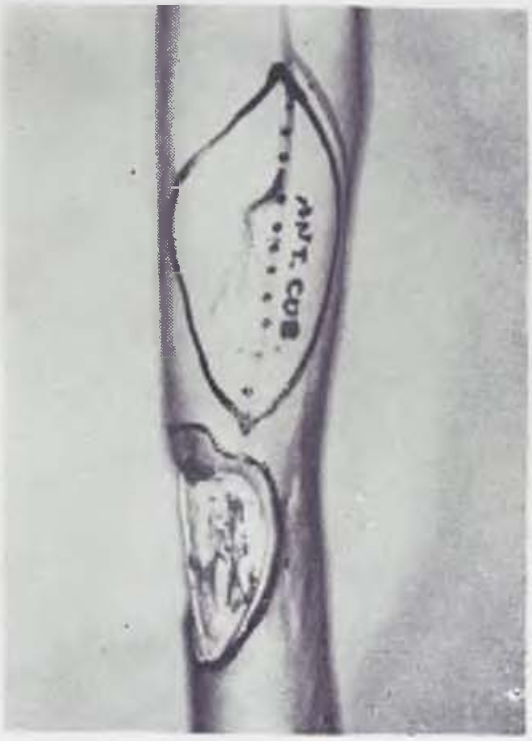

Fig. 1 (A) The appearance of an Adriamycin extravasasion ulcer 4 months after the injection over the forearm; (B) Design of the flap.

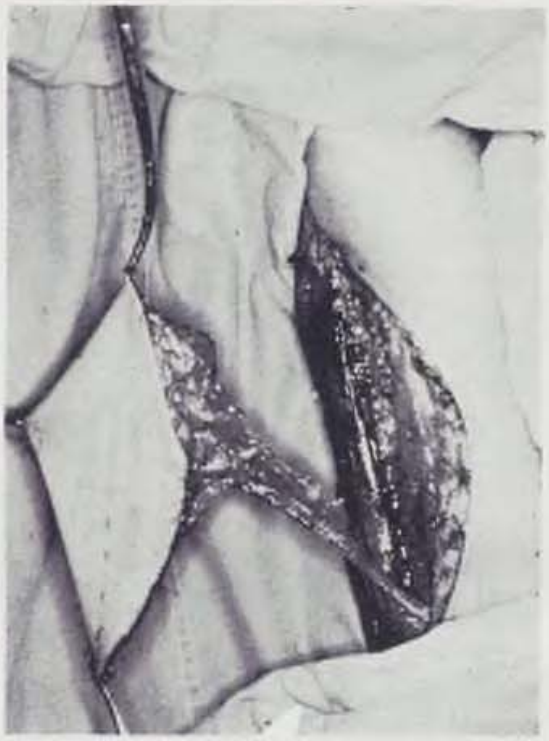

Fig. 1 (C) Flap raised and transposed to the forearm defect; (D) Result, superficial proximal necrosis occurred but favorable results shown.

The donor site was covered with split skin. Almost all the flap survived except the proximal marginal superficial necrosis, but healed well conservatively in next two weeks, and favorable results has been obtained (Fig. 1d).

DISCUSSION

The radial forearm flap has been proved a useful donor site for free flap, normograde or reverse pedicled one. The inferior cubital artery is the first cutaneous branch from the radial artery.

There are two situations in which this flap would not be feasible. Firstly in the absence of a significantly sized inferior cubital artery and secondly in the presence of such an artery when it arose from a radial recurrent which had its point of origin from the brachial artery (5, 6).

In our case preoperative angiography demonstrated the presence of the inferior cubital artery branching from radial artery. By the harvesting of the forearm flap no congestive changes occurred though it was performed as an antecubital reverse forearm flap. Consequently, it shoved a favorable result, except proximal small superficial necrosis. This was thought to be rathen proximally designed flap.

SUMMARY

The antecubito-radial flap based on the inferior cubital artery via radial artery had been transposed to the forearm defect. Through the flow of this flap is normal at cubital and that of radial vessels retrograde, good results have been obtained.

Advantage of this flap was discussed in relation to the radial forearm and the antecubital flap.

RÉSUMÉ

Greffe antécubitalo-radiale dans réparation de défaut de l'avant-bras

Yoshitake, M., Maruyama, Y., Okajima, Y., Motegi, M.

Un lobe antécubitalo-radial, basé sur l'artère cubitale inférieure via l'artère radiale, était transféré sur le défaut de l'avant-bras. Malgré que le flux sanguin aie été normal dans les artères cubitales, et inverse dans les artères radiales, de bons résultats furent obtenus. Les avantages de ce lobe étaient examinés en relation à la partie radiale de l'avant-bras et au lobe antécubital.

ZUSAMMENFASSUNG

Antekubital-radiale Transplantate zur Rekonstruktion eines Defekts des Vorderarms

Yoshitake, M., Maruyama, Y., Okajima, Y., Motegi, M.

Der antekubital-radiale Lappen, der auf der unteren Ellbogenarterie über der radialen Arterie liegt, wurde auf einen Defeckt des Vorderarms übertragen. Obwohl der Blutfluß in diesem Lappen normal durch die Ellbogengefässe strömte, dagegen in den

Radialgefässen umgekehrt, wurden gute Ergebnisse erzielt. Der Vorteil eines solchen Lappens wurde in Beziehung zum radialen Teil des Vorderarms und zum antekubitalen Lappen beurteilt.

REFERENCES

1. **Yang, Guofan et al.:** Forearm free skin flap transplantation. National Medical Journal of China, 61 : 139, 1981.
2. **Soutar, D. S. and McGregor, I. A.:** The radial forearm flap in intraoral reconstruction; the experience of 60 consecutive cases. Plast. reconstr. Surg. 78 : 1 1986.
3. **Chang, T. S. and Hwang, W. Y.:** Forearm flap in one stage reconstruction of the penis. Plast. reconstr. Surg. 74 : 251, 1984.
4. **Biemer, F. and Stock, W.:** Total thumb reconstruction using an osteocutaneous forearm flap. Br. J. Plast. Surg. 35 : 420, 1983.
5. **Lamberty, B. G. H. and Cormack, G. C.:** The antecubital fasciocutaneous flap. Br. J. Plast. Surg. 36, 428, 1983.
6. **Lamberty, B. G. H. and Cormack, G. C.:** The forearm angiotomes. Br. J. Plast. Surg. 35 : 4, 1982.

Michio Yoshitake, M.D.
Department of Plastic and Reconstructive Surgery,
Toho University Hospital,
6-11-1 Ohmorinisi Ohta-ku Tokyo 143 Japan

Medical Corps of the Hungarian Army

FUNCTIONAL AND AESTHETIC RESULTS OF TREATMENT OF THERMAL INJURY

J. NOVÁK, G. KOZMA, J. JÓSVAY

The results of treatment of thermal injury are usually indicated in terms of survival rate and/or the length of hospital stay. Social as well as individual interests however emphasize the importance of the functional results and aesthetic outcome of the treatment of thermal injury. These factors can lead to the necessity of changing the job and due to that, the way of life of the injured patient.

It is well known that burn trauma due to its peculiarities differs from other types of injuries. The patient cannot be considered cured after healing of skin lesion, for the underlying tissues are constantly changing for months after the injury. These considerations made us to introduce a rehabilitation system in our Burn Center providing a possibility for 5 -year follow -up patient after thermal injury. In this study we present the data of our patients followed-up for 5 years.

PATIENTS, METHODS

We performed a retrospective study of complete information available during a 5 year follow-up study of 1000 burned patients selected from more than 2000 injured in- and outpatients discharged from the Burn Center of the Central Military Hospital between Jan. 1, 1982 and Dec. 31, 1986. In this study we used the data of those burned patients who had their last record of a persisting or cured functional or aesthetical damage of the injured part of the body registered not earlier than 1 year after injury. By the time of the last body registered not earlier than 1 year after injury. By the time of the last working capability of the injured (of its possible changes and reasons). The study of the state of the internal organs was always performed personally by the authors. Thus we obtained precise information on the 48 % of the survived burned inpatients and on 43 % of the injured outpatients.

The data from the admission till the last control were processed on special collectors of data for the Data Bank of Thermal Injures. Representative data

Table 1. Distribution of patients according to age and activity

Age		Sex		Activity	
< 20	29	Men	718	brain	133
21—40	560	Women	282	manual	543
41—60	268			pension.	162
> 60	143			family memb.	60
				student	28
				other	74

Table 2. Distribution of the causes of burns

	Scald	Flash	Flame	Hot object	Expl.	Electr.	Other
Domestic	386	2	16	48	14	3	26
Industrial	103	16	96	62	13	7	83
Traffic	6	—	12	8	—	—	5
Other	2	—	2	—	—	—	—

Table 3. Superficial and dermal burns

		Superficial	518
Surgery:	255	deep dermal	313
		subdermal	169

Table 4. Rate of definitive impairment

	Head, neck	Upper extr.	Hand	Lower extr.	Trunc	Patients
Aesthetical	54	31	37	39	25	141
and/or functional	8	23	21	12	2	52
Number of patients	62	54	58	51	27	193
Patients with deep dermal and subdermal burns	115	117	93	231	243	482

for the needs of our study collected in 1000 burned patients are summarized in Table I, II, and III. Table IV presents the distribution of the remaining aesthetical defects meaning here not the place of the injury, but the alterations affecting the appearence of the patient both in the opinion of the patient and his doctor, but inducing no functional impairment. Table I also gives the data on the functional impairments according to the affected parts of the body. Table V gives the data on medical rehabilitation and impairment of working capability.

Table 5. 52 burned with functional impairment

Surgery	29	succes
Other methods	8	success
Be reserved	1	→ invalidity
Not returned	10	→ 2 patients with decreased working capability
Impossible to correct	4	→ invalidity

DISCUSSION

We cannot adequately compare the data of our patients with literary data, for the latter are not sufficient for standartization. Due to the fact that very few data compatible with ours are available in literature, we decided to publish the results of our study.

We studied the data of Juhin et al. (6) on the treatment of 615 patients with deep burns from 1962 to 1974. Contractures occurred in 40% of the patients if the skin necrosis had been treated conservatively. Surgical necrectomy decreased this ratio to 23.5 %. However, the authors stress that the limitations of motion decreased from 58 % to 23 % at discharge due to the complex functional therapy. Of 1000 injured we treated 482 patients with superficial and deep dermal burns. Functional impairment due to scars was observed in 52 cases (about 11 %). This ratio is lower than that of the burned patients representatively studied from 1970 to 1974 (28%) (7). The possible reason of this observation may be the difference of the severity of burns in the two groups of patients: in our previous investigation we studied patients only with deep dermal burns.

Huang et al. (5) conducted a retrospective study of 3235 patients with thermal trauma also affecting the joints (from 1964 to 1975). They evaluated the data of 625 patients. Their experience shows that in patients after treatment with fixation and/or elastic compression dressings worn for a long period, the need for multiple reconstructive surgical interventions arised only in 11.8 %, and for a single operation — in 14.5 % of the cases. Without this

method (219 injured) this ratio increased to 57.7 % and 35.2 % respectively. Only compression dressing which are worn over 6 months were considered to be effective. The ratio of 11.8 % mentioned in this study shows good coincidence with our results (11 %).

A more detailed report (1972), compared to the previous one and also dealing with joint damages has been presented by Dobbs and Curreri (2). According to their data 3312 superficial and deep thermal injuries affecting joints (912 case of hand burns) resulted in the limitation of motion and functional impairment in 523 and 295 (9 %) cases. This ratio corresponds to the data of Huang et al. (5) and to our results. Griskewich et al. (4) found 81 elbow joint contractures in 71 burned patients in 1984—1986. This ratio is markedly higher than that observed by us (69 elbow joints — 9 contractures); the reason of this difference has remained unrevealed.

It is important to mention that Huang et al. (5) found 100 % ratio of occurrence of the contractures in case of deep burns of axilla. Our data show significantly lower ratio: 48 axillary burns — 14 contractures. The source of the difference might be in the way of calculation of this ratio: the authors considered 10—15 % limitations of motion as contracture, while in our study patients with function impairment had limitations of motion restricting their everyday life and working capability. However the studies indicate that there is no uniform way of evaluation of these parameters of healing, furthermore every author (including our group) interprets his results in a different way. The other possible source of differences is the necessity of multiple operations in extensive burns, so the exact time of skin transplatation for the joint studied is questionable.

Evaluation of our already mentioned data (7) from 1970 to 1974 indicate that the working capability decreased in 19 % of the cases. 4 % of these patients have become irreversibly disabled. These data stand only for our patients.

Of the patiens with thermal injury in- and outpatiens occur at a ratio of 1 : 22. The common study of these two groups provides information on the morbidity.

The average BBS of our in- and outpatients = 5.4 % (quadratic means are not important in this comparative study). These values may possibly explain the low ratio of the disabled (0.7 %), compared to our previous results and literary data (we believe that the increase of the surgically treated cases may also play some part in the decrease of this ratio). Juhin et al. (6) reports 18.5 % of disabled among 615 burned patients and Engrav et al. (3) found 6.2 % ratio in a population of 325 burned patients (mean BBS = 11.6 %). Of 158 premorbid actively working patients 4 remained irreversibly disabled and 16 had to change their job.

These data indicate that the ratio of the disabled varies between 1 and 19 % depending on the groups of the patients.

A more detailed mathematical analysis of our and literary data could possibly give more information, however as we have already mentioned, the lack

of basic data makes standartization impossible indicating the extreme importtance of creating the international standards.

Considering the so-called aesthetic sequelae of burns, Deitch et al. (1) stressed the importance of the problem of scar formation in the patients who survived a thermal injury. The authors concluded that the main factor inducing complication is the time interval elapsed from the injury till the healing of the burn wound. If this period lasts for 14—21 days, then one-third of the patients had hypertrophic scars; the longer period of healing leads to scarrification in further 18% of the patients (more than a half of the patients were children and 73 belonged to the Negro race). As we have already mentioned in the Methods we recorded the aesthetic sequelae of burns only if according to the physician it disturbed the patient but did not induce functional impairment (that is a new problem of evaluation of the efficacy of treatment). Considering the above mentioned, aesthetic sequelae of burns have been recorded in 141 cases (29.3 %) with dermal and deep dermal burns. However it should be mentioned that in these recorded cases there were many operated patients. Relatively high incidence of the operated patients can be due to the imperfect technique of surgical treatment or to the inevitable shrinkage of the transplantate and the inner layers of the tissues. The most important reason in our opinion is the spontaneous healing of the tissues which occurs in two-thirds of our patients following dermal burns. The aesthetic sequelae of burn injury suggest the introduction of more operative methods of treatment.

According to the definition of permanent complications, the patients mainly complain (186 patients, 91 areas of the body) about the irreversible aesthetic sequeale of burns devoloped on the parts of their body not covered by the garments.

Aesthetic results of the primary excisions performed after dermal injury of the face are insufficient. We should like to stress once more the beneficial effect of elastic dressings worn for a long time also mentioned by Huang et al. (5).

Finally we should like to emphasize that our results of treatment of the burned patients are presented not for comparison of other authors' data. Reviewing the literature we found very few data on this problem and most of them are not comparable with ours. Our goal was to indicate the most important circumstances of treatment and the extreme need for rehabilitation of burned patients.

SUMMARY

The authors report the results of treatment and a one year follow-up study of 1000 burned patients (1982—1986). Of 482 patients with superficial and deep dermal burns 246 patients had been operated (135 of 168 patients with deep burns). Impairment of function has been observed in 52 and complete disability in 7 cases. The authors suggest planned collecting of data on the remaining complications following thermal injury.

RÉSUMÉ

Résultats fonctionnels et esthétiques du traitement des brûlures

Novák, J., Kozma, G., Jósvay, J.

Les auteurs font un rapport sur le traitement et les résultats de l'observation effectuée dans la période de 1982—1986, dont l'objet représentait 1000 patients brûlés. Du total 482 brûlés, avec les brûlures superficielles et profondes, 246 malades étaient opérés (dont 135 patients avec de profondes brûlures). L'altération fonctionnelle fut observée 52 fois, l'invalidité totale 2 fois. Les auteurs proposent une collecte de données organisée, se concernant sur les complications ultérieures après les brûlures.

ZUSAMMENFASSUNG

Funktions- und ästhetische Ergebnisse einer Behandlung von Verbrennungen

Novák, J., Kozma, G., Jósvay, J.

Die Autoren berichten über die Behandlung und die Ergebnisse von Beobachtungen im Verlauf der Jahre 1982—1986 bei 1000 Patienten mit Verbrennungen. Von 482 verbrannten Patienten mit oberflächlichen und tiefgehenden Hautverbrennungen wurden 246 Patienten operiert (davon 135 Patienten mit tiefgehenden Verbrennungen). Eine Verschlimmerung der Funktion wurde 52-mal beobachtet und eine vollständige Dysfunktion zweimal. Die Autoren schlagen das planmässige Sammeln von Angaben über Komplikationen vor, die nach Verbrennungen zurückbleiben.

REFERENCES

1. **Deitch, E. A., Wheelahan, T. M., Rose, M. P., Clothier, J., Cotter, J.:** Hypertrophic burn scars: analysis of variables. J. Trauma **23** : 895, 1983.

2. **Dobbs, E. R., Curreri, P. W.:** Burns: analysis of results of physical therapy in 681 patients. J. Trauma **12** : 242, 1972.

3. **Engrav, L. H., Covey, M. H., Dutcher, K. D., Heimbach, D. H., Walkinshaw, M. D., Marvin, J. A.:** Impairment, time out of school and time off from work after burns. Plast. reconstr. Surg. **79** : 927, 1987.

4. **Grishkewich, W. M., Moroz, W. Y., Mjatiew, H. B., Alexejew, A. A., Britun, Y. A.:** Novyj podhod k lechenijam posleozogovych kontraktur. Ortop. Travmat. Protez. 1 : 20, 1988.

5. **Huang, F. T., Blackwell, S. J., Lewis, S. R.:** Ten years experience in managing patients with burn contractures of axilla, elbow, wrist and knee joints. Plast. reconstr. Surg. **61** : 70, 1978.

6. **Juchin, L. S., Ognienko, W. S., Pewzin, I. E.:** Rezultaty lechenia bolnych, perenesshich glubokie ozogi. Westn. Chir. 9 : 78, 1975.

7. **Novák, J., Merkel, D., Medgyés É., Nádai, E., Medzihdasky, L., Gyeney, M.:** Kórház-poliklinikai egység keretében működő első hazai égés-sebészeti gondozószakrendelés kétéves tapasztalatai és fejlesztési terve. Orv. Hetilap **121** : 75, 1980.

8. **Novák, J.:** A bőr égési sérülésének pathomechanizmusa, morbiditása és kórj óslata. Doktori értekezés, Budapest, 1980.

9. **Novák, J., Gyeney, M., Merkel, D., Galamb, G.:** Das Informationssystem der thermischen Verletzungen. Zbl. Chir. **109** : 617, 1984.

János NOVÁK, Budapest 1027, Csalogány-u. 41.
Hungary

Silesian Medical Academy, Katowice (Poland)
Department of Children's Laryngology
Head H. Kawalski, M. D.

CONTROVERSY CONCERNING THE DEADLINE FOR SURGICAL INTERVENTIONS OF A NOSE IN CHILDREN

J. SONDEJ, H. KAWALSKI, E. CIERPJOŁ-TRACZ

There is an opinion that surgical procedures in the middle part of the face should not be carried out before finishing of psychomotoric development of a child.

Sixty years ago some arbitrary limit borderline age was established preventing surgeons from operating on the nose of a childpatient. This borderline was 16 years of age for girls and 18 years of age for boys respectively. This age limit was introduced by Joseph, and then observed by other facial surgeons Aufricht and Safian being his faithful followers.

Peck said that one day he had asked dr. Aufricht why he had insisted on observing strictly that age limit in his patients for qualifying them for an operation but had not taken into account other important physiological and anatomical factors. Dr. Aufricht's reply was simple enough: "Joseph said that".

And so until now, there is a strict division among the surgeons into those few ones who operate on a child's nose earlier than the deadline and the majority of surgeons who wait until the child reaches this magic limit borderline age.

We are interested in the negative aspect of this problem: the growth arrest retarding of growing of a nose along with the middle part of the jaw under the influence of various mechanical injuries and limitation of patency of nasal dactules. We have been trying to explain this problem on the basis of numerous clinical observations, cephalometric examinations and some remote post-operational results in children and later in adults.

Two factors were checked in the tests carried out on animals which theoretically speaking have some influence upon the growth of a nose and the preceeding part of the jaw i. e. on incidence of traumas and secondary obturation of nasal dactules (1, 11, 16).

The experiments were made on guinea pigs, rabbits, dogs, baboons and chimpanzees. The retrospective test results carried out on the latter seem to be the most valuable for man because of close philogenetic likeness [17].

Siegle [16] was extracting submucosally strips of cartilage in the nasal septum in 2 and 4 month old chimpanzees, not finding considerable difference in the growth of a nose of chimpanzees in both contral and experimental groups. Such observations were carried out during 3 years and afterwards the conclusion were drawn that the centre governing the growth of a nose is situated in a bone septum and that the incidence of traumas did not influence or disturb the growth of a nose or a jaw-bone.

The experiments carried out on rats by the Guitrancourts were even more interesting [16]. In one group they were incising cartilaginous septum of a nose, but did not find any disturbances in growth. In another group they cut out subperichondrially some strips of cartilaginous septum of a nose. And here they found cartilage renewal progressing from the perichondrial-mucosal stratum and also did not find any irregularities of a nose growth. However, in the third experimental group after complete surgical removal of a cartilaginous septum along with perichondrium and mucosa visible and possible to assess were some considerable disturbances.

Pirsig [11] stated during XIX Meeting of German Association of Plastic and Reconstructive Surgery in Wuerzburg in 1981 that until today there had not been found or proved where was the centre or centres of man's nose growth. It is supposed to be found in bones, in bone sutures, in syndesmosae, on the upper surface of cartilage as well as in the marrow itself and that these places show different growth activity in different age and in particular, areas of the body, a nasal septum consists of 11 parts: cartilages and bones and each of them has its own growth dynamics. On the upper surface of a bone, especially in its middle part of palate bone of a jaw, cribriform plate and nasal bones growing process is taking place earlier and is made through stratification and partial resorption. The wings of the middle part of the jaw [premaxilla] show active growth only after the 6 years of age of a child to be finally joined together to create a vomer nasal spine after the age of 15 of a patient.

On the basis of observations on children with inborn facial defects development of the middle part of a face takes place without a nasal septum.

In 1987 Buck and Brown [3] published results of their experiment on a nose growth in patients aged between 6—18 years old who used to live in various latitudes but who were not operated on. Cephalometric data were analysed and compared with analogical measurements done for the age between 21—30 years. The so called borderline of man's maturity was determined on the basis of these experiments and so for girls it is at the age of 12 years of life in 84 per cent of cases while it is 15 years of life for boys in 87 per cent of them respectively.

Pellnitz [15] calculated statistically some particular phases of development of a nose from the length of 26,2 mm at child birth till 50,4 mm in adult-

hood on the basis of some experiments. According to him this development takes place in the following phases:

between the age 3— 4 years of child's life — growth is 7,7 mm
between the age 7—10 years of child's life — growth is 3,7 mm
between the age 10—15 years of child's life — growth is 4,7 mm
between the age 15—20 years of child's life — growth is 6,4 mm

Mustoe et al [8] from Boston children's clinical hospital reported that in the years 1966—1980, because of breaking of the nose and jaw they treated preventfully as well as operated on 78 children. And 5—10 years later they carried out the retrospective survey only to find that there were no considerable disturbances of either nasal or jaw growth and development in their patients who were adults then.

Ortiz-Monasterio and Olmedo were the first to publish in "Reconstructive and Plastic Surgery" in 1981 the results of corrective operations on a bone nose as well as on a nasal septum in children between the age of 5—8 years. After 15 years since the time of their operation this group of 44 children underwent anthropometric examinations and also some contrastive photographs were taken. Both the results of corrective operations on the nose and repositions of the nasal septum were positive — growth of a nose was not changed at all [9].

Tulasne and Tessier operated on children at the age of 8—9 because of their hypertelorism. They said on the basis of remote postoperational results, that no disturbances were found in the arrangement of bones in a nose or in the alvolar processes of the jaw. They only noticed slight delay in development of the middle jaw area [7].

Nose growth is inseparably connected with the facial skeleton development and they form the whole developmental complex. Under the influence of some hormone and genetic factors through a nasal septum takes place its anterior—posterior growth development. This development is a resultant of pressure of a larger sphenoid bone from the sides-wings as well as pulling of ligament attached to a pear-shaped opening holl and an orbicular muscle of the mouth [17].

Indications for operations on children, very much like on adults are purely aesthetic and functional. In such indications it is necessary to take into account psychic immaturity of a child manifesting itself in emotional unbalance and regression. Sometimes the very staying in a hospital may be very traumatic for children along with the separation from their family not to mention regular fear of the awaiting operation. After hospitalization experience there is the so called psychological scar left on the children's psyche. Staying in a hospital may cause the so called stigmatization in some children which may become the cause of difficulties in their psychic development in the future [5, 6, 7, 13].

Difficulties in breathing because of deviation of a nasal septum in children is a classical indicator for correctional operations. Some rhinologists indi-

cate the necessity of operation by means of minute rhynoscopy or rhynamanometry in partial obstruction of nasal dactules (2, 12).

However, the majority of surgeons underline the necessity to correct the deviation of a nasal septum, which is responsible for proper development and shape of a nose (7, 11, 14, 15, 18, 19, 20).

An operating surgeon should observe strictly three of the principles:

1. Most sensible judgement in diagnosis indications for the operation.
2. Sensibility concerning the time (age of a child) of surgical intervention.
3. Sensibility or better to say obligation to apply physiological operational techniques.

Post-traumatic deformity of a nose is well compensated by small children (4—5 years old). No disorders or difficulties in nose functioning are found. But sometimes parents make a demand for carrying out corrective procedure of a nose. It is necessary to persuade them that because of meaning well for their child such operational procedure should be put off in time (4, 10, 15).

A bigger child (about 15 years of age) is in the special age when its interest in appearance and its own attractiveness is awakened. It is especially true about boys in whom even minimum deformities in appearance are being exaggerated. Therefore one must be very patient and use some tricks to explain to them that operating on a nose is not needed.

One principle should always be remembered before deciding on making operational procedure — "It is necessary to save as much of the child's natural organs as possible".

Hagege (7) writes that when operating on children's nose one should, most of all, save the junction of a cartilaginous septum with the anterior nasal spine as being especially sensitive for injuries. Resection of a dorsum bone of the nose should be done very carefully since a bone scar inhibits development of the nose in length. For carrying out such an operational procedure, it is necessary to have the typical operation set of instruments.

There is a term of atraumatic surgery, anatomic operating, physiological one. It is just the children who should be operated on atraumatically and physiologically since during the operational procedure one must always remember the factors of growth of the child's nose. Walter and Hagege (7, 20) presented the operational technique respecting the requirements of both jaws and a nose growth in children. It differs from operational technique applied in adult patients in some essential features. First of all it is necessary to protect the growth zone, especially in the area of spina nasalis anterior. Subcartilaginous detachment of a mucosa from the nasal septum is of utmost importance. The mucosa cannot be broken or damaged while being splitted into layers. It is always necessary to make reposition of a cartilaginous septum but not cutting out of the strips in a cartilaginous septum; there cannot be any defects in cartilage of a cartilaginous septum — it is necessary to com-

plete the loss after resection of the septum with the pieces of the patient's own cartilage e. g. "after having done" the wing cartilages. Side subperiosteum osteotomy without detachment of the skin by Walter's chisel of 2 mm width is carried out. A piece of a cartilage is placed near the nasal spine to stir and activate the centre of growth.

We used this technique of operation on 32 children aged 8—16 in the years 1985—1990. The majority of cases qualified for operation was the consequence of the past disease of face injuries and breaking of the nasal bones. Some of these groups of children patients were operated on a cartilaginous septum of a nose by middle and side osteotomy.

Finally a certain group of treatment on older children was carried out because of aesthetic reasons. These corrective procedures were done on both girls and boys (between 13—16 years of age). The postoperational period of observations extended from 0,5 year until 5 years. We did not find a single case of inhibition in growth of a nose among them. It is clear from our own observations that procedures sensibly and carefully done, when all the conditions mentioned above were observed, does not mean any danger of impaired growth of a nose.

SUMMARY

The authors try to explain when the surgeons can operate the nose of a child-patient. Sixty years ago the limit borderline age was established. This borderline was 16 years for girls and 18 years for boys. Some plastic surgeons published the results of corrective operations in children between the age 5—16 years, because of breaking of the nasal bones, past diseases and inborn facial defects. No disturbances have been found of cartilages and bones of nose and the jaw area.

RÉSUMÉ

Oppinions différentes sur les limites des interventions chirurgicales sur le nez des adolescents

Sondej, J., Kawalski, H., Cierpoł-Tracz, E.

Les auteurs essayant de déterminer l'âge optimal pour l'intervention chirurgicale sur le nez des patients adolescents. Il y a 16 ans, cette limite a été indiquée et elle représente l'âge de 16 ans pour les filles et 18 ans pour les garçons. Quelques plasticiens ont publié leurs résultats des interventions correctives, effectuées sur les sujets âgés de 5 à 16 ans. Il s'agissait des corrections des fractures des os nasaux, des séquelles de maladies différentes et des défauts faciaux congénitaux. Aucuns troubles cartilagineux et osseux de la région nasale ou maxillaire n'étaient pas constatés.

ZUSAMMENFASSUNG

Meinungsverschiedenheiten über die Grenzen chirurgischer Eingriffe an der Nase bei Jugendlichen

Sondej, J., Kawalski, H., Cierpoł-Tracz, E.

Die Autoren versuchen festzulegen, wann ein Chirurg die Nasen bei jugendlichen Patienten operieren darf. Diese Grenze wurde vor 16 Jahren bestimmt. Sie beträgt für Mädchen 16 Jahre und für Knaben 18 Jahre. Einige plastische Chirurgen veröffentlichten Ergebnisse korrektiver Operationen bei Kindern im Alter von 5 bis 16 Jahren, die auf Brüche von Nasenknochen folgten oder nach durchgemachten Krankheiten oder angeborenen Gesichtsdefekten. Sie haben keine Knorpel- und Knochenstörungen in der Region der Nase oder des Kiefers gefunden.

REFERENCES

1. **Bernstein, L.:** Early submucous resection of nasal septal cartilage: A pilot study in camine pups. Arch. Otolaryngol. Head Neck Surg. 97 : 273, 1973.

2. **Brain, D. J., Rock, W. P.:** The influence of nasal trauma during childhood on growth of the facial skeleton. J. Laryngol. Otol. 97 : 917, 1983.

3. **Buck, D., Brown, C.:** A longitudinal study of nose growth from ages 6 to 18. Ann. Plast. Surg. 18 : 310, 1987.

4. **Flemming, I.:** Rhinoplasty in children. Aesth. Plast. Surg. 5 : 145, 1981.

5. **Fodor, P. B.:** Aesthetic rhinoplasty in early adolescence. Aesth. Plast. Surg. 12 : 207, 1988.

6. **Gorney, M.:** Rehabilitation for the post-cleft nasolabial stigma. Clin. Plast. Surg. 1, 15 : 73, 1988.

7. **Hagege, J. C.:** La rhinoplastie avant et après ... dix-huit et quarante ans. Ann. Chir. Plast. Esthet. 34, 5 : 443, 1989.

8. **Mustoe, T. A., Kaban, L. B., Mulliken, J. B.:** Nasal fractures in children. European J. Plast. Surg. 10 : 135, 1987.

9. **Ortiz-Monasterio, F., Olmedo, A.:** Corrective rhinoplasty before puberty: a long-term follow-up. Plast. reconstr. Surg. 68, 3 : 381, 1981.

10. **Petterson, G.:** Deformities and defects of the nose in children. Acta Chir. Scand. 107 : 539, 1954.

11. **Pirsig, W.:** Die Wachtumzonen der Nase: heutiger Stand des klinischen und experimentalen Wissens. 19. Jahrestagung der Deutschen Gesellschaft für Plastische und Wiederherstellungschirurgie, 29 bis 31 Oktober 1981, Würzburg, 15—23.

12. **Ramadan, M. F.:** Restricted nasal respiration influence on facial growth. Int. J. Pediatr. Otorhinolaryngol. 1 : 249, 1979.

13. **Rees, Th., Baker, D. B., Tabbal, N.:** Rhinoplasty Problems and Controversies. The C. V. Mosby Co., St. Louis. Washington. Toronto, 1988.

14. **Schultz-Coulon, H. J.:** Die Korrektur ausgeprägter Deformitäten des ventrokaudalen Septumabschnitts beim Kind. HNO 31 : 6, 1983.

15. **Senechal, G., Senechal, B.:** Pour ou contre la rhinoplastie chez l'enfant? Ann. Chir. Plast. Esthet. 34, 5 : 439, 1989.

16. **Siegel, M. I., Sadler, D.:** Nasal septum resection and craniofacial growth in a chimpansee animal model: implications for cleft palate surgery. Plast. reconstr. Surg. 68, 6 : 849, 1981.

17. **Snell, R.:** Clinical Embryology for Medical Students. Little, Brown and Co., Boston. Toronto, 1983.

18. **Verwoerd, C. D. A., Urbanus, N. A. M., Nijdam, D. C.:** The effects of septal surgery on the growth of nose and maxilla. Rhinology, 17 : 53, 1979.

19. **Vetter, U., Heit, W., Helbing, G., Heinze, E., Pirsig, W.:** Growth of human septall cartilage. Laryngoscope, 94 : 1226, 1984.

20. **Walter, G.:** Die Septo-Rhinoplastik im Kindesalter. 19. Jahrestagung der Deutschen Gesellschaft für Plastische und Wiederstellungschirurgie, 29 bis 31 Oktober 1981, Würzburg, 15—23.

Dr. H. Kawalski
Silesian Medical Academy, Katowice
Department of Children's Laryngology
41-500 Chorzów, ul. Truchana 7
Poland

Department of Plastic Surgery
Masarykova nemocnice, Ústí nad Labem
Head: MUDr. Jan Rus

REPAIR OF A VAGINAL DEFECT WITH A MUSCULOCUTANEOUS FLAP

B. ČERNÁ, J. RUS

The development in the field of Plastic and Reconstructive Surgery accomplished in recent years provided numerous new approaches for the repair of defects with pedicled flaps. Perineal defects can be covered with musculocutaneous or fasciocutaneous flaps from the thigh, the gluteal region, or by

Fig. 1. Infected chronic vaginal defect.

distal pedicled rectus abdominis muscle flap. The choice of rotated flaps is limited to the use of musculocutaneous flaps from the m. gracilis, or from the tensor fasciae latae and of the fasciocutaneous flap from the thigh.

Fig. 2. Mobilized musculocutaneous flap from the m. gracilis before the dissection of the insertion of the tendon.

Fig. 3. Mobilized musculocutaneous flap from the m. gracilis.

The availability of these surgical procedures provides the possibility of a surgical repair of complicated and unfavourably situated defects in one stage operations, even at surgical departments where free flap transfers re-

Fig. 4. Mobilized musculocutaneous flap prior to transposition.

Fig. 5. The adapted flap at the site of the defect.

quiring vascular anastomosis under an operation microscope, are not performed routinely.

CASE REPORT

A female patient aged 36 years with paraplegia of 12 years duration was admitted to our department because of an infection in a defect on the right side of the vaginal introitus persisting for six months. The lesion was oval-shaped, 5 × 4 cm in size and about 3 cm in depth. The defect was situated at the level of the urethra and it extended below the denuded symphysis. Its bottom formed the ramus of the pubic bone. The tissues surounding the defect were covered with chronic inflammatory changes. A communication with neighbouring cavitary organs was not demonstrated. After due consideration of the localization and character of the vaginal defect it was decided to use for its repair a rotated musculocutaneous flap from the m. gracilis. After the excision of the lesion, with a sufficiently wide margin of normal tissue, and the dissection of skeletal lamellae at the bottom of the defect, followed a mobilization of a musculocutaneous flap with a skin island of adequate size and at a convenient distance. The axis of the skin island formed the m. gracilis (Fig. 2). The flap was stretched freely via the mobilized subcutaneous tissue of the proximal third of the thigh and of the perineum and was implanted into the site of the defect (Fig. 4).

Fig. 6. The local condition three months after surgery.

During a physiologic perfusion of the flap the postoperative course proceeded without any complications (Fig. 5).

The patient was discharged from the hospital into home care and even after a prolonged period of time showed no signs of recurrent infection. The tissue of the flap proved satisfactory, both in qualitative and in quantitative view (Fig. 6).

DISCUSSION

In our patient a proper indication of the procedure described above yielded a satisfactory result in the repair of her vaginal defect. The indispensable excision of the lesion and the filling of the defect with muscular tissue, which was perfused during the postoperative period by systemic administration of antibiotics, resulted in the control of infection which persisted preoperatively for a long period of time.

SUMMARY

The authors present a case report dealing with a successful treatment of an infected chronic defect of vaginal region. The surgical treatment consisted in the use of a transposition of a pedicled gracilis musculocutaneous flap. The described procedure could prove useful at departments where transpositions of free flaps are not performed routinely.

Key words: Musculocutaneous flap in the vagina.

RÉSUMÉ

Recouvrement de défaut vaginal par lobe musculocutané

Černá, J., Rus, J.

Les auteurs présentent un cas du recouvrement réussi d'un défaut chronique infecté de la région vaginale par un lobe musculocutané transposé de m. gracilis.

Ce procédé peut être considéré comme très avantageux, si l'équipe chirurgicale ne pratique pas de transferts des lobes libres.

ZUSAMMENFASSUNG

Die Deckung eines Vaginaldefekts durch einem Muskelkutanlappen

Černá, J., Rus, J.

Die Autoren legen die Beschreibung eines Falls der erfolgreichen Deckung eines infizierten chronischen Defekts der Vaginalregion durch einen transportierten Muskulkutanlappen m. gracilis vor. Falls die betreffende Arbeitsstätte die Übertragung freier Lappen nicht vornimmt, kann man einen solchen Vorgang als sehr vorteilhaft empfehlen.

REFERENCES

1. **Stephen Mathes, Foad Nahai:** Clinical Applications for Muscle and Musculocutaneous Flaps. St. Louis, Mosby, 1982.

2. **Herman T. Smet:** Tissue Transfers in Reconstructive Surgery, Raven Press, New York, 1989.

3. **Wiliam W. Shaw, David A. Hidalgo:** Microsurgery in trauma. Future Publ. Co., New York, 1987.

B. Černá, M. D.
Oddělení plastické chirurgie
Masarykova nemocnice
400 01 Ústí nad Labem
Czechoslovakia

Department of Plastic Surgery, Brno, Czechoslovakia

RECONSTRUCTION OF THE PENIS IN TRANSSEXUAL PATIENTS

J. VESELÝ, L. BAŘINKA, P. SANTI. P. BERRINO, M. MUGGIANU

Transsexual patients seeking change of female into male sex undergo a number of operative procedures performed in several stages.

The whole operation includes breast ablation, hysterectomy and ovarectomy, reconstruction of the penis and the scrotum. In this paper, we would like to review the approaches available in reconstruction of the penis.

Of the classic methods for phallic reconstruction, attention should be given to Gillies' procedure using a long-pedicle flap in the hypogastrium (Figs. 1—5). A two-pedicle flap covers a simultaneously formed urethra by two skin flaps sutured on a catheter. In the next stage, the flap's proximal pedicle is separated and transferred to the site of the root of the new penis with urethral suture. A third stage involves the separation of the flap's distal pedicle and, in a fourth stage, a cartilaginous graft to be fixed to the symphysis is implanted into the new penis. A similar multi-stage pattern is employed in reconstruction of the penis using cylindrical groin or mid-thigh flap (Bařinka, Mukherjee) (Figs. 6—7). The flap is placed over the patient's clitoris, whose glans is retained constituting an important erotogenous zone.

The more recent methods are one-stage procedures based on either the transfer of a m. rectus abdominis flap, or on microsurgical reconstruction using a fasciocutaneous flap.

The microsurgical reconstruction, as proposed by Chang and Meyer, is an ingenious procedure based on the formation of the urethra and the body of the penis using the rolled Chinese forearm flap. In this method, arterial anastomoses are established between the radial artery and the deep inferior epigastric artery, or the lateral femoral circumflex artery. Sensitive innervation of the penis is provided by anastomoses of cutaneous forearm nerves with the pudental nerve.

The approach employing m. rectus abdominis has two modifications, Santi's vertical myocutaneous flap on a vascular pedicle of the deep inferior epigastric artery, and Lemperle's muscular flap covered by a skin graft.

The myocutaneous flap is bulky and gives rise to a big penis; to reduce its size, the flap's dorsal segment was likewise covered by a skin graft sutured to the exposed muscle. The muscle making up the corpora of the penis gives

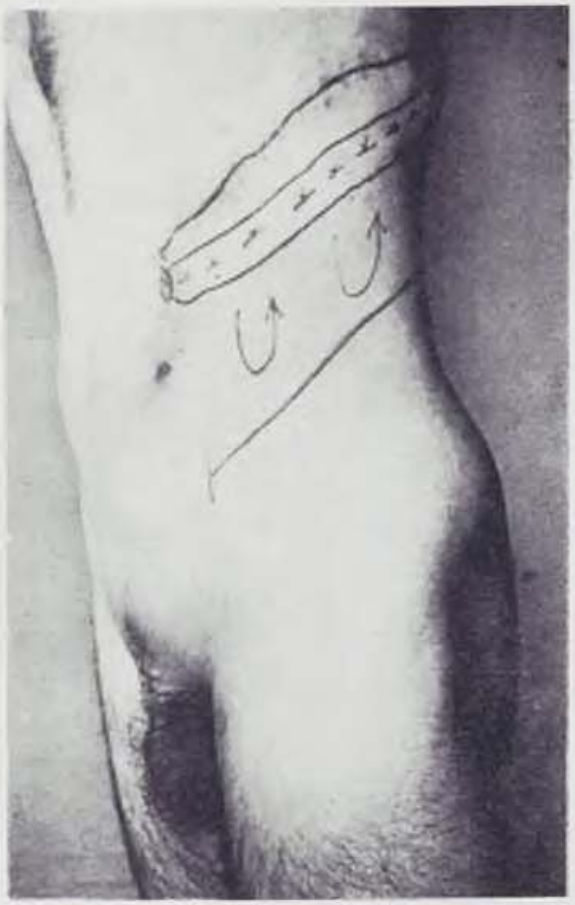

1. Schematic representation of Gillies' reconstruction of a traumatically amputated penis as performed by Prof. Barinka

2. Formation of the urethra

3. Urethra with catheter inside wrapped in a two-pedicle flap.

4. A cartilaginous graft from the rib was implanted following transplantation

the latter a natural consistency, and the urethra is formed by a skin graft sutured into the muscle on a catheter. Should the surgeon prefer this modality, he can use m. rectus abdominis covered by a sensitive Chinese forearm flap to form the corpora of the penis as an advantageous one-stage method for reconstruction.

5. Completed reconstruction

CASE REPORT

A 28-year-old transsexual patient with a female habitus, big developed breasts, normally developed external and internal female genitals, felt himself, ever since childhood, a boy and, later, a man. The male pattern of bodily and facial hair growth as well as voice were influenced by hormones. The patient was admitted for surgical treatment at the Department of Plastic Surgery of the Instituto Nazionale per la Riserca sul Cancro in Genoa in the spring of 1989 (Fig. 8).

Stage 1 included breast ablation with linear suture of the skin and transplantation of the areola with nipples. After ablation, a skin graft for urethral reconstruction was obtained from the breast, and another one to cover the defect on the left forearm following flap removal. The medial two thirds of m. rectus abdominis (12 cm long) with a vascular pedicle of the deep inferior

6. Tubulized flap formed on the inner side of the transsexual patient's thigh

7. Penile erection is imitated by a telescopic stent inserted into the cavity created in the penile corpus.

epigastric vessel were isolated from a suprapubic horizontal incision. Next, the muscle was passed through a subcutaneous tunnel into the pubic region and sutured around a catheter (20 F) with the skin graft forming the urethra (Fig. 9). A 16 × 12 cm fasciocutaneous flap with a vascular pedicle of the radial vessel, cephalic vein and both cutaneous nerves was isolated on the left forearm (Fig. 10). The flap was sutured around the penis made up of the muscle. Using a venous graft, the radial artery was sutured to a branch of

8. Schematic representation of phallic reconstruction using a combination of a m. rectus flap and a Chinese flap with one-stage breast ablation.

the lateral circumflex artery of the thigh. Concomitant veins of either artery were anastomosed end-to-end. As the next step, the flap's cephalic vein was anastomosed end-to-side to the large saphenous vein in the right groin. The flap's sensitive nerves were sutured with the right ilioinguinal and the left internal pudendal nerves. The skin defect on the left forearm following flap removal was covered by a full-thickness skin graft removed from the mastectomized breast. Healing was free of complications (Figs. 11—12).

9. Body of the penis made up to a muscle wrapping up the urethra sutured to a catheter

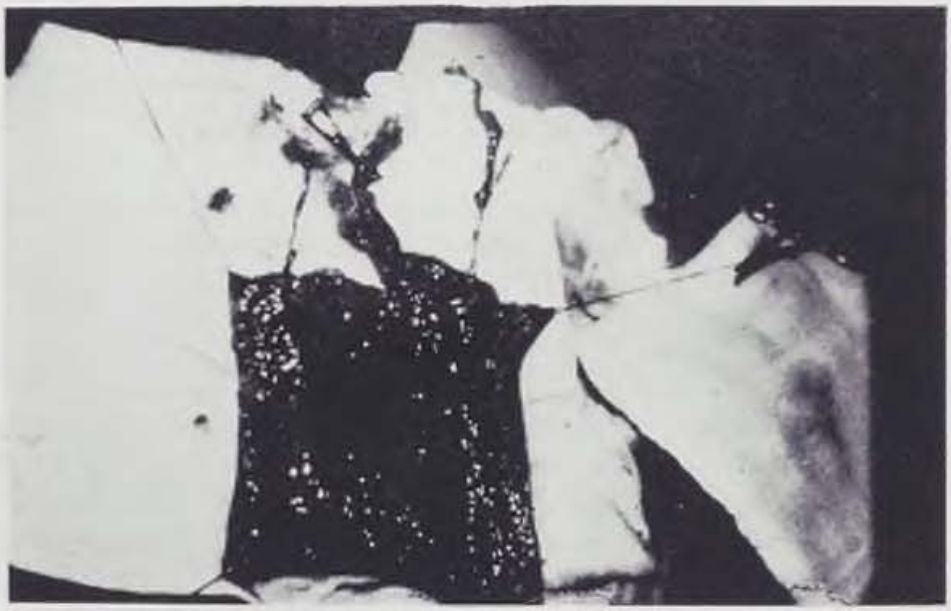

10. Isolated forearm flap with vascular and nervous pedicles

Three months later, the patient had abdominoperineal colpohysterectomy with ovarectomy. Furthermore, using vaginal mucosa covering the defect between both orifices, urethral reconstruction was undertaken by anastomosing urethral meatus with the neourethra. Next, the vaginal cavity was closed, the labia minora were de-epithelized and sutured together in median plane to imitate the scrotum. A perineal fistula, developing in the postoperative period, was surgically closed a month later when testicular prostheses were also implanted. Today the patient, satisfied with the outcome, is two years after the procedure.

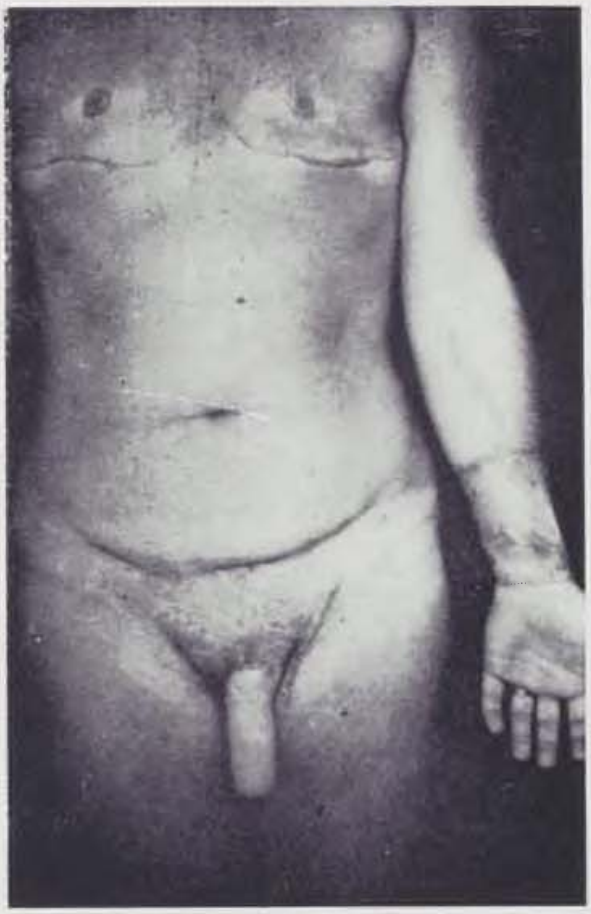

11. Status at three weeks postoperatively

DISCUSSION

The above technique offers several advantages. Gilbert and Horton employed a myocutaneous m. rectus abdominis and m. gracilis flap covered by a free dorsalis pedis flap and a forearm flap. The urethra was fashioned from a skin island of the musculocutaneous flap. Drawing on Santi's experience, we believe the skin island invariably has a thick subcutis and is too bulky for a delicate reconstruction such as that involving the urethra. While use

of the transversal m. rectus abdominis myocutaneous flap allows flap tubulization, it virtually eliminates the possibility of making the muscle the axis of the new penis. The vertical m. rectus abdominis myocutaneous flap, described previously by Santi, results in an extremely big penis and is not suitable for this purpose. The outcome of a procedure employing a separate forearm fasciocutaneous flap is similar to that seen in tubulized flaps which, moreover, require a multi-stage approach and are commonly complicated by healing of the flap's dead end. The penis is too soft requiring reinforcement either by a prosthesis or a cartilaginous graft. A "muscular" penis is a good idea and there is little doubt it should preferably be covered by a flap rather than by a skin graft as proposed by Lemperle. The consistency of a muscular penis is natural and requires reinforcement.

12. Status at three weeks postoperatively

SUMMARY

In the article, the authors offer a review of the modalities available for phalloplasty in transsexual patients. The classic methods for multi-stage transplantation of tubulized flaps in the lumbar and inguinal regions, in

mid-thigh as well as current methods for one-stage reconstruction are discussed.

The paper contains the case report of a transsexual patient undergoing one-stage reconstruction of the penis using m. rectus abdominis with the inferior pedicle, urethral reconstruction by a skin graft from simultaneous mastectomy with a free forearm flap covering the muscle.

The paper examines the pros and cons of each method for reconstruction.

RÉSUMÉ

Reconstruction du pénis chez les patients transsexuels

Veselý, J., Bařinka, L., Santi, P., Berrino, P., Muggianu, M.

Dans leur article les auteurs traitent les possibilités de la reconstruction du pénis chez les patients transsexuels. Ils se réfèrent aux méthodes classiques des transferts à plusieurs étapes des lobes tubulés de la région des lombes, des aines et de la région de la cuisse intérieure, ainsi qu'aux méthodes modernes de la reconstruction à un temps.

Un cas est décrit, d'un patient transsexuel avec reconstruction du pénis à un temps, par le muscle rectus abdominis à pédicule inférieur, avec l'uretère reconstruit par un greffon cutané, prélevé aux seins, le muscle étant recouvert par un lobe libre de l'avant-bras.

Dans le travail, on discute les avantages et les désavantages de différents types de reconstruction.

ZUSAMMENFASSUNG

Die Rekonstruktion des Penis bei transsexualen Patienten

Veselý, J., Bařinka, L., Santi, P., Berrino, P., Muggianu, M.

In ihrem Beitrag befasen sich die Autoren mit der Möglichkeit einer Rekonstruktion des Penis bei transsexualen Patienten. Sie weisen auf die klasische Methode von Übertragungen tubulisierter Lappen in mehreren Etappen in der Lenden- und Leistenregion sowie in der Gegend des inneren Oberschenkels hin, sowie auch auf die modernen Methoden einer Rekonstruktion auf einmal.

Es wird die Kasuistik eines transsexualen Patienten mit einer Rekonstruktion des Penis auf einmal mittels des musculus rectus abdominis und der unteren Wurzel beschrieben, die durch einen Urethra-Hautspan aus der zu gleicher Zeit amputierten Brust rekonstruiert und der Muskel durch einen freien Unterarmlappen gedeckt wurde.

Die Arbeit diskutiert die Vor- und Nachteile der einzelnen Typen einer Rekonstruktion.

REFERENCES

1. **Chang, T. S., Hwang, W. I.:** Forearm flap in one-stage reconstruction of the penis, Plast. reconstr. Surg. 74 : 251, 1984.
2. **Davies, D. M., Matti, B. A.:** A method of phalloplasty using the deep inferior epigastric flap, Br. J. Plast. Surg. 41 : 165, 1988.
3. **Gilbert, D. A., Horton, C. E., Terzis, J. K., Devine, C. J., Williams, M. M.:** Phallic reinervation via the internal pudendal nerve. In (R. J. Manelsha Ed.) Transaction of the IX Int. Congr. of Plast. Rec. Surg., p. 444, Tata McGraw Co. Ltd., New Delhi, 1987.

4. **Gilbert, D. A., Horton, C. E., Terzis, J. K., Devine, C. J., Winslow, B. H., Devine, P. C.**: New concepts in phallic reconstruction, Ann. Plast. Surg. 18 : 128, 1987.

5. **Horton, C. E., McGraw, J. B., Gilbert, D. A., Terzis, J. K., Devine, P. C., Fiveash, J., Schnellhammer, P.**: Phallic construction with genital sensation, In (H. B. Williams Ed.) Transaction of the VIII Int. Congr. of Plast. reconstr. Surg., p. 721, Montreal, 1983.

6. **Lemperle, G.**: Personal Communication with Santi, 1989.

7. **Meyer, R., Daviero, P. J., Dequesne, J.**: One stage phalloplasty in transsexuals, Ann. Plast. Surg. 16, 6; 472, 1986.

8. **Mukherjee, G. D.**: Use of groin and mid-thigh flap in reconstruction of penis with penile and perineal urethra and a dorsal skinlined socket for a removable prosthesis, An. Plast. Surg. 16, 3 : 235, 1986.

9. **Santi, P. L., Berrino, P., Cnavese, G., Galli, A., Rainero, M. L., Badellino, F.**: Immediate reconstruction of the penis using an inferiorly based rectus abdominis myocutaneous flap, Plast. reconstr. Surg. 81 : 961, 1988.

MUDr. Jiří Veselý
Department of Plastic Surgery
Berkova 34
602 00 Brno
Czechoslovakia

Medical Faculty, Pilsen (Czechoslovakia)
Department of Surgery
Head Prof. J. Valenta, M. D., DrSc.
Department of Plastic Surgery

MEATOPLASTY WITH RECONSTRUCTION OF THE FORESKIN A PROCEDURE FOR ANTERIOR HYPOSPADIAS

J. ŠOLC, V. BURSA

Hypospadia is a common disorder occurring in 1 out of 300 live male births. Majority of these boys — about 70 per cent — have the meatus situated on the ventral surface of the glans, in the balanopenile furrow or on the distal third of the shaft. In the absence of chordee this congenital abnormality causes no functional handicap with regard to voiding or sexual activity. In all cases there is a conspicuous cleft of the prepuce and often association with stenosis of the meatus. The reason for surgery is predominantly cosmetic.

Numerous techniques have been described of how to repair minor hypospadias. Many surgeons are reluctant to offer any reconstruction, owing to high complication risks, inferior cosmetic effect and technical demands of these methods. The results of repairs with the cleft of the prepuce left, prepuce deformation or its partial consumption for distal urethra completing are not considered satisfactory by most patients. Circumcision of the penis is not usual in this country.

Growing demands for the normal appearance of the male genitalia made us look for new methods, combine and adapt them.

The method described has been used at the Department of Plastic Surgery in Pilsen since 1989.

CLASSIFICATION, CANDIDATES FOR SURGERY

The classification of hypospadias differs in literature. We use the classification of Barcat, which is based upon the localisation of the meatus after release of the chordee. There are 3 groups — anterior hypospadias (glandular, coronal, anterior penile), middle (middle third of the shaft) and posterior hypospadias (posterior penile, scrotal and perineal). Candidates for meatoplasty with reconstruction of the foreskin are boys with anterior hypospadias, no fibrous chordee and good quality perimeatal skin. The technique involves

enlargement of the stenotic meatus and elongation of ventral penile skin. The operation is performed from the age of 3 onward under general anesthesia.

OPERATIVE TECHNIQUE

The first step is to lengthen the dorsal aspect and correct stenosis of meatus. Longitudinal incision is done from the inside of the dorsal edge of the meatus to the distal glans groove. A horizontal closure of the incision advances the dorsal aspect of urethra and enlarges the meatus (Fig. 1, 2).

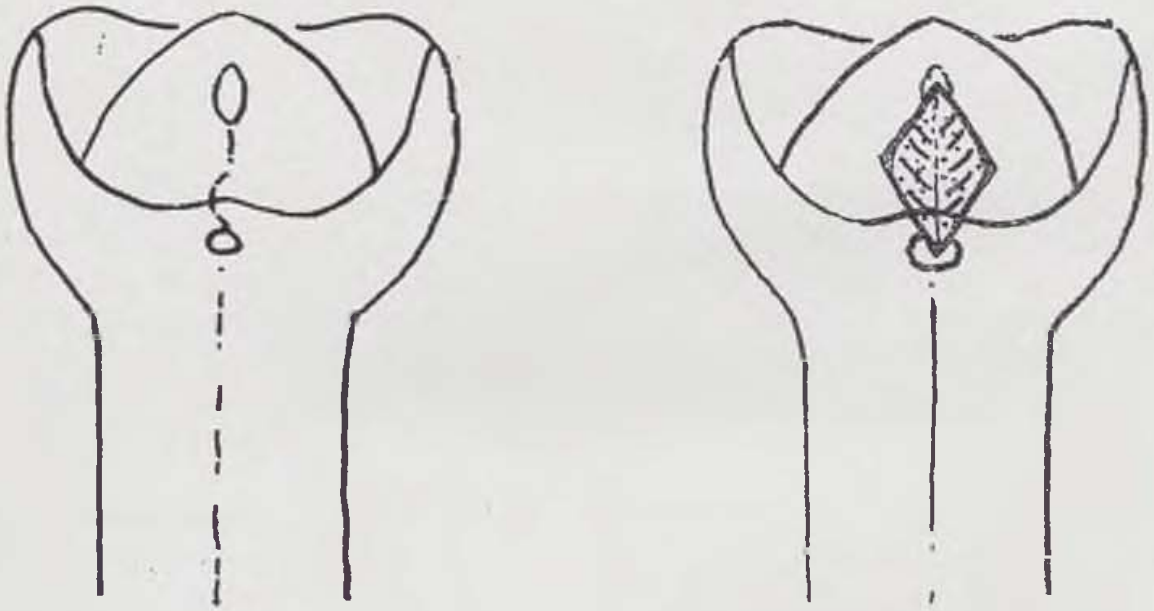

Fig. 1., 2. Meatoplasty and glanduloplasty. See text explanation.

The following step is to lengthen the ventral aspect of urethra and reconstruct the inner layer of foreskin. A semicircular incision, which joins both halves of the cleft prepuce lies approximately at the same distance from the meatus proximally as the distance of the meatus from the tip of the glans. Using a fine hook, the skin over the distal urethra and its surroundings is dissected with extreme care and retracted toward the glans. This enables lengthening of the ventral edge of urethra. It is held in position by approximation of the glans and closure of the glandular skin with 2 or 3 vertical matress sutures. Only exceptionally it is necessary to lengthen the urethra with a longer perimeatal-based flap. Suture of the inner sheet of foreskin is done with continued suture (Fig. 3, 4).

The next step is to reconstruct the outer sheet of prepuce and lengthen the insufficient ventral penile skin. This is accomplished with a single or double Z-plasty (Fig. 5, 6). We use absorbable materials for all sutures (Vicryl 6-0, 5-0). Usually, there is no need to leave any catheter after the operation.

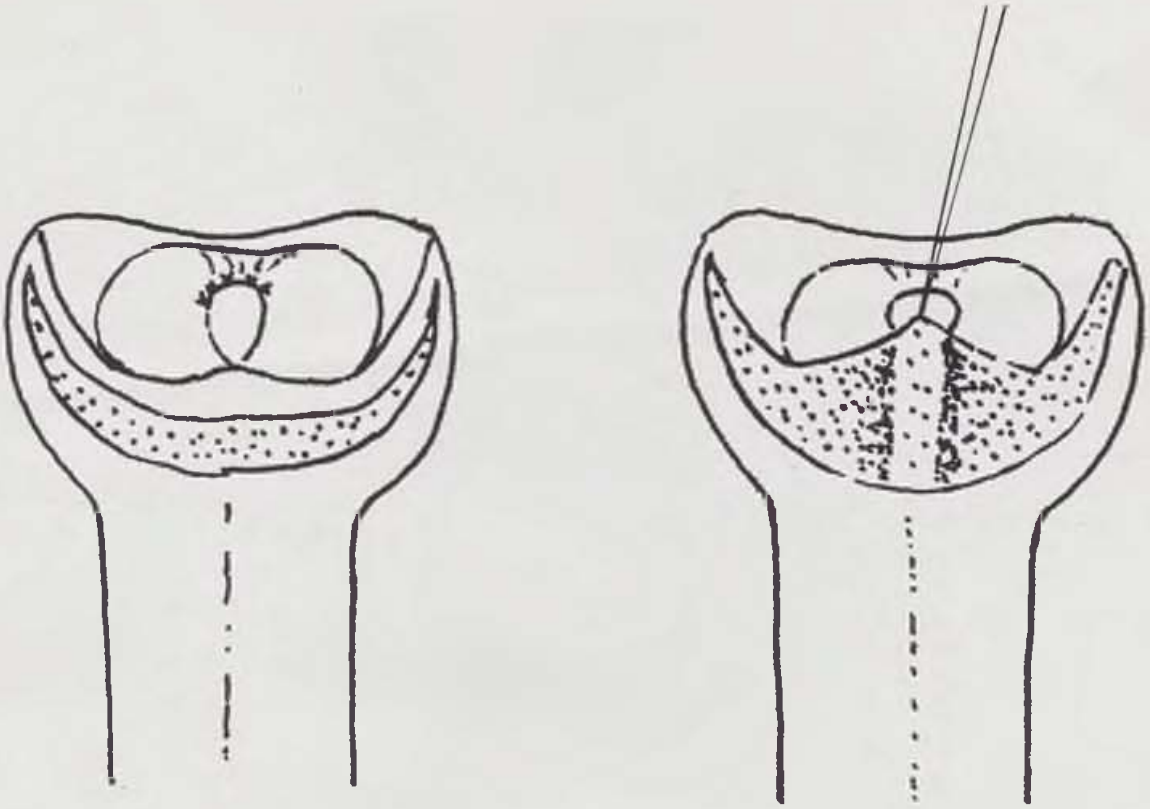

Fig. 3., 4.

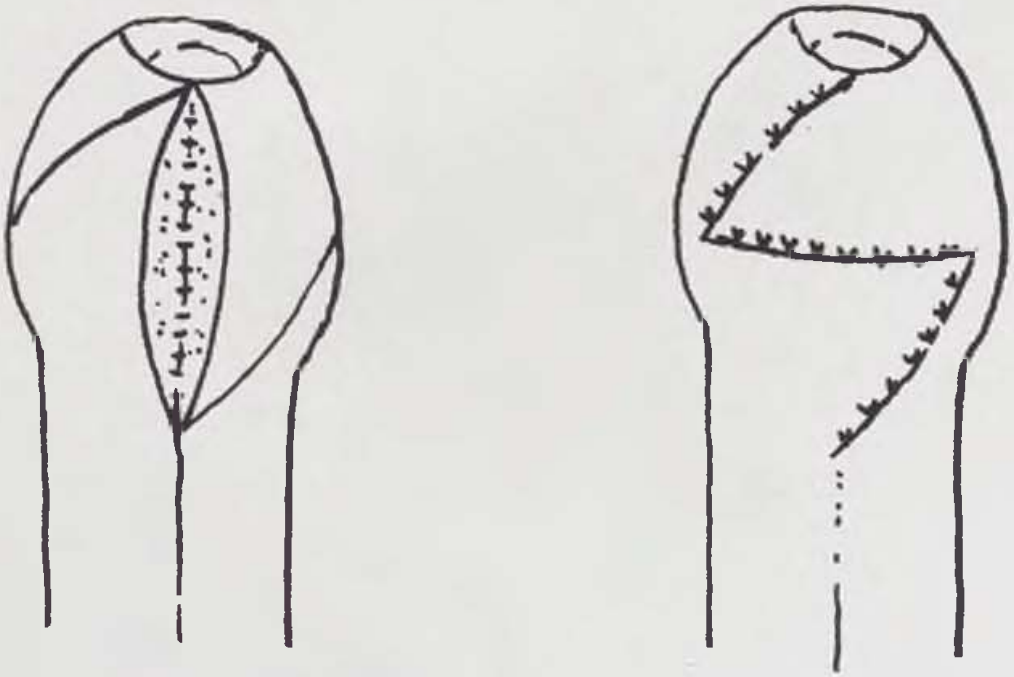

Fig. 5., 6.

Fig. 7. a

Fig. 7. b

Fig. 7. c

Fig. 8. a

Fig. 8. b

Fig. 8. c

RESULTS

We have performed 20 operations with 3 complications. Once it was a stenosis of the prepuce, a sort of arteficial phimosis. Twice there occurred a little dehiscence — a fenestration in the foreskin.

All of these were easily corrected at the next operation. No fistula, no stenosis of the meatus occurred.

DISCUSSION

Many techniques have been described to correct hypospadias with a meatus at the distal shaft or coronal level. The method described is derived from the MAGPI procedure of Duckett, who does not accomplish the reconstruction of the foreskin, the appearance resulting from this procedure being a circumcised penis.

Van Dorpe reconstructs the foreskin with simple suture in the midline. Adding a Z-plasty eliminates sutures of the inner and outer sheet of the foreskin being situated one on top of the other and adds insufficient skin on the ventral aspect of the penis.

The advantages of our procedure are:

1. The operation is relatively simple.
2. Cosmetic effect is considerable, because the penis approaches normal appearance, Preputium is mobile and has normal aspect.
3. Complications are rare and not serious.
4. No need of catheters and use of absorbable material enable shortening of hospitalization to 2—3 days and operating boys from the 3 years of age.

SUMMARY

There is a growing awareness of normal outlook of the male genitalia.

Described technique of meatoplasty with reconstruction of the foreskin is a relatively simple but safe method with satisfactory results, both functional and cosmetic, in cases of glandular, coronal and anterior penile hypospadias, applicable in the absence of fibrous chordee.

RÉSUMÉ

Méatoplastie avec reconstruction du prépuce — intervention pour hypoplasie antérieure

Šolc, J., Bursa, V.

On se rend compte de plus en plus de l'aspect des organes sexuels masculins extérieurs. La technique décrite de la méatoplastie avec reconstruction du prépuce représente une méthode relativement simple, mais fiable et donne les résultats satisfaisants du point de vue fonctionnel et cosmétique dans les cas de l'hypospadie du pénis glandulaire, coronaire et antérieure. Cette methode n'est pas utilisable en presence de la „chorda fibrosa".

ZUSAMMENFASSUNG

Die Meatoplastik bei Rekonstruktion der Vorhaut — ein Eingriff bei vorderer Hypospadie

Šolc, J., Bursa, V.

Mehr und mehr wird man sich des normalen Aussehens der männlichen äusseren Geschlechtsorgane bewusst. Die beschriebene Technik der Meatoplastik mit Rekonstruktion der Vorhaut ist eine verhältnismässig einfache aber zuverlässige Methode und gibt zufriedenstellende Funktions- und Kosmetikergebnisse in Fällen einer glandulären, koronären und vorderen Hypospadie des Penis. In Anwesenheit der „chorda fibrosa" ist die Methode unverwedbar.

REFERENCES

1. **Duckett, J. W.:** MAGPI (meatoplasty and granuloplasty): a procedure for subcoronal hypospadias. Urol. Clin. N. Amer., 8 : 513, 1981.
2. **Sheldon, A. C., Duckett, J. W.:** Hypospadias. Pediatr. Clin. N. Amer., 34 : 1259, 1987.
3. **Van Dorpe, E. J.:** Correction of distal hypospadias with reconstruction of the preputium. Plast. reconstr. Surg., 80 : 290, 1987.
4. **MacMillan, R. D. H., Churchill, B. M., Gilmour, R. F.:** Assessment of urinary stream after repair of anterior hypospadias by meatoplasty and glanuloplasty. J. Urol., 134 : 100, 1985.

Dr. J. Šolc,
Department of plastic surgery,
Tř. Dr. E. Beneše 13,
305 99 Plzeň
Czechoslovakia

NEWS

PSEF international meeting resumes in Czechoslovakia

PSEF's first International Symposium in three years it set for Oct. 18—21, 1992, in Prague, Czechoslovakia.

The Educational Foundation has not hosted a meeting in Europe since its 1989 conference in Budapest. The meeting set for 1991 in Israel was canceled due to fears that traveling there would be too risky. There was not enough time to reschedule it.

Registration and opening ceremonies for the 1992 symposium are tentatively scheduled for Oct. 18 in Prague. The scientific program will run Oct. 19—21. Topics to be highlighted include congenital malformations, reconstructive microsurgery and aesthetic surgery.

Rather than focusing on speakers, organizers plan to shape the meeting's schedule around the abstracts received, allotting more discussion time to especially appealing papers. Abstracts must be submitted by March 15, and may be sent on a single sheet of paper to Elaine Larkin-Leighton, PSEF, 444 E. Algonquin Road, Arlington Heights, IL 60005, USA.

Attendees will have ample opportunity to enjoy the historic charm of Prague — — which has been hailed by artists and visitors alike as one of the most beautiful cities in the world. The Wallenstein Palace, which lies in the shadow of the castle that overlooks the city, will be the site of a welcoming reception. Plans are also in the works for a final banquet at a historic site outside Prague. Organizers are attemting to include a visit by Shirley Temple Black, the U. A. Ambassador to Czechoslovakia, in the program.

Also to be offered in conjunction with the symposium are tours of Old Prague, including the site of the so-called „Velvet Revolution,"a crystal production factory, and a Moravian winery. Optional post-meeting trips are being considered to Krakow and Budapest.

The meeting is co-sponsored by PSEF and Czechoslovakian plastic surgeons. ASPRS members Jack C. Fisher and Bryant Toth are co-chairing the meeting with Václav Poláček, MD. **Miroslav Fára, MD, chief of the Charles University Plastic units in Prague,** will serve as honorary chairman.

ASPRS members are urged to register early because October is a peak tourist month for Prague. Enrollment is limited, with approximately half of the attendance expected to consist of plastic surgeons from Czechoslovakia and adjoining nations. Prague's new Atrium Hotel is hosting the meeting.

PSEF plans to choose an official air carrier and travel company to assist members in making their travel arrangements to this program. A registration brochure will be available later.

BOOK REVIEW

Color Atlas of Aesthetic Surgery of the Abdomen; Jorge M. Psillakis, Erdulfo Appiani, Rafael de la Plaza (1991 — Thieme Medical Publishers, Inc., New York, Georg Thieme Verlag Stuttgart — New York, ISBN 3-13-757501-x, DM 148.)

The 86-page book comprises 40 chapters, 73 figs. in 205 ills. (100 in color) a list of references and an index. The chapters are arrangnd as follows:

1 Introduction

2 Preoperative evaluation

3 Operative technique

4 Postoperative period

In the Introduction, the authors point out the importance of a detailed interview with the female patient in order to alert the surgeon to her complaints so the surgeon can operate accordingly.

The second chapter discusses various types of operations including performance of liposuction. The presented classification of abdominal aesthetic deformities, distinguishing 6 types, is bound to attract the reader's attention. Combined aesthetic procedures are also reviewed. The beginner will welcome the tunnel tracer to mark the tunnels for suction — assisted lipectomy, as well as the clearly arranged ABC's of liposuction accompanied by figures.

In plastic surgery of the abdominal wall, the emphasis is justly placed not only on m. rectus abdominis plication but, also, on the advancement of the external oblique muscle technique with the goals to reduce the waist, to reshape the semilunar lines, and to reshape the medial depression to the iliac crest.

These and many other partial procedures on the abdominal musculature and fascia are schematically shown in superb drawings interspersed throughout Chapter 3.

A less experienced surgeon will certainly appreciate the description of procedures such as the technique of repositioning of the navel, rib resection to correct asymmetries of the upper abdomen, the potential of appropriate reshaping of the abdominal relief by compressive plastic bandages, and so on.

The last chapter is dedicated to postoperative care and complications of healing with instructions on prevention of the latter. The book ends with questions frequently asked by patients, followed by appropriate answers.

To summarize, the "Color Atlas of Aesthetic Surgery of the Abdomen" is not only a clearly arranged and illustrative guide to the surgical treatment of the abdominal wall, it also makes fascinating reading even for the experienced plastic surgeon.

Prof. MUDr. M. Fára, DrSc.

CONTENTS