ACTA CHIRURGIAE PLASTICAE

No. 2, 1994

CONTENTS

SCOPE AND LIMITATIONS

Acta Chirurgiae Plasticae is an international journal with a long-standing tradition respected by the professional public worldwide. It is published in English four times per year. The journal contains clinical, experimental and theoretic studies from the discipline of plastic, reconstructive and aesthetic surgery, surgery of the hand, craniofacial surgery, treatment of burns and allied surgical disciplines (traumatology, orthopaedics, gynaecology etc.). In the journal you will also find reviews, case-histories, innovations, comments, reports from study trips and congresses, reviews of books and various announcements.

ACTA CHIRURGIAE PLASTICAE

SUBSCRIPTION AND FEES

Price for a single issue: Kč 39,50 (Czech Republic), Sk 47,50 (Slovak Republic), USD 35,80 (other countries).
1994 subscription rate: Kč 158,-, Sk 190,-, USD 143,20, respectively.
Subscription orders should be sent to the Publishing Division of the Czech Medical Association JEP, Sokolská 31, 120 26 Prague 2, Czech Republic, or by fax No.+422/ 249 11 420.

I hereby subscribe to Acta Chirurgiae Plasticae

Name ..... Date .....

Full address .....

.....

..... Signature .....

ACTA CHIRURGIAE PLASTICAE

Editorial board: M.Tvrdek, chairman, L.Brož, J.Kozák, A. Nejedlý, Z. Šmahel, J.Válka, members. Published four times a year by the Czech Medical Association J.E.Purkyně, Sokolská 31, 120 26 Prague 2, Czech Republic. Printed by MTT, Ostrovní 30, Prague 2.Distributor for the Czech Republic and Slovak Republic: ADLEX System, Pravoúhlá 26, 150 00 Praha 5. Distributor for other countries: ARTIA PEGAS PRESS, s.r.o., Palác Metro, Národní třída 25, P.O.Box 825, 111 21 Prague 1, Czech Republic. Fax: +422/24 22 78 72. Price for a single issue: Kč 39,50 (Czech Republic), Sk 47,50 (Slovak Republic), USD 35,80 (other countries). 1994 subscription rate: Kč 158,-, Sk 190,-, USD 143,20, respectively. Subscription orders should be sent to the Publishing Division of the Czech Medical Association JEP, Sokolská 31, 120 26 Prague 2, Czech Republic, or by fax No.+422/ 249 11 420. Manuscripts should be sent to ACTA CHIRURGIAE PLASTICAE, Šrobárova 50, 100 34 Prague 10, Czech Republic. Advertisements and enquiries concerning conditions of advertising should be sent to ALFA, Varšavská 12, 120 00 Prague 2, Czech Republic. Podávání novinových zásilek povoleno Ředitelstvím pošt Praha č.j. NP 1558/1994 ze dne 13. 7. 1994.

ACTA CHIRURGIAE PLASTICAE 36, 2, 1994, pp. 35 - 37

MEDIAN CLEFT OF THE UPPER LIP

G. P. Singh, A. Singh, G. Malhotra, S. K. Gulati, K. J. S. Mander

Department of Plastic Surgery, Government Medical College, Rajendra Hospital, Patiala, India

SUMMARY

Two cases of the true median cleft of the upper lip are reported, one with bilateral blepharoptosis and the other with a pedunculated mass from the nasal sill.

ZUSAMMENFASSUNG

Mediale Spalte der Oberen Lippe

G. P. Singh, A. Singh, G. Malhotra, S. K. Gulati, K. J. S. Mander

Ein Bericht über zwei Fälle einer medialen Spalte der oberen Lippe, bei einem bestand eine bilaterale Blepharoptose, beim zweiten war unter dem Nasenflügel eine gestielte Missbildung.

Key words: median, cleft lip

True median cleft of the upper lip is a rare congenital anomaly. More than hundred cases have been reported till now by different people. Fogh Anderson (1965), Millard and Williams (1968), Sen et al. (1990), Mahajan and Singh (1992) and others. We report two more cases treated in our unit.

EMBRYOLOGY

Embryologically the defect is in the development of the face which begins as two essentially independent halves when neural crest cells migrating into the face never cross the midline. In later stages, the median nasal processes are drawn together and the medial growth of medial nasal processes contributes to the fusion at the midline. Failure of the fusion of these processes in their lowest parts is thought to be responsible for median cleft of the upper lip. It may involve one- or two-thirds or total vertical height of the lip, depending upon the timing of inhibition of fusion. Other findings may consist of a bifid frenulum, a midline notch of the alveolus, a midline cleft palate or a bifid nose with or without hypertelorism.

CASE REPORTS

Case No. 1

G. S., a male, aged 18 years was admitted in 1993 with a defect of upper lip and nose since birth. He had a median cleft of the upper lip in-

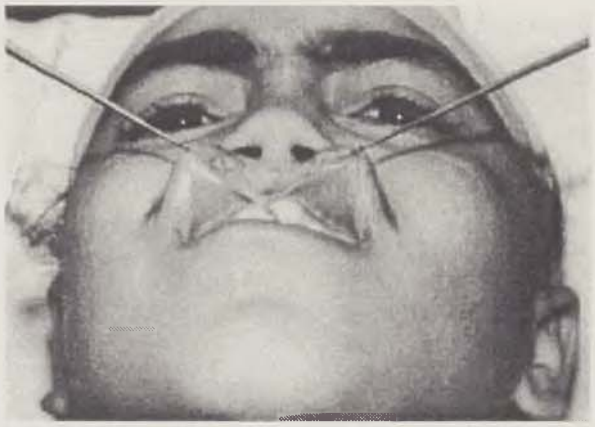

Fig. 1. Pre-operative photograph showing bifid frenulum.

Fig. 2. Pre-operative photograph showing median cleft lip and bilateral mild blepharoptosis.

Fig. 3. Post-operative photograph showing repaired lip.

volving the total lip with short broad columella, the nose was broad. There was a duplication of the frenulum (Fig. 1) and a blind sinus at the junction of the lip and the alveolus.

The upper incisors were malformed and malrotated. The facial development was normal but for a mild bilateral blepharoptosis (Fig. 2). The lip was repaired with the method described by Millard and Williams (1968) (Fig. 3).

Case No. 2

G. K., a baby female, aged 3 months, was admitted in 1994 with a defect of the upper lip. On examination there was a complete median cleft of the upper lip with duplication of the frenulum and notching of the alveolus and a short broad columella. A mass with a thin long pedicle was attached to the sill of the right nostril. Facial development was normal (Fig. 4). The lip repair was done with the method described by Millard and Williams (1968) (Fig. 5). The pedunculated mass was excised and its histopathological examination showed fibrous and fatty tissue with a normal skin cover and no cartilagenous tissue was seen in the specimen.

DISCUSSION

The median cleft of the upper lip is a rare congenital facial anomaly which was first described by Bechard in 1823 (Galanti, 1961). Keith (1909) reported this malformation in a specimen located in the museum of the Royal College of Surgeons in London.

The median cleft of the upper lip has been divided into true and false varieties (Braithwaite and Watson, 1949).

Veau (1938) favoured the recognition of three varieties of median clefts. A notch, a median cleft extending to the columella and a defect caused by atrophy of the whole medial element.

Millard and Williams (1968) proposed that any congenital vertical cleft through the centre of the upper lip, no matter to what extent, should be classified as a median cleft of the lip. If any vestige of prolabium is present then it becomes bilateral.

Pinto and Goleria (1977) divided median cleft lip into two groups, group I as agenesis with deficiency of tissues which developed from the median nasal process and group II as failure of fusion of tissues from the two sides.

Many others - Sharma and Razdan (1988), Sen et al. (1990), Mahajan and Singh (1992) - reported different cases with similar anomalies.

The cases reported by us represent true median clefts of upper lip and they were repaired with method described by Millard and Williams (1968). Fogh Anderson (1965) mentioned an associated malformation of the hand. Tripathi et al. (1984) described an associated columellar cyst and Sen et al. (1990) reported meningocele penetrating through the palate. The other associated anomali-

Fig. 4. Pre-operative photograph showing median cleft of the upper lip and a pedunculated mass arising from the right nostril.

Fig. 5. Post-operative photograph showing repaired lip.

es reported in both cases i.e. bilateral blepharoptosis in Case No. 1 and pedunculated mass from the nasal sill in Case No. 2 were not reported in the literature available.

REFERENCES

1. Braithwaite, F., Watson, J.: A report of three unusual cleft lips. Br. J. Plast. Surg., 2: 38-50, 1949.
2. Fogh Anderson, P.: Rare cleft of face. Acta Chir. Scand., 129: 275, 1965.
3. Galanti, S.: Rare congenital malformation of nose (2 cases of bifid nose). Ann. Laryngol., 60: 583-584, 1961.
4. Johnston, M. C., Bronsky, P. T., Millicovsky, G.: Embryogenesis of cleft lip and palate. In: McCarthy, J. G., Plastic surgery, Vol. 4, Philadelphia, Saunders W. B., 1990, p.2540.
5. Keith, A.: Congenital deformities of the palate, face and neck. Br. Med. J., 2: 310-311, 1909.
6. Mahajan, R. K., Singh, G. P.: Rare types of cleft lip: Case reports. Surg. J. N. Ind., 8: 14-16, 1992.
7. Millard, D. R., Jr., William, S.: Median lip clefts of upper lip. Plast. Reconstr. Surg., 42: 4-14, 1968.
8. Millard, D. R., Jr.: Cleft craft: The evolution of its Surgery. Vol. 2, Boston, Little, Brown and Co., 1977, 727-734.
9. Pinto, C. J. T., Goleria, K. S.: Classification of Median cleft of upper lip. In: Millard, D. R., Jr., Cleft Craft.Vol. 2, Boston,Little, Brown and Co., 1977, p. 729.
10. Sen, S. P., Nandi, M., Ghosh, S.: Median cleft of upper lip: A report of two cases. Ind. J. Plast. Surg., 23: 102-104, 1990.
11. Sharma, R. N., Razdan, J. N.: False median cleft. A case report. Ind. J. Plast. Surg., 21: 116-118, 1988.
12. Tripathi, F. M., Jena, S. K., Bhattacharya, V., Sinha, J. K.: Median cleft of upper lip: Two case reports. Ind. J. Plast. Surg., 17: 14-16, 1984.
13. Veau, V.: Hasenscharten Menschlicher Keimlinge auf der Stufe. Ztschr. Anat., 108: 459, 1937-38. In: Millard, D. R., Jr., Cleft Craft: The evolution of its Surgery. Vol. 2, Boston, Little Brown and Co., 1977, 727-734.

Address for correspondence: *G. P. Singh,*
"Guru Villa",
Bhupindra Road,
Patiala,
147 001 India

ACTA CHIRURGIAE PLASTICAE 36, 2, 1994, pp. 38 - 41

EFFECTS OF PRIMARY BONE GRAFTING ON FACIAL DEVELOPMENT IN PATIENTS WITH UNILATERAL COMPLETE CLEFT LIP AND PALATE

M. Tomanová[1], *Ž. Müllerová*[2]

[1]Institute of Experimental Medicine, Laboratory of Craniofacial Malformations, Academy of Sciences of the Czech Republic, Prague
[2]Department of Cleft Defects, University Hospital Královské Vinohrady, Prague, Czech Republic

SUMMARY

The study is based on an anthropometric assessment of X-ray films obtained in 22 adult males with complete unilateral cleft lip and palate treated during childhood with primary bone grafts and in 32 males with the same type of cleft without bone grafting.

In the series with bone grafts was recorded a more marked reduction of maxillary depth associated with a larger retrusion than in the series without bone grafts. This deviation was therapeutically compensated by a larger displacement of the mandible backwards which contributes to the increase of mandibular posterior rotation. This provided the possibility to attain an edge to edge bite.

Our results confirmed the unfavourable effects of primary bone grafting on maxillary growth and development.

ZUSAMMENFASSUNG

Einwirkungen der primären Knochenimplantation auf Gesichtswachstum und Entwicklung bei Patienten mit einseitigen totalen Lippen-, Gaumenspalten

M. Tomanová, Ž. Müllerová

Die Arbeit beruht auf einer anthropometrischen Auswertung bei Röntgenaufnahmen bei 22 erwachsenen Männern mit totalen einseitigen Lippen-, und Gaumenspalten, und bei 32 Männern mit denselben Gesichtsspalten ohne Knochenimplantation.

In dem Krankengut mit einer Knochenimplantation bestand eine grössere Verkürzung der Oberkiefertiefe mit einer stärkeren Retrusion als bei den Patienten ohne Knochenimplantation. Die therapeutische Kompensation dieser Abweichung wurde durch eine grössere Rückverschiebung des Unterkiefers erreicht, die zu einer stärkeren rückwertigen Rotation des Unterkiefers beiträgt. Dadurch wurde ein "tête à tête" erreicht.

Unsere Ergebnisse bestätigten den ungünstigen Einfluss der primaren Knochenimplantation auf den Oberkieferwachstum und Entwicklung.

Key words: cleft lip and palate, primary bone grafting, facial growth

The method of early implantation of bone grafts into the cleft jaw was aimed at the prevention of a collapse of the disconnected segments of the maxilla and it was expected that a bone graft will exert a favourable effect on the growth of the jaw. However, these anticipated favourable effects did not occur, on the contrary it was possible to record frequently an untoward action of the bone graft on the anteroposterior and vertical growth of maxilla (Friede and Johanson, 1974, 1982; Ross, 1987; Müllerová and Šmahel, 1989). Therefore this method was gradually discarded. But there are equally some studies which failed to record an untoward effect of bone grafting (Rosenstein et al., 1982) or reported satisfactory results (Wood, 1970).

The degree of impairment of the development and growth of the maxilla produced by an early implantation of bone grafts was definitely related to the extent and technique of the surgical procedure. This illustrates the necessity of an analysis of the results obtained in our own series of patients treated with our method of bone grafting.

The aim of the present communication was to assess the long-term effects of primary bone grafting on the configuration of the craniofacial regi-

on in adult patients after the termination of the treatment, at a time when it could be considered as the final outcome.

MATERIAL AND METHOD

The studied series consists of 22 adult males with complete unilateral cleft lip and palate without visible signs of any associated anomalies. They were examined at a mean age of 21 years and 8 months. All patients were operated upon with the same method. Primary lip suture according to Tennison (a few cases according to Veau) supplemented by the implantation of a bone graft from the rib into the alveolar process (the graft did not extend into the palate) was performed at the age of about 7 months. Palate surgery, which consisted of a pushback and of pharyngeal flap surgery, was carried out at a mean age of 4 years and 4 months. All surgical procedures were carried out at the Department for Plastic Surgery in Prague towards the end of the sixties and at the beginning of the seventies. Orthodontic therapy was applied in all patients at a specialized department. Fixed appliances were used during the pubertal growth spurt in 12 patients (55%). Without a correction in the region of the lip and of the nose remained 4 patients (18%). Six patients were excluded from our series because of maxillofacial surgery.

The group of controls consisted of 32 males with the same type of cleft. At the time of X-ray studies their mean age was 28 years. They included patients born in the two first post-war decades. They had a lip suture according to Veau at the age of about 7 months (at the mean age of 7.59 months). A bone graft was not implanted. Palate surgery was carried out with the same method as in the series with bone grafting at a mean age of 4 years and 8 months. Without a correction of the lip and of the nose remained 3 patients (9.3%). Orthodontic therapy without the use of fixed appliances was applied up to 1957 in the terrain and subsequently at the same specialized department as the above described series. Only two of 34 examined patients underwent maxillofacial surgery and are not included in this study.

The study is based on an anthropometric assessment of lateral X-ray films made under standard conditions during central occlusion. The craniometric points and reference lines are presented on Fig. 1.

The perpendicular distance of a point from the reference line is marked e.g. Ptm-VL, an angle is expressed by three points with the top of the angle represented by the middle point (N-S-Ba) or as a fraction of the signs designating the reference lines which form the given angle (ML/RL). The slope of the axis of the upper middle incisors to the palatal plane is designated +1/PL, of the lower middle incisors towards the

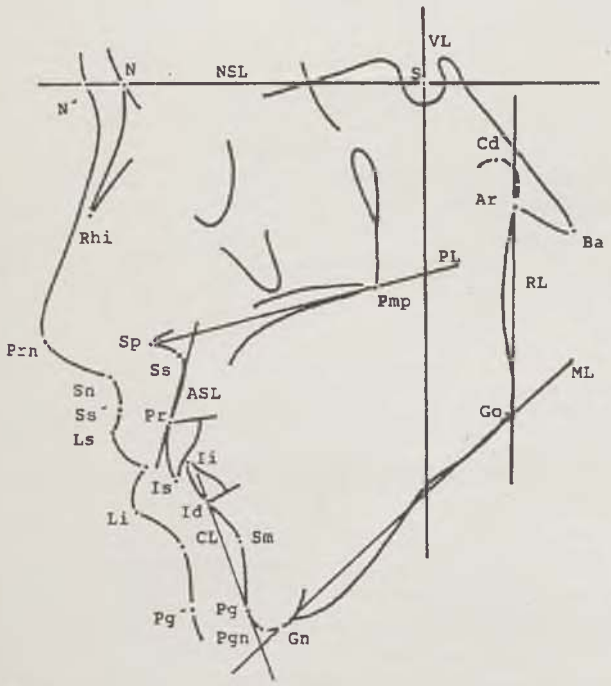

Fig. 1. Cephalometric points and reference lines used in the present study. Reference lines: NSL - line through N and S, VL - perpendicular to NSL through S, PL - line through Sp and Pmp, ML - tangent to the mandibular body through Gn, RL - tangent to the mandibular ramus through Ar, CL - line through Id and Pg, ASL - tangent to the upper alveolar process through Pr.

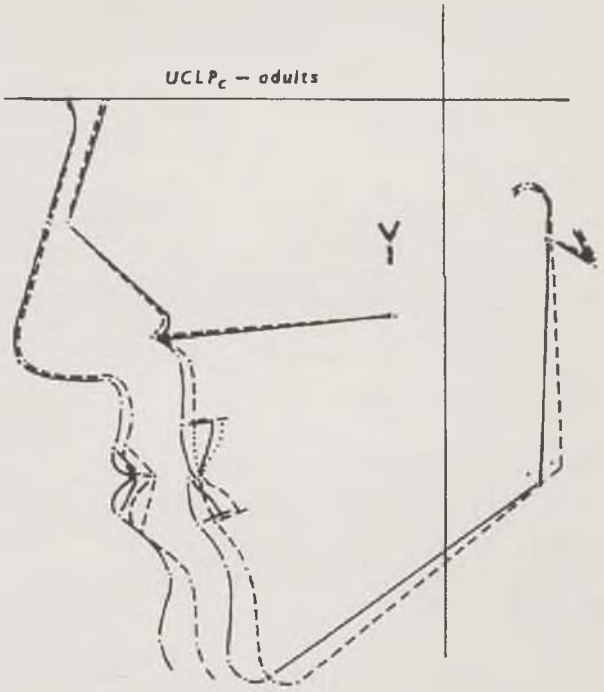

Fig. 2. Faciograms in patients with primary bone grafting (dashed line) as compared to patients without bone grafts (full line).

mandibular plane -1/ML. An overjet (Is-Ii) is measured between the edges of upper and lower incisors parallel to the occlusal plane. The characteristic Ls+Li shows the degree of prominence of the upper lip over the lower lip in anterior direction in the above mentioned points (measured perpendicularly to the connecting line N'- Pg'). A negative value of some parameters indicates that the point on the maxilla is situated more posteriorly than on the mandible (Is-Ii, Ls+Li). After the prosthetic treatment the values obtained by measurements are reduced by 2-6 in the inclination of upper and lower incisors and by 18 in the case of an overjet.

The significance of the differences between both series was determined with the t-test.

RESULTS

The results are presented in Table 1 and on Figure 2.

Tab. 1. Mean values and standard errors of X-ray cephalometric characteristics in patients with and without primary bone grafting

	graft (n=22)		no graft (n=32)			
Variable	X	SE	X	SE	dif.	t-test
Linear						
N-S	74.05	0.75	73.19	0.57	+0.86	0.928
N-Sp	53.50	0.81	54.06	0.64	-0.56	0.545
Ss-Pmp	45.36	0.82	48.02	0.70	-2.66	2.456*
Pmp-VL	10.77	0.57	10.97	0.52	-0.20	0.256
N-Gn	35.82	1.24	132.62	1.15	+3.20	1.858+
Id-Gn	39.23	0.52	36.32	0.67	+2.91	3.194**
Sp-Pg	77.32	1.06	73.03	1.09	+4.29	2.710**
S-Go	83.59	1.02	85.16	0.89	-1.57	1.148
Pmp-NSL	47.36	0.68	47.16	0.68	+0.20	0.201
Cd-Go	60.05	0.76	64.22	0.79	-4.17	3.483***
Pgn-Go	76.73	0.68	75.72	1.09	+1.01	0.706
Is-Ii	-0.27	0.66	-1.14	0.83	+0.87	0.822
Angles						
N-S-Ba	132.18	0.98	130.28	1.18	+1.90	1.155
S-N-Rhi	106.14	1.48	108.38	0.85	-2.24	1.404
S-N-Ss	71.86	0.84	74.78	0.89	-2.92	2.292*
S-N-Pr	74.55	0.81	76.59	0.85	-2.04	1.669
S-N-Id	75.41	0.81	77.44	0.78	-2.03	1.749+
S-N-Sm	73.23	0.78	75.94	0.77	-2.71	2.399*
S-N-Pg	74.95	0.78	77.81	0.81	-2.86	2.425*
N-S-Pgn	74.18	0.89	71.06	0.73	+3.12	2.708**
ASL/PL	96.59	1.28	95.56	1.72	+1.03	0.442
+1/PL	99.71	1.45	100.15	1.50	-0.44	0.211
-1/ML	84.09	1.52	83.27	1.30	+0.82	0.416
ML/VL	130.41	0.99	126.97	1.10	+3.44	2.195*
RL/NSL	92.27	1.08	87.91	1.01	+4.36	2.881**
ML/RL	127.77	1.29	129.03	1.26	-1.26	0.678
CL/ML	66.14	1.15	64.00	1.01	+2.14	1.385
PL/VL	95.45	0.83	96.47	0.85	-1.02	0.823
N-Ss-Pg	186.77	1.73	185.50	1.21	+1.27	0.616
Ss-N-Sm	-1.36	0.82	-1.16	0.57	-0.20	0.207
Soft profile						
N'-Prn	58.27	0.76	58.19	0.70	+0.08	0.076
N'-Sn	63.14	0.82	62.34	0.67	+0.80	0.755
S-N'-Ss'	78.09	0.97	79.56	0.81	-1.47	1.161
S-N'-Sm'	75.36	0.87	77.56	0.73	-2.20	1.933+
S-N'-Pg'	76.82	0.87	79.94	0.75	-3.12	2.687**
N'-Sn-Pg'	175.23	1.94	177.25	1.41	-2.02	0.864
Ss'-N'-Sm'	+2.73	0.73	+2.00	0.51	+0.73	0.851
Ls+Li	-1.32	0.49	-1.97	0.44	+0.65	0.979

Significant differences between patients with and without grafts at p 0.001***, p 0.01**, p 0.05*, p 0.1+.

The main dimensions of the cranial base (N-S, N-S-Ba) are indentical in both compared series, which is suggestive of the comparability of these two groups of patients. The patients with primary bone grafting differ from patients without bone grafts mainly by the anteroposterior shortening (Ss-Pmp) and retrusion of the maxilla (S-N-Ss). On the soft profile the difference between the retrusion was not significant (S-N'-Ss'). The anteroposterior position of the maxilla (Pmp-VL) and the anterior (N-Sp) and posterior (Pmp-NSL) upper face height were identical in both series (PL/VL). The degree of retroinclination of the dentoalveolar component of the maxilla (ASL/PL, +1/PL) equally did not differ in individuals with and without bone grafts. The mandible is more retrognathe in individuals with bone grafts than in patients without bone grafts (S-N-Id, S-N-Sm and S-N-Pg), inclusive of the soft profile (S-N'-Sm', S-N'-Pg'). There is a more pronounced posterior growth rotation with a steeper slope of the mandibular ramus (RL/NSL). The length of the mandibular ramus is markedly reduced (Cd-Go), the length of the mandibular body (Pgn-Go) was identical in both series. Compensation mechanism leads in patients with bone grafts to an increase of the anterior height of the mandible (Id-Gn), and thus also to an increase of the lower and total face height (Sp-Pg, N-Gn). The posterior height of the face (S-Go) did not differ on both series. The gonial angle (ML/RL), the chin angle (CL/ML) and the inclination of lower incisors (-1/ML) were identical in both series. The flattening of the facial skeletal framework (N-Ss-Pg) and the impairment of sagittal jaw relations (Ss-N-Sm, Ss'-N'-Sm') were identical in both series, however, the overjet (Is-Ii) was more satisfactory in patients with bone grafts where it was, on the average, possible to attain an edge to edge bite as compared to an anterior crossbite in patients without bone grafts. The convexity of the soft profile (N'-Sn-Pg') and the prominence of the upper lip (Ls+Li) were identical in both series of patients.

DISCUSSION

The skeletal facial configuration in our patients with primary bone grafting differed from patients without bone grafts by a more marked reduction of the anteroposterior dimension of the maxilla associated with its larger retrusion. This difference was present in spite of exclusion of six patients with most severe impairment from our series with osteoplasty because of maxillofacial surgery. Thus these deviations were most probably due to the actual effects of bone grafting. They lead to a further increase of the alterations which are characteristic for patients with clefts. They represent to a large extent the sequelae of surgical management of the palate (tension exerted by scars, ossification of the palate). Because of the

effect of primary bone grafting on the anteroposterior reduction and retrusion of the maxilla was most frequently suggested the possibility to block the growth within the vomero-premaxillary suture (Friede and Johanson, 1974, 1982) which in early childhood accounts for horizontal growth, rather than for vertical increments (Friede, 1978).

Our patients with bone grafts showed equally a more marked mandibular posterior rotation than individuals without bone grafting. It is not justified to believe that the recorded mandibular changes were primarily related to the effects of the implanted bone graft. Yet it is possible to suggest that it might exert secondary effects. An important role plays orthodontic therapy aimed at the reduction of the impaired sagittal jaw relations and at a restoration of a positive overjet which subsequently interferes with the development of the mandible in anterior direction. Orthodontic therapy was more effective in patients with bone grafts due to the use of fixed appliances.

Because of the more marked posterior position of the mandible in patients with bone grafts a higher retrusion of the maxilla does not lead to a larger impairment of sagittal jaw relations which might be anticipated. The increase of the anterior height of the mandible and of the lower face after bone grafting were most probably due to the compensation for the increased posterior rotation (Šmahel and Škvařilová, 1988). A significant mandibular deviation recorded in patients with bone grafts consisting of a shortening of the mandibular ramus which might contribute to the increased posterior rotation and to other mandibular changes (Šmahel and Škvařilová, 1988). It was suggested that this deviation occuring commonly in patients which clefts are produced by a primary impairment of growth (Šmahel et al., 1993) which could be related to the development of a cleft (Jelínek et al., 1983). A more marked shortening of the mandibular ramus in the series with bone grafts could be due to orthodontic therapy aimed at a larger displacement of the mandible backwards and impeding the growth of the mandibular ramus. Yet it is not possible to exclude a bias due to the small number of cases.

A more intense orthodontic therapy with the use of fixed appliances resulted in a more favourable situation within the frontal segment of teeth in the series with bone grafts. On the average, an edge to edge bite was attained, which indicates that in many individuals it was possible to restore a positive overjet. The two opposite trends, i.e. the tendency of the dentoalveolar process towards a retroinclination after primary bone grafting and the attempt of the orthodontist to attain its proclination, provide obviously the answer to the question why the degree of retroinclination of the alveolar process and of upper incisors are identical in both series.

REFERENCES

1. Friede, H., Johanson, B.: A follow-up study of cleft children treated with primary bone grafting. Scand. J. Plast. Reconstr. Surg., 8: 88-103, 1974.
2. Friede, H., Johanson, B.: Adolescent facial morphology of early bone-grafted cleft lip and palate patients. Scand. J. Plast. Reconstr. Surg., 16: 41-53, 1982.
3. Friede, H.: The vomero-premaxillary suture - a neglected growth site in mid-facial development of unilateral cleft lip and palate patients. Cleft Palate J., 15: 398-404, 1978.
4. Jelínek, R., Dostál, M., Peterka, M.: Cleft lip and palate in the picture of experiment (in Czech). Praha, Univerzita Karlova, 1983.
5. Müllerová, Ž., Šmahel, Z.: Effects of primary osteoplasty on facial growth in unilateral cleft lip and palate after ten years of follow-up. Acta Chir. Plast., 31: 181-191, 1989.
6. Rosenstein, S. V., Monroe, C. W., Kernahan, D. A., Jacobson, B. N., Griffith, B. H., Bauer, B. S.: The case for early bone grafting in cleft lip and palate. Plast. Reconstr. Surg., 70: 297-307, 1982.
7. Ross, B. R.: Treatment variables affecting facial growth in complete unilateral cleft lip and palate. Part 3: Alveolus repair and bone grafting. Cleft Palate J., 24: 33-44, 1987.
8. Šmahel, Z., Škvařilová, B.: Roentgencephalometric study of cranial interrelations. J. Craniofac. Genet. Dev. Biol., 8: 303-318, 1988.
9. Šmahel, Z., Betincová, L., Müllerová, Ž., Škvařilová, B.: Facial growth and development in unilateral complete cleft lip and palate from palatal surgery up to adulthood. J. Craniofac. Genet. Dev. Biol., 13: 55-71, 1993.
10. Wood, B. G.: Control of the maxillary arch by primary bone graft in cleft lip and palate cases. Cleft Palate J., 7: 194, 1970.

Address for correspondence: M. Tomanová,
Šrobárova 50,
100 34 Prague 10,
Czech Republic

ACTA CHIRURGIAE PLASTICAE 36, 2, 1994, pp. 42 - 47

THE PREDICTION OF RESTORATION OF A POSITIVE OVERJET IN UNILATERAL CLEFT LIP AND PALATE

Z. Šmahel

Laboratory of Craniofacial Malformations, Institute of Experimental Medicine, Academy of Sciences of the Czech Republic, Prague, Czech Republic

SUMMARY

X-ray cephalometric studies were carried out repeatedly in 92 individuals with unilateral cleft lip and palate at the age of 10 and 15 years with investigations of a possible restoration of a positive overjet in relation to the development of sagittal interalveolar relations. On the basis of this analysis was constructed a nomogram which according to the age of the patient allows to use a single easily determined X-ray cephalometric parameter for the estimation of the risk of a failure of the management aimed at the restoration of a positive overjet. The system includes critical boundaries which should be attained in the course of the treatment for the restoration of a positive overjet and it provides the possibility to check the effects of all therapeutic procedures. The simple application of the nomogram and the easy collection of data (the age and sagittal interalveolar relations) allow its use in the clinical practice as a component of the documentation on the management of the patient.

ZUSAMMENFASSUNG

Prädiktion der Wiederherstellung des positiven Vorbisses bei einseitigen Lippen-, und Gaumenspalten

Z. Šmahel

Wiederholte röntgenzephalometrische Untersuchungen im Alter von 10 und 15 Jahren erfolgten bei 92 Patienten mit einseitigen Lippen- und Gaumenspalten zur Ermittelung der Möglichkeit einer Wiederherstellung eines positiven Vorbisses in der frontalen Zahngegend, in Abhängigkeit von der Entwicklung der sagittalen interalveolaren Beziehungen. Anhand dieser Analyse wurde ein Nomogram entwickelt, mit dem, je nach dem Alter des Patienten, mittels eines einzigen röntgenzephalometrischen Merkmales die Wahrscheinlichkeit eines Erfolges, bzw. die Gefahr eines Misserfolges, der Bemühungen um eine Wiederhestellung des Vorbisses beurteilt werden kann. In diesem System werden kritische Grenzen angegeben, die im Laufe der Behandlung zur Wiederherstellung des Vorbisses erreicht werden müssen, und ausserdem ermöglicht den Verlauf der gesamten Behandlung zu kontrollieren. Die einfache Ermittelung der benötigten Angaben (Lebensalter und Zustand der interalveolaren Beziehungen) ermöglichen die Anwendung des Nomograms in der täglichen klinischen Praxis im Rahemn der Dokumentierung des Behandlungsverlaufes bei individuallen Patienten.

Key words: unilateral cleft lip and palate, overjet, prediction, nomogram

The main problem associated with the development of the face in cleft lip and palate represents the growth deficiency of the maxilla in anterior direction. This leads to a gradually increasing retrusion of the upper jaw, a flattening of the facial profile, impairment of sagittal jaw relations and results in the development of anterior crossbite.

Another important deviation from normal consisted of the predominating vertical growth of the lower jaw with the persistence of an infantile steep slope of the mandibular body. Thus during the development of the face a reduced anterior growth rotation led to impaired vertical jaw relations. This could result in an open bite within the frontal segment of the denture with a subsequent proclination of the lower dentoalveolar component or an anterior displacement of the mandible as a whole which all of them promoted a further impairment of occlusion of incisors. To this unfavourable development contributed the retroinclination of upper incisors, and of the alveolar process which are produced by the increasing tension of the lip after its suture.

Thus three main components participate in the impairment of occlusion of incisors in anteroposterior direction: the deficiency of anterior growth of the upper jaw, the dentoalveolar retroinclination of the maxilla and the direction of growth and rotation of the mandible. Othodontic therapy or jaw orthopedics exert no effects on the deficient anterior growth of the maxilla. Yet an improvement of the retroinclination of upper incisors and partly also of the alveolar process can be

attained. The combination of this improvement with the retroinclination of lower incisors can serve for the compensation of disproportions in anteroposterior position of both jaws. The restoration of a positive overjet subsequently impedes the growth of the lower jaw in anterior direction, however it is more difficult to effect a change of mandibular rotation.

The participation of three deviations from normal in the impairment of sagittal jaw relations and their differing response to therapeutic procedures are consistent with the high variability of the development of facial skeletal framework in cleft patients. The anterior growth of the upper jaw is regularly deficient and sometimes occurs an anterior growth rotation of the lower jaw. In this situation is of major importance the degree of retroinclination of the dentoalveolar component of the maxilla because of its participation in disorders of occlusion, as well as in the compensation mechanisms. Due to the large variability of the development of both jaws in facial clefts an assessment of prognosis and therapeutic perspective are associated with difficulties.

So far reported studies dealing with the prediction of facial growth and development were carried out in the general population though frequently affected by various forms of malocclusions (Hixon, 1968; Björk, 1969; Johnston, 1975; Greenberg and Johnston, 1975; Schulhof and Bagha, 1975; Baumrind et al., 1984; Skjeller et al., 1984; Thames et al., 1985). Yet clefts of the lip and palate represent a specific form of malformation which belongs among the most severe facial skeletal and orthodontic anomalies associated with impaired development of the face. Therefore predictive systems devised on the basis of findings obtained in individuals without this malformation were not relevant for the assessment of clefts.

We have disclosed in the literature only a single system for the prediction of the development of both jaws devised by Enlow et al. (1969) and applied by Gnoinski (1982) in clefts. The system was aimed at studies into the anterior growth of the jaws and at the detection of the first signs heralding an unfavourable development. The sooner they developed the more unfavourable was the prognosis. The drawback of this method consisted in the lack of a precise localization of certain points requiring high quality films and in too much complicated technique for the daily routine. In the period of mixed dentition, determination of the functional occlusal plane is associated with great difficulties in patients with severe orthodontic anomalies and orthodontic therapy can result was rapid and marked changes in the slope of this plane. Thus even the input data suffered from a lack of precision and this resulted necessarily in a less precise prediction. Therefore it is our aim to devise a system which would be based on a small number of clearly defined and located points and which after the cutting of permanent incisors could estimate perspective to attain the development of a positive overjet in patients with clefts. This method would allow to focus attention on individuals with a high risk of an unfavourable development and thus an early initiation of an efficient orthodontic therapy. This could result in the reduction of the proportion of patients requiring maxillofacial surgery.

MATERIAL AND METHOD

The analysis is based on repeated studies of X-ray films of the head in 92 patients with unilateral cleft lip and palate at the age of 10-11 and 15 years (6 months). A complete cleft was present in 80 of these patients, while the remaining 12 individuals had a soft bridge within the treshold of the nostril (Simonart's band). The lip was repaired according to Tennison (in 27 patients according to Veau) at the age of about 7 months. In 52 boys was performed simultaneously a periosteoplasty, in 22 girls and 18 boys an osteoplasty. The patients treated with bone grafting were born in 1966-1972, the patients with periosteal flap surgery were born in 1972-1978. Palate surgery was carried out about the age of 4 years (bone grafting), or at the age of 5 years (periosteal flap surgery), with a pushback and pharyngeal flap surgery. One half of the patients (46 individuals) were treated with fixed appliances, the remaining individuals were treated only with removable appliances in the aim to attain a proclination of upper incisors and thus a positive overjet.

The X-ray films were made under standard conditions during centric occlusion with the head

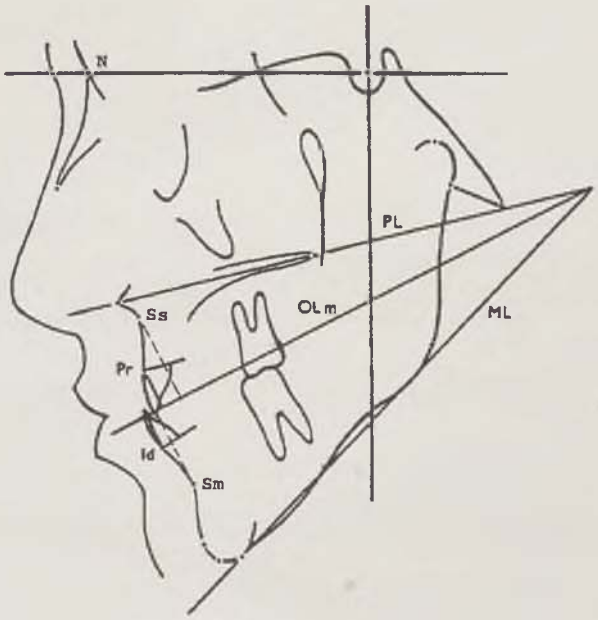

Fig. 1. Method of measurement of sagittal interalveoar relations (Pr+Id) and sagittal jaw (Ss+Sm) relations (see in the text).

of the patient fixed in a cephalostat. Of several tested methods for the prediction of a restoration of positive overjet in patients with clefts, proved most efficient to predict this perspective on the basis of the interalveolar relations expressed in terms of the anteroposterior difference between the edges of the upper and lower alveolar process after their perpendicular projection on the suggested so called modified occlusal plane (OLm, Fig. 1). This line passed through the midpoint between the edges of the upper and lower incisors during centric occlusion and the top of the angle formed by the palatal and mandibular planes (PL/ML angle). It is less related to the cutting of permanent teeth, to dentoalveolar anomalies or orthodontic therapy than the actual occlusal plane. Mandibular rotation is to a certain degree reflected by its slope produced by the displacement of the top of the PL/ML angle. Thus the rotation of the lower jaw is transferred into the slope of the occlusal plane where the amount of the difference after a perpendicular projection of the edges of both alveolar processes (Pr + Id) reflects the extent of the anterior growth of the maxilla, of the anteroposterior development of the mandible as well as the amount of dentoalveolar retroinclination. All parameters discussed in the introduction and which in the previous analyses proved to be of great importance for the development of sagittal jaw relations and of overjet were pooled into a single characteristic. The relationship of this characteristic and overjet was assessed with the correlation-regression analysis and the results obtained were used for the construction of a nomogram alloving to determine empirically the probability of the restoration of a positive overjet according to the age of the patient and to the actual interalveolar relations. An overjet (Is - Ii) was measured between the edges of upper and lower central incisors parallel to the occlusal plane.

RESULTS

Sagittal interalveolar relations in clefts at the age of 10 years predetermined only slightly the development of overjet at the age of 15 years (r = 0.501). This was beyond any doubt due to a developmental disorder, as well as to orthodontic therapy. However the positive value of interalveolar relations at this age (Pr + Id) most probably heralds good therapeutic results (Fig. 2). An exception represented three patients (marked on the Figure) with the development of an anterior crossbite which was in all of them due to the deficient growth of the maxilla in anterior direction. Only in one of them this development was consistent with a high deficiency of growth during the previous period between five and ten years. The correlation coefficient between interalveolar relations at the age of ten and fifteen years attained the value of 0.743 which explains only 55% of the variability of this characteristic and is not sufficient for the designation of a favourable prognosis.

The relation of overjet to the interalveolar relations at the age of ten and fifteen years (Figs. 3, 4) is much closer, the correlation coefficients attain the value of 0.8. An anterior crossbite occurs at the age of 10 years in values of interalveolar relations amounting to -1 mm, at the age of 15 years in values of -3 mm (arrow K). The exceptional cases marked with numbers have a slight crossbite, mostly due to a retroinclination of upper incisors. Their proclination resulted subsequently in the restoration of a positive overjet (area above the level of horizontal arrows). The regression lines for both age groups show an almost parallel course (Fig. 5), however within five years occurs a displacement by 2.3 mm, i.e. about 0.5 mm per year towards negative values of interalveolar relations. On the basis of these data and of confidence limits (95%) of regression lines was constructed a nomogram which according to age predicts the probability of a favourable outcome, or of a failure

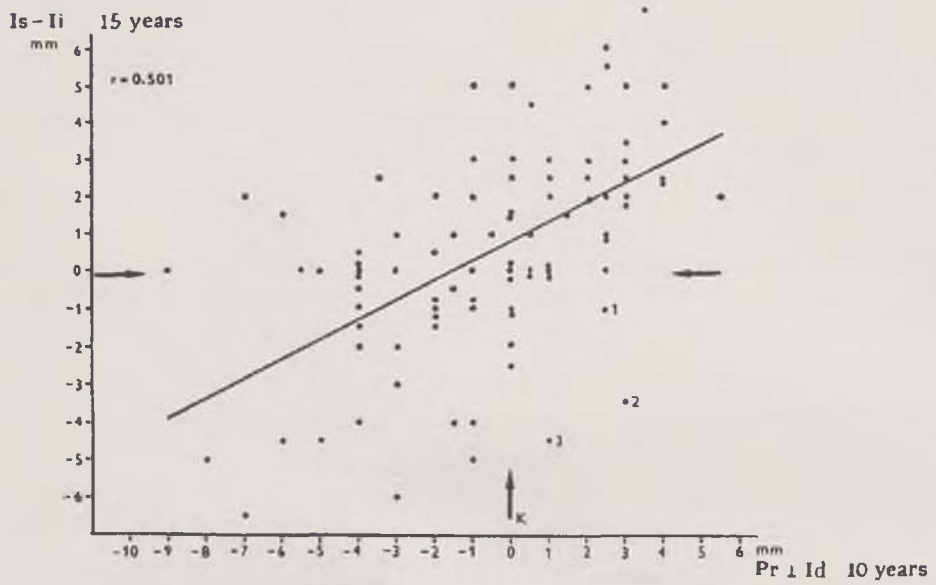

Fig. 2. The relation of overjet (Is - Ii) at the age of 15 years to the interalveolar relations (Pr + Id) at the age of 10 years. Distribution of the data and the regression line (arrow K designates value below which occures an anterior crossbite, horizontal arrows designate an edge to edge bite).

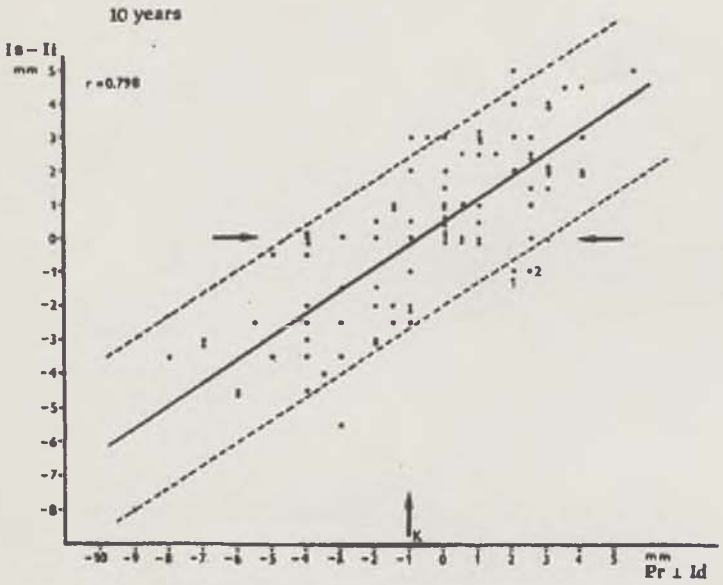

Fig. 3. The relation of overjet (Is - Ii) to the interalveolar relations (Pr + Id) at the age of 10 years. Distribution of the data and the regression line with 95% confidence intervals (arrow K designates critical boundary below which occurs an anterior crossbite, horizontal arrows designate and edge to edge bite).

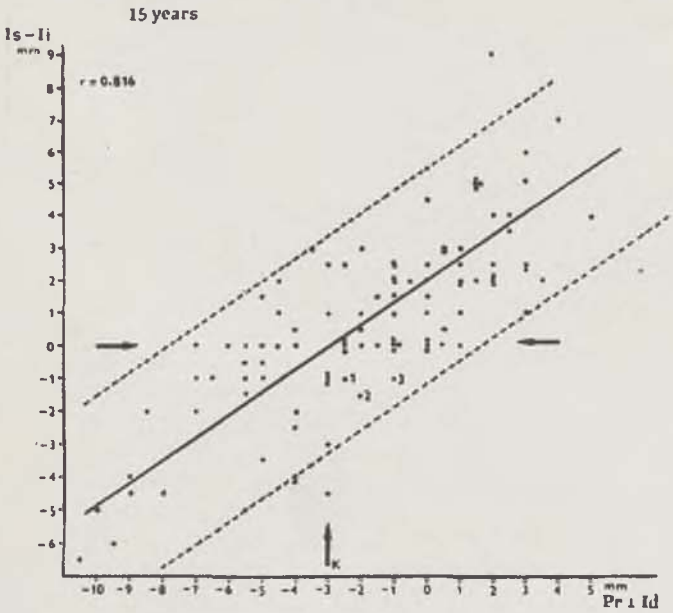

Fig. 4. The relation of overjet (Is - Ii) to the interalveolar relations (Pr + Id) at the age of 15 years. Distribution of the data and the regression line with 95% confidence intervals (explanatory notes see Fig. 3).

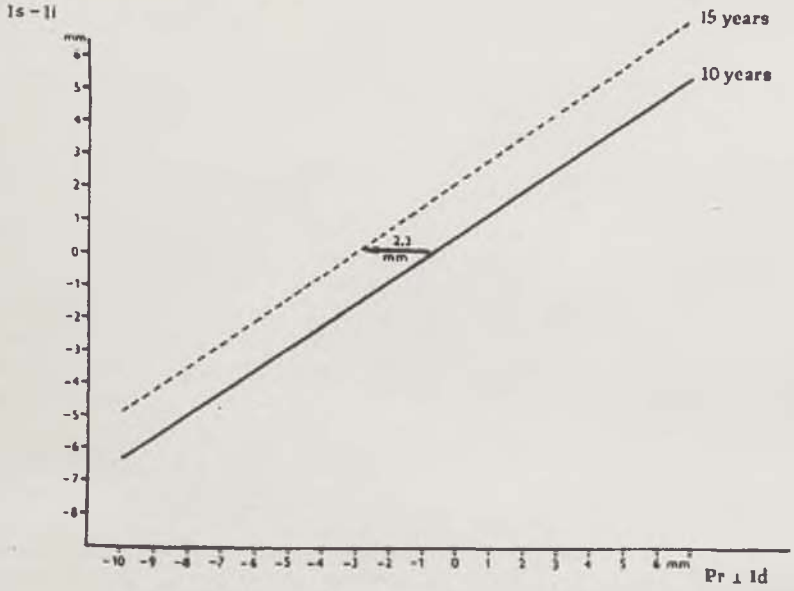

Fig. 5. The relation of overjet (Is - Ii) to the interalveolar relations (Pr + Id) at the age of 10 and 15 years. Regression lines.

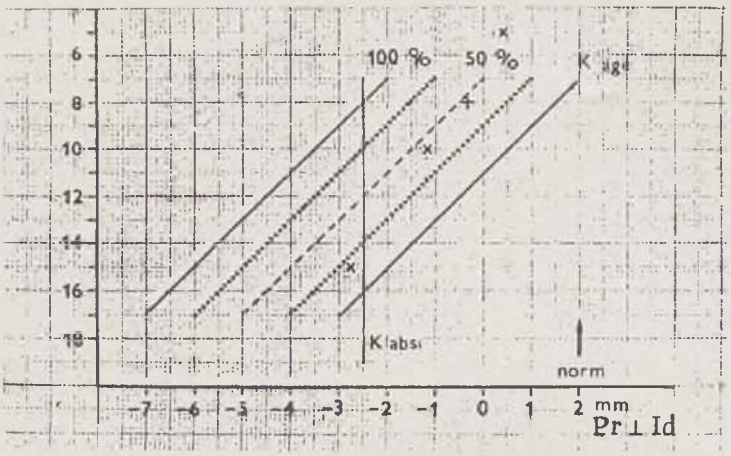

Fig. 6. A nomogram for the estimation of the possibility to restore a positive overjet in clefts (see text, norm = mean value of interalveolar relations in controls).

of the management of an impaired overjet in patients which cleft lip and palate on the basis of a single cephalometric finding characterizing the sagittal interalveolar relations (Fig. 6).

The critical boundary (K age) shows, according to age (marked on the ordinate) the range of values of interalveolar relations (marked on the abscissa) allowing definitely a restoration of a positive overjet. The aim of the therapy should be to attain values in front of this critical boundary (to the right). The absolute critical boundary (K abs) designates the limit which must be attained up to adult age for a definite restoration of a positive overjet with orthodontic therapy. The marked confidence limits illustrate equally that the restoration of a positive overjet fails almost in 100% of patients who attain this boundary at the age of 8 years, in 50% of individuals who attain it at the age of 12 years and in 25% of those who attain it at the age of 14 years. In other terms, if a patient attains this boundary as early as at the age of 8 years there is an almost 100% risk of a failure of the restoration of a positive overjet, if this value is attained at the age of 10, 12, or 14 years the risk amounts to 75%, 50% and 25% resp. Thus on the basis of the measurements of interalveolar relations and according to the age, it is possible to assess the therapeutic perspective in every individual patient: e.g. in a patient aged 10 years with an interalveolar relation of -1 mm the risk of a failure of the restoration of a positive overjet ranges between 25 and 50%.

In the nomogram are marked by crosses mean values of interalveolar relations recorded in our longitudinal study of a series of patients with unilateral cleft lip and palate at the age of 5, 10 and 15 years, supplemented by data obtained in another series at the age of 8 years (after the cutting of permanent incisors). They show to what extent the applied therapy succeeded to attain an improvement in our series of patients. The plotting of a straight line between these data the value after the termination of treatment at the age of 17 years would be consistent with the observation that 10% of the patients require surgery for the restoration of a positive overjet. More severe or inadequately treated cases would be situated on the left side of the nomogram, less severe and competently treated patients on the right side.

DISCUSSION

The nomogram was constructed on the basis of therapeutic results in our patients. In the case of a more effective therapy, either because of a better co-operation of the patient, or due to the availability of modern equipment and methods the critical boundaries could be shifted even more towards the left. However this shift could lead to the illusion that the management will be easier and thus it must be verified in large series of patients. The comparison of two series of our patients, with primary bone grafting and with periosteal flap surgery, equally failed to reveal any substantial differences. The problem consists rather in the mechanic capacity of the amount of differences between the anteroposterior position of the edges of both alveolar processes which will still allow the restoration of a positive overjet. This capacity improves with age, and is related therapeutically to the possibility of a proclination of the upper and retroinclination of the lower dentoalveolar component, yet also on the possibility to attain changes in the position of the lower jaw.

The values plotted on the nomogram are empiric and represent mean values of the risk which can differ in individual patients. For an exact assessment the development of an individual patient should be gradually recorded into the nomogram which shows whether its position in relation to the critical boundary for the given age improves or deteriorates. In the case of a failure the treatment can be either intensified or modified in the aim to improve the position of the given patient. At the same time it is possible to compare the data obtained in individual patients with the average situation in the reference series of patients with clefts recorded in the nomogram.

Of all facial parameters the interalveolar relations are logically most closely related to overjet and therefore were used for the construction of the nomogram. The advantage of the above mentioned characteristic expressed in this term con-

sists in its easy and precise determination, as well as in the fact that in the normal general population it does not change with age and does not differ according to sex. Mean values in our control series of boys and girls aged from 4 to 6 years and in adult females varied about 2 mm (Tab. 1). They were somewhat lower in adult males (1.2 mm), but they did not differ significantly from values in boys aged five years or from adult females. Therefore the decreasing values of this characteristic in patients with clefts represent a definite impairment. Sagittal jaw relations expressed in similar terms - the so-called Wits appraisal (Ss + Sm) decrease with age (Tab. 2) and are less closely correlated with overjet (at the age of 15 years r = 0.623 as compared to 0.816 in Pr + Id).

Tab. 1. X-ray cephalometric characteristics of sagittal interalveolar relations (Pr + Id) in controls

	5 years			adults				
	n	X	SE	n	X	SE	dif.	t
Males	27	2.20	0.32	37	1.26	0.35	-0.95	1.94
Females	30	1.97	0.28	36	1.92	0.45	-0.05	0.09
dif.		-0.23	t=0.55		0.66	t=1.17		

Tab. 2. X-ray cephalometric characteristics of sagittal jaw relations (Ss + Sm) in controls

	5 years			adults				
	n	X	SE	n	X	SE	dif.	t
Males	27	1.30	0.43	37	-0.99	0.47	-2.28	3.48*
Females	30	0.60	0.40	36	-0.71	0.60	-1.31	1.74
dif.		-0.70	t=1.19		0.28	t=0.37		

* significant difference at $p < 0.001$

The drawback of sagittal jaw relations and interalveolar relations expressed in terms of angles Ss-N-Sm (ANB) and Pr-N-Id is their relation to the length of the anterior cranial base (position of point N) and to other factors (Hussels and Nanda, 1984; Jacobson, 1988). They were even more slightly correlated to overjet than when they were expressed in the above mentioned terms (at the age of 15 years r = 0.475 and 0.708).

The nomogram is constructed exclusively for the period after the eruption of permanent incisors. It is based on the development of the relation of overjet to the interalveolar relation between the age of 10 to 15 years and it is therefore not certain whether the regression lines can be prolonged beyond this period of life, in particular into the postpubertal period. At the present time cleft patients from the reference series are examined after the termination of the treatment, i.e. in adult age. This should provide the answer to this question, and possibly allow a modification of the nomogram for the postpubertal period. Since the nomogram was based on the analysis of data obtained during a long-term follow-up study of large numbers of patients (n = 92) and since the interalveolar relations on the average, regularly deteriorated in patients up to the age of 15 years, we believe that it is relevant up to this age. Both the collection of data and the application of the nomogram are simple. Thus the nomogram is convenient for the daily clinical practice within the scope of the documentation of the management of patients with clefts.

REFERENCES

1. Baumrind, S., Korn, E. L., West, E. E.: Prediction of mandibular rotation: An empirical test of clinician performance. Am. J. Orthod., 86: 371-385, 1984.
2. Björk, A.: Prediction of mandibular growth rotation. Am. J. Orthod., 55: 585-599, 1969.
3. Enlow, D. H., Moyers, R. E., Hunter, S. W., McNamara, J. A.: A procedure for the analysis of intrinsic facial form and growth. An equivalent-balance concept. Am. J. Orthod., 56: 6-23, 1969.
4. Gnoinski, W. M.: Early maxillary othopedics as a supplement to conventional primary surgery in complete cleft lip and palate cases - long-term results. J. Max.-fac. Surg., 10: 165-172, 1982.
5. Greenberg, L. Z., Johnston, L. E.: Computerized prediction: The accuracy of a contemporary long-range forecast. Am. J. Orthod., 67: 243-252, 1975.
6. Hixon, E. H.: Prediction of facial growth. Trans. Eur. Orthod. Soc., 44: 127-139, 1968.
7. Hussels, W., Nanda, R. S.: Analysis of factors affecting angle ANB. Am. J. Orthod., 85: 411-423, 1984.
8. Jacobson, A.: Update on the Wits appraisal. Angle Orthod., 58: 205-219, 1988.
9. Johnston, L. E.: A simplified approach to prediction. Am. J. Orthod., 67: 253-257, 1975.
10. Schulhof, R. J., Bagha, L.: A statistical evaluation of the Ricketts and Johnston growth-forecasting methods. Am. J. Orthod., 67: 258-276, 1975.
11. Skieller, V., Björk, A., Linde-Hansen, T.: Prediction of mandibular growth rotation evaluated from a longitudinal implant sample. Am. J. Orthod., 86: 359-370, 1984.
12. Thames, T. L., Sinclair, P. M., Alexander, R. G.: The accuracy of computerized growth prediction in Class II high-angle cases. Am. J. Orthod., 87: 398-405, 1985.

Address for correspondence: Z. Šmahel,
Šrobárova 50,
100 34 Prague 10,
Czech Republic

ACTA CHIRURGIAE PLASTICAE 36, 2, 1994, pp. 48 - 52

SURGICAL TREATMENT OF JAW DEFORMATIONS IN ADULT PATIENTS WITH CLEFTS

J. Kozák[1], *P. Voska*[2]

[1]Charles Univesity, 2nd Medical School, University Hospital in Motol, Prague
[2]Central Military Hospital, Prague, Czech Republic

SUMMARY

The authors report their long-term experience with the surgical treatment of malformations of the jaws and of the face associated with clefts in adults. They carried out 172 maxillary surgeries, 65 mandibular operations and 20 bimaxillary surgical procedures. In recent years they performed almost exclusively operations on the upper jaws. The applied surgical procedure allows the repair of malformations of the whole face, and the team of surgeons is not concerned solely with the impaired relations between both jaws.

ZUSAMMENFASSUNG

Chirurgische Behandlung von Deformationen der Kiefer bei Erwachsenen mit Spaltmissbildungen

J. Kozák, P. Voska

Die Verfasser berichten über ihre langjährigen Erfahrungen mit der Behandlung von Kieferdeformationen bei Erwachsenen mit Spaltmissbildungen. Sie berichten über 172 Operationen an Oberkiefern, 65 an Unterkiefern und 20 bimaxillären Operationen. Während der letzten Jahre erfolgten chirurgische Eingriffe fast aussliesslich am Oberkiefer. Das angewandte Operationsverfahren ermöglicht eine Behandlung der gesamten Gesichtsmissbildung und begrenzt sich nicht auf die alleinige Beseitigung der gestörten Beziehungen zwischen den beiden Kiefern.

Key words: clefts, face deformations, adult age, maxillary osteotomy

Deformations of jaws in clefts occurring in adult patients are clinically manifested by maxillary hypoplasia, Angel class III occlusion and by a collapse of the alveolar arch. The clinical manifestation occur in varying degree and extent of combinations and their development is induced by a number of factors. In the first place it is the cleft jaw, per se, which leads to a failure of the fusion of maxillary segments and to a deficiency of growth. This results in an alveolar and palatal malformation and later to a disorder in the position of the teeth and to an impairment of occlusion in vertical direction. Another important factor represents the surgical trauma when the process of cicatrization of tissues leads to an inhibition of growth of the transverse and sagittal dimensions of the jaws. This observation is in agreement with the fact that patients without a surgical closure of the cleft palate have a normal development and a good expansion of the upper jaw (Kufner, 1966). The care for the surgically treated patients with cleft lip, jaw and palate is provided since early childhood by an orthodontist. Yet in spite of the expert orthodontic treatment and the satisfactory co-operation with the patient in a certain number of patients occurs an impairment of the transverse, sagittal and vertical growth of the jaws. The development of the mandible is mostly normal and thus the relations between both jaws are impaired. These cases which are not amenable to orthodontic therapy require surgical repair. Ross (1987) stated that 25% of patients with clefts require surgical orthodontic correction.

At our department are used for surgical treatment of these malformations the following procedures:

1. Le Fort I-III maxillary osteotomy,
2. osteotomy or ostectomy of the lower jaw,
3. bimaxillary surgery,
4. partial osteotomy associated with adequate orthodontic therapy.

In recent years are treated surgically almost exclusively the upper jaws. The surgical procedure is preceded by a comprehensive preoperative examination and by an analysis of X-ray films and dental casts. The assessment is not limited to the relationship between both jaws but attention is paid also to the anticipated changes of soft tissues and to the global features of the patient. In these patients nasotracheal intubation is associa-

ted with difficulties since most of them was subjected previously to pharyngeal flap surgery. After unsuccessful attempt to perform a nasotracheal intubation should follow an oral intubation and only then, when the patient is at rest a tube can be passed through the nose and a subsequent reintubation is possible.

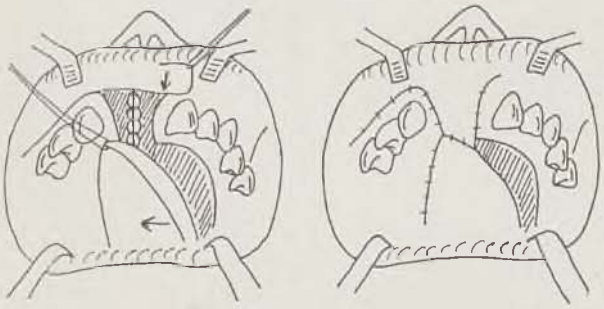

Fig. 1. Oronasal communication is closed by medial displacement of the palatal flap and with vestibular mucosal flap.

In a surgical procedure involving a large segment three vertical incisions are used for an osteotomy of the jaw according to Le Fort I line. Simultaneously a second surgical team dissects bone grafts from the iliac bone. Bone grafts are implanted into the line of the cleft beyond both tuber maxillae and into the void space produced by the ventral displacement of the upper jaw.

On the palate next to the large segment is created a flap (Fig. 1) with a dorsal pedicle which 's after a transverse shift rotated medialy, which reduced the necessity to create a long mucosal flap, the tip of which often shows necrotic changes. But for the last twenty individuals, all patients were treated for 6-8 weeks with intermaxillary fixation and with an external fixation with zygomatic hinges. The last twenty individuals were treated with the mini-plate system and a short-term intermaxillary fixation or with plastic strips. An oronasal communication was closed by an air-tight suture of a nasal mucosal layer, an inserted bone graft is covered with a vestibular flap. Contrary to the earlier practice this flap should not be long, due to the medial displacement of the palatal flap it can be short and because of its sufficiently width basis it is safe. Sometimes a narrow strip of zenoderm is applied posteriorly behind the bone graft, for the prevention of a possible impairment of the nasal layer, or a penetration of nasal secretion and a defect of the mucosal closure. The operation is performed under the cover of antibiotics administered for 8-10 days (Figs. 2 a,b).

In bilateral clefts are mobilized both lateral segments of the upper jaws, with an advancement of the premaxilla. This procedure includes equally an application of bone grafts and a closure of oronasal communication with vestibular flaps. In cases with marked maxillary hypoplasia an osteotomy according to Le Fort II-III lines is

2a)

2b)

Figs. 2 a,b. Patient with hypoplasia of the maxilla before and after Le Fort I maxillary advancement.

used for the advancement of the middle face (Figs. 3 a,b).

After the healing an orthodontic prosthetic treatment with a fixed bridge should follow as early as possible, which in our opinion provides an adequate prevention of a recurrence (Figs. 2 c,d; 3 c,d).

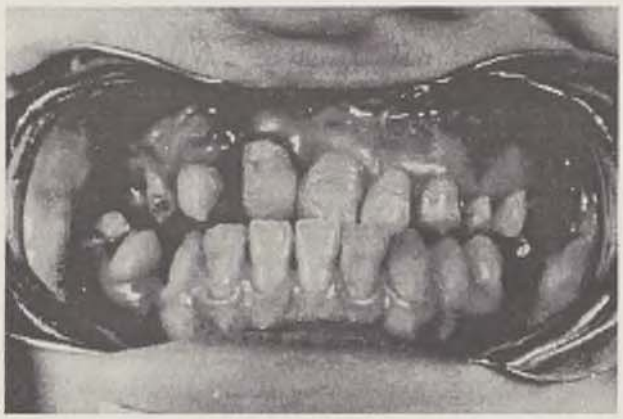

2c)

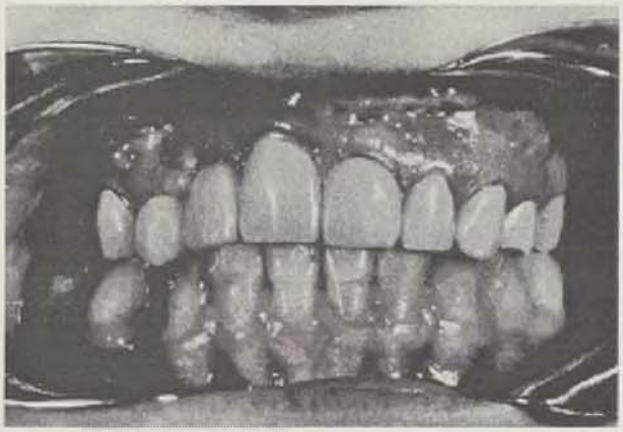

2d)

Figs. 2 c, d. Intermaxillary relation and the condition after the operation and prosthodontic treatment.

RESULTS

From 1974 to 1992 incl. were carried out 172 advancements of the upper jaws, 65 operations on the lower jaw and 20 bimaxillary surgeries. Out of the total number of 257 patients, 2 individuals developed a necrosis of a maxillary segment (once in a small and once in a large segment). Other complications included in 15 cases a necrosis of the tip of the vestibular flap which were very long and narrow. In 10 of these 15 patients was lost also the bone graft. The recorded late complications consisted of 3 total recurrencies and of 14 partial recurrencies which could be satisfactorily managed with the use of a prosthesis.

3a)

3b)

Figs. 3 a,b. Patient with severe deformation of the face ("dish face") before and after Le Fort III maxillary advancement.

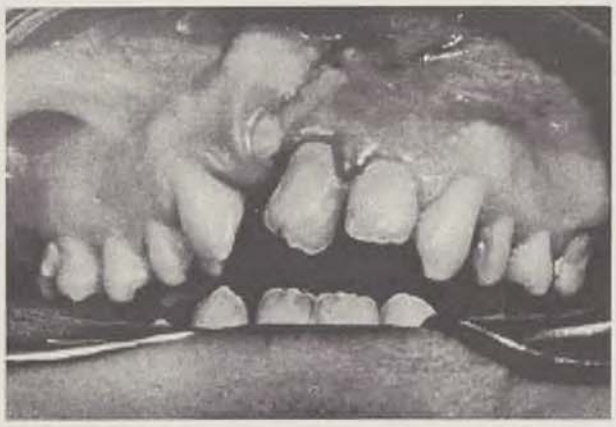

3c)

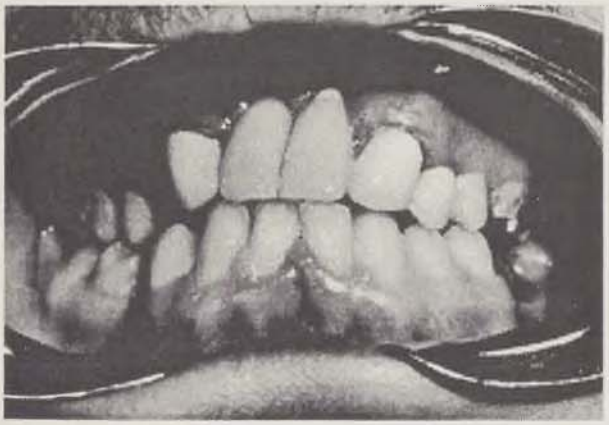

3d)

Figs. 3 c, d. Intermaxillary relation and the condition after the operation and prosthodontic treatment.

DISCUSSION

Surgical procedures used for the correction of late facial malformations in clefts undergo a certain progress, similarly as it is the case on other branches of medicine. Some surgical procedures were carried out exclusively on the lower jaw (Bilder, 1984). More recently were added certain surgical procedures for the treatment of the upper jaw which consisted in the implantation of bone grafts and of cartilaginous onlays. These so-called camouflage procedures (Georgiade, 1974) are aimed at an esthetic improvement. Gillies and Millard (1957), Obwegeser (1965) and others started to carry out operations on the upper jaw, in spite of numerous objections concerning the risk of bleeding, disorders of cardiac rhytm, the development of necrosis of maxillary segments, the reopening of oronasal communication a.o. The complications can be subdivided into peroperative and late complications. Peroperative complications include bleeding which could be either of arterial or venous origin. Venous bleeding is mostly due to an injury of the pterygoidal plexus. Arterial bleeding is due to an injuries of the branches of the a. maxillaris, most often is injured the a. palatina descendens and the a. sphenopalatina. An arterial injury requires cauterization and if its exact identification is not possible the surrounding space should be filled with a hemostypic readily resorbed material (Surgical).

The most severe complication which was reported but did not occur in our series represents an injury of the trunk of the a. maxillaris during the exposure of the operation site dorsally from the tuber maxillae. Turvey and Fonseca (1980) estimated that its distance from the pterygomaxillary joint is about 25 mm. Freihofer (1984) stated that 1% of complications were due to bleending occuring during these surgical procedures. A slighter bleeding which could be controlled with nasal tamponade, Spongostan or Surgicel was also present in our series. Another reported complication were disorders of cardiac rhytm which was due to the manipulation of the maxilla. Precious and Skulsky (1990) described the development of bradycardie up to asystolia in 1.6% of the patients. It is believed that the origin of this disorder is explained by the increased tension of soft tissues during the advancement of the maxilla and by the trigeminovagal reflex inducing bradycardia. This disrhytmia is well known from the ophthalmologic surgical practice and is designated as the occulocardiac reflex. In our series this complication was present in one patient and it was controlled by the administration of atropine.

A severe late complication represents the necrosis of a maxillary segment produced by an impairment of blood supply. During their studies of blood supply, Bell et al. (1975) failed to disclose any excessive differences in maxillary blood supply after the ligation of palatal vessels and he was the first author who proposed the indication of a direct vestibular incision during Le Fort I osteotomy. He demonstrated also that the disconnection of the a. palatina resulted only in a change of blood supply in which instead of the axial arterial mucosal flap develops a blood supply of the so-called random flap. In our series an extensive necrosis of osseous segments occurred in two cases. In one case was affected a small segment after an advancement of more than 1 cm and therefore it is believed that Bell did not fully accepted the rather high tension exerted on vessels within this area. For this reason the advancement is limited to 1 cm, in a larger disproportion is carried out bimaxillary surgery. In some cases is used a modified procedure consisting of an incomplete osteotomy allowing to avoid the use of splints and the orthodontist attains a required advancement by the application of strong tension. The second necrosis developed after the detachment of the vestibular mucosa with an already obvious mucosal flap. Since this flap helps to close the oronasal communication it is mandatory to use exclusively vertical incisions during an osteotomy for the exposure of the anterior surface of

the maxilla. Though, according to Posnick and Tompson (1992) they are not ideal because they do not allow a perfect visualization of the whole operation site or an easy fixation of mini-plates. A modification devised by this author provides the possibility of an advancement and medial displacement of a small segment and thus a closure of an osseous defect without bone grafting. However in the prevalent majority of our patients is required in addition a transverse displacement and an increase of the width of the jaw which are not possible with this surgical procedure. Among late complications belongs also an infection of bone grafts which was observed only in association with necrosis of the mucosal flap and exposure of the bone graft. During the last four years the implantation of bone grafts beyond the tuber maxillae was discarded since we believe, in agreement with Eskenazi and Schnedel (1992), that bone grafts are not necessary in this localization in patients where a fixation is performed with mini-plates. A further complication is a recurrence which can be prevented by the restoration of a deep overbite and by an excessive correction of an overjet of the upper jaw. It is also necessary to apply as soon as possible a fixed dental prosthesis.

In agreement with Tessier (1971) we are of the opinion that clefts represent a malformation affecting mostly the upper jaw and that it is therefore indicated to apply for their management maxillary surgery. In marked maxillary hypoplasia and a development of a dish face the surgical treatment includes also the middle face within Le Fort II-III lines.

On basis of our long experience we believe that the surgical repair of jaw malformations associated with clefts belong among the most difficult surgical procedures used for the reconstruction of the face. These surgical procedures require a great deal of experience, a careful exposure of the site of operation and a good co-operation with other specialists and they should be performed exclusively at specialized departments.

REFERENCES

1. Bell, W. H., Fonseca, R. J., Kennedy, J. W. et al.: Bone healing and revascularization after total maxillary osteotomy. J. Oral Surg., 33: 253, 1975.
2. Bilder, J.: On tactics in post cleft facial reconstruction. Scripta Medica 3: 155, 1984.
3. Eskenazi, B., Schendel, S. A.: An analysis of Le Forte I maxillary advancement in cleft lip and palate patients. Plast. Reconstr. Surg., 90: 779, 1992.
4. Freihofer, H. P.: Latitude and limitation of midface movements. Br. J. Oral Maxilofac. Surg., 22: 393, 1984.
5. Georgiade, N. G.: Mandibular osteotomy for the correction of facial disproportion in the cleft lip and palate patient. Ann. Plast. Reconstr. Surg., 8: 238, 1974.
6. Gillies, H., Millard, R.: Principle and art of plastic surgery. Boston, Little Brown, 1957.
7. Kufner, J.: Porozštěpové vady chrupu a skusu u dospělých a jejich léčení. Thesis, Charles Univ., Prague, 1966.
8. Obwegeser, H.: Eingriffe am Oberkiefer zur Korrektion des progenen Zustandbildes. Schweiz Monatschr. Zahnheilk., 75: 365, 1965.
9. Posnick, J. C., Tompson, B.: Modification of the maxillary Le Forte I osteotomy in cleft-orthognathic surgery. J. Oral Maxillofac. Surg., 50: 666, 1992.
10. Precious, D. S., Skulsky, F. G.: Cardiac disrhytmias complicating maxillofacial surgery. Int. J. Oral Maxillofac. Surg., 19: 279, 1990.
11. Ross, R. B.: Treatment variables affecting facial growth in complete unilateral cleft lip and palate. Part 7. Cleft Palate J., 24: 71, 1987.
12. Tessier, P.: The definitive surgical treatment of severe facial deformities of craniofacial dysostosis. Plast. Reconstr. Surg., 48: 419, 1971.
13. Turvey, T., Fonseca, R.: The anatomy of the internal maxillary artery in the pterygopalatina fossa. Its relationship to maxillary surgery. J. Oral Surg., 18: 38, 1980.
14. Wilmar, K.: On Le Forte I osteotomy. A follow up study on 106 operated patients with maxillo-facial deformity. Scand. J. Plast. Reconstr. Surg., 12, Suppl. 1: 1, 1974.

Address for correspondence: J. Kozák,
Vítězné náměstí 14,
160 00 Prague 6,
Czech Republic

ACTA CHIRURGIAE PLASTICAE 36, 2, 1994, pp. 53 - 56

THE OCCURRENCE OF HYPODONTIA IN PATIENTS WITH CLEFT LIP AND/OR PALATE

O. Jiroutová, Ž. Müllerová

Department of Cleft Defects, University Hospital Královské Vinohrady, Prague, Czech Republic

SUMMARY

The frequency of hypodontia (but for the third molar) was studied in a series of 600 patients with cleft lip and/or palate. The series was subdivided into three groups according to the type of facial cleft. As compared to the general normal population the occurrence of hypodontia was markedly increased in patients with clefts. The highest percentage of hypodontia was recorded in patients with cleft lip and palate, the lowest frequency was present in cleft lip only. In cleft lip and in cleft lip and palate girls were affected signiticantly more frequently than boys. The occurrence of hypodontia in the lower and in the upper jaw differed according to the type of cleft. The upper jaw was affected more often in cleft lip and in cleft lip and palate, the mandible was involved more frequently in isolated cleft palate. The dental bud of the upper lateral incisor was affected most commonly in cleft lip and in cleft lip and palate, while the second lower premolar was most frequently absent in isolated cleft palate.

ZUSAMMENFASSUNG

Häufigkeit der Hypodontie bei Patienten mit Lippen- und/oder Gaumenspalten

O. Jiroutová, Ž. Müllerová

Bei einem Krankengut von 600 Patienten mit Lippen- und/oder Gaumenspalten, unterteilt in drei Gruppen, je nach dem Typ der Missbildung, wurde die Häufigkeit der Hypodontie (mit der Ausnahme der dritten Molare) ermittelt.

Im Vergleich zur gesunden Population bestand ein starker Anstieg der Häufigkeit der Hypodontie bei Patienten mit Gesichtsspaltmissbildungen. Die höchsten perzentuellen Werte der Häufigkeit der Hypodontie bestand bei Patienten mit Lippen- und Gaumenspalten, die niedrigsten Werte wurden bei isolierten Lippenspalten verzeichnet. Bei Lippenspalten, und bei Lippen- und Gaumenspalten waren viel häufiger Mädchen betroffen, als Jungen. Bei isolierten Gaumenspalten konnte kein Unterschied zwischen beiden Geschlechten festgestellt werden. Die Häufigkeit der Hypodontie im Ober-mund im Unterkiefer war unterschiedlich und durch den Typ der Spaltmissbildung bedingt.

Bei der Lippenspalte und bei der Lippen- und Gaumenspalte war häufiger der Oberkiefer betroffen, bei einer isolierten Gaumanspalte der Unterkiefer.

Bei Lippen und Gaumenspalten fehlte am häufigsten die Anlage des zweiten oberen Schneidezahnes, bei isolierten Gaumenspalten die Anlage des unteren zweiten Prämolars.

Unsere Beobachtungen sind im Einverständnis mit den gegenwärtigen Erkenntnissen über die Anomalien der Dentition bei Lippen und/oder Gaumenspalten.

Key words: hypodontia, cleft lip and/or palate

The absence of dental germs or the occurence of supernumerous teeth of both deciduous and permanent dentitions are quite frequent anomalies in patients with facial clefts.

The aim of this study was to determine the frequency of hypodontia in permanent dentition in all groups of permanent teeth except for the third molars in all types of clefts, to compare the occurrence in boys and girls and with that in the normal general population.

MATERIAL AND METHOD

The series consisted of 600 children with cleft lip and/or palate, selected by randomization from children treated at our department. The whole series was subdivided into three groups according to the types of cleft. In the first group were 200 children (111 boys and 89 girls) with cleft lip or with cleft lip and jaw. The second group included 200 children (132 boys and 68 girls) with unilateral or bilateral cleft lip and palate. The third group consisted of 200 patients (93 boys and 107 girls) with isolated cleft palate. The age of the patients ranged from 11 to 14 years.

X-ray studies included orthopantograms of the upper and lower jaws for the determination of hypodontia inclusive of the cleft area in all patients with permanent teeth. The third molars were not assessed because of their inaccurate visua-

lization on X-ray films, in children within the above mentioned age groups.

The results of our study were tested with the t-test in order to disclose differences between two relative values. The controls were taken from the study published by Marková (1985).

RESULTS

Cleft lip (CL):

In this group hypodontia was present in 42 probands, i.e. in 21% (Tab. 1). As compared to the group of controls the increase of its frequency was highly significant (Tab. 6). Girls were affected more frequently (in 28%, at a $p < 0.05$ level) than boys (15%, Tab. 8). Anomalies of teeth in the upper jaw (19%) were much more frequent than in the lower jaw (4.5%, $p < 0.001$, Tab. 9).

The most frequently missing dental bud within the upper jaw was that of the lateral incisor (in 17.5%) while in the lower jaw it was the bud of the second premolar (3.5%, Tabs. 4 and 5). The teeth belonging within several morphological groups were involved only in 2%.

Cleft lip and palate (CLP):

In this group hypodontia was present in 59 individuals, i.e. in 29.5% (Tab. 2). As compared to the group of controls the difference attained a high significance level (Tab. 6).

Girls were again more frequently affected (39.5%) than boys (24.2%, $p< 0.05$, Tab. 8). Hypodontia was more common in the upper jaw (in 26.5%) as compared to the lower jaw (4.5%, $p < 0.001$, Tab. 9).

In the upper jaw was equally most frequently affected the dental bud of the lateral incisor (22.5%) and the second premolar (6%) while in the lower jaw it was the second premolar (4.5%, Tabs. 4 and 5). Tooth buds belonging into several morphologic classes were missing in 6% of the patients.

Isolated cleft palate (CP):

In this group hypodontia occured in 48 children i.e. in 24%. As compared to controls the difference was highly significant (Tab. 6). In this type of cleft the frequency of hypodontia in girls did not exceed its occurrence in boys (24.5% and 23.5%, Tab. 8). In contrast to both above mentioned groups hypodontia was present more commonly in the lower jaw (17%) than in the upper jaw (10%, $p < 0.05$, Tab. 9).

In a permanent dentition the most often affected teeth were the second lower premolar (14%) and the lateral upper incisor (10%, Tabs. 4 and 5).

The teeth belonging into more morphologic groups were affected simultaneously in 3% of individuals examined.

Tab. 1. Frequency of hypodontia in patients with cleft lip (± alveolus)

Hypodontia	Boys		Girls		Total	
	n	%	n	%	n	%
Total	17	15.0	25	28.0	42	21.0
Maxilla only	15	13.4	18	20.0	33	16.5
Mandible only	1	0.8	3	3.5	4	2.0
Both jaws	1	0.8	4	4.5	5	2.5
Maxilla total	16	14.2	22	24.5	38	19.0
Mandible total	2	1.6	7	8.0	9	4.5

Tab. 2. Frequency of hypodontia in patients with cleft lip and palate (unilateral or bilateral)

Hypodontia	Boys		Girls		Total	
	n	%	n	%	n	%
Total	32	24.2	27	39.5	59	29.5
Maxilla only	25	19.0	25	36.5	50	25.0
Mandible only	5	3.7	1	1.5	6	3.0
Both jaws	2	1.5	1	1.5	3	1.5
Maxilla total	27	20.5	26	38.0	53	26.5
Mandible total	7	5.2	2	3.0	9	4.5

Tab. 3. Frequency of hypodontia in patients with isolated cleft palate

Hypodontia	Boys		Girls		Total	
	n	%	n	%	n	%
Total	22	23.5	26	24.5	48	24.0
Maxilla only	7	7.5	7	6.5	14	7.0
Mandible only	10	10.5	18	17.0	28	14.0
Both jaws	5	5.5	1	1.0	6	3.0
Maxilla total	12	13.0	8	7.5	20	10.0
Mandible total	15	16.0	19	18.0	34	17.0

Tab. 4. Frequency of hypodontia of individual teeth within the maxilla

Types of teeth	CL		CLP		CP	
	n	%	n	%	n	%
Central incisor	0	0	2	1.0	1	0.5
Lateral incisor	35	17.5	45	22.5	20	10.0
Canine	0	0	0	0	0	0
First premolar	0	0	1	0.5	0	0
Second premolar	6	3.0	12	6.0	1	0.5
First molar	0	0	0	0	1	0.5
Second molar	0	0	0	0	1	0.5

Tab. 5. Frequency of hypodontia of individual teeth within the mandible

Types of teeth	CL		CLP		CP	
	n	%	n	%	n	%
Central incisor	1	0.5	1	0.5	3	1.5
Lateral incisor	1	0.5	1	0.5	4	2.0
Canine	0	0	0	0	1	0.5
First premolar	0	0	1	0.5	1	0.5
Second premolar	7	3.5	9	4.5	28	14.0
First molar	0	0	0	0	1	0.5
Second molar	0	0	0	0	2	1.0

Tab. 6. Frequency of hypodontia (%) in individual types of clefts as compared to controls

		Cleft	Controls*		
CL	Boys	15.0	5.9	t = 3.00	p < 0.01
	Girls	28.0	7.1	t = 5.15	p < 0.001
	Total	21.0	6.5	t = 5.81	p < 0.001
CLP	Boys	24.2	5.9	t = 5.70	p < 0.001
	Girls	39.5	7.1	t = 6.49	p < 0.001
	Total	29.5	6.5	t = 8.42	p < 0.001
CP	Boys	23.5	5.9	t = 4.75	p < 0.001
	Girls	24.5	7.1	t = 4.82	p < 0.001
	Total	24.0	6.5	t = 6.77	p< 0.001

* Marková (1985)

Tab. 7. Comparison of frequency of hypodontia (in %) in individual types of clefts

CLP vs. CL	29.5	21.0	t = 1.96	p = 0.05
CLP vs. CP	29.5	24.0	insign	
CP vs. CL	24.0	21.0	insign	

Tab. 8. Frequency of hypodontia in boys and girls (in %)

	Boys	Girls		
CL	15.0	28.0	t = 2.25	p < 0.05
CLP	24.2	39.5	t = 2.25	p < 0.05
CP	23.5	24.5	insign	

Tab. 9. Frequency of hypodontia in the upper and the lower jaw (in %)

	Maxilla	Mandible		
CL	19.0	4.5	t = 4.74	p < 0.001
CLP	26.5	4.5	t = 6.54	p < 0.001
CP	10.0	17.0	t = 2.06	p < 0.05

DISCUSSION

The present study was aimed at the verification of the increased frequency of hypodontia in patients with facial clefts as compared to the normal general population, as well as at the differences in the occurrence of dental anomalies in individual types of clefts. The lowest percentage of hypodontia was recorded in patients with cleft lip (21%). According to Ranta (1977) it amounted to 29% in the Finish population.

In the group of patients with cleft lip, jaw and palate (cheilognathopalatoschisis) dental buds were missing in 29.5% of cases. This value was lower than that reported by Ranta (1977) in the Finish population (72%). This difference could be partly due to the differing range of age in the group reported by Ranta. X-ray films made in patients younger than 8 years cannot eliminate a certain misinterpretation of the results obtained because a missing bud of the second premolar can be visualized on X-ray films only after the age of 8 years. Another factor could represent the distinct etiologic background of clefts in the Finish population, as it was suggested by the distinct relative distribution of individual types of clefts in the Finish population. In contrast to other European countries the most frequent type represents an isolated cleft palate (Ranta 1977). It cannot be excluded that this factor plays an important role in the origin of hypodontia.

The most frequently absent tooth bud in cleft lip and in cleft lip and palate is that of the second upper incisor. The frequency of this anomaly ranged from 17.5% to 22.5% as compared to the normal general population where the frequency varies from 1 to 2%.

Hypodontia was much more common in girls with cleft lip, or with cleft lip and palate. Marková (1985) equally reported more frequent anomalies in females (7.1%) then in males (5.9%) in the normal general population.

The impaired development of the second upper incisor was interpreted as due to the vicinity of cleft. Yet the canine situated on the other side of the cleft was only very rarely affected. We failed to disclose a missing upper canine in our series of 600 individuals. The anomaly of the upper lateral incisor was probably due to different causes. It was described in the literature that the dental lamina was formed by 3 different sections. Incisiform, caniniform and molariform teeth differ in shape, by the position of their buds and by the periods of their development. According to the theory of morphogenetic systems the most distal situated buds of individual parts of the dental ridge are primarily exposed to a teratogenic damage (Peterka, 1979). The results obtained in our series of patients with facial clefts are in agreement with the proposed theory.

The frequent missing of the second upper incisor could be due to some additional factors. This tooth develops partly also from the maxillary ectomesenchyme (Peterková, personal communication). Therefore in patients with facial clefts this tooth is often double and is situated on both sides of the cleft jaw. Often it can be disclosed only on the maxillary side (Ross and Johnston, 1972). On the basis of this observation it is possible to anticipate a frequent missing of the upper lateral incisor on the cleft side in patients with clefts.

Burian (1954) suggested that it could be also caused by a deficient vascular supply to this area. Aa. alveolares cannot bridge the cleft in the premaxilla and the dental buds are supplied by the small a. pterygopalatina.

The missing single lateral upper incisor is more frequent in patients with cleft lip where the alternation occurred in the period of integration of facial processes. A more common missing of dental buds was observed equally in other parts of the maxillary dental ridge in patients with cleft lip and palate which developed after a stronger teratogenic impulse. The second premolar in the

second segment and the third molar in the third segment (data from the literature) were more frequently absent (Ranta, 1977, reported a missing third molar in 34.2%).

The group of patients with isolated cleft palate differed from the other groups by a more frequent hypodontia in the lower jaw. The second lower premolar was the most commonly affected tooth.

It was proved in experiments on animals that an isolated cleft palate could be caused during the embryogenesis by a deficient development of the mandibular anlage within the third critical period (Jelínek et al., 1983). This results that above the tongue within the primitive oral cavity is not avaiable a sufficient space for the horizontalisation of the palatal plates which represents the prerequisity for their fusion into the secondary palate (Jelínek et al., 1983). Simultaneously with the alteration of the mandible could take place a damage to the dental ridge from which originate individual dental buds. These observations were in agreement with experimental data.

Craniometric studies suggest that in an isolated cleft palate the mandible was the smaller and shorter, the slighter the severity of cleft palate and the later it developed (Šmahel, 1986). The anomalies of teeth are in agreement with this observation. In total clefts hypodontia was recorded in 13.3%, while in isolated cleft palate it was present in 19.5% of individuals (Jiroutová, 1991).

Our observations are in agreement with the present knowledge on the impaired development of dentition in facial clefts.

REFERENCES

1. Burian, F.: Chirurgie rozštěpů rtu a patra, SZN Praha, 1954.
2. Hellquist, R., Linder-Aronson, S., et al.: Dental abnormalities in patients with alveolar clefts, operated upon with or without primary periosteoplasty. Eur. J. Orthod., 1: 169-180, 1979.
3. Jelínek, R., Dostál, M., Peterka, M.: Rozštěp rtu a patra v obraze experimentu. UK Praha, 1983.
4. Jiroutová, O.: Hypodontia in patients with isolated cleft palate, its relationship to etiopathogenesis. Acta Chir. Plast., 33: 57-63, 1991.
5. Marková, M., Taichmanová, Z.: Incidence of orthodontic anomalies in school children in Prague 10. Acta Univ. Carol. Med., 31: 415-433, 1985.
6. Olin., W. H.: Dental anomalies in cleft lip and cleft palate patients. Angle Orthod., 34: 119-123, 1964.
7. Peterka, M.: Prenatální růst a poškození orofaciálního komlexu. Thesis, Praha, 1979.
8. Ranta, R.: A comparative study of frequency of hypodontia in children with cleft lip and/or palate. 3rd Int. Congress of Cleft Palate and Related Craniofacial Anomalies. Abst. No.120, Toronto, Canada, 1977.
9. Ranta, R.: A review of tooth formation in children with cleft lip and palate. Am. J. Orthod. Dentofac. Orthop., 90: 11-18, 1986.
10. Ranta, R.: Correlations of hypodontia in children with isolated cleft palate. Cleft Palate J., 20: 163-165, 1983.
11. Ross, R. B., Johnston, M. C.: Cleft lip and palate. The Williams and Wilkins Comp., Baltimore, 1972.
12. Sládková, M.: Genetické aspekty hypodoncie. Thesis, Praha, 1987.
13. Šmahel, Z.: Kraniofaciální změny při jednostranném rozštěpu rtu a patra v dospělém věku. Čs. Stomat., 85: 217-230, 1985.
14. Šmahel, Z.: Kraniofaciální změny při isolovaném rozštěpu patra v dospělém věku. Čs. Stomat., 86: 393-409, 1986.
15. Weise, W., Erdmann, P.: Anomalien der Zahnzahl und Zahnform im bleibenden Gebiss bei Lippen-Kiefer-Gaumen-Splaten. Zahnaertzl. Rundsch., 76: 357-372, 1967.

Address for correspondence: O. Jiroutová,
Šrobárova 50,
100 34 Prague 10,
Czech Republic

For those who wish to submit colour photodocumentation:

Use preferably photographs, sharp, of high quality only, optimal size 10 x 15 cm, max. 21 x 15 cm. For further details, see Instructions to the Authors, p.29. Slides are also accepted. Slides should be unframed, each in an individual envelope marked with the name of the author and the Fig. number. Graphs in colours are not accepted in any form.

Colour documentation is reproduced free of charge. Please remember that the reproduction is expensive and use colour photographs or slides only in case they are really important for the article submitted.

ACTA CHIRURGIAE PLASTICAE 36, 2, 1994, pp. 57 - 60

EARLY ENTERAL NUTRITION IN SEVERE BURNS

J. Koller, K. Kvalténi

Burns Department, NsP Ružinov, Bratislava, Slovakia

SUMMARY

The method of early enteral nutrition (EEN) in extensively burned patients was started at the Bratislava Burns Department in January 1992. EEN was instituted in all patients with burns exceeding 20% of the BSA who were admitted to the department not later than 6 hours post burn. The nutrition itself was started with administration of milk, and later on, if good tolerance was observed, the milk was replaced by standard tube feeding formulas. The feeding was adjusted to the actual needs of the individual patients according to nutritional balance calculations and regular control of the patients' weights.

During a period of 18 months 20 patients met the criteria for EEN. Twelve of them survived and 8 died due to complications of extensive burns. The overall tolerance of EEN was very good in both the survivors and nonsurvivors groups of patients. EEN proved to be safe and effective in maintaining nutritional balance of the patients and eliminating particularly the occurence of Curling's ulcers.

ZUSAMMENFASSUNG

Die enterale Frühernährung bei schweren Verbrennungen

J. Koller, K. Kvalténi

Die Methode der enteralen Frühernährung (EFE) bei Patienten mit ausgedehnten Verbrennungen wurde in Bratislava an der Abteilung für Verbrennungen im Januar 1992 eingeleitet. Diese Ernährung erwies wurde bei alien Kranken mit Verbrennungen von mehr als 20% der Körperoberfläche verabreicht, die an die Klinik binnen 6 Stunden nach der Verbrennung eingeliefert wurden. Den Patienten wurde zuerst Milch verabreicht und im Falle dass eine gute Verträglichkeit von Milch beobachtet werden konnte, folgte später die übliche künstliche Ernährung. Die Verabreichung der Nährung wurde den individuellen Bedürfnissen angepasst, je nach den Berechnungen des nutritionellen Gleichgewichtes und durch regelmässige Kontrollen des Körpergewichtes der Patienten.

Im Laufe von 18 Monaten entsprachen 20 Patienten den Kriterien für die Verabreichung dieser Ernährung. Von ihnen überlebten 12 Kranke, 8 kamen ad exitum infolge schwerer Komplikationen der ausgedehnten Verbrennungen. Insgesamt war die Toleranz der enteralen Frühernährung sehr gut, sowohl bei den überlebenden wie auch bei den nicht überlebenden Patienten. Diese Ernährung erwies sich als wirksam zur Erhaltung des nutritionellen Gleichgewichtes und war wirksam in der Vorbeugung der Curlingschen Ulzeration.

Key words: burns, gastrointestinal reaction, nutritional balance

It was less than 20 years ago, when the importance of nutrition in burn injury began to be appreciated by burn surgeons. Alexander et al.(1980) in a group of patients with thermal injuries exceeding 50% of the BSA who survived the initial 5 days of hospitalization and who were fed continually with aggressive tube feeding, found an approximate 80% drop of mortality from septicemia and burn wound sepsis. The usual approach was to start enteral feeding after the shock period when the vital signs of the patients have stabilized. The reason for not starting enteral feeding immediately after burn was the belief that the hemodynamic and cardiopulmonary aspects of burn care took priority over achieving nutritional balance in the first week after burn. This concept no longer appears valid. Instead of it appears, that immediate enteral feeding after burn may improve patient outcome not just by providing nutrients but by helping to maintain intestinal barrier function, preventing bacterial translocation, and increasing the host's ability to control a septic challenge (McDonald et al., 1991, Alexander and Gottschlich, 1990).

The concept, that immediate post-burn enteral feeding may be beneficial, was first shown experimentally by Alexander's group. They documented, that early enteral, but not parenteral feeding of burned animals can attenuate markedly the hypermetabolic response to thermal injury (Mochizuki et al.,1985). Furthermore Kudsk et al. (1983) documented, that animals fed enterally, survive a septic insult better than those fed with the same nutrients parenterally. A study in severely burned patients performed by Alexander's group (1980) also revealed, that patients fed immediately after burn injury compared to those with delayed feeding have a reduced incidence of

diarrhea and infection as well as improvements in total serum proteins, albumin, ceruloplasmin, and IgG measured 7 days postburn.

Based on these findings, we started with the method of early enteral nutrition (EEN) in extensively burned patients admitted to the Bratislava Burns Department in January 1992.

MATERIAL AND METHODS

Tab. 1. Early enteral nutrition inclusion criteria

admission time:	< 6 hours post burn
TBSAB:	> 20%
bowel sounds:	present
nausea: 0	vomiting: 0

TBSAB = Total Body Surface Area Burn

EEN (Tab. 1) was instituted in all patients with burns exceeding 20% of the BSA who were admitted primarily to our department, i.e. who arrived not later than 6 hours post burn. The first measures were insertion of i.v. lines, fluid replacement therapy, insertion of urinary catheter, primary wound care, and insertion of a nasogastric tube.

Tab. 2. Early enteral nutrition (adults)

1st 24 hours:	milk 80 - 120 ml every 2 hours
24 - 48 hours:	milk 200 ml every 2 hours
> 48 hours:	tube formula 150 - 250 ml*/2 h

* according to calculated energetic needs

The nutrition itself (Tab. 2) was started with application of milk in quantities from 80 - 120 ml every two hours during the first 24 hours. Later on, if good tolerance was observed, the doses were gradually increased to 200 ml every 2 hours. Beginning with the day 2 post burn milk was replaced by standard tube feeding formulas on the base of milk proteins with glycids and fat. Currently we use 5 types of tube feeding formulas which differ in proportion of the nutrient components and energetic value per ml. The average energy content is 4.2 kJ/ml.

Before each application of the feeding bolus the residual gastric content is aspirated and measured. Starting from the day 3 post burn, if the patient is lucid and cooperative, he is allowed to eat normal nutrient diet food. In these cases the enteral feeding is supplementary to achieve the calculated energy and protein requirments.

The preburn weight of the patients is recorded, and later on the patient's weight is checked at least twice a week. The nitrogen balance is calculated daily.

The actual energetic needs of the patients are initially calculated according to Curreri's formula (Tab. 3). The data obtained are used only as a guide when the feeding starts. The feeding is than adjusted to the actual needs of the individual patients from nutritional balance calculations and regular control of the patient's weight (Tab. 4).

Tab. 3. Curreri's formula

Adult
100 kJ/kg + 170 kJ/% BSAB

Child
x* kJ/kg + 170 kJ/% BSAB

(x* = 420 kJ/kg at the age of 1 year decreasing to 100 kJ/kg at the age of 15 years)

BSAB = Body Surface Area Burn

Tab. 4. Nitrogen balance

Balance = Intake - Output

Intake
protein intake (g)/6.25

Output
urea (urine, mmol)/24 h. x 0.0336 + losses through skin*

* skin losses: 4x [(0.2 g x % III°BSAB) + (0.1 g x % II°BSAB)]

The signs of intolerance were dealed with as follows. If severe nausea and/or vomiting occurred, the next feeding dose was reduced, or omitted. Intolerance was stated, when during two consecutive days the amount of aspirates was equal, or greater, than the amount administered. In these cases the nutrition had to be changed to total parenteral one until the functions of the GIT returned to normal.

Tab. 5. Criteria of sepsis

Clinical criteria	
Sensorium	lethargic, confused, coma
Temperature	below 36.5°C, or above 39 °C
Respiratory rate	40/min.
G. I. symptoms	nausea, vomiting, diarrhoe, gastric and/or bowel paralysis
Blood pressure	more than 20% fall
Oliguria	present, specific gravity low
Wound appearance	pale, wet, foul smelling, pus, breakdown of healed areas
Laboratory criteria	
White blood cell count	< 5000, or > 20000
Platelet count	< 150 000
Hemoglobin	progressive anemia
Blood culture	repeatedly positive
Urea (blood)	> 10 mmol/l
Nitrogen balance	turned to negative
pAO_2	< 8 kPa
Skin biopsy culture	> 10^5 m.o./g tissue, same microorganism as in blood
Chest x-ray	signs of pneumonia, or ARDS
Signs of DIC	present

At least three positive criteria in each group must be present.

The signs of sepsis were assessed according to criteria, which are displayed on Table 5. Sepsis was found to be present, if at least three clinical and three laboratory criteria were positive.

RESULTS

During a period of 18 months 20 patients (Tab. 6) met the criteria for early enteral feeding. The age of the patients was at a range of 1 to 74 years. The extent of burns varied between 18% and 80% of the BSA.

According to the outcome we divided the patients into the groups of survivors nad non-survivors. All the patients received fluid resuscitation according to Parkland formula during the first 48 hours. In patients with deep anesthetic burns early surgical excisions of the burn eschar were performed starting preferably not later than 48 hours after the injury. The excised areas were covered by autografts whenever they were available. Only in very extensive burns, or in burns, where the excision could not be performed properly, temporary skin substitutes were used, mostly human allografts.

There were 8 patients in the non-survivors group with a mean age of 47.1 years, mean TBSAB of 45%, and mean 29.1% full thickness skin loss. In all of the patients except one the survival probability was less than 10% due to their age and/or extent of burns. The only exemption was a 41 years old man, who was a prison inmate committing suicide by igniting his clothes soaked by gasoline. He suffered burns of 25% of the BSA with 20% BSA full thickness injury and inhalation injury. He died on day 4 post burn due to DIC, renal failure and ARDS. The enteral nutrition tolerance was good in all but two patients with very extensive burns, who died within 24 hours post burn due to delayed beginning of replacement therapy, inhalation injury and shock. Sepsis was observed in two cases with relatively delayed onset.

In 12 patients of the survivor's group the mean age was 22.5 years and the mean BSAB 34.3% with a range from 18% to 65%. Sepsis was observed only in one patient - a 2 years old girl with 30% burns and 29% BSA being full thickness loss. The overal tolerance of the enteral feeding was in all patients very good. The most common complication of the feeding was diarrhoea observed in about 1/3 of the cases. To stop the diarrhoea it was usually necessary to change the enteral feeding formula and to normalize the enteral flora with medicaments containing bacterial cultures (Bactisubtil, Hylacombun).

In summary, early enteral feeding in our patients proved to be safe and effective. Because of the big differences in the two groups pertaining the age, extent, and depth of burns, no statistical evaluation could be done.

Tab. 6. Early enteral nutrition group

Initials	Age y	TBSA %	BSAIII° %	INH inj.	Sepsis	Death PBD	Cause	EEN tolerance
NONSURVIVORS (N=8)								
A.M.	72	35	35	+	+	9	RF, PN	+
F.K.	36	67	55	++	-	1	shock	-
I.O.	56	28	5	-	-	15	RF,HF,DTr.	+
F.H.	74	19	19	-	-	19	pneumonia	+
T.T.(idiot)	45	31.5	17.5	-	-	26	pneumonia	+
M.S.	41	25	20	+	-	4	RF,DIC,ARDS	+
J.B.	31	80	75	++	-	1	shock	-
M.M.	22	67	67	+	+	15	RF,PN,ARDS	+
Mean	47.1	45	29.1	5	2	11.2		
SURVIVORS (N=12)								
						LOS days	Complications	
D.T.	48	41	38	++	-	81	ARDS, pneumonia	+
K.M.	7	21	-	-	-	6		+
B.A.	12	44.5	13.5	-	-	71	delayed healing	+
M.K.	1	42	15	-	-	64		+
J.N.	35	34	-	-	-	21		+
L.D.	42	65	30	-	-	7+	transferred Romania	+
K.H.	12	45	25	-	-	40		+
J.P.	2	18	10	-	-	16	PN,IRDS	+
G.J.	39	24.5	5.5	+	-	42		+
Š.A.	49	35.5	11	-	-	43		+
Z.A.	22	39	12	-	-	30	pregnancy	+
Z.S.	2	30	29	-	+	58		+
Mean	22.5	34.3	13.5	2	1	39.25		

RF = renal failure, PN = pneumonia, HF = hepatal failure, DTr = delirium tr., ARDS = adult respiratory distress syndrome, IRDS = infant respiratory distress sy., INH = inhalation injury, PBD = post burn day, LOS = length of stay, DIC = diffuse intravascular coagualation sy.

DISCUSSION

As early as in 1974 Levine et al. showed, that enteral nutrition is superior to parenteral in maintaining gastrointestinal mass and function because the weight, mucosal height, mucosal protein and DNA content, as well as enzymatic activity of the intestines, decreased in parenterally fed animals. Studies in human published by Deitch (1990) documented, that intestinal barrier function is lost immediately after burn as well as during periods of sepsis. Early enteral nutrition helps to maintain the normal function of the gastrointestinal tract under these circumstances. In conditions in which gastrointestinal mucosal growth is required, such as after massive small bowel resections, enteral feeding is more effective in stimulating mucosal growth and functional adaptation than the same nutrients administered parenterally (Levine et al.,1976). Survival from

bacterial peritonitis was greater in enterally repleted than in parenterally repleted malnourished rats (Petersen et al., 1984). Enteral nutrients appear to exert a trophic effect on intestinal morphology and function that is not observed with standard hyperalimentation solutins. Early enteral feeding also prevented the occurrence of Curling's ulcers and gastrointestinal bleeding and eliminated the need of antacids and H_2 blockers (Choctaw et al., 1980). Extensive use of these drugs may result in alkalinisation of the stomach which may have deleterious effects such as bacterial colonization of the stomach which then may serve as a reservoir for various bacteria. Optimal diets for nutritional support of burn patients contain 20% of energy from whey protein, 2% from arginine, 0.5% from cysteine, and 0.5% from histidine (Gottschlich et al.,1990). Lipids comprise 15% of nonprotein calories with 50% fish oil (rich on omega-3 fatty acids) and 50% safflower oil (rich on linoleic acid). In a prospective clinical study, administration of this diet was found to reduce wound infection, shorten hospital stay, and reduce death (Alexander and Gottschlich, 1990).

In our limited experience with early enteral feeding it was shown, that early feeding is safe and effective. We observed a very good tolerance, a decrease of stress ulcerations and a virtual elimination of bleeding from the GIT. We also feel that the rate of systemic infections and sepsis was reduced, although we could not as yet prove it statistically.

REFERENCES

1. Alexander, J. W., MacMillan, B. G., Stinett, J. D. et al.: Beneficial effects of aggressive protein feeding in severely burned children. Ann. Surg., 192: 505-517, 1980.
2. Alexander, J. W., Gottschlich, M. M.: Nutritional immunomodulation in burn patients. Critical Care Medicine, 18: S149-S153, 1990.
3. Choctaw, W. T., Fujita, C., Zawacki, B. E.: Prevention of gastrointestinal bleeding in burn patients. Arch. Surg., 115: 1073-1076, 1980.
4. Deitch, E. A.: Intestinal permeability is increased in burn patients shortly after injury. Surgery, 107: 411-416, 1990.
5. Gottschlich, M. M., Jenkins, M. J., Warden, G. D.: Differential effects of three enteral dietary regimens on selected outcome variables in burn patients. JPEN, 14: 225-236, 1990.
6. Kudsk, K. A., Stone, J. M., Carpenter, G., Sheldon, G.:Enteral and parenteral feeding influences mortality after hemoglobin E. coli peritonitis in normal rats. J. Trauma, 23: 605-609, 1983.
7. Levine, G. M., Deren, J. J., Steiger, E. T.: Role of oral intake in maintenance of gut mass and disaccharide activity. Gastroenterology, 67: 975-982, 1974.
8. Levine, G. M., Deren, J. J., Yezdimir, E.: Small bowel resection: oral intake is the stimulus for hyperplasia. Am. J. Dig. Dis., 21: 542-546, 1976.
9. McDonald, W. S., Sharp, C. W., Deitch, E. A.: Immediate enteral feeding in burn patients is safe and effective. Ann. Surg., 213: 177-183, 1991.
10. Mochizuki, H., Trocki, O., Dominioni, L., Alexander, J. W.: Reduction of postburn hypermetabolism by early enteral feeding. Current Surgery, 42: 121-125, 1985.
11. Petersen, S. R., Kudsk, K. A., Carpentier, G.: Malnutrition and immunocompetence increased mortality following an infectious challenge during hyperalimentation. J. Trauma, 21: 528-533, 1984.

Address for correspondence: Ján Koller,
NsP Ružinov,
826 06 Bratislava,
Slovakia

For those who prefer to submit their papers on a diskette:

Both 3 1/2" and 5 1/4" diskettes are accepted. Use WORD (DOS), version 5.0 and higher, or WINWORD text editor, only. In WINWORD, cancel automatic SAVE before you start writing. Write doublespaced (max.30 lines per page), do not underline, do not change typesizes, do not indent. New paragraph should be marked only by ENTER on a previous line. Do not create Tables, write them only as a text. Each diskette must be prevented from accidental erasing and accompanied by a printed text, in which you can underline and mark the desired shape of Tables. Due to increasing postage, diskettes are not returned to the authors.

ACTA CHIRURGIAE PLASTICAE 36, 2, 1994, pp. 61 - 63

LIPOMATOSIS BENIGNA SYMMETRICA - SYNDROM LAUNOIS-BENSAUDE (Case report)

M. Dušková, H. Topinka

SUMMARY

Forty years old patient with benign symmetric lipomatosis Launois-Bensaude was treated by liposuction of shoulders, arm, thighs and buttock made in stages. About 1200 ml of tissue were removed on average with no need of blood loss compensation. Good functional and cosmetic effect was achieved. The average duration of full remission was 10 months, then the relaps have been slowly recoming.

ZUSAMMENFASSUNG

Lipomatosis benigna symmetrica - Launois Bensaude Syndrom (Kasuistik)

M. Dušková, H. Topinka

Ein vierzigjähriger Patient mit einer gutarticen symmetrischen Lipomatose (Launois-Bensaude Syndrom) wurde in Etappen mittels einer Aussaugung des Fettgewebes an den Schultern, Armen, Schenkeln und Gesässbacken behandelt. Durchschnittlich wurden 12000 ml Fettgewebes ausgesaugt ohne die Nötigkeit eines Ersatzes des damit verbundenen Blutverlustes. Es wurde ein guter funktioneller un kosmetischer Erfolg erreicht. Die durchschnittliche Dauer der Remission betrug 10 Monate. Das Risiko von lokalen Rezidiven ist jedoch ziemlich hoch.

Key words: benign symmetric lipomatosis, Launois-Bensaude, liposuction

At first this very rare disease was mentioned by Benjamin Brodie in 1846 and syndrom was specified by Launois and Bensaude in 1888.

Ethipathogenesis is unknown, relations to the metabolic defects of hyperlipemia type IV., hyperurikemia, diabetes mellitus and alcoholism are discussed.

It is often associated with hepatopthy, peripheral neuropathy and macrocytal anaemia which are probably caused by alcoholism. There is a higher risk of oropharyngeal carcinoma development. Specific type of heredity was not found even if familiar cummulation is noticeable. One of the latest hypothesis assumes the defects in lipolysis being caused by mitochondrial disturbance in the brown fat, that is similarly distributed as the typical lipomatous deposits in the body and contains a lot of mitochondrias. The alcohol abuse is a trigger moment for manifestation of the defect.

Madelung's cervical lipomatosis is considered either a different variety of this disease or a quite different one. Launois-Bensaude syndrom affects mainly the men (in the ratio 30: 1) in age at range from 20 to 50 years.

Next differential diagnosis is lipomatosis dolorosa Decrum, characterised by the painful affections and by incidence mainly among women during menopause. The real multiple lipomas can occur elsewhere, are capsulated and therefore palpable as single tumours.

Launois-Bensaude syndrom is typical by a pseudoathletic outlook with diffuse unpainfull tumorous hypertrophy of pasty or elastic fat in the area of neck (so called bull protuberance), arms (especially the upper parts including the axilae), then the lateral parts of the body. Sometimes the flexor parts of the thighs are affected.

The treatment is only surgical, either by excision of superfluous tissue or by liposuction. An extreme intervention using the liposuction method usually is not recommended because of the tissue's relation to blood vessels. A frequent coincidence with hepatopathy and anaemia increases the bleeding time even more.

Frequent relapses with no relation to the used method are mostly reported. Up till now about two hundred cases of this syndrom have been completely reported.

A CASE REPORT

Forty-year old patient was repeatedly hospitalised at the Department of Plastic and Reconstructive Surgery in Prague for benign symmetric lipomatosis. From the family history: Father died of leukaemia, mother still lives, treated for arthrosis, osteoporosis and diabetes mellitus, one of

the brothers died of a head trauma, the other died of stomach carcinoma, the third one suffers from ischaemic heart disease. From the patient's history: meningitis in six years, cerebral commotion in twelve years, ulcus duodeni with haematemesis, pollinosis. He used to smoke from ten to twenty cigarettes a day on 25 years and to drink about three litres of beer a day. He worked as a casual mechanic, now he is receiving disability pension because of complications connected with current illness.

Since 30 years of age progressive hypertrophy of lateral parts of arms, thighs and the neck, attended with reduction of movement extent together with paresthesias both in stress and in ease and general muscle fatigue has occured. He is not able to repeat a large extent of movements (e.g. knees bend and raising, streching arms upwards and sideways). An easy origin of haematomas.

Status praesens:

Pseudoathletic outlook with excessive hypertrophy of the subcutaneous fat tissue of the neck, shoulder, lateral arms, lateral parts of the body and thighs. The skin is both hypesthetic and hyperesthetic with good capillary return and with noticeable net of subcutaneous blood vessels.

The complex diagnostic and presurgical investigations were established at the II. Department of Dermatology and included: X-ray of chest, X-ray of sella turcica, X-ray of shoulders and coxae (spina bifida), X-ray of oesophagus, X-ray elimination urography, ultrasound examination of abdomen (chronic right-side nephropathy), ultrasound subcutaneous examination (37-42 mm in the arms, 30-33 mm in the thighs), visceral fat not being enlarged.

Oesophagogastroduodenoscopy: a slight bulbitis, colonoscopy: chronic rift of the anal canal, outside haemorhoids, subcutaneous histology: normal fat tissue, EKG, blood pressure, stress test, EMG of the extremities, FW, blood count - the red blood count at the lower normality borderline, lymphocytosis, urine, RRR, TPH, glycaemia, faeces for the presence of bleeding, mineralogram (Na, K, Fe, Ca, P, Mg), urea and creatinine levels in serum, cholesterol, triacylglycerols, HBSAg, Paul Bunnel reaction, CRP, imunoelfo - the increase of IgA, bilirubin, ALT (1.21), AST (1.05), ALP (1.93), GMT, CK, glomerular filtration (1.06), resorbtion (0.984), T3, T4, TSH (9.9), EBV antibodies - marked increase of IgG: alfa 1, antitrypsin, transferin, prealbumin, alfa 2 macroglobulin, orosomukoid, INR, APTT, fibrinogen,direct skin immunofluorescence, serum level of insulin, serum level of cortisol. If not explicity written up all the results are within normal borders.

Complex diagnostic and therapeutic conclusion:

Benign symmetric lipomatosis Launois-Bensaude

Hepatopathy v.s. of ethyl origin

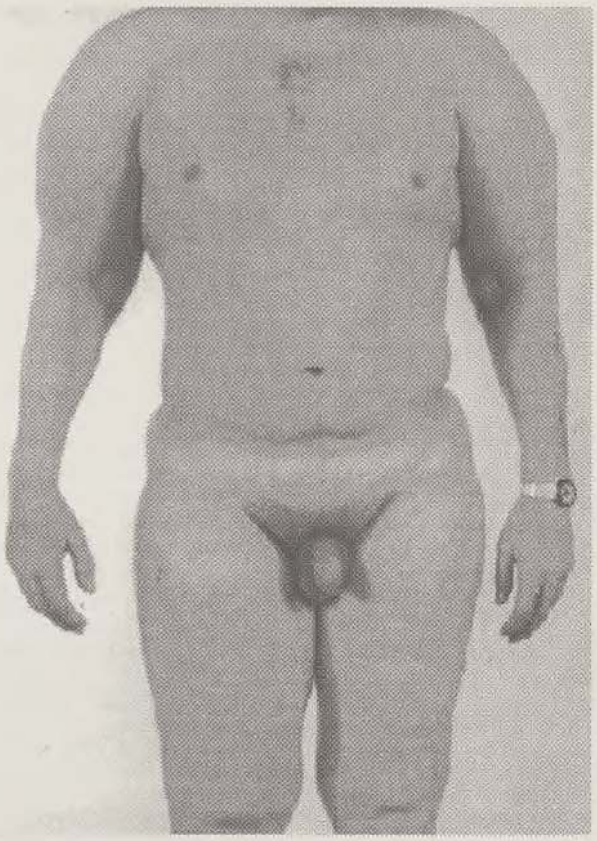

Fig. 1 a. Presurgical state

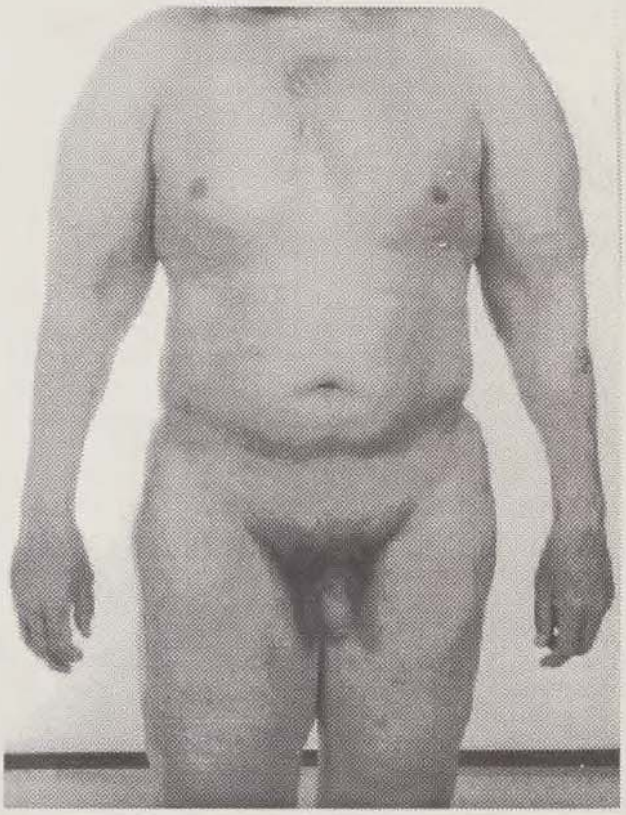

Fig. 1 b. Postsurgical state

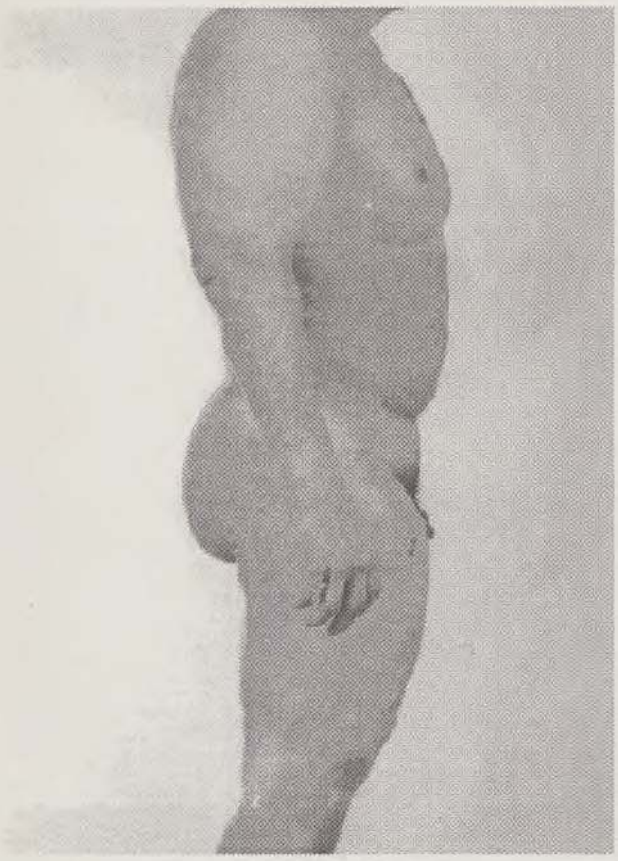

Fig. 2 a. Presurgical state

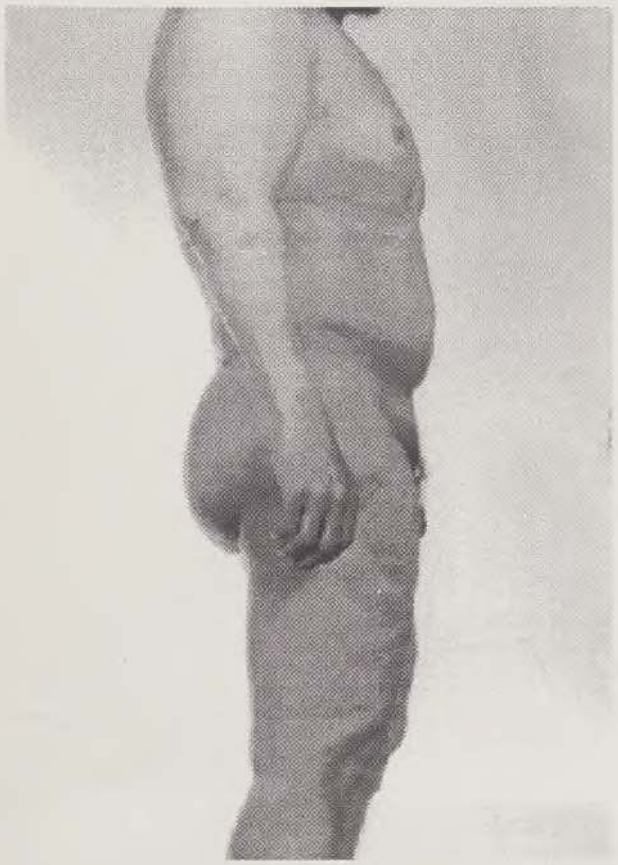

Fig. 2 b. Postsurgical state

Anaemia attending chronic hepatopathy v.s.
Chronic right-side pyelonephritis
Spina bifida
Ulcus bulbi duodeni with haematemesis in case history
Outside haemorhoids and anal fissure
Status after cerebral commotion
Status after meningitis
Recommended: liver diet, Lipovitan 3 x 1, Aviril H supp., surgical solution of lipomatosis.

The surgical approach was a four stages liposuction (left thigh, right thigh, both arms, both buttocks).

From 990 till 1500 ml of the tissue were removed every surgery. The antibiotics (cephalosporins) were used as a prophylactics, there was no need to compensate the blood loss. No drains were applied. A compressive bandage was applied immediately after the surgery. Marked signs of bleeding have not been noticed. The healing was without complications every time. The period between single stages was six weeks on average. Satisfactory functional and cosmetic effects were achieved.

The effect of therapy was controlled by precise measurement of the extremity circumference.

The average duration of remission was ten months, then the gradual growth of lipomatose tissue has been occurring. The next liposuction is planned if function difficulties origin.

REFERENCES

1. Badran, H. A., Kodeara, K. Z., Mabrouk, M. H.: Blood conservation in massive suction lipectomy. Plast. Reconstr. Surg., 92: 1298-1304, 1993.
2. Basse, P., Lohman, M., Hovgard, C., Alsbjorn, B.: Multiple symmetric lipomatosis: combined surgical treatment and liposuction. Case report. Scand. J. Plast. Reconstr. Surg. Hand Surg., 26: 111-112, 1992.
3. Biasi, D., Caramaschi, P., Carletto, A., Baracchino, F., Botto, M., Pacor, M. L., Bambara, L. M.: Symmetric multiple lipomatosis with Charcot' joint and neuropathic ulcer. Description of a clinical case. Minerva Med., 84: 135-139, 1993.
4. Ibanes-Carcamo, E.: Liposuction as a treatment for Launois-Bensaude disease. Acta Otorhinolar. Esp., 41: 181-182, 1990.
5. Illouz, Y.: Body sculpturing by lipoplasty. Edinburgh, Churchil Livingstone, 1989.
6. Köble, K., Weltman, G.: Lipomatosis benigna symmetrica. Syndrom Launois-Bensaude. Hautarzt, 35: 33-34, 1984.
7. McCarthy, J.: Plastic Surgery. Vol. 6. Philadelphia, W. B. Saunders Comp., 1990.
8. Samdal, F., Kleppe, G., Tonvang, G.: Benign symmetric lipomatosis of the neck treated by liposuction. Case report. Scand. J. Plast. Reconstr. Surg. Hand Surg., 25: 281-284, 1991.
9. Wood, R.: Benign symmetrical lipomatosis - a complication of excessive alcohol consumption. A case report. S. Afr. Med. J., 77: 369-370, 1990.

Address for correspondence: M. Dušková,
Šrobárova 50,
100 34 Praha 10,
Czech Republic

INSTRUCTIONS TO AUTHORS

Acta Chirurgiae Plasticae, the international journal of plastic surgery, is published in English four times a year. For publication are accepted articles dealing with problems of plastic, reconstructive and aesthetic surgery, craniofacial surgery, hand surgery, microsurgery, burns and allied branches (clinical, laboratory, experimental studies); they must be submitted in English or Czech language. The text must be original and not previously published elsewhere.

Kindly send your manuscripts to the following address: Acta Chirurgiae Plasticae, Šrobárova 50, 100 34 Praha 10, Czech Republic.

The manuscript must be typewritten in two copies (1 original plus 1 copy), one page per sheet, with double-spacing between the lines, 60 types per line and no more than 30 lines per page. There should not be more than five corrections by handwriting per manuscript. The institute where the authors work, the title of the article and the full name of the author (of authors), must be stated on the first page. All other pages should be numbered consecutively. The summary with key words, the references in alphabetic order according to the surname of the first author and the legend to the Figures are to be written each on a separate page and added to both copies of the manuscript. The address of the main author should be given at the bottom of the References. The place where the Tables are to be inserted, must be marked in pencil on the margin of the text. Figures are to be separate and not affixed in the text. On the back of each Figure, the author is requested to write in soft pencil his name, the short title of the paper and the consecutive number of the illustration with an arrow indicating the top of the Figure. Photographs must be clear, with good contrast and of a convenient size. Colour photographs are accepted for reproduction as well. The Tables and Graphs should be lined with Indian ink on white paper so as to make them well readable. Text in Figures should be avoided; it is preferable to use symbol a, b, c, or 1, 2, 3 and to include the text in the legend. The Tables must be numbered consecutively with Arabic numerals and typed on separate pages.

References should be quoted in the text with surname of the author and the year of publication. Two or more works by the same authors published in the same year must be marked with the suffixed a, b, c, etc. Quotations should be adjusted according to the Czech norm as follows: Articles in journal - author's surname and initials, title of the article, international abbreviation of the journal, volume, pages and the year of issue. For instance: Motoki, D. S., Altobelli, D. E., Mulliken, J. B.: Enophthalmos following orbital transposition for craniofacial malformations. Plast. Reconstr. Surg., 91: 416 - 422, 1993.

Books and monographs: the name of authors, title of publication, place of issue, publisher, year of issue and - maybe - also the page from which the quotation was taken. For instance: Burian, F.: Surgery of Cleft. Praha, SZdN 1954. The abbreviation et al. is not acceptable in the reference section and each reference must begin on a new line.

Manuscripts which do not comply with these requirements cannot be published. The editorial board reserves the right to suggest the publication of author's article in the form of an annotation, make corrections, or on account of comments made by the reviewers, return the manuscript to the author for redrafting. The papers must be send to the editor in their final formulation. The galley proofs are done by the author, but no essential changes are permitted.

DOKÁŽEME TÉMĚŘ VŠECHNO, NĚCO VŠAK JEN S VAŠÍ POMOCÍ.

V životě jsou situace, kdy se člověk bez pomoci těch druhých prostě neobejde. ***Československá nadace Charty 77*** *děkuje Vám všem, kteří jste začali pomáhat prostřednictvím* ***konta „Bariéry"*** *našim postiženým spoluobčanům. Finanční pomoc uvítaly desítky rehabilitačních středisek, speciální školy i školky, ale také jednotlivé rodiny s postiženými dětmi... Mnozí další však na pomoc teprve čekají.* ***Konto „Bariéry"*** *je založeno na malém, ale pravidelném příspěvku. Za 20 Kč dnes sotva koupíte krabičku cigaret či lístek do kina, ale z Vašich měsíčních příspěvků můžeme pomoci tam, kde je to nutné. Na dobré rozhodnutí není nikdy pozdě.*

Dvacet korun samo o sobě mnoho neznamená. Dvacet korun znásobených každý měsíc tisíci dobrovolnými dárci dává postiženým šanci překonávat mnohé bariéry.

PROHLÁŠENÍ MZDOVÉ ÚČTÁRNĚ

Já . . . . . prosím o trvalý převod 20,- Kč měsíčně ze mzdy od nejbližšího možného termínu ve prospěch **konta „Bariéry"** u EAGB, pob. Praha 17 111 444/1800 (konst. s. 558, var. s. 9).

Dne . . . . . podpis . . . . . .

Bezplatné uveřejnění tohoto inzerátu bylo možné díky pochopení redakce.

BARIÉRY

KONTO EAGB PRAHA 17 111 444/1800

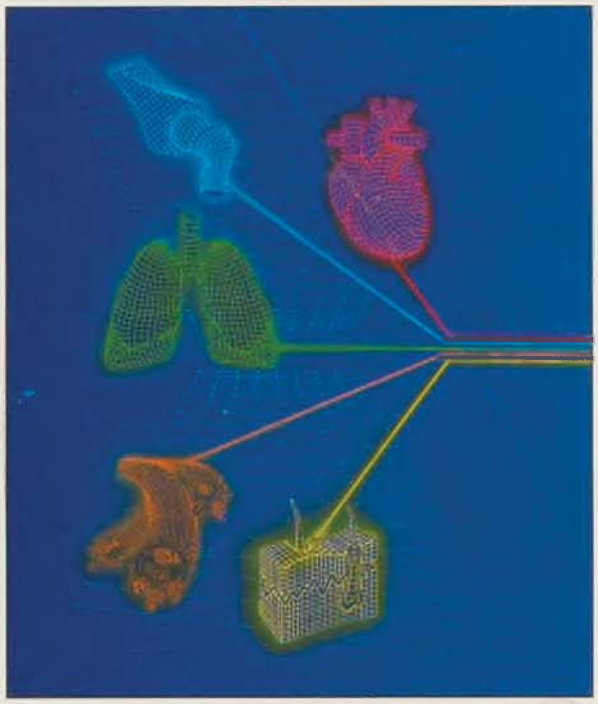

TARGOCID® IM/IV
[teicoplanin]

SPOLEHLIVÁ OCHRANA PROTI GRAMPOZITIVNÍM INFEKCÍM

Výrazná baktericidní účinnost

- baktericidní účinek in vitro proti většině grampozitivních patogenů včetně enterokoků, Staphylococcus aureus, Staphylococcus epidermidis, a to i kmenů multirezistentních na meticilin, cefalosporiny a jiná antibiotika
- není známa zkřížená rezistence s beta-laktamy nebo jinými antibiotiky

Výborná klinická účinnost a prokázaná bezpečnost

- úplné vyléčení nebo výrazné zlepšení v 92% případů u různých infekcí (septikémie, endokarditis, infekce kostí a kloubů, infekce kůže a měkkých tkání, infekce dolních cest dýchacích)
- výborný průnik do tkání
- sérové hladiny vyšší než MIC většiny patogenů
- velmi dobrá snášenlivost, nežádoucí účinky jsou většinou mírné a přechodné
- není známa zkřížená rezistence s beta-laktamovými antibiotiky

Výhodné dávkování

- Targocid se podává jedenkrát denně (intravenózně nebo intramuskulárně)

MARION MERRELL DOW

obchodní zastoupení pro Českou republiku:
ewopharma Korunní 127 130 00 Praha3
Telefon: 02/67 31 16 13 Fax: 02/73 71 95

ewopharma