ACTA CHIRURGIAE PLASTICAE

INTERNATIONAL JOURNAL OF PLASTIC SURGERY, MAXILLOFACIAL SURGERY, HAND SURGERY AND BURNS

Vol. 41 • 4/99

PUBLISHED BY THE CZECH MEDICAL ASSOCIATION J. E. PURKYNĚ

ISSN 0001-5423

INDEXED IN EMBASE/Excerpta Medica, MEDLINE/Index Medicus, BIOLOGICAL ABSTRACTS

NABÍDKA KNIH Z NAKLADATELSTVÍ MAXDORF

GASTROINTESTINÁLNA ENDOSKOPIA

Lars Aabakken, Arne Rosseland, Magne Osnes, *Ulleval Sykehus, Oslo, Norsko,*
MUDr. Rastislav Kunda, *Transplantačné centrum Banská Bystrica, Slovensko*

Slovenský překlad oficiální publikace Skandinávské společnosti pro digestivní endoskopii (SADE), která je považována za jednu z nejlepších učebnic v daném oboru na světě. Praktický průvodce od vybudování endoskopického pracoviště po přesné návody pro všechny časté i vzácnější indikace. Hlavní kapitoly jsou věnovány diagnostickým i terapeutickým endoskopickým výkonům v horní i dolní části trávicí trubice, vč. kolonoskopie, ERCP, endoskopické ultrasonografie atd. Rozebrána je i pediatrická problematika.
Kniha je určena všem lékařům, kteří se věnují endoskopii, a to nejen v gastrointestinální oblasti.
Váz., B5, velký počet instruktivních obrázků, barev. příloha, rejstřík, 233 str., 345 Kč

NEUROINFEKCE

Doc. MUDr. Milan Duniewicz, CSc., *infekční klinika FN Bulovka,* ***MUDr. Pavel Adam, CSc.***, *neurologická klinika 1. LF UK, Praha,* ***doc. MUDr. Marie Staňková, CSc.***, *vedoucí AIDS centra, infekční klinika FN Bulovka,* ***prof. MUDr. J. Bohutová, DrSc.***, *radiologická klinika FN Bulovka*

Základní publikace věnovaná neuroinfekcím vyskytujícím se v našich zemích. Je koncipována jako standardní příručka s konkrétními návody a doporučeními pro lékařskou praxi. ***Kniha je určena*** infekcionistům, neurologům, pediatrům a také praktickým lékařům pro ambulantní službu.
Váz., A5, ilustrace, tabulky, barev. příloha, rejstřík, 320 str., 395 Kč

PRAKTICKÝ SLOVNÍK MEDICÍNY

5. rozšířené vydání, 11000 hesel, barevná anatomická příloha
MUDr. Martin Vokurka, CSc., MUDr. Jan Hugo

Páté, rozšířené vydání úspěšného výkladového slovníku lékařské terminologie. Obsahuje cca 11 000 hesel, velký počet příkladů, ilustrace. Nově je do slovníku zařazena barevná anatomická příloha. Slovník kromě aktuální lékařské terminologie obsahuje také řadu hovorových výrazů užívaných zdravotníky, zkratky a pro snazší orientaci i české výrazy. Publikace je prvním výkladovým slovníkem lékařských termínů srozumitelným široké veřejnosti u nás za posledních 50 let. ***Slovník je určen*** především široké veřejnosti a nelékařům ve zdravotnictví. Pro lékaře může být zajímavý zařazením mnoha výrazů z nových oborů medicíny, důsledně propracovaným propojením hesel formou odkazů a srovnání, stejně jako praktickým a živým zpracováním lékařské etymologie.
Váz., A5, barevná anatomická příloha, velký počet obrázků, 512 str., 285 Kč

FOTODERMATÓZY

Prof. MUDr. Lubor Malina, DrSc., *Dermatologická klinika 3. lékařské fakulty Univerzity Karlovy a Fakultní nemocnice Královské Vinohrady*

Z celosvětového hlediska je v současné době fotobiologie, zvláště lékařská, na prudkém vzestupu. Důvodem je jednak odhalení zásadní role ultrafialového záření v indukci imunosupresivních pochodů a kancerogeneze, jednak účast jednotlivých složek tohoto radiačního pásma v etiologii fototoxických a fotoalergických lékových reakcí i ozřejmení etiopatogeneze celé řady dříve nevysvětlených tzv. primárních (idiopatických) fotodermatóz. Význam má i UV-radiace jako provokační faktor mnoha metabolických chorob.
Váz., A5, 19 obrázků, 20 fotografií, tabulky, rejstřík, 240 str., 285 Kč, vyjde 1999

Objednávky uvedených publikací můžete zasílat na adresu:
Nakladatelské a tiskové středisko ČLS JEP, Sokolská 31, 120 26 Praha 2, fax 02/2491 1420

ZÁVAZNĚ OBJEDNÁVÁM

Aabaken a kol.: **Gastrointestinálna endoskópia** *233 str., 345 Kč* ..... *výt.*
Duniewicz a kol.: **Neuroinfekce** *320 str., 395 Kč* ..... *výt.*
Vokurka, Hugo: **Praktický slovník medicíny** *512 str., 285 Kč* ..... *výt.*
Malina: **Fotodermatózy** *240 str., 285 Kč* ..... *výt.*

Jméno, příjmení, titul: .....

Instituce, firma: .....

IČO, DIČ: .....

Adresa vč. PSČ: .....

Datum: ..... Podpis, razítko: .....

ACTA CHIRURGIAE PLASTICAE

No. 4, 1999

CONTENTS

SCOPE AND LIMITATIONS

Acta Chirurgiae Plasticae is an international journal with a long-standing tradition respected by the professional public worldwide. It is published in English four times per year. The journal contains clinical, experimental and theoretic studies from the discipline of plastic, reconstructive and aesthetic surgery, surgery of the hand, craniofacial surgery, treatment of burns and allied surgical disciplines (traumatology, orthopaedics, gynaecology etc.). In the journal you will also find reviews, case-histories, innovations, comments, reports from study trips and congresses, reviews of books and various announcements.

ACTA CHIRURGIAE PLASTICAE

SUBSCRIPTION AND FEES

Price for a single issue: Kč 64,- (Czech Republic), Sk 73,- (Slovak Republic).
1999 subscription rate: Kč 256,-, Sk 292,-, respectively.
Information on subscription rate for other countries provides: CzMA JEP, Sokolská 31, 120 26 Prague 2, Czech Republic.
Subscription orders should be sent to the Publishing Division of the Czech Medical Association JEP, Sokolská 31, 120 26 Prague 2, Czech Republic, or by fax No.+4202/249 11 420 or by e-mail: nts@iol. cz.
http://www.clsjep.cz

I hereby subscribe to Acta Chirurgiae Plasticae

Name ..... Date .....

Full address .....

.....

..... Signature .....

ACTA CHIRURGIAE PLASTICAE

Editorial board: M. Tvrdek, chairman, Z. Šmahel, vicechairman, L. Brož, J. Kozák, R. Königová, A. Nejedlý, J. Válka, J. Veselý, members. Published four times a year by the Czech Medical Association J.E.Purkyně, Sokolská 31, 120 26 Prague 2, Czech Republic. Printed by MTT, Za Poříčskou bránou 9, Prague 8. Distribution for the Czech Republic and Slovak Republic: ADLEX System, Pravoúhlá 26, 150 00 Prague 5. Distribution abroad: ABONT s. r. o., Chlumova 17, 130 00 Prague 3. Price for a single issue: Kč 64,- (Czech Republic), Sk 73,- (Slovak Republic). 1999 subscription rate: Kč 256,-, Sk 292,-, respectively. Subscription orders should be sent to the Publishing Division of the Czech Medical Association JEP, Sokolská 31, 120 26 Prague 2, Czech Republic, or by fax No. +4202/249 11 420. Manuscripts should be sent to Acta Chirurgiae Plasticae, Šrobárova 50, 100 34 Prague 10, Czech Republic. Advertisement and inquiries concerning conditions of advertising should be sent to Advertisement Department of the Czech Medical Association JEP, Vršovická 17, 101 00 Prague 10, Czech Republic, e-mail: ntsinzerce@iol.cz. Podávání novinových zásilek povoleno Ředitelstvím pošt Praha, č.j. NP 1558/1994, ze dne 13.7.1994. Registrační značka MK ČR F 4844. Indexed in Excerpta Medica/EMBASE, Index Medicus/MEDLINE, Biological Abstracts. Internet service provider: EuroNet. Cz., spol. s r. o., Štěpánská 18, 110 00 Prague 1, phone number: +4202/22 23 07 02, fax: +4202/22 23 07 08; e-mail: medical@euronet.cz; Internet: www.Medical.cz.

ACTA CHIRURGIAE PLASTICAE 41, 4, 1999, pp. 103 - 106

AN INFILTRATION TECHNIQUE FOR REDUCTION MAMMAPLASTY: RESULTS IN 192 CONSECUTIVE BREASTS

O'Donoghue J. M.[1], *Chaubal N. D.*[2], *Haywood R. M.*[1], *Rickard R.*[1], *Desai S. N.*[1]

Departments of Plastic Surgery[1] and Anaesthesia[2], Stoke Mandeville NHS Trust Hospital, Aylesbury, Bucks, United Kingdom

SUMMARY

The use of local anaesthetic infiltration with adrenaline is now considered safe in reduction mammaplasty. However, the technique of infiltration by those who support its use is often unclear. Any technique must take account of the neurovascular anatomy of the breast if it is to be effective. We propose the use of a large volume of dilute local anaesthetic (20 ml of 1% lignocaine and 1 mg of adrenaline made up to 400 ml with 0.9% saline) which is placed judiciously in the retroglandular space 15 minutes prior to surgery.

The results in 96 consecutive patients (192 breasts) who had an inferior pedicle technique were analysed. The breast complication rate was 9.36 % and the patient complication rate 19.79 %. Postoperative blood loss ranged from 0 to 305 ml with a mean of 56.03 ml and a median of 50 ml.

The described method could be considered a variation of the tumescent technique used in liposuction. The results is an almost bloodless dissection with minimal postoperative blood loss. It should be possible to dispense with the use of drains in most cases.

ZUSAMMENFASSUNG

Die Infiltrationstechnik bei der reduzierten Mamoplastik. Die Ergebnisse von 192 aufeinanderfolgenden Brustoperationen

O'Donoghue J. M., Chaubal N. D., Haywood R. M., Rickard R., Desai S. N.

Die Anwendung der lokalen anästhetischen Infiltration mit Adrenalin wird jetzt für sichere Methode bei der reduzierten Mamoplastik gehalten. Jedoch diese Technik wird oft von denjenigen, die sie benutzten, unklar angegeben.

Jede Technik, wenn sie efektiv sein soll, muß die neurovaskulare Anatomie der Brust in Betracht ziehen. Wir schlagen die Anwendung vom großen Umfang des verdünnten Lokalanästhetikum (20 ml Lignokains und 1 mg Adrenalins in 400 ml in die physiologische Lösung einmischen), das in den retroglandularen Raum 15 Minuten vor dem chirurgischen Eingriff appliziert wird.

Bei 96 Patienten (192 der Brüste), bei denen die untere Stieltechnik angewandt wurde, wurden die Ergebnisse analysiert. Das Prozent der Brustkomplikationen war 9,36 %, das Prozent der Komplikationen bei den Patienten war 19,7 %, der postoperative Blutverlust schwankte von 0 bis 305 ml, im Durchschnitt 56,03 ml und mit Mittelpunkt 50 ml.

Diese beschriebene Methode kann für die Variation zur Anschwelung verursachende Technik, die bei der Liposuktion angewandt wird, gehalten werden. Das Ergebnis ist fast der nichtblutige Schnitt mit dem minimalen postoperativen Blutverlust.

Key words: breast, reduction mammaplasty, local anaesthesia

The use of local anaesthetic infiltration during breast reduction surgery is not new (Mottura, 1992; Blomqvist, 1996; De Bono, 1997), while the additional use of adrenaline has been shown to be both safe and beneficial in terms of reducing blood loss (Varma, 1990; Bretteville-Jensen, 1974; Brantner, 1985). Indeed, in combination with intravenous sedation it is now possible to carry out breast reductions as day case procedures (Zukowski, 1996).

While the various authors mentioned use different mixtures and concentrations of local anaesthetic solutions with adrenaline, their description of the infiltration technique is often unclear. De Bono and Rao (7) carry out their infiltration along the planned incision lines and into the „subcutaneous and deeper tissues" but avoid infiltrating the nipple pedicle. Zukowski et al. (19) use a „sequential layered injection technique" down to the level of the pectoralis major muscle to overcome the problem of injecting through dense and firm breast tissue. They also recommend infiltrating at the deep dermal level along the pedicle prior to deepithelialisation and emphasise the importance

of infiltrating laterally to block the lateral intercostal nerve branches. Mottura (13) mentions infiltrating in the retroglandular space to block the perforants of the intercostal nerves.

The aim of local anaesthetic infiltration with adrenaline during breast reduction surgery is to produce analgesia and to reduce blood loss. Therefore it is logical that any infiltration technique must take account of the neurovascular anatomy of the breast.

NEUROVASCULAR ANATOMY OF THE BREAST

The vascular supply of the central breast mound is via branches and perforators arising from the lateral thoracic artery, intercostal vessels, thoracoacromial artery and internal mammary perforators. They enter the gland posteriorly either by perforating the overlying chest wall musculature or by passing superficial to the muscles (Hester, 1985).

Although some dispute exists in the literature regarding sensory innervation of the breast, two recent articles have helped to clarify the situation (Sarhadi, 1996; Jaspars, 1997). Medially the breast is supplied by the anterior cutaneous branches of the Ist - VIth intercostal nerves and laterally by the lateral cutaneous branches of the IInd - VIIth intercostal nerves. They enter the breast posteriorly (9).

Therefore a maximum vasoconstrictor effect is likely to be achieved if adrenaline is placed in a retroglandular position around the site of the perforating vessels. Maximal and rapid analgesic effect is also likely if the local anaesthetic is placed where the nerves enter the breast tissue posteriorly.

We describe in detail our technique of infiltration which was devised by NDC. This method was used by the senior author (SND) for 12 years prior to retirement.

PATIENTS AND METHODS

The last 96 consecutive bilateral breast reductions (192 breasts) of the senior author (SND) were reviewed from the case notes. All breast reductions were performed under general anaesthesia with supplemental local anaesthetic infiltration. An inferior pedicle technique was used in all patients. None had free nipple grafting. Drains were used routinely and the postoperative drainage was recorded. Intraoperative blood loss was not measured as this was minimal.

INFILTRATION TECHNIQUE

The solution used is comprised of 20 ml of 1% lignocaine and 1 ml of 1:1000 (1 mg) adrenaline made up to a volume of 400 ml with 0.9% saline. Following induction of general anaesthesia and prior to draping, 200 ml is injected into each breast. A time elapse of at least 15 minutes is allowed prior to commencing the operation.

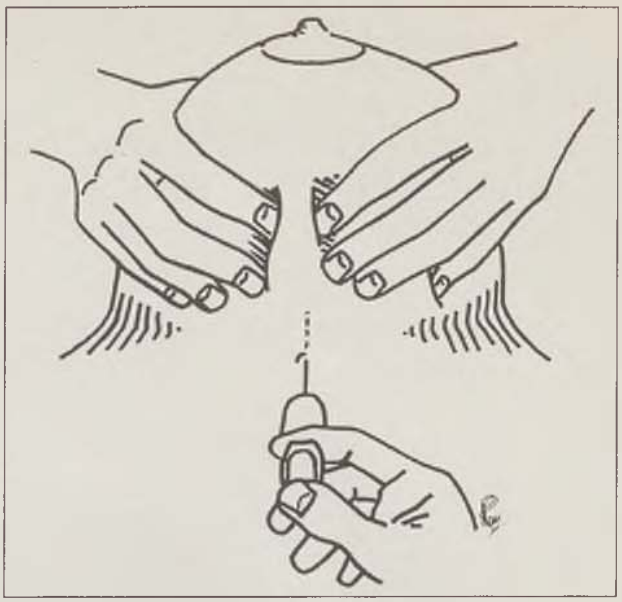

Fig. 1. As the assistant distracts the breast from the chest wall, a 20 gauge spinal needle is passed into the retroglandular space along the plane of the pectoral fascia.

An assistant grasps the breast to be infiltrated and distracts it from the chest wall by vertical traction. A 20 gauge spinal needle is then passed between the breast tissue and pectoralis major muscle along the plane of the pectoral fascia taking care not to enter the thoracic cavity (Fig. 1). The breast is divided into four quadrants (inferior, lateral, superior and medial). Each quadrant is infiltrated in turn with 30 ml of solution. The needle is initially placed beneath the central part of the quadrant and 5 ml is injected. A further 5 ml is injected on withdrawal. The needle is not removed completely but is then angled at 45° and fully advanced. A further 5 ml is

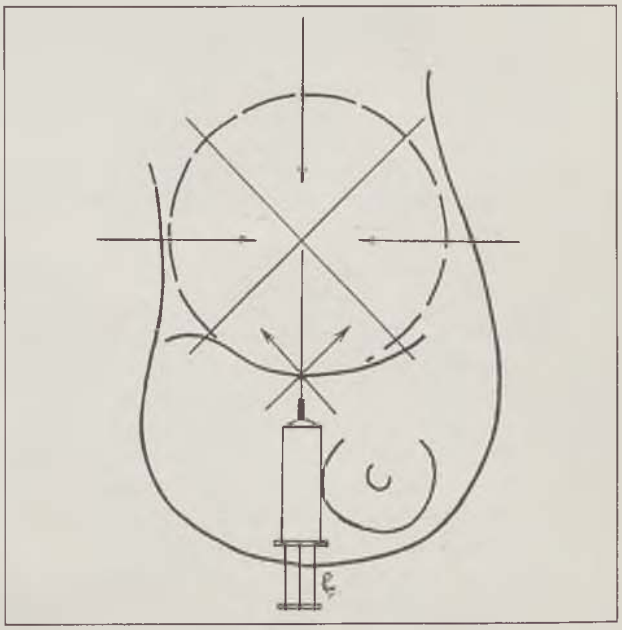

Fig. 2. Each quadrant of the breast disc is infiltrated by three passes of the needle.

injected and again on withdrawal. Finally the quadrant is completed by angling the needle 45° from the central injection point and the procedure is repeated (Fig. 2). The medial quadrant is injected by the assistant while the medial quadrant of the contralateral breast is infiltrated by the operator. The procedure then continues on the opposite side with the operator distracting the breast and the assistant infiltrating. A total of 120 ml of solution is injected into the retroglandular space of each breast. This also includes infiltrating beneath the nipple pedicle. The remaining 80 ml is then injected along the proposed incision lines and into the skin that is to be deepithelialised. Any remaining solution can be injected around the proposed exit site of the drain and into the breast tissue proper in the upper outer quadrant where the lateral flap is thinned.

RESULTS

The mean age of the patients was 32.7 years (range 16 - 60 years) and the mean weight of the total breast tissue excised was 1478 mg (range 408 - 4480 mg). Postoperative complications are listed in Table 1. The overall complication rate was 19.79 % in terms of the number of patients effected and 9.36 % in terms of the number of breasts effected.

Table 1. Postoperative complications (n = 192 breasts)

Complications	No. of breasts	Percentage
Haematoma	1	0.52
Minor Wound Problems	7	3.64
Wound Breakdown	2	1.04
Wound Infection (Proven)	4	2.08
Fat Necrosis	0	0
Total NAC Necrosis	2	1.04
Partial NAC Necrosis	2	1.04
Total	**18**	**9.36**
Complication rate:		
Breasts 18/192	(9.36 %)	
Patients 19/96	(19.79 %)	

(NAC = Nipple Areolar Complex)

There were no complications attributed to the technique of infiltration and there was no evidence of systemic lignocaine toxicity in any case. The mean postoperative blood loss was 56.03 ml (range 0 - 305 ml), the median being 50 ml. No patient required a blood transfusion.

DISCUSSION

The technique described allows the placement of a large volume of fluid in the retroglandular space. The result is an almost bloodless dissection with minimal postoperative blood loss even though the concentration of adrenaline is only 1:400,000. This is akin to the technique used in tumescent liposuction. The reasons for the minimal blood loss noted in tumescent liposuction have been discussed in detail by Samdal et al. (15). Although adrenaline has some effect, it would appear that the large volume of fluid used results in compression of the vascular structures. We are of the opinion that the same mechanisms are at work in this application of the technique. In those patients with very large breasts it may be necessary to use even larger volumes of fluid. We have used 800 ml of the solution described on several patients without any adverse clinical effects.

However, safety concerns about using large volumes of local anaesthetic solutions in breast reduction surgery have been expressed by Bostwick (2). The main concern is the delayed absorption of a potentially toxic dose of lignocaine. As is probably the case with tumescent liposuction, a considerable portion of the anaesthetic solution is removed with the specimen. Indeed, Oochoa and Yrausquin (14) demonstrated no evidence of lidocaine toxicity up to a maximum dose of 18 mg/kg used for a unilateral reduction of 2500 gm, and they noted that peak serum levels of lidocaine occurred between 6 and 9 hours post injection. Mottura (13) has also published examples of lidocaine plasma levels measured during surgery at 15, 30, 45, 60, 90 and 120 minutes using a fluorescence polarisation immunoassay. In all samples, serum lidocaine levels remained very low. In our technique, the dose of lignocaine used is within the accepted dose limitations of 5 mg/kg up to a maximum of 500 mg (5). However, much higher doses are clearly quite safe when more dilute lignocaine (0.05% or 0.1%) with adrenaline is infiltrated slowly into relatively avascular subcutaneous fat. Up to 52 mg/kg has been used during tumescent liposuction without adverse clinical effects (Klein, 1993).

Another potential complication is the production of an iatrogenic tension pneumothorax during infiltration of the breast (Kaye, 1995). Care must be taken when injecting the retroglandular space not to enter the thoracic cavity. It is probably more likely to occur on the lateral side where the chest wall curves laterally away from the breast disc. It is important to bend the needle and introduce it by angling it upwards parallel to the convexity of the chest wall in order not to enter the pleural space inadvertently. We have not seen any instances of this life-threatening complication.

The complication rate in this series is in keeping with other reported series (De Bono, 1997; Mandrekas, 1996; Schnur, 1997) and once again confirms the fact that use of adrenaline during reduction mammaplasty does not contribute to morbidity (De Bono, 1997). Budny et al. (6) have demonstrated quite clearly that the only variable which independently contributes significantly to

the complication rate in breast reduction surgery is a high body mass index and the use of local anaesthesia with adrenaline does not contribute to the complication rate. However, because we infiltrate the pedicle, nipple/areolar complex (NAC) observation in the immediate postoperative period can be difficult as they are invariably pale and cold. The circulation returns to normal 3 to 4 hours later. If the NAC fails to reestablish its circulation after 5 to 6 hours, then a free graft should be performed. No free grafts were performed in this series. The two total NAC losses could have been prevented by delayed free NAC grafting, but this incidence of NAC loss is similar to other series that use the inferior pedicle technique (De Bono, 1997; Mandrekas, 1996; Schnur, 1997).

Because of the retrospective nature of this study it was not possible to assess postoperative pain control. Although it is our clinical impression that these patients are relatively comfortable in the postoperative period, one could legitimately question the use of a local anaesthetic with a relatively short half-life. The first author (JOD) now adds 20 ml of 0.5% bupivacaine to the solution as well as 1500 IU of hyaluronidase to aid spreading of the fluid in the planned tissue planes.

The mean postoperative drainage was 56.03 ml (range 0 - 305 ml). This suggests that it should be possible to dispense with drains in most cases. However, convention and perhaps fear of the unknown have prevented us from taking this leap of faith. Nevertheless, patients are no longer cross matched and postoperative haemoglobin checks are not performed.

In summary therefore, we propose that the use of a large volume of dilute local anaesthetic solution placed judiciously in the retroglandular space is both helpful and safe during reduction mammaplasty. The method described could be considered a tumescent technique.

REFERENCES

1. Blomqvist, L., Sellman, G., Strombeck, J. O.: Reduction mammaplasty with adrenaline infiltration: effects on perioperative bleeding. Scand. J. plast. reconstr. Hand Surg., 30: 29-32, 1996.
2. Bostwick, J.: Breast reduction under intravenous sedation: A review of 50 cases (Discussion). Plast. reconstr. Surg., 97: 957-958, 1996.
3. Brantner, J. N., Peterson, H. D.: The role of vasoconstrictors in control of blood loss in reduction mammaplasty. Plast reconstr. Surg., 75: 339-341, 1985.
4. Bretteville-Jensen, G.: Mammaplasty with reduced blood loss: effect of Noradrenaline. Br. J. plast. Surg., 27: 31-34, 1974.
5. British National Formulary: British Medical Association and Royal Pharmaceutical Society of Great Britain, 34: 541-542, 1997.
6. Budny, P. G. B., Vesley, M., Coleman, D. J.: The effect of body weight and body mass index on outcome and complication rates in breast reduction surgery. Proceedings: Summer meeting of British Association of Plastic Surgeons, 1996.
7. De Bono, R., Rao, G. S.: Vasoconstrictor infiltration in breast reduction surgery: Is it harmful? Br. J. plast. Surg., 50: 260-262, 1997.
8. Hester, T. R., Bostwick, J., Miller, L., Cunningham, S.: Breast reduction utilising the maximally vascularized central breast pedicle. Plast. reconstr. Surg., 76: 890-898, 1985.
9. Jaspars, J. J. P., Posma, A. N., Van Immerseel, A. A. H., Gittenberger-de Groot, A. C.: The cutaneous innervation of the female breast and nipple-areola complex: Implications for surgery. Br. J. plast. Surg., 50: 249-259, 1997.
10. Kaye, A. D., Eaton, W. M., Jahr, J. S., Nossaman, B. D., Youngberg, J. A.: Local anaesthesia infiltration as a cause of intraoperative tension pneumothorax in a young healthy woman undergoing breast augmentation with general anesthesia. J. clin. Anaesth., 7: 422-424, 1995.
11. Klein, J. A.: Tumescent technique for local anaesthesia improves safety in large-volume liposuction. Plast. reconstr. Surg., 92: 1085-1098, 1993.
12. Mandrekas, A. D., Zambacos, G. J., Anastasopoulos, A., Haspas, D. A.: Reduction mammaplasty with the inferior pedicle technique: early and late complications in 371 patients. Br. J. plast. Surg., 46: 442-446, 1996.
13. Mottura, A. A.: Local anaesthesia in reduction mastoplasty for out-patient surgery. Aesth. plast. Surg., 16: 309-315, 1992.
14. Oochoa, J., Yrausquin, E.: Anestesia local en cirugia de las mamas. Gaceta Med., Caracas, 99: 31, 1991.
15. Samdal, F., Amland, P. F., Bugge, J. F.: Blood loss during liposuction using the tumescent technique. Aesth. plast. Surg., 18: 157-160, 1994.
16. Sarhadi, N. S., Shaw Dunn. J., Lee, F. D., Soutar, D. S.: An anatomical study of the nerve supply of the breast, including the nipple and areola. Br. J. plast. Surg., 49: 156-164, 1996.
17. Schnur, P. L., Schnur, D. P., Petty, P. M., Hanson, T. J., Weaver, A. L.: Reduction mammaplasty: An outcome study. Plast. reconstr. Surg., 100: 875-883, 1997.
18. Varma, S. K., Henderson, H. P.: A prospective trial of adrenaline infiltration for controlling bleeding during surgery for gynaecomastia. Br. J. plast. Surg., 43: 590-593, 1990.
19. Zukowski, M. L., Ash, K., Klink, B., Reid, D., Messa, A.: Breast reduction under intravenous sedation: A review of 50 cases. Plast. reconstr. Surg., 97: 952-956, 1996.

Address for correspondence:

Mr. J. M. O'Donoghue, M. Med. Sci.,
M. Ch., FRCSI (Plast.),
Consultant Plastic Surgeon,
Department of Plastic Surgery,
St. George's Hospital,
Blackshaw Road,
London, SW17 0QT,
United Kingdom.

ACTA CHIRURGIAE PLASTICAE 41, 4, 1999, pp. 107 - 111

PRECISION GRIP WITH CONGENITAL HYPOPLASTY OR HYPOFUNCTION OF THE THUMB

Smrčka V.[1], *Dylevský I.*[2], *Kuklík M.*[1]

[1]Center for Patients with Locomotor Defects, Prague, Czech Republic
[2]Department of Anatomy, 2nd Medical Faculty, Charles University, Prague, Czech Republic

SUMMARY

We tested the grip in four patients with congenital defects of the hand and either a hypoplastic thumb or a thumb with impaired inervation. Small objects were taken by a scissors grip between the fingers. In a hand with radial duction in the manus vara congenita, during strengthening of the wrist, the grip from the ulnar side between the fourth and fifth fingers was changed to the radial side between the second and third fingers. Large objects were gripped by all the three-phalanx fingers into the palm in a horizontal position. In case 4 with hypoplasia of the thumb grade IIIC by the classification of Blauth and Buck-Gramcko, we describe a transposition of the index finger to the site of the thumb and the hypoplastic thumb to the site of the index finger. It is obvious that the precision grip is affected by the thumb length and strengthening of the ulnar side of the wrist. We assume that the scissors grip is the earliest precision grip in the evolution of the primate hand.

ZUSAMMENFASSUNG

Die genaue Greifkraft bei der angeborenen Hypoplasie oder die Hypofunktion der Hand

Smrčka V., Dylevský I., Kuklík M.

Bei vier Patienten mit dem angeborenen Handsdefekt mit dem hypoplastischen Daumen oder mit dem Daumen mit der beschädigten Inervation haben wir die Griefkraft getestet. Kleine Gegenstände wurden mit dem Scherengreifkraft zwischen den Fingern ergriffen. In der Hand mit der radialen Duktion manus vara congenita war während der Handsgelenkverstärkung die Greifkraft aus der ulnaren Seite zwischen dem vierten und fünften Finger zur radialen Seite zwischen dem zweiten und dritten Finger geändert. Breite Gegenstände wurden von allen drei Fingerfalangen in den Handteller in der waagenrechte Position ergriffen. Bei dem vierten Fall mit der Daumenhypoplasie des Grades IIIC nach der Blauth und Buck-Gramck Klassifikation beschreiben wir die Transposition des Zeigefingers zur Daumenseite und des hypoplastischen Daumens an die Stelle des Zeigefingers. Es ist offenbar, daß die genaue Greifkraft durch die Daumenlänge und durch die Verstärkung der ulnaren Seite des Handgelenkes beeinflußt ist. Die Scherengreifkraft halten wir für die älteste genaue Greifkraft in der Evolution der Hand bei den Primaten.

Key words: thumb, congenital hypoplasty, precision grip

Congenital defects of the extremities occur in the population in a ratio of 1:1000; of these, defects of the proximal extremities represent 20 to 80 %. In our group of 28 patients with congenital hand defects, a special group is formed by congenital hand deformities with hypoplasty of the thumb, usually occurring as associated defects in the femur-fibula-ulna complex or defects in which other systems are also impaired in the presence of locomotor system involvement. In the group of congenital deformities of the hands with a hypoplastic thumb, it is necessary to implement a reconstruction. Prior to the reconstruction surgery, we perform a grip examination. The term precision grip was introduced by Napier (1956). In this grip, the objects are kept and handled with the thumb in opposition and fingers beyond the palm. The condition for this grip is the full opposition of the thumb with a wide distal phalanx and wide distal phalanges of the three-phalanx fingers, having the length of the thumb and fingers allow for full contact between the bellies of the fingers. In many congenital defects this condition is not adhered to due to the length of the thumb, its gracility or restricted functions. With changes in these conditions, the grip is also altered, which should be recognized prior to the reconstruction surgery of the thumb.

MATERIAL, METHODS

The grip was tested in two patients with congenital hand defects and hypoplasty of the thumb; the third patient has a non-functioning

thumb after poliomyelitis. The boys with congenital defects had both hands involved, the patient with poliomyelitis had only one hand involved. All four boys were asked to grip a metallic tube, 10 cm long and 2 cm in diameter, a circular object 4 cm in diameter and an oval object 1.5 cm in diameter. All of them were also asked to arrange a standard-size LEGO system.

Case 1

A 3-year-old boy, with a combined syndrome of thrombocytopenia - aplasia of the radius, where the configuration of the hands corresponds to the manus vara congenita with hypoplasty of the thumbs, with a missing first left metacarpus (radial club hand). As a further associated impairment, a cleft neck and thorax vertebrae were found with right pes equinovarus cong. and superficial amnial narrowings and preauricular tubers in front of the left auricle. Impairment of the knee joints can occur concurrently. In this patient the impairment of the joints was not present. Both syndromes are monogenously-autosomally recessively congenital with a 25% risk of repeating in brothers and/or sisters. Both parents are carriers without manifestations of the condition. The prenatal diagnosis was carried out by ultrasonography; the diagnosis could also be complemented by foetoscopy. The equinovarous impairment of the right distal extremity was conservatively solved by ortheses and plaster splints. No similar case has been recorded among relatives. During neurological examination at 7 months of age, the neurotopic finding was without deviations; however, there was a retardation of the postural reactivity, and the locomotor development was at a level of 2.5 months.

Grip testing:

On the LEGO system, we tested the grip of both hands with thumb hypoplasty. The boy first arranged particular parts of the LEGO system without wrist fixation. The grip of these objects was between the fourth and fifth fingers. By a scissors grip, sometimes also referred to as a pincers grip, the boy took both larger and smaller parts of the LEGO system and arranged them together (Fig. 1).

In the second stage, a situation was simulated in which the wrist was centered. The wrists of both hands were fixed with soft splints and a splint with an ulnarly inserted block for the hypothenar. In the fixed wrist, the grip of objects was shifted between the second and third fingers in both hands. The fourth finger was the strongest one during the test; the thumb with hypoplasty was the weakest.

Case 2

A 5-year-old boy has a three-digit left hand, with radiohumeral synostosis; provided that two three-phalanx fingers are normally developed, the thumb is hypoplastic.

Grip testing:

In the test on the LEGO system, the grip by the three-digit left hand was between the second and third fingers. In contrast to this, on the right hand, with normally developed three-phalanx fingers and a hypoplastic thumb, the grip was between the fourth and fifth fingers.

For comparison, we tested the grip in a patient who did not suffer from morphological deficiency of the thumb within scope of hypoplasia but rather from dysfunction due to damage to the inervation.

Case 3

A 6-year-old boy with poliomyelitis after an intraparenchymal hemorrhage on the left side and bilateral intraventricular hemorrhage.

Grip testing:

In testing the grip with the right hand, he is not able to perform either pronation or supination, in spite of the fact that the movement is passively free. He cannot extend the wrist in spite of the fact that he is able to extend the fingers. The basic grip is a movement of the three-phalanx fingers into flexion in the horizontal position of the object (Fig. 2). In the grip of the

Fig. 1. Precision grip between fingers in a patient with a radial club hand.

Fig. 2. Power grip with horizontally held object in a patient with thumb hypofunction.

Fig. 3. Precision grip between fingers in a patient with thumb hypofunction.

Fig. 4. Hypoplasia of the thumb Grade IIIC (by the classification of Blauth and Buck-Gramcko).

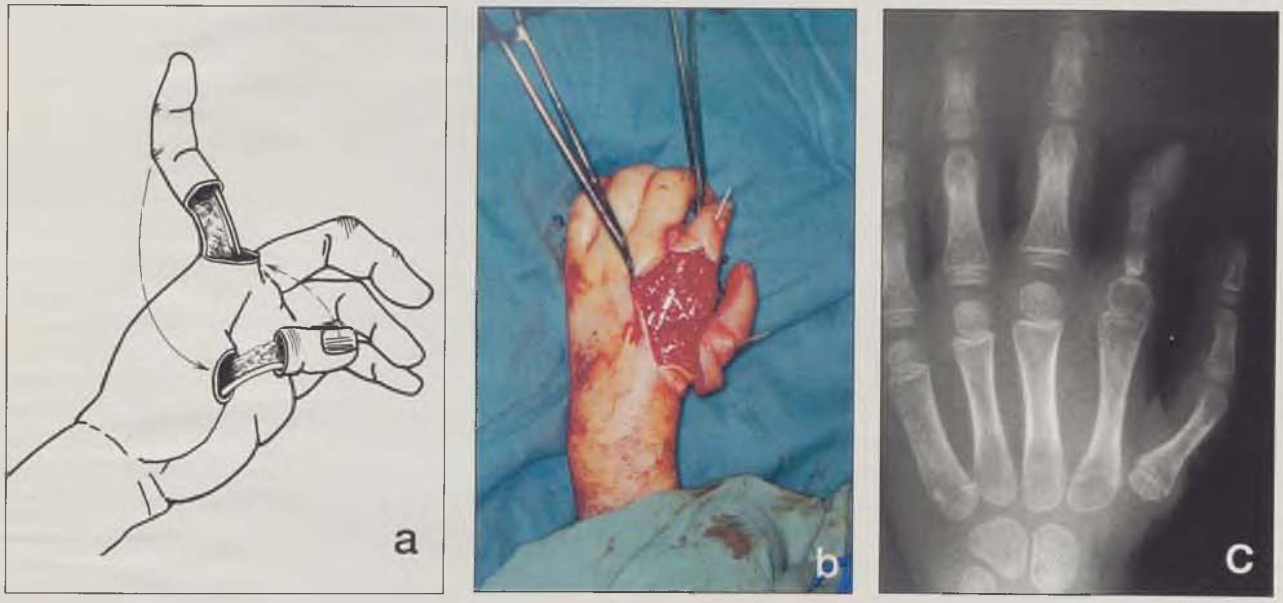

Fig. 5. Scheme of the transposition of the index finger to the site of the thumb and simultaneously the hypoplastic thumb to the site of the index finger (a), final position of the fingers after the double-transposition (b), X-ray picture 1 year after surgery (c).

tube or of a larger circular object, he also takes the object by the adducted thumb; however, he is unable to shift the thumb into opposition with the index or middle finger. In the case of a small object up to 2 cm in diameter, he takes it between the index and middle fingers (Fig. 3).

Case 4

In a boy of five years of age with thumb hypoplasia of grade IIIC (Fig. 4) according to the classification by Blauth (1967) and Buck-Gramck (1993), an exchange of the hypoplastic thumb and index finger was performed in 1994 at the request of his parents (Figs 5a-c, Fig. 6).

The index finger was transposed to the site of the thumb onto the ulnar digital artery (the radial one was hypoplastic) with a dorsal skin bridge. The hypoplastic thumb was shifted to the site of the index finger on a volar skin bridge with the radial neuromuscular bundle. The grip was

Fig. 6. The transposed fingers after five years.

between the third finger and fourth finger prior to the operation. The original hypoplastic thumb, i.e. the index finger after the intervention, with a missing growth plate, remained hypoplastic. In 1997 the anthropologist did not recommend the transfer of the growth zone from the distal extremity; he proposed that the motor reconstruction to flexion would be implemented only after the completion of bone growth. The passive mobility of the hypoplastic finger in the metacarpophalangeal joint is 30°; in the interphalangeal joint it is 40°.

After a period of five years from the operation, the precise grip for very small objects is still implemented between the third finger and the index finger. The newly formed thumb exerts an improved mobility in comparison with the thumb on the second hand involved by a hypofunction of the flexor.

RESULTS

In testing the precise grip in two patients with congenital defects involving a shortened hypoplastic thumb, there was a scissors grip between the fingers. In the hand with the radial duction of the wrist during straightening, there was a change of the grip from the ulnar side between the ring and little fingers to the radial side between the index and middle fingers.

In the hand having only an impaired thumb nervous system, there is also a precise scissors grip between the index and middle fingers. In congenital defects with a hypoplastic thumb and in patients with the functional involvement of the thumb due to an impairment of the nervous system, the principal power grip and grip of large objects remains as a grip of the flexor apparatus of three-phalanx fingers, keeping the object horizontally in the palm (Fig. 2).

DISCUSSION

Our testing procedure represents a preliminary stage prior to the reconstruction of the principal grip unit: thumb - index finger, thumb - middle finger.

Details of the pre-surgical preparation in the manus vara congenita: In the first stage (hypoplasia of thumbs, wrists in the varose position), after 6 months, we left the patient only with soft splints straightening the wrist; the grip was trained. At this stage, the ring finger is the strongest and is being prepared for the pollicization in this way. In the second stage (hypoplastic thumbs, wrist straightened with an orthesis or splint with ulnar strengthening), the grip is shifted between the index and middle fingers; the short muscles are trained. In the third stage, after the pollicization of the ring finger, it is already possible to train the whole grip unit, i.e. the grip of the pollicized thumb with the index and middle fingers.

The described scissors grip is very similar to the grip described by Schultz (1969) in howler monkeys, subfamily *Alovattinae*, who noted that the thumb is not always necessary for arboreal movement and that the small thumb or its vestiges are being lost, up to an extreme case such as the spider monkey (*Ateles paniscus*) or the guerezas (*Colobus*). These monkeys are perfectly adapted to locomotion in trees, and they support themselves by a flexion of their fingers around branches.

Jolly (1970) showed that *Theropithecus gelada* uses a precision grip for most of its food-collecting. Its food consists mainly of grass, seeds and rhizomes, which are picked up singly between the thumb and index finger and collected in the fist until a mouthful is accumulated. The index is thus continually used independently of the other digits. This feeding method is facilitated by a well-developed pollex and a very short index finger, a combination giving the gelada the highest „opposability index“ of any catarrhine, including *Homo sapiens*.

Thus, the length and strength of the thumb affects the type of hand grip. This would also correspond to our experience with traumatically amputated thumbs (Smrčka et al., 1996) in the thenar area. The patients were forced to learn to grip between their fingers. However, immediately after performing thumb reconstruction, even when it was rigid without movable joints, but of a sufficient length with respect to the other normally movable fingers, function was restored with the possibility of a precise grip in the principal functional unit, thumb - index finger - middle finger.

The same situation was also encountered in case 4, where a boy of five years had the grip between the second and third fingers in the presence of a hypoplastic thumb. After the transposition of the index finger to the site of the thumb, the motion remained between these two fingers, since the hypoplastic thumb transposed to the site of the index finger confers only passive mobility.

A further case is a patient with manus vara congenita on the right side, with aplasia of the radius and thumb, in which we centered the ulna in 1992 and shifted the immobile index finger, supplied only through the ulnar vascular bundle, to the position of the thumb. The grip was recovered between the rigid thumb and fingers.

The power grip is a term introduced by Napier (1956) to describe the human grip when holding a hammer. The object is held diagonally across the palm by squeezed, flexed fingers and supported by the adducted thumb. In an analysis of non-human primates, Napier (1960) also differentiated the human grip from the grip of apes, who keep cylindrical objects by four flexed fingers without significant participation of the thumb.

Napier identified several morphological features characterizing the power grip in humans. These are a strong long thumb, flexion ability, lateral rotation and deviation of fingers in the ulnar direction, in addition to strong tips on the distal phalanges and the elevation of fingers in the ulnar direction, in addition to strong tips on the distal phalanges and the elevation of the hypothenar, providing the opposition of the thenar eminence. Finally, there is also an irreplaceable saddle joint between the hamatus and fifth metacarpus. Marzke et al. (1992, 1996, 1997) also mentioned a difference between the grip of cylindrical objects and large spherical objects and provided a classification of grips. Their classification does not include the scissors grip between fingers, probably due to the fact that the classification was based on chimpanzees, in whom the thumb length may be replaced with an increased mobility of three-phalanx fingers.

In the description of the grip beyond the flexors controlled by the n. medianus described by Napier, there is also the participation of the short muscles of the hand, inervated by the ulnar nerve.

In examining the power grip in our patients with congenital defects, however, these patients took the objects horizontally into the palm (Fig. 2). In examining patients with congenital defects of the hand, the functioning of the short muscles was shown to be restricted.

Members of the Zoological Garden in Prague also informed us that young chimpanzees held objects horizontally in the palm. This could indicate that the grip of extrinsic flexors (*power grip*) inervated from the medianus is an „older" grip than the grip with the help of intrinsic muscles (*precision grip*) inervated from the ulnar nerve, where the rotation of metacarpi occurs. We assume that the scissors precision grip between triphalangeal fingers with primates is evolutionarily an „earlier" grip than the „later" thumb - index finger, thumb - middle finger precision grips. This hypothesis should, however, be checked in a further study.

CONCLUSION

In testing the grip in patients with congenital defects involving hypoplasty of the thumb, we found that small objects are taken by a scissors (or pincers) grip between two fingers. The question of what will be these fingers, whether ulnarly or radially, depended on the wrist position. Large objects were held with all fingers in a horizontal position in the palm. It is obvious that the precise grip of an object depends in particular on the length and strength of the thumb and, further, on the position of the wrist and particularly on the strength of its ulnar side.

ACKNOWLEDGEMENT

We are indebted to Mrs. Pluhařová for technical documentation, to Prof. Rakovič for translation.

Our thanks are extended to the staff members of the Zoological Garden in Prague for consultations and for making it possible to us to observe primates in the course of feeding, particularly to Dr. Brandl, Mrs. A. Horová, Mr. M. Ždánský, Mrs. G. Herbertová and Mrs. V. Pavlíčková.

REFERENCES

1. Blauth, W.: Der hypoplastiche Daumen Arch. Orthop. Unfall-Chir., 62: 225-246, 1967.
2. Buck-Gramcko: Congenital malformation of the hand and forearm. Part III. European Medical Biobliography Hand Surgery, Vol. 3, No. 4, 1993, p. 7-46.
3. Dylevský, I.: Connective tissues of the hand and foot. Acta Univ. Carol. Med., Monogr., 127: 195 pp., 1988.
4. Dylevský, I.: Morphology of the superficial muscle layer of the hand and forearm. In: Smrčka, V., Dylevský, I.: Flexor tendons of the hand. Brno, 1999 (in Czech).
5. Jolly, C. J.: The Seed-Eaters: a new model of hominid differentiation based on a baboon analogy. Man, 5: 5-26, 1970.
6. Napier, J. R.: The prehensile movements of the human hand. J. Bone Joint Surg., 38B: 902-913, 1956.
7. Marzke, M. W., Wullstein, K. L., Viegas, S. F.: Evolution of the power (squeeze) grip and its morphological correlates in hominids. Am. J. Phys. Anthropol., 89: 283-298, 1992.
8. Marzke, M. W., Wullstein, K. L.: Chimpanzee and human grips: A new classification with a focus to an evolutionary morphology. Int. J. Primatol., 17: 117-139, 1996.
9. Marzke, M. W.: Precision grips, hand morphology and tools. Am. J. Phys. Anthropol., 102: 91-110, 1997.
10. Schultz, A.: The Life of Primates. Weidenfeld and Nicolson, 1969, p. 60-62.
11. Smrčka, V., Hrbatý, J., Holuša, P.: Microsurgical reconstruction of a stiff jointless thumb after an avulsion injury. Acta Chir. plast., 38: 24-29, 1996.
12. Smrčka, V., Dylevský, I.: Congenital contracture of the superficial flexor of the hand. Acta Chir. plast., 40: 109-111, 1998.

Address for correspondence:

Václav Smrčka
Nádražní 113
264 01 Sedlčany
Czech Republic

ACTA CHIRURGIAE PLASTICAE 41, 4, 1999, pp. 112 - 116

CHANGING PATTERN OF INFECTION IN THE BRATISLAVA BURN CENTER

Koller J.[1], *Boča R.*[2], *Langšádl L.*[3]

[1]Burn Center, Ružinov General Hospital, Bratislava, Slovakia
[2]Medical Faculty, Commenius University, Bratislava, Slovakia
[3]State Institute of Health, Bratislava, Slovakia

SUMMARY

Infection still remains one of the major problems in burn treatment. The authors investigated the occurence of burn wound pathogens in burn wound biopsies and/or semiquantitative wound surface off-prints. As the results have shown, trends of a decreased contribution of „classical pathogens", like Staphylococcus aureus and Pseudomonas aeruginosa, to burn wound infections were observed. The role of „other pathogens", like Enterobacter, Acinetobacter, etc., which were quite rare in the past, is on the opposite, increasing. One of the explanations can be the increasing rate of early surgical treatment methods of deep burns. The results were in accordance with similar studies from other burn centres.

ZUSAMMENFASSUNG

Die Profilveränderungen der Infektion im Bratislava's Verbrennungszentrum

Koller J., Boča R., Langšádl L.

Einer der Hauptprobleme bei der Verbrennungsbehandlung bleibt ständig die Infektion. Die Autoren untersuchten das Aufkommen der Patogenen in den Verbrennungswunden von den Biopsien in den Verbrennungswunden oder der semikvantitiven Separaten der frühen Flächen. Sie erwiesen den Trend des herabsetzenden Anteils der „klassischen Patogenen", wie Stafylokokus aureus und Pseudomonas eruginosa, in den infizierten Verbrennungswunden. Der Anteil der „anderen Patogenen", wie enterobakterie, acinetobakterie usw., die in der Vergangenheit sehr seltsam aufkamen, wuchs im Gegenteil herauf. Einer der Erklärungen kann der steigende Anteil von den frühen chirurgischen Behandlungsmethoden bei den tiefen Verbrennungen sein. Die Ergebnisse sind im Einklang mit den ähnlichen Studien anderer Verbrennungszentren.

Key words: burn wound infection, quantitative biopsies

One of the major problems in the treatment of extensive burns still remains infection with its resulting complications. Several studies in our country have shown that the rate of deaths that could be attributed to infection was as high as 75 % (Šimko, 1992), or even 80 % in extensive burns (Königová, 1978). Due to these reasons the continuous monitoring of the burn wound flora is a „conditio sine qua non" in treating burn injuries. In addition to qualitative microbiological investigations, quantitative bacterial counts from the burn wounds can supply us with more reliable information as to the character of the infection. Quantitative counts can be performed either from the wound surfaces by an off-print method, or by performing a burn wound biopsy with subsequent quantitative bacterial counts. The aim of this study was to observe the evolution and changes of microbial colonisation of burn wounds as well as the resistance of bacterial strains to antibiotics in patients treated in the Bratislava Burn Center during the years 1994 - 1996.

MATERIAL AND METHODS

The sources of information for creating a database were records from burn wound off-prints and burn wound biopsy examinations which were performed in the State Institute of Health in Bratislava - Ružinov by Dr. Leon Langšádl. The methods of microbiological examinations were as follows:

Quantitative examinations of burn wound biopsies: Biopsies were taken from vital sites of the burn wounds (not from necrotic parts!). The biopsies were weighed by analytical balances, then they were homogenized in sterile saline diluted by 1:10. The homogenate was diluted again by 1:10 and then evenly spread on the surfaces of blood agar, Mac Conkey agar, and

Saboraud's agar plates. Following an 18 to 24 hour incubation period in an incubator at 37 °C (48 hours with the Saborauds's agar) the bacterial colonies were counted and calculated as the number of microorganisms per 1 g of tissue. Qualitative examinations were done by routine methods used in the laboratory.

Off-print method (semi-quantitative method): Petri-dishes with blood agar were prepared in the laboratory. A square piece of sterile filter paper measuring 3.5 x 3.5 cm was placed on the surface of the plate in the dish. The expiration period of these dishes was 3 days provided they were stored in a refrigerator. The sampling was done as follows. The filter paper piece was removed from the dish with sterile forceps and placed flat on the surface of the wound. It needed to be slightly pressed by the sterile forceps to achieve good contact with the wound surface. Then it was returned back to the dish with the surface that contacted the wound facing the surface of the plate. The dishes were transported to the laboratory, where the paper pieces were removed again by sterile forceps, and the plates were cultivated in an incubator at 37 °C for 18 - 24 hours. Following the cultivation, the number of growing colonies was counted and converted to the approximate number of microorganisms present on 1 cm^2 of the wound surface.

The evaluation of the sensitivity of the microbial strains to antibiotics was done by the disc diffusion method (NCCS, 1994). The calculations of MIC concentrations of antibiotics were done according to the method described by Urbášková (1985). For facilitating the calculations a Slovnet computer program was used. The database was created in the program MS Access and included 675 records. Each record included the following information: patient initials, birth date, date of taking the sample, localisation, diagnosis, and results (qualitative, quantitative, sensitivity).

RESULTS

Of the total of 675 samples evaluated, 331 were found to be sterile (49.04 %). In non-sterile samples a total of 519 microbial isolates were cultured (Fig. 1). A single strain was isolated from 202 samples (58.72 %), two strains in 117 cases (34.01 %), 3 strains in 23 samples (6.69 %) and 4 strains in 2 samples (0.58 %) (Fig. 2). In 135 samples the counts were below the level of 10^5 microorganisms per 1 g of tissue, i.e. 20 % of the positive samples (Fig. 1). In 45 samples a level of 10^5 microorganisms per 1 g of tissue was reached, i.e. 6.65 % of the positive samples; in 163 samples the counts were 10^6 microorganisms per 1 g of tissue, i.e. 24.14 % of the positive samples, and in one case 10^7 microorganisms per 1 g of tissue were found, i.e. 0.14 % of the positive samples.

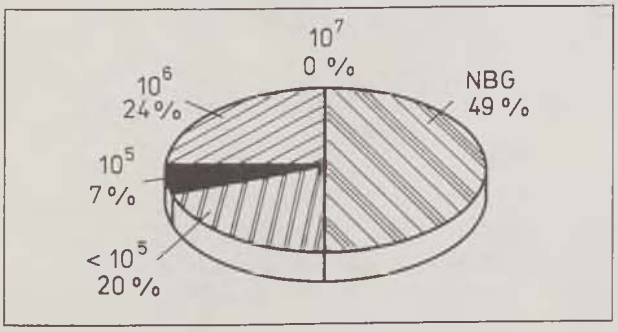

Fig. 1. Quantitative bacterial counts (total No. = 675; NBG = no bacterial growth).

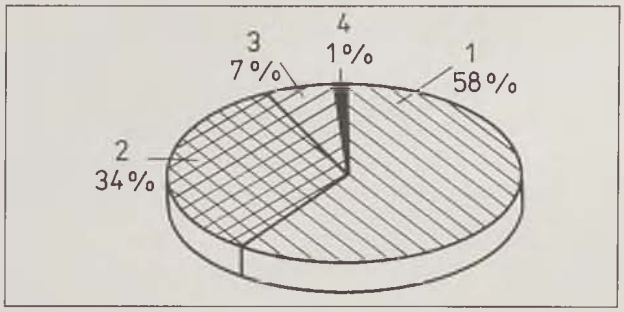

Fig. 2. Number of bacterial strains isolated from one biopsy (off-print sample).

The most frequently found isolate was Staphylococcus epidermidis in 24.5 % of the samples, followed by Staphylococcus aureus (16 %), closer non-identified non-fermenting bacilli ninfb (14 %), Enterococcus faecalis (10.5 %), Pseudomonas aeruginosa (9.5 %), and Acinetobacter Baumanii (7 %) (Fig. 3). E. coli was found in 5,5 % of the samples, Bacillus spp. in 3 %. Strains like Enterobacter cloacae, Proteus mirabilis, Klebsiella spp., and Corynebacterium spp. were rarely found (occurence between 1-2 %). The occurrence of other isolates was below 0,5 % (Tab. 1).

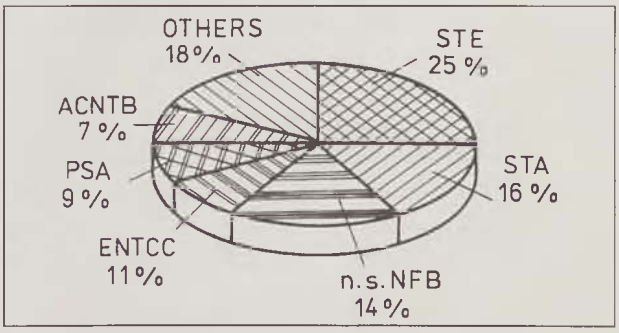

Fig. 3. Most frequently isolated strains.

Table 1. Less frequently isolated strains

E. coli	5,59 %
Bacillus sp.	3,08 %
Corynebacterium sp.	1,73 %
Enterobacter cloacae	1,35 %
Proteus mirabilis	1,34 %
Serratia marcescens	0,96 %
Hafnia alvei	0,77 %
Candida albicans	0,58 %

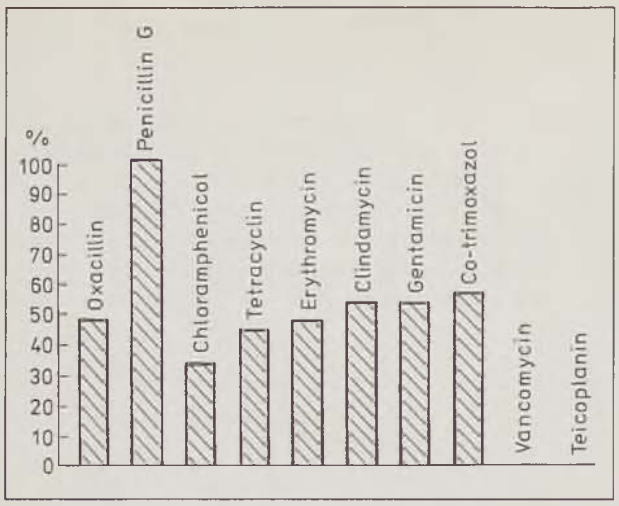

Fig. 4. Resistance rate (%) of Staphylococcus aureus.

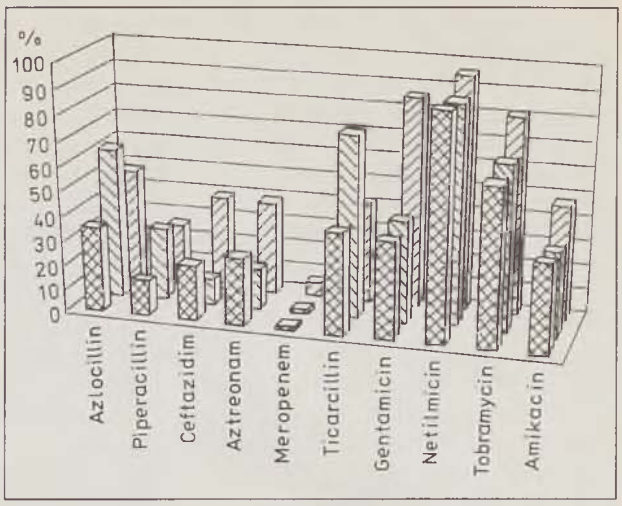

Fig. 6. Resistance rate (%) of Pseudomonas aeruginosa in 1994, 1995 and 1996.

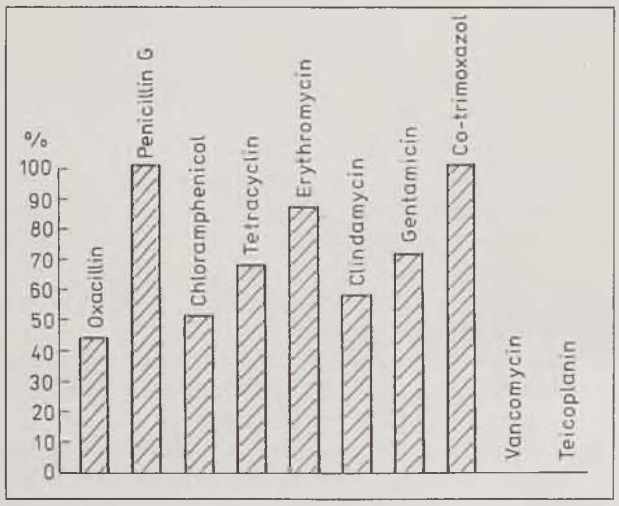

Fig. 5. Resistance rate (%) of Staphylococcus epidermidis.

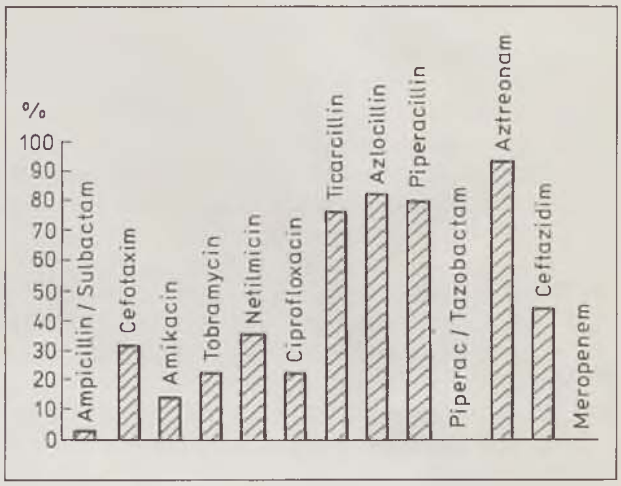

Fig. 7. Resistance rate (%) of Acinetobacter.

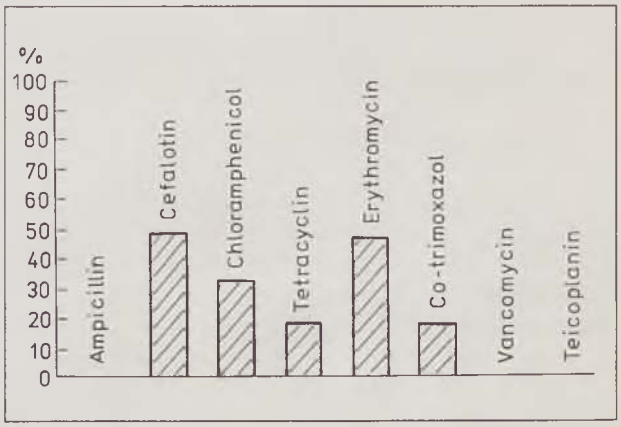

Fig. 8. Resistance rate (%) of Enterococcus faecalis.

The resistance of the particular isolates to antibiotics was as follows: Staphylococcus aureus strains were of 100 % resistant to Penicillin G, and 47 % were resistant to Oxacillin (Meticillin). The sensitivity to Erythromycin, Gentamicin and Clindamycin was similar, the sensitivity to Chloromycetin was 52%. The sensitivity of the strains to Vancomycin and Teicoplanin remained at 100 % (Fig. 4).

The situation was similar with strains of Staphylococcus epidermidis, but the resistance of the strains to the majority of antibiotics was higher than in Staphylococcus aureus isolates. The efficacy of Vancomycin and Teicoplanin remained at 100 % (Fig. 5).

The strains of Pseudomonas aeruginosa were resistant to Tobramycin and Netilmicin. The resistance to Gentamicin increased from year to year (40 % in 1994, 42 % in 1995, 86 % in 1996). The sensitivity to Meropenem was 95%, and to a combination of Piperacillin with Tazobactam, 93%. The frequency of resistant strains to Piperacillin, Ceftazitim, and Aztreonam was relatively the same during the whole period (Fig. 6).

In the isolates of Acinetobacter, high resistance to Aztreonam, Azlocillin and Ticarcillin was found. The sensitivity was very good to combinations of Piperacillin with Tazobactam, and Ampicillin with Sulbactam (only 2 % resistant

strains). The best efficacy was achieved by Meropenem with 100 % of strains being sensitive (Fig. 7).

The isolates Enterococcus faecalis were all resistant to Gentamicin. However, the sensitivity to Ampicillin was 92%, and to Co-trimoxazol, 84%. The sensitivity to both Vancomycin and Teicoplanin was 100% (Fig. 8).

DISCUSSION

Before the Second World War the leading cause of death in burn patients was streptococcal infection. In Great Britain streptococci caused 75 % of the fatalities (Frame, 1992). Streptococci as a cause of deaths could be eliminated successfully by the discovery and use of penicillin. The occurrence of streptococci in our patients was very low, which we attribute to the routine use of penicillin prophylaxis in all extensive burns for the initial 5 days. Streptococci could usually be found only in patients in whom treatment of the wounds was delayed (no treatment, or home treatment for the first few days), or in patients transferred from another facilities. The correlation between quantitative and qualitative burn wound biopsy culture and surface swabs is so far still not clear (Steer, 1996). With regard to these results we were not able to find any clinical correlation as well.

Recent studies have shown, that in burns the following microorganisms have been isolated most frequently: the occurrence of Staphylococcus aureus strains varied between 25 - 70 %, for Pseudomonas aeruginosa the range was 25 - 45 %, for E. coli 4 - 30 %, Proteus mirabilis 15 - 20 %, Klebsiella sp. 4 - 10 %, Enterobacter cloacae 5 - 18 %, and Enterococcus spp. 4 - 20 % (Donati, 1993).

Studies from the USA have shown a rapid increase in Staphylococcus aureus strains resistant to penicillin, which caused many problems in the 50's. The same situation occurred after the institution of Meticillin into clinical practice. Meticillin-resistant Staphylococcus aureus (MRSA) was the most frequently isolated microorganism in burn centres in the years 1977 - 1988 (Smith, 1992) and still can cause many problems in burn centres (Lesseva, 1996; Holder, 1998). The situation at that time was also very similar in British burn centres (Frame, 1992; Cook, 1998), particularly in pediatric patients. Conversely, Reardon (1998) in his study reports that the occurrence of MRSA was not associated with increased morbidity or mortality in burn patients. Donati (1992) reported the occurrence of staphylococci to be 21% (Fig. 9). In our patients Staphylococcus aureus represented 16 % of the isolates and the resistance to meticillin was at a level close to 50 %. Fortunately, these strains still retained their 100% sensitivity to Vancomycin and Teicoplanin.

During the years 1984 - 1988 there was a relatively rapid increase in the occurrence of enterococci in the USA (Smith, 1992). In our patients they represented 11 % of the isolates, a similar occurrence was reported in the British study (Frame, 1992), Donati reported 15 % (1992).

In the 70's the predominant strains in burn centres were Staphylococcus aureus and Pseudomonas sp., particularly in the USA (Smith, 1992). Recently their frequency has been decreasing, and they are being replaced by other strains, such as Acinetobacter, Enterobacteriaceae, and Serratia spp. (Edgar, 1997). In Donati's report the occurrence of Pseudomonas sp. was 25 %, in our patients it was 10 %, which seems to be relatively low. We can partly explain this by the fact that the methods of treatment which are used in our centre for deep burns prefer early excisions and immediate grafting of the burn wounds. A different situation seems to exist in India, where Pseudomonas sp. was the most frequently (36 %) isolated microorganism (Revathi, 1998). The occurrence of Proteus, Serratia, and Klebsiella spp. in our patients was as low as 2 %.

In the 70's and 80's there was a gradual increase of candida infections from 11.5 % to 20 % in American burn centres. In our patients candida represented only about 1 % of the infections. We can explain this by the routine use of antimycotic agents (miconazol) in all severely burned patients who are treated by systemic antibiotics.

CONCLUSIONS

Our findings are in accordance with the trends towards a decreased contribution of „classical pathogens", like Staphylococcus aureus and Pseudomonas aeruginosa, to burn wound infec-

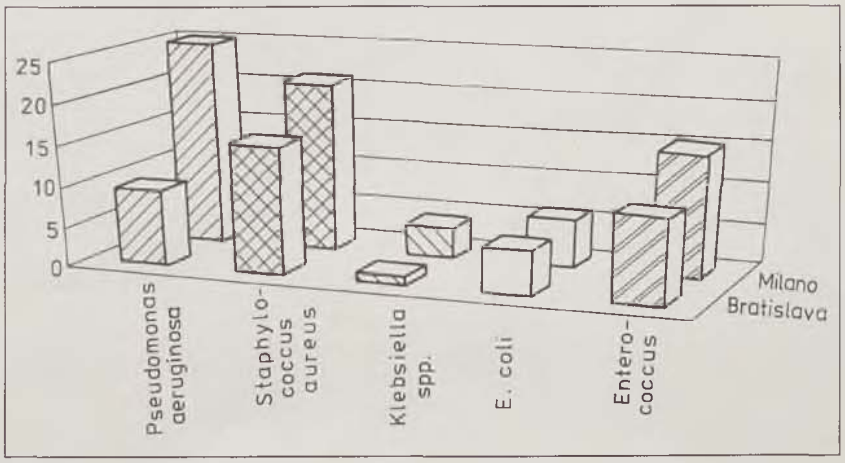

Fig. 9. Comparison of isolated strains Bratislava vs. Milano (data for Milano: Donati et al., 1992).

tions. The role of „other pathogens“, like Enterobacter, Acinetobacter, etc., which were quite rare in the past, is, on the other hand, increasing. We would partly explain this by the increasing rate of early surgical treatment of deep burns. When we compare our results with the results of other similar studies, our results seem closest to those of Donati's (1992) study (Fig. 9).

REFERENCE

1. Cook, N.: Methicillin-resistant Staphylococcus aureus versus the burn patient. Burns, 24: 91-98, 1998.
2. Disk Susceptibility Tests. Fifth Edition, NCCLS document M2-A5, 1994 NCCLS, 771 East Lancester Avenue, Villanova, Pennsylvania, USA.
3. Donati, L., Scamazzo, F., Gervasoni, M., Magliano, A., Stankov, B., Fraschini, F.: Infection and antibiotic therapy in 4000 burned patients treated in Milano, Italy, between 1976 and 1988. Burns, 19: 345-348, 1993.
4. Edgar, P., Mlcak, R., Desai, M., Linares, H. A., Phillips, L. G., Heggers, J. P.: Containment of multiresistant Serratia marcescens outbreak. Burns, 23: 15-18, 1997.
5. Frame, J. D., Kangesu, L., Malik, W. M.: Changing flora in burn and trauma units: experience in the United Kingdom. J. Burn Care Rehabilitation, 13: 281-286, 1992.
6. Holder, I. A., Neely, A. N.: Fear of MRSA - potential for future disaster. Burns, 24: 99-103, 1998.
7. Königová, R., et al.: Rozsáhlé popáleninové trauma. Avicenum, Praha, 1978, pp. 121-179.
8. Lesseva, M. I., Hadjiiski, O. G.: Staphylococcal infections in the Sofia Burn Centre, Bulgaria. Burns, 22: 279-282, 1996.
9. Reardon, C. M., Brown, T. P., La, H., Stephenson, A. J., Freedlander, E.: Methicillin-resistant Staphylococcus aureus in burns patients - why all the fuss? Burns, 24: 464-470, 1998.
10. Revathi, G., Puri, J., Jain, B. K.: Bacteriology of burns. Burns, 24: 347-349, 1998.
11. Smith, D. J., Thomson, P. D.: Changing flora in burn and trauma units: historical experience in the United States. J. Burn Care Rehabilitation, 13: 276-280, 1992.
12. Steer, J. A., Papini, R. P. G., Wilson, A. P. R., McGrouther, D. A., Parkhouse, N.: Quantitative microbiology in the management of burn patients. I. Correlation between quantitative and qualitative burn wound biopsy culture and surface alginate swab culture. Burns, 22: 173-176, 1996.
13. Steer, J. A., Papini, R. P. G., Wilson, A. P. R., McGrouther, D. A., Parkhouse, N.: Quantitative microbiology in the management of burn patients. II. Relationship between bacterial counts obtained by burn wound biopsy culture and surface alginate swab culture, with clinical outcome following burn surgery and change of dressings. Burns, 22: 177-181, 1996.
14. Šimko, Š., Koller, J., et al.: Popáleniny, Osveta, Bratislava, 1992, pp. 17-36.
15. Urbášková, P.: Vyšetření pro antimikrobiální terapii. Avicenum, Praha, 1985, p. 150.

Address for corresopndence:

Ján Koller
Centre for Burns and Reconstructive Surgery
Ružinov General Hospital
Ružinovská 6
826 00 Bratislava
Slovakia

ACTA CHIRURGIAE PLASTICAE 41, 4, 1999, pp. 117 - 119

SPHERICAL DILATORS TO RESOLVE ARTERIAL SPASM

Meyer V. E., Smahel J., Valka J.

Division of Reconstructive Surgery, University Hospital, Medical School, Zurich, Switzerland

SUMMARY

Arterial spasms developing during microsurgical vascular anastomoses can be a difficult problem. We have been using specially developed spherical dilators in clinical practice to remove spasm that do not respond to the application of warm saline with lidocain. Dilating the spastic segment of the vessel two or three times with the instrument will usually relieve the spasm. Experimental testing of the method on the rat carotid artery has shown that using the dilator three times causes only moderate damage to the endothelium, which is largely overcome within one week. Thrombosis of the dilated artery was never seen in experimental studies and clinical use.

ZUSAMMENFASSUNG

Dilatation spastischer Arterien mit Kugelkopfsonden

Meyer V. E., Smahel J., Valka J.

Das Auftreten des arteriellen Spasmus bei der Durchführung von mikrochirurgischen Gefässanastomosen kann ein schwieriges Problem darstellen. Seit 6 Jahren verwenden wir in der Klinik zur Behebung des Spasmus, welcher auf die Applikation von warmer Kochsalzlösung mit Lidocaine nicht anspricht, speziell zu diesem Zweck entwickelte Kugelkopfsonden. Die zwei- bis dreimalige Dilatation des spastischen Gefäßsegmentes mit der Sonde reicht gewöhnlich zur Behebung des Spasmus. Die experimentelle Prüfung der Methode an der Arteria carotis der Ratte zeigte, daß die dreimalige Dilatation mit der Sonde nur eine mässige Schädigung des Endothels zur Folge hat, die innert einer Woche weitgehend behoben wird. In keinem Fall, weder im Experiment noch in der Klinik, ist es zur Thrombose der dilatierten Arterie gekommen.

Key words: microvascular anastomosis, arterial spasm, use of spherical dilator

Spasm of the artery can make it more difficult to create an arterial micro-anastomosis and can seriously endanger its function. Spasms in the proximal segment of the artery, outside the surgical field, are a particular problem. Application of warm saline with lidocain will normally relax the spasm, but fails to do so in some cases. Over the last 6 years we have dilated the artery with a spherical dilator in this case, using an instrument specially designed for the purpose.[1]

The sounds have a handle about 6 cm in length and terminate in a sphere (Fig. 1). Four sizes proved sufficient: 0.5, 1, 1.4 and 2 mm. The spherical heads of the stainless steel instruments are finely polished, with the surface improved using a special process. The size of dilator chosen corresponds to the artery in question in its dilated state. Opening the vessel with micro-forceps makes it easier to introduce the dilator. It is then moved to and fro 2 or 3 times in the spastic artery segment. In our experience, this is sufficient to relax the spasm and restore flow.



Fig. 1. Set of spherical dilators.

The endothelium is known to react very sensitively to any kind of mechanical manipulation. To estimate the risk of endothelial denudation and subsequent thrombosis, the effects of dilatation

[1]Manufacured by S & T Marketing Ltd, Zollstrasse 91, CH-8012 Neuhausen am Rheinfall, Switzerland

Fig. 2. Fibrin nets with captured blood cells, 1 hour after dilatation (SEM, x450).

Fig. 3. Denuded part of intima with endothelial regeneration in margin, 3 days after dilatation (SEM, x450).

Fig. 4. Restoration of endothelial lining with typical intima profile, 7 days after dilatation (SEM, x450).

with spherical dilators were tested experimentally.

EXPERIMENTAL STUDIES

The dilator was tested on the rat carotid artery. The artery was dissected out on one side in 15 animals and partly cut close to a distally placed clamp. The opening of the artery, which was in spasm, was widened and a dilator of the required diameter introduced into the lumen to a distance of 12 mm, pushing it to and fro three times. We then closed the vascular wall with a 10-0 nylon suture. The surgical intervention ended with the release of the clamp and suturing of the skin. The dilated vascular segments were removed for scanning electron microscopy (SEM) 1 hour, 3 days and 7 days after the operation. 5 arteries were available on each occasion. The same operation was used on 3 more animals who served as controls, but without dilating the vessel. In this group the vessel was removed for examination 3 days after the operation.

All arteries under investigation showed active flow prior to removal. In the controls, the intimal profile was intact, with no pathological changes. In the dilated arteries, fine fibrin nets had developed on the wall 1 hour after the operation, with blood cells held in them (Fig. 2). Endothelial cells had ablated in places. Examination on the third day after the intervention showed denuded areas of the intima with active regeneration beginning in the margins (Fig. 3). On the 7th day after the intervention, the pathological changes in the intima had largely disappeared, with continuity of the endothelial lining restored (Fig. 4).

DISCUSSION

In both experimental and clinical work, dilatation of spastic arteries with a spherical dilator proved a technically simply method of relaxing arterial spasm outside of the surgical field. Use of the dilator on the rat carotid artery showed that the moderate damage to the intima caused by dilatation repeated three times had largely disappeared after one week. Parallel to our clinical experience, we did not see thrombosis of the artery in any of the animals. The pathophysiologic processes that developed in the intima after dilatation were very similar to those we observed after applying micro clamps (1). In principle our observations also agree with the de-

tailed studies of intima regeneration after mechanical denudation (2-5). The pathophysiologic processes described in those studies were, however, much more serious, as damage to the intima was also more profound. Haudenschild and Schwartz (4), for example, repeated dilatation with a balloon catheter eight times, but also did not see thrombi develop. This suggests that our practice of dilating three times is well below the critical level.

In our view, spherical dilators are a useful addition to the microsurgical armamentarium.

Acknowledgment

SEM examinations were performed in the Research Division of the Department of Surgery, with support from EMDO and the Emil Barrel Foundation. We are indebted to Mr. K. Marquart for his technical assistance.

REFERENCES

1. Smahel, J., Meyer, V. E.: Pathophysiological processes in the wall of small arteries produced by microvascular clamps. Int. J. Microsurg., 3: 199, 1981.
2. Fishman, J. A., Ryan, G. B., Karnovsky, M. J.: Endothelial regeneration in the rat carotid artery and the significance of endothelial denudation in the pathogenesis of myointimal thickening. Lab. Invest., 32: 339, 1975.
3. Schwartz, S. M., Stemerman, M. B., Benditt, E. P.: The aortic intima. II. Repair of the aortic lining after mechanical denudation. Am. J. Pathol., 81: 15, 1975.
4. Haudenschild, C. C., Schwartz, S. M.: Endothelial regeneration. II. Restitution of endothelial continuity. Lab. Invest., 41: 407, 1979.
5. Christensen, B. C., Chemnitz, J., Tkocz, I., Kim, C. M.: Repair in arterial tissue. I. Endothelial regrowth, subendothelial tissue changes and permeability in the healing rabbit thoracic aorta. Acta Pathol. Microbiol. Scand., 87A: 265, 1979.

Address for correspondence:

Dr. J. Smahel
Okenstrasse 8
CH-8037 Zurich
Switzerland

ACTA CHIRURGIAE PLASTICAE 41, 4, 1999, pp. 120 - 122

A MODIFIED STAINING METHOD FOR CONNECTIVE TISSUE IN SEMI-THIN HISTOLOGICAL SECTIONS OF PERIPHERAL AND CRANIAL NERVES

Menovsky T.[1], *van den Bergh Weerman M.*[2]

[1]Department of Neurosurgery, University Hospital Nijmegen St. Radboud, Nijmegen, The Netherlands
[2]Department of Pathology, Academic Medical Center, Amsterdam, The Netherlands

SUMMARY

A simple staining method for collagen in semi-thin sections of nerves is described. This technique consists of applying basic fuchsin (0.05%) solution for 2 min. to ± 1.25 µm plastic resin-embedded sections after routine toluidine blue staining. This staining method clearly demonstrates the amount and orientation of collagenous connective tissue in the nerve, both in transverse and longitudinal sections.

ZUSAMMENFASSUNG

Die modifizierte farbende Methode für das Bindungsgewebe bei den mitteldünnen histologischen Schnitten der peripheren und kranialen Nerven

Menovsky T., van den Bergh Weerman M.

Es wird beschrieben die einfache farbende Methode für Kolagen bei den mitteldünnen Nervenschnitten. Diese Technik basiert auf der Applikation der basischen Lösung des Fuchcins (0,05%) für 2 Minuten auf ± 1,25 µm starke Schnitte, die nach der vorgehenden routinen Färbung durch das Toluidblau im Kunstharz eingelassen sind. Die beschriebene farbende Methode erweist eindeutlich die Menge und Orientation des kolagenen Bindungsgewebe im Nerv, sowohl in den Queren-als auch in den Längschnitten.

Key words: basic fuchsin, collagen, histology, nerve, toluidine blue

INTRODUCTION

Light microscopic examination of peripheral nerves has been one of the most important methods for evaluating the results of experimental studies on cranial and peripheral nerve injury, repair, and regeneration. Most commonly, after harvesting and fixation of the nerve, the specimen is either embedded in paraffin or in an epoxy resin.

The plastic resin-embedded specimens have the advantage that the sections are very easily stained with toluidine blue. In these sections, the myelin sheaths with axons within appear like rings. Therefore it is an excellent staining method for evaluating axonal regeneration with the feasibility to perform nerve morphometry, including axonal count, myelinated fiber diameter, and myelinated nerve fiber density. Also, the blood vessels are easily interpreted on these sections. Another advantage is that plastic resin-embedded specimens can be cut and processed for transmission electron microscopy, while this is not possible with paraffin-embedded specimens without deparafination (1). The disadvantage of plastic resin-embedded specimens is that only a limited number of staining methods can be applied. In particular, those which specifically stain collagenous tissue are missing. This is of importance, as collagenous tissue in nerves has an important impact on regeneration after nerve repair (5).

In this technical note, we report on a supplementary staining method for collagenous tissue in toluidine blue-stained sections of peripheral and cranial nerves.

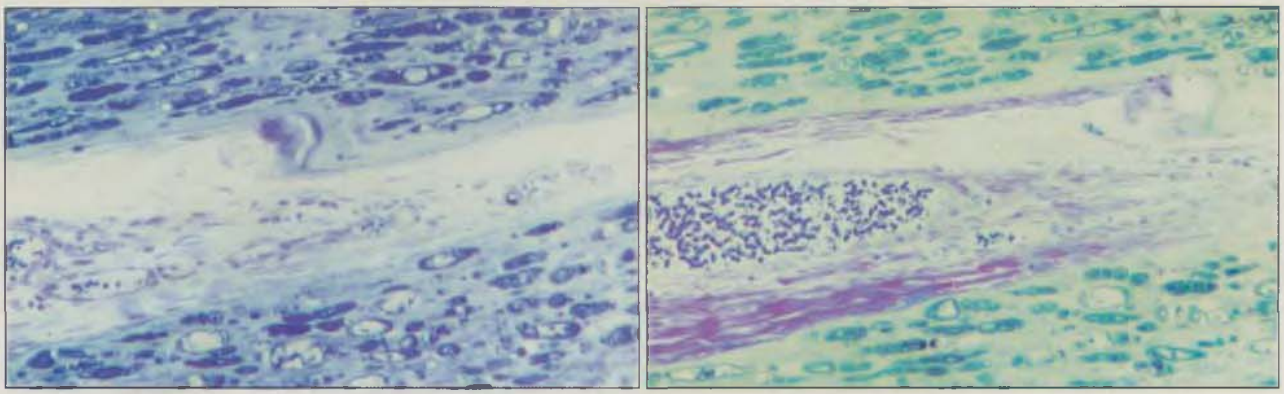

1a) 1b)

Fig. 1. Longitudinal section of a degenerating rat sciatic nerve: **a** - routinely stained toluidine blue section, **b** - toluidine blue section with addition of basic fuchsin stain. Note the reddish color of the epi/perineurium containing collagen (original magnification x 100).

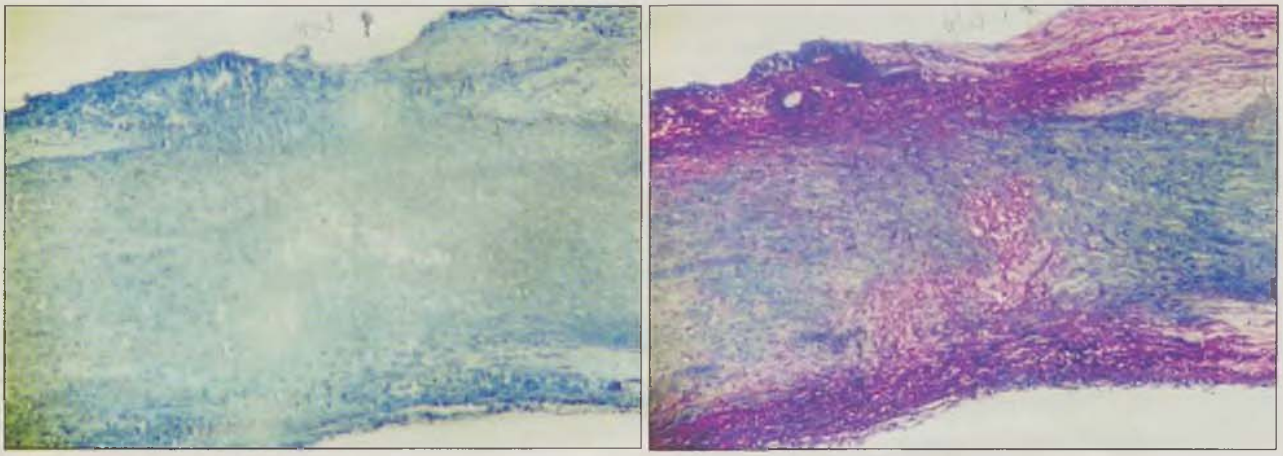

2a) 2b)

Fig. 2. Longitudinal section of the rat sciatic nerve one week after surgical repair: **a** - routinely stained toluidine blue section, **b** - toluidine blue section with addition of basic fuchsin stain. Note the proliferating connective tissue (reddish) at the repair site protruding intraneurally, while the axons are stained blue (original magnification x 40).

MATERIALS AND METHODS

The nerves, fixed in Karnovsky's fixative, are postfixed in 1% osmium tetroxide, stained with uranyl acetate, dehydrated in acidified 2,2-dimethoxypropane (4), and embedded in Epon. After hardening, semi-thin cross-sections are cut (1.25 - 2 μm) and stained with 1% toluidine blue solution (Toluidine blue, Fluka Chemika A. G., Buchs, Swiss). Thereafter, basic fuchsin solution 0.1% (Fuchsin, Chroma-Gesellschaft, Schmidt, Germany) is made from 100 ml near-boiled distilled water. The histological slice is flooded with the basic fuchsin solution for approximately 30 - 45 s, flushed with distilled water, and allowed to dry on a 60 - 80 °C hot plate and mounted as desired.

RESULTS AND DISCUSSION

A toluidine-stained nerve, with and without supplementary staining with basic fuchsin, is shown in figures 1 and 2. As can be seen, connective tissue hardly stains differently from nervous tissue in toluidine blue-stained sections. In sections with basic fuchsin, connective tissue is seen as reddish. Having stained and examined over 400 nerve specimens after surgical repair or laser injury in the rat sciatic and oculomotor nerve (3), it is the opinion of the authors that this supplementary staining technique is valuable in evaluating intraneural and extraneural scar tissue.

The staining procedure is fast and can be well combined with toluidine blue, without impairing the staining qualities of the individual stains, and adds information about the collagen content. This small modification requires just 2 min. more work per slice (out of approximately 5 min. total time for toluidine blue staining) and is a valuable addition.

It must be emphasized that this staining technique is not new. A modified version has been described earlier (2); nevertheless, to our knowledge it is not widely used for cranial and peri-

pheral nerves. Also, we are not aware of any report in the neurosurgical and microsurgical literature, using this staining technique. The goal of this technical report is to call attention to this stain for those clinical readers who have little access or knowledge of histological staining methods.

In conclusion, the basic fuchsin stain is a very easy and simple additional staining method of collagenous tissue in semi-thin sections of nerves. This staining method can be recommended to all involved in peripheral and cranial nerve research.

REFERENCES

1. Dingemans, K. P., van den Bergh Weerman, M. A.: Rapid contrasting of extracellular elements in thin sections. Ultrastruct. Pathol., 14: 519-527, 1990.
2. Humphrey, C. D., Pittman, F. E.: A simple methylene blue-azure II-basic fuchsin stain for epoxy-embedded tissue section. Stain Technol., 49: 9-14, 1974.
3. Menovsky, T.: Laser-assisted nerve repair. An experimental study. Thesis, University of Amsterdam, 1999.
4. Muller, L. L., Jacks, T. J.: Rapid chemical dehydration of samples for electronmicroscopic examinations. J. Histochem. Cytochem., 23: 107-110, 1975.
5. Samii, M., Wallenborg, R.: Tierexperimentelle Untersuchungen über den Einfluß der Spannung auf den Regenerationserfolg nach Nervennaht. Acta neurochir., 27: 87-110, 1972.

Address for correspondence:

Tomas Menovsky
Department of Neurosurgery
University Hospital Nijmegen St. Radboud
P.O. Box 9101, 6500 HB Nijmegen
The Netherlands

SOUHRNY

Infiltrační technika u redukující mamoplastiky. Výsledky 192 posloupných operací prsů

O'Donoghue J. M., Chaubal N. D., Haywood R. M., Rickard R., Desai S. N.

Použití infiltrace lokální anestezie s adrenalinem je nyní považováno za bezpečnou metodu při redukující mamoplastice. Nicméně, tato technika bývá často těmi, kteří ji používají, popisována nejasně.

Každá technika, má-li být efektivní, musí vzít v potaz neurovaskulární anatomii prsu. Navrhujeme užití velkého objemu zředěného lokálního anestetika (20 mililitrů 1% lignokainu a 1 mg adrenalinu namíchat do 400 ml 0,9% fyziologického roztoku), který je uvážlivě aplikován do retroglandulárního prostoru 15 minut před chirurgickým zákrokem.

U 96 pacientů (192 prsou), u nichž byla použita technika dolní stopky, byly analyzovány výsledky. Procento prsních komplikací bylo 9,36 %, procento komplikací u pacientů 19,7 %. Pooperační krevní ztráta kolísala od 0 do 305 ml, s průměrem 56,03 ml a mediánem 50 ml.

Popsaná metoda může být považována za variaci na techniku způsobující zduření, používanou při liposukci. Výsledkem je téměř nekrvavý řez s minimální pooperační krevní ztrátou.

Přesné sevření u vrozené hypoplazie nebo hypofunkce palce ruky

Smrčka V., Dylevský I., Kuklík M.

U čtyř pacientů s vrozenými defekty ruky s hypoplastickým palcem nebo palcem s poškozenou inervací jsme testovali sevření. Malé předměty byly uchopovány nůžkovitým sevřením mezi prsty. V ruce s radiální dukcí manus vara congenita během posílení zápěstí bylo sevření z ulnární strany mezi čtvrtým a pátým prstem změněno k radiální straně mezi druhým a třetím prstem. Široké předměty byly uchopovány všemi třemi falangami prstů do dlaně ve vodorovné poloze. U čtvrtého případu s hypoplazií palce stupně IIIC klasifikace Blautha a Buck-Gramcka popisujeme transpozici ukazováčku ke straně palce a hypoplastického palce na místo ukazováčku. Je zřejmé, že přesné sevření je ovlivněno délkou palce a posílením ulnární strany zápěstí. Nůžkovité sevření považujeme za nejstarší přesné sevření v evoluci ruky primátů.

Změny profilu infekce v Bratislavském popáleninovém centru

Koller J., Boča R., Langšádl L.

Jedním z hlavních problémů při léčbě popálenin stále zůstává infekce. Autoři vyšetřovali výskyt patogenů v popáleninových ranách z biopsií z popáleninových ran nebo semikvantitativních separátů ranných povrchů. Prokázali trend snižujícího se podílu „klasických patogenů", jako Staphylococcus aureus a Pseudomonas aeruginosa, v infikovaných popáleninových ranách. Úloha „ostatních patogenů", jako Enterobacter, Acinetobacter atd., které byly v minulosti zcela vzácné, byla naopak stoupající. Jedním z vysvětlení může být zvětšující se podíl časných chirurgických léčebných metod u hlubokých popálenin. Výsledky jsou ve shodě s podobnými studiemi z dalších popáleninových center.

Sférický dilatátor k odstranění arteriálního spazmu

Meyer V. E., Smahel J., Válka J.

Arteriální spazmus vznikající během mikrochirurgických vaskulárních anastomóz může být závažným problémem. V klinické praxi k odstranění spazmu, který nereaguje na aplikaci te-

plého solného roztoku s lidokainem, užíváme speciálně vyvinuté sférické dilatátory. Dvojnásobná nebo trojnásobná dilatace spastického segmentu cévy tímto zařízením zpravidla spazmus uvolní. Experimentální testování této metody na arteria carotis u krysy ukázalo, že trojnásobné použití dilatátoru způsobí jenom mírné poškození endotelu, které je zhojeno během jednoho týdne. Trombóza dilatované arterie nebyla v experimentálních studiích ani klinických situacích nikdy pozorována.

Modifikovaná barvicí metoda pro pojivovou tkáň u polotenkých histologických řezů periferních a kraniálních nervů

Menovsky T., van den Bergh Weerman M.

Je popsána jednoduchá barvicí metoda pro kolagen u polotenkých řezů nervů. Tato technika je založena na aplikaci bazického roztoku fuchcinu (0,05%) po 2 minuty na ± 1,25 μm silné řezy zapuštěné do umělé pryskyřice po předcházejícím rutinním barvení toluidinovou modří. Popsaná barvicí metoda jasně prokazuje množství a orientaci kolagenní vazivové tkáně v nervu, jak v příčných, tak i v podélných řezech.

BOOK REVIEW

Head and Neck Surgery. Vol. 3: Neck

Edited by W. R. Panje, C. Herberhold, Georg Thieme Verlag, Stuttgart - New York 1998

The monograph is the third volume of an extensive publication devoted to head and neck surgery. Part one deals with surgery of the face, facial bones and the nose, part two with the ear. More than 20 years have elapsed since the publication of the first German edition. During that period surgery has undergone great development, many surgical procedures were revised and innovated. A five-hundred-page publication on the contemporary state of diagnosis and surgery has been revised. Surgery of the neck comprises a great scope and number of surgical procedures. For the anatomy of the neck the presence of various tissues such as bones, muscles, blood vessels, lymphatic vessels, nervous tissues and glands is typical. Structures of the neck comprise also the airways and deglutition pathways.

A multidisciplinary approach is typical for the surgery of the neck. In surgery participate in addition to ENT specialists also vascular surgeons, neurosurgeons, maxillofacial surgeons, general surgeons, plastic surgeons and other specialists. In the submitted publication therefore 30 specialists collaborate, representatives of different disciplines. The whole problem is dealt with in great detail and therefore it will be an inspiration for the beginner as well as the highly experienced specialist. The monograph is divided into 19 chapters and contains 1007 illustrations. A very detailed account is given of oncological problems by different anatomical sites.

Advances in the surgery of the neck were influenced in a major way by the development of laser technology. Two chapters are devoted to laser surgery of the upper airways and deglutition pathways. This surgery makes it possible to implement operations with a reduced morbidity. Endoscopy to which one chapter is devoted enables the surgeon to implement aimed and accurate operations of the airways and deglutition pathways.

For the surgery of the neck modern imaging methods are essentials as they help to make the indication and planning of surgical intervention. The chapter devoted to intervention radiology demonstrates possibilities of surgery after embolization of highly vascularized tissues and even of the internal carotid artery.

For the plastic surgeon the part of the publication devoted to reconstruction of the neck will be of great interest. Various approaches are outlined, from the modification of scars after reconstruction with skin flaps, e.g. the deltopectoral, as well as myocutaneous flaps in particular from the m. pectoralis major, and also the trapezius and m. latissimus dorsi. In this chapter special attention is devoted to reconstruction of the oesophagus by means of skin flaps, but also flaps from the jejunum, stomach and other sites.

Interesting is also the neurosurgically oriented chapter devoted to surgery of the cervical spine. Otorhinolaryngologists will appreciate in particular chapters devoted to surgery of the larynx, rehabilitation of the voice and others.

As the team of authors is multidisciplinary it may be stated without exaggeration that in the submitted monograph useful information can be found by all who are concerned with the surgery of the neck.

Jiří Kozák, M. D.

ANNALS OF BURNS AND FIRE DISASTERS

Official publication of The Mediterranean Club for Burns and Fire Disasters (MBC)

WHO COLLABORATING CENTRE

VOLUME XII NUMBER 2 JUNE 1999

CONTENTS

EDITORS **M. MASELLIS M.D.**
S.W.A. GUNN M.D.

c/o Secretariat of The Mediterranean Club for Burns and Fire Disasters - Divisione di Chirurgia Plastica e Terapia delle Ustioni Ospedale Civico - Via C. Lazzaro - 90127 Palermo, Italy

CONTENTS Vol. 41, 1999

Book review

INDEX
Acta chirurgiae plasticae 41, 1999

ODBORNÉ ČASOPISY
ČESKÉ LÉKAŘSKÉ SPOLEČNOSTI J.E.PURKYNĚ

ROČNÍK 2000

ČASOPIS	PERIOD.	CENA/ČÍSLO Kč	PŘEDPLATNÉ Kč	CENA/ČÍSLO Sk	PŘEDPLATNÉ Sk
Acta chirurgiae plasticae	4 x	71,-	284,-	77,50	310,-
Anesteziologie a neodkladná péče	6 x	57,-	342,-	69,-	414,-
Central European Journal of Public Health	4 x	79,-	316,-	91,-	364,-
Časopis lékařů českých	24 x	28,-	672,-	34,-	816,-
Česká a slovenská farmacie	6 x	67,-	402,-	75,-	450,-
Česká a slovenská gastroenterologie	6 x	60,-	360,-	67,-	402,-
Česká a slovenská neurologie a neurochirurgie	6 x	62,-	372,-	71,-	426,-
Česká a slovenská oftalmologie	6 x	53,-	318,-	60,-	360,-
Česká a slovenská psychiatrie	8 x	41,-	328,-	52,-	416,-
Česká gynekologie	6 x	60,50	363,-	66,50	399,-
Česká radiologie	6 x	61,-	366,-	70,-	420,-
Česká revmatologie	4 x	64,-	256,-	86,-	344,-
Česká stomatologie a Praktické zubní lékařství	6 x	57,50	345,-	68,-	408,-
Česko-slovenská dermatologie	6 x	66,-	396,-	74,-	444,-
Československá fyziologie	4 x	98,-	392,-	100,-	400,-
Česko-slovenská patologie a Soudní lékařství	4 x	94,-	376,-	94,-	376,-
Česko-slovenská pediatrie	12 x	55,-	660,-	60,-	720,-
Endoskopie	4 x	52,50	210,-	62,50	250,-
Epidemiologie, mikrobiologie, imunologie	4 x	59,-	236,-	67,-	268,-
Hygiena	4 x	65,-	260,-	74,-	296,-
Klinická biochemie a metabolismus	4 x	70,50	282,-	78,-	312,-
Lékař a technika	6 x	63,-	378,-	69,50	417,-
Otorinolaryngologie a foniatrie	4 x	69,50	278,-	73,-	292,-
Pracovní lékařství	4 x	69,-	276,-	77,-	308,-
Praktický lékař	12 x	34,-	408,-	42,50	510,-
Rehabilitace a fyzikální lékařství	4 x	63,50	254,-	72,-	288,-
Rozhledy v chirurgii	12 x	71,50	858,-	74,50	894,-
Transfuze	4 x	42,-	168,-	52,-	208,-
Vnitřní lékařství	12 x	60,50	726,-	67,50	810,-
Zdravotní pojištění a revizní lékařství	4 x	80,-	320,-	89,-	356,-

STUDENTI (je nutné doložit potvrzení o studiu):

ČASOPIS	PERIOD.	CENA/ČÍSLO Kč	PŘEDPLATNÉ Kč	CENA/ČÍSLO Sk	PŘEDPLATNÉ Sk
Praktický lékař	12 x	16,-	192,-	21,-	252,-
Česká stomatologie a Praktické zubní lékařství	6 x	29,-	174,-	34,-	204,-
Lékař a technika	6 x	31,50	189,-	35,-	210,-

Objednávky zasílejte na adresu:
Nakladatelské a tiskové středisko ČLS JEP
Sokolská 31, 120 26 Praha 2
tel./fax: 02/249 11 420

KATALOG 2000

kongresů
konferencí
sympozií
přednášek

Vydává
Česká lékařská společnost
J. Ev. Purkyně
Sokolská 31, 120 26 Praha 2
Tel./fax: 02/2491 1420

Dovolujeme si tímto oznámit, že 11. – 14. září 2000 se uskuteční v Praze

12. regionální středoevropská konference IUAPPA a 4. mezinárodní konference „Hodnocení vlivů na životní prostředí".

Adresa webové stránky konference je:
http://congress.cls.cz/iuappa2000

a adresa sekretariátu konference:

Sekretariát konference IUAPPA

Česká lékařská společnost J. E. Purkyně

P.O. Box 88, Sokolská 31

120 26 Praha 2

Tel. 02-297271, 2491 5195-8

Fax: 02-294610, 2421 6836

E-mail: senderova@cls.cz

Veškeré dotazy budou promptně zodpovězeny.

This is to announce that the 12th Regional Central European Conference IUAPPA (International Union of Air Pollution Prevention and Environmental Protection Associations) and 4th International Conference on "Environmental Impact Assessment"

will take place on 11 – 14 September 2000 in Prague, Czech Republic.

The web address of the Conference:
http://congress.cls.cz/iuappa2000

and the address of the Conference Secretariat:

Czech Medical Association J. E. Purkyně

P.O. Box 88, Sokolská 31

120 26 Prague 2, Czech Republic.

Phone: 420-2-297271, 2491 5195-8

Fax: 420-2-294610, 2421 6836

E-mail: senderova@cls.cz

Any questions will be promptly replied.